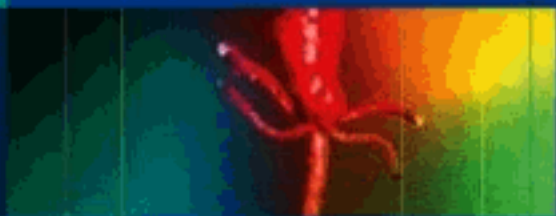


Mark R. Harrigan
John P. Deveikis



Handbook of Cerebrovascular Disease and Neurointerventional Technique

 Humana Press

Contemporary Medical Imaging

For other titles published in this series, go to
www.springer.com/series/7687

Handbook of Cerebrovascular Disease and Neurointerventional Technique

Mark R. Harrigan, M.D.

Department of Surgery, Division of Neurosurgery
and Department of Radiology
University of Alabama, Birmingham, USA


John P. Deveikis, M.D.

Department of Imaging Sciences
and Department of Neurosurgery
University of Rochester, Rochester, USA

With a chapter on ischemic stroke by:

Agnieszka Anna Ardelt, M.D., Ph.D.

Department of Neurology
University of Alabama, Birmingham, USA

 **Humana Press**

Mark R. Harrigan
Department of Surgery
Division of Neurosurgery
Department of Radiology
University of Alabama, Birmingham
Alabama
USA
mharrigan5@hotmail.com

John P. Deveikis
Department of Imaging Sciences
Department of Neurosurgery
University of Rochester
Rochester, NY
USA
jdeveikis@hotmail.com

ISBN 978-1-58829-755-6 e-ISBN 978-1-60327-125-7
DOI 10.1007/978-1-60327-125-7
Springer Dordrecht Heidelberg London New York

Library of Congress Control Number: 2008938655

© Humana Press, a part of Springer Science+Business Media, LLC 2009

All rights reserved. This work may not be translated or copied in whole or in part without the written permission of the publisher (Humana Press, c/o Springer Science+Business Media, LLC, 233 Spring Street, New York, NY 10013, USA), except for brief excerpts in connection with reviews or scholarly analysis. Use in connection with any form of information storage and retrieval, electronic adaptation, computer software, or by similar or dissimilar methodology now known or hereafter developed is forbidden.

The use in this publication of trade names, trademarks, service marks, and similar terms, even if they are not identified as such, is not to be taken as an expression of opinion as to whether or not they are subject to proprietary rights.

While the advice and information in this book are believed to be true and accurate at the date of going to press, neither the authors nor the editors nor the publisher can accept any legal responsibility for any errors or omissions that may be made. The publisher makes no warranty, express or implied, with respect to the material contained herein.

Cover illustration: Mark R. Harrigan

Printed on acid-free paper

Springer is part of Springer Science+Business Media (www.springer.com)

ACKNOWLEDGMENTS

The authors wish to express their appreciation to Susan Deveikis for both personal support and for making things happen in the neuroendovascular suite. In addition, many thanks to two great people, Jason and Sabrina Deveikis and the authors' other family members and friends who have been tremendously indulgent and supportive during the demanding professional careers thus far, culminating in completion of this project. David Fisher, who produced the artwork for this book, was a pleasure to work with and did a fantastic job. We also owe a debt of gratitude to the following people who have been important figures in our training and in our careers, or who have helped with the development of this book: William F. Chandler, Joel K. Cure, Winfield S. Fisher III, Alan Fox, Lee R. Guterman, L. Nelson Hopkins, Don Lee, W. Jerry Oakes, Dave Pelz, Martee Posey, Adnan I. Qureshi, Stephen Rudin, Dieter Schellinger, Carl Schott, B. Gregory Thompson Jr., R. Shane Tubbs, Wesley W. Wyatt, and Michael Yester.

ABBREVIATIONS

A-comm	Anterior communicating artery	BNP	Brain natriuretic peptide
ACAS	Asymptomatic Carotid Atherosclerosis Study	BRANT	British Aneurysm Nimodipine Trial
ACCP	American College of Chest Physicians	CAA	Cerebral amyloid angiopathy
ACE	Angiotensin converting enzyme	CABERNET	Carotid Artery Revascularization Using the Boston Scientific FilterWire EX/EZ and the EndoTex NexStent
ACST	Asymptomatic Carotid Surgery Trial	CADASIL	Cerebral autosomal dominant arteriopathy with subcortical infarcts and leukoencephalopathy
ACT	Activated clotting time	cANCA	Circulating antineutrophil-cytoplasmic antibody
ACTH	Adrenocorticotropic hormone	CAPTURE	Carotid Acculink/Accunet Post Approval Trial to Uncover Rare Events
ADC	Apparent diffusion coefficient	CARASIL	Cerebral autosomal recessive arteriopathy with subcortical infarcts and leukoencephalopathy
ADH	Antidiuretic hormone	CaRESS	Clopidogrel and Aspirin for Reduction of Emboli in Symptomatic Carotid Stenosis
ADPKD	Autosomal dominant polycystic kidney disease	CAS	Carotid angioplasty and stenting
AED	Antiepileptic drug	CASANOVA	Carotid Artery Stenosis with Asymptomatic Narrowing: Operation versus Aspirin
AF	Atrial fibrillation	CASES-PMS	Carotid Artery Stenting With Emboli Protection Surveillance-Post-Marketing Study
AHA	American Heart Association	CBC	Complete blood count
AICA	Anterior inferior cerebellar artery also known as	CBF	Cerebral blood flow
ALT	Alanine aminotransferase	CBV	Cerebral blood volume
AMA	Accessory meningeal artery	CCA	Common carotid artery
ANA	Antinuclear antibody	CCF	Carotid-cavernous fistula
ANP	Atrial natriuretic peptide	CCM	Cerebral cavernous malformation
ARCHeR	Acculink for Revascularization of Carotids in High-Risk Patients	CEA	Carotid endarterectomy
ARR	Absolute risk reduction	CI	Confidence interval
ARUBA	A Randomized Trial of Unruptured Brain Arteriovenous Malformations	CK	Creatine kinase
ASA	Aspirin (acetylsalicylic acid); Anterior spinal artery	CK-MB	Creatine kinase - MB isoenzyme (cardiac-specific CK)
ASAN	Atrial septal aneurysm	CM	Cardiomyopathy; centimeter
ASITN	American Society of Interventional and Therapeutic Neuroradiology	CMS	Centers for Medicare and Medicaid Services
ASNR	American Society of Neuroradiology	CNS	Central nervous system
atm	Atmosphere	COSS	Carotid Occlusion Surgery Study
AV	Arterio-venous	CPK	Creatine phosphokinase
AVF	Arteriovenous fistula	CPP	Cerebral perfusion pressure
AVM	Arteriovenous malformation		
BA	Basilar artery		
BE	Bacterial endocarditis		
BEACH	Boston Scientific EPI-A Carotid Stenting Trial for High Risk Surgical Patients		
bFGF	Basic fibroblast growth factor		

Cr	Creatinine	GCS	Glasgow coma scale
CREATE	Carotid Revascularization With ev3 Arterial Technology Evolution	GESICA	Groupe d'Etude des Sténoses Intra-Crâniennes Athéromateuses symptomatiques
CREST	Calcinosis, Raynaud phenomenon, esophageal dysmotility, sclerodactyly, and telangiectasia; Carotid Revascularization, Endarterectomy versus Stenting Trial	GIST-UK	United Kingdom Glucose Insulin in Stroke Trial
CRH	Corticotropin releasing hormone	GP	Glycoprotein
CRP	C-reactive protein	Gy	Gray
CRT	Cathode ray tube	HbF	Fetal hemoglobin
CSC	Comprehensive stroke center	HbS	Hemoglobin S
CSF	Cerebrospinal fluid	HbSS	Hemoglobin S homozygosity
CSW	Cerebral salt wasting	HDL	High density lipoprotein
CTA	CT angiography	HERS	Heart and Estrogen/Progestin Study
CVP	Central venous pressure	HIPAA	Health Insurance Portability and Accountability Act
CVT	Cerebral venous thrombosis	HIT	Heparin-induced thrombocytopenia
dAVF	Dural arteriovenous fistula	HMG CoA	3-Hydroxy-3-methylglutaryl coenzyme A
DMSO	Dimethyl sulfoxide	HRT	Hormone replacement therapy
DPD	Distal protection device	IA	Intra-arterial
DSA	Digital subtraction angiography	ICA	Internal carotid artery
DSPA	<i>Desmodus rotundus</i> salivary plasminogen activator	ICH	Intracranial hemorrhage
DVA	Developmental venous anomaly	ICP	Intracranial pressure
DVT	Deep venous thrombosis	ICSS	International Carotid Stenting Study
DWI	Diffusion weighted imaging	ICU	Intensive care unit
EBV	Epstein Barr virus	IEL	Internal elastic lamina
EC-IC	Extracranial to intracranial	IEP	Intracranial embolization procedure
EC-TRICKS	Elliptical centric time-resolved imaging of contrast kinetics	II	Image intensifier
ECA	External carotid artery	IJ	Internal jugular vein
ECST	European Carotid Surgery Trial	IMA	Internal maxillary artery
EDAMS	Encephalo-duro-arterio-myosynangiosis	IMT	Intima media thickness
EDAS	Encephalo-duro-arterio-synangiosis	INR	International Normalized Ratio
EDS	Ehlers-Danlos Syndrome	IPS	Inferior petrosal sinus
EEG	Electroencephalogram	IPSS	Inferior petrosal sinus sampling
EEL	External elastic lamina	IRB	Institutional Review Board
EJ	External jugular vein	ISAT	International Subarachnoid Aneurysm Trial
EKG	Electrocardiogram	IV	Intravenous
EMG	Electromyography	IVH	Intraventricular hemorrhage
EMS	Encephalo-myo-synangiosis	KSS	Kearns-Sayre Syndrome
EPD	Embolic protection device	LAC	Lacunar stroke
ESPS	European Stroke Prevention Study	LDL	Low density lipoprotein
ESR	Erythrocyte sedimentation rate	LINAC	Linear accelerator
EVA-3S	Endarterectomy vs. Angioplasty in Patients with Symptomatic Severe Carotid Stenosis	LMWH	Low molecular weight heparin
EXACT	Emboshield and Xact Post Approval Carotid Stent Trial	LOC	Level of consciousness; loss of consciousness
F	French	LV	Left ventricle
FDA	Food and Drug Administration	MAC	Mitral annular calcification
FLAIR	Fluid attenuated inversion recovery	MACE	Major adverse cerebrovascular events
FMD	Fibromuscular dysplasia	MATCH	Management of ATherothrombosis with Clopidogrel in High-risk patients
fps	Frames per second	MAVERiC	Medtronic AVE Self-Expanding Carotid Stent System With Distal Protection In the Treatment of Carotid Stenosis

MCA	Middle cerebral artery	Pro-UK	Prourokinase
MELAS	Mitochondrial encephalomyopathy, lactic acidosis, and stroke-like episodes	PROACT	Prolyse in Acute Cerebral Thromboembolism
MERRF	Myoclonic epilepsy and ragged red fibers	PSA	Posterolateral spinal arteries
MI	Myocardial infarction	PSV	Peak systolic velocity
mm	Millimeter	PT	Prothrombin time
MRA	Magnetic resonance angiography	PTA	Percutaneous transluminal angioplasty
MRI	Magnetic resonance imaging	PTE	Pulmonary thromboembolism
mRS	Modified Rankin score	PTT	Partial thromboplastin time
MTT	Mean transit time	PVA	Polyvinyl alcohol
MVP	Mitral valve prolapse	RA	Rheumatoid arthritis
NA	Not available	rem	roentgen-equivalent-man
NASCET	North American Symptomatic Carotid Endarterectomy Trial	RHV	Rotating hemostatic valve (aka Y-adapter, aka Touey-Borst Valve)
NBCA	N-butyl-2-cyanoacrylate	RIND	Reversible ischemic neurologic deficit
NBTE	Nonbacterial thrombotic endocarditis	RPR	Rapid plasma reagin
NCRP	National Council on Radiation Protection and Measurements	RR	Risk reduction
NCS	Nerve conduction study	RRR	Relative risk reduction
NEMC-PCR	New England Medical Center Posterior Circulation Registry	RX	Rapid exchange
Newt	Newton	SBP	Systolic blood pressure
NICU	Neurological intensive care unit	SCA	Superior cerebellar artery
NIH-SS	National Institutes of Health Stroke Scale	SCD	Sickle cell disease
NNH	Number needed to harm	SDH	Subdural hematoma
NNT	Number needed to treat	SECURITY	Study to Evaluate the Neuroshield Bare Wire Cerebral Protection System and X-Act Stent in Patients at High Risk for Carotid Endarterectomy
NPH	Neutral Protamine Hagedorn	SIADH	Syndrome of inappropriate ADH secretion
NPO	Nil per os (no feeding)	SIM	Simmons
NS	Not significant	SIR	Society of Interventional Radiology
NSAID	Nonsteroidal antiinflammatory drug	SLE	Systemic lupus erythematosus
OA-MCA	Occipital artery to middle cerebral artery	SOV	Superior ophthalmic vein
OA-PCA	Occipital artery to posterior cerebral artery	SPACE	Stent-Protected Percutaneous Angioplasty of the Carotid versus Endarterectomy
OCP	Oral contraceptive	SPARCL	Stroke Prevention by Aggressive Reduction in Cholesterol Levels
OEF	Oxygen extraction fraction	SPECT	Single photon emission computed tomography
OSA	Obstructive sleep apnea	SSS	Superior sagittal sinus
OTW	Over the wire	SSYLVA	Stenting of Symptomatic Atherosclerotic Lesions in the Vertebral or Intracranial Arteries
P-comm	Posterior communicating artery	STA	Superficial temporal artery
PA	Postero-anterior	STA-MCA	Superficial temporal artery to middle cerebral artery
PAC	Partial anterior circulation stroke	TAC	Total anterior circulation stroke
PAN	Polyarteritis nodosa	TASS	Ticlopidine Aspirin Stroke Study
PASCAL	Performance And Safety of the Medtronic AVE Self-Expandable Stent in Treatment of Carotid Artery Lesions	TCD	Transcranial Doppler
PCA	Posterior cerebral artery	TEE	Transesophageal echocardiography
PCR	Polymerase chain reaction	TGA	Transient global amnesia
PCWP	Pulmonary capillary wedge pressure	TIA	Transient ischemic attack
PCXR	Portable chest xray	TOAST	Trial of Org 10172 in Acute Stroke Treatment
PEEP	Positive end-expiratory pressure	tPA	Tissue plasminogen activator
PET	Positron emission tomography	TTE	Transthoracic echocardiography
PFO	Patent foramen ovale	TTP	Time to peak; Thrombotic thrombocytopenic purpura
PICA	Posterior inferior cerebellar artery		
PKD	Polycystic kidney disease		
PNS	Peripheral nervous system		
PCC	Posterior circulation stroke		
PPRF	Paramedian pontine reticular formation		

U	Unit	VIVA	ViVEXX Carotid
UOP	Urinary output		Revascularization Trial
VACS	Veterans Affairs Cooperative	VOGM	Vein of Galen malformation
	Study on Symptomatic Stenosis	VZV	Varicella zoster virus
VBI	Vertebrobasilar insufficiency	WASID	Warfarin versus Aspirin for
VDRL	Venereal Disease Research		Symptomatic Intracranial Disease
	Laboratory	WEST	Women Estrogen Stroke Trial
VERT	Vertebral	WHI	Women's Health Initiative

Contents

Acknowledgments v

Abbreviations v

Introduction xi

Part 1: Fundamentals

1. Essential Neurovascular Anatomy 1
2. Diagnostic Cerebral Angiography 87
3. Spinal Angiography 117
4. Neuroendovascular Suite 135

Part 2: Interventional Techniques

5. Intracranial Aneurysm Treatment 143
6. Provocative Testing 179
7. Intracranial Embolization Procedures 205
8. Extracranial Embolization 259
9. Thrombolysis for Acute Ischemic Stroke 301
10. Extracranial Angioplasty and Stenting 347
11. Endovascular Treatment of Intracranial Stenosis and Vasospasm 365
12. Venous Procedures 381

Part 3: Specific Disease States

13. Intracranial Aneurysms and Subarachnoid Hemorrhage 433
14. Arteriovenous Malformations 511
15. Dural Arteriovenous Fistulas 539
16. Cavernous Malformations and Venous Angiomas 561
17. Acute Ischemic Stroke *by Agnieszka Anna Ardelt* 571
18. Extracranial Cerebrovascular Occlusive Disease 641
19. Intracranial Cerebrovascular Occlusive Disease 679
20. Spinal Vascular Lesions 701
21. Index 715

Introduction

In recent years, neurointerventional radiology has evolved into a rarified and complex field, with a set of techniques and a knowledge base that are distinct from other fields within medicine. At the same time, clinicians from an assortment of disciplines have come to practice neurointerventional radiology, with backgrounds ranging from radiology to neurosurgery, neurology, cardiology, and vascular surgery. Presently, there are more people training to become neurointerventionalists than there ever have been before in history. These developments have resulted in a need for a practical, unified handbook of techniques and essential literature. The purpose of this book is to serve as a practical guide to endovascular methods and as a reference work for neurovascular anatomy and published data about cerebrovascular disease from a neurointerventionalist's perspective.

We have attempted to enhance the accessibility and ease use of this handbook by arranging it in a semioutline format. Dense narrative passages have been avoided wherever possible (who has time to read long, thick chapters, anyway?). In that spirit, the rest of this Introduction will be presented in the style of this book.

1. This book is divided into three parts.

(a) Fundamentals:

- Essential neurovascular anatomy and basic angiographic techniques provide the foundation of the first section.
 - The focus of Chap. 1 (*Essential Neurovascular Anatomy*) is on vascular anatomy that is pertinent to day-to-day clinical practice. Embryology and discussions of angiographic shift, which are less pertinent these days because of widely available non-invasive intracranial imaging, are left out. Discussions of anatomic variants include both normal variants and anomalies.
 - Chapters 2 and 3 cover diagnostic angiographic techniques.
 - Chapter 4 (*Neuroendovascular Suite*) is primarily intended for newcomers to the angio suite and for experienced interventionalists planning a new suite.

(b) Techniques:

- Endovascular methods, device information, and tips and tricks are detailed.

(c) Specific disease states:

- Essential, useful information about each commonly encountered condition is presented.
 1. Significant clinical studies are summarized and placed into context.
 2. Interesting and novel facts (and *factlets*) are included here and there.
 - The term *systematic review* is used to refer to useful publications that have analyzed published clinical data in an organized way. The term *meta-analysis* is avoided because it refers to a specific statistical technique that is not always present in review articles purporting to be a meta-analysis.
 - For readers with extra time on their hands, *A Brief History of...* sections describe the background and evolution of various techniques.
 - Chapter 17 (*Acute Ischemic Stroke*) contains a comprehensive discussion of the medical management of patients with stroke. The topics are arranged alphabetically to permit ease of use.
2. Core philosophy: Within the practical information contained within this book, we hope to impart our underlying patient-oriented clinical philosophy. In our view, each patient's welfare is paramount. The clinical outcome of each case takes priority over *pushing the envelope* by trying out new devices or techniques, generating material for the next clinical series or case report, or satisfying the device company representatives standing in the control room. In practical terms, clinical decision making should be based on sound judgment and the best available clinical data. Moreover, new medical technology and drugs should be used *within reason*, and whenever possible, based on

established principles of sound practice. Thus, while we have the technology and the ability to coil aneurysms in very old patients with Hunt Hess V subarachnoid hemorrhage, embolize asymptomatic and low-risk dural AV fistulas, and perform carotid angioplasty and stenting in patients with asymptomatic stenosis, we should recognize the value of conservative management when it is called for. We hope that this cautious and common sense outlook is reflected throughout this book.

3. Cookbook presentation: We have made every attempt to present procedures in a plainly written, how-to-do-it format. Although some readers may take issue with the reduction of a field as complex as neurointervention to a relatively simplistic how-to manual, we feel that structure and standardization of technique can only serve to benefit the field in the long run. For comparison, consider commercial air travel in the present era. Air travel fatalities are extremely rare, because of pilot training, standardization of flying techniques, and meticulous aircraft maintenance. Even the most skilled and careful neurointerventionalists cannot hold a candle to the stellar safety record obtained by the airline industry.
4. Conventions used in this book:
 - (a) Terminology can be confusing. The authors have adopted the most current and commonly used terms; synonymous terms are listed in parentheses after “aka,” for *also known as*.
 - (b) We have limited the use of abbreviations to those commonly used in everyday conversation, such as “ICA” and “MCA.” Excessive use of abbreviations, particularly for uncommon terms, can clutter the text and make it difficult to read.
 - (c) The terms, *see below* and *see above*, are used to indicate other material within the same chapter.
5. Overlap and redundancy: Discussion of some topics may appear to be repetitive and redundant; for instance, guide catheters are discussed in both Chap. 5 (*Intracranial Aneurysm Treatment*), and in Chap. 7 (*Intracranial Embolization*). This is intentional, as we hoped to avoid frequent cross-referencing between sections of the book, which can be annoying for a busy reader looking for quick advice. In addition, some overlap can actually be beneficial, as some topics can be discussed from different perspectives. For example, the evaluation of a stroke patient in the emergency room is discussed in Chap. 9 (*Thrombolysis for Acute Ischemic Stroke*), from the perspective of an interventionalist seeing a patient with a firm diagnosis of acute ischemic stroke, whereas a discussion of the same topic appears in Chap. 17 (*Acute Ischemic Stroke*) from the perspective of the *Code Stroke* team answering a call from the ER.
6. Medicolegal disclaimer: This book is meant to serve as a guide to the use of a wide variety of medical devices and drugs. However, the authors and the publisher cannot be held responsible for the use of these devices and drugs by readers, or for failure by the readers of this book to follow specific manufacturer specifications and FDA guidelines.

Mark R. Harrigan, Birmingham, Alabama
John P. Deveikis, Rochester, New York

1. Essential Neurovascular Anatomy

1.1. Aortic arch and great vessels

Aortic arch anatomy is pertinent to neuroangiography because variations of arch anatomy can affect access to the cervicocranial circulation:

1. Branches
 - (a) Innominate artery (aka brachiocephalic artery)
 - (b) Left common carotid artery
 - (c) Left subclavian artery
2. Variants (Fig. 1.1):
 - (a) Bovine arch (Figs. 1.1B and 1.2). The innominate artery and left common carotid artery share a common origin (up to 27% of cases), or the

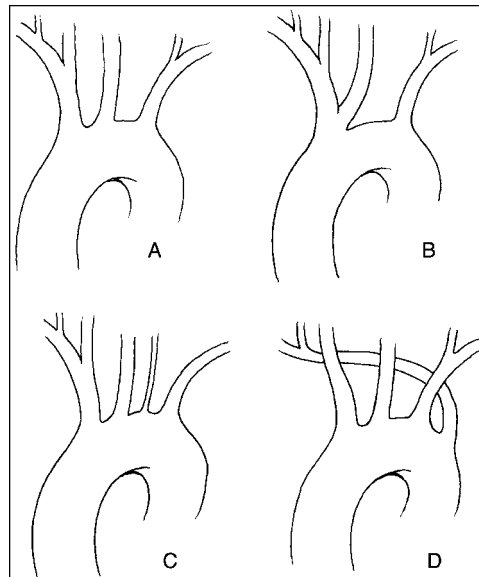


Fig. 1.1 Common aortic arch configurations. *Clockwise from upper left*: Normal arch; Bovine arch, Aberrant right subclavian artery, origin of the left vertebral artery from the arch.

- (a) left common carotid artery arises from the innominate artery (7% of cases).¹
- (b) Aberrant right subclavian artery. The right subclavian artery arises from the left aortic arch, distal to the origin of the left subclavian artery. It usually passes posterior to the esophagus on the way to the right upper extremity. Most common congenital arch anomaly; incidence: 0.9%.² Associated with Down syndrome.
- (c) Origin of the left vertebral artery from the arch, is seen in 0.5% of cases.¹

- (d) Less common variants (Fig. 1.3). Some of these rare anomalies can lead to the formation of a vascular ring, in which the trachea and esophagus are encircled by connected segments of the aortic arch and its branches.
3. Effects of aging and atherosclerosis on the aortic arch and great vessels. The aortic arch and great vessels become elongated and tortuous with age (Fig. 1.4); this can have practical implications for neurointervention in the elderly, as a tortuous vessel can be difficult to negotiate with wires and catheters. Although atherosclerosis has been implicated in the etiology of this phenomenon, more recent data suggest that the cervical internal carotid artery may undergo *metaplastic transformation*, in which elastic and muscular tissue in the artery wall is replaced by loose connective tissue.³

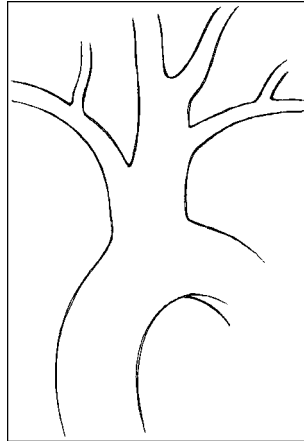


Fig. 1.2 What exactly is a "Bovine Arch?" Drawing of an arch from a cow.

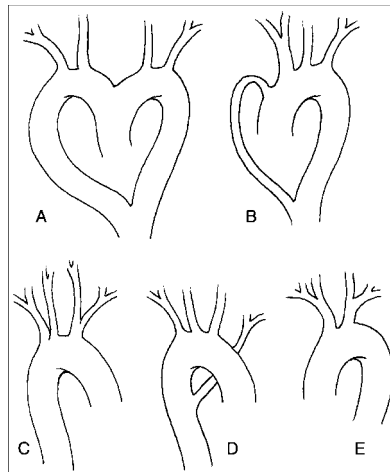


Fig. 1.3 Selected aortic arch anomalies. (A) Double aortic arch. The arches encircle the trachea and esophagus to form the descending aorta, which is usually on the left. The *right arch* is larger than the left in up to 75% of cases.¹ (B) Double aortic arch with left arch atresia. (C) Right aortic arch with a mirror configuration. The descending aorta is on the right side of the heart. This anomaly does not form a vascular ring, but is associated with other anomalies such as tetralogy of Fallot.¹ (D) Right aortic arch with a nonmirror configuration and an aberrant left subclavian artery. The descending aorta is on the right side of the heart, and the left subclavian artery arises from the proximal aorta. A common cause of a symptomatic vascular ring.⁴ (E) Bi-innominate artery.

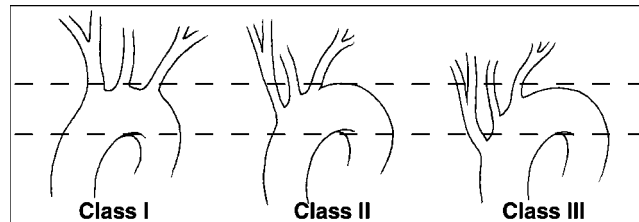


Fig. 1.4 Aortic arch elongation classification scheme.

The most common subclavian artery configuration is shown in Fig. 1.5. Major branches are:

- Vertebral artery (1)
- Thyrocervical trunk
 - Inferior thyroid artery (2)
 - Ascending cervical artery (most commonly a branch of transverse cervical) (3)
 - Transverse cervical artery (4)
 - Suprascapular artery (5)
- Costocervical trunk
 - Deep cervical artery (6)
 - Superior or supreme intercostal artery (7)
- Dorsal scapular artery (8)
- Internal thoracic (mammary) artery (9)

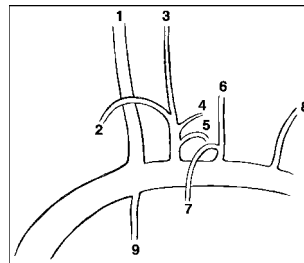


Fig. 1.5 Subclavian artery.

1.2. Common carotid arteries

The CCAs travel within the carotid sheath, which also contains the internal jugular vein and the vagus nerve. The right CCA is usually shorter than the left. The CCAs typically bifurcate at the C3 or C4 level (upper border of the thyroid cartilage), although the bifurcation may be located anywhere between T2 and C2.⁵ The CCAs do not usually have branches, although anomalous branches can include the superior thyroid, ascending pharyngeal, or occipital arteries.¹

1.3. External carotid artery

The external carotid artery originates at the common carotid bifurcation. From its origin, the external carotid usually curves forward medial to the internal carotid, then immediately begins a cephalad ascent, curving laterally and slightly posteriorly until it ends behind the mandible in its terminal bifurcation into the internal maxillary and superficial temporal arteries.⁶ Thus on a frontal radiographic view, the external carotid begins medially and swings cephalad and laterally, and on a lateral view it begins anteriorly and then ascends, angling slightly posteriorly.

External Carotid Branches (Fig. 1.6)

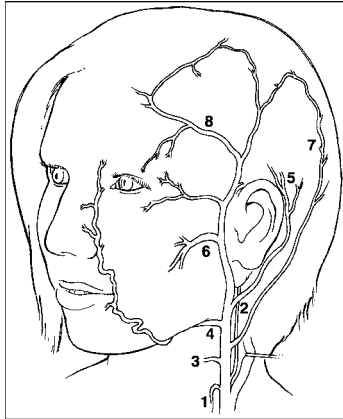


Fig. 1.6 External carotid artery. (1) Superior thyroid artery; (2) Ascending pharyngeal artery; (3) Lingual artery; (4) Facial artery; (5) Posterior auricular artery; (6) Internal maxillary artery; (7) Occipital artery; (8) Superficial temporal artery.

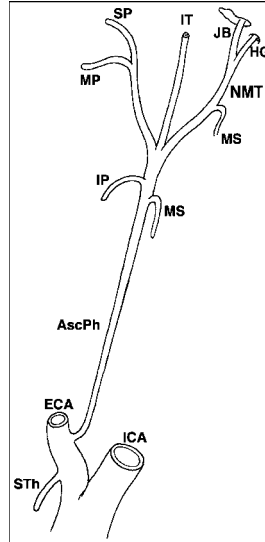


Fig. 1.7 Ascending pharyngeal artery. A common branching pattern of the ascending pharyngeal artery is shown. Note internal carotid (ICA), external carotid (ECA), superior thyroid (STh), ascending pharyngeal (Asc Ph), inferior pharyngeal (IP), middle pharyngeal (MP), superior pharyngeal (SP), inferior tympanic (IT), musculospinal branches (MS), neuromeningeal trunk (NMT), jugular branch (JB) entering the jugular foramen, hypoglossal branch (HG) entering the hypoglossal foramen, and prevertebral (not shown).

Mnemonic for the External Carotid Branches

After reading this book...
Some Angry Linguists Find Our Paragraphs Somewhat Irritating.

- Superior thyroid
- Ascending pharyngeal
- Lingual
- Facial
- Occipital
- Posterior auricular
- Superficial temporal
- Internal maxillary

One can also construct more amusing and off-color mnemonics to assist the novice in remembering these branches. If the readers' imaginations fail them, the authors would be more than happy to supply additional memory aids for this purpose.

There are eight major branches of the external carotid. A common order of listing the branches is related to the frequent origin of the vessels from proximal to distal (Figs. 1.7, 1.8, and 1.9):

- (a) Superior thyroid
- (b) Ascending pharyngeal
- (c) Lingual
- (d) Facial
- (e) Occipital
- (f) Posterior auricular
- (g) Superficial temporal
- (h) Internal maxillary

These various branches can sometimes arise variably from the external carotid trunk. Therefore, a more useful way to consider the external carotid branches regards grouping them into the ventral group which arises anteriorly from the

external carotid and the dorsal group of branches, which arises posteriorly from that vessel. These tend to be more constant than the proximal to distal order.

- Ventral external carotid branches:
 - Superior thyroid
 - Lingual
 - Facial
 - Internal maxillary
- Dorsal external carotid branches
 - Ascending pharyngeal
 - Occipital
 - Posterior auricular
 - Superficial temporal

4. Territories

The external carotid supplies much of the soft tissue and bony structures of the head and face, the deep structures of the upper aero-digestive tract, and much of the dura of the intracranial compartment. Numerous anastomoses are present between external carotid branches and the branches of the internal carotid and vertebral arteries. These anastomoses provide collateral flow to the vascular

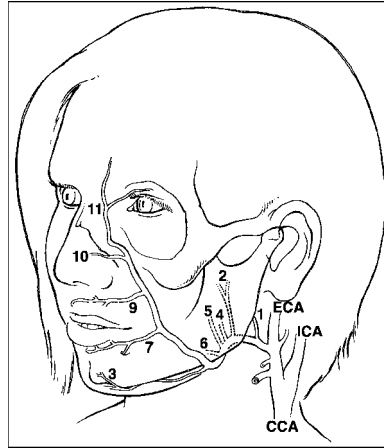


Fig. 1.8 Facial artery. (1) Ascending palatine artery; (2) Tonsillar artery; (3) Submental artery; (4) Inferior masseteric artery; (5) Jugal trunk; (6) Middle mental artery; (7) Inferior labial artery; (8) Anterior jugal artery (not shown); (9) Superior labial artery; (10) Lateral nasal artery; (11) Angular artery.

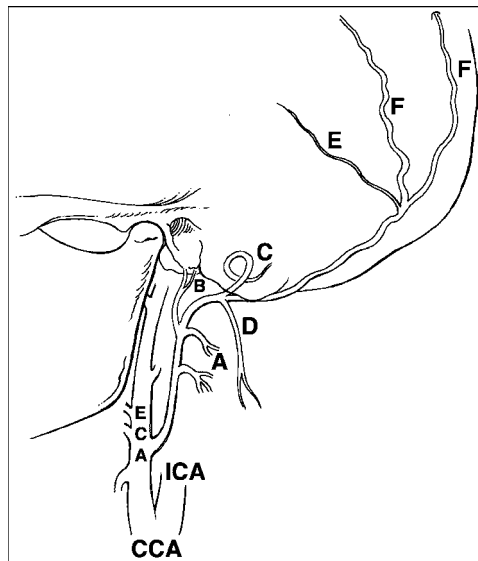


Fig. 1.9 Occipital artery. (A) Sternocleidomastoid branches; (B) Stylomastoid artery; (C) Mastoid branch; (D) Descending branch; (E) Lateral meningeal branch; (F) Occipital branches.

territories distal to a proximal occlusion. Anastomoses to carotid or vertebral arteries can also be considered “dangerous anastomoses,” when attempting to embolize vascular lesions in the head and neck via external carotid branches. See below for discussion of individual external carotid branch anastomoses and [Tables 1.1, 1.2, 1.3, and 1.4](#).

5. Variants:

- (a) The most common branching pattern at the common carotid bifurcation (in 48.5%) is the external carotid arises anteromedially while the internal carotid arises posterolaterally,⁷ but occasionally one can see the external carotid arising posterolaterally or directly laterally.^{8, 9}
- (b) The external and internal carotid may rarely arise as separate branches of the aortic arch.^{6, 10}

Table 1.1 Danger zones: Common anastomoses: Anterior circulation

Territory at risk	Anastomosis from	Anastomosis to	Comments/reference
Brain: Anterior circulation	Ascending pharyngeal, neuromeningeal trunk	Cavernous carotid via meningo-hypophyseal trunk	19
	Ascending pharyngeal, inferior tympanic branch	Petrous carotid via caroticotympanic	19
	Ascending pharyngeal, superior pharyngeal	Cavernous carotid via inferolateral trunk	19
	Ascending pharyngeal, superior pharyngeal	Petrous carotid via mandibular branch	19
	Accessory meningeal (cavernous branch)	Cavernous carotid via inferolateral trunk, posterior branch	19
	Middle meningeal (cavernous branch)	Cavernous carotid via inferolateral trunk, posterior branch	19
	Middle meningeal (cavernous branch)	Cavernous carotid via meningo-hypophyseal trunk	19
	Distal internal maxillary (artery of foramen rotundum)	Cavernous carotid via inferolateral trunk, anterolateral branch	19

Table 1.2 Danger zones: Common anastomoses: Ophthalmic artery

Territory at risk	Anastomosis from	Anastomosis to	Reference
Eye (and secondarily brain)	Middle meningeal, sphenoidal branch	Ophthalmic	19
	Middle meningeal, frontal branch	Ophthalmic via anterior falx artery	19
	Inferolateral trunk, anteromedial branch	Ophthalmic	19
	Distal internal maxillary, anterior deep temporal	Ophthalmic	19
	Distal internal maxillary, infraorbital	Ophthalmic	19
	Distal internal maxillary, sphenopalatine	Ophthalmic via ethmoidal branches	19
	Distal facial	Ophthalmic	19
	Transverse facial	Ophthalmic	19
	Superficial temporal, frontal branch	Ophthalmic	19
	Cavernous carotid, inferolateral trunk	Ophthalmic via recurrent meningeal branch	19

Table 1.3 Danger zones: Common anastomoses: Posterior circulation

Territory at risk	Anastomosis from	Anastomosis to	Comments/reference
Brain: Posterior circulation	Ascending cervical	Vertebral segmental branches	19
	Deep cervical	Vertebral segmental branches	19
	Occipital, muscular branches	Vertebral segmental branches	19
	Ascending pharyngeal, muscular branches	Vertebral segmental branches	19
	Ascending pharyngeal, neuromeningeal trunk	C3 segmental vertebral via odontoid arch	Odontoid arch connects side-to-side ¹⁹

Table 1.4 More trouble: Cranial nerve blood supply

Cranial nerve	Arterial supply	References
I: Olfactory	Anterior cerebral	19
II: Optic	Supraclinoid carotid, ophthalmic	19
III: Oculomotor	Basilar, superior cerebellar, posterior cerebral, inferolateral trunk, ophthalmic	19, 73
IV: Trochlear	Inferolateral trunk, meningo-hypophyseal trunk	19, 73
V: Trigeminal	Inferolateral trunk, meningo-hypophyseal trunk, middle meningeal, accessory meningeal, artery of foramen rotundum, infraorbital	19, 73
VI: Abducens	Inferolateral trunk, meningo-hypophyseal trunk, middle meningeal, accessory meningeal, ascending pharyngeal (jugular branch)	19, 24, 73
VII: Facial	Stylomastoid (from post auricular or occipital), middle meningeal (petrous branch), ascending pharyngeal (inferior tympanic and odontoid arcade)	19, 74
VIII: Auditory	Basilar, AICA, ascending pharyngeal jugular branch	19, 75
IX: Glossopharyngeal	Ascending pharyngeal jugular branch	19, 24
X: Vagus	Ascending pharyngeal jugular branch, superior and inferior thyroid, laryngeal branches	19, 24
XI: Spinal Accessory	Ascending pharyngeal (jugular, inferior tympanic and musculospinal branches)	19, 24
XII: Hypoglossal	Ascending pharyngeal, hypoglossal branch and proximal trunk, occipital, directly from external carotid, lingual	19, 76

- (c) Some external carotid branches, especially the superior thyroid, may arise from the common carotid.
- (d) Some branches (especially ascending pharyngeal or occipital) may originate from the internal carotid.
- (e) A common origin of superior thyroid, occipital, and ascending pharyngeal from the internal carotid has been reported.¹¹
- (f) Rarely, even all external carotid branches may arise from the internal carotid.¹²
- (g) External carotid branches may arise as common trunks with other branches including: linguofacial trunk (20% of cases), thyrolingual trunk (2.5% of

- cases), thyrolinguofacial trunk (2.5% of cases), and occipitoauricular trunk (12.5% of cases).¹³
- (h) Persistent stapedial artery,¹⁴ or, for the anatomic purist, the persistent hyoido-stapedial artery¹⁵ arises from the petrous internal carotid, passes through the middle ear, and forms the middle meningeal. The prevalence of persistent stapedial arteries in 100 temporal bones that were studied was 0.48%.¹⁶ This anomaly can be associated with the so-called aberrant course of the internal carotid in the middle ear, which probably really represents a collateral pathway involving the inferior tympanic branch of the ascending pharyngeal bypassing a segmental agenesis of the true internal carotid.^{17, 18}

1.3.1. Superior thyroid artery

Whether it arises above or below the common carotid bifurcation, the superior thyroid originates from the anterior surface of the parent artery and immediately turns caudally to supply the anterior soft tissue structures of the neck.

1. Branches

(a) Infrahyoid artery

The infrahyoid (a.k.a. hyoid) artery travels medially from its origin, and then follows along the lower hyoid bone. It can anastomose with the submental artery, providing a collateral pathway to the facial artery.¹⁹

(b) Superior laryngeal artery

The superior laryngeal artery traveling inferomedially from its origin, follows along with the internal laryngeal nerve, and pierces the thyrohyoid membrane to supply the mucosa of the larynx superior to the vocal cords and taste buds of the epiglottis.²⁰

i. Branches

There are two major branches consisting of a ventral branch that anastomoses with the cricothyroid artery and superior laryngeal arcade and a dorsal branch that anastomoses with the longitudinal laryngeal arcade. There is also a small epiglottic branch.¹⁹

ii. Territory

The superior laryngeal supplies the pharyngeal and laryngeal structures, as well as the internal laryngeal nerve. It anastomoses with its contralateral partner and with the inferior laryngeal artery, from the inferior thyroid artery.

iii. Variants

- May arise as a separate branch from the external carotid or ascending pharyngeal.¹⁹
- In 6 of 22 anatomic specimens, the superior laryngeal does not pierce the thyrohyoid membrane but instead passes through a thyroid foramen in the thyroid cartilage to supply the soft tissues of the larynx.²¹

(c) Sternocleidomastoid artery

Feeds the middle part of the sternocleidomastoid muscle and can anastomose with the muscular branches of the posterior auricular and occipital superiorly, and thyrocervical trunk and suprascapular inferiorly. The sternocleidomastoid branch can also connect with the glandular branches of the superior thyroid.

(d) Cricothyroid artery

Anastomoses with the superior laryngeal and feeds the upper trachea.

(e) Glandular branches

This is the continuation of the superior thyroid trunk. There are superior, medial and lateral arcades to supply the thyroid gland and freely anastomose with their contralateral counterparts.

2. Territories

- (a) The superior thyroid artery supplies the majority of the blood to the larynx with its associated musculature and upper pole of the thyroid gland.⁹ Only in a small minority of cases does the superior thyroid provide blood flow to the parathyroid glands.²² The superior laryngeal branch accompanies and can supply the internal laryngeal nerve. The superior thyroid branches freely anastomose with their contralateral counterparts and with the inferior thyroid artery (from the thyrocervical trunk).

3. Variants

- (a) The superior thyroid arises from the external carotid in 46% of cases and more commonly, from the common carotid in 52% of cases.²³
- (b) Superior thyroid may arise in a common trunk with the lingual as a thyrolingual trunk.
- (c) Very rarely, the superior thyroid may arise from the internal carotid.¹¹

1.3.2. Ascending pharyngeal artery

A thin, slender branch arising at the very proximal posterior aspect of the external carotid, or in the crotch of the common carotid travels cephalad and parallels the internal carotid. Its termination in the superior pharynx creates a forward and medial right angle turn (Fig. 1.7).

1. Branches

(a) Inferior pharyngeal

A relatively small vessel arising from the proximal ascending pharyngeal and traveling anteriorly in a zigzag fashion. It supplies pharyngeal muscles and mucosa. It anastomoses with its contralateral counterpart.

(b) Musculospinal

The vessel may arise from the ascending pharyngeal itself or from the neuromeningeal trunk. It takes a typical course extending posteriorly and superiorly for a short distance before curving inferiorly. It supplies primarily muscles, but also potentially the ipsilateral upper spinal nerve roots, the XIth cranial nerve and superior sympathetic ganglion with potential anastomoses with the ascending and deep cervical and vertebral arteries.^{19, 24}

(c) Neuromeningeal trunk

It is a major branch of the ascending pharyngeal that continues cephalad, but angling gently to the posterior. It has several important branches that pass through foramina in the skull base.

i. Branches

– *Musculospinal.*

This branch may variably arise from the neuromeningeal trunk instead of originating from the ascending pharyngeal itself.

– *Jugular.*

Often the largest branch of the neuromeningeal trunk, this vessel heads straight cephalad to the jugular foramen. It supplies the IXth through XIth cranial nerves and their ganglia. A medial branch then ascends on the clivus supplying the VIth cranial nerve and a lateral branch travels along the dura around the sigmoid sinus. It can be a major contributor to the dura of the posterior fossa. Anastomoses with the lateral clival branch of the meningohypophyseal trunk and dural branches of the vertebral are possible.¹⁹

– *Hypoglossal.*

This branch enters the hypoglossal canal and supplies the XIIth cranial nerve. It also supplies the dura in the posterior cranial fossa and anastomoses with the jugular branch, medial clival branches of the meningohypophyseal trunk, the contralateral hypoglossal artery, and the odontoid arcade.^{19, 25}

– *Prevertebral.*

It often arises from the neuromeningeal trunk and contributes to the odontoid arcade. It anastomoses with its contralateral counterpart and the anterior meningeal branch of the vertebral, as well as the hypoglossal branch.²⁵

ii. Territories

The very important neuromeningeal trunk of the ascending pharyngeal supplies cranial nerves VI, IX, X, XI, and XII, and potentially collateralizes to the upper three spinal nerves and the superior sympathetic ganglion. The meningeal component of its territory includes much of the meninges of the posterior fossa. Anastomotic channels exist to its contralateral counterpart, meningeal branches of the vertebral and the meningohypophyseal trunk.²⁴

- iii. Variants

All the branches of the neuromeningeal trunk are in vascular equilibrium with each other, and with their anastomotic connecting vessels. Hypoplasia or occlusion of one or more vessels leads to hypertrophy of the existing branches.
 - (d) Prevertebral

Occasionally, this vessel arises directly from the ascending pharyngeal, but still contributes to the odontoid arcade.²⁵
 - (e) Inferior tympanic
 - i. Branches

There are three common branches of the inferior tympanic.¹⁹

 - Ascending branch connects to petrosal branch of middle meningeal
 - Anterior branch connects to the caroticotympanic branch
 - Posterior branch connects to the stylomastoid artery, a branch of the posterior auricular artery
 - ii. Territories

Supplies middle ear cavity and associated nerves, including Vllth nerve and tympanic branch of the IXth cranial nerve (aka Jacobson's nerve).
 - iii. Variants

May arise from the neuromeningeal branch, the ascending pharyngeal distal to the origin of the latter, or it may appear as a trifurcation with a neuromeningeal division and pharyngeal division with the inferior tympanic arising in between.¹⁹
 - (f) Middle pharyngeal
 - i. Branches

No named branches.
 - ii. Territories

Supplies mucosa and muscles of the naso- and oropharynx as well as the soft palate.²⁶ Anastomoses with contralateral middle pharyngeal, ipsilateral ascending palatine, greater palatine, and branches of the accessory meningeal.
 - iii. Variants

May arise from ascending pharyngeal proximal or occasionally distal to the origin of neuromeningeal trunk.
 - (g) Superior pharyngeal

As the most cephalad anterior branch of the ascending pharyngeal, this tends to be a small vessel. The pharyngeal branches take an abrupt anterior and medial angulation from the vertical ascending pharyngeal.

 - i. Branches

There are several common branches of the superior pharyngeal, but only one is named.

 - Carotid branch actually traverses the cartilage filling the foramen lacerum and connects to the cavernous carotid artery via the inferolateral trunk.
 - Anterior un-named branches to the upper nasopharynx and adjacent tissues.
 - ii. Territories

Supplies upper nasopharynx including the orifice of the Eustachian tube as well as associated muscles, including superior constrictor. Has many potential anastomoses, including accessory meningeal, pterygovaginal, contralateral superior pharyngeal with dangerous anastomoses to cavernous carotid via the carotid branch and petrous carotid via its Vidian branch, if present.
 - iii. Variants

Pharyngeal territories of the superior pharyngeal may be primarily supplied by the accessory meningeal, Vidian, or other nasopharyngeal feeders.
- 2. Territories

Ascending pharyngeal supplies the mucosa and adjacent muscles of the pharynx, soft palate, odontoid process, bones, muscles and nerve roots at C1 and C2, lower cranial nerves (IX–XII and potentially VI and VII), lower clivus and medial skull base, middle ear, and meninges of the posterior fossa and portions of the middle cranial fossa. There are extensive anastomoses with its contralateral counterpart as well as the occipital, middle and accessory meningeal, and distal internal maxillary arteries as well as particularly dangerous anas-

tamoses with the internal carotid and vertebral arteries.²⁴ This is a *very busy* little artery.

3. Variants
 - (a) Ascending pharyngeal may arise from the internal carotid.
 - (b) Often arises as a common trunk with the occipital artery.
 - (c) Ascending cervical artery may supply the territory of the ascending pharyngeal.¹⁹
 - (d) Can contribute to the persistent hypoglossal artery variant.
 - (e) Can reconstitute the vertebral artery when it is aplastic.
 - (f) The so-called “aberrant internal carotid” in the middle ear cavity is probably more appropriately termed the ascending pharyngeal artery, providing a collateral pathway for the territory of a segmentally occluded internal carotid.^{17, 18}

1.3.3. Lingual artery

Arises from the ventral aspect of the external carotid and takes a gentle anterior-inferior path to create a “U” shaped curve on both frontal and lateral angiographic projections. It then curves upward to form an arc through the tongue as the dorsal lingual branch with its characteristic radiating branches to the tongue:

1. Branches
 - (a) Suprahyoid
A small branch runs along the superior aspect of the hyoid bone and anastomoses with the contralateral suprahyoid.⁶
 - (b) Dorsal lingual
May consist of two or three upwardly arcing branches that curve up over the tongue and gives radiating branches, that follow the pattern of the radiating intrinsic lingual muscle. The dorsal lingual anastomoses with its contralateral counterpart.⁶
 - (c) Sublingual
This branch angles anteriorly to supply the sublingual gland and floor of the mouth, and anastomoses with the submental branch of the facial and with its contralateral counterpart. A small branch pierces the lingual foramen of the mandible, and supplies the adjacent bone.⁶
 - (d) Deep lingual
A small terminal branch to the frenulum of the tongue.⁶
2. Territories
The lingual artery provides generous arterial supply to the tongue and floor of the mouth. There are anastomoses with the contralateral lingual and ipsilateral facial via the submental branch. However, it should be remembered that the branches to the tip of the tongue are effectively end arteries, and distal embolization with small particles or liquid agents can produce ischemic necrosis of the tip of the tongue, especially if the emboli are forced across the midline via the side-to-side anastomosis, or if bilateral embolization is intentionally done.
3. Variants
 - (a) Often arises from a common facial-lingual trunk with the facial artery (20% of cases).¹³
 - (b) Occasionally, can arise as a common thyrolingual trunk with the superior thyroid artery (2.5% of cases), or thyrolinguofacial trunk (2.5% of cases).¹³
 - (c) Rarely can arise from the common carotid.
 - (d) Lingual artery can supply variable amounts of the submental artery’s supply to the floor of the mouth.

1.3.4. Facial artery

The facial artery is usually one of the larger external carotid branches and arises from the anterior aspect of the external carotid. It then curves in a slightly redundant fashion through the submandibular gland and under and around the angle of the mandible, then angling forward and cephalad, as well as medially to extend up along the angle of the nose as the angular artery. The facial artery has a number of named and un-named branches that anastomose freely from one to the other, and with other vessels in the face (Fig. 1.8).

1. Branches
 - (a) Ascending palatine

This vessel ascends for a few centimeters from its origin, and then takes a right angle forward to the soft palate, by taking a small loop-de-loop as it curves around the tonsils. Consequently, this vessel can be a casualty of tonsillectomy or palatal surgery,²⁶ and can be the source of post-op bleeding, along with the smaller tonsillar arteries.

i. Branches

Three fairly constant and several less constant branches were found on a cadaveric study of palatine blood supply.²⁷

- *Glossal*. Arises at the level of the upper border of the tongue and supplies the palatoglossus muscle.
- *Tonsillar*. Arises at the level of the oropharyngeal tonsil, supplying the tonsil and palatopharyngeus and sometimes palatoglossal muscles.
- *Hamular*. Arises adjacent to the hamulus of the medial pterygoid plate and mucosa and palatoglossus.
- Variable branches to uvula, levator palatini, palatoglossus, and palatopharyngeus muscles.

ii. Territories

Supplies mucosa and muscles of the lateral oropharynx and soft palate. Anastomoses with contralateral ascending palatine and ipsilateral middle pharyngeal, greater palatine, and the branches of accessory meningeal.

iii. Variants

Usually arises from the proximal facial artery, but may arise directly from the external carotid, from a common trunk with the submandibular branch, occasionally from the middle pharyngeal artery (from the ascending pharyngeal) or even from the accessory meningeal artery.¹⁹

(b) Tonsillar artery

One or more small proximal facial branches to the tonsils. This is the dominant supply to the palatine (oropharyngeal) tonsil along with the ascending palatine artery, pharyngeal branches of the ascending pharyngeal, dorsal lingual branch of the lingual, and greater palatine branch of the internal maxillary.⁶ The tonsillar artery must, therefore, be considered as a culprit in the case of postoperative bleeding after tonsillectomy, along with the ascending palatine. The tonsillar branches of the facial can also contribute to the nasopharyngeal tonsils, but most of the blood supply to that tonsil comes from the superior pharyngeal, ascending palatine, pterygo-vaginal, and occasionally the inferior hypophyseal branch of the meningohypophyseal trunk.⁶

(c) Submandibular branches

Small branch or branches to the submandibular gland region. May arise from the submental artery. It may anastomose to the lingual and superior thyroid branches.²⁸

(d) Submental artery

This vessel is usually fairly large, traveling along the inferior margin of the mandible, and it shares the task of supplying the floor of the mouth with the lingual artery. The submental anastomoses to the lingual via its submandibular branch, and with the superior thyroid via its infrahyoid branch, and also has side-to-side anastomoses with its contralateral partner.²⁸ Its terminal branches curve up to the chin to anastomose with the middle mental and inferior labial arteries.⁶

(e) Inferior masseteric

Anterior-superior angling branch that follows along and can supply the lower masseter muscle. Can have a small amount of collateral flow to the superior masseteric branch of the internal maxillary.²⁸

(f) Jugal trunk

Those who are familiar with Latin know that "jugal" concerns the cheek, and the jugal trunk is one of the three main superior-to-inferior anastomoses in the soft tissues of the cheek.

i. Branches

Two fairly constant and angiographically visible branches arise from the trunk.

- *Bucco-masseteric. (aka buccal)*. Arises from the trunk at the level of the ramus of the heads cephalad, and deeply in the cheek. It gives a buccal branch that supplies the mucosa and deep parts of the cheek and a masseteric branch that feeds

that muscle. There are anastomoses from the buccal with the distal internal maxillary via the buccal branch of the latter and the superior masseteric. The masseteric branch anastomoses with the transverse facial and infraorbital. On lateral angiographic views it characteristically crosses the transverse facial at a right angle.²⁸

- *Posterior jugal*. This branch travels obliquely anterior-superiorly and anastomoses with the infraorbital branch of the internal maxillary, superior alveolar and also the transverse facial.²⁸

- (g) **Middle mental**
A small horizontal branch along the body of the mandible supplying skin and adjacent subcutaneous tissues with anastomoses to adjacent facial branches and inferior alveolar branch of the internal maxillary.²⁸
- (h) **Inferior labial**
This anterior and medially directed branch is the major supply to the lower lip. It has anastomoses with the contralateral inferior labial, and also potentially with the ipsilateral superior labial and submental arteries.²⁸ There may be a common trunk with the superior labial in 10% of angiographic studies.²⁹
- (i) **Middle jugal**
An inconstant branch that parallels and potentially anastomoses with the anterior and posterior jugal trunks.²⁸
- (j) **Superior labial**
Anterior and medially directed branch to the upper lip, it parallels but is usually larger than the inferior labial. It usually has septal and alar branches to the nose. It freely anastomoses with the contralateral superior labial and has potential dangerous anastomoses with nasal branches of the ophthalmic.^{6, 28}
- (k) **Anterior jugal**
The anterior-most of the upward angulated branches in the cheek, it supplies the anterior cheek and lateral aspect of the upper lip and nose. It freely anastomoses with the infraorbital, the posterior and middle jugal arteries, the transverse facial, and superior alveolar artery.²⁸
- (l) **Lateral nasal (aka alar)**
This small branch extends anteriorly to supply the nostril and anastomose with the contralateral alar artery.⁶
- (m) **Nasal arcade**
Anastomotic channels curving over and across the nose and collecting and connecting inputs from the facial and ophthalmic arteries bilaterally.²⁸
- (n) **Angular**
Lives up to its name and travels up along the angle lateral to the nose, supplying the cheek beside the nose and the lateral aspect of the nose, contributing to the nasal arcade. It has dangerous anastomoses with inferior palpebral and nasal branches of the ophthalmic.²⁸

2. Territories

The major supply to the superficial soft tissues of the face, it also contributes to the masseter muscle, parotid gland, palate and tonsils, floor of the mouth, and portions of the buccal mucosa. It can give vasa nervosa to distal facial artery branches in the face. There are numerous anastomoses between facial branches and to virtually every other artery in the facial region, including major connections to the internal maxillary, transverse facial, and important collaterals to distal ophthalmic branches.

3. Variants

Lasjaunias proposed a theory of hemodynamic balance at a number of collecting points in the face, to explain the variety of vascular configurations encountered in clinical practice.^{19, 28} There is a buccal and masseteric balance in the posterolateral aspect of the face, an infraorbital and transverse facial balance in the mid-portion, and an ophthalmic balance in the anteromedial face. At six points in the face (termed jugal, infraorbital, and ophthalmic superiorly, and mandibular, labial and nasal inferiorly), dominance of blood flow to the region by one or the other potential inputs determines the course and size of the facial artery. Numerous variations are possible, but the common variants are listed below.

- (a) The facial artery frequently may arise as a common trunk with the lingual (20% of cases).¹³
- (b) The proximal facial may have a posterolateral “jugal” course through the jugal point.¹⁹

- (c) It may also travel anteromedially through the labial point for a “labial course.”¹⁹
- (d) Left and right facial arteries are symmetrical in 68% of autopsy cases.³⁰
- (e) Sixty-eight percent of facial arteries appear to terminate in the angular artery.³⁰
- (f) Twenty-six percent end in the lateral nasal branch.³⁰
- (g) Four percent terminate in the superior labial.³⁰

1.3.5. Occipital artery

This is a large branch of the posterior aspect of the external carotid that angles posteriorly and superiorly, first being fairly straight as it goes up through the upper neck, becoming more tortuous and redundant as it travels up the posterior scalp (Fig. 1.9).

1. Branches

- (a) **Sternocleidomastoid branches (aka muscular branches)**
There may be multiple muscular branches. The hypoglossal nerve hooks around the lowest branch as it heads first inferiorly, then anteriorly toward the tongue.⁶ Each muscular branch characteristically tends to curve cephalad for a short distance, before taking an abrupt turn posteroinferiorly. Each muscular branch corresponds to a vertebral level and provides segmental supply to the muscles, nerves and bone at these levels. The occipital artery shares the segmental vertebral blood supply with the vertebral artery, ascending pharyngeal and deep cervical artery, all of which the occipital muscular branches freely anastomose. The muscular branches normally supplied by the occipital may also arise from the posterior auricular or directly from the external carotid.¹⁹
- (b) **Stylomastoid artery**
The stylomastoid artery arises from the occipital artery in 20–50% of cases.^{19,31} It is a common source of blood flow to the facial nerve and middle ear. It can form collateral anastomoses with the inferior tympanic, anterior tympanic, and superior tympanic arteries.
- (c) **Mastoid branch**
This vessel angles cephalad and medially from the occipital artery giving some supply to the soft tissues in the adjacent scalp, before entering the skull via the occipital foramen.
 - i. **Branches**
After it enters the skull, the mastoid commonly gives three groups of branches.¹⁹
 - *Descending branches.*
These approach the jugular foramen and anastomose with the jugular branch of the ascending pharyngeal.
 - *Ascending branches.*
These approach the internal auditory canal and can anastomose with the subarcuate branch of the anterior-inferior cerebellar artery.
 - *Posteromedial branches.*
These spread out into the lateral dura of the posterior fossa, potentially anastomosing with branches of the hypoglossal branch of the ascending pharyngeal or the posterior meningeal branch arising from the vertebral (or posterior-inferior cerebellar).¹⁹
 - ii. **Territories**
Supplies the superficial soft tissues, the bone and dura in the mastoid and temporal bone region. It may supply large areas of the dura in the posterior fossa.
 - iii. **Variants**
The mastoid artery may be absent or hypoplastic, and its territory supplied by middle meningeal, hypoglossal or jugular branches or the meningeal branches of the vertebral.
- (d) **Descending branch**
The most cephalad muscular branch at the occipital–C1 junction tends to be quite prominent, usually with large anastamotic connections to the

vertebral artery and a descending branch connecting to the deep cervical artery.

(e) Lateral meningeal branches

Distal to the origin of the mastoid branch, there may be one or more branches that enter the skull via a small parietal foramen and supply supratentorial dura. There are usually anastomoses with middle meningeal branches.

(f) Occipital branches

Multiple scalp vessels with a redundant, zigzag configuration arise from the occipital to supply the scalp, muscles and pericranium. These anastomose with the contralateral occipital branches, and with scalp branches of the posterior auricular and superficial temporal arteries.⁶

2. Territories

The occipital artery travels 3 cm lateral to theinion and generally supplies the posterior third of the scalp, the occipital-frontalis, trapezius, and sternocleidomastoid muscles, portions of the occipital, mastoid and temporal bones, dura, the seventh and ninth cranial nerves and first few spinal nerves. There are numerous anastomoses to the contralateral occipital artery, the ipsilateral ascending pharyngeal artery, vertebral artery, middle meningeal artery, superficial temporal artery, posterior auricular artery, deep cervical artery and even anterior-inferior-cerebellar artery.

3. Variants

- (a) The ascending pharyngeal may arise from the occipital artery.
- (b) There can be a common origin of the occipital with the posterior auricular as an occipitoauricular trunk (12.5% of cases).¹³
- (c) The occipital may arise from the internal carotid artery.
- (d) The occipital can be involved with persistent carotid-vertebral anastomoses, such as a persistent proatlantal artery.
- (e) The occipital may originate from C1 or C2 segmental branches of the vertebral artery or from the ascending cervical artery.^{19, 32}

1.3.6. Posterior auricular artery

This posterior branch of the distal external carotid is usually fairly small and can be identified angiographically by the tortuous scalp branch curving cephalad behind the ear.

1. Branches

(a) Sternocleidomastoid branch (aka muscular)

Proximal branch of the posterior auricular can assist the occipital in providing blood flow to the sternocleidomastoid, digastric and stylohyoid muscles.⁶

(b) Parotid branches

Small branches from the proximal posterior auricular to the parotid. Can supply portions of the facial nerve.

(c) Stylomastoid branch

The stylomastoid artery arises from the posterior auricular in 50–70% of cases.^{31, 33} The next most common origin is from the occipital, followed by direct origin from the external carotid. It feeds the facial nerve and middle ear, mastoid air cells and portions of the inner ear.⁶ It can anastomose with anterior tympanic (from middle meningeal) and inferior tympanic (from ascending pharyngeal).

(d) Auricular branch

A fairly constant branch seen in 65% of cases, this vessel supplies much of the posterior aspect of the pinna.³⁴ Its branches form a dense arterial network in the ear.

(e) Occipital branch (aka retroauricular branch)

Also a fairly constant branch seen in 65% of cases, this branch supplies the scalp behind the ear.

(f) Parietal branch

A fairly inconstant branch only seen when the superficial temporal does not have a dominant parietal branch. It has the typical ascending, tortuous appearance of a scalp vessel.

2. Territories

The posterior auricular artery supplies the auricle, entering the middle part of the ear posteriorly.³⁵ It is the major supplier of blood flow to the ear.³⁶ It can

supply portions of the parotid gland, facial nerve, sternocleidomastoid, digastric and stylohyoid muscles.⁶ It has variable supply to the scalp posterior and superior to the ear, depending on the dominance of the superficial temporal and occipital arteries. It anastomoses with the superficial temporal, and occipital via the scalp and auricular branches and with anterior tympanic (from middle meningeal) and inferior tympanic (from ascending pharyngeal) via the stylo-mastoid artery.

3. Variants

- (a) May arise 12.5% of the time in common with the occipital artery as an occipito-auricular trunk.¹³
- (b) The scalp territories of the posterior auricular are in a hemodynamic balance with the superficial temporal and occipital arteries. If one is hypoplastic, the adjacent vessels are hypertrophic, and vice versa.

1.3.7. Superficial temporal artery

One of the two terminal branches of the external carotid (the other is the internal maxillary), this vessel continues the general vertical course of the external carotid. The superficial temporal arises behind the neck of the mandible within the parotid gland. It is easily palpable anterior to the ear at the tragus.⁶ The superficial temporal provides typically two major branches that then angle cephalad in a wavy, redundant fashion that is typical for scalp vessels:

1. Branches

(a) Transverse facial

This vessel originates anteriorly from the superficial temporal artery within the parotid gland and travels anteriorly and slightly inferiorly between the parotid duct and zygomatic arch, to supply the structures in the face.⁶ On lateral angiographic studies, it typically crosses the buccal artery at right angles.¹⁹ With agenesis or diminution of the facial artery, this branch may take over as the dominant artery of the face.

i. Branches

Along its course, the transverse commonly has a number of branches, but only one (superior masseteric) has a well described formal name.

– *Parotid branches.*

These feed the parotid gland and duct and may contribute to facial nerve branches.

– *Superior masseteric.*

Prominent branch to the masseter muscle that anastomoses with the buccal artery (from the facial artery).¹⁹

– *Jugal branches.*

One or more descending branches to the cheek that may anastomose with the jugal branches of the facial artery.

– *Zygomatic branches.*

These spread out into the face, potentially anastomosing with branches of the zygomatico-orbital branch of the superficial temporal.¹⁹ Distally these terminal branches may anastomose with the infraorbital and lacrimal arteries.⁶

ii. Territories

It supplies the superficial soft tissues of the upper face. It freely anastomoses with other superficial temporal and facial branches, as well as with potential collaterals to the infraorbital and ophthalmic arteries.

iii. Variants

The transverse facial artery may arise directly from the external carotid.

(b) Anterior auricular

It is a proximal branch of the superficial temporal, supplying blood primarily to the anterior aspect of the ear. It has three branches, the most superior of which curves up over the helix to anastomose with posterior auricular branches, but the lower two branches only provide limited supply to the anterior ear.³⁵

(c) Zygomatico-orbital

A variably prominent, anteriorly directed branch of the superficial temporal runs just superior to the zygomatic arch towards the lateral aspect

of the orbit. It supplies the scalp and the orbicularis oculi muscles.⁶ It can have numerous anastomoses with the frontal branch of the superficial temporal, transverse facial, and supraorbital, frontal, palpebral, and lacrimal branches of the ophthalmic.¹⁹

(d) Middle temporal

Also called the posterior deep temporal by some authors, this is a relatively small branch supplying the temporalis muscle, specifically the posterior aspect of this muscle.³⁷ It potentially anastomoses with the deep temporal branches of the internal maxillary.⁶

(e) Frontal branch

One of the two large terminal branches of the superficial temporal takes a tortuous course over the frontal scalp, supplying tissues from skin down to pericranium. It anastomoses with its contralateral counterpart across the midline, and with the ipsilateral zygomatico-orbital branch of the superficial temporal and supraorbital and supratrochlear branches of the ophthalmic.⁶ The distal frontal branch over the vertex can also provide branches that pass through foramina for emissary veins, to anastomose with middle meningeal branches.¹⁹ This is why superficial temporal arteries sometimes supply intracranial lesions such as meningiomas.

(f) Parietal branch

The other, usually larger terminal branch of the superficial temporal angles more posteriorly to supply the parietal scalp. It anastomoses with the contralateral parietal branch, and ipsilateral frontal branch, as well as posterior auricular and occipital branches. It can also provide some trans-cranial anastomoses with the middle meningeal branches.

2. Territories

The superficial temporal is a major contributor of blood flow to the scalp, and is in a hemodynamic equilibrium with the occipital and posterior auricular arteries. There are extensive anastomoses between the superficial temporal branches and the branches of occipital, posterior auricular, middle meningeal, ophthalmic, and facial arteries.

3. Variants

There is considerable variability of the size and territory of the major superficial branches. The balance that exists between individual superficial temporal branches and between the superficial temporal and its competing scalp vessels, means that when one vessel is large and takes on a wide territory, the adjacent vessels may be small or absent.

1.3.8. Internal maxillary artery

The internal maxillary artery (IMA) is the larger of the two terminal branches of the external carotid. Inclusion of the word *internal* is superfluous, as there is no “external” maxillary artery; however, *internal maxillary artery* is the colloquial, and most widely used, version of the term for this vessel. The IMA arises at a right angle from the external carotid behind the neck of the mandible, and travels anteriorly. Anatomically, it can be divided into three segments (1) the proximal mandibular part traveling horizontally, first posterior, then medial to the mandible, (2) the middle pterygoid part travels in a slightly oblique fashion, anteriorly and cephalad, adjacent to the lateral pterygoid muscle (medial or lateral to it, depending on whether it is the superficial or deep variant as described below), and (3) the distal pterygopalatine part passes between the upper and lower heads of the lateral pterygoid, curves medially and travels through the pterygomaxillary fissure into the pterygopalatine fossa.⁶

1. Branches

The mandibular part of the IMA often gives rise to the deep auricular, anterior tympanic, middle meningeal, accessory meningeal, and inferior alveolar arteries (i.e., branches that traverse foramina or fissures). The pterygoid part usually has deep temporal, pterygoid, masseteric and buccal branches (i.e., muscular branches). The pterygopalatine part provides the posterior superior alveolar, infraorbital, artery of foramen rotundum, pterygovaginal, greater palatine, Vidian, and sphenopalatine arteries.⁶

(a) Deep auricular artery

Tiny branch of very proximal internal maxillary

i. Branches

No named branches.

- ii. Territories
Supplies external auditory meatus, tympanic membrane, and temporomandibular joint.⁶
- iii. Variants
 - May arise in a common trunk with anterior tympanic
- (b) Anterior tympanic
Very small branch of very proximal internal maxillary
 - i. Branches
No named branches.
 - ii. Territories
Supplies tympanic cavity and anastomoses with the stylomastoid artery, pterygogaginal branch of internal maxillary and carotico-tympanic artery from petrous carotid.⁶
 - iii. Variants
Extremely variable anterior tympanic origins were found in a study of 104 cadaveric specimens.³⁸
 - May arise as a common trunk with deep auricular artery, middle meningeal, accessory meningeal, or posterior deep temporal.
 - Seventy-eight percent of right and 45% of left arise from internal maxillary
 - Next most common site of origin: superficial temporal
 - 1–4% arise from external carotid itself
 - Rarely, the anterior tympanic may be duplicated, triplicated, or absent.³⁸

(c) Middle meningeal artery (Fig. 1.10)

The first substantial ascending branch of the internal maxillary enters the cranial cavity through foramen spinosum. It then takes a characteristic right-angle turn in both the sagittal plane in which it turns anteriorly and coronal plane, in which it turns laterally.

- i. Branches
 - *Accessory meningeal.*
This may be a major extracranial branch of the middle meningeal, or may arise separately from the internal maxillary. The accessory meningeal is discussed in detail below.
 - *Petrous.*
The small, but important petrous branch first gives a medial cavernous branch to the cavernous sinus which can anastomose with the posterior branch of the inferolateral trunk, then gives a posterior basal tentorial branch, potentially anastomosing with basal tentorial branches of the petrosquamosal branch of the middle meningeal, and cavernous branches of the internal carotid.¹⁹ It then follows along the greater petrosal nerve giving the superior tympanic branch to the facial nerve and geniculate ganglion. This portion anastomoses with the stylomastoid.⁶
 - *Petrosquamosal.*
A posteriorly directed branch of the proximal intracranial middle meningeal supplies to the middle cranial fossa dura, and can have a basal tentorial branch that can contribute to the dura of the posterior fossa, and potentially anastomose with the jugular branch of the ascending pharyngeal.¹⁹
 - *Sphenoidal.*
This branch supplies dura along the planum sphenoidale, and then enters the orbit via the superior orbital fissure to freely communicate with the ophthalmic.³⁹ The sphenoidal collateral to the ophthalmic was seen in 16% of cadaveric specimens.⁴⁰
 - *Meningolacrimal.*
This orbital branch is derived from the superior branch of the primitive stapedia artery, enters the orbit through a cranio-orbital foramen (of Hyrtl), and directly fills the lacrimal artery.³⁹ This type of orbital branch of the middle meningeal was found in 43% of the cadaveric specimens.⁴⁰
 - *Temporo-occipital (aka temporal).*
It usually arises distal to the sphenoidal branch and curves posteriorly. It supplies skull and dura of the middle cranial

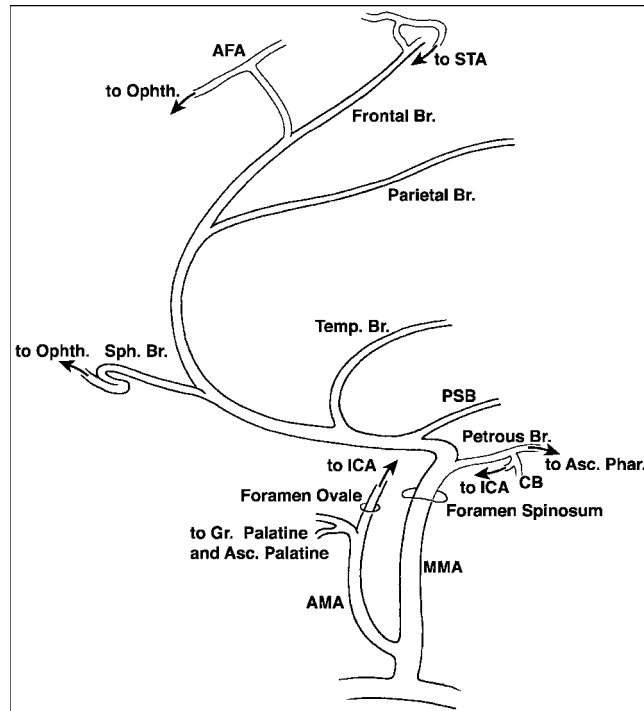


Fig. 1.10 Middle meningeal artery: Branches and anastomoses. The middle meningeal artery (MMA) often has a large extracranial branch, the accessory meningeal artery (AMA), which, in turn has anastomoses with the greater palatine (Gr. Palatine) and ascending palatine (Asc. Palatine) arteries before entering the skull via the foramen ovale and anastomosing with cavernous branches of the internal carotid (ICA). The middle meningeal artery continues into the skull via the foramen spinosum. The petrous branch (Petrous Br.) is the first intracranial branch and anastomoses with ascending pharyngeal branches in the temporal bone and with ICA branches via its cavernous branch (CB). Petrosquamosal (PSB), temporal, parietal, and frontal branches supply the dura over the middle and anterior fossa. Transcranial anastomoses to the superficial temporal (STA) and midline anastomoses with the anterior falx (AFA) branch of the ophthalmic (Ophth.) are depicted. The sphenoidal branch (Sph. Br.) is a major collateral to the ophthalmic.

fossa and can extend all the way around the calvarium to the midline, sometimes contributing to the posterior falx and tentorium, but generally only in pathological states. It anastomoses with the petrosquamosal and parietal branches of the middle meningeal and potentially with scalp vessels via transcranial collaterals.

– *Parietal.*

One of the two terminal branches of the middle meningeal, this vessel contributes to the blood supply of anterior cranial fossa dura. It can be of a variable size and distribution, since it is in a hemodynamic balance with the frontal and temporo-occipital

branches, with which it can freely anastomose. The parietal branch reaches the vertex and can contribute to the walls of the superior sagittal sinus and falx. At the midline, it may anastomose with the contralateral middle meningeal artery. Transcranial anastomoses with scalp vessels (superficial temporal and occipital) are also seen, in virtually all 20 cadaver specimens studied.⁴¹

– *Frontal.*

Usually the last branch of the middle meningeal, this branch also is in hemodynamic balance with the parietal branch and can therefore be of a variable size and distribution. It is a major contributor to the blood supply of anterior cranial fossa dura. It can reach the midline and frequently anastomoses with the anterior falx branch of the ophthalmic. Other anastomoses include the ipsilateral parietal branch, the contralateral frontal branch, and transcranial collaterals from the scalp vessels, especially the frontal branch of the superficial temporal.

ii. Territories

The middle meningeal provides extensive flow to the calvarium and meninges of the anterior and middle fossae (Table 1.5). It

Table 1.5 Intracranial dural vascular supply

Dural structure/ region	Feeding arteries	...Which usually arise from:	Reference
Posterior fossa	Petrosquamosal	Middle meningeal	
	Petrous	Middle meningeal	
	Mastoid	Occipital	6
	Jugular	Ascending pharyngeal	6
	Hypoglossal	Ascending pharyngeal	6
	Posterior meningeal	Vertebral	6
Tentorium	Anterior meningeal	Vertebral	
	Artery of Bernasconi and Cassinari (marginal tentorial)	Cavernous carotid	19
	Basal tentorial	Cavernous carotid	19
	Petrosquamosal	Middle meningeal	19
	Mastoid	Occipital	19
Falx cerebri	Artery of Davidoff and Schechter	Posterior cerebral	63
	Anterior falx artery	Ophthalmic	
	Frontal and parietal branches	Middle meningeal	
Anterior cranial fossa	Artery of Davidoff and Schechter	Posterior cerebral	63
	Ethmoidals	Ophthalmic	6
	Recurrent meningeal	Ophthalmic	
	Anterior falx	Ophthalmic	
	Sphenoidal	Middle meningeal	
Middle cranial fossa	Frontal and parietal branches	Middle meningeal	
	Inferolateral trunk	Cavernous carotid	6
	Accessory meningeal	Middle meningeal	6
	Temporo-occipital	Middle meningeal	6
	Recurrent meningeal	Ophthalmic	6
	Carotid branch	Ascending pharyngeal	6

These vessels should be considered when evaluating vascular lesions in or around the dura

has important collaterals to the internal carotid circulation.⁴² The middle meningeal can have contributions to the cranial nerves in the cavernous sinus via the cavernous branch and also to the facial nerve via the superior tympanic branch.

iii. Variants

The middle meningeal artery develops from the fetal stapedia artery. This stapedia artery arises from the fetal hyoid artery, a branch of what is to later become the petrous internal carotid, and passes through the mesenchyma that later becomes the stapes (hence the name). The stapedia gives rise to supraorbital, maxillary and mandibular branches, which are later incorporated into the external carotid. The supraorbital anastomoses with the developing ophthalmic territory.⁶ Persistence of portions of fetal vessels that usually regress and/or regression of segments that usually persist, results in a number of congenital variants.⁴³

- Distal middle meningeal can frequently be seen to arise from the ophthalmic.⁴⁴
- Middle meningeal may arise from the internal carotid.^{45, 46}
- Ophthalmic may arise from the middle meningeal.⁴⁷⁻⁵⁰
- A number of extracranial branches may arise from the middle meningeal, including a palatine branch,⁵¹ as well as the posterior superior alveolar artery.⁵²
- Tentorial branches (usually arising from cavernous carotid) may arise from the middle meningeal.⁵³
- Occasionally, the middle meningeal may arise from the basilar artery.⁵⁴⁻⁵⁶
- The size and general direction of the distal middle meningeal branches can be extremely variable.
- Dural-to-pial collateral flow from middle meningeal branches to anterior or middle cerebral branches can occur. However, these are almost always seen in the presence of occlusive disease (such as carotid occlusion with impaired collateral flow)⁵⁷ or in cases of high-flow lesions (such as brain arteriovenous malformations). These are likely acquired connections due to high flow demand and release of angiogenic factors, rather than a true congenital variation.

(d) Accessory meningeal

This small branch arising from either the proximal middle meningeal or less commonly from the IMA just distal to the middle meningeal, takes a characteristic gently curving antero-superior course. Ironically, in spite of its name, only about 10% (range 0-40%) of its blood supply is intracranial.⁵⁸

i Branches

Terminal branches of the accessory meningeal are variable in size, configuration, and variably named in the literature.⁵⁹ The major branches are most commonly described by the general direction they take from the accessory meningeal. There are ascending, descending, and recurrent rami.⁵⁸

- Lateral territory ascending ramus (aka posterior branch)
- Medial territory ascending ramus (aka inferomedial branch)
- Intracranial ascending ramus (aka intracranial branch). Small branch usually enters the skull via foramen ovale
- Descending companion ramus to the medial pterygoid nerve (aka *arteria pterygoidea medialis*)
- Anterior descending ramus (aka inferopalatine branch). This is the apparent continuation of the main accessory meningeal. Can supply to the soft palate and the nasal cavity.
- Variable recurrent rami to mandibular nerve and otic ganglion

ii Territories

There are lateral, medial and intracranial territories. Most of the blood supply is extracranial, supplying lateral and medial pterygoid and levator veli palatine muscles, the pterygoid plates and greater wing of the sphenoid bone, the mandibular nerve and otic ganglion. Can occasionally have considerable supply to the posterior nasal cavity and can be a source of nasal bleeding.⁶⁰

The intracranial contribution is usually small and enters the skull through foramen ovale (most commonly) or the sphenoidal emissary foramen of Vesalius (22% of cases).⁵⁸ The intracranial rami supply the meninges of variable portions of the middle cranial fossa, portions of the cavernous sinus, including the trigeminal nerve and its ganglion.⁶ It can anastomose with the posterior limb of the cavernous carotid's inferolateral trunk.⁶¹

iii Variants

- Usually arises from the middle meningeal artery, when the internal maxillary is lateral to the lateral pterygoid muscle (superficial type IMA).
- Usually arises from internal maxillary artery itself, when MA is medial to the lateral pterygoid (deep type IMA).
- There can be multiple accessory meningeal arteries (25% of cases), but only rarely is it absent (4% of cases).⁵⁸
- There can be an anastomosis from the accessory meningeal to the superior cerebellar artery in a rare persistent trigeminal variant.⁶²

(e) Inferior alveolar (aka dental) artery

This branch takes an anterior-inferior angulation from its origin from the proximal internal maxillary. It then enters the mandibular foramen, following along the mandibular canal.

i. Branches

- *Mylohyoid branch.* It is a small branch to the mylohyoid muscle arising from the inferior alveolar, before it enters the mandibular canal. It anastomoses with the submental branch of the facial.⁶
- *Incisive branch.* One of the two terminal branches of the inferior alveolar, the incisive branch under the incisor teeth, reaching the midline and anastomosing with the contralateral incisive branch.⁶
- *Mental branch.* This branch travels out through the mental foramen of the mandible to anastomose with the submental and inferior labial branches of the facial artery.⁶

ii. Territories

The inferior alveolar supplies the mylohyoid muscle, the mandible, mandibular teeth, the inferior alveolar nerve, and the soft tissues of the chin.

iii. Variants

- The inferior alveolar arises as a common trunk with the middle deep temporal in the deep type internal maxillary variant.
- Inferior alveolar may arise directly from the external carotid⁶⁴

(f) Middle deep temporal

Just to make things complicated, some authors refer to this branch as the posterior deep temporal, but the majority of authorities call it the middle deep temporal. The deep temporal arteries ascend in a relatively straight course, unlike the redundant superficial temporal branches. The middle deep temporal provides approximately one half of the blood flow to the temporalis muscle.³⁷ It can anastomose with the superficial temporal and occasionally, the transcranial collaterals from this vessel can anastomose with the middle meningeal branches. A common origin of the inferior alveolar and middle deep temporal arteries is a component of the deep-type internal maxillary variant.^{65, 66}

(g) Pterygoid branches

Small inferiorly directed branches of the distal pterygoid part to the pterygoid muscles that are not often visualized angiographically.

(h) Masseteric artery

Small, inferiorly directed branch to the masseter that anastomoses with masseteric branches of the facial and the transverse facial arteries.

(i) Buccal artery

Inferiorly directed branch that connects to the jugal trunk of the facial, supplying the soft tissues of the cheek from mucosa to skin, and providing collateral flow between distal internal maxillary artery and facial artery. Also has a connection to the transverse facial.

- (j) **Anterior deep temporal**
This vessel angles cephalad in a fairly straight course to provide approximately 30% of the blood supply to the temporalis muscle.³⁷ This vessel has important anastomoses to the lacrimal branch of the ophthalmic artery.
- (k) **Posterior superior alveolar**
It descends behind the maxilla before sending branches to bone, teeth, and gingiva in the posterior aspect of the maxilla.
- (l) **Infraorbital**
Anterior-most branch of the I.M.A. that passes through the inferior orbital fissure, then enters the infra-orbital canal to outline the roof of the maxillary sinus.⁶
- i. **Branches**
 - *Middle superior alveolar*. Provides contribution to alveolar process of the mandible.
 - *Anterior superior alveolar*. Also contributes to the supply of the maxillary teeth.
 - *Orbital*. This vessel primarily supplies the adipose tissue in the inferior aspect of the orbit, but can anastomose with the ophthalmic.⁶⁷
 - *Palpebral*. Distal branch to the lower eyelid, it anastomoses with the dorsal nasal branch of the ophthalmic.
 - *Naso-orbital*. They are small branches to the anterior-inferior orbit and side of the nose that also anastomose with the ophthalmic.
 - *Zygomatic branches*. Lateral branch (or branches) supplying the cheek and connecting to the transverse facial and to the jugal trunk of the facial artery.
 - ii. **Territories**
The infraorbital artery supplies the adjacent infraorbital (maxillary) nerve, mucosa and bony margin of the maxillary sinus.⁶⁸ Distal branches contribute to the lower eyelid and pre-maxillary cheek soft tissue.⁶ Both the orbital branch and the distal infraorbital (palpebral branch) freely anastomose with the ophthalmic, putting vision at risk when anything toxic is injected in the infraorbital.⁶⁹ There are also connections to the posterior superior alveolar, sphenopalatine, and the facial arteries.
 - iii. **Variants**
 - May be hypoplastic or hypertrophic, depending on the dominance of the facial artery.
 - Can arise in a common trunk with the posterior superior alveolar artery.
- (m) **Pterygo-vaginal artery**
It is a small branch running posteriorly from the IMA into the pterygoid canal and anastomosing with the accessory meningeal and ascending pharyngeal branches to the Eustachian tube region, and also potentially connecting to the petrous carotid.
- (n) **Vidian artery (aka artery of the pterygoid canal)**
It may arise from the pterygovaginal, or separately from the IMA. It enters the vidian canal and anastomoses with the vidian branch of the petrous internal carotid.
- (o) **Artery of foramen rotundum**
Small, posteriorly directed branch often displaying a characteristic wavy appearance as it passes through the foramen rotundum. Supplies maxillary nerve and adjacent skull base. It is an important collateral to the anterolateral branch of the inferolateral trunk (from cavernous carotid).
- (p) **Greater palatine (aka descending palatine)**
This fairly large vessel descends obliquely from its origin, travels in the greater palatine canal, and turns abruptly forward horizontally traveling medial to the maxillary teeth to supply the palate.
- i. **Branches**
 - *Lesser palatine artery*. Smaller branch or branches running parallel to the greater palatine, but in a separate bony canal, usually without a distal horizontal segment. May arise independently from the IMA.²⁷
 - *Palatine branch*. It is a small branch turning posteriorly to supply the soft palate that anastomoses with the middle pharyngeal and/or the ascending palatine.

- *Septal branch*. It is the terminal branch of the greater palatine at the incisive canal. It supplies the nasal septum and anastomoses with sphenopalatine and ethmoidal arteries.
- ii. Territories

A major contributor to the blood supply of the hard palate, it also contributes to the mucosa and gingiva, the soft palate, and tonsils.⁶ Anastomotic connections can exist with the contralateral greater palatine, and ipsilateral middle pharyngeal, ascending palatine, sphenopalatine, and even ethmoidal branches of the ophthalmic.¹⁹
- iii. Variants
 - Greater palatine may be hypoplastic or absent on one or both sides.
 - Bilateral hypoplasia of the greater palatine can be seen in cleft palate syndrome.⁷⁰
- (q) Sphenopalatine

It is a major branch of the terminal internal maxillary that enters the sphenopalatine foramen to supply the nasal cavity. The vessel can be a major source of bleeding in many cases of epistaxis. The sphenopalatine artery also supplies vascular lesions in the nasal cavity such as juvenile nasopharyngeal angiofibromas.

 - i. Branches
 - Septal

It is a small branch that first goes straight medially, then takes a right angle cephalad, then another right angle medially before spreading out into the nasal septum. It also supplies the superior turbinate in 72% of cases.⁷¹
 - Lateral nasal (aka posterior lateral nasal)

This branch travels inferiorly, before ramifying along the nasal turbinates to supply the bulk of the mucosa in the nasal cavity.
 - ii. Territories

Sphenopalatine arteries supply the mucosa of nasal cavity and are a very common source of bleeding in idiopathic epistaxis. They anastomose with ethmoidal branches of the ophthalmic, the greater palatine, and the septal branch of the superior labial artery.⁶
 - iii. Variants

None described.
- 2. Territories (IMA)

The internal maxillary artery supplies bones in the mid-and lower face, muscles of mastication mucosa in the nasal cavity, the palate, numerous cranial nerves (III–VII) and large areas of dura.⁶ There are multiple potential anastomoses with the internal carotid directly, the ophthalmic and numerous other vessels in the face and head.
- 3. Variants (IMA)
 - (a) Superficial-type IMA travels lateral to lateral pterygoid and is associated with accessory meningeal arising from middle meningeal (and separate origin of inferior alveolar and middle deep temporal directly from IMA) (Fig. 1.11).^{65, 66}
 - (b) Deep-type IMA travels medial to lateral pterygoid, and is associated with a common trunk giving rise to the inferior alveolar and middle deep temporal arteries (and origin of accessory meningeal directly from IMA).^{65, 66} Hint: “Deep-type” IMA has common origin of inferior alveolar and middle Deep temporal (Fig. 1.12).
 - (c) Rarely, the internal maxillary may arise as a common trunk with the facial artery.⁷²

1.3.9. Other ECA branches

Variable unnamed branches of the ECA may be present. They are usually small and not well seen angiographically, unless they are involved with a vascular malformation or neoplasm. The named branches that occasionally arise from the external carotid, normally arise from one of its major branches:

- (a) Tiny carotid body branches may arise from the proximal external carotid itself, or from the origins of proximal branches of the external carotid.
- (b) Sternocleidomastoid branch (or branches) can arise from the external, but normally arise from the superior thyroid, occipital, or posterior auricular.

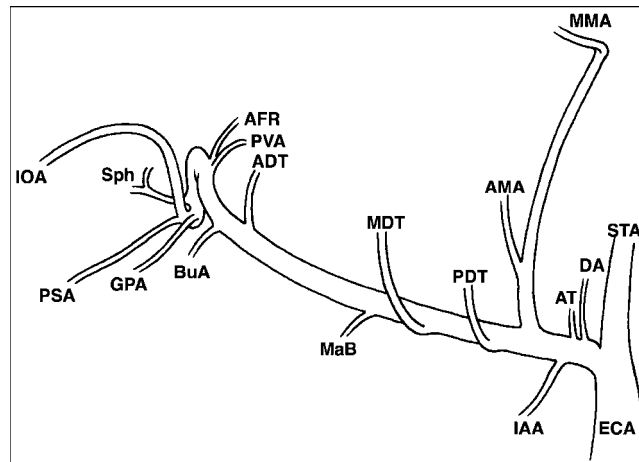


Fig. 1.11 Internal maxillary artery, Superficial-type variant. The internal maxillary artery (IMA) travels lateral to the lateral pterygoid muscle, and is characterized by separate origins of the middle deep temporal (MDT) and inferior alveolar artery (IAA). The accessory meningeal (AMA) arises from the proximal middle meningeal (MMA). Other IMA branches include deep auricular (DA), anterior tympanic (AT), posterior deep temporal (PDT), pterygoid branches (not shown), masseteric branches (MaB), buccal artery (BuA), anterior deep temporal (ADT), posterior superior alveolar (PSA), infraorbital (IOA), greater palatine (GPA), pterygo-vaginal (PVA), artery of foramen rotundum (AFR), sphenopalatine (Sph).

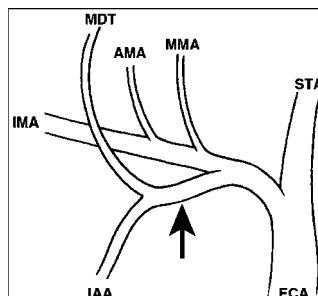


Fig. 1.12 Internal maxillary artery, deep-type variant. The deep type internal maxillary (IMA) is medial to the lateral pterygoid muscle. This variant has a common trunk (arrow) that gives rise to the middle deep temporal (MDT) and inferior alveolar artery (IAA). Also note separate origins of the accessory meningeal (AMA) and middle meningeal artery (MMA). Superficial temporal origin (STA) and distal external carotid (ECA) are also shown.

- (c) Superior laryngeal normally originates from the superior thyroid, but can arise separately from the external.
- (d) A recurrent pharyngeal branch to the upper oropharynx and palate can fill directly from the external carotid.²⁷
- (e) Small branch to the stylomastoid muscle can fill from the distal external carotid.
- (f) Small masseteric branch can originate from the distal external carotid.

- (g) Ascending palatine artery usually arises from the facial artery, but may originate directly from the proximal external carotid artery.
- (h) Transverse facial artery fairly frequently arises separately from the distal external carotid, although it is more often a branch of the superficial temporal.

1.4. Internal carotid artery

Several classification schemes exist for the segments of the ICA, including various numbering systems (Fig. 1.13). The numbering systems can be confusing and needlessly arcane for the purposes of everyday clinical work. In everyday clinical practice, the authors of this handbook favor the following simple system (corresponding to the description by Gibo and colleagues)⁷⁷

1. Cervical
2. Petrous
3. Cavernous
4. Supraclinoid

The segmental nomenclature used by Bouthillier and coworkers will be used in this chapter for the purpose of anatomic description.⁷⁸

The system established by Fischer in 1938 was intended to describe angiographic patterns of arterial displacement by intracranial tumors, number the ICA segments against the flow of blood, and exclude the extracranial ICA.⁷⁹ Subsequent systems have included the cervical segment and have numbered the segments with the flow of blood.

1.4.1. Cervical segment (C1)

This segment begins at the carotid bifurcation and ends at the skull base and usually has no branches. The carotid bifurcation is usually at the level of C3. The ICA receives approximately 80% of flow from the CCA. The ICA is encircled by sympathetic fibers, and travels in the carotid sheath, which also contains the internal jugular vein and the vagus nerve. Some authors state that the uppermost portion of the carotid sheath (superior to the nasopharynx) also contains cranial nerves IX, XI, and XII.

1. Divisions
 - (a) *Carotid bulb*. Focal dilation of the ICA at the origin, measuring 7.4 mm in diameter on average, compared to 7.0 mm for the CCA and 4.7 mm for the ICA distal to the carotid bulb.⁸⁰
 - (b) *Ascending cervical segment*. The diameter remains relatively constant throughout its course. Coiling or complete looping of the vessel is seen in up to 15% of angiograms.¹
2. Branches: None.

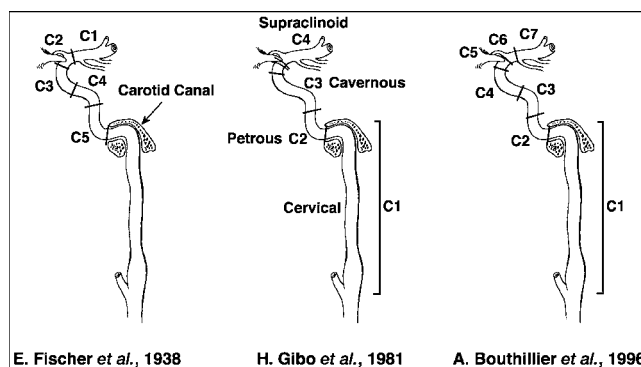


Fig. 1.13 Selected segmental classification schemes of the internal carotid artery.⁷⁷⁻⁷⁹

3. Variants

- (a) Position of origin. The carotid bifurcation can be found as low as T2 or as high as C1.¹ Rarely, the ICA may arise directly from the aortic arch; in these cases the non-bifurcating carotid artery gives rise to all of the branches normally supplied by the ECA and then continues as the ICA.⁸¹
- (b) Agenesis and hypoplasia
 - i. Congenital absence or hypoplasia of the ICA may occur sporadically in a association with other congenital anomalies, such as anencephaly or basal telangiectasia.⁸² Intracranial aneurysms are associated in about 67% of cases.⁸³
 - ii. Agenesis of the ICA has a prevalence of 0.01%⁸⁴ and can be distinguished from ICA occlusion by imaging of the skull base; in patients with agenesis, the carotid canal is absent.⁸⁵ It is more frequent on the left.⁸⁶
 - iii. Bilateral ICA agenesis is seen in <10% of ICA agenesis cases⁸⁶ and is associated with intracranial aneurysms in some 25% of cases.⁸⁷
 - iv. *ICA Hypoplasia* has an incidence of 0.079%,⁸⁶ and should not be confused with diffuse narrowing of the ICA, which is most commonly seen with fibromuscular dysplasia, dissection, or secondary to high-grade atherosclerotic stenosis. Congenital hypoplasia can be distinguished from acquired stenosis by the presence of a small petrous carotid canal.⁸⁵
- (c) Anomalous branches are rare but can include⁸⁸
 - i. Ascending pharyngeal artery
 - ii. Superior thyroid artery
 - iii. Occipital artery
 - iv. Posterior meningeal artery
 - v. Persistent stapedial artery
 - vi. Vidian artery
- (d) Duplication and fenestration of the cervical ICA has been reported.^{89, 90}
- (e) Carotid–vertebrobasilar anastomoses. See below.

1.4.1.1. Carotid–Vertebrobasilar anastomoses

Transient connections appear during development between the carotid and hindbrain circulations. These anastomoses usually disappear as the posterior communicating arteries develop; in rare cases these vessels persist into adulthood. The most common of these is the persistent fetal origin of the posterior cerebral artery, which has a prevalence of some 18–22% in the general population (see below).⁹¹ Three of the four other embryonic vessels are named for the cranial nerves they parallel. From superior to inferior, these persistent fetal vessels are (excepting the fetal PCA): *trigeminal*, *otic*, *hypoglossal*, and *proatlantal intersegmental* arteries (Fig. 1.14). A mnemonic for this uses the acronym *TO(h)P*: The primitive anastomotic vessels appear near the *TO(h)P* of the craniospinal axis.

- 1. Persistent trigeminal artery
 - (a) Most common carotid-basilar anastomosis, seen in some 0.1–0.2% of angiograms.^{33, 88}
 - (b) Extends from the cavernous ICA to the upper part of the basilar artery and often perforates the dorsum sellae.
 - i. The vertebrobasilar system proximal to the upper basilar artery may be hypoplastic, with the primitive trigeminal artery supplying most of the flow to the PCAs and the SCAs.
 - (c) Two main variants.⁹² The relative prevalence of the two types is almost equal.⁹³
 - i. *Saltzman Type I*. The persistent trigeminal artery supplies the PCA and SCA territories. The posterior communicating arteries and the basilar artery proximal to the anastomosis are hypoplastic.
 - ii. *Saltzman Type II*. The PCAs are supplied by the posterior communicating arteries, and the persistent trigeminal artery joins the basilar artery at the level of the SCAs.
 - (d) Associated with intracranial aneurysms.
 - (e) May have an intrasellar component and should not be mistaken for a pituitary mass.⁹⁴
- 2. Persistent otic artery
 - (a) Most rare carotid-basilar anastomosis.

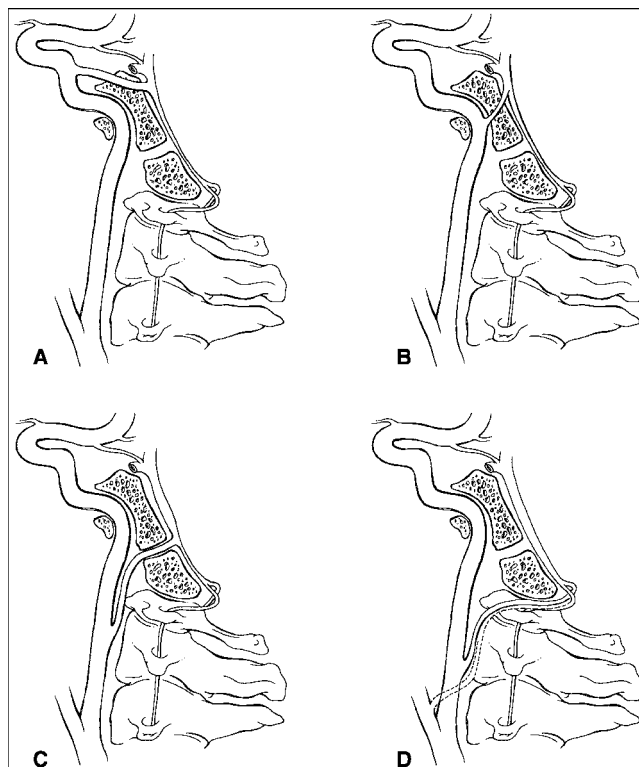


Fig. 1.14 Carotid–vertebrobasilar anastomoses. The most common configuration of each type of persistent embryologic connection between the carotid and vertebrobasilar system are shown. The persistent fetal origin of the PCA is illustrated in Fig. 1.20. (A) Persistent trigeminal artery; (B) Persistent otic artery; (C) Persistent hypoglossal artery; (D) Proatlantal intersegmental artery, Type I (*dashed*) and Type II (*solid*).

- (b) Extends from the petrous ICA to the basilar system via the internal auditory canal.^{95, 96}
- (c) The existence of this variant is controversial, and some authors argue that the otic artery does not exist as a separate entity.³³
- 3. Persistent hypoglossal artery
 - (a) Second most common carotid-basilar anastomosis, seen in 0.03–0.26% of angiograms.⁹⁷
 - (b) Extends from the cervical ICA to the basilar artery via the hypoglossal canal.
 - i. Arises from the ICA between the carotid bifurcation and C1.
 - ii. The posterior communicating arteries may be absent.⁹⁸
 - iii. The ipsilateral vertebral artery is usually hypoplastic.
 - (c) May be associated with an aneurysm.⁹⁹
- 4. Proatlantal intersegmental artery
 - (a) Extends from the cervical ICA or ECA to the vertebrobasilar system via the foramen magnum. Extremely rare.
 - (b) Associated with aplasia or hypoplasia of the vertebral arteries in 50% of cases.¹⁰⁰

- (c) Type I
 - i. Arises from the ICA at C2–3, courses horizontally above the atlas, and gives rise to the ipsilateral vertebral artery.
 - ii. More common than Type II.
- (d) Type II
 - i. Arises from ICA and joins the vertebral artery at C1.
 - ii. May have a common origin with the occipital artery.¹⁰¹

1.4.2. Petrous segment (C2)

The petrous segment extends from the opening of the carotid canal in the skull base to the posterior edge of the foramen lacerum. The vertical subsegment transitions into the horizontal subsegment via the genu of the petrous ICA, which is a 90° bend in the vessel. At the entrance into the carotid canal, the carotid sheath splits into two layers; the inner layer continues as the periosteum of the carotid canal, and the outer layer is continuous with the periosteum of the inferior surface of the skull base. Post-ganglionic sympathetic fibers (internal carotid nerve) continue to travel with the ICA. A venous plexus also surrounds the petrous ICA; the existence of this venous plexus has been proposed to effectively dampen the pulsation of the carotid, making it less perceptible by the adjacent hearing apparatus.¹⁰² In fact, anatomic specimens have shown that the venous plexus seems to be most prominent on the side of the vessel facing the cochlea, a finding that lends support to the theory (Fig. 1.15).

1. Subsegments
 - (a) Vertical
 - i. Average length is 10.5 mm.¹⁰³
 - (b) Horizontal
 - i. Approximately twice the length of the vertical subsegment; average length is 20.5 mm.¹⁰³
 - ii. A 1-cm length of this segment may be exposed in the floor of the middle fossa lateral to the trigeminal nerve, and covered by dura only or a thin layer of cartilage.
2. Branches
 - (a) Normal petrous ICA branches are visible on angiography in only 23% of cases.¹⁰⁴ In a cadaver dissection series, the petrous ICA was found to have branches in only 38% of the specimens (a Vidian branch in was found in 30%, and a periosteal branch was present in 8%); the “carotico-tympanic artery,” was not found in single case.¹⁰³
 - (b) Periosteal branch
 - i. Arises at the entrance of the ICA into the carotid canal. Found in 8% of the dissections.¹⁰³

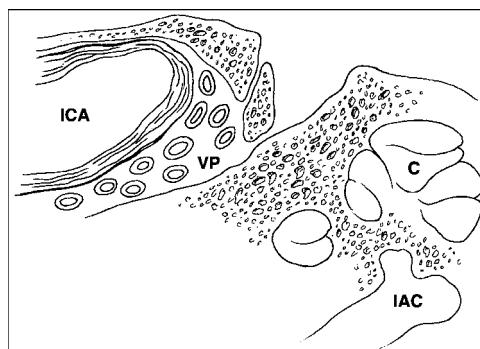


Fig. 1.15 Relationship between the pericarotid venous plexus and the cochlea. Drawing of a histological section through the temporal bone showing that the pericarotid venous plexus (VP) is most developed on the side of the ICA facing the cochlea (C) IAC, internal auditory canal.

- (c) Caroticotympanic artery
 - i. Commonly described branch of the petrous ICA, although its existence has been disputed by some authors.¹⁰³
 - ii. Arises from the petrous ICA near the genu and travels superiorly and posteriorly to the middle ear cavity.
 - iii. Anastomoses with the ascending pharyngeal artery via the inferior tympanic artery.¹⁰⁴
 - (d) Vidian artery (aka artery of the pterygoid canal)
 - i. Small branch that may arise from the horizontal petrous ICA and travels anteriorly within the Vidian (pterygoid) canal to the pterygo-palatine fossa. The Vidian canal is in the floor of the sphenoid sinus and also contains the Vidian nerve.
 - The Vidian nerve is formed by the combination of the deep petrosal nerve (containing sympathetic fibers from the plexus surrounding the ICA) and the greater superficial petrosal nerve (containing parasympathetic and sensory fibers).
 - ii. Anastomoses with branches of the internal maxillary artery.
3. Variants
- (a) Aberrant ICA.
 - i. The ICA enters the temporal bone posterior to the external auditory meatus, ascends between the facial canal and the jugular bulb, and passes within the middle ear cavity.
 - May present as a pulsatile mass within the middle ear or with hearing loss; this variant must be kept in mind to avoid a potentially disastrous biopsy procedure.
 - Predilection for woman (67% of patients are female); 15% are bilateral.¹⁰⁵
 - As discussed above, the so-called “aberrant ICA” is more appropriately termed ascending pharyngeal artery supplying collateral flow to segmentally atretic internal carotid.¹⁸
 - (b) Persistent stapedial artery
 - i. A rare, persistent embryonic vessel that appears as a branch of the vertical segment of the petrous ICA, travels through the middle ear, and gives rise to the middle meningeal artery.¹⁰⁶
 - (c) Persistent otic artery (described with the other carotid–vertebrobasilar anastomoses, above).

1.4.3. Lacerum segment (C3)

The lacerum segment is a short part of the vessel that extends from the petrous ICA to the cavernous segment, over the foramen lacerum. The foramen lacerum is approximately 1-cm long and is filled with fibrocartilage, amounting to a “closed floor” over which the ICA passes.¹⁰³ The foramen lacerum is not a true foramen, as no significant structures (other than the Vidian nerve) travel through it. The lacerum segment is separated from the cavernous segment by the petrolingual ligament. The petrolingual ligament is a small fold of periosteum that extends from the lingula of the sphenoid bone to the petrous apex,¹⁰⁷ and represents a continuation of the periosteum of the carotid canal.⁷⁸ The lacerum segment lies inferior to the trigeminal ganglion, and has thus been termed the “trigeminal segment” by some authors.¹⁰⁸ The foramen lacerum is vulnerable to wayward placement of needles or electrodes during percutaneous procedures, such as foramen ovale instrumentation for trigeminal neuralgia.¹⁰⁹ Among patients with basilar skull fractures, the junction between the lacerum and cavernous segments is the most frequently fractured segment of the carotid canal (62% of all carotid canal fractures occur at that site).¹¹⁰

1. Subsegments: None.
2. Branches: None.
3. Variants: None.

1.4.4. Cavernous segment (C4)

The cavernous segment is S-shaped and extends from the superior margin of the petrolingual ligament, through the cavernous sinus, to the proximal dural ring (Fig. 1.16). This portion of the ICA is surrounded by areolar tissue, fat, postganglionic sympathetic fibers, and the interconnecting venous chambers of the cavernous

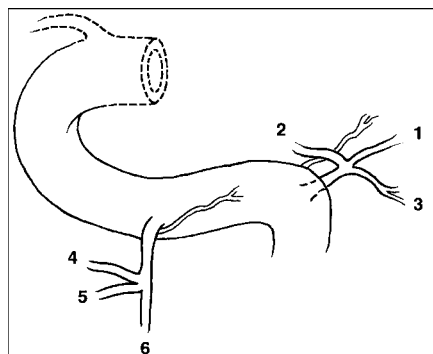


Fig. 1.16 Cavernous internal carotid artery.

Lateral view of the cavernous segment of the ICA. Major branches:

- Posterior trunk
 - (a) Tentorial artery (1)
 - (b) Inferior hypophyseal artery (2)
 - (c) Dorsal meningeal artery (3)
- Lateral trunk
 - (a) Anteromedial branch (4)
 - (b) Anterolateral branch (5)
 - (c) Posterior branch (6)
- Medial branch group – not shown here because they arise from the opposite side of the ICA from that shown.

sinus. The ICA rests directly against the lateral surface of the body of the sphenoid bone in a groove called the carotid sulcus, which defines the course of the cavernous segment of the ICA.¹¹¹ The cavernous ICA also travels directly adjacent to the wall of the sphenoid sinus; a layer of bone less than 0.5-mm thick separates the artery from the sinus in almost 90% of cases, and a complete absence of bone between the artery and the sinus is present in nearly 10%.¹¹¹ In some cases, the ICA may actually extend into the sphenoid sinus, an anatomic variant that should be kept in mind during surgery of the sphenoid sinus. The cavernous segment of the ICA forms the greater part of the carotid siphon (Fig. 1.17).

1. Subsegments:¹¹²

- (a) Posterior vertical
- (b) Posterior bend
- (c) Horizontal
 - i. Longest part of the cavernous ICA.
- (d) Anterior bend
- (e) Anterior vertical

2. Branches:

- (a) The most prominent branches of the cavernous ICA can be divided into three groups.¹¹³ These branches are highly variable; the most consistent branches are the posterior and lateral trunks.¹¹²
 - i. Posterior trunk (aka the meningohypophyseal artery) arises from the posterior bend of the cavernous ICA approximately 10 mm distal to the foramen lacerum.¹¹² All three of the following branches are found in some 70% of dissections:¹¹²
 - Tentorial artery. This vessel is the most consistent branch of the posterior trunk, being present in 100% of dissections.¹¹⁴ It has two branches:
 - (a) Marginal artery of the tentorium (aka artery of *Bernasconi and Cassinari*).¹¹⁵ Travels posteriorly along the medial edge of the tentorium. This artery may arise directly from the ICA.
 - (b) Basal tentorial artery. Travels laterally along the border between the tentorium and the petrous ridge. Anastomoses with the middle meningeal artery and the dural arteries of the posterior fossa.⁵

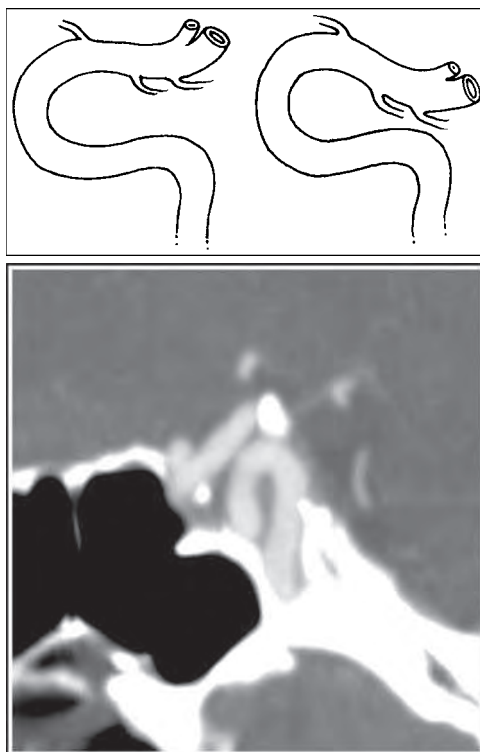


Fig. 1.17 Carotid siphon. The *carotid siphon* is an S-shaped part to the ICA; it begins at the posterior bend of the cavernous ICA and ends at the ICA bifurcation. It can have an open configuration (*left*) or a closed one (*right*), with obvious implications for the ease of endovascular navigation in this region. A closed siphon anatomy can be attributed in some cases to exaggerated tortuosity of the ICA, as can be seen in patients with advanced age or fibromuscular dysplasia.¹²¹ A CTA image of a closed siphon in a patient with an ophthalmic segment aneurysm (*below*).

- Inferior hypophyseal artery
 - (a) Travels in a superior and medial direction to supply the posterior lobe of the pituitary gland.¹¹⁶ It anastomoses with the superior hypophyseal artery, the medial branch group, and the contralateral inferior hypophyseal artery.
- Dorsal meningeal artery. Two branches that supply dura of the skull base:
 - (a) Lateral clival artery
 - (b) Dorsal (aka medial) clival artery
- Recurrent artery of foramen lacerum: Tiny vessel that may anastomose with the carotid branch of the ascending pharyngeal.¹⁹
- ii. Lateral trunk (aka the inferolateral trunk, artery of the inferior cavernous sinus, or lateral main stem) arises from the lateral aspect of the horizontal segment and travels superior to the abducens nerve to supply cranial nerves within the cavernous sinus. It is found in about 66% of dissections.¹¹³

- *Anteromedial branch*. May anastomose with the ophthalmic artery via its recurrent meningeal branch.
 - *Anterolateral branch*. May anastomose with the artery of the foramen rotundum.
 - *Posterior branch*. May anastomose with the cavernous branches of the middle and accessory meningeal arteries.
 - *Superior branch*. Very small vessel that may anastomose with ophthalmic.¹⁹
- iii. Medial branch group (aka capsular arteries of McConnell) arises from the most superior portion of the cavernous segment, and supplies the pituitary gland. They are found in only about 28% of dissections.¹¹³
- iv. Other cavernous ICA branches:
- Ophthalmic artery (found to arise from the cavernous segment, instead of the ophthalmic segment), in about 8% of cases¹¹⁷
 - Recurrent artery of the foramen lacerum
 - Artery of the Gasserian ganglion
3. Variants:
- (a) Kissing intrasellar ICAs
- i. The cavernous ICA may extend beyond the medial wall of the cavernous sinus and run medially in the sella turcica. The ICAs approach within 4 mm of each other within the sella in some 10% of cases.¹¹⁸ Has been associated with acromegaly.¹¹⁹
- (b) Intercavernous ICA anastomoses
- i. Hypoplasia or agenesis of the ICA can be associated with an intercavernous ICA anastomosis, in which a large collateral vessel connects the cavernous carotid arteries.^{84, 85, 120}
- (c) Persistent trigeminal artery (described with the other carotid–vertebro-basilar anastomoses, above).

1.4.5. Clinoidal segment (C5)

The clinoidal segment comprises a tiny wedge-shaped part of the ICA between the proximal and distal dural rings (Fig. 1.18). The anterior clinoid process lies superior and lateral to the clinoidal ICA, over the part of widest separation between the dural rings. Although this segment is described as “interdural,” the carotid is surrounded in this region by a “dural collar” that contains venous tributaries of the cavernous sinus, known as the clinoid venous plexus.¹¹⁴ These venous channels extend to the distal dural ring and have implications for surgery in this region.

1. Subsegments: None
2. Branches: The ophthalmic artery may arise from the clinoidal segment in rare cases.¹
3. Variants: None.

1.4.6. Ophthalmic segment (C6)

The ophthalmic segment is the most proximal intradural part of the ICA and extends from the distal dural ring to the origin of the posterior communicating artery. The average length is 9.6 mm.⁷⁷ The optic nerve travels superior and medial to the ICA in this region, and the sphenoid sinus is anterior and inferior. The optic strut is a bony process that extends between the base of the anterior clinoid to the body of the sphenoid bone. The optic strut separates the optic canal from the superior orbital fissure, and the identification of the optic strut on CT can help distinguish cavernous segment aneurysms from ophthalmic segment aneurysms.¹²³

1. Subsegments: None.
2. Branches:
 - (a) *Ophthalmic artery* (Fig. 1.19)
 - i. The ophthalmic artery arises from the anterior aspect of the ICA medial to the anterior clinoid process. The vessel originates distal to or at the distal dural ring in >90% of cases; in about 8% of cases, the vessel arises from the cavernous segment.¹¹⁷ The artery then usually travels inferior and lateral to the optic nerve in the optic canal. Within the orbit, the ophthalmic artery loops inferior and lateral

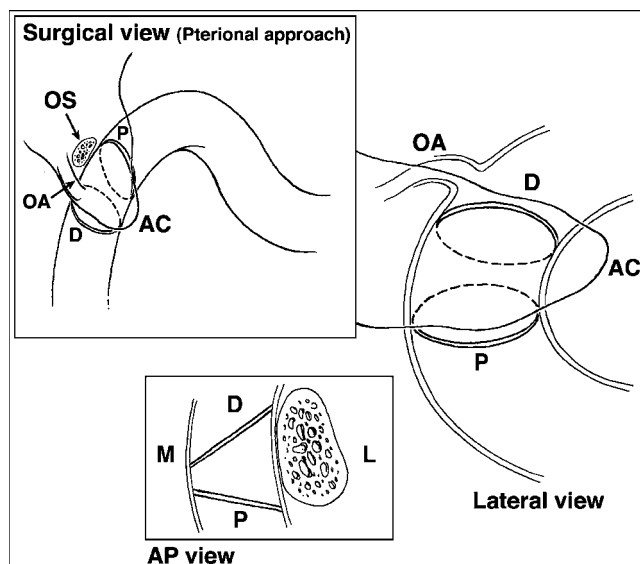


Fig. 1.18 Clinoidal segment

The clinoidal segment is defined by the proximal (P) and distal (D) dural rings, which are related to one another at an angle, like two dinner plates nearly touching on one edge.

The space between the dural rings is wide on the lateral aspect of the ICA and small on the medial aspect, where the dural rings come closest together. The medial part of the distal dural ring is incomplete; this region, which includes the proximal portion of the ophthalmic segment, is known as the "carotid cave" and is a site for aneurysm formation.^{108, 122} The anterior clinoid process (AC) extends like a thumb over the clinoidal segment; the relationships between the dural rings and the anterior clinoid are variable.

OA, ophthalmic artery; OS, optic strut; M, medial; L, lateral.

to the optic nerve in 83% of cases, and then approaches the globe along its medial aspect. In 17% of cases, the ophthalmic artery stays medial and inferior to the optic nerve throughout its course.¹¹⁷

- ii. The diameter of the ophthalmic artery at the origin averages 1.4 mm (range, 0.9–2.1 mm).¹²⁴
- iii. Ophthalmic artery branches. The ophthalmic artery branches are highly variable, and anastomoses with the branches of the external carotid artery are extensive. Ophthalmic artery branches can be divided into three groups:
 1. Ocular group
 - (a) Central retinal artery
 - i. Arises from the ophthalmic artery as a single trunk or in common with a posterior ciliary artery, then penetrates the optic sheath and optic nerve to supply the retina.¹²⁴ The central retinal artery is a terminal branch of the ophthalmic artery and a true end-artery, with no appreciable collateral circulation. Occlusion of the central retinal artery usually results in loss of vision.
 - ii. The inner diameter averages 400 μm (range, 300–600 μm).¹²⁴

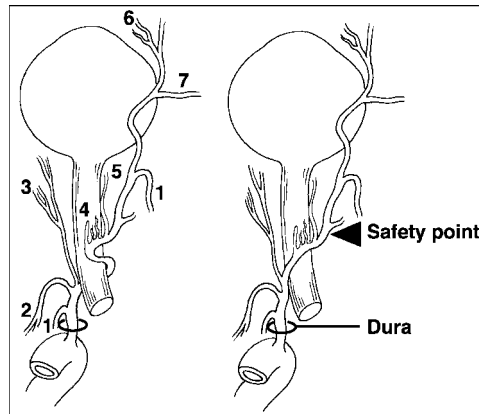


Fig. 1.19 Ophthalmic artery.

Superior and lateral views of the ophthalmic artery (OA). In 83% of cases, the OA passes around the lateral aspect of the optic nerve (*left*); in the remaining cases the OA stays medial to the optic nerve (*right*). Significant branches include:

1. Recurrent meningeal arteries
2. Posterior ethmoidal artery
3. Muscular branches
4. Central retinal artery
5. Ciliary arteries (anterior and posterior)
6. Lacrimal artery
7. Anterior falx artery

The OA can be divided into three segments:¹²⁹

1. Segment 1. Extends from the entrance of the OA into the orbit to the point where the vessel changes direction to cross over or under the optic nerve.
2. Segment 2. Short part of the vessel as it passes over or under the nerve.
3. Segment 3. Extends from the bend in the vessel on the medial aspect of the optic nerve, to the edge of the orbit.

The *safety point*, beyond which embolization can be done with minimal risk of embolization of the retina, is generally thought to be anywhere beyond Segment 2.¹³⁰

(b) Ciliary arteries

- i. Divided into posterior and anterior ciliary arteries, these vessels produce the *choroidal blush* seen on lateral angiography.

2. Orbital group

(a) Lacrimal artery

- i. The lacrimal artery arises from the ophthalmic artery adjacent to the optic nerve and passes along the lateral rectus muscle to irrigate the lacrimal gland and conjunctiva. It anastomoses anteriorly with branches of the superficial temporal artery, and with multiple branches of the internal maxillary artery.¹²⁵
- ii. A significant branch of the lacrimal artery is the recurrent meningeal artery, which travels back and out of the orbit through the superior orbital fissure, and anastomoses with the middle meningeal artery.

- (b) Muscular branches
 - i. Arteries that irrigate the extraocular muscles and periosteum of the orbit; each branch is named for the structure it irrigates (e.g., muscular branch to the medial rectus).
 - 3. Extraorbital group
 - (a) Ethmoidal arteries
 - i. These vessels supply the upper nasal mucosa and anastomose with branches of the sphenopalatine branches of the internal maxillary artery. They also perforate the cribriform plate to irrigate the dura of the anterior fossa.
 - ii. Anterior ethmoidal artery
 - 1. Gives rise to the anterior falx artery which enters the intracranial space via the foramen cecum.
 - iii. Posterior ethmoidal artery
 - 1. Anastomoses with branches of the sphenopalatine artery.
 - (b) Palpebral artery
 - i. Divides into medial, inferior medial, and superior medial palpebral branches.¹¹⁷ These branches anastomose with the frontal branch of the superficial temporal artery and the infraorbital branch of the internal maxillary artery.
 - (c) Terminal portion of the ophthalmic artery
 - i. The ophthalmic artery terminates by dividing into the
 - 1. Supratrochlear branch
 - a. Anastomoses with branches of the superficial temporal artery.
 - 2. Dorsal nasal branch
 - a. Anastomoses with branches of the facial artery.
 - iv. Ophthalmic artery variants

Several anomalous origins of the ophthalmic artery have been described. The most common is a middle meningeal artery origin, seen in nearly 16% of cases in a dissection series¹²⁶ (conversely, an ophthalmic origin of the middle meningeal artery is seen in about 0.5% of the angiograms).⁴⁴ Other reported anomalous origins include the cavernous ICA, the MCA, ACA, or PCA, and the basilar artery.¹¹⁷
 - (b) *Superior hypophyseal artery*
 - i. There is an average of 1.8 superior hypophyseal arteries arising from the ICA, and most originate within 5 mm of the ophthalmic artery origin.¹²⁷ Superior hypophyseal arteries appear in two forms: in 42% of cases, a single large artery branches like a candelabra into smaller branches, and in the remaining cases, two or three hypophyseal arteries are present.¹²⁷ The vessels then travel toward the origin of the pituitary stalk and connect with the branches of the contralateral superior hypophyseal artery and the posterior communicating arteries to form a circumfundibular anastomosis.¹²⁷ The superior hypophyseal arteries and the circumfundibular plexus are distributed to the pituitary stalk and the anterior lobe of the pituitary (the inferior hypophyseal branch of the meningohypophyseal artery irrigates the posterior lobe).⁷⁷
 - (c) *Perforating branches*
 - i. Several perforating branches arise from the ophthalmic segment that are not properly included with the superior hypophyseal arteries. They arise from the posterior or medial aspect of the ICA and primarily irrigate the optic chiasm, the optic nerve, the floor of the third ventricle, and the optic tract.⁷⁷
3. Variants: Most discussions of anatomic variants of the ophthalmic segment of the ICA are limited to anomalous origins of the ophthalmic artery (see above). A fenestration of the ophthalmic segment of the ICA has been reported.¹²⁸

1.4.7. Communicating segment (C7)

The communicating segment begins just proximal to the origin of the posterior communicating artery and ends with the bifurcation of the ICA into the ACA and the MCA. The average length is 10.6 mm.⁷⁷

1. Branches

(a) Posterior communicating artery

- i. The posterior communicating artery arises from the ICA at an average of 9.6mm distal to the ophthalmic artery and 9.7mm proximal to the ICA bifurcation.⁷⁷ It travels posteromedially an average distance of 12 mm, to join the PCA at the junction between the P1 and P2 segments.
- ii. Branches. The number of perforating arteries ranges from four to 14, with an average of 7.8.⁷⁷ These branches terminate in the floor of the third ventricle, the posterior perforated substance, optic tract, pituitary stalk, and optic chiasm.³¹ These perforators reach the thalamus, hypothalamus, and internal capsule. These vessels are called the anterior thalamoperforators (to distinguish them from the thalamoperforators that arise from the P1 segment); the largest and the most constant of these is the premamillary artery.⁹¹
- iii. Variants
 1. Persistent fetal origin. A “fetal configuration” is defined as a prominent P-comm artery that gives rise to, and has the same diameter of, the P2 segment of the PCA (Fig. 1.20). This anatomy is present in 18–22% of cases.⁹¹ The associated ipsilateral P1 segment is usually hypoplastic.
 2. Infundibulum. A funnel-shaped origin of the P-comm artery (see below).
 3. Hypoplasia. Although a “hypoplastic” P-comm artery is present in upto 34% of the dissections, the complete absence of the vessel is very rare.⁹¹
 4. Absence. Complete absence of the P-comm artery is found in 0.6% of the dissections.¹³²
 5. Fenestration of the P-comm artery has been reported.¹³³

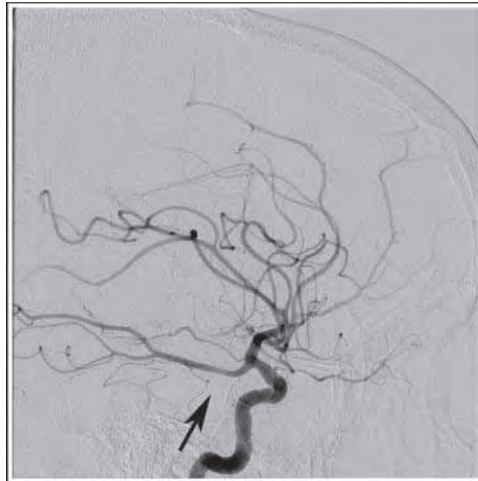

Fig. 1.20 Persistent fetal configuration of the posterior communicating artery. A posterior communicating artery is a “fetal” variant (*arrow*) when the diameter of the vessel is equal to the diameter of the P2 segment it connects to.

(b) *Anterior choroidal artery*

- i. The anterior choroidal artery (Fig. 1.21) arises from the posterolateral aspect of the ICA, 2–4 mm distal to the posterior communicating artery, and an average of 5.6 mm proximal to the ICA bifurcation.⁷⁷ The diameter of the vessel averages 1.0 mm⁷⁷, and is duplicated in 4% of cases.¹³⁴ The anterior choroidal artery has two segments:
 1. *Cisternal segment.* From the ICA, the vessel travels in a posterior direction, sweeping first medially, then laterally to pass around the cerebral peduncle. The anterior choroidal artery then angles upward as it passes through the choroidal fissure to enter the temporal horn of the lateral ventricle. The cisternal segment averages 24 mm in length and gives rise to an average of eight perforating branches;¹³⁴ these are the branches of the anterior choroidal artery that irrigate most of the vital structures that are vulnerable to ischemic injury with anterior choroidal artery occlusion.
 2. *Intraventricular segment.* Within the ventricle, the anterior choroidal artery travels with the choroid plexus, anastomosing with branches of the lateral posterior choroidal artery in this region. The artery then arcs up and around the thalamus, and in some cases it reaches as far as the Foramen of Monro and anastomoses with branches of the medial posterior choroidal artery. Branches from the intraventricular segment supply to the optic tract, lateral geniculate body and thalamus.¹³⁵
- ii. *Territories*
 1. The anterior choroidal artery sends the branches, in decreasing order of frequency, to the optic tract, cerebral peduncle, lateral geniculate body, uncus, and temporal lobe.⁷⁷ The brain structures irrigated by these branches include the optic radiations, globus pallidus, midbrain, thalamus, and posterior limb of the internal capsule. Occlusion of the anterior choroidal artery can produce contralateral hemiplegia, hemianesthesia, hemianopia, memory loss, and somnolence. Regions of the brain affected by the anterior choroidal artery occlusion on CT include the posterior limb of the internal cap-

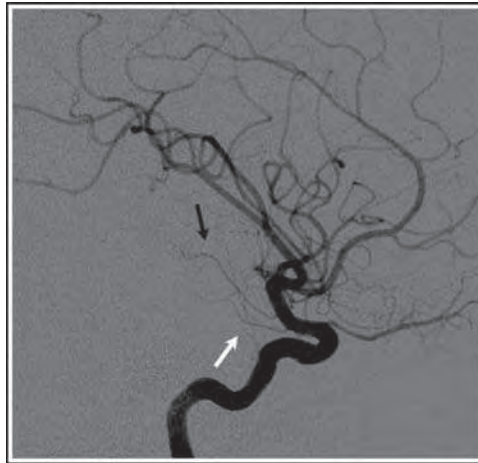


Fig. 1.21 Anterior choroidal artery. On a lateral angiogram, the cisternal segment of the anterior choroidal artery has a characteristic gentle, undulating appearance as it passes around the cerebral peduncle. A kink appears in the vessel (the plexal point, (black arrow)) where it enters the temporal horn. The posterior communicating artery (white arrow) travels inferior and parallel to the anterior choroidal artery.

sule, the retrolenticular portion of the internal capsule, the internal portion of the globus pallidus, and the lateral thalamus.¹³⁶ The severity of neurologic change after occlusion of the vessel is highly variable, however, presumably because of varying anastomoses with the posterior choroidal arteries as well as the PCA (and less commonly, the ACA and MCA). This variability was demonstrated by a functional neurosurgeon, Irving S. Cooper.¹³⁷ During a subtemporal approach for a cerebral pedunculotomy to treat a patient with Parkinson's disease, Cooper occluded the anterior choroidal artery because of an inadvertent injury to the vessel. The patient awoke after surgery with complete resolution of his tremor and rigidity, without any persistent hemiparesis. Deliberate occlusion of the anterior choroidal artery was undertaken for the treatment of Parkinson's disease in the 1950s.¹³⁸

iii. Variants

1. Ectopic origin. Seen in 4% of the dissections.¹³⁵
 - (a) The anterior choroidal artery may originate from the MCA or PCA.
 - (b) Rarely, the anterior choroidal artery may originate from the ICA proximal to the posterior communicating artery.¹³⁹
 2. Absence of the anterior choroidal artery is seen in 3% of angiograms.¹⁴⁰
 3. Hyperplasia, in which the anterior choroidal artery supplies part of the PCA territory, is seen in 2.3% of angiograms.¹⁴⁰
- (c) *Perforating branches*
- i. Perforators arising from the communicating segment extend to the optic tract, floor of the third ventricle, and the anterior perforated substance.⁷⁷

1.4.8. The infundibulum: a normal variant

An infundibulum is a conical, triangular, or funnel-shaped dilatation at the origin of an artery, and is found most commonly at the junction of the posterior communication artery and ICA (Fig. 1.22). At this location, an infundibulum has been defined as a symmetric bulge at the origin of the P-comm, with a maximum diameter of 3 mm.^{141, 142} The authors of this handbook have also found infundibula at the P-comm-PCA junction, the P2 segment, in the anterior communicating artery complex, the ophthalmic artery origin, and at the origin of the anterior choroidal artery. The reported prevalence of infundibula on otherwise normal angiograms is 7–15%.^{143–145} In some 25% of cases, the P-comm infundibula are present bilaterally. Angiographic criteria for infundibular dilatation include round or conical in shape, ≤ 3 mm in the maximum diameter, without aneurysmal neck, and with a posterior communicating artery arising from its apex.¹⁴¹

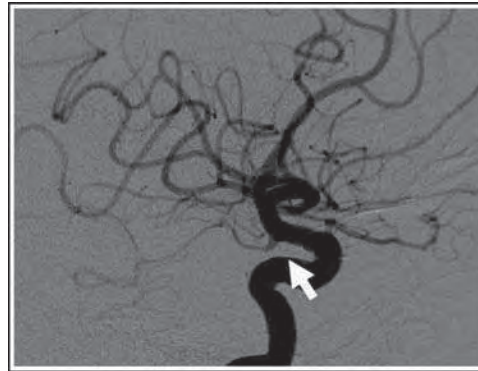

Fig. 1.22 Posterior communicating artery infundibulum.

1.5. Circle of Willis

The circle of Willis is the ring of interconnecting vessels that encircles the pituitary infundibulum and provides important collateral circulation between the carotid territories and the vertebrobasilar system (Fig. 1.23). It is actually a nonagon, a nine-sided structure, rather than a circle. Although it bears the name of Thomas Willis (named in honor of Willis by his student Lower), who described the structure in 1664 in a publication illustrated by Sir Christopher Wren,¹⁴⁶ earlier anatomists had recognized an arterial circle at the base of the brain.¹⁴⁷ Although a complete circle of Willis is present in some 90% of individuals, a well-developed and symmetric circle is found in <50% of cases.¹⁴⁸ In some 60% of cases, at least one component of the circle is relatively hypoplastic and diminished in its capacity to provide collateral flow.¹ Asymmetry of the circle of Willis results in significant asymmetry of flow,¹⁴⁹ and is an important factor in the development of intracranial aneurysms and in ischemic stroke. Patients with aneurysms are more likely to have asymmetry or an anomaly of the circle,¹⁵⁰ and the presence of a nonfunctional anterior collateral pathway in the circle of Willis in patients with ICA occlusive disease is strongly associated with ischemic stroke.¹⁵¹ The individual components of the circle are discussed separately in this handbook. Anatomic variations that cause asymmetry of the circle are listed in Table 1.6.

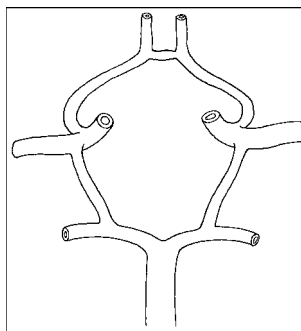


Fig. 1.23 Circle of Willis.

Table 1.6 Sources of asymmetry in the circle of Willis

Vessel	Variant	Incidence
A1 segment	Hypoplastic	10% ¹⁵²
	Absent	1–2% ¹
A-comm artery	Absent	5% ¹⁵³
P-Comm artery	Hyperplastic (Fetal)	18–22% ⁹¹
	Hypoplastic	34% ⁹¹
ICA	Absent	0.6% ¹³²
	Hypoplastic	0.079% ⁸⁶
P1 segment	Absent	0.01% ⁸⁴
	Hypoplastic	15–22%
	Absent	Rare ¹³²

1.6. Anterior cerebral artery

Several classification schemes for the ACA have been described. The simplest and most common system includes three segments (Fig. 1.24):

1. A1. From ICA to anterior communicating artery
2. A2. From anterior communicating artery to the origins of the pericallosal and supramarginal arteries
3. A3. Distal branches

1.6.1. A1 segment and anterior communicating artery complex

The A1 segment (aka the precommunicating segment)¹ extends from the ICA bifurcation in a medial and superior direction to its junction with the anterior communicating artery within or just inferior to the interhemispheric fissure. It travels superior to the optic chiasm or optic nerves and inferior to the anterior perforated substance. The A-comm complex is highly variable and may take one of the four main patterns (Fig. 1.25). The A-comm artery averages 4.0 mm in length and 1.7 mm in diameter.¹⁵⁴

1. Branches.

(a) A1 perforating branches can be divided into superior and inferior branches

- i. Some 2–15 superior branches are medial lenticulostriate arteries that travel superiorly and posteriorly into the anterior perforated substance and supply the anterior hypothalamus, septum pellucidum, anterior commissure, fornix, and the anterior striatum.¹⁵²
- ii. Inferior branches supply the optic chiasm and optic nerves.

(b) A-comm branches

- i. Perforating branches of the A-comm artery can be divided into subcallosal, hypothalamic, and chiasmatic branches, according to their vascular territories.¹⁵⁴ The subcallosal branch is usually single and the largest branch of the A-comm; it supplies the septum pellucidum, columns of the fornix, corpus callosum and lamina terminalis.¹⁵⁵ The hypothalamic branches are smaller and multiple. A chiasmatic branch is present in only 20% of cases.¹⁵⁴

(c) Recurrent artery of Heubner, most often an A2 branch, may arise from the A1 segment in upto 17% of cases and from the ACA-A-comm junction in 35% of cases.^{156, 157} (See below for further discussion of Heubner).

2. Variants

(a) A1 variants

- i. Asymmetry. The left and right A1 segments are asymmetric in size in upto 80% of cases.⁵ About 10% of the A1 vessels are hypoplastic (defined as having a diameter of ≤ 1.5 mm).¹⁵²
- ii. Absence. Absence of one A1 segment is seen in 1–2% of cases.¹
- iii. Persistent olfactory artery. Rare anomaly in which a persistent primitive olfactory artery travels from the ICA, along the olfactory tract, to supply the distal ACA territory.¹⁵⁸ May be associated with an aneurysm.¹⁵⁹

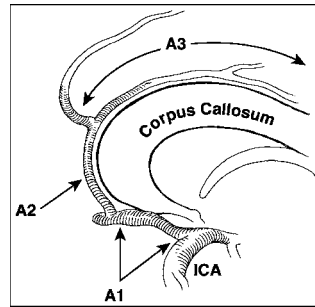


Fig. 1.24 Anterior cerebral artery. Left lateral oblique view of the left ACA.

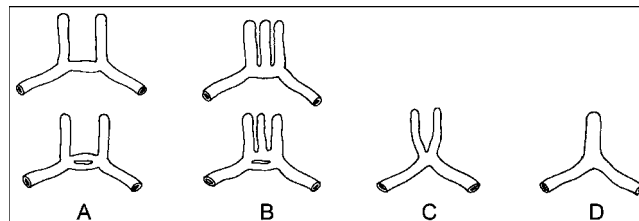


Fig. 1.25 Anterior communicating artery complex. In most cases, the A-comm complex assumes one of the four configurations.¹⁵⁴ A, A single, or duplicated A-comm forms a bridge between the ACAs. B, A single large branch arises from the A-comm. C, The A-comm vessel is not present, and the two ACAs join together directly. D, Azygos ACA.

- iv. **Infraoptic ACA.** In rare cases the A1 segment may travel inferior to or through the optic nerve.^{160–162} Associated with aneurysms.
 - v. **Fenestration of the A1 segment** is rare and is associated with aneurysms.^{163–165}
 - vi. **Accessory ACA.** An atypical branch of the ICA courses under the optic nerve and ACA to give rise to the orbitofrontal and frontopolar arteries.¹⁶⁶
 - vii. **Anomalous origins of the A1** from the cavernous ICA¹⁶⁷, from the ICA at or proximal to the ophthalmic artery,¹⁶⁸ and from the contralateral ICA¹⁶⁹ have been reported.
- (b) **A-comm artery variants.** Some 227 A-comm artery complex variations have been described.¹⁷⁰ A “normal” A-comm artery, in which single vessel forms a link between two non-anomalous ACAs, is present in only about 40% of cases.^{154, 156, 170, 171} Anomalous A-comm anatomy is present in the remaining 60% of cases. In an autopsy study, these patterns included plexiform (i.e., multiple complex vascular channels, 33%), dimple (i.e., incomplete fenestration, 33%), fenestration (21%), duplication (18%), string (18%), fusion (12%), median artery of the corpus callosum (6%), and azygos ACA (3%).¹⁵⁴ The A-comm artery is absent in some 5% of cases.¹⁵³

1.6.2. A2 segment

The A2 segment travels in a vertical direction from the A-comm artery to its division into the pericallosal and callosomarginal arteries, adjacent to the genu of the corpus callosum. Defined in this way, the A2 segment is analogous to the M1 segment of the MCA, which is defined in this handbook as ending with its bifurcation into the superior and inferior divisions. Although the authors of this handbook prefer this definition of the A2 segment, it is somewhat problematic, as some 18% of the hemispheres do not have a definite callosomarginal branch.¹⁷² Other authors have defined the A2–A3 junction as the part of the ACA immediately anterior to the corpus callosum genu¹ or at the junction between the rostrum and genu of the corpus callosum.⁵

Defined as extending from the A-comm to the origin of the callosomarginal artery, the length of the A2 segment averages 43 mm.¹⁷² The left and right A2 segments usually travel together in the interhemispheric fissure, although the right A2 is more often (72% of cases) anterior to the left A2 in the sagittal plane.¹⁷²

1. Branches

- (a) **Perforators.** Perforating branches of the A2 segment are located along the first 5 mm of the segment, and penetrate the brain at the gyrus rectus and olfactory sulcus.¹⁵⁶
- (b) **Recurrent artery of Heubner.** This vessel, which is a large lenticulostriate vessel, arises from the A2 segment in most (57–78%) cases.^{152, 156} It doubles back and runs in the opposite direction to the A1 segment to enter the lateral anterior perforated substance lateral to the ICA bifurcation.¹⁵⁷ The vessel supplies the head of the caudate nucleus, anterior limb of the internal capsule, and the anterior third of the putamen.¹⁷³ Although it is often not large enough to be seen on angiography, it is regularly identified during surgery of the A-comm complex; inadvertent occlusion of the vessel can occur by pinching the vessel during retraction of the frontal lobe. Isolated infarction of the territory of this vessel can be clinically silent, or produce a hemiparesis that is most prominent in the face and upper extremity.⁵
- (c) **Orbitofrontal artery.** This artery is the first cortical branch of the A2 segment, and may appear as two or three vessels, rather than single branch.¹⁷² The artery runs close to the midline in an anterior direction to the gyrus rectus, olfactory bulb, and medial aspect of the inferior frontal lobe.
- (d) **Frontopolar artery.** This artery may also appear as a group of vessels and usually arises from the distal A2 segment, below the corpus callosum. It travels anteriorly and superiorly towards the frontal pole.

2. Variants

- (a) **Bihemispheric ACA.** In this variant, one A2 segment is hypoplastic and the other A2 vessel irrigates both the hemispheres. Present in upto 7% of cases.¹⁷²
- (b) **Azygos ACA.** This is defined as a single unpaired A2 segment that arises from the junction of the A1s (Fig. 1.26). It is present in < 1% of the

- general population;¹⁷⁴ as many as 41% of patients with an azygos ACA have a terminal aneurysm.^{175, 176} This anomaly is also associated with holoprosencephaly.¹⁷⁷
- (c) *Duplicated A2.* More than one A2 segment has been reported in upto 13% of cases.¹ In some cases, this may represent persistence of the primitive median artery of the corpus callosum,¹ which is found in 6% of cases.¹⁵⁴
 - (d) *Superior anterior communicating artery.* An anomalous communicating vessel between the ACAs near the corpus callosum has been described and is associated with aneurysms.¹⁷⁸

1.6.3. A3 branches

The “A3 branches” include all the ACA branches distal to the origin of the pericallosal and callosomarginal arteries (Fig. 1.27). Other authors have further subdivided the distal ACA into A4 and A5 segments;^{79, 172} in this system, the A3 segment is defined as the part of the ACA that extends around the genu of the corpus callosum, and the A4 and A5 segments comprise the part of the ACA that travels posteriorly over the corpus callosum. The A4 and A5 segments are separated by the coronal suture.¹⁷² The distal ACA branches have extensive anastomoses with distal branches of the MCA and PCA. These connecting vessels, arising from the furthest reaches of the intracranial circulation, comprise the watershed zones; the corresponding territories of the brain are the most vulnerable to ischemia during hemodynamic failure.

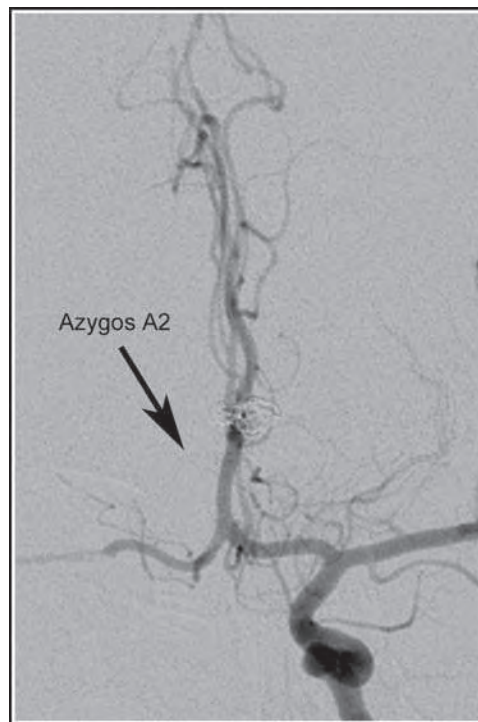

Fig. 1.26 Azygos anterior cerebral artery. In an azygos anterior cerebral artery, both A1 segments join to form single A2 segment.

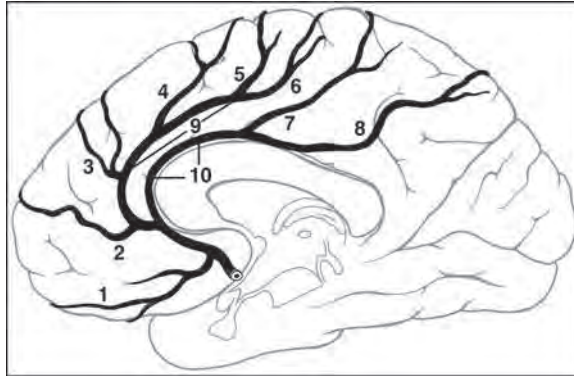


Fig. 1.27 Distal ACA branches. (1) Orbitofrontal artery; (2) Frontopolar artery; (3) Anterior internal frontal artery; (4) Middle internal frontal artery; (5) Posterior internal frontal artery; (6) Paracentral artery; (7) Superior parietal artery; (8) Inferior parietal artery; (9) Callosomarginal artery; (10) Pericallosal artery.

1. Branches

- (a) *Pericallosal artery*. The pericallosal artery comprises the main trunk of the ACA as it passes posteriorly over the corpus callosum. It gives off multiple small branches (“short callosal arteries”)¹⁷² that travel laterally along the corpus callosum (Fig. 1.28) and anastomoses with the splenic artery (the “posterior pericallosal branch”), a branch of the PCA. Infrequently, a “long callosal artery” may be present, which is a branch of and runs parallel to the pericallosal artery.¹⁷²
- (b) *Callosomarginal artery*. The callosomarginal artery is the second largest distal branch of the ACA, after the pericallosal artery. It travels superiorly over the cingulate gyrus to run in a posterior direction within the cingulate sulcus. It is absent in 18% of the hemispheres.¹⁷²

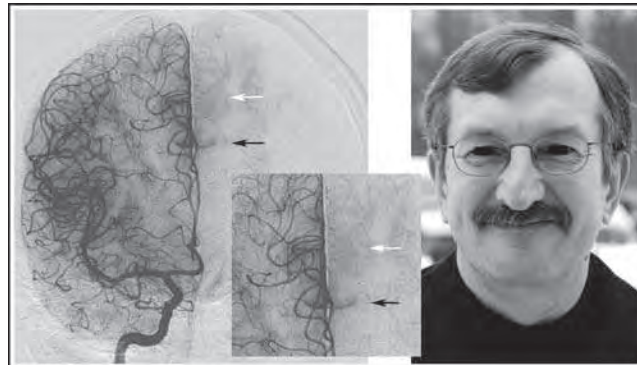


Fig. 1.28 The smile and the mustache. During the late arterial phase of an AP angiogram (high magnification, *inset*), the branches of the pericallosal artery curve upward along the surface of the corpus callosum, forming a smile (*left, black arrows*). Branches of the callosomarginal artery curve downward, forming a mustache (*left, white arrows*). This pattern is nicely demonstrated in a photograph of the senior author of this handbook (*right*). *Black bars* have been placed across his eyes to protect his privacy and to comply with HIPAA regulations.

- (c) *Internal frontal branches.* These branches are identified according to which part of the superior frontal gyrus they supply. They may arise from the pericallosal or the callosomarginal artery.
 - i. Anterior internal frontal arteries
 - ii. Middle internal frontal arteries
 - iii. Posterior internal frontal arteries
 - (d) *Paracentral artery.* This vessel arises from the pericallosal or callosomarginal artery midway between the genu and splenium of the corpus callosum, to supply the paracentral lobule.
 - (e) *Parietal arteries.* These are the final and most distal branches of the ACA. They supply the medial aspect of the hemisphere above the corpus callosum, and most of the precuneus¹⁷⁹ anastomose with the parieto-occipital branch of the PCA. They can be divided into:
 - i. Superior parietal artery
 - ii. Inferior parietal artery
2. Variants
- (a) Branches to the contralateral hemisphere are found in some 64% of the brains.¹⁷²
 - (b) Although the anatomy of the distal ACA branches are highly variable, true developmental anomalies in this region are uncommon.¹

Mnemonic for the Cortical ACA Branches
On Frontal Imaging, Find Peace and Prosperity

Orbitofrontal Artery
Frontopolar Artery
Internal Frontal Branches (Anterior, Middle, and Posterior)
Paracentral Artery
Parietal Arteries (Superior and Inferior)

The two Ps at the end of the mnemonic also serve to remind the reader of the **P**osterior **P**ericallosal artery, which anastomose with the distal end of the ACA.

1.7. Middle cerebral artery

Most classification schemes divide the MCA into four segments. The authors of this handbook favor the following system (Fig. 1.29):

1. M1 From ICA to the bifurcation (or trifurcation)
2. M2 From the MCA bifurcation to the circular sulcus of the insula
3. M3 From the circular sulcus to the superficial aspect of the sylvian fissure
4. M4 Cortical branches

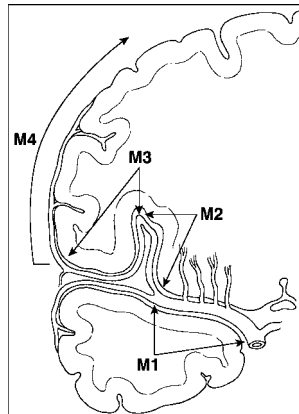


Fig. 1.29 Middle cerebral artery.

1.7.1. M1 segment

The M1 segment (aka horizontal segment or sphenoidal segment¹⁸⁰) arises from the ICA and travels in a lateral direction, parallel to the sphenoid wing, and terminates by dividing into the M2 segments. The M1 origin is usually twice the size of the A1 origin.¹ Although most anatomic studies define the M1 segment as the ending where the MCA branches take a 90° turn within the sylvian fissure^{79, 180} (and thus having both *prebifurcation* and *postbifurcation* subsegments), the division point of the main MCA trunk is considered by most clinicians to be the M1/M2 junction.⁵ The MCA bifurcates in 71% of cases, trifurcates in 20% of cases, and divides into four branches in 9% of cases.¹⁸¹ The M1 segment averages about 16 mm in length.¹⁸¹

1. Branches

- (a) *Lateral lenticulostriate branches.* Approximately 80% of the lenticulostriates that arise from the MCA arise from the M1 segment. These branches average 10 in number,^{181, 182} and most arise from the superior aspect of the M1 segment. They enter the anterior perforated substance to supply the anterior commissure, internal capsule, caudate nucleus, putamen, globus pallidus, and substantia innominata.
- (b) *Anterior temporal artery.* The anterior temporal artery typically arises near the midpoint of the M1 segment. Less commonly, it arises from the inferior division (an M2 segment) or as part of an M1 trifurcation. It travels in an anterior and inferior direction over the temporal tip and does not usually enter the sylvian fissure itself.¹ It supplies the anterior temporal lobe.

2. Variants

- (a) *MCA duplication.* This anomaly consists of a large MCA branch arising from the ICA proximal to the ICA bifurcation, and has a frequency of 0.2–2.9%.¹⁸³ This vessel travels parallel and inferior to the main M1 segment and primarily supplies the anterior temporal lobe.^{183, 184} It is associated with aneurysms.^{185, 186}
- (b) *Accessory MCA.* An accessory MCA arises from the ACA and runs parallel to the M1 segment, and has a frequency of 0.3–4.0%.^{183, 187} There is the Manelfe classification of accessory MCA.¹⁸⁸ Type 1 arises from the carotid (aka MCA duplication), type 2 from the A1 segment, and type 3 from the A2 segment. The accessory MCA primarily supplies the orbitofrontal area¹⁸⁰, and is also associated with aneurysms.^{185, 189} This anomaly should be not be confused with a large recurrent artery of Heubner.¹⁹⁰
- (c) *Aplasia.* Aplasia of the MCA is rare and is associated with aneurysms.¹⁹¹
- (d) *Fenestration.* Fenestration of the M1 segment has been reported.¹⁸⁴

1.7.2. M2 segments

The M2 segments (aka insular segments) extend from the main division point of the M1 segment, over the insula within the sylvian fissure, and terminate at the circular sulcus of the insula. The MCA divisions are equal in diameter and size to cortical area in 18% of the hemispheres; the superior division is larger (dominant) in 28% of the hemispheres and the inferior division is larger in 32% of the hemispheres.¹⁸⁰ The cortical area supplied by the superior division usually extends from the orbitofrontal area to the posterior parietal area. The cortical area supplied by the inferior division usually extends from the temporal pole to the angular area. The M2 segments number from six to eight vessels at the point of transition into the M3 segments.

1.7.3. M3 segments

The M3 segments (aka opercular segments) begin at the circular sulcus of the insula and end at the surface of the sylvian fissure. These vessels travel over the surface of the frontal and temporal opercula to reach the external surface of the sylvian fissure. The M3 branches, together with the M2 vessels, give rise to the *stem arteries*, which in turn give off the cortical branches. There are usually eight stem arteries per hemisphere, and each one typically gives rise to one to five cortical branches.¹⁸⁰

1.7.4. M4 branches

The M4 branches (aka cortical branches) begin at the surface of the sylvian fissure and extend over the surface of the cerebral hemisphere (Figs. 1.30, 1.31). The smallest cortical branches arise from the anterior sylvian fissure and the largest ones emerge from the posterior sylvian fissure.¹⁸⁰ The cortical branches can be grouped according to the region of the cortex that they supply; any given region may have a single artery or several arteries supplying it. The following 12-subdivision system is in common usage.^{1, 180, 192} Although each branch is discussed as a single artery, any given cortical artery may actually exist as several branches (up to five) from a single stem artery.

1. *Orbitofrontal artery*. May arise from the M1 or M2 segment, and may share a common origin with the prefrontal artery. Travels within the anterior horizontal ramus of the sylvian fissure to supply orbital surface of the frontal lobe.
2. *Prefrontal artery*. May share a common origin with the orbitofrontal artery. Supplies the opercular part of the inferior frontal gyrus and most of the middle frontal gyrus.
3. *Precentral artery*. Travels within the precentral sulcus. Supplies part of the inferior frontal gyrus and the inferior part of the precentral gyrus.
4. *Central artery*. (aka Rolandic artery) Travels within the central sulcus. May share a common origin with the anterior parietal artery. Largest MCA branch to the frontal lobe.¹⁸⁰ Supplies the superior part of the precentral gyrus and the inferior half of the postcentral gyrus.
5. *Anterior parietal artery*. May arise with the central artery or the posterior parietal artery. Travels in the postcentral sulcus. Supplies the superior part of

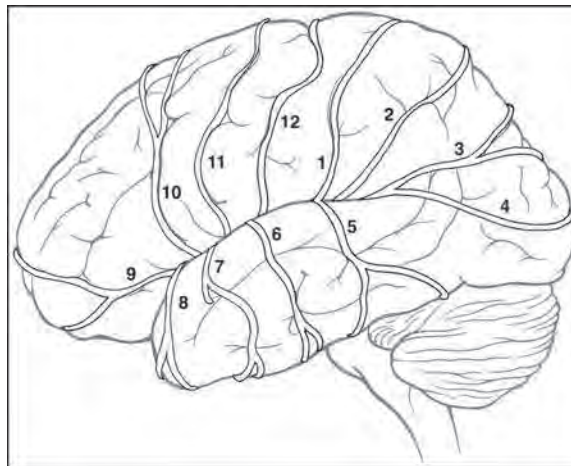


Fig. 1.30 MCA cortical branches.

The most common branching pattern of the MCA is shown:

1. Anterior parietal artery
2. Posterior parietal artery
3. Angular artery
4. Temporo-occipital artery
5. Posterior temporal artery
6. Middle temporal artery
7. Anterior temporal artery
8. Temporopolar artery
9. Orbitofrontal artery
10. Prefrontal artery
11. Precentral artery
12. Central artery

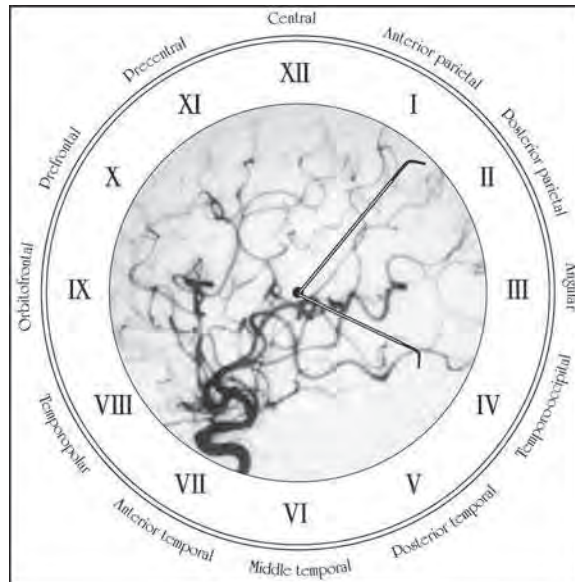


Fig. 1.31 Mnemonic for the cortical MCA branches.

Because of the astonishing coincidence that there are 12 cortical branches and 12h on the clock, the cortical branches can be remembered by assigning each one to an hour of the day. The *central* artery occupies the *central* position on the clock, that of high noon. The position of the angular artery at 3 o'clock, reflects the importance of that vital artery, because, as we all know, 3 o'clock was the time that school let out when we were kids. The *middle* temporal artery is at 6 o'clock, which is in the *middle* position at the bottom of the clock. The orbitofrontal artery is at the extreme left position, at 9 o'clock, which is appropriate because the orbitofrontal artery is the most extreme anterior branch of the MCA.

- the postcentral gyrus, the upper part of the central sulcus, the anterior part of the inferior parietal lobule, and the anteroinferior part of the superior parietal lobule.
6. *Posterior parietal artery.* The most posterior ascending branch of the MCA. May share a common trunk with the anterior parietal artery or the angular artery. Supplies the posterior part of the superior and inferior parietal lobules, including the supramarginal gyrus.
 7. *Angular artery.* The terminal and largest branch of the MCA. It emerges from the posterior end of the sylvian fissure to travel over the superior temporal gyrus and terminate over the superior half of the occipital lobe. Supplies the posterior part of the superior temporal gyrus, and parts of the supramarginal and angular gyri, and superior parts of the lateral occipital lobe.
 8. *Temporo-occipital artery.* May share an origin with the angular artery. Supplies the posterior half of the superior temporal gyrus, the posterior extent of the middle and inferior gyri, and the inferior parts of the lateral occipital lobe.
 9. *Posterior temporal artery.* Leaves the posterior sylvian fissure and crosses over the superior and middle temporal gyri. Supplies the middle and posterior parts of the superior temporal gyrus, the posterior third of the middle temporal gyrus, and the posterior extent of the inferior temporal gyrus.
 10. *Middle temporal artery.* Emerges from the middle of the sylvian fissure. Supplies the middle parts of the temporal gyri.

11. *Anterior temporal artery* Passes inferiorly and posteriorly over the temporal lobe, and terminates in the middle temporal sulcus. Supplies the anterior parts of the superior, middle, and inferior temporal gyri.
 12. *Temporopolar artery*. Supplies the anterior pole of the temporal lobe. The cortical branches can be grouped according to which lobe they supply:¹⁹²
 1. *Frontal lobe*. Orbitofrontal, prefrontal, precentral, and central arteries
 2. *Parietal lobe*. Anterior and posterior parietal arteries and angular artery
 3. *Temporal lobe*. Temporopolar, anterior, middle and posterior temporal arteries, and temporooccipital artery
 4. *Occipital lobe*. Temporo-occipital artery
- The cortical branches can also be grouped according to which M2 segment they arise from:¹⁸⁰
1. *Superior division*. Orbitofrontal, prefrontal, precentral, and central arteries.
 2. *Inferior division*. Temporopolar, temporo-occipital, angular, and anterior, middle, and posterior temporal arteries.
 3. *Dominant division* (these branches may arise from either division, and usually come off of the larger of the MCA divisions). Anterior and posterior parietal arteries.

1.8. Posterior cerebral artery

Most classification schemes for the PCA include three or four segments. The following system is the most common (Fig. 1.32):

1. P1 From the basilar artery bifurcation to the junction with the P-comm artery.
2. P2 From the P-comm artery to the posterior aspect of the midbrain.
3. P3 From the posterior aspect of the midbrain to the calcarine fissure.
4. P4 The terminal branches of the PCA distal to the anterior limit of the calcarine fissure.

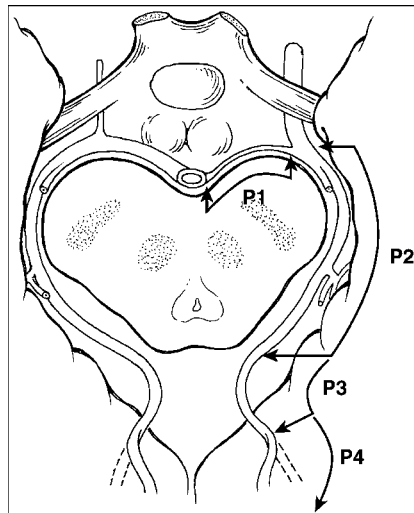


Fig. 1.32 Posterior cerebral artery. The most common PCA configuration is on the *left*, and the persistent fetal origin of the PCA is on the *right*.

1.8.1. PCA branches

The PCA branches can be divided into three categories:

1. Perforating branches, to the brainstem and thalamus.
2. Ventricular branches.
3. Cortical branches.

Perforating branches arise from the P1 and P2 segments. Ventricular branches originate mostly from the P2 segment. Cortical branches arise from the P2, P3, and P4 segments. Perforating arteries are divided into direct branches, which pass directly into the brain, and circumflex vessels, which travel around the brainstem for various distances before entering the brain (Fig. 1.33).

1.8.2. P1 segment

The P1 segment (aka precommunicating, mesencephalic or horizontal segment) lies immediately superior to the oculomotor and trochlear nerves. The average length is 6.6 mm; when a fetal PCA is present, the vessel averages 8.6 mm in length.¹⁹³

1. Branches.

- (a) Perforators

- i. Direct perforating branches (aka posterior thalamoperforating arteries) from the P1 segment pass directly into the brainstem. These are termed the posterior thalamoperforators to distinguish them from the anterior thalamoperforators, which arise from the P-comm artery. These vessels average 2.7 in number,¹⁹³ and arise from the posterior and superior aspects of the P1 segment,

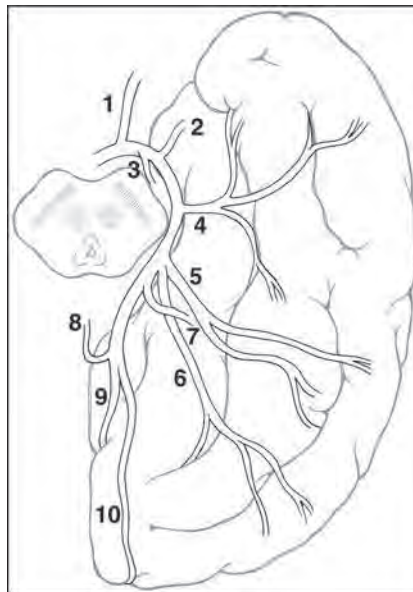


Fig. 1.33 Major branches of the posterior cerebral artery. (1) Posterior communicating artery; (2) Hippocampal artery; (3) Posteromedial choroidal artery; (4) Anterior temporal artery; (5) Middle temporal artery; (6) Posterior temporal artery; (7) Posterolateral choroidal artery; (8) Splenic artery; (9) Parieto-occipital artery; (10) Calcarine artery.

although, rarely, they may arise from the anterior aspect of the vessel.¹³¹ The direct perforators enter the brain medial cerebral peduncles and posterior perforated substance to supply parts of the thalamus, brainstem, and posterior internal capsule.

- ii. Circumflex arteries. The circumflex arteries (aka peduncular, mesencephalic, or tegmental thalamoperforating arteries) arise from the P1 and P2 segments and encircle the midbrain parallel and medial to the PCA. They are subdivided into short and long circumflex arteries. The short and long circumflex arteries number 0.8 and 1.3 per hemisphere, respectively.¹⁹³
 1. *Short circumflex arteries.* One or more short circumflex arteries travel a short distance around the brainstem before entering the brain, and reach only as far as the geniculate bodies. Most short circumflex arteries arising from P1 terminate at the posterolateral border of the peduncle.¹⁹³
 2. *Long circumflex arteries.* Up to three long circumflex arteries (aka quadrigeminal arteries) pass around the brainstem, to supply the geniculate bodies and superior colliculi. It arises from the PCA distal to the origin of the short circumflex arteries; in 80% of cases they arise from P1 and in the remaining cases they arise from P2.¹⁹³ The long circumflex artery anastomoses with the branches of the superior cerebellar arteries.
- (b) Posteromedial choroidal artery. This vessel usually arises from the P2 segment (see below), but arises from the P1 segment in 12% of cases.¹⁹³
- (c) Meningeal branch (aka artery of Davidoff and Schecter). A small branch from the P1 segment to supply a midline strip of the inferior surface of the tentorium may be enlarged by pathological processes.¹⁹⁴

2. Variants

- (a) Side-to-side asymmetry of the P1 segments common, being present in 52% of angiograms.¹⁹⁵ When a fetal P-comm artery is present, the ipsilateral P1 is typically hypoplastic, and may not fill noticeably on angiography, making it appear to be absent or occluded.
- (b) In some persistent carotid–vertebrobasilar anastomoses, the PCA may be supplied by branches from the carotid system (see above).
- (c) True anomalies of the P1 segment are uncommon, accounting for 3% of cases in an autopsy series.¹⁹⁶ These included a duplication, fenestration, and a bilateral shared origin of the PCA and SCA.
- (d) Congenital absence of the P1 is rare.¹³¹
- (e) There may be a prominent perforating branch that supplies portions of both the ipsilateral and contralateral thalamus and potentially mid-brain, as well.¹⁹⁷ This perforator has been called the artery of Percheron.^{198, 199}

1.8.3. P2 segment

The P2 segment (aka ambient segment) is relatively long, averaging 50 mm in length.¹⁹³ It is subdivided by some authors into an anterior half and a posterior half for discussion of surgical approaches.¹⁹³ The P2 segment begins at the P-comm artery junction and travels around the lateral aspect of the midbrain within the ambient cistern, parallel and inferior to the basal vein of Rosenthal. Other adjacent structures are the trochlear nerve, the free edge of the tentorium, and the superior cerebellar artery.

1. Branches

(a) Perforators

i. Direct perforators

1. Thalamogeniculate arteries arise from the midportion of the P2 segment, and arise in a superior and lateral direction to perforate the inferior surface of the geniculate bodies. They number 1–3 per hemisphere,^{193, 200} and supply the posterior half of the lateral thalamus, the posterior limb of the internal capsule, and the optic tract.
2. Peduncular perforating arteries pass directly into the cerebral peduncle and supply multiple structures within the

- brainstem as well as parts of the oculomotor nerve. They average 2.8 per hemisphere.¹⁹³
- ii. Circumflex arteries. The circumflex arteries usually arise from the P1 segment. In 20% of cases, however, the long circumflex artery arises from the P2 segment.¹⁹³
- (b) Posteromedial choroidal artery (Fig. 1.34). This vessel (aka medial posterior choroidal artery) is single in 54% of the hemispheres and may be duplicated or triplicated.¹⁹³ The vessel arises from the P2 segment in most cases. Other sites of origin of the posteromedial choroidal artery are the P1 segment (12%), P3 segment (4%), parieto-occipital artery (10%), and calcarine artery (3%),¹⁹³ or, rarely, the basilar artery.²⁰¹ The posteromedial choroidal artery has two segments:
- i. *Cisternal segment*. This segment averages 42mm in length.²⁰² From its origin, the vessel curves around the brainstem medial to the main trunk of the PCA and gives off small tegmental branches before it turns forward adjacent to the pineal gland to enter the roof of the third ventricle. The tegmental branches irrigate portions of the midbrain, tectal plate, pineal gland, thalamus, and medial geniculate body.
 - ii. *Plexal segment*. This segment travels anteriorly within the velum interpositum between the thalami, adjacent to the internal cerebral vein and the contralateral medial posterior choroidal artery. It travels through the foramen of Monro to enter the choroid plexus of the lateral ventricle, and anastomose with the terminal branches of the lateral posterior choroidal artery. Branches from the plexal segment irrigate the choroid plexus of the third ventricle, as well as the thalamus and the stria medullaris.²⁰²

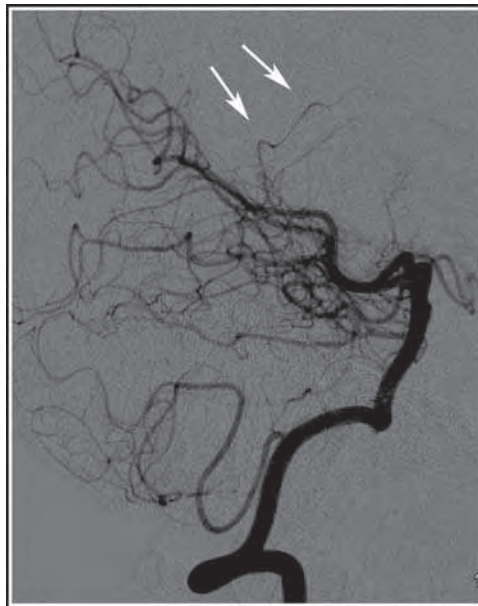

Fig. 1.34 Posteromedial choroidal artery. The undulating course of the posteromedial choroidal artery as it passes over the quadrigeminal plate, gives it a characteristic undulating “3” pattern (arrows).

(c) Posterolateral choroidal arteries. Unlike the posteromedial choroidal artery, the posterolateral choroidal arteries are multiple in the majority (84%) of cases²⁰² and number up to nine (average: 4).¹⁹³ They arise from the P2 segment in 51% of cases; other sites of origin include the parieto-occipital (13%), anterior temporal (10%), hippocampal (8%), posterior temporal (9%), posteromedial choroidal (4%), calcarine (2%), or middle temporal artery (2%).¹⁹³ Size of these vessels are inversely proportional to the size of the anterior choroidal artery.²⁰³ The posterolateral choroidal arteries travel laterally to enter the choroidal fissure, and have two segments:

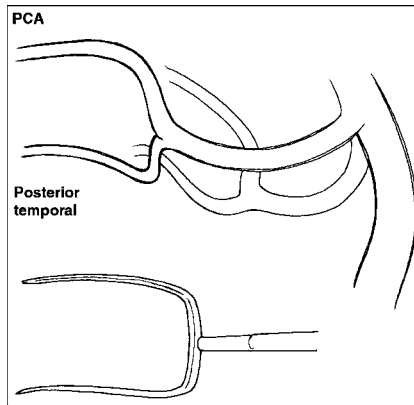


Fig. 1.35 The PCA pitchfork.

A distinctive identifying landmark of the PCA on a lateral view is the “pitchfork” appearance of the take-off of the posterior temporal artery from the main trunk of the PCA. Visualization of this feature can help distinguish the PCA from other arteries on a cluttered angiogram.

- i. *Cisternal segment.* The cisternal segment averages 23 mm in length and sends branches to the thalamus, geniculate bodies, fornix, cerebral peduncle, pineal body, corpus callosum, tegmentum, and temporal occipital cortex.²⁰²
 - ii. *Plexal segment.* This segment begins with the passage of the lateral posterior choroidal arteries through the choroidal fissure lateral to the ambient cistern at the level of the temporal horn or atrium. They travel along the medial border of the choroid plexus in the lateral ventricle, eventually intermingling with branches of the medial posterior choroidal artery in the body of the ventricle and at the foramen of Monro.²⁰² Branches from plexal segment vessels irrigate the choroid plexus and penetrate the ventricular surfaces of the thalamus and fornix.
- (d) Hippocampal artery. A hippocampal artery arises from the P2 segment in 64% of cases; when present, it is the first cortical branch of the PCA.¹⁹³ This artery supplies the uncus, hippocampal gyrus, hippocampal formation, and dentate gyrus. Some authors include the hippocampal artery with the inferior temporal arteries.¹⁹³
- (e) Inferior temporal arteries. The inferior temporal arteries are distinguished from the temporal arteries, which are branches of the MCA. The inferior temporal arteries are variable and may appear as a single initial branch of the P2 segment, called a common temporal artery (aka lateral division of the PCA or lateral occipital artery), which is seen in 16% of cases.¹⁹³
- i. *Anterior inferior temporal artery.* The anterior temporal artery is usually the second cortical branch of the PCA. It may be duplicated. It travels anteriorly and laterally inferior to the hippocampal gyrus, and anastomoses with anterior temporal branches of the MCA.¹⁹⁵
 - ii. *Middle inferior temporal artery.* A middle temporal artery is present in 38% of the hemispheres, and supplies the inferior surface of the temporal lobe.¹⁹³
 - iii. *Posterior inferior temporal artery (Fig. 1.35).* The posterior temporal artery is a prominent branch of the PCA and usually arises from the inferior and lateral aspect of the P2 segment and travels obliquely toward the occipital pole. It supplies the inferior temporal

and occipital surfaces. This vessel arises from the P3 segment in 6% of cases.

- (f) Parieto-occipital artery. The parieto-occipital artery arises as a single trunk from the P2 segment slightly more commonly than from the P3 segment.¹⁹³ It travels posteriorly and laterally within the parieto-occipital fissure, which separates the parietal lobe from the occipital lobe, to supply the posterior parasagittal region, cuneus, precuneus, and lateral occipital gyrus. In 24% of cases it sends branches through the choroidal fissure into the lateral ventricle.
 - (g) Calcarine artery. The calcarine artery arises from the P2 segment slightly less commonly than from the P3 segment (see below).
 - (h) Splenial artery. The splenial artery originates from the P2 segment in 4% of cases (see below).¹⁹³
 - (i) Artery of Davidoff and Schechter. (aka dural branch) Generally only seen in pathological conditions, this artery supplies the apex of the tentorium, walls of the vein of Galen, and then curves forward along the free edge of the falx cerebri.²⁰⁴ It can also provide some collateral supply to the superior vermis and inferior colliculi.²⁰⁵ The artery of Davidoff and Schechter is often difficult to see angiographically, even when enlarged, due to superimposition with other PCA branches. It is more commonly seen on the left.²⁰⁶
2. Variants.
- (a) Anomalous origin of cortical branches. In rare cases, the parieto-occipital, posterior temporal, or calcarine artery may arise directly from the ICA.^{1,207} Similarly, anomalous anterior choroidal artery supply to temporal, parietal and occipital cortical regions normally supplied by branches of the PCA has been reported.²⁰⁸

1.8.4. P3 segment

The P3 segment (aka quadrigeminal segment) extends in a medial and posterior direction from the quadrigeminal plate to the anterior limit of the calcarine fissure, and averages 20 mm in length. The P3 segments from each side approach each other. The point where the two PCAs are nearest to each other is referred to as the collicular, or quadrigeminal point; this separation averages 8.9mm.¹⁹³ The PCA often divides into its two terminal branches (the calcarine and parieto-occipital arteries) between the quadrigeminal plate and the calcarine fissure.

1. Branches

- (a) Parieto-occipital artery. The parieto-occipital artery arises from the P3 segment in 46% of the hemispheres (see above).
- (b) Posterolateral choroidal artery. This vessel arises from the P3 segment in 11% of cases (see above).²⁰²

1.8.5. P4 segment

The P4 segment begins at the anterior limit of the calcarine fissure, and includes one of the two main terminal branches of the PCA, the calcarine artery. The other main terminal branch of the PCA, the parieto-occipital artery, frequently arises from the P2 or P3 segment.

1. Branches

- (a) Calcarine artery. The calcarine artery travels posteriorly and medially within the calcarine fissure to reach the occipital pole. It is duplicated in 10% of cases, and arises from the parieto-occipital artery in 10% of cases.¹⁹³ The calcarine artery sends branches to the lingual gyrus and inferior cuneus, and primarily supplies visual cortex.
- (b) Splenial artery. The splenial artery (aka posterior pericallosal artery) arises from the parieto-occipital artery in 62% of cases, but may arise from the calcarine (12%), posteromedial choroidal (8%), posterior temporal (6%), P2 or P3 segments (4% each) or the posterolateral choroidal artery (4%).¹⁹³ The splenial artery is relatively constant and travels superiorly around the splenium of the corpus callosum to anastomose with the pericallosal artery.

1.9. Vertebral artery

Most classification schemes divide the vertebral artery into four segments (Fig. 1.36).

1. V1 From the subclavian artery to the foramen transversarium of C6.
2. V2 From C6 to the foramen transversarium of C1.
3. V3 From the C1 to the dura.
4. V4 Intradural part of the vertebral artery.

1.9.1. V1 segment

The V1 segment (aka extraosseous segment) arises from the posterosuperior wall of the subclavian artery (Fig. 1.37), travels in a superior and posterior direction. It passes posterior to the anterior scalene muscles and enters the transverse foramen of the C6 (90% of most cases), C5 (7%) or C7 (3%). Supplies the stellate ganglion.²⁰⁹

1. Variants.

- (a) *Anomalous origin.* The left vertebral artery arises directly from the aortic arch in about 0.5% of cases.¹ Anomalous origins of the right vertebral artery from the arch,²¹⁰ of both vertebral arteries from the arch,²¹¹ and of the right vertebral artery from the right common carotid artery²¹² have been reported.
- (b) *Duplication and fenestration.* Duplication²¹³ or fenestration of the vertebral artery are found in <1% of dissections.¹¹³

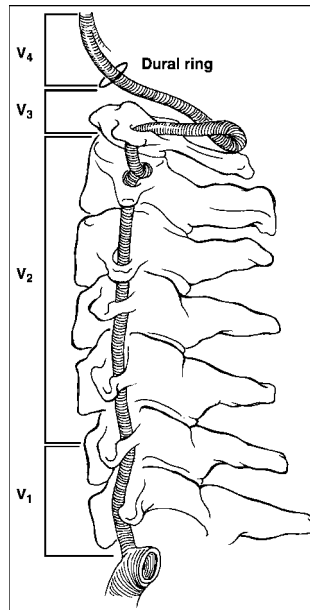


Fig. 1.36 Vertebral artery.

1.9.2. V2 segment

The V2 segment (aka foramenal segment) travels in a vertical direction within the foramen transversaria, usually from C6 to C2. It is surrounded by sympathetic fibers (although this is now debatable²¹⁴) from the stellate ganglion and by a venous plexus that covers the entire V2 segment and drains through the vertebral vein into the subclavian or internal jugular veins.²¹⁵ The vertebral vein (or veins) is usually large and directly anterior to the vertebral artery.²¹⁶

1. Branches

- (a) *Spinal branches.* These branches (aka radiculomedullary branches) arise from the vertebral artery from C1 to C5 and may vary in the number and side of origin.^{215, 216} They supply the spinal cord as well as the periosteum and bone of the vertebrae.
- (b) *Muscular branches.* Multiple small muscular branches arise from the V2 segment to supply the cervical muscles.
- (c) *Artery of the cervical enlargement.* The artery of the cervical enlargement usually arises from both vertebral arteries in the region of C4 to C6 and anastomoses with the anterior spinal artery to supply the ventral aspect of the spinal cord. This vessel may also arise from the thyrocervical trunk.⁵
- (d) *Anterior meningeal artery.* Originates from the distal V2 segment and supplies the dura around the foramen magnum and extends up the clivus.

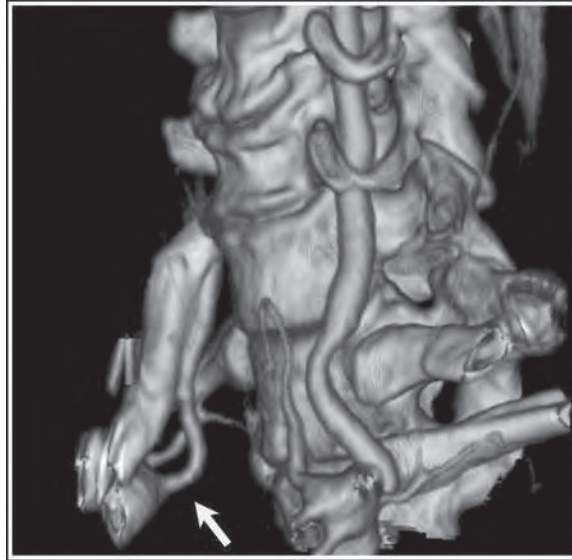


Fig. 1.37 Vertebral artery origin. Anterolateral view of a cervical spine CT angiogram showing the right vertebral artery (*arrow*) arising from the posterior wall of the subclavian artery. The optimal angiographic projection is usually an AP view with 20–30° of Townes.

Forms collaterals with the ascending pharyngeal via the odontoid arcade and the dural branches of the ascending pharyngeal, and with the internal carotid via the meningohypophyseal trunk branches.

- (e) *Posterior meningeal artery*. Arises near the foramen magnum and supplies the medial occipital dura and the falx cerebelli.
- (f) *PICA*. Rarely, the PICA may originate at the C1 level.²¹⁷

1.9.3. V3 segment

The V3 segment (aka extraspinal segment) begins as the vertebral artery, and exits the transverse foramen of C1 on the medial side of the lateral rectus muscle of the head. It then travels in a horizontal and medial direction superior to the posterior arch of C1 and runs inferior to the posterior atlanto-occipital membrane before turning superiorly and anteriorly to penetrate the dura.

1. Branches

- (a) *PICA*. In some 5–20% of cases, the PICA has an extradural origin, usually from the V3 segment.²¹⁷ In these cases the PICA may originate at any point along the V3 segment.

1.9.4. V4 segment

The V4 segment is the intradural part of the vertebral artery and extends from its entrance through the dura to the junction with the opposite vertebral artery. The dura is thickened and it forms a fibrous dural ring around the vertebral artery.²¹⁸ The length of the V4 segment averages 22mm.²¹⁹ The left and right V4 segments usually come together at the level of the pontomedullary junction. The branches of the intradural vertebral artery can be separated into medial branches (including the anterior spinal artery

and branches of the foramen caecum) and lateral branches, the most prominent of which is the PICA.²¹⁹ A wide anastomotic net usually interconnects the branches of V4.²¹⁹

1. Branches

(a) *Posterior inferior cerebellar artery (PICA)*. The PICA is the largest and most complex of the cerebellar arteries (Fig. 1.38). It originates approximately 16–17 mm proximal to the vertebrobasilar junction, an average of 8.6 mm superior to the foramen magnum.²²⁰ The territory supplied by the PICA includes lower medulla and inferior aspects of the fourth ventricle, cerebellar tonsils, vermis, and inferolateral cerebellar hemisphere. The PICA arises from the vertebral artery and travels posterolaterally around the medulla. Over the dorsal aspect of the brainstem, the vessel travels inferiorly for a variable distance – sometimes as far south as C2 – then forms a loop (the *caudal loop*) and turns 180° to travel superiorly adjacent to the cerebellar tonsil. The vessel then reaches its superior extent and forms another loop (the *cranial loop*) and then travels inferiorly and laterally to emerge over the cerebellar hemisphere (Fig. 1.39). The PICA can be divided into five segments, detailed below. The first four segments can be remembered by using the acronym, *ALPS*.

- i. Anterior medullary segment. Extends from the origin to the inferior olivary prominence. In some 40% of cases, there is no anterior medullary segment, because the PICA arises lateral, rather than anterior to the medulla.²²⁰ This segment averages one perforator.²²⁰
- ii. Lateral medullary segment. Extends from the inferior olivary prominence to the origins of the ninth, 10th, and 11th cranial nerves, and averages 1.8 perforators.²²⁰

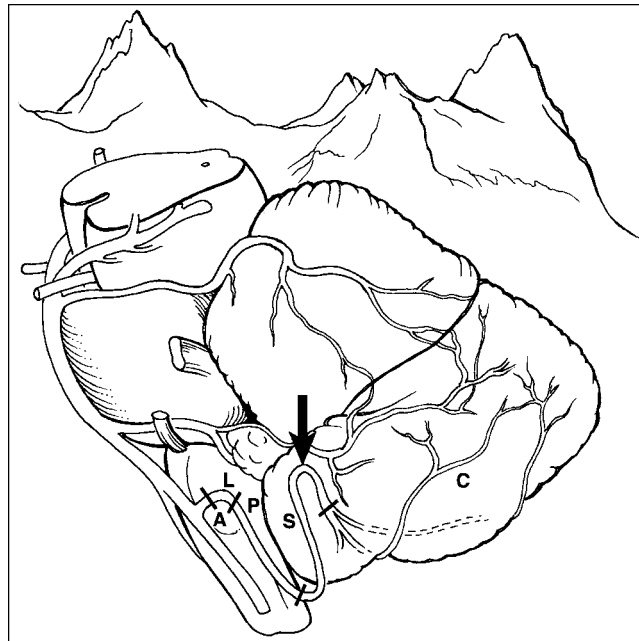


Fig. 1.38 Posterior inferior cerebellar artery. Lateral view of the brainstem and cerebellum. The segments of the PICA include the anterior medullary (A), lateral medullary (L), posterior medullary (P), supratonsillar (S), and cortical (C) segments. Arrow indicates the choroidal point. The artist was inspired to depict the Swiss Alps in the background.

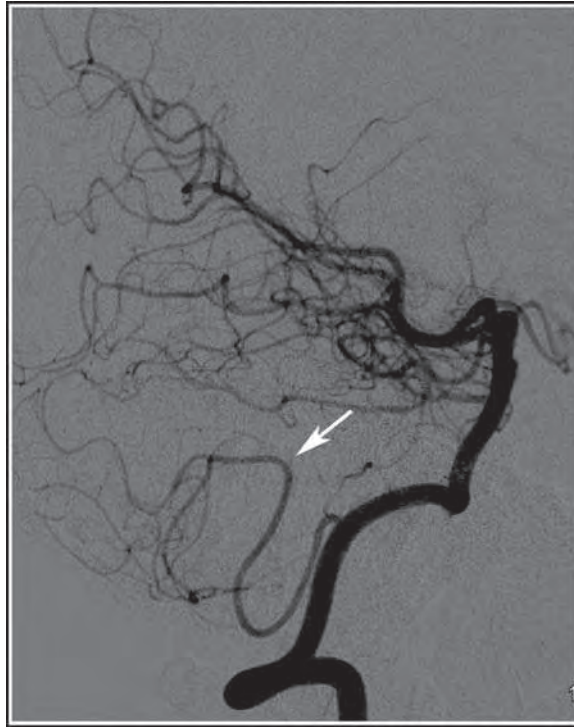


Fig. 1.39 The choroidal point. The single most important anatomical fact about the PCA for neurointerventionalists has to do with the cranial loop (*arrow*), aka the *choroidal point*. The choroidal point is the superior-most point of the PCA. The PCA gives off branches to the brainstem proximal to the choroidal point but not distal to it. Occlusion of the PCA at or distal to the choroidal point does not usually result in a functionally significant ischemic injury, because of anastomotic connections with AICA and SCA.^{226, 227}

- iii. Posterior medullary segment. This segment, aka tonsillomedullary segment, begins where the PCA passes posterior to the lower cranial nerves and ends where the ascending vessel reaches the midlevel of the medial surface of the tonsil. It passes immediately posterior to the roof of the lower half of the fourth ventricle, and averages 3.3 perforators.²²⁰
- iv. Supratonsillar segment. This segment, aka telovelotonsillar segment, begins midway up the tonsil, includes the cranial loop, and ends where the PCA exits the fissures between the vermis, tonsil, and cerebellar hemisphere to reach the cortical surface. On a lateral angiogram, the supratonsillar segment outlines the tonsil along its anterior, superior, and posterior aspects.⁵
- v. Cortical segments. These segments are also known as hemispheric branches. The PCA often bifurcates into medial and lateral trunks where the vessel emerges onto the inferior cortical surface. The medial trunk gives rise to the vermian and tonsillar branches, and the lateral trunk produces the hemispheric branches.
- vi. PCA branches.

1. Perforators
 - (a) Direct perforators. These branches travel directly into the brainstem, and are found in all three medullary segments.
 - (b) Circumflex perforators. These perforators travel around the brainstem for some distance before entering it. These vessels arise mostly from the lateral and posterior medullary segments.
 2. Choroidal arteries. Branches to the choroid plexus of the fourth ventricle arise from the posterior and supratonsillar segments.
 3. Cortical arteries
 - (a) Vermian branches
 - (b) Tonsillar branches
 - (c) Hemispheric branches
 4. Meningeal branches. The posterior meningeal artery and the artery of the falx cerebelli may arise from the PICA.
- vii. PICA variants
1. Anomalous origin. Extradural origin of the PICA is found in 5–20% of cases (see above). Origination of the PICA from the ICA,²²¹ the posterior meningeal artery,²²² a hypoglossal artery,²²³ and a proatlantal artery²²³ have been reported.
 2. Duplication. The PICA is duplicated in some 2.5–6% of cases.²²⁰
 3. Hypoplasia. The PICA is hypoplastic in 5–16% of the hemispheres.^{223, 224}
 4. Absence. The PICA is absent on one side in 15–26% of cases and on both sides in 2% of cases.^{223, 224}
 5. A shared AICA-PICA trunk is a normal variant.¹
 6. In 0.2% of cases, the vertebral artery terminates in PICA.¹
- (b) *Perforators*. An average of 4.2 perforators arise directly from each vertebral artery and supply lateral medulla, inferior cerebellar peduncle, and the medullary surface of the cerebellum.²¹⁹
 - (c) *Anterior spinal artery*. The anterior spinal artery arises from the vertebral artery 6.5 mm proximal to the vertebrobasilar junction²¹⁹ and travels in an inferior direction to supply the anterior surface of the medulla and spinal cord. In about 50% of cases a small communicating artery (the anterior spinal communicating artery) connects the left and right anterior spinal arteries on the anterior surface of the medulla.²¹⁹
 - (d) *Branches of the foramen caecum*. In about one third of cases, branches of the vertebral artery travel superiorly to supply the foramen caecum at the base of the pons.²¹⁹
 - (e) *Lateral spinal artery*. The lateral spinal artery may arise from the V4 segment or from the PICA,²²⁵ and may be difficult to see on angiography.⁵ It originates lateral to the medulla and travels in a caudal direction, anterior to the posterior spinal nerve roots and posterior to the dentate ligament. It supplies the 11th cranial nerve and the lateral and posterior surfaces of the cord via branches to the C1–C4 spinal nerves.
 - (f) *Meningeal branches*. The posterior meningeal artery and the artery of the falx cerebelli may arise from the PICA.

1.10. Basilar artery

The basilar artery originates at the pontomedullary junction, travels anterior to the pons, and terminates near pontomesencephalic junction. The normal vessel averages 32 mm in length¹³¹ and travels in the midline, or at least medial to the lateral margins of the clivus, in 98% of cases.²²⁸ The course of the vessel is straight in 45% of cases, curved in 35%, and tortuous in 20%.²²⁹ The outer diameter is typically constant, averaging 4.1 mm in adults,²³⁰ except for a widening at the basilar bifurcation, giving it a “cobra-like appearance,” in 16% of cases.¹³¹

1. Branches
 - (a) *Anterior inferior cerebellar artery (AICA)*. The AICA arises from the basilar artery at an average of 9.6 mm distal to the vertebrobasilar junction.²²⁹ It travels in a posterior, inferior and lateral direction across the

pons toward the cerebellopontine angle. It terminates by passing over and sending branches to the anterolateral surface of the cerebellar hemisphere.²³¹ Usually the smallest of the three cerebellar arteries, the AICA has a reciprocal relationships and extensive anastomoses with the SCA and the PICA. It also has anastomoses with the SCA. The sixth cranial nerve crosses the AICA 6–7 mm distal to the origin of the artery,²³⁰ and the vessel lies adjacent to the seventh and eighth cranial nerves in the cerebellopontine angle.²³² The AICA has three segments:

- i. Premeatal segment. Extends from the origin of the vessel to the seventh and eighth cranial nerves.
 - ii. Meatal segment. The part of the AICA that is related to the internal auditory canal.
 - iii. Postmeatal segments. The AICA typically divides into rostral and caudal trunks in the cerebellopontine angle.^{233, 234} After crossing the seventh and eighth cranial nerves, the rostral trunk travels laterally over the flocculus to reach the middle cerebellar peduncle and the superior part of the anterolateral (petrosal) surface of the cerebellar hemisphere. The caudal trunk supplies the inferior part of the anterolateral surface.
 - iv. AICA branches.
 1. Perforators. The brainstem receives small perforating branches from the premeatal segment and recurrent perforating branches from the meatal segment.
 2. Internal auditory artery (aka labyrinthine artery). This vessel arises from the AICA in 45% of cases.¹ The vessel may arise from the premeatal or meatal segment, or from the lateral branch of the postmeatal segment. The internal auditory artery travels with the seventh and eighth cranial nerves into the internal auditory meatus and is distributed to the inner ear.²³⁵
 3. Subarcuate artery. The subarcuate artery arises from the AICA medial to the internal auditory meatus and penetrates the dura covering the subarcuate fossa on the posterior surface of the temporal bone and supplies the bone in the region of the semicircular canals.²³⁶
 4. Cerebellar cortical branches.
 - v. AICA variants.
 1. Duplication. The origin of the vessel is single in 72% of cases, a duplicate in 26%, and triplicate in 2%.²³⁶
 2. Anomalous origin. Origination of the AICA from the ICA has been reported several times.²³⁷
- (b) *Basilar perforators*. An average of 17 perforators arises from the basilar artery from its origin to the SCAs.²²⁹ In addition, on average, another 2.5 average small horizontal brainstem perforators arise from the posterior surface of the basilar artery distal to the origin of the SCAs.²³⁸ Significantly, no perforators arise directly from the tip of the basilar artery.^{238, 239} Basilar perforators supply the posterior perforated substance and brainstem structures such as the corticospinal and corticobulbar tracts, pontine nuclei, and the lemnisci, fasciculi, and motor nuclei of the midbrain and pons.
- i. Medial perforators. Medial perforators average 5.8 mm in length and enter the pons in the basilar sulcus or within a few mm of it.²²⁹
 - ii. Circumflex perforators. Circumflex perforators average 16 mm in length and travel around the brainstem for various distances before entering.
- (c) *Superior cerebellar artery (SCA)*. The SCA is the most constant cerebellar artery and arises from the basilar artery immediately prior to the basilar bifurcation. The SCA travels posterolaterally around the brainstem, inferior to the third and fourth cranial nerves and superior to the fifth cranial nerve. The SCA comes into contact with the fifth cranial nerve in 50% of cases,²⁴⁰ and is usually the target of surgical microvascular decompression for trigeminal neuralgia (the AICA and adjacent veins may also come into contact with the fifth nerve). At an average distance of 18.5 mm from the origin, the SCA bifurcates into a rostral and a caudal trunk.²⁴¹ The rostral trunk continues around the brainstem, gives off direct and circumflex perforators, sends branches to the inferior colliculi, and supplies the superior surface of the vermis

and the paramedian aspect of the cerebellar hemisphere. The caudal trunk supplies the superior lateral surface of the cerebellar hemisphere, the superior cerebellar peduncle and dentate nucleus, and part of the brachium pontis. The SCA can be divided into four segments:²⁴¹

- i. Anterior pontomesencephalic segment. This segment (aka anterior pontine segment) extends from the SCA origin to the anterolateral margin of the brainstem.
- ii. Lateral pontomesencephalic segment. This segment (aka ambient segment) extends from the anterolateral margin of the brainstem to the anterior margin of the cerebellomesencephalic groove. This segment is parallel to the PCA and basal vein of Rosenthal. The fourth cranial nerve crosses the midportion of this segment.
- iii. Cerebellomesencephalic segment. This segment (aka quadrigeminal segment) travels within a groove between the cerebellum and the midbrain and the superior cerebellar peduncles.
- iv. Cortical segments. The cortical segments include branches to the vermis and superior cerebellar hemisphere cortical surface.
- v. SCA branches
 1. Perforators. An average of two perforators arises from the main SCA trunk, five from the rostral trunk, and two from the caudal trunk.²⁴¹ Direct perforators from the SCA are less common than circumflex perforators.
 2. Precerebellar arteries. The precerebellar arteries arise from the hemispheric branches (average: four) and the vermian branches (average: two), and supply the deep cerebellar nuclei, the inferior colliculi, and the superior medullary velum.²⁴¹
 3. Cortical arteries.
 - (a) Hemispheric branches
 - (b) Vermian branches
 - (c) Marginal artery.
 4. Internal auditory artery. This vessel is most often a branch of the AICA (see above) but arises from the SCA in 25% of cases.¹

- vi. SCA variants
 1. Duplication. The SCA is duplicated in 14% of hemispheres;²⁴¹ in these cases, the duplicate vessels correspond to the rostral and caudal trunks.
 2. Absence. Although rare, absence of the SCA has been reported.²⁴²

(d) *Internal auditory artery.* This vessel is most often a branch of the AICA (see above) but arises directly from the basilar artery in 16% of cases.¹

2. Variants
 - (a) Fenestration of the basilar artery is found in 1.33% of dissection and 0.12% of angiograms.^{1, 243}
 - i. Fenestration or segmental duplication is a rare congenital anomaly. In a review of 5,190 cerebral angiograms, arterial fenestration was observed in 37 (0.7%).²⁵⁰ Considering all fenestrations, the prevalence of an associated aneurysm is 7%.²⁵⁰ Table 1.7 is an inventory of reported intracranial fenestrations.

Table 1.7 Intracranial arterial fenestrations

Vessel	References
ICA	244
A1 segment	245
Azygos anterior cerebral artery	246
M1 segment	184
P-comm artery	133
P1 segment	196
Vertebral artery	247, 248
Basilar artery	219, 249

1.11. Venous system

The most important facts about the craniocervical venous system are:

1. The venous anatomy is highly variable.

2. The venous structures of the head and neck are widely interconnected.
3. Valves are not present in the intracranial venous system.
4. Valves are typically present at several predictable locations in the cervical region.

Two other useful generalizations can be made:

1. The size of many venous structures have reciprocal relationships with other structures. For instance, if the vein of Labbé is large, the vein of Trolard is usually small.
2. In addition to anatomical variation, the size and flow direction of any given vein can vary greatly with the patient's head and neck position and in the presence of pathology.

As the venous system is so variable, the following discussion details the most common venous anatomic patterns and selected clinically relevant variants. An exhaustive inventory of known variations would be mind-numbingly tedious to read and not particularly useful.

1.11.1. Extracranial veins

1.11.1.1. Scalp veins

The scalp veins have extensive connections with the emissary vein of the skull, although these connections are not normally seen on angiography.

1. *Frontal vein*. Drains the anterior part of the skull and forehead and communicates with the supratrochlear and supraorbital veins.
2. *Supratrochlear vein*. Drains the frontal scalp and forehead and descends over the forehead medial to the supraorbital vein.
3. *Supraorbital vein*. Drains the frontal scalp and forehead and travels over the superior orbital rim lateral to the supratrochlear vein to anastomose with the orbital veins and the angular vein.
4. *Medial temporal vein*. Drains the anterior temporal region and joins the superficial temporal vein.
5. *Superficial temporal vein*. Usually runs together with the corresponding superficial temporal artery. It descends in front of the ear and penetrates the parotid glands, where it is joined by the maxillary vein to form the retromandibular vein, which drains into the internal jugular (IJ) or external jugular (EJ) vein.
6. *Posterior auricular vein*. Drains the retroauricular area and connects to the IJ or EJ.
7. *Occipital vein*. Drains the occipital and posterior cervical areas and anastomoses with the deep cervical and vertebral veins and the transverse sinus via the mastoid emissary vein. It drains into the IJ or EJ (Fig. 1.40).

1.11.1.2. Orbital veins

The orbital veins comprise an important anastomoses between the intracranial and extracranial venous systems, and are typically enlarged in the presence of a carotid-cavernous fistula.

1. *Superior ophthalmic vein (SOV)*. The largest and the most constant orbital vein.²⁵¹ It originates near the trochlea below the medial orbital roof, and travels posteriorly and medially to enter the cavernous sinus. The normal direction of flow in the ophthalmic veins is from extracranial to intracranial;²⁵² reversal of flow in the SOV should raise suspicion of intracranial venous hypertension. The SOV anastomoses with the supraorbital vein and the angular vein.
2. *Inferior ophthalmic vein*. Much smaller than the SOV, it is connected to the SOV via several anastomotic vessels (anterior, medial, and posterior anastomosing veins), and also drains into the cavernous sinus or directly into the superior ophthalmic vein.
3. *Medial ophthalmic vein*. Present in some cases.

1.11.1.3. Facial veins

1. *Angular vein*. The angular vein is formed by the junction of the supratrochlear and supraorbital veins. It travels in an inferior direction at an angle next to the

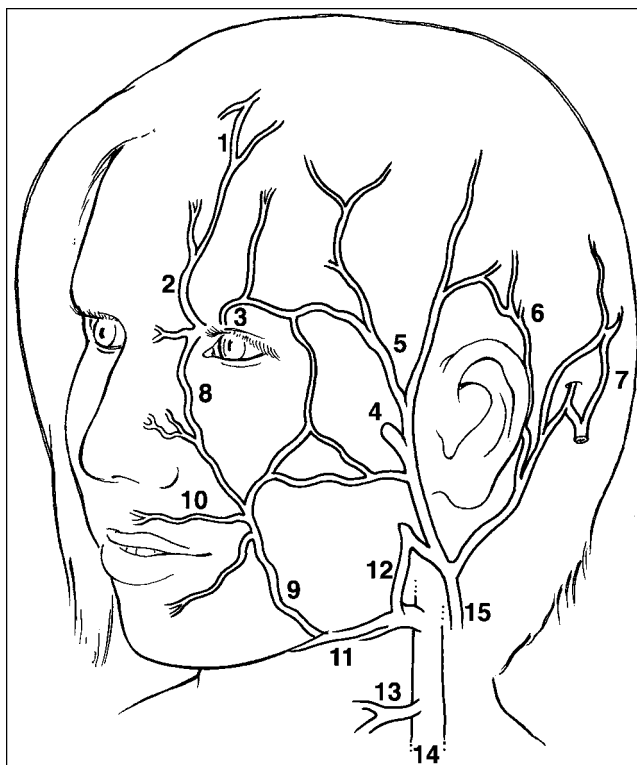


Fig. 1.40 Superficial extracranial veins. (1) Frontal vein; (2) Supratrochlear vein; (3) Supraorbital vein; (4) Medial temporal vein; (5) Superficial temporal vein; (6) Posterior auricular vein; (7) Occipital vein; (8) Angular vein; (9) Facial vein; (10) Labial veins; (11) Submental vein; (12) Retromandibular vein; (13) Thyroid veins; (14) Internal jugular vein; (15) External jugular vein.

nose (thus the name), medial to the orbit. The angular vein communicates with orbital veins and continues inferiorly as the facial vein.

2. *Facial vein.* The facial vein (aka *anterior* facial vein) is the continuation of the angular vein, and it begins at the medial palpebral angle. The facial vein descends obliquely across the face and curves around the inferior edge of the mandible to merge with the submental and retromandibular veins to drain into the IJ. Along its course, the facial vein receives tributaries from the orbit, facial muscles, and submental region.¹ It has extensive connections with deep facial vein, pterygoid plexus, and cavernous sinus.²⁵²
3. *Pterygoid plexus.* The pterygoid plexus is a network of venous channels that is nestled between the temporalis and lateral pterygoid muscles. It is connected to the facial vein via the deep facial vein, and it receives a wide array of tributaries from deep facial and oropharyngeal structures. It connects to the cavernous sinus via emissary veins that travel through the foramen ovale and spinosum, and to the IJ via the maxillary vein (Fig. 1.41).
4. *Deep facial vein.* Connection between the facial vein and the pterygoid plexus.

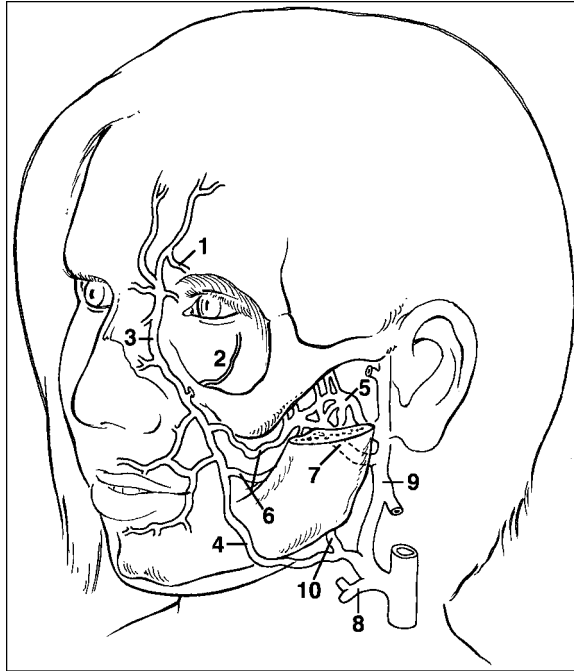


Fig. 1.41 Deep extracranial veins. (1) Superior orbital vein; (2) Inferior orbital vein; (3) Angular vein; (4) Facial vein; (5) Pterygoid plexus; (6) Deep facial veins; (7) Maxillary vein; (8) Common facial vein; (9) Suboccipital veins; (10) Pharyngeal vein.

5. *Maxillary vein*. This vein connects to the pterygoid plexus and travels posteriorly to join the superficial temporal vein to form the retromandibular vein.
6. *Labial veins*. The superior and inferior labial veins drain the upper and lower lips, respectively, and drain into the facial vein.
7. *Retromandibular vein*. This vein (aka temporo-maxillary vein) is formed by the confluence of the maxillary and superficial temporal veins, and passes within the parotid gland to join the facial vein.
8. *Common facial vein*. Formed by the junction of the facial, lingual anterior division of the retromandibular and communicating veins. It receives submental, lingual and thyroid tributaries, and drains into the IJ.¹
9. *Submental vein*. Drains the floor of the mouth and runs under the mandible. It drains into the facial vein.

1.11.1.4. Cervical veins

1. *Internal jugular vein (IJ)*. The IJ begins in the jugular fossa and is the continuation of the sigmoid sinus. The enlargement of the IJ at its origin is termed as the superior jugular bulb. The IJ travels within the carotid sheath posterior and lateral to the common carotid artery, and connects with the subclavian vein on each side to form the brachiocephalic vein. Valves are usually present where the IJ meets the subclavian vein. The right IJ is usually dominant.
2. *External jugular vein (EJ)*. The EJ is formed by the junction of the posterior division of the retromandibular and posterior auricular veins. It originates

inferior to the angle of the mandible and travels across the sternocleidomastoid muscle to drain into the subclavian vein. Valves may be present where the EJ meets the subclavian vein.

3. *Suboccipital veins*. These veins drain the suboccipital region and communicate with the vertebral venous plexus.
4. *Thyroid veins*. Superior and inferior thyroid veins drain the thyroid gland and connect to IJ.
5. *Pharyngeal vein*. Drains the posterior pharyngeal region and connects to the IJ.
6. *Anterior condylar vein*. The anterior condylar vein travels through the hypoglossal canal and connects the inferior petrosal sinus with the vertebral venous plexus and suboccipital veins. It is the rostral equivalent of a spinal radicular vein.²⁵³
7. *Posterior condylar vein*. Connection between the sigmoid sinus and vertebral venous plexus.¹
8. *Spinal radicular veins*. Each spinal radicular vein corresponds to a spinal artery. These veins travel within the neural foramina and connect the epidural venous plexus to the vertebral venous plexus.
9. *Vertebral venous plexus*. The vertebral venous plexus begins in the suboccipital region and extends inferiorly along the vertebral column to drain into the brachiocephalic vein. It surrounds the V2 segment of the vertebral artery and has numerous connections with the occipital veins, epidural venous plexus, and other cervical and facial veins.
10. *Vertebral vein*. The vertebral vein (aka anterior vertebral vein²⁵⁴) is anterior to the vertebral artery²¹⁶ and drains into the vertebral venous plexus.

1.11.2. Venous structures of the skull

A rich network of veins connects the intracranial venous system to the extracranial venous system.

1. *Diploic veins*. The cancellous bone between the inner and outer tables of the skull, contains an extensive network of veins that do not normally cross suture lines and are not normally seen on angiography.⁵ They communicate widely with meningeal and pericranial veins, and with the dural sinuses.
2. *Emissary veins*. These veins connect the extracranial veins to the intracranial venous sinuses.
 - (a) *Parietal emissary veins*. Communicate between the scalp veins and the superior sagittal sinus.
 - (b) *Mastoid emissary veins*. Communicate between the occipital and posterior auricular veins and the sigmoid sinus.

1.11.3. Meningeal veins

Meningeal veins lie on the outer surface of the dura and each corresponds to its respective meningeal artery⁵. The anterior meningeal vein joins the superficial Sylvian vein to form the sphenoparietal sinus.

1.11.4. Intracranial venous sinuses

The dural sinuses are venous channels that are located between the meningeal and endosteal layers of dura. They are rigid and do not have valves. They may be trabeculated and contain bands, chords, and bridges.²⁵⁵ They also contain arachnoid granulations; *Pacchionian granulations* are macroscopic arachnoid granulations that project directly into the venous sinuses. Pacchionian granulations may measure up to 1 cm in diameter²⁵⁶ and should not be mistaken on angiography for intraluminal thrombus (Fig. 1.42). Dural sinuses are also present within the falx cerebri and tentorium. There are two main groups of dural venous sinuses.²⁵⁶

1.11.4.1. Superior group

The superior group primarily drains the majority of the brain and skull (Fig. 1.43).

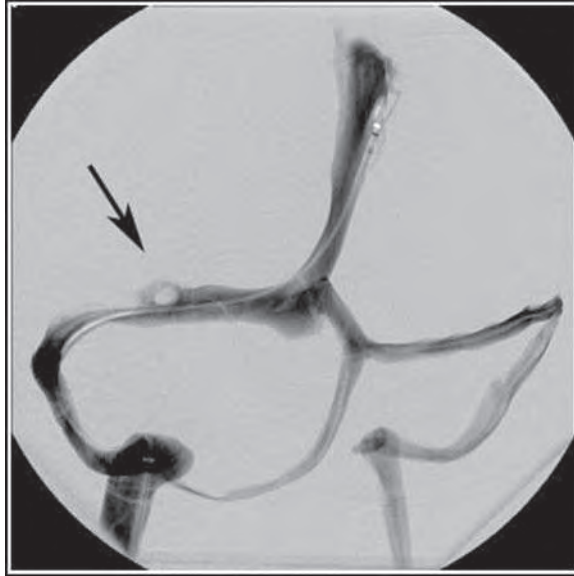

Fig. 1.42 Arachnoid granulation. Venogram of the inferior venous sinuses, showing an arachnoid granulation in the transverse sinus (*arrow*). Arachnoid granulations can have a "punched out" appearance on angiography that can mimic a flow void due to intraluminal thrombus.

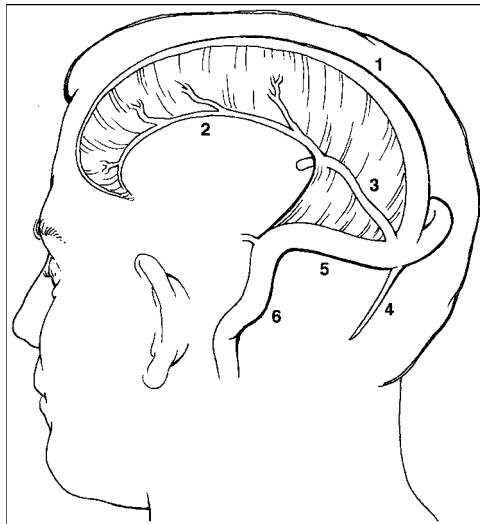


Fig. 1.43 Superior group of dural venous sinuses. (1) Superior sagittal sinus; (2) Inferior sagittal sinus; (3) Straight sinus; (4) Occipital sinus; (5) Transverse sinus; (6) Sigmoid sinus.

1. *Superior sagittal sinus (SSS)*. The SSS lies in a shallow midsagittal groove at the junction of the falx cerebri and the dura lining the inner table of the calvaria. It originates near the crista galli and terminates in the torcular Herophili. The transverse diameter of the SSS ranges from 4 mm in the frontal area to 10 mm in the occipital region.²⁵⁵ The “1/3rd Rule” states that it is generally safe to therapeutically occlude the SSS in the anterior third of the structure, without a significant risk of venous infarction.²⁵⁷ Cortical venous tributaries are most prominent in the middle third of the SSS, and relatively few in number and caliber in the posterior third.
 - (a) Venous connections
 - i. Facial and nasal veins
 - ii. Scalp veins
 - iii. Cortical veins
 - iv. “Intermediate veins”:²⁵⁶ Diploic, meningeal, and emissary veins. These structures provide important collateral pathways in the event of venous sinus occlusion
2. *Inferior sagittal sinus*. The inferior sagittal sinus is relatively small and travels in, or slightly superior to the falx. It begins at the junction of the anterior and middle thirds of the falx, runs above the corpus callosum, and terminates at the falcotentorial apex by connecting with the vein of Galen to form the straight sinus. It is more prominent in infants and young children, than adults.²⁵⁶
 - (a) Venous connections
 - i. Tributaries from the falx, corpus callosum, medial cerebral hemispheres, and SSS via falcine veins.
3. *Straight sinus*. The straight sinus is formed by the confluence of the inferior sagittal sinus and vein of Galen. It travels posteriorly and inferiorly beneath the splenium of the corpus callosum towards the internal occipital protuberance. The straight sinus averages 5 cm in length²⁵⁸ and drains into the confluence of the sinuses, or predominantly into one transverse sinus, usually the left.²⁵⁶ The straight sinus is single channel in most cases, but is doubled or tripled in some 15% of cases.²⁵⁹
 - (a) Venous connections
 - i. Vermian veins
 - ii. Tentorial sinuses
 - iii. Cerebellar hemispheric veins
4. *Occipital sinus*. The occipital sinus is present in 65% of cases, and travels in the midline, within the attached margin of the falx cerebelli, between the confluence of the sinuses and the marginal sinus.²⁶⁰
5. *Torcular Herophili*. The confluence of the sinuses (Fig. 1.44) is formed by the junction of the SSS, straight sinus, transverse sinuses, and occipital sinus. The torcular Herophili is typically asymmetric and widely variable in its configuration. In 10–15% of cases, the superior sagittal sinus drains into one transverse sinus, and there is no direct connection between the left and right transverse sinuses.²⁶¹
6. *Transverse sinus*. The transverse sinus (aka lateral sinus) travels within the peripheral margin of the tentorium and extends from the internal occipital protuberance to

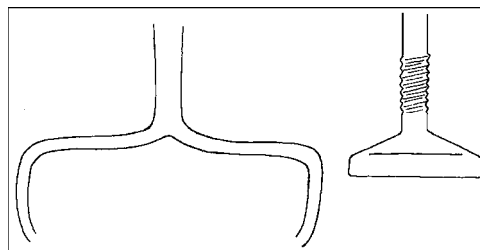


Fig. 1.44 Torcular herophili. The confluence of the sinuses carries the eponym, *Torcular Herophili*, after the anatomist, Herophilus of Chalcedon. The term “torcular” is commonly thought to be translated from the ancient Greek as “wine press,” as the four-limbed confluence (*left*) bears some resemblance to a wine press (*right*).²⁶² An alternative school of thought holds that this is a mistranslation, and that Torcular Herophili actually refers to the concavity on the interior of the occipital bone that houses the confluence.²⁶³

the base of the petrous temporal bone. They are asymmetric in about half of cases, and the right transverse sinus is usually larger.²⁶¹ In some 20% of cases, there is partial or total agenesis of one of the transverse sinuses, usually the left, and in these cases the sigmoid sinus may fill via the vein of Labbé.²⁶¹

- (a) Venous connections
 - i. SSS and contralateral transverse sinus
 - ii. Veins from the inferior and lateral surfaces of the temporal and occipital lobes, including the vein of Labbé.
 - iii. Cerebellar veins.
 - iv. Veins of the scalp via mastoid emissary veins.
 - v. Superior petrosal sinus
- 7. *Sigmoid sinus*. The sigmoid sinus originates where the transverse sinus leaves the tentorial margin. It forms a gentle S-shape and terminates at jugular bulb, where the internal jugular vein begins.
 - (a) Venous connections
 - i. Transverse sinus and internal jugular vein.
 - ii. Suboccipital muscular and scalp veins and the vertebral venous plexus via the mastoid and condylar emissary veins.

1.11.4.2. Inferior group

The inferior group primarily drains the sylvian veins, the inferior surface of the brain, and the orbits (Fig. 1.45).

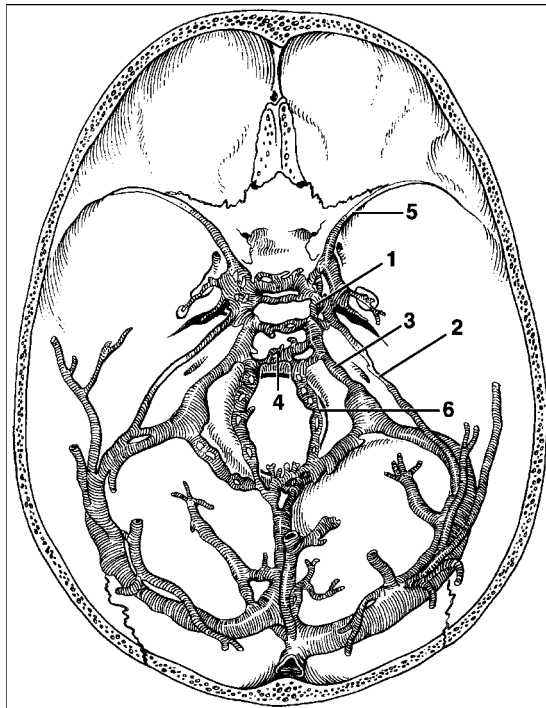


Fig. 1.45 Inferior group of dural venous sinuses
 1. Cavernous sinus 2. Superior petrosal sinus 3. Inferior petrosal sinus 4. Basilar venous plexus 5. Sphenoparietal sinus 6. Vertebral venous plexus.

1. *Cavernous sinus*. Each cavernous sinus lies lateral to the body of the sphenoid bone and extends from the superior orbital fissure to the petrous apex. The anterior and posterior part of the cavernous sinuses are connected to each other via the *circular sinus* (aka “intercavernous sinus”) around the sella turcica, and the basilar venous plexus. Cranial nerves III, IV, V1, and V2 travel in the lateral wall of the cavernous sinus, and the ICA, sympathetic plexus, and cranial nerve VI are suspended by fibrous trabeculae within the lumen of the cavernous sinus.²⁵⁶
 - (a) Venous connections
 - i. Superior and inferior ophthalmic veins
 - ii. Sphenoparietal sinus
 - iii. Superior petrosal vein
 - iv. Inferior petrosal sinus
 - v. Pterygoid plexus via emissary veins of the foramen ovale, foramen lacerum, and foramen Vesalius.
2. *Inferior petrosal sinus*. The inferior petrosal sinus travels in groove between the petrous apex and the clivus (Dorello’s canal), extending from the posterior part of the cavernous sinus to the anterior, superior aspect of the jugular bulb. In some 39% of cases, the left and right inferior petrosal sinuses are markedly asymmetric, and in 8% of cases the sinus is absent on at least one side.²⁶⁴
 - (a) Venous connections
 - i. Cavernous sinus
 - ii. Basilar venous plexus
 - iii. Internal auditory veins
 - iv. Cerebellar and brainstem veins
 - v. Internal jugular vein
3. *Superior petrosal sinus*. The superior petrosal sinus extends from the transverse sinus to the cavernous sinus, and travels along the attachment of the tentorium to the superior margin of the petrous temporal bone. The direction of flow is presumably from posterior to anterior.²⁶⁵
 - (a) Venous connections
 - i. Transverse sinus
 - ii. Petrosal vein
 - iii. Lateral mesencephalic vein
 - iv. Cerebellar veins
 - v. Veins draining the tympanic cavity
 - vi. Cavernous sinus
4. *Sphenoparietal sinus*. The sphenoparietal sinus (aka sinus of Breschet) is the medial extension of the Sylvian veins.²⁵⁶ It travels beneath the lesser wing of the sphenoid bone and drains into the cavernous sinus, pterygoid plexus, or into the inferior petrosal sinus or transverse sinus.²⁶⁵ A “true” sphenoparietal sinus exists when the structure anastomoses with other venous structures at both ends.²⁵¹
5. *Basilar venous plexus*. The basilar venous plexus (aka clival venous plexus) is a network of dural veins that extends over the dorsal surface of the clivus.
 - (a) Venous connections
 - i. Cavernous sinus
 - ii. Inferior petrosal sinus
 - iii. Marginal sinus
6. *Marginal sinus*. The marginal sinus lies in the margin of the foramen magnum and drains into the jugular bulbs. It anastomoses with the occipital sinus and vertebral venous plexuses.
7. *Vertebral venous plexus*. The venous plexus is the extensive network of veins associated with the spine. It is sometimes, subdivided into internal and external components.

1.11.5. Supratentorial cortical veins

The cortical veins drain the outer 1–2cm of the cortex and the subcortical white matter, and travel centrifugally (Fig. 1.46). They have no valves. They exhibit reciprocal prominence, i.e., when one vein is large on a given side, others are usually small.²⁵⁶ Cerebral cortical drainage occurs via three principle routes:

1. *Sylvian veins*. The Sylvian veins (aka superficial middle cerebral veins) originate in the posterior third of the lateral Sylvian fissure and travel through the

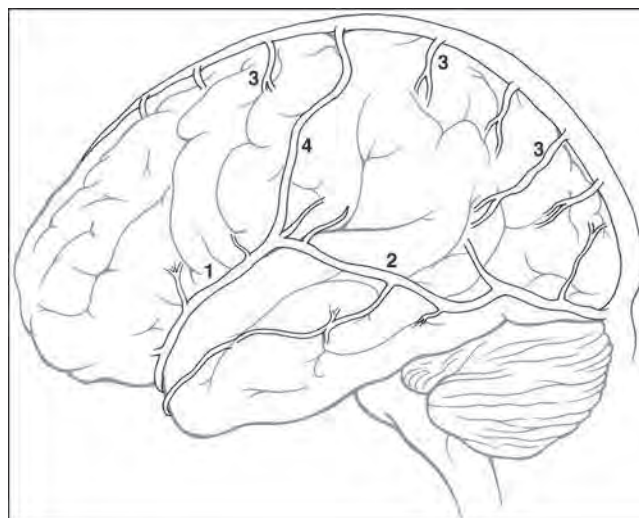


Fig. 1.46 Superficial cortical veins. (1) Sylvian vein; (2) Vein of Labbé; (3) Superior convexity veins; (4) Vein of Trolard.

- lateral aspect of the sylvian fissure and drain parts of the frontal and temporal lobes into the cavernous sinus and pterygoid plexus.^{256, 266}
2. *Temporo-occipital veins.* These veins drain temporal, occipital and parts of the parietal cortex into the transverse sinus.
 - (a) *Vein of Labbé* (aka occipito-temporal vein) is defined as the largest cortical vein crossing the temporal lobe convexity from the sylvian vein to the transverse sinus.⁵ It can be identified on one or both hemispheres in 75% of dissections,²⁶⁷ and is most commonly prominent in the dominant hemisphere.²⁶⁸ It travels in the occipitotemporal sulcus and may have important anastomotic connections with tentorial dural sinuses.
 3. *Superior convexity veins.* These veins, which average 14 per hemisphere,²⁵⁵ drain the superolateral and superomedial cortex into the superior sagittal sinus. The veins enter the superior sagittal sinus perpendicularly in the anterior frontal region; the angle becomes progressively more acute (i.e., opposite to the direction of flow in the superior sagittal sinus) in the parietal and occipital regions. Occipital region veins may pass for a considerable distance before connecting to the superior sagittal sinus, and may be confused with venous anomalies.²⁵⁶ The vein of Rolando travels in the central sulcus.
 - (a) *Vein of Trolard* (aka frontoparietal vein) is defined as the largest anastomotic channel connecting the Sylvian vein to the superior sagittal sinus.⁵ It is most commonly prominent in the non-dominant hemisphere.²⁶⁸

1.11.6. Deep Venous system

The deep venous system drains the periventricular white matter, basal ganglia, and thalamic regions (Fig. 1.47). In contrast to the cortical venous system, which runs centrifugally, the deep venous system runs centripetally. The deep veins can be divided into a *ventricular group* (which includes the subependymal veins and internal cerebral vein) and a *cisternal group* (primarily consisting of the basal vein of Rosenthal and its tributaries).

1. *Medullary veins.* The medullary veins are an array of veins that drain the cerebral white matter. They originate 1–2-cm deep to the cortical mantle and join

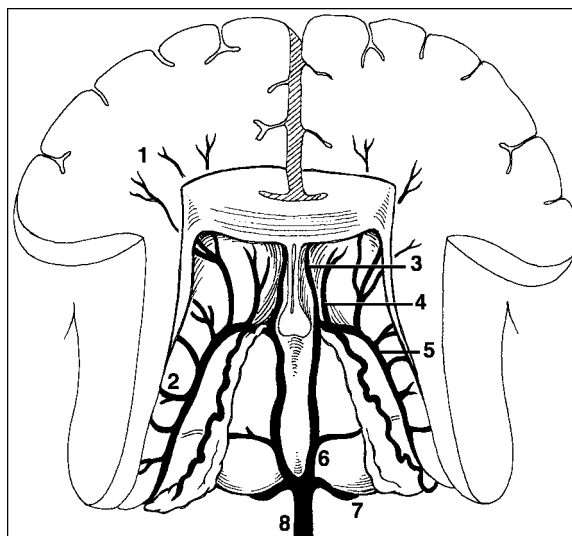


Fig. 1.47 Deep venous system. (1) Medullary veins; (2) Subependymal veins; (3) Septal vein; (4) Anterior caudate vein; (5) Thalamostriate vein; (6) Internal cerebral vein; (7) Basal vein of Rosenthal; (8) Vein of Galen (aka great cerebral vein).

the subependymal veins. They are typically straight and perpendicular to the subependymal veins.

2. *Subependymal veins*

(a) *Septal veins*. The septal veins originate at the lateral aspect of the frontal horns and travel posteriorly and medially to run along the septum pelucidum. In the majority of cases, the septal veins join the thalamostriate veins to form the internal cerebral vein. The venous angle is the junction of the septal vein with the thalamostriate vein. Although the venous angle is generally considered to approximate the location of the foramen of Monro on angiography, in 47.5% of hemispheres, the septal vein joins the internal cerebral vein at an average of 6 mm posterior to the foramen of Monro.²⁶⁹ The septal veins drain the deep frontal white matter and anterior corpus callosum.

(b) *Anterior caudate veins*. The anterior caudate veins (aka longitudinal caudate vein or anteroinferior caudate veins) are a group of tributaries from the medial surface of the caudate nucleus that drain into the thalamostriate vein.

(c) *Thalamostriate vein*. The thalamostriate vein arises from tributaries that converge on the sulcus between the caudate nucleus and the thalamus, and travels in a medial direction towards the Foramen of Monro to join the septal veins and form the internal cerebral vein. It drains the posterior frontal lobe, anterior parietal lobe, caudate nucleus, and internal capsule. Despite its name, the thalamostriate vein does not receive significant tributaries from the thalamus.

(d) *Medial and lateral atrial veins*. These veins drain the walls of the atrium, and may drain directly into the internal cerebral vein, basal vein of Rosenthal, or the vein of Galen.²⁷⁰

3. *Internal cerebral vein*. The internal cerebral vein is formed by the junction of the septal veins and the thalamostriate vein posterior to the foramen of Monro. It travels posteriorly to join the contralateral internal cerebral vein to form the vein of Galen. The internal cerebral vein receives subependymal tributaries and, just anterior to the vein of Galen, the ipsilateral basal vein of Rosenthal.

It averages 30.2mm in length²⁷⁰ and drains the posterior frontal lobe, anterior parietal lobe, caudate nucleus, lentiform nucleus, and internal capsule.

4. *Basal vein of Rosenthal.* The basal vein of Rosenthal (aka basal vein) is the most prominent cisternal vein and is formed below the anterior perforated substance by the junction of the *anterior cerebral* and *deep middle cerebral veins*. The anterior cerebral vein originates near the optic chiasm and is connected to its contralateral counterpart by the anterior communicating vein. The deep middle cerebral vein is formed near the limen insula by the confluence of the insular veins. The basal vein of Rosenthal travels posteriorly between the midbrain and the temporal lobe and terminates by joining the internal cerebral vein or the vein of Galen. It receives extensive tributaries from the temporal lobe, thalamus, and midbrain.
5. *Vein of Galen.* The vein of Galen (aka great cerebral vein) originates in the quadrigeminal cistern by the union of the internal cerebral veins. It curves in a posterosuperior direction towards the apex of the tentorium, where it joins the straight sinus. It is 5–20 mm in length⁹ and its tributaries include the posterior pericallosal, superior cerebellar, and precentral cerebellar veins.

1.11.7. Infratentorial venous system

The veins of the posterior fossa can be grouped according to the principle route of drainage (Fig. 1.48).

1. *Superior (vein of Galen) group.* These veins drain the upper part of the cerebellar hemispheres, vermis, and midbrain.
 - (a) *Precentral cerebellar vein.* The unpaired midline precentral cerebellar vein receives the superior hemispheric and vermian tributaries, and

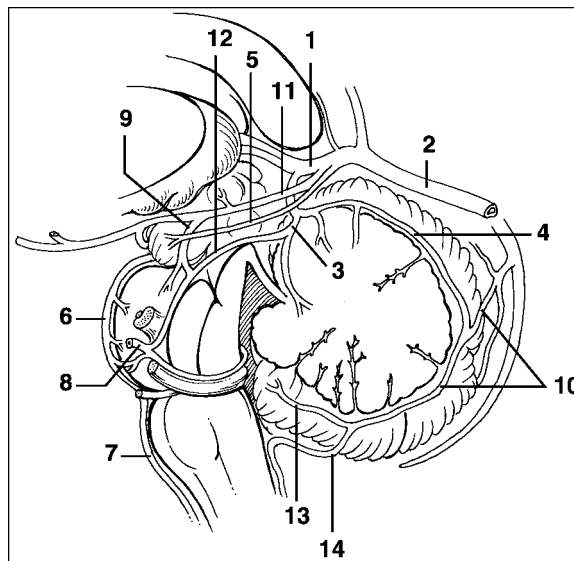


Fig. 1.48 Infratentorial venous system. (1) Vein of Galen; (2) Straight sinus; (3) Precentral cerebellar vein; (4) Superior vermian vein; (5) Basal vein of Rosenthal; (6) Anterior pontomesencephalic vein; (7) Anterior medullary vein; (8) Petrosal vein; (9) Lateral mesencephalic vein; (10) Inferior vermian vein; (11) Posterior mesencephalic vein; (12) Brachial vein; (13) Superior retrotonsilar vein; (14) Inferior retrotonsilar vein.

- travels superiorly and posteriorly parallel to the roof of the fourth ventricle. It enters the vein of Galen posterior to the inferior colliculi.
- (b) *Superior vermian vein*. The paired superior vermian veins originate from tributaries in the culman, posterior to the precentral cerebellar vein. They travel superiorly to drain into the vein of Galen, with or anterior to the precentral cerebellar vein.
 - (c) *Posterior mesencephalic vein*. This vein originates in the interpeduncular fossa and curves around the midbrain to enter the vein of Galen or internal cerebral vein.²⁵¹
2. *Anterior (petrosal vein) group*. These veins drain the anterior part of the brainstem and cerebellum, and empty primarily into the superior and inferior petrosal sinuses.
 - (a) *Anterior pontomesencephalic vein*. The unpaired midline pontomesencephalic vein travels along the anterior belly of the pons, connecting the midline *anterior medullary vein* inferiorly (which, in turn, connects to the *anterior spinal vein*) to the *peduncular vein*, in the interpeduncular cistern. It may also communicate with the petrosal vein and the basal vein of Rosenthal.
 - (b) *Petrosal vein (aka Dandy's vein)*. The petrosal vein is formed by numerous tributaries from the pons, medulla, and cerebellum. It is 2–2.5 cm long,²⁵¹ and travels anterior and lateral to the trigeminal nerve to enter the superior petrosal sinus above the internal auditory meatus.
 - (c) *Lateral mesencephalic vein*. This vein runs in the lateral mesencephalic sulcus and anastomoses with the posterior mesencephalic and petrosal veins.
 3. *Posterior (tentorial) group*. These veins drain toward the tentorium.
 - (a) *Inferior vermian veins*. The paired inferior vermian veins are formed by the superior and inferior retrotonsillar veins. The inferior vermian veins receive tributaries from the vermis and cerebellar hemispheres, and travel posteriorly and superiorly along the inferior vermis to drain into the tentorial, straight, or transverse sinus.

1.11.8. Intracranial venous system variants

The intracranial venous system is widely variable. Selected variants and anomalies are detailed below:

1. *Venous angioma*. A venous angioma (aka developmental venous anomaly or cerebral venous malformation) is a normal variant in which a network of small medullary veins converges into single large central venous channel (see also Chap. 16). They are found in some 2% of autopsies.²⁷¹ They have a characteristic stellate appearance on imaging, and have been hypothesized to occur when medullary veins become hypertrophic to compensate for the occlusion or absence of some other adjacent venous structure. They are frequently found adjacent to cavernous malformations; among patients with cavernous malformations, and upto 29% have an associated developmental venous anomaly.^{272, 273} In fact, focal venous congestion within developmental venous anomalies are thought to contribute to the formation of cavernous malformations.²⁷⁴
2. *Vein of Galen malformation*. This anomaly consists of a dramatically enlarged persistent median vein of the prosencephalon, which is the embryonic precursor to the vein of Galen (see also Chap. 14).²⁷⁵ Multiple feeding arteries typically flow directly into the varix and usually arise from the anterior and posterior choroidal arteries and the anterior cerebral artery. The malformation develops prior to the formation of the vein of Galen and the straight sinus, and the venous pouch drains via the falcine sinus to the superior sagittal sinus. The straight sinus may be hypoplastic or absent. The deep venous system, as a rule, does not appear to communicate with the malformation, although there is a well-documented case of visualization of a communication to normal deep veins after treatment of a vein of Galen malformation.²⁷⁶
3. *Chiari II malformation*. In the Chiari II malformation (Fig. 1.49), the posterior fossa is very small and the straight sinus is angled sharply downward. The confluence of sinuses may be at or below the level of the foramen magnum.
4. *Dandy–Walker complex*. The Dandy–Walker complex is a congenital syndrome that includes cystic dilatation of the fourth ventricle and enlargement of the posterior fossa (Fig. 1.50). The straight sinus and torcular Herophili are often elevated and the transverse sinuses angle inferiorly.

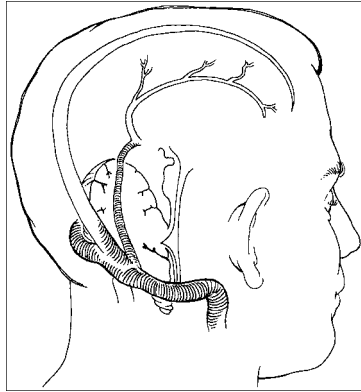


Fig. 1.49 Chiari II malformation
The Chiari II malformation is characterized by an abnormally small posterior fossa, with downward angulation of the straight sinus and low-lying transverse sinuses.

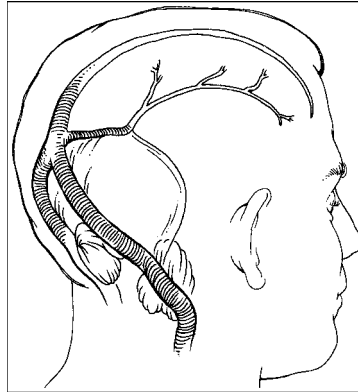


Fig. 1.50 Dandy-walker complex
The tentorium, straight sinus, and torcular Herophili are displaced superiorly by cystic dilatation of the fourth ventricle and enlargement of the posterior fossa.

1.12. Spinal neurovascular anatomy

The spine, and in particular, the spinal cord, is supplied by a number of relatively small and variable arteries with similarly small and variable veins. There is a general organization of spinal blood supply that is constant: Segmental arteries contribute to the segmental levels of the spine and may contribute to the extrinsic arteries of the spinal cord, which then contribute to the intrinsic arteries within the substance of the cord. Similarly, the intrinsic veins of the spinal cord drain into the extrinsic veins on the surface of the cord, which then drains to epidural and paraspinal venous structures.

These vessels should be considered when evaluating vascular lesions in the spine (Table 1.8).

Spinal cord blood supply: General Principles

- Segmental arteries input supply to longitudinal systems.
- Segmental venous drainage is *from* longitudinal spinal cord systems to longitudinal epidural and paraspinal systems.
- Inter-segmental and side-to-side anastomoses are *common*.
- Variability of segmental connections to longitudinal systems is *very common*.

1.12.1. Potential spinal systems

1. Vertebral

These branches of the subclavian are paired longitudinal spinal vessels that travel in the foramina transversaria of the cervical spine. Besides their vital contributions to the blood flow of the brain, there are also important spinal contributions.

(a) Anterior spinal artery

This has two, very short paired branches from the extreme distal vertebral arteries creating a small V-like configuration that merges to a single midline channel that descends from the vertebrobasilar junction inferiorly in the ventral sulcus of the cord. Sometimes, one limb of the V is hypoplastic and the anterior spinal arises from only one of the distal vertebral arteries.

(b) Posterolateral spinal arteries

These are branches, one on each side, arising from distal vertebral or proximal posterior inferior cerebellar artery (PICA), and travel inferiorly

Table 1.8 Arteries supplying the spine

Vertebral level(s)	Feeding arteries	...Which usually arise from:
C1–C2	Ascending pharyngeal	External carotid
	Occipital	External carotid
	Vertebral	Subclavian
	Ascending cervical	Thyrocervical trunk
	Deep cervical	Costocervical trunk
C3–C7	Vertebral	Subclavian
	Ascending cervical	Thyrocervical trunk
	Deep cervical	Costocervical trunk
T1–T3	Supreme intercostal	Costocervical trunk
T3–T4	T4 (“Superior”) intercostal	Aorta
T5–T12	T5–T12 intercostal	Aorta
L1–L4	Lumbar arteries	Aorta
L5	Median sacral	Aortic bifurcation
	Ileolumbar	Internal iliac
Sacrum	Median sacral	Aortic bifurcation
	Lateral sacral	Internal iliac

along the posterior cord. There are two major categories of this vertebral artery contribution to the posterior spinal cord. Each can be associated with variations in the size and course of the distal vertebral artery, and level of origin of the PICA.^{225, 277}

i. Posterior spinal artery

This arises from either the distal extracranial portion of the vertebral or commonly also from the proximal part of an extracranial origin of PICA. Each posterior spinal then travels inferiorly along the posterior cord, dorsal to the posterior spinal nerve roots.²⁷⁷

ii. Lateral spinal artery

Again arises from distal vertebral or proximal PICA. However, these vessels travel along the posterolateral cord, ventral to the posterior roots of C1 through C4.²²⁵ The lateral spinal joins the ipsilateral posterior spinal at the C4 or C5 level.²⁷⁷

(c) Segmental branches

These are small, paired vessels that provide muscular and osseous blood flow in the cervical region. Variably, it can supply an anterior and posterior radicular branch that follows the spinal nerve roots. Again, variably, these radicular branches can connect to either the anterior spinal artery or to the posterolateral spinal artery to provide segmental input to these longitudinal spinal arteries, usually below C3.²⁷⁸

(d) A particularly large radicular input into the cervical anterior spinal artery, is sometimes termed the artery of the cervical enlargement. This often arises from the vertebral, although it may arise from the costocervical trunk or even directly from the subclavian artery.

2. Deep cervical

The deep cervical arteries arise from the costocervical trunk or directly from the second part of the subclavian artery, and represent paired longitudinal systems that are posterior to the transverse processes. They have considerable muscular territories, anastomose with the vertebral arteries and can provide flow to the radicular arteries along the C7 and C8 roots.²⁷⁸ It can variably potentially contribute to the lower cervical cord.

3. Ascending cervical

Branches of the thyrocervical trunk are spinal longitudinal vessels anterior to the transverse processes. These also have muscular supply and also anastomose with the vertebral artery, and can provide radicular branches.

4. **Supreme intercostals**
These arteries arise from the costocervical trunk or directly from the subclavian artery and descend to supply several spinal levels, generally giving radicular arteries for the C7 and C8 levels,²⁷⁸ and potentially one or two levels below. Branches contribute to the bone, connective tissue and muscle at the cervico-thoracic junction usually at T1 and T2 and collateralizing to T3. The supreme intercostals occasionally arise directly from the aorta.⁶
5. **Intercostal (aka posterior intercostal)**
Usually nine pairs of intercostal arteries arise from the aorta, although occasionally adjoining intercostal arteries arise as a common trunk. Intercostal arteries give branches to the spine and paraspinal tissues before setting in under the rib in its costal groove. There are numerous collaterals between adjacent intercostal branches. The intercostal arteries have several common branches.⁶
 - (a) **Dorsal branch**
The dorsal branch, in turn, divides into a spinal branch that supplies bone and dura, and in turn gives a radicular branch that supplies the nerves and possibly the spinal cord. The dorsal branch also has medial and lateral musculocutaneous branches that supply posterior muscles and overlying skin.
 - (b) **Collateral intercostal branch**
Freely anastomoses to adjacent intercostals.
 - (c) **Muscular branches**
Supply lateral and anterior chest wall muscles and anastomose with lateral thoracic branches of the axillary artery.
 - (d) **Lateral cutaneous**
Supply intercostal nerves and lateral chest-wall skin
 - (e) **Multiple small branches to ribs and deep chest wall tissues.**
6. **Lumbar**
Usually four pairs of lumbar arteries arise from the aorta. They have collaterals between ipsilateral lumbar arteries and from side-to-side, the lumbar arteries have branches similar to the intercostals arteries.⁶
 - (a) **Dorsal branch**
The dorsal branch gives osseous branches to the vertebral body, and then gives a spinal branch that supplies bone and dura via a post-central branch in the anterior region of the spinal canal, and a prelaminar branch to the posterior region of the canal. In between those two, the spinal artery gives a radicular branch that supplies the nerves and possibly the spinal cord. The dorsal branch also has medial and lateral musculocutaneous branches that supply the posterior muscles and the overlying skin of the lumbar region.
 - (b) **Collateral lumbar branches**
Freely anastomoses to adjacent lumbar arteries.
 - (c) **Muscular branches**
Supply lateral and posterior muscles and anastomose with lower intercostals, adjacent lumbar arteries, iliolumbar, inferior epigastric, and deep circumflex iliac branches.⁶
7. **Iliolumbar**
A branch of the posterior division of the internal iliac that has branches to the psoas muscle, collaterals to the fourth lumbar artery, an L5 radicular artery, and supplies the gluteal and abdominal wall muscles.⁹
8. **Lateral sacral**
Paired internal iliac branches that supply upper sacral radicular arteries, and can anastomose with median sacral artery branches.
9. **Median sacral**
A single, descending branch arising at the aortic bifurcation and supplying multiple levels of the sacrum. It anastomoses with the lateral sacral and ileolumbar arteries.⁹ Represents the caudal aorta prior to the development of the limb buds.

1.12.2. Segmental contributions to neural territories

Radicular arteries (anterior and posterior)

These are vessels that enter the spine along the spinal nerves, including an anterior one along the ventral root and a posterior one along the dorsal root. They exist potentially at each level, but are not necessarily contributing to the spinal cord

at every possible level. In the cervical spine, studies have shown an average of 2–3 radicular artery connections to the spinal cord, including 2–3 anteriorly and 1 or 2 posteriorly.²⁷⁸ In the thoracolumbar region, 80% of spinal cord blood flow comes from 2 radicular contributions.²⁷⁹ Throughout the cord, anterior radicular contributions to the cord number 3–15, and posterior radicular artery contributions number 14–25.²⁸⁰ There are two commonly mentioned types of radicular artery contributions to the spinal cord, radiculomedullary, and radiculopial.

- **Radiculomedullary** arteries. Radicular branches connecting from generally an anterior radicular artery directly to the anterior spinal artery
- **Radiculopial** arteries. Radicular branches connecting to pial network and posterior radicular branches connecting to posterolateral spinal arteries.²⁸¹
- Artery of Adamkiewicz (aka “arteria radicularis magna” or “artery of the lumbar enlargement”)
- Dominant radiculomedullary contribution to anterior spinal artery (ASA) in thoracolumbar spine, supplies an average 68% of blood flow to the lower cord, with an average diameter of 0.7 mm.²⁷⁹
- Classic “hairpin turn” appearance. Travels sharply cephalad from radicular artery, and then takes a sharp caudal turn as it joins ASA.
- Variable origin. In nearly all cases, arises from the intercostal and lumbar arteries from T8-L2, 80% of the time on the left.²⁸² One study showed that 70% of the time, Adamkiewicz arises from a lumbar artery.²⁸³ Only 3 of 4,000 studied angiographies of the spine, revealed a dominant radiculomedullary artery below L3.²⁸⁴
- When arising from above T8, or below L2, there can be a second dominant radiculomedullary contributor above or below.
- In 63% of cases. The radiculomedullary feeder also has a posterior radiculopial contribution to PSA.²⁸²
- [Table 1.9](#) lists vessels that should be considered to be possible contributors to the spinal cord.

Strange, but True

Albert Wojciek Adamkiewicz had the bright idea that tabes dorsalis was a blood-borne disease, so he needed to study the vascular anatomy of the spinal cord.^{278, 285, 286} The rest is history.

Table 1.9 Danger zones: Territories which, if embolized, risk ischemia of spinal cord

Territory at risk	Anastomosis from	Anastomosis to	Comments/reference
Spinal cord	Lumbar and intercostals arteries	Radiculomedullary or Radiculopial branches	Side-to-side and intersegmental anastomoses are common
	Costocervical trunk	Artery of cervical enlargement	Spinal cord artery may arise from costocervical trunk or from subclavian as a separate vessel
	Ascending cervical	Anterior spinal artery	
	Deep cervical	Posterolateral spinal artery	
	Segmental vertebral branches	Anterior or posterolateral spinal arteries	
	Occipital, muscular branches	Spinal arteries via segmental vertebral branches	
	Ascending pharyngeal, muscular branches	Spinal arteries via segmental vertebral branches	

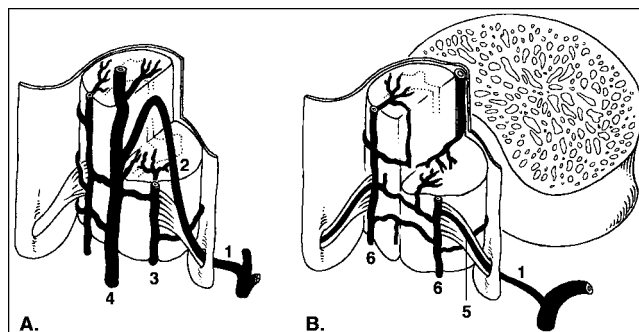


Fig. 1.51 Normal spinal arterial anatomy. (A) Anterior view. Radicular artery (1), radiculomedullary artery (2), pial arterial plexus (3), anterior spinal artery (4); (B) Posterior view. Radicular artery (1), radiculopial artery (5), posterolateral arteries (6).

1.12.3. Extrinsic cord arteries

These arteries are along the surface of the spinal cord (Fig. 1.51).

- Anterior spinal artery (ASA)
ASA is a longitudinal vessel that starts from terminal vertebral arteries and runs continuously down the cord, in the anterior median sulcus of the cord with variable contributions from radiculomedullary inputs.²⁸³ Occasionally, it may split into two channels, but almost never below C5–6.²⁷⁸
- Posterolateral spinal arteries (PSA)
Paired longitudinal vessels start from vertebral arteries proximal to PICA (or PICA itself) and run more or less discontinuously along the posterolateral cord, with sporadic contributions from radiculopial inputs. In the cervical region, there may be two pairs of longitudinal vessels posteriorly, including the lateral spinal ventral to the dorsal root and posterior spinal dorsal to that dorsal root; these two systems merge at C4 or C5.²⁷⁷ A single pair of posterior longitudinal vessels exist throughout the majority of the extent of the cord.
- Pial network. Variable network of longitudinal and interconnecting axial vessels, that primarily anastomose to the PSA with only very small connections to ASA.²⁸⁰
- Conus “basket”. ASA and PSA systems join together at the lower aspect of the conus medularis.

1.12.4. Intrinsic cord arteries

1. Sulcal commissural arteries
Arise from ASA, dive into the median sulcus, and feed the grey matter structures.
2. Radial perforating arteries
Arise from pial network, penetrate deeply, and primarily feed white matter tracts.
3. Intrinsic anastomoses
Axial and longitudinal precapillary connections interconnect the intrinsic arteries in all planes from one to another at the same axial level, and to the vessels cranial and caudal to that level.²⁸¹

1.12.5. Spinal venous systems

These are in many ways similar to and in other ways different from the corresponding arterial organization. “The same, but different.” Lasjaunias²⁸¹ has an exhaustive description of the venous anatomy.

1.12.6. Intrinsic cord veins

1. Radially distributed venules with axial and longitudinal anastomoses, fairly uniformly distributed throughout cord
2. Ventral and dorsal sulcal veins
3. Transmedullary anastomoses between ventral and dorsal sulcal veins

1.12.7. Extrinsic cord veins

- Ventromedial and dorsomedial veins
More or less continuous longitudinal craniocaudal channels of more or less equal size. Unlike arteries, ventral vessels are *not* dominant.²⁸¹
- Ventral and dorsal pial network
Small interconnected veins collecting radial intrinsic veins with longitudinal veins.
- Dorsal and ventral radicular veins
Variable veins connecting cord veins to epidural veins. Levels without a patent radicular vein may have a fibrotic remnant. Transdural portion of vein has a relative narrowing.
- In thoracic region: Longitudinal ventromedial and dorsomedial veins often split up into three channels. Many more patent radicular veins are usually present, compared to cervical or lumbar. Upper thoracic cord may drain cephalad, and lower thoracic cord caudad, giving a potential “watershed zone” at variable levels in the thoracic spine.²⁸¹

1.12.8. Epidural/Extra-spinal veins

- Epidural venous plexus
Dense, multichannel network from skull-base to sacrum. Lateral longitudinal channels and side-to-side connections at each vertebral level. Ventral channels are more prominent. No valves.
- Dorsal and ventral emissary radicular veins
These connect epidural plexus to longitudinal spinal veins (vertebral, azygos/hemiazygos, lumbar, and sacral veins)
- Cervical region: Vertebral veins connect with suboccipital plexus above and jugular and deep cervical veins below
- Thoracic region: On right, azygos vein; on left, superior (accessory) and inferior hemiazygos veins
- Lumbar region: Azygos, directly in IVC and left renal vein
- Sacrum: Internal iliac veins

1.13. References

1. Osborn AG. Diagnostic Cerebral Angiography. 2nd ed. Philadelphia, PA: Lippincott; 1999
2. Tsutsumi M, Ueno Y, Kazekawa K, Tanaka A, Nomoto Y. Aberrant right subclavian artery – three case reports. *Neurol Med Chir (Tokyo)* 2002;42(9):396-8
3. La Barbera G, La Marca G, Martino A, et al. Kinking, coiling, and tortuosity of extracranial internal carotid artery: Is it the effect of a metaplasia? *Surg Radiol Anat* 2006;28(6):573-80
4. Pickhardt PJ, Siegel MJ, Gutierrez FR. Vascular rings in symptomatic children: Frequency of chest radiographic findings. *Radiology* 1997;203(2):423-6
5. Morris P. Practical Neuroangiography. Baltimore, MD: Williams & Wilkins; 1997
6. Standring S. Gray's Anatomy. 39th ed. New York, NY: Elsevier; 2005
7. Trigaux JP, Delchambre F, Van Beers B. Anatomical variations of the carotid bifurcation: Implications for digital subtraction angiography and ultrasonography. *Br J Radiol* 1990;63(747):181-5
8. Handa J, Matsuda M, Handa H. Lateral position of the external carotid artery. Report of a case. *Radiology* 1972;102(2):361-2
9. Teal JS, Rumbaugh CL, Bergeron RT, Segall HD. Lateral position of the external carotid artery: A rare anomaly? *Radiology* 1973;108(1):77-81
10. Dahm MS, Kaurich JD, Brown FR. Independent origins of the internal and external carotid arteries – a case report. *Angiology* 1999;50(9):755-60
11. Aggarwal NR, Krishnamoorthy T, Devasia B, Menon G, Chandrasekhar K. Variant origin of superior thyroid artery, occipital artery and ascending pharyngeal artery from a common trunk from the cervical segment of internal carotid artery. *Surg Radiol Anat* 2006;28(6):650-3
12. Kaneko K, Akita M, Murata E, Imai M, Sowa K. Unilateral anomalous left common carotid artery: A case report. *Ann Anat* 1996;178(5):477-80

13. Zimre O, Salbacak A, Cicekibasi AE, Tuncer I, Seker M. Investigation of the bifurcation level of the common carotid artery and variations of the branches of the external carotid artery in human fetuses. *Ann Anat* 2005;187(4):361-9
14. Silbergleit R, Quint DJ, Mehta BA, Patel SC, Metes JJ, Noujaim SE. The persistent stapedial artery. *AJNR Am J Neuroradiol* 2000;21(3):572-7
15. Rodesch G, Choi IS, Lasjaunias P. Complete persistence of the hyoid-stapedial artery in man. Case report. Intrapetrous origin of the maxillary artery from ICA. *Surg Radiol Anat* 1991;13(1):63-5
16. Moreano EH, Paparella MM, Zeltman D, Goycoolea MV. Prevalence of facial canal dehiscence and of persistent stapedial artery in the human middle ear: A report of 1000 temporal bones. *Laryngoscope* 1994;104(3 Pt 1):309-20
17. Lasjaunias P, Moret J. Normal and non-pathological variations in the angiographic aspects of the arteries of the middle ear. *Neuroradiology* 1978;15(4):213-9
18. Lasjaunias P, Santoyo-Vazquez A. Segmental agenesis of the internal carotid artery: Angiographic aspects with embryological discussion. *Anat Clin* 1984;6(2):133-41
19. Lasjaunias P BA. *Functional Anatomy of Craniofacial Arteries*. New York, NY: Springer; 1987
20. Monfared A, Kim D, Jaikumar S, Gorti G, Kam A. Microsurgical anatomy of the superior and recurrent laryngeal nerves. *Neurosurgery* 2001;49(4):925-32; discussion 32-3
21. Liu JL, Liang CY, Xiang T, et al. Aberrant branch of the superior laryngeal artery passing through the thyroid foramen. *Clin Anat* 2007;20(3):256-9
22. Delattre JF, Flament JB, Palot JP, Pluot M. Variations in the parathyroid glands. Number, situation and arterial vascularization. Anatomical study and surgical application. *J Chir (Paris)* 1982;119(11):633-41
23. Lo A, Oehley M, Bartlett A, Adams D, Blyth P, Al-Ali S. Anatomical variations of the common carotid artery bifurcation. *ANZ J Surg* 2006;76(11):970-2
24. Haccin-Bey L, Daniels DL, Ulmer JL, et al. The ascending pharyngeal artery: Branches, anastomoses, and clinical significance. *AJNR Am J Neuroradiol* 2002;23(7):1246-56
25. Haffajee MR. A contribution by the ascending pharyngeal artery to the arterial supply of the odontoid process of the axis vertebra. *Clin Anat* 1997;10(1):14-8
26. Mercer NS, MacCarthy P. The arterial supply of the palate: Implications for closure of cleft palates. *Plast Reconstr Surg* 1995;96(5):1038-44
27. Huang MH, Lee ST, Rajendran K. Clinical implications of the velopharyngeal blood supply: A fresh cadaveric study. *Plast Reconstr Surg* 1998;102(3):655-67
28. Lasjaunias P, Berenstein A, Doyon D. Normal functional anatomy of the facial artery. *Radiology* 1979;133(3 Pt 1):631-8
29. Djindjian R MJ. *Supraselective Arteriography of the External Carotid Artery*. New York, NY: Springer; 1978
30. Niranjan NS. An anatomical study of the facial artery. *Ann Plast Surg* 1988;21(1):14-22
31. Moreau S, Bourdon N, Salame E, et al. Facial nerve: Vascular-related anatomy at the stylomastoid foramen. *Ann Otol Rhinol Laryngol* 2000;109(9):849-52
32. Tubbs RS, Salter G, Oakes WJ. Continuation of the ascending cervical artery as the occipital artery in man. *Anat Sci Int* 2004;79(1):43-5
33. Lasjaunias P, Berenstein A, ter Brugge KG. *Surgical Neuroangiography, Volume 1: Clinical Vascular Anatomy and Variations*. Berlin: Springer; 2001
34. McKinnon BJ, Wall MP, Karakla DW. The vascular anatomy and angiosome of the posterior auricular artery. A cadaver study. *Arch Facial Plast Surg* 1999;1(2):101-4
35. Pinar YA, Ikiz ZA, Bilge O. Arterial anatomy of the auricle: Its importance for reconstructive surgery. *Surg Radiol Anat* 2003;25(3-4):175-9
36. Imanishi N, Nakajima H, Aiso S. Arterial anatomy of the ear. *Okajimas Folia Anat Jpn* 1997;73(6):313-23
37. Burgasser G, Happak W, Gruber H, Freillinger G. The temporalis: Blood supply and innervation. *Plast Reconstr Surg* 2002;109(6):1862-9
38. Wasieky R, Pretterklieber ML. The human anterior tympanic artery. A nutrient artery of the middle ear with highly variable origin. *Cells Tissues Organs* 2000;166(4):388-94
39. Diamond MK. Homologies of the meningeal-orbital arteries of humans: A reappraisal. *J Anat* 1991;178:223-41
40. Erturk M, Kayalioglu G, Gova F, Varol T, Ozgur T. The cranio-orbital foramen, the groove on the lateral wall of the human orbit, and the orbital branch of the middle meningeal artery. *Clin Anat* 2005;18(1):10-4
41. Yoshioka N, Rhoton AL, Jr, Abe H. Scalp to meningeal arterial anastomosis in the parietal foramen. *Neurosurgery* 2006;58(1 Suppl):ONS123-6; discussion ONS-6
42. Tolosa E. Collateral circulation in occlusive vascular lesions of the brain. The role of the middle meningeal artery in the collateral circulation in compensating for occlusions of the internal carotid artery or its branches. *Prog Brain Res* 1968;30:247-54
43. Dilenge D, Ascherl GF, Jr. Variations of the ophthalmic and middle meningeal arteries: Relation to the embryonic stapedial artery. *AJNR Am J Neuroradiol* 1980;1(1):45-54
44. Gabriele OF, Bell D. Ophthalmic origin of the middle meningeal artery. *Radiology* 1967;89(5):841-4
45. McLennan JE, Rosenbaum AE, Haughton VM. Internal carotid origins of the middle meningeal artery. The ophthalmic-middle meningeal and stapedial-middle meningeal arteries. *Neuroradiology* 1974;7(5):265-75
46. Kawai K, Yoshinaga K, Koizumi M, Honma S, Tokiyoshi A, Kodama K. A middle meningeal artery which arises from the internal carotid artery in which the first branchial artery participates. *Ann Anat* 2006;188(1):33-8
47. Brucher J. Origin of the ophthalmic artery from the middle meningeal artery. *Radiology* 1969;93(1):51-2
48. Hiura A. An anomalous ophthalmic artery arising from the middle meningeal artery. *Anat Anz* 1980;147(5):473-6
49. Watanabe A, Hirano K, Ishii R. Dural carotico-cavernous fistula with both ophthalmic arteries arising from middle meningeal arteries. *Neuroradiology* 1996;38(8):806-8
50. Liu Q, Rhoton AL, Jr. Middle meningeal origin of the ophthalmic artery. *Neurosurgery* 2001;49(2):401-6; discussion 6-7
51. Anderson RJ. A Palatine Branch from the Middle Meningeal Artery. *J Anat Physiol* 1880;15(Pt 1):136-8
52. Kresimir Lukic I, Glunovic V, Marusic A. Extracranial branches of the middle meningeal artery. *Clin Anat* 2001;14(4):292-4
53. Silvela J, Zamarron MA. Tentorial arteries arising from the external carotid artery. *Neuroradiology* 1978;14(5):267-9
54. Seeger JF, Hemmer JF. Persistent basilar/middle meningeal artery anastomosis. *Radiology* 1976;118(2):367-70
55. Lasjaunias P, Moret J, Manelfe C, Theron J, Hasso T, Seeger J. Arterial anomalies at the base of the skull. *Neuroradiology* 1977;13(5):267-72
56. Waga S, Okada M, Yamamoto Y. Basilar-middle meningeal arterial anastomosis. Case report. *J Neurosurg* 1978;49(3):450-2
57. Hofmeijer J, Klijn CJ, Kappelle LJ, Van Huffelen AC, Van Gijn J. Collateral circulation via the ophthalmic artery or leptomeningeal vessels is associated with impaired cerebral vasoreactivity in patients with symptomatic carotid artery occlusion. *Cerebrovasc Dis* 2002;14(1):22-6
58. Bauml JJ, Beard DY. The accessory meningeal artery of man. *J Anat* 1961;95:386-402
59. Vitek JJ. Accessory meningeal artery: An anatomic misnomer. *AJNR Am J Neuroradiol* 1989;10(3):569-73
60. Duncan IC, Dos Santos C. Accessory meningeal arterial supply to the posterior nasal cavity: Another reason for failed endovascular treatment of epistaxis. *Cardiovasc Intervent Radiol* 2003;26(5):488-91
61. Lasjaunias P, Theron J. Radiographic anatomy of the accessory meningeal artery. *Radiology* 1976;121(1):99-104
62. Komiyama M, Kitano S, Sakamoto H, Shiomi M. An additional variant of the persistent primitive trigeminal artery: Accessory meningeal artery - antero-superior cerebellar artery anastomosis associated with moyamoya disease. *Acta Neurochir (Wien)* 1998;140(10):1037-42
63. Weinstein M, Stein R, Pollock J, Stucker TB, Newton TH. Meningeal branch of the posterior cerebral artery. *Neuroradiology* 1974;7(3):129-31
64. Khaki AA, Tubbs RS, Shoja MM, Shokouhi G, Farahani RM. A rare variation of the inferior alveolar artery with

- potential clinical consequences. *Folia Morphol (Warsz)* 2005;64(4):345-6
65. Lauber H. Ueber einige Varietäten im Verlaufe der Arteria maxillaris interna. *Anat Anat* 1901;19:444-8
 66. Lurje A. On the topographical anatomy of the internal maxillary artery. *Acta Anat* 1947;2:219-31
 67. Chien HF, Wu CH, Wen CY, Shieh JY. Cadaveric study of blood supply to the lower intraorbital fat: Etiologic relevance to the complication of anaerobic cellulitis in orbital floor fracture. *J Formos Med Assoc* 2001;100(3):192-7
 68. Traxler H, Windisch A, Geyerhofer U, Surd R, Solar P, Firbas W. Arterial blood supply of the maxillary sinus. *Clin Anat* 1999;12(6):417-21
 69. Markham JW. Sudden loss of vision following alcohol block of the infraorbital nerve. Case report. *J Neurosurg* 1973;38(5):655-7
 70. Amin N, Ohashi Y, Chiba J, Yoshida S, Takano Y. Alterations in vascular pattern of the developing palate in normal and spontaneous cleft palate mouse embryos. *Cleft Palate Craniofac J* 1994;31(5):332-44
 71. Lee HY, Kim HU, Kim SS, et al. Surgical anatomy of the sphenopalatine artery in lateral nasal wall. *Laryngoscope* 2002;112(10):1813-8
 72. Pretterklieber ML, Krammer EB, Mayr R. A bilateral maxillofacial trunk in man: An extraordinary anomaly of the carotid system of arteries. *Acta Anat (Basel)* 1991;141(3):206-11
 73. Kristh A, Barnett DW, Barrow DL, Bonner G. The blood supply of the intracavernous cranial nerves: An anatomic study. *Neurosurg* 1994;34(2):275-9;discussion 9
 74. Moret J, Lasjaunias P, Doyon D, Vignaud J. Angiographic study of facial paralyses (author's transl). *Neuroradiology* 1978;16:308-10
 75. Lee H, Sohn SJ, Jung DK, et al. Sudden deafness and anterior inferior cerebellar artery infarction. *Stroke* 2002;33(12):2807-12
 76. Fernando DA, Lord RS, Ozmen J. The blood supply of the hypoglossal nerve and its relevance to carotid endarterectomy. *Cardiovasc Surg* 1999;7(3):287-91
 77. Gibo H, Lenkey C, Rhoton AL, Jr. Microsurgical anatomy of the supraclinoid portion of the internal carotid artery. *J Neurosurg* 1981;55(4):560-74
 78. Bouthillier A, van Loveren HR, Keller JT. Segments of the internal carotid artery: A new classification. *Neurosurgery* 1996;38(3):425-32; discussion 32-3
 79. Fischer E. Die Lageabweichungen der vorderen Hirnarterie im Gefäßbild. *Zentralbl Neurochir* 1938;3:300-13
 80. Kerber CW, Know K, Hecht ST, Buxton RB. Flow dynamics in the human carotid bulb. *International Journal of Neuroradiology* 1996;2:422-9
 81. Morimoto T, Nitta K, Kazekawa K, Hashizume K. The anomaly of a non-bifurcating cervical carotid artery. Case report. *J Neurosurg* 1990;72(1):130-2
 82. Pascual-Castroviejo I, Viano J, Pascual-Pascual SI, Martinez V. Facial haemangioma, agenesis of the internal carotid artery and dysplasia of cerebral cortex. Case report. *Neuroradiology* 1995;37(8):692-5
 83. Lee JH, Oh CW, Lee SH, Han DH. Aplasia of the internal carotid artery. *Acta Neurochir (Wien)* 2003;145(2):117-25; discussion 25
 84. Chen CJ, Chen ST, Hsieh FY, Wang LJ, Wong YC. Hypoplasia of the internal carotid artery with intercavernous anastomosis. *Neuroradiology* 1998;40(4):252-4
 85. Quint DJ, Boulos RS, Spera TD. Congenital absence of the cervical and petrous internal carotid artery with intercavernous anastomosis. *AJNR Am J Neuroradiol* 1989;10(2):435-9
 86. Tasar M, Yetiser S, Tasar A, Ugurel S, Gonul E, Saglam M. Congenital absence or hypoplasia of the carotid artery: Radioclinical issues. *Am J Otolaryngol* 2004;25(5):339-49
 87. Cali RL, Berg R, Rama K. Bilateral internal carotid artery agenesis: A case study and review of the literature. *Surgery* 1993;113(2):227-33
 88. Teal JS, Rumbaugh CL, Segall HD, Bergeron RT. Anomalous branches of the internal carotid artery. *Radiology* 1973;106(3):567-73
 89. Glasscock ME, 3rd, Seshul M, Seshul MB, Sr. Bilateral aberrant internal carotid artery case presentation. *Arch Otolaryngol Head Neck Surg* 1993;119(3):335-9
 90. Chess MA, Barsotti JB, Chang JK, Ketonen LM, Westesson PL. Duplication of the extracranial internal carotid artery. *AJNR Am J Neuroradiol* 1995;16(7):1545-7
 91. Pedroza A, Dujovny M, Artero JC, et al. Microanatomy of the posterior communicating artery. *Neurosurgery* 1987;20(2):228-35
 92. Saltzman GF. Patent primitive trigeminal artery studied by cerebral angiography. *Acta Radiol* 1959;51(5):329-36
 93. McKenzie JD, Dean BL, Flom RA. Trigeminal-cavernous fistula: Saltzman anatomy revisited. *AJNR Am J Neuroradiol* 1996;17(2):280-2
 94. Richardson DN, Elster AD, Ball MR. Intracranial trigeminal artery. *AJNR Am J Neuroradiol* 1989;10(1):205
 95. Lie AA. Congenital Anomalies of the Carotid Arteries. Amsterdam: Excerpta Medica Foundation; 1968
 96. Patel AB, Gandhi CD, Bederson JB. Angiographic documentation of a persistent otic artery. *AJNR Am J Neuroradiol* 2003;24(1):124-6
 97. De Caro R, Parenti A, Munari PF. The persistent primitive hypoglossal artery: A rare anatomic variation with frequent clinical implications. *Ann Anat* 1995;177(2):193-8
 98. Brismar J. Persistent hypoglossal artery, diagnostic criteria. Report of a case. *Acta Radiol Diagn (Stockh)* 1976;17(2):160-6
 99. Kanai H, Nagai H, Wakabayashi S, Hashimoto N. A large aneurysm of the persistent primitive hypoglossal artery. *Neurosurgery* 1992;30(5):794-7
 100. Kolbinger R, Heindel W, Pawlik G, Erasmi-Korber H. Right proatlantal artery type I, right internal carotid occlusion, and left internal carotid stenosis: Case report and review of the literature. *J Neurol Sci* 1993;117(1-2):232-9
 101. Suzuki S, Nobechi T, Itoh I, Yakura M, Iwashita K. Persistent proatlantal intersegmental artery and occipital artery originating from internal carotid artery. *Neuroradiology* 1979;17(2):105-9
 102. De Ridder D, De Ridder L, Nowe V, Thierens H, Van de Heyning P, Moller A. Pulsatile tinnitus and the intrameatal vascular loop: Why do we not hear our carotids? *Neurosurgery* 2005;57(6):1213-7
 103. Paullus WS, Pait TG, Rhoton AL, Jr. Microsurgical exposure of the petrous portion of the carotid artery. *J Neurosurg* 1977;47(5):713-26
 104. Quisling RG, Rhoton AL, Jr. Intrapetrous carotid artery branches: Radioanatomic analysis. *Radiology* 1979;131(1):133-6
 105. Windfuhr JP. Aberrant internal carotid artery in the middle ear. *Ann Otol Rhinol Laryngol Suppl* 2004;192:1-16
 106. Pahor AL, Hussain SS. Persistent stapedial artery. *J Laryngol Otol* 1992;106(5):254-7
 107. Tauber M, van Loveren HR, Jallo G, Romano A, Keller JT. The enigmatic foramen lacerum. *Neurosurgery* 1999;44(2):386-91
 108. Ziyal IM, Salas E, Wright DC, Sekhar LN. The petro-lingual ligament: The anatomy and surgical exposure of the posterolateral landmark of the cavernous sinus. *Acta Neurochir (Wien)* 1998;140(3):201-4; discussion 4-5
 109. Ziyal IM, Ozgen T, Sekhar LN, Ozcan OE, Cekirge S. Proposed classification of segments of the internal carotid artery: Anatomical study with angiographical interpretation. *Neurol Med Chir (Tokyo)* 2005;45(4):184-90; discussion 90-1
 110. Marshman LA, Connor S, Polkey CE. Internal carotid-inferior petrosal sinus fistula complicating foramen ovale telemetry: Successful treatment with detachable coils: Case report and review. *Neurosurgery* 2002;50(1):209-12
 111. Resnick DK, Subach BR, Marion DW. The significance of carotid canal involvement in basilar cranial fracture. *Neurosurgery* 1997;40(6):1177-81
 112. Rhoton AL, Jr. The sellar region. *Neurosurgery* 2002;51(4 Suppl):S335-74
 113. Inoue T, Rhoton AL, Jr., Theele D, Barry ME. Surgical approaches to the cavernous sinus: A microsurgical study. *Neurosurgery* 1990;26(6):903-32

114. Tran-Dinh H. Cavernous branches of the internal carotid artery: Anatomy and nomenclature. *Neurosurgery* 1987;20(2):205-10
115. Rhoton AL, Jr. The cavernous sinus, the cavernous venous plexus, and the carotid collar. *Neurosurgery* 2002;51(4 Suppl):S375-410
116. Bernasconi V, Cassinari V. Angiographical characteristics of meningiomas of tentorium. *Radiol Med (Torino)* 1957;43(10):1015-26
117. Parkinson D. Collateral Circulation of Cavernous Carotid Artery: Anatomy. *Can J Surg* 1964;7:251-68
118. Hayreh SS. Orbital vascular anatomy. *Eye* 2006;20(10):1130-44
119. Renn WH, Rhoton AL, Jr. Microsurgical anatomy of the sellar region. *J Neurosurg* 1975;43(3):288-98
120. Sacher M, Som PM, Shugar JM, Leeds NE. Kissing intrasellar carotid arteries in acromegaly: CT demonstration. *J Comput Assist Tomogr* 1986;10(6):1033-5
121. Midkiff RB, Boykin MW, McFarland DR, Bauman JA. Agenesis of the internal carotid artery with intercavernous anastomosis. *AJNR Am J Neuroradiol* 1995;16(6):1356-9
122. Gottfried ON, Soleau SW, Couldwell WT. Suprasellar displacement of intracavernous internal carotid artery: Case report. *Neurosurg* 2003;53(6):1433-4; discussion 4-5
123. Kobayashi S, Kyoshima K, Gibo H, Hegde SA, Takemae T, Sugita K. Carotid cave aneurysms of the internal carotid artery. *J Neurosurg* 1989;70(2):216-21
124. Gonzalez LF, Walker MT, Zabramski JM, Partovi S, Wallace RC, Spetzler RF. Distinction between paraclinoid and cavernous sinus aneurysms with computed tomographic angiography. *Neurosurgery* 2003;52(5):1131-7; discussion 8-9
125. Tsutsumi S, Rhoton AL, Jr. Microsurgical anatomy of the central retinal artery. *Neurosurgery* 2006;59(4):870-8; discussion 8-9
126. Hayreh SS. Arteries of the Orbit in the Human Being. *Br J Surg* 1963;50:938-53
127. Lang J, Kageyama I. The ophthalmic artery and its branches, measurements and clinical importance. *Surg Radiol Anat* 1990;12(2):83-90
128. Krisht AF, Barrow DL, Barnett DW, Bonner GD, Shengalaia G. The microsurgical anatomy of the superior hypophyseal artery. *Neurosurgery* 1994;35(5):899-903; discussion
129. Fujimura M, Seki H, Sugawara T, Tomichi N, Oku T, Higuchi H. Anomalous internal carotid artery- anterior cerebral artery anastomosis associated with fenestration and cerebral aneurysm. *Neurol Med Chir (Tokyo)* 1996;36(4):229-33
130. Hayreh SS, Dass R. The ophthalmic artery. II. Origin and intracranial and intra-canalicular course. *Br J Ophthalmol* 1962;46:165-85
131. Alvarez H, Rodesch G, Garcia-Monaco R, Lasjaunias P. Embolisation of the ophthalmic artery branches distal to its visual supply. *Surg Radiol Anat* 1990;12(4):293-7
132. Saeki N, Rhoton AL, Jr. Microsurgical anatomy of the upper basilar artery and the posterior circle of Willis. *J Neurosurg* 1977;46(5):563-78
133. Alpers BJ, Berry RG, Paddison RM. Anatomical studies of the circle of Willis in normal brain. *AMA Arch Neurol Psychiatry* 1959;81(4):409-18
134. Tripathi M, Goel V, Padma MV, et al. Fenestration of the posterior communicating artery. *Neurol India* 2003;51(1):75-6
135. Rhoton AL, Jr., Fujii K, Fradd B. Microsurgical anatomy of the anterior choroidal artery. *Surg Neurol* 1979;12(2):171-87
136. Morandi X, Brassier G, Darnault P, Mercier P, Scarabin JM, Duval JM. Microsurgical anatomy of the anterior choroidal artery. *Surg Radiol Anat* 1996;18(4):275-80
137. Paroni Sterbini GL, Agatiello LM, Stocchi A, Solivetti FM. CT of ischemic infarctions in the territory of the anterior choroidal artery: A review of 28 cases. *AJNR Am J Neuroradiol* 1987;8(2):229-32
138. Das K, Benzil DL, Rovit RL, Murali R, Couldwell WT, Irving S. Cooper (1922-1985): A pioneer in functional neurosurgery. *J Neurosurg* 1998;89(5):865-73
139. Cooper IS. Surgical occlusion of the anterior choroidal artery in Parkinsonism. *Surg Gynecol Obstet* 1954;92(2):207-19
140. Moyer DJ, Flamm ES. Anomalous arrangement of the origins of the anterior choroidal and posterior communicating arteries. Case report. *J Neurosurg* 1992;76(6):1017-8
141. Takahashi S, Suga T, Kawata Y, Sakamoto K. Anterior choroidal artery: Angiographic analysis of variations and anomalies. *AJNR Am J Neuroradiol* 1990;11(4):719-29
142. Taveras JM, Wood EH. *Diagnostic Neuroradiology*. In: 2nd ed. Baltimore, MD: Williams & Wilkins; 1976:584-7
143. Waga S, Morikawa A. Aneurysm developing on the infundibular widening of the posterior communicating artery. *Surg Neurol* 1979;11(2):125-7
144. Ohyama T, Ohara S, Momma F. Fatal subarachnoid hemorrhage due to ruptured infundibular widening of the posterior communicating artery - case report. *Neurol Med Chir (Tokyo)* 1994;34(3):172-5
145. Saltzman GF. Infundibular widening of the posterior communicating artery studied by carotid angiography. *Acta Radiol* 1959;51(6):415-21
146. Wollschlaeger G, Wollschlaeger PB, Lucas FV, Lopez VF. Experience and result with postmortem cerebral angiography performed as routine procedure of the autopsy. *Am J Roentgenol Radium Ther Nucl Med* 1967;101(1):68-87
147. Willis T. *Cerebri anatomie; cui accessit nervorum descriptio et usus*. London: J. Fleisher; 1664
148. Wolpert SM. The circle of Willis. *AJNR Am J Neuroradiol* 1997;18(6):1033-4
149. Krabbe-Hartkamp MJ, van der Grond J, de Leeuw FE, et al. Circle of Willis: Morphologic variation on three-dimensional time-of-flight MR angiograms. *Radiology* 1998;207(1):103-11
150. Hendrikse J, van Raamt AF, van der Graaf Y, Mali WPTM, van der Grond J. Distribution of cerebral blood flow in the circle of Willis. *Radiology* 2005;235(1):184-9
151. Alpers BJ, Berry RG. Circle of Willis in cerebral vascular disorders. The anatomical structure. *Arch Neurol* 1963;8:398-402
152. Hoksbergen AW, Legemate DA, Csiba L, Csati G, Siro P, Fulesdi B. Absent collateral function of the circle of Willis as risk factor for ischemic stroke. *Cerebrovasc Dis* 2003;16(3):191-8
153. Perlmutter D, Rhoton AL, Jr. Microsurgical anatomy of the anterior cerebral-anterior communicating-recurrent artery complex. *J Neurosurg* 1976;45(3):259-72
154. Rhoton AL, Jr., Saeki N, Perlmutter D, Zeal A. Microsurgical anatomy of common aneurysm sites. *Clin Neurosurg* 1979;26:248-306
155. Serizawa T, Saeki N, Yamaura A. Microsurgical anatomy and clinical significance of the anterior communicating artery and its perforating branches. *Neurosurgery* 1997;40(6):1211-6; discussion 6-8
156. Dunker RO, Harris AB. Surgical anatomy of the proximal anterior cerebral artery. *J Neurosurg* 1976;44(3):359-67
157. Gomes FB, Dujovny M, Umansky F, et al. Microanatomy of the anterior cerebral artery. *Surg Neurol* 1986;26(2):129-41
158. Marinkovic S, Milisavljevic M, Kovacevic M. Anatomical bases for surgical approach to the initial segment of the anterior cerebral artery. Microanatomy of Heubner's artery and perforating branches of the anterior cerebral artery. *Surg Radiol Anat* 1986;8(1):7-18
159. Moffat DB. A case of persistence of the primitive olfactory artery. *Anat Anz* 1967;121(5):477-9
160. Nozaki K, Taki W, Kawakami O, Hashimoto N. Cerebral aneurysm associated with persistent primitive olfactory artery aneurysm. *Acta Neurochir (Wien)* 1998;140(4):397-401; discussion 2
161. Bollar A, Martinez R, Gelabert M, Garcia A. Anomalous origin of the anterior cerebral artery associated with aneurysm - embryological considerations. *Neuroradiology* 1988;30(1):86
162. Maurer J, Maurer E, Perneczky A. Surgically verified variations in the A1 segment of the anterior cerebral artery. Report of two cases. *J Neurosurg* 1991;75(6):950-3
163. Given CA, 2nd, Morris PP. Recognition and importance of an infraoptic anterior cerebral artery: Case report. *AJNR Am J Neuroradiol* 2002;23(3):452-4
164. Minakawa T, Kawamura M, Hayano M, Kawakami K. Aneurysms associated with fenestrated anterior cerebral

- arteries. Report of four cases and review of the literature. *Surg Neurol* 1985;24(3):284-8
165. Suzuki M, Onuma T, Sakurai Y, Mizoi K, Ogawa A, Yoshimoto T. Aneurysms arising from the proximal (A1) segment of the anterior cerebral artery. A study of 38 cases. *J Neurosurg* 1992;76(3):455-8
 166. Choudhary KA. Fenestrated anterior cerebral artery. *Br J Neurosurg* 2002;16(5):525-9
 167. Ladzinski P, Maliszewski M, Majchrzak H. The accessory anterior cerebral artery: Case report and anatomic analysis of vascular anomaly. *Surg Neurol* 1997;48(2):171-4
 168. Singer RJ, Abe T, Taylor WH, Marks MP, Norbash AM. Intracavernous anterior cerebral artery origin with associated arteriovenous malformations: A developmental analysis: Case report. *Neurosurgery* 1997;40(4):829-31; discussion 31
 169. Spinnato S, Pasqualin A, Chioffi F, Da Pian R. Infraoptic course of the anterior cerebral artery associated with an anterior communicating artery aneurysm: Anatomic case report and embryological considerations. *Neurosurgery* 1999;44(6):1315-9
 170. Burbank NS, Morris PP. Unique Anomalous Origin of the Left Anterior Cerebral Artery. *AJNR Am J Neuroradiol* 2005;26(10):2533-5
 171. Busse O. Aneurysmen und Bildungsfehler der A. Communicans Anterior. *Virchows Arch Pathol Anat* 1927;229:178-89
 172. Marinkovic S, Milisavljevic M, Marinkovic Z. Branches of the anterior communicating artery. Microsurgical anatomy. *Acta Neurochir (Wien)* 1990;106(1-2):78-85
 173. Perlmutter D, Rhoton AL, Jr. Microsurgical anatomy of the distal anterior cerebral artery. *J Neurosurg* 1978;49(2):204-28
 174. Ostrowski AZ, Webster JE, Gurdjian ES. The proximal anterior cerebral artery: An anatomic study. *Arch Neurol* 1960;3:661-4
 175. Baptista AG. Studies on the Arteries of the Brain. II. the Anterior Cerebral Artery: Some Anatomic Features and Their Clinical Implications. *Neurology* 1963;13:825-35
 176. Huber P, Braun J, Hirschmann D, Agyeman JF. Incidence of berry aneurysms of the unpaired pericallosal artery: Angiographic study. *Neuroradiology* 1980;19(3):143-7
 177. Cinnamon J, Zito J, Chalif DJ, et al. Aneurysm of the azygos pericallosal artery: Diagnosis by MR imaging and MR angiography. *AJNR Am J Neuroradiol* 1992;13(1):280-2
 178. Osaka K, Matsumoto S. Holoprosencephaly in neurosurgical practice. *J Neurosurg* 1978;48(5):787-803
 179. Yasargil MG, Carter LP. Saccular aneurysms of the distal anterior cerebral artery. *J Neurosurg* 1974;40(2):218-23
 180. Gloger S, Gloger A, Vogt H, Kretschmann HJ. Computer-assisted 3D reconstruction of the terminal branches of the cerebral arteries. I. Anterior cerebral artery. *Neuroradiology* 1994;36(3):173-80
 181. Gibo H, Carver CC, Rhoton AL, Jr., Lenkey C, Mitchell RJ. Microsurgical anatomy of the middle cerebral artery. *J Neurosurg* 1981;54(2):151-69
 182. Umansky F, Gomes FB, Dujovny M, et al. The perforating branches of the middle cerebral artery. A microanatomical study. *J Neurosurg* 1985;62(2):261-8
 183. Grand W. Microsurgical anatomy of the proximal middle cerebral artery and the internal carotid artery bifurcation. *Neurosurgery* 1980;7(3):215-8
 184. Komiya M, Nakajima H, Nishikawa M, Yasui T. Middle cerebral artery variations: Duplicated and accessory arteries. *AJNR Am J Neuroradiol* 1998;19(1):45-9
 185. Umansky F, Dujovny M, Ausman JI, Diaz FG, Mirchandani HG. Anomalies and variations of the middle cerebral artery: A microanatomical study. *Neurosurgery* 1988;22(6 Pt 1):1023-7
 186. Uchino M, Kitajima S, Sakata Y, Honda M, Shibata I. Ruptured aneurysm at a duplicated middle cerebral artery with accessory middle cerebral artery. *Acta Neurochir (Wien)* 2004;146(12):1373-4; discussion 5
 187. Takahashi T, Suzuki S, Ohkuma H, Iwabuchi T. Aneurysm at a duplication of the middle cerebral artery. *AJNR Am J Neuroradiol* 1994;15(6):1166-8
 188. Jain KK. Some Observations on the Anatomy of the Middle Cerebral Artery. *Can J Surg* 1964;7:134-9
 189. Abanou A, Lasjaunias P, Manelfe C, Lopez-Ibor L. The accessory middle cerebral artery (AMCA). Diagnostic and therapeutic consequences. *Anat Clin* 1984;6(4):305-9
 190. Morioka M, Fujioka S, Itoyama Y, Ushio Y. Ruptured distal accessory anterior cerebral artery aneurysm: Case report. *Neurosurgery* 1997;40(2):399-401; discussion 2
 191. Takahashi S, Hoshino F, Uemura K, Takahashi A, Sakamoto K. Accessory middle cerebral artery: Is it a variant form of the recurrent artery of Heubner? *AJNR Am J Neuroradiol* 1989;10(3):563-8
 192. Han DH, Gwak HS, Chung CK. Aneurysm at the origin of accessory middle cerebral artery associated with middle cerebral artery aplasia: Case report. *Surg Neurol* 1994;42(5):388-91
 193. Michotey P, Moscow NP, Salamon G. Anatomy of the cortical branches of the middle cerebral artery. In: Newton TH, Potts DG, eds. *Radiology of the Skull and Brain*. St. Louis, MO: Mosby; 1974:1471-8
 194. Zeal AA, Rhoton AL, Jr. Microsurgical anatomy of the posterior cerebral artery. *J Neurosurg* 1978;48(4):534-59
 195. Margolis MT, Newton TH, Hoyt WF. Gross and roentgenologic anatomy of the posterior cerebral artery. In: Newton TH, Potts PC, eds. *Radiology of the Skull and Brain*. St. Louis, MO: Mosby; 1974:1551-76
 196. Margolis MT, Newton TH, Hoyt WF. Cortical branches of the posterior cerebral artery. Anatomic-radiologic correlation. *Neuroradiology* 1971;2(3):127-35
 197. Caruso G, Vincentelli F, Rabehanta P, Giudicelli G, Grisoli F. Anomalies of the P1 segment of the posterior cerebral artery: Early bifurcation or duplication, fenestration, common trunk with the superior cerebellar artery. *Acta Neurochir (Wien)* 1991;109(1-2):66-71
 198. Percheron G. Arteries of the human thalamus. II. Arteries and paramedian thalamic territory of the communicating basilar artery. *Rev Neurol (Paris)* 1976;132(5):309-24
 199. Raphaeli G, Liberman A, Gomori JM, Steiner I. Acute bilateral paramedian thalamic infarcts after occlusion of the artery of Percheron. *Neurology* 2006;66(1):E7
 200. Matheus MG, Castillo M. Imaging of acute bilateral paramedian thalamic and mesencephalic infarcts. *AJNR Am J Neuroradiol* 2003;24(10):2005-8
 201. Milisavljevic MM, Marinkovic SV, Gibo H, Puskas LF. The thalamogeniculate perforators of the posterior cerebral artery: The microsurgical anatomy. *Neurosurgery* 1991;28(4):523-9; discussion 9-30
 202. Berland LL, Houghton VM. Anomalous origin of posterior choroidal artery from basilar artery. *AJR Am J Roentgenol* 1979;132(4):674-5
 203. Fujii K, Lenkey C, Rhoton AL, Jr. Microsurgical anatomy of the choroidal arteries: Lateral and third ventricles. *J Neurosurg* 1980;52(2):165-88
 204. Galloway JR, Greitz T. The medial and lateral choroid arteries. An anatomic and roentgenographic study. *Acta radiol* 1960;53:353-66
 205. Wollschlaeger PB, Wollschlaeger G. An infratentorial meningeal artery. *Radiologie* 1965;5(11):451-2
 206. Ono M, Ono M, Rhoton AL, Jr., Barry M. Microsurgical anatomy of the region of the tentorial incisura. *J Neurosurg* 1984;60(2):365-99
 207. Bojanowski WM, Rigamonti D, Spetzler RF, Flom R. Angiographic demonstration of the meningeal branch of the posterior cerebral artery. *AJNR Am J Neuroradiol* 1988;9(4):808
 208. Furuno M, Yamakawa N, Okada M, Waga S. Anomalous origin of the calcareine artery. *Neuroradiology* 1995;37(8):658
 209. Abrahams JM, Hurst RW, Bagley LJ, Zager EL. Anterior choroidal artery supply to the posterior cerebral artery distribution: Embryological basis and clinical implications. *Neurosurgery* 1999;44(6):1308-14
 210. Tubbs RS, Salter G, Wellons JC, 3rd, Oakes WJ. Blood supply of the human cervical sympathetic chain and ganglia. *Eur J Morphol* 2002;40(5):283-8
 211. Lemke AJ, Benndorf G, Liebig T, Felix R. Anomalous origin of the right vertebral artery: Review of the literature and case report of right vertebral artery origin distal to the left subclavian artery. *AJNR Am J Neuroradiol* 1999;20(7):1318-21

212. Goray VB, Joshi AR, Garg A, Merchant S, Yadav B, Maheshwari P. Aortic arch variation: A unique case with anomalous origin of both vertebral arteries as additional branches of the aortic arch distal to left subclavian artery. *AJNR Am J Neuroradiol* 2005;26(1):93-5
213. Palmer FJ. Origin of the right vertebral artery from the right common carotid artery: Angiographic demonstration of three cases. *Br J Radiol* 1977;50(591):185-7
214. Goddard AJ, Annesley-Williams D, Guthrie JA, Weston M. Duplication of the vertebral artery: Report of two cases and review of the literature. *Neuroradiology* 2001;43(6):477-80
215. Tubbs RS, Loukas M, Remy AC, Shoja MM, Salter EG, Oakes WJ. The vertebral nerve revisited. *Clin Anat* 2007;20(6):644-7
216. Brink B. Approaches to the second segment of the vertebral artery. In: Berguer R, Bauer R, eds. *Vertebrobasilar Arterial Occlusive Disease*. New York, NY: Raven; 1984:257-64
217. Diaz FG, Ausman JI, Shrontz C, et al. Surgical correction of lesions affecting the second portion of the vertebral artery. *Neurosurgery* 1986;19(1):93-100
218. Fine AD, Cardoso A, Rhoton AL, Jr. Microsurgical anatomy of the extracranial-extradural origin of the posterior inferior cerebellar artery. *J Neurosurg* 1999;91(4):645-52
219. de Oliveira E, Rhoton AL, Jr, Peace D. Microsurgical anatomy of the region of the foramen magnum. *Surg Neurol* 1985;24(3):293-352
220. Akar ZC, Dujovny M, Slavin KV, Gomez-Tortosa E, Ausman JI. Microsurgical anatomy of the intracranial part of the vertebral artery. *Neuro Res* 1994;16(3):171-80
221. Lister JR, Rhoton AL, Jr., Matsushima T, Peace DA. Microsurgical anatomy of the posterior inferior cerebellar artery. *Neurosurgery* 1982;10(2):170-99
222. Ahuja A, Graves VB, Crosby DL, Strother CM. Anomalous origin of the posterior inferior cerebellar artery from the internal carotid artery. *AJNR Am J Neuroradiol* 1992;13(6):1625-6
223. Ogawa T, Fujita H, Inugami A, Shishido F, Higano S, Uemura K. Anomalous origin of the posterior inferior cerebellar artery from the posterior meningeal artery. *AJNR Am J Neuroradiol* 1991;12(1):186
224. Margolis MT, Newton TH. The posterior inferior cerebellar artery. In: Newton TH, Potts DG, eds. *Radiology of the Skull and Brain*. St. Louis, MO: Mosby; 1974:1710-74
225. Salamon G, Huang YP. *Radiologic Anatomy of the Brain*. 1976:305-6
226. Lasjaunias P, Vallee B, Person H, Ter Brugge K, Chiu M. The lateral spinal artery of the upper cervical spinal cord. Anatomy, normal variations, and angiographic aspects. *J Neurosurg* 1985;63(2):235-41
227. Barr JD, Lemley TJ. Endovascular arterial occlusion accomplished using microcoils deployed with and without proximal flow arrest: Results in 19 patients. *AJNR Am J Neuroradiol* 1999;20(8):1452-6
228. Lewis SB, Chang DJ, Peace DA, Lafrentz PI, Day AL. Distal posterior inferior cerebellar artery aneurysms: Clinical features and management. *J Neurosurg* 2002;97(4):756-66
229. Smoker WR, Price MJ, Keyes WD, Corbett JJ, Gentry LR. High-resolution computed tomography of the basilar artery: I. Normal size and position. *AJNR Am J Neuroradiol* 1986;7(1):55-60
230. Torche M, Mahmood A, Araujo R, Dujovny M, Dragovic L, Ausman JI. Microsurgical anatomy of the lower basilar artery. *Neuro Res* 1992;14(3):259-62
231. Shrontz C, Dujovny M, Ausman JI, et al. Surgical anatomy of the arteries of the posterior fossa. *J Neurosurg* 1986;65(4):540-4
232. Amarencio P, Rosengart A, DeWitt LD, Pessin MS, Caplan LR. Anterior inferior cerebellar artery territory infarcts. Mechanisms and clinical features. *Arch Neurol* 1993;50(2):154-61
233. Naidich TP, Kricheff II, George AE, Lin JP. The normal anterior inferior cerebellar artery. Anatomic-radiographic correlation with emphasis on the lateral projection. *Radiology* 1976;119(2):355-73
234. Atkinson WI. The anterior inferior cerebellar artery: It's variation, pontine distribution and significance in surgery of cerebello-pontine angle tumors. *J Neurol Neurosurg Psychiatry* 1949;12:137-51
235. Rhoton AL, Jr. Microsurgery of the internal acoustic meatus. *Surg Neurol* 1974;2(5):311-8
236. Brunsteins DB, Ferreri AJ. Microsurgical anatomy of VII and VIII cranial nerves and related arteries in the cerebello-pontine angle. *Surg Radiol Anat* 1990;12(4):259-65
237. Martin RG, Grant JL, Peace D, Theiss C, Rhoton AL, Jr. Microsurgical relationships of the anterior inferior cerebellar artery and the facial-vestibulocochlear nerve complex. *Neurosurgery* 1980;6(5):483-507
238. Ito J, Takeda N, Suzuki Y, Tekeuchi S, Osugi S, Yoshida Y. Anomalous origin of the anterior inferior cerebellar arteries from the internal carotid artery. *Neuroradiology* 1980;19(2):105-9
239. Caruso G, Vincentelli F, Giudicelli G, Grisoli F, Xu T, Gouaze A. Perforating branches of the basilar bifurcation. *J Neurosurg* 1990;73(2):259-65
240. Pedroza A, Dujovny M, Ausman JI, et al. Microvascular anatomy of the interpeduncular fossa. *J Neurosurg* 1986;64(3):484-93
241. Hardy DG, Rhoton AL, Jr. Microsurgical relationships of the superior cerebellar artery and the trigeminal nerve. *J Neurosurg* 1978;49(5):669-78
242. Hardy DG, Peace DA, Rhoton AL, Jr. Microsurgical anatomy of the superior cerebellar artery. *Neurosurgery* 1980;6(1):10-28
243. Stopford JSB. The arteries of the pons and medulla oblongata. *J Anat* 1916;50:131-64
244. Newton TH, Mani RL. The vertebral artery. In: Newton TH, Potts DG, eds. *Radiology of the Skull and Brain: Angiography*. St. Louis, MO: Mosby; 1974:1659-709
245. Ng PP, Steinfort B, Stoodley MA. Internal carotid artery fenestration with dual aneurysms. Case illustration. *J Neurosurg* 2006;104(6):979
246. Kachhara R, Nair S, Gupta AK. Fenestration of the proximal anterior cerebral artery (A1) with aneurysm manifesting as subarachnoid hemorrhage - case report. *Neurol Med Chir (Tokyo)* 1998;38(7):409-12
247. Ihara S, Uemura K, Tsukada A, Yanaka K, Nose T. Aneurysm and fenestration of the azygos anterior cerebral artery - case report. *Neurol Med Chir (Tokyo)* 2003;43(5):246-9
248. Rieger P, Huber G. Fenestration and duplicate origin of the left vertebral artery in angiography. Report of three cases. *Neuroradiology* 1983;25(1):45-50
249. Tran-Dinh HD, Soo YS, Jayasinghe LS. Duplication of the vertebro-basilar system. *Australas Radiol* 1991;35(3):220-4
250. De Caro R, Serafini MT, Galli S, Parenti A, Guidolin D, Munari PF. Anatomy of segmental duplication in the human basilar artery. Possible site of aneurysm formation. *Clin Neuropathol* 1995;14(6):303-9
251. Sanders WP, Sorek PA, Mehta BA. Fenestration of intracranial arteries with special attention to associated aneurysms and other anomalies. *AJNR Am J Neuroradiol* 1993;14(3):675-80
252. Huber P. *Cerebral Angiography*. 2nd ed. New York, NY: Thieme; 1982
253. Osborn AG. Craniofacial venous plexuses: Angiographic study. *AJR Am J Roentgenol* 1981;136(1):139-43
254. Braun JP, Tourmade A. Venous drainage in the craniocervical region. *Neuroradiology* 1977;13(3):155-8
255. Gray H. *Gray's Anatomy*. 1901 Edition ed. Philadelphia, PA: Running Press; 1901
256. Andrews BT, Dujovny M, Mirchandani HG, Ausman JI. Microsurgical anatomy of the venous drainage into the superior sagittal sinus. *Neurosurgery* 1989;24(4):514-20
257. Curé JK, Van Tassel P, Smith MT. Normal and variant anatomy of the dural venous sinuses. *Semin Ultrasound CT MR* 1994;15(6):499-519
258. Jaeger R. Observations on resection of the superior longitudinal sinus at and posterior to the rolandic venous inflow. *J Neurosurg* 1951;8(1):103-9
259. Hasegawa M, Yamashita J, Yamashita T. Anatomical variations of the straight sinus on magnetic resonance imaging in the infratentorial supracerebellar approach to pineal region tumors. *Surg Neurol* 1991;36(5):354-9

260. Browder J, Kaplan HA, Krieger AJ. Anatomical features of the straight sinus and its tributaries. *J Neurosurg* 1976;44(1):55-61
261. Das AC, Hasan M. The occipital sinus. *J Neurosurg* 1970;33(3):307-11
262. Zouaoui A, Hidden G. Cerebral venous sinuses: Anatomical variants or thrombosis? *Acta Anat (Basel)* 1988;133(4):318-24
263. Acar F, Naderi S, Guvencer M, Ture U, Arda MN. Herophilus of Chalcedon: A pioneer in neuroscience. *Neurosurgery* 2005;56(4):861-7; discussion 7
264. Tubbs RS. Herophilus of Chalcedon: A pioneer in neuroscience. *Neurosurgery* 2006;58(3):E590; discussion E
265. Gebarski SS, Gebarski KS. Inferior petrosal sinus: Imaging-anatomic correlation. *Radiology* 1995;194(1):239-47
266. Hacker H. Superficial supratentorial veins and dural sinuses. In: Newton TH, Potts DG, eds. *Radiology of the Skull and Brain: Veins*. St. Louis, MO: Mosby; 1974:1851-902
267. Galligioni F, Bernardi R, Pellone M, Iraci G. The superficial sylvian vein in normal and pathologic cerebral angiography. *Am J Roentgenol Radium Ther Nucl Med* 1969;107(3):565-78
268. Sener RN. The occipitotemporal vein: A cadaver, MRI and CT study. *Neuroradiology* 1994;36(2):117-20
269. Di Chiro G. Angiographic patterns of cerebral convexity veins and superficial dural sinuses. *Am J Roentgenol Radium Ther Nucl Med* 1962;87:308-21
270. Ture U, Yasargil MG, Al-Mefty O. The transcallosal-transforaminal approach to the third ventricle with regard to the venous variations in this region. *J Neurosurg* 1997;87(5):706-15
271. Ono M, Rhoton AL, Jr., Peace D, Rodriguez RJ. Microsurgical anatomy of the deep venous system of the brain. *Neurosurgery* 1984;15(5):621-57
272. Garner TB, Del Curling O, Jr., Kelly DL, Jr., Laster DW. The natural history of intracranial venous angiomas. *J Neurosurg* 1991;75(5):715-22
273. Wilms G, Bleus E, Demaerel P, et al. Simultaneous occurrence of developmental venous anomalies and cavernous angiomas. *AJNR Am J Neuroradiol* 1994;15(7):1247-54; discussion 55-7
274. Abe T, Singer RJ, Marks MP, Norbash AM, Crowley RS, Steinberg GK. Coexistence of occult vascular malformations and developmental venous anomalies in the central nervous system: MR evaluation. *AJNR Am J Neuroradiol* 1998;19(1):51-7
275. Mullan S, Mojtahedi S, Johnson DL, Macdonald RL. Embryological basis of some aspects of cerebral vascular fistulas and malformations. *J Neurosurg* 1996;85(1):1-8
276. Raybaud CA, Strother CM, Hald JK. Aneurysms of the vein of Galen: Embryonic considerations and anatomical features relating to the pathogenesis of the malformation. *Neuroradiology* 1989;31(2):109-28
277. Gailloud P, O'Riordan D P, Burger I, Lehmann CU. Confirmation of communication between deep venous drainage and the vein of Galen after treatment of a vein of Galen aneurysmal malformation in an infant presenting with severe pulmonary hypertension. *AJNR Am J Neuroradiol* 2006;27(2):317-20
278. Siclari F, Burger IM, Fasel JH, Gailloud P. Developmental anatomy of the distal vertebral artery in relationship to variants of the posterior and lateral spinal arterial systems. *AJNR Am J Neuroradiol* 2007;28(6):1185-90
279. Chakravorty BG. Arterial supply of the cervical spinal cord (with special reference to the radicular arteries). *Anat Rec* 1971;170(3):311-29
280. Schalow G. Feeder arteries, longitudinal arterial trunks and arterial anastomoses of the lower human spinal cord. *Zentralbl Neurochir* 1990;51(4):181-4
281. Tveten L. Spinal cord vascularity. III. The spinal cord arteries in man. *Acta Radiol Diagn (Stockh)* 1976;17(3):257-73
282. Lasjaunias PL, BA. *Surgical Neuroangiography: Functional Vascular Anatomy of Brain, Spinal Cord and Spine*. New York, NY: Springer; 1991
283. Rodriguez-Baeza A, Muset-Lara A, Rodriguez-Pazos M, Domenech-Mateu JM. The arterial supply of the human spinal cord: A new approach to the arteria radicularis magna of Adamkiewicz. *Acta Neurochir (Wien)* 1991;109(1-2):57-62
284. Biglioli P, Roberto M, Cannata A, et al. Upper and lower spinal cord blood supply: The continuity of the anterior spinal artery and the relevance of the lumbar arteries. *J Thorac Cardiovasc Surg* 2004;127(4):1188-92
285. Lo D, Vallee JN, Spelle L, et al. Unusual origin of the artery of Adamkiewicz from the fourth lumbar artery. *Neuroradiology* 2002;44(2):153-7
286. Adamkiewicz A. Die Blutgefäße des menschlichen Rückenmarkes. I. Theil. Die Gefäße der Rückenmarksubstanz. *Sitzungsberichte der Kaiserlichen Akademie der Wissenschaften, mathematisch-naturwissenschaftliche Classe* 1881;84:469-502
287. Adamkiewicz A. Die Blutgefäße des menschlichen Rückenmarkes. II. Theil. Die Gefäße der Rückenmarks-Oberfläche. *Sitzungsberichte der Kaiserlichen Akademie der Wissenschaften, mathematisch-naturwissenschaftliche Classe* 1882;85:101-30

2. Diagnostic Cerebral Angiography

2.1. Introduction

Catheter angiography is still considered the gold standard for imaging cerebral vasculature. Diagnostic angiography is also typically done as the first step during neurointerventional procedures. Mastery of diagnostic angiography is a prerequisite for neurointerventional training. Training standards formulated by the American Society of Interventional and Therapeutic Neuroradiology (ASITN), the Joint Section of Cerebrovascular Neurosurgery, and the American Society of Neuroradiology (ASNR) recommend the performance of at least 100 diagnostic angiograms before entering neuroendovascular training.¹ The authors' preference, however, is for a neurointerventionalist-in-training to perform at least 250 diagnostic cerebral angiograms prior to becoming the lead operator in neurointerventional cases.

2.2. Indications

1. Diagnosis of primary neurovascular disease (e.g., intracranial aneurysms, arteriovenous malformations, dural arteriovenous fistulas, atherosclerotic stenosis, vasculopathy, cerebral vasospasm, acute ischemic stroke)
2. Planning for neurointerventional procedures
3. Intra-operative assistance with aneurysm surgery
4. Follow-up imaging after treatment (e.g., after aneurysm coiling or clipping, treatment of arteriovenous fistulas)

2.3. A brief history of cerebral angiography

The first report of X-ray angiography of blood vessels was in 1896. In Vienna, E. Haschek and O.T. Lindenthal obtained x-rays of blood vessels by injecting a mixture of petroleum, quicklime, and mercuric sulfide into the hand of a cadaver.² António de Egas Moniz, a Portuguese neurologist, is credited with the introduction of cerebral angiography. Moniz was interested in developing "arterial encephalography" as a means to localize brain tumors. He obtained cerebral angiograms in cadavers using a solution of strontium bromide and sodium iodide. These early studies demonstrated universal branching patterns among the intracranial arteries, which were contrary to popular theories based on cadaver dissection. After studies in dogs and monkeys, Moniz and his colleague Almeida Lima, a neurosurgeon, performed the first angiogram on a living human patient in 1927, in a 53-year-old man with a history of seizures and hemiparesis.³ The cervical internal carotid artery was surgically exposed and temporarily occluded with a ligature while a total of 5 mL of a solution of 25% sodium iodide was injected into the vessel. Flow was restored in the artery while simultaneously obtaining an X-ray. Although no complications were noted during the procedure and the X-rays showed good filling of the intracranial circulation, the patient died two days later in status epilepticus.⁴ Moniz went on to obtain successful angiograms in other patients with epilepsy, brain tumors, and postencephalitic Parkinsonism.^{5, 6} The first cerebral venogram was accomplished in 1931 when an inadvertent delay in photographing an angiographic plate led to an image of the venous angiographic phase, which Moniz termed a "cerebral phlebogram."

The technique became fully developed in the 1930s. By then, cerebral angiography involved direct percutaneous puncture of the carotid artery and injection of iodinated

organic contrast media.⁷ Despite a flurry of publications about cerebral angiography over the ensuing decade, many by Moniz himself, ventriculography and encephalography remained more popular as methods to image intracranial pathology.⁸ Moniz was awarded the Nobel Prize in Physiology and Medicine in 1949 for his work on frontal leukotomy for psychiatric disorders, which, unlike cerebral angiography, gained early and widespread acceptance by the medical community.⁹ The popularity of cerebral angiography did rise significantly by the 1950s, becoming the premier method to image the intracranial space. The neurosurgeon Gazi Yasargil performed some 10,000 angiograms between 1953 and 1964.⁸

Direct percutaneous puncture of the cervical carotid artery remained the primary technique for cerebral angiography in the 1950s and 1960s. Direct puncture of the vertebral artery was reported in 1956;¹⁰ the posterior circulation was also imaged by puncture of the right brachial artery and retrograde injection of the contrast into the vertebral artery.^{11, 12} The movie *The Exorcist* (1973) featured a graphic (and realistic) depiction of a direct carotid stick. The transition from direct puncture of the cervical vessels to transfemoral artery arteriography began in the late 1960s¹³ and became widespread in the 1970s.

The introduction of computed tomography (CT) in the early 1970s sharply reduced the demand for diagnostic angiography, although the field continued to develop because of the advent of interventional cardiology and other interventional fields. Metrizamide, introduced in the 1970s, was the first nonionic isosmolar iodinated contrast medium. Nonionic contrast media improved the safety and comfort of angiographic procedures considerably.

Digital subtraction angiography (DSA) was introduced in the 1980s as a method for intravenous injection of contrast for imaging the arterial system, as the contrast in the arterial system following intravenous injection was too dilute to be imaged with standard X-rays. Over the ensuing decade, the spatial resolution of DSA imaging improved to the extent that it began to rival the resolution of unsubtracted X-ray images. Further technical refinements in recent years include rotational angiography, 3D angiography, and flat panel detectors for imaging.

2.4. Complications of diagnostic cerebral angiography

Informed consent prior to an angiogram should include an estimate of the risk of complications.

2.4.1. Neurological complications

Neurological complications in cerebral angiography are most commonly cerebral ischemic events that occur as a result of thromboembolism or air emboli from catheters and wires. Other causes include disruption of atherosclerotic plaques and vessel dissection. Less common neurological complications include transient cortical blindness^{14 15} and amnesia.¹⁶

In a prospective analysis of 2,899 diagnostic cerebral angiograms, the largest recent series published to date, Willinsky and colleagues reported an overall rate of neurological complications of 1.3%.¹⁷ Of these, 0.9% were transient or reversible, and 0.5% were permanent. The Asymptomatic Carotid Atherosclerosis Study (ACAS) reported an often quoted neurological complication rate of 1.2% with angiography.¹⁸

The risk of complications appears to be related to the underlying disease process. Patients with atherosclerotic carotid disease have been reported to be at elevated risk of neurological complications with cerebral angiography.¹⁹ Other risk factors for neurological complications include a recent cerebral ischemic event,^{20, 21} advanced age,^{17, 19} a long angiography procedure time,^{19, 22, 23} and a diagnosis of hypertension,²³ diabetes²³ or renal insufficiency.²⁴

The risk of neurological complications in patients with subarachnoid hemorrhage, intracranial aneurysms, and arteriovenous malformations was found to be relatively low in a meta-analysis of prospective studies of angiography.²¹ For these patients, the overall rate of neurological complications was 0.8%, and the rate of permanent neurological complications was 0.07%. The Joint Standards of Practice Task Force of the Society of Interventional Radiology, the American Society of Interventional and

Table 2.1 Quality improvement guidelines for adult diagnostic neuroangiography

		Suggested complication – specific threshold (%)
Neurological complications	Reversible neurologic deficit	2.5
	Permanent neurologic deficit	1
Non-neurologic Complications	Renal failure	0.2
	Arterial occlusion requiring surgical thrombectomy or thrombolysis	0.2
	Arteriovenous fistula/pseudoaneurysm	0.2
	Hematoma requiring transfusion or surgical evacuation	0.5
All major complications		2

Quality improvement guidelines for adult diagnostic neuroangiography: Cooperative study between ASITN, ASNR, and SIR²⁵

Therapeutic Neuroradiology, and the American Society of Neuroradiology reviewed the complications reported in clinical series and produced guidelines for expected complication rates in neuroangiography (Table 2.1).²⁵ The figures in these guidelines can be quoted to patients during informed consent.

2.4.2. Nonneurological complications

Nonneurological complications of cerebral angiography via the femoral artery include groin and retroperitoneal hematoma, allergic reactions, femoral artery pseudoaneurysm, thromboembolism of the lower extremity, nephropathy, and pulmonary embolism.²⁶ In a review of 2,899 cerebral angiograms, hematomas occurred in 0.4% of procedures, allergic cutaneous reactions occurred in 0.1%, and a pseudoaneurysm occurred after one (0.03%) procedure.¹⁷

2.5. Selective cerebral angiography: basic concepts

2.5.1. Preprocedure evaluation

1. A brief neurological exam must be conducted to establish a baseline, should a neurologic change occur during or after the procedure.
2. The patient should be asked if he or she has had a history of iodinated contrast reactions.
3. The femoral pulse, as well as the dorsalis pedis and posterior tibialis pulses, should be examined.
4. Blood work, including a serum creatinine level and coagulation parameters, should be reviewed.

2.5.2. Pre-angiogram orders

1. NPO except medications for 6 h prior to the procedure.
2. Place 1 peripheral IV (2 if an intervention is anticipated)
3. Place foley catheter (only if an intervention is anticipated)

2.5.3. Contrast agents

Nonionic contrast agents are safer and less allergenic than ionic preparations.^{27–30} Iohexol (Omnipaque[®], GE Healthcare, Princeton, NJ), a low osmolality, nonionic contrast agent, is relatively inexpensive and probably the most commonly used agent in cerebral angiography.

1. Diagnostic angiogram: Omnipaque[®], 300 mg I mL⁻¹
2. Neurointerventional procedure: Omnipaque[®], 240 mg I mL⁻¹

Patients with normal renal function can tolerate as much as 400–800 mL of Omnipaque[®], 300 mg I mL⁻¹ without adverse effects.³¹

2.5.4. Femoral artery sheath (vs. no sheath)

Trans-femoral angiography can be done with or without a sheath.

Sheath:

1. Allows for the rapid exchange of catheters and less potential for trauma to the arteriotomy site.
2. Shown in a randomized trial to lessen the frequency of intraprocedural bleeding at the puncture site, and to ease catheter manipulation.³²
3. Short sheath (10–13-cm arterial sheath) is used most commonly
4. Longer sheath (25 cm) is useful when iliofemoral artery tortuosity or atherosclerosis might impair catheter navigation.
5. Technique: A 5-F sheath (Check-Flo[®] Performer[®] Introducer set; Cook, Bloomington, IN) is slowly and continuously perfused with heparinized saline (2,000 U heparin per liter of saline) under arterial pressure.
6. Sheaths come in sizes 4F up to 10F or larger. The size refers to the inner diameter. The outer diameter is 1.5–2.0F larger than the stated size.

No sheath:

1. Slightly smaller arteriotomy and permitting earlier ambulation.
2. Use a 4-F, 5-F, or 3.3-F catheter.³³
3. Technique: After the Potts needle enters the femoral artery, a 145 cm 0.035 in. J-tipped wire (for most 4-F catheters) or a 145 cm 0.038 in. J-tipped wire (for most 5-F catheters) is introduced instead of a short J-wire. The Potts needle is then exchanged for an appropriately sized dilator, which is then exchanged for the diagnostic catheter.
4. Note: If a 4-F catheter is going to be used without a sheath, use a 19 gauge arterial access needle or a micropuncture set, because a standard 18 gauge Potts needle creates an arteriotomy larger than the catheter, resulting in bleeding around the catheter.

2.5.5. Sedation/analgesia

1. Midazolam (Versed[®]) 1–2 mg IV for sedation; lasts approximately 2 h
2. Fentanyl (Sublimaze[®]) 25–50 mcg IV for analgesia; lasts 20–30 min

The use of sedation should be minimized, as over-sedation makes it hard to detect subtle neurological changes during the procedure. Paradoxical agitation has been reported in up to 10.2% of patients,³⁴ particularly elderly patients and patients with a history of alcohol abuse or psychological problems.³⁵ Flumazenil (Romazicon[®]) 0.2–0.3 mg IV can reverse this effect.³⁶

2.5.6. Suggested wires and catheters for diagnostic cerebral angiography

2.5.6.1. Hydrophilic wires

- The 0.035 in. angled Glidewire® (Terumo Medical, Somerset, NJ) is soft, flexible, and steerable.
- The 0.038 in. angled Glidewire® (Terumo Medical, Somerset, NJ) is slightly stiffer than the 0.035 in., making it helpful when added wire support is needed.
- Extra-stiff versions of these wires are available for even more support, but they should be used with extreme caution because of the tendency of the tip to dissect vessels.

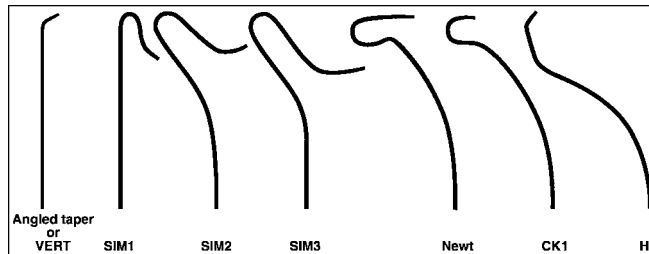


Fig. 2.1 Recommended diagnostic catheters.

Catheter	Use
5-F Angled Taper	Good all-purpose diagnostic catheter
4- or 5-F Vertebral	Good all-purpose diagnostic catheter, slightly stiffer than the Angled Taper but similar in shape
4 or 5F Simmons 1	Spinal angiography
4 or 5F Simmons 2 or 3	Left common carotid artery; bovine configuration; tortuous aortic arch; patient's age >50
5F CK-1 (aka HN-5)	Left common carotid or right vertebral artery
5F H1 (aka Headhunter)	Right subclavian artery; right vertebral artery
4 or 5F Newton	Tortuous anatomy, patients >65

Measurement systems

- *Needles*: Gauge, which is a measurement system too obscure for the human mind to grasp. The larger the gauge, the smaller the needle
- *Catheters*: French (F), defined as the outer diameter of a catheter measured as a multiple of thirds of a millimeter (French number/3 = outer diameter in mm)
- *Wires*: Measured in thousandths of an inch. (a 0.035 wire is 0.035 in. thick)

2.6. Catheter navigation

Diagnostic catheters should usually be advanced over a hydrophilic wire. The wire keeps the catheter tip from rubbing against the wall of the vessel and causing a dissection. When advancing the wire and catheter toward the aortic arch from

the femoral artery, the tip of the wire should be followed by direct fluoroscopic visualization. The catheter/wire assembly should never be advanced with <8–10 cm of wire extending from the tip, as a short length of leading wire can act as a spear and cause injury to the intima. A catheter/wire assembly with only a few cm of wire sticking out can resemble a Roman short sword (Fig. 2.2).

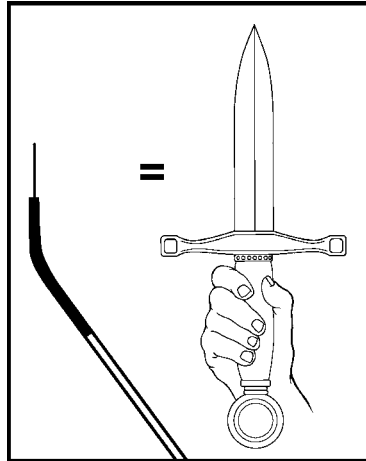


Fig. 2.2 Roman short sword.

2.7. Roadmapping

Roadmapping should be used when engaging the vertebral arteries, and the internal and external carotid arteries. Roadmapping is essential during intracranial navigation. In some angiography suites, a “false roadmap” can be created using a regular digital subtraction angiogram; a frame from an angiographic run is selected, then inverted (i.e., vessels are turned white against a black background). This technique conserves contrast and reduces radiation exposure.

2.8. Double flushing

Double flushing consists of aspiration of the contents of the catheter with one 10-mL syringe of heparinized saline, followed by partial aspiration and irrigation with a second syringe of saline. This maneuver clears clots and air bubbles from the catheter, and should be done every time a wire is removed from the catheter, prior to the injection of contrast. Meticulous attention to detail is required to prevent blood from sitting in the catheter lumen, where it can coagulate into potential emboli. Any air bubbles in the system can also occlude small vessels if injected intravascularly.

2.9. Continuous saline infusion

A three-way stopcock or manifold can be used to provide a heparinized saline drip through the catheter. This continuous drip is particularly useful if there is any delay between injections of contrast, because it keeps the catheter lumen free of blood products. Careful double flushing is still required if a wire is inserted and removed or if any blood is present in the lumen. Use of stopcocks and continuous infusion is mandatory for any therapeutic intervention.

2.10. Hand injection

A 10-mL syringe containing contrast should be attached to the catheter, and the syringe should be snapped with the middle finger several times to release bubbles stuck to the inside surface. The syringe should be held in a vertical position, with the plunger directed upward, to allow bubbles to rise away from the catheter (Fig. 2.3). For larger vessels, like the common carotid artery, the plunger on the syringe can be depressed with the palm of the hand in order to generate enough force; for smaller vessels, like the vertebral arteries, thumb-depression of the plunger is sufficient. An adequate angiographic run can be done with a single swift injection of 4–6 mL of contrast (70%) mixed with saline (30%). The patient should be instructed to stop breathing (“Don’t move, don’t breath, don’t swallow”) for several seconds during the angiogram, then told to start breathing again.

A Poetic Interlude

Bubbles

I love ‘em in my lager.

I love ‘em in my stout.

But when they get inside my head

I want to get them out!

I hate them in carotids.

I hate them in the “verts.”

They end up doing something bad.

Oh yes, it really hurts!

The small ones make me stupid.

The big ones make me dead.

‘Cause when they get inside me

They dance around my head!

The little doctors search and search

And shake out all they find.

The ones they missed

(It makes me pissed!)

Will make me lose my mind!

They find them in my saline.

They find them everywhere!

And superficial temporal ones

Will make me lose my hair!

Prevention of cerebral air emboli

- Use meticulous technique for flushing and contrast injections (see above).
- Whenever possible, flush the catheter in the descending aorta to keep bubbles away from the cerebral circulation.
- After filling a syringe, allowing it to sit for a few minutes before injection will allow bubbles to come out of suspension and become visible.³⁷
- A slower flush is less likely to cause bubbles than a rapid flush.³⁷
- 1.2- μ m Intrapur[®] filter (B. Braun Medical, Bethlehem, PA) in the tubing for contrast or saline injections can reduce the risk of air emboli.³⁸

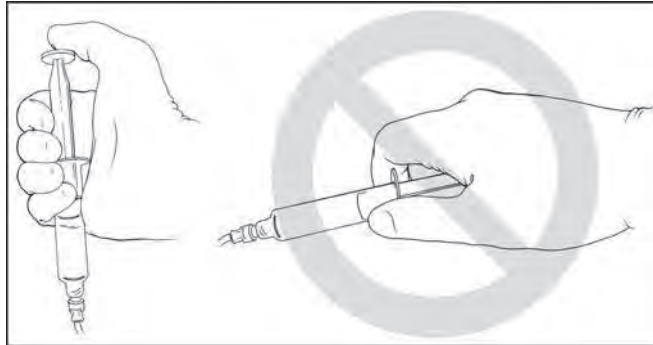


Fig. 2.3 Syringe holding method for hand injections. Correct method (*left*): The syringe is grasped in the palm of the hand when it is attached to the catheter; this position places the plunger in an upright position to allow bubbles to rise away from the attachment to the catheter. Incorrect method (*right*): The syringe is held in a horizontal position, like a weapon. Bubbles can go any which way.

Management of cerebral air emboli

Prevention is best, but if air emboli are suspected, urgent treatment is required to prevent stroke caused by occlusion of flow in vessels due to the surface tension produced by the interface between air and blood.

- If the gas embolus is large enough to be detected fluoroscopically, and the vessel is easily accessible, a microcatheter may be used to aspirate the gas embolus and flush the vessel with heparinized saline to break up the remaining bubbles.
- Quick and readily available (though unproven) methods include the use of transcranial Doppler (to agitate and break up bubbles), heparinization (to prevent clot from forming in vessels stagnating from the air), and administration of oxygen and induction of hypertension (as in vasospasm therapy).
- If available, hyperbaric oxygen chambers have been shown (anecdotally and in small series) to result in good outcomes.³⁹⁻⁴² One series suggests that even after considerable delay in initiating therapy, hyperbaric oxygen helps.⁴³ However, a larger series showed 67% good outcome when hyperbaric treatment was started within 6 h after the onset of symptoms, vs. only 35% good outcomes when treatment began later.⁴⁴
- Induction of retrograde cerebral flow by infusing arterial blood under pressure in the jugular vein has been shown to limit ischemic damage to the brain.⁴⁵
- When in doubt, a variety of methods can be used simultaneously, including hyperbaric oxygen *plus* retrograde cerebral flow *plus* induction of barbiturate coma to attempt to protect the brain.⁴⁶
- The most important thing is to recognize that air emboli have occurred and then use whatever treatment modalities that are available.

2.11. Mechanical injection

A power contrast injector is necessary for aortic arch angiograms, and some operators prefer to use an injector routinely for other vessels as well. Mechanical injection can lower radiation exposure to the operator's hands and body.⁴⁷ The pressure (pounds per square inch, psi) and flow rate during the injection should not exceed the rated pressure or flow rate of the catheter. Likewise, if a stopcock is used, the psi during injection should not exceed the rated pressure and flow rate. Common power injector settings for selective catheter digital subtraction diagnostic angiograms using a

5-F catheter are listed in [Table 2.2](#). The term “rate rise” refers to a setting on the mechanical injector that causes it to gradually increase the rate of contrast flow during the injection, to prevent the catheter tip from being kicked out of the vessel it is in. Rate rise is defined as the time required during the injection to reach the maximum flow rate. If the vessel is smaller than average, occluded, or if the catheter is in an unstable position within the vessel, a rate rise of 0.3–0.5 s should be used. Power injector settings are different (longer) when a 3D angiogram is done; typical settings for 3D images are 3 mL s⁻¹, total of 6 mL or 4 mL s⁻¹, total of 12 mL.

Table 2.2 Standard power injector settings

Vessel	Power injector settings
Aortic arch	20 mL s ⁻¹ ; total of 25 mL
Common carotid artery	8 mL s ⁻¹ ; total of 12 mL
Subclavian artery	6 mL s ⁻¹ ; total of 15 mL
Internal carotid artery	6 mL s ⁻¹ ; total of 8 mL
External carotid artery	3 mL s ⁻¹ ; total of 6 mL
Vertebral artery	6 mL s ⁻¹ ; total of 8 mL

For digital subtraction angiography using a 5-F catheter

2.12. Vessel selection

A cerebral angiogram should begin with the vessel of interest first, so that the most important vessels can be imaged in case problems with the equipment or the patient prevents completion of the entire angiogram. Following catheterization of the vessel of interest, it is usually easiest to navigate from right to left (i.e., the right vertebral artery, followed by the right common carotid artery, etc.).

2.12.1. Angiographic Images and standard views

Biplane angiography is the standard of care for cerebral angiography. It allows for orthogonal images to be simultaneously obtained with a single contrast injection, limiting the time and amount of contrast needed to adequately visualize the cerebral vasculature. Monoplanar cerebral angiography is acceptable only when biplane equipment is not available; the use of monoplane imaging is limited by its inability to perform automatic optical calibration and to image from orthogonal views simultaneously.

1. When viewing the angiographic images, the contrast and brightness of the image should be adjusted so that vessels are semitransparent; this can allow visualization of aneurysms, branches, or filling defects (e.g., intraluminal thrombus) which may otherwise not be visible.
2. Other imaging features worthy of attention during the performance of a cerebral angiogram:
 - (a) Vessel contour and size (“angioarchitecture”)
 - (b) Contrast flow patterns
 - (c) Presence or absence of a vascular blush
 - (d) Venous phase (i.e., do not forget to examine the venous phase)
 - (e) Bony anatomy

Standard postero-anterior (PA) projections are illustrated in [Fig. 2.4](#). The standard PA view places the petrous ridges in the lower 1/3 of the orbits. The Caldwell projection aligns the petrous ridges with the bottoms of the orbits to provide an optimal view of orbital and supratentorial structures unobstructed by the petrous ridges. The Towne’s view aligns the petrous ridges with the superior rim of the orbits and is the standard PA view for imaging the posterior fossa. The Water’s view is inclined 45° relative to the skull base and positions the petrous ridges some distance below the orbits; this is a good view for imaging the maxillary sinuses.

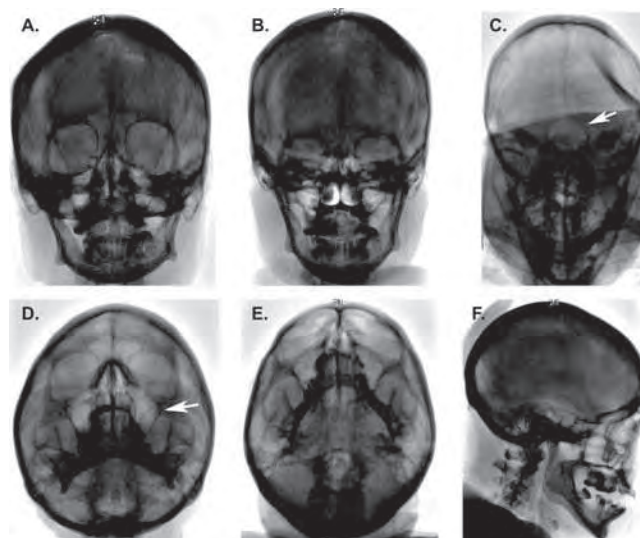


Fig. 2.4 Standard PA and lateral projections

- a. PA (postero-anterior). The petrous bones are at the lower edge of the orbits.
- b. Caldwell. The petrous bones are about one third of the way up the orbits.
- c. Towne. The foramen magnum (arrow) can be seen through the calvarium.
- d. Water. The view is from below; the maxillary sinuses (arrow) can be seen clearly.
- e. Submentovertex. The view is from way below; the vertex of the skull is framed by the mandible.
- f. Lateral. On a straight lateral view, the floors of the left and right frontal fossas directly overlapping.

The Houghton projection is a lateral view and is helpful for imaging the carotid siphon and the middle cerebral bifurcation. The patient's head is inclined away from the side of the injected carotid artery;⁴⁸ this view opens up the carotid siphon.

Pearl

Mnemonic for remembering the relative positions of the standard PA projections: The *Water(s)* runs beneath the *Town(e)*. *Caldwell* is in between.

2.12.2. Frame rates for digital subtraction angiography

Most cerebral angiography can be done with 3–5 frames per second (fps). Higher rates (e.g., 8–20 fps) are useful for imaging arteriovenous malformations and other high-flow lesions. Usually, a variable frame rate may be used to limit radiation dose, since a higher frame rate (3 per second) is needed in the arterial phase, whereas a lower rate (0.5–1 per second) can be used in the venous phase. For standard cerebral

Table 2.3 Standard views

Target	Optimal views	Additional views/ comments
Carotid bifurcation	PA	Ipsilateral oblique
	Lateral	
Anterior intracranial circulation	Caldwell	Transorbital oblique
	Lateral	
ICA cavernous segment	Caldwell	Haughton
	Lateral	
ICA ophthalmic segment	Caldwell	Transorbital oblique
	Lateral	
Posterior communicating artery aneurysms	Haughton	Lateral
	Transorbital oblique	
ICA bifurcation	Transorbital oblique	
Anterior communicating artery aneurysms	Transorbital oblique	
Middle cerebral artery aneurysms	Transorbital oblique	
	Submentovertex	
Middle cerebral artery candelabra	Lateral with Haughton	
	Waters with oblique	
Vertebral artery origin	Towne	The vertebral artery arises from the posterior aspect of the subclavian artery
Posterior circulation	Water	Ipsilateral oblique
	Lateral	
Basilar artery	Water	Ipsilateral oblique
	Lateral	Water will "elongate" the basilar artery trunk
PCA, SCA, AICA, PICA	Towne	Ipsilateral oblique
	Lateral	
Basilar apex aneurysms	Water	Ipsilateral oblique
	Lateral	

Angiographic positions for common anatomical targets. *ICA* internal carotid artery, *PCA* posterior cerebral artery, *SCA* superior cerebellar artery, *AICA* anterior inferior cerebellar artery, *PICA* posterior inferior cerebellar artery

arteriography, a 10–12 s imaging sequence allows for visualization of arterial, capillary, and venous phases.

2.12.3. Calibration and measurement

Biplanar angiography units are capable of auto-calibration by analysis of simultaneous orthogonal images. Monoplanar angiography requires placement of a marker on or in the patient. A United States dime is 18 mm in diameter and can be taped to the patient's face or head; however a marker on the surface of the patient's body can

be inaccurate in the measurement of internal structures because of magnification. Magnification error can lead to errors in linear measurement of up to 13%.⁴⁹ Markers on intravascular catheters and wires, placed close to the angiographic target, are more accurate. The ATW™ Marker Wire (Cordis, Miami Lakes, FL) has radio-opaque markers that are 1-mm wide and spaced 10 mm apart. “Two-tipped” microcatheters for detachable coil deployment have markers that are spaced 3 cm apart. To maximize accuracy, the calibration marker and the structure being measured should be as close to the center of the image as possible to minimize the effect of X-ray beam divergence.

2.13. Procedures

2.13.1. Femoral artery puncture

1. The groin area is prepped and draped.
2. The femoral pulse is palpated at the inguinal crease, and local anesthesia (2% lidocaine) is infiltrated, both by raising a wheal and injecting deeply toward the artery.
3. Five-millimeter incision is made parallel to the inguinal crease with an 11-blade scalpel.
4. A Potts needle is advanced with the bevel facing upward. The needle is advanced at a 45° angle to the skin, pointing toward the patient’s opposite shoulder.
5. A single wall puncture is useful if heparin or antiplatelet agents are used. It can be done by looking for blood return from the hollow stylet of the Potts needle. The needle should be advanced one to two millimeters after the first blood return since the stylet protrudes that far beyond the tip of the needle.
6. A two wall puncture is obtained by advancing the needle through and through both vessel walls, then removing the stylet, and slowly withdrawing the needle until pulsatile blood return is obtained.
7. When bright red, pulsatile arterial blood is encountered, a J-wire is gently advanced through the needle for 8–10 cm.
8. The needle is then exchanged for a 5-F sheath, which is secured with a silk stitch.

Pearls

If the artery is difficult to locate, try the following tricks:

- When the Potts needle is inserted, let go of the needle. If the needle pulsates, the artery is usually located to the side that the needle is pulsating toward.
- Fluoroscopic bony landmarks. On PA fluoroscopy, the femoral artery is located 1 cm medial to the center of the femoral head (Fig. 2.5).
- Use a micropuncture set (see instructions below). An atherosclerotic femoral artery can be heavily calcified and deflect larger needles; a smaller needle can be helpful.
- Use a needle with a doppler ultrasound stylet (Smart-needle®, Peripheral Systems Group, Mountain View, CA) (20 gauge or smaller) to allow puncture of a non-palpable vessel.
- Try the opposite groin or the upper extremity approach.
- Puncturing vascular grafts can be difficult due to extensive scar tissue. This may require use of a stiff Amplatz guidewire, use of dilators one size larger than the inserted catheter or sheath, and certain soft catheters should not be used because they may fracture. In general, it is best to use a sheath in Gortex grafts.

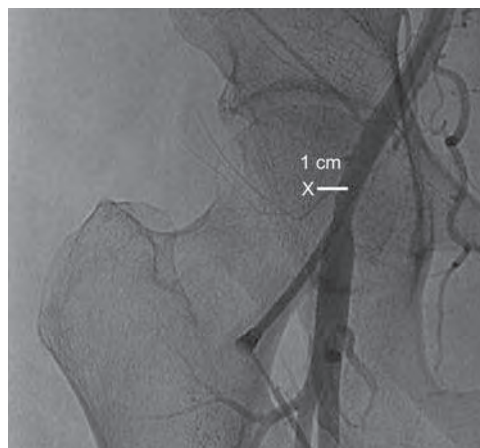

Fig. 2.5 Fluoroscopic landmarks for femoral artery puncture. The femoral artery is located approximately 1 cm medial to the center of the femoral head. The "X" indicates the center of the femoral head.

Micropuncture technique

1. Obtain micropuncture set
2. Insert the 21 gauge needle in same fashion as a Potts needle.
3. Insert 0.018 in. microwire.
4. Exchange 21 gauge needle for the dilator.
5. Exchange dilator for the sheath.

2.13.2. Aortic arch imaging

1. A 4-F or 5-F pigtail catheter is guided over a hydrophilic wire into the ascending part of the aortic arch.
2. The image intensifier (II) is placed on low magnification and rotated 30° to the left.
3. The patient's head is rotated to the left, so that his or her face is facing the II (this position will permit visualization of the cervical vessels).
4. A power injector is used to administer contrast.
5. Standard left anterior oblique (LAO) view can be supplemented with a lateral view by rotating the II 30° to the right.

2.13.3. Carotid artery catheterization

1. An angled diagnostic catheter is advanced over a hydrophilic wire over the aortic arch to a position proximal to the innominate artery.
2. The wire is then brought back into the catheter, and the catheter is gently pulled back, with the tip of the catheter facing superiorly, until the innominate artery is engaged. The wire is then advanced superiorly in the right common carotid artery, followed by the catheter.
3. To engage the left common carotid artery, the catheter is gently and slowly pulled out of the innominate artery, with the wire inside the catheter and the tip facing to the patient's left, until the catheter "clicks" into the left common carotid. The wire is then advanced superiorly, followed by the catheter.
4. For older patients (>50 years), and those with a bovine arch configuration, the Simmons II catheter is helpful for accessing the left common carotid.

5. If selective internal carotid artery catheterization is planned, angiography of the cervical carotid system should be done to check for internal carotid artery stenosis for any patient at risk of atherosclerosis. Catheterization of the internal carotid artery should be done under road-map guidance.
6. Turning the patient's head away from the carotid being catheterized may allow the wire and/or catheter to enter the vessel more easily.
7. Once the common carotid is catheterized, turning the head away from the side being catheterized facilitates internal carotid catheterization, and turning toward the ipsilateral side facilitates external carotid catheterization.
8. When the wire or catheter does not advance easily into the vessel of interest, asking the patient to cough may sometimes bounce the catheter into position.

2.13.4. Vertebral artery catheterization

1. An angled diagnostic catheter is advanced over a hydrophilic wire and placed in the subclavian artery. Intermittent "puffing" of contrast will allow identification of the vertebral artery origin.
2. A road map is made and the wire is passed into the vertebral artery until the tip of the wire is in the upper third of the cervical portion of the vessel. Placing the wire relatively high in the vertebral artery provides adequate purchase for advancement of the catheter, will help straighten out any kinks in the artery that may be present near the origin, and will also facilitate smooth passage of the catheter past the entrance of the of artery into the foramen transversarium at C6. The C6 foramen transversarium is where the vertebral artery makes a transition from free-floating to fixed, and is a region at risk for iatrogenic dissection if the catheter is allowed to scrape against the wall of the vessel.
3. Remember that the vertebral artery makes a right angle turn laterally at C2, so be careful not to injure the vessel at that point with the wire.
4. After removal of the wire, and double flushing, an angiogram should be done with the tip of the catheter in view, to check for dissection of the vessel during catheterization.
5. For patients at risk of atherosclerosis, an angiogram of the vertebral artery origin should be done prior to accessing the vessel to check for stenosis.
6. Uncommonly, the left vertebral artery arises directly from the aorta, which should be kept in mind when the origin of the vessel cannot be found on the left subclavian artery.
7. When kinks or loops in the vessel prevent catheterization, tilting the head away from the vertebral artery being catheterized can help.

Several options exist for patients in whom vessel tortuosity (usually of the innominate artery) makes catheterization of the vertebral artery difficult.

1. The roadmap should be done with an ipsilateral oblique Towne view; this will show the vertebral artery origin, and separate the vertebral artery from the common carotid artery.
2. A Headhunter catheter is well suited for navigation through a tortuous innominate artery.
3. Other catheters that can be helpful in negotiating a difficult right vertebral artery are the Vertebral catheter and the DAV catheter.
4. When catheterization of the vertebral artery is not possible because of tortuosity of the great vessels or atherosclerotic stenosis, an adequate angiogram can be done by inflating a blood pressure cuff on the ipsilateral upper extremity and injecting 100% contrast into the subclavian artery with a power injector. Be careful not to place the catheter with its tip in the thyrocervical or costocervical trunks. A large volume contrast injection in these small vessels can be painful, and can cause spinal cord injury in cases where large spinal cord feeders arise from these branches, or even directly from the subclavian artery. If the catheter tip cannot be placed in a stable position in the subclavian artery proximal to the origin of the vertebral artery, place the tip distal to the origin of the vertebral artery.
 - The power injector should be set to allow a good injection without kicking the catheter out.
 - 6 mL s⁻¹; total of 25 mL
 - Linear rate rise: 0.5 s

2.13.5. Reconstituting a Simmons 2 catheter

The Simmons 2 catheter is useful in the catheterization of the left common carotid artery, particularly when there is a bovine configuration, when the aortic arch is tortuous, and in patients aged >50. The catheter can be reconstituted in the left subclavian artery, the aortic arch, or the aortic bifurcation (Figs. 2.6 and 2.7). Reconstitution in the left subclavian or aortic bifurcation is preferred to the aortic arch, to minimize risk of dislodging atherosclerotic plaque material and subsequent embolization into the intracranial circulation.

Remember that the tip of the Simmons catheter advances into the vessel when you pull back on the catheter at the groin and pulls out of the vessel when the catheter is pushed forward at the groin. This effect is the reverse of the behavior of more simple-curved or angled catheters. The Simmons catheter can also be advanced antegrade over a wire, allowing for selective catheterization of the internal or external carotid arteries.

2.13.6. Femoral artery puncture site management

The “gold standard” for management of the arteriotomy after an angiogram is manual compression.

1. The sheath is removed while pressure is applied to the groin 1–2 cm superior to the skin incision.
2. Pressure is applied for 15 min, usually 5 min of occlusive pressure, followed by 10 min of lesser pressure.
 - (a) For patients on aspirin and/or clopidogrel, a longer time is required, usually 40 min. At the end of the time period, pressure on the groin is slowly released and a pressure dressing is applied.
3. At the end of the time period, pressure on the groin is slowly released and a pressure dressing is applied.
4. The Chito-seal™ pad (Abbott Laboratories, Abbott Park, IL) and the Syvek® NT Patch (Marine Polymer Technologies, Inc., Danvers, MA) are topical hemostatic agents that can be applied to the incision after sheath removal to accelerate hemostasis.
 - (a) In an animal model, the Syvek® Patch was found to control bleeding better than Chito-seal™.⁵⁰
 - (b) These topical agents cannot be expected to produce the same security of hemostasis as the closure devices described below, especially if the sheath size is greater than 5 French.

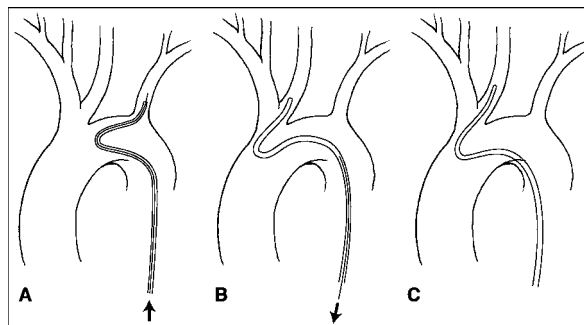


Fig. 2.6 Reconstituting a Simmons 2 Catheter in the left subclavian artery. The catheter is advanced over a hydrophilic wire into the left subclavian artery so that the tip is in the subclavian artery (A), and the primary bend in the catheter (the “elbow”) is in the aortic arch. The wire is then withdrawn until the tip is proximal to the elbow (B), and the catheter is then pushed forward, until the elbow moves into the proximal part of the aortic arch (C), and the tip of the catheter is out of the subclavian artery, directed backward toward the shaft of the catheter.

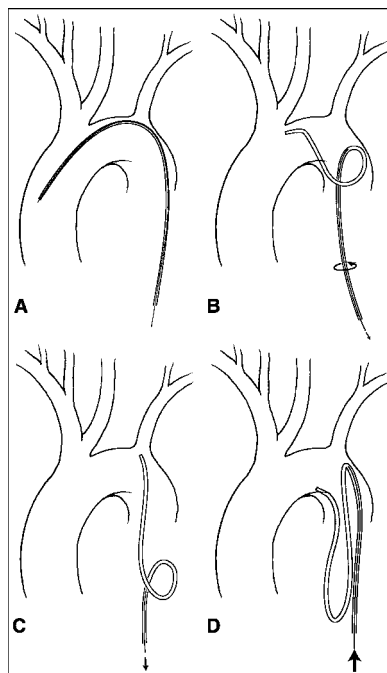


Fig. 2.7 Alternative method for reconstituting a Simmons 2 Catheter. The catheter is advanced over a hydrophilic wire so the tip of the catheter is in the ascending aorta (A). The wire is then withdrawn until the wire tip is proximal to the elbow, and the catheter is rotated clockwise as it is simultaneously withdrawn so that the loop is in the descending aorta (B–C). The wire is then advanced swiftly (D), to reconstitute the catheter.

5. The femoral artery clamp (Compressar[®], Instromedex, Hillsboro, OR) can be used instead of manual compression; the patient must be cautioned to remain still while the clamp is in place.
6. A balloon compression dressing (FemoStop[®]plus Femoral Compression System, Radi Medical Systems, Wilmington, MA) compresses the site with a balloon, but the balloon must be deflated after 1 h to prevent pressure injury to the skin. The dressing is then left in place and the balloon can be reinflated if oozing from the site occurs.
7. After compression, the patient should remain supine for 5 h, then be allowed to ambulate but remain under nursing observation for one more h prior to discharge.
8. Using topical hemostatics, the patient should remain flat in bed for 2 h, and can ambulate in 3 h.

2.13.7. Closure devices

Percutaneous femoral artery closure devices can allow the patient to ambulate sooner than with compression techniques, and can be helpful when the patient is on antiplatelet or anticoagulant medications. When a closure device is used, the patient should remain supine for 1 h. These devices are particularly useful in patients receiving anticoagulation or antiplatelet therapy. However, there is a greater risk of

complications with the use of closure devices. In a meta-analysis to assess the safety of closure devices in patients undergoing percutaneous coronary procedures, an overall analysis favored mechanical compression over closure devices.⁵¹

2.13.8. Selected femoral artery closure devices

1. Perclose® Pro-glide™ (Perclose, Inc., Menlo Park, CA).
 - (a) Closure method: A proline stitch is placed in the arteriotomy.
 - (b) Requires a femoral artery angiogram; the puncture site must be at least 1 cm away from major branches of the vessel, such as the femoral artery bifurcation (Fig. 2.8).
 - (c) Advantage: The same artery can be re-punctured immediately if necessary.
2. Angio-Seal™ (St. Jude Medical, St. Paul, MN).
 - (a) Closure method: The device creates a mechanical seal by sandwiching the arteriotomy between a bioabsorbable anchor and a collagen sponge, which dissolves within 60–90 days.
 - (b) May be used at femoral artery branch points.
 - (c) Manufacturer recommends that the vessel not be re-punctured for at least 3 months.

2.13.9. Post-angiogram orders

1. Bed rest with the accessed leg extended, head of bed $\leq 30^\circ$, for 5 h, then out of bed for 1 h. (If a closure device is used, bed rest, with head of bed $\leq 30^\circ$, for 1 h, then out of bed for 1 h).
2. Vital signs: Check on arrival in recovery room, then Q 1 h until discharge. Call physician for SBP < 90 mmHg or decrease 25 mmHg; pulse > 120 .

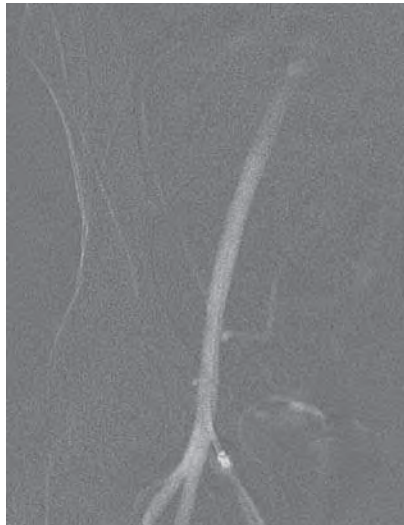


Fig. 2.8 Femoral artery angiogram done prior to the use of a closure device. Injection of contrast through the sheath shows that the sheath enters the femoral artery proximal to the bifurcation. Optimal visualization of the femoral bifurcation is usually obtained with an ipsilateral or contralateral oblique angiogram.

3. Check the puncture site and distal pulses upon arrival in recovery room, then Q 15 min × 4, Q 30 min × 2, then Q 1 h until discharge. Call physician if
 - (a) Bleeding or hematoma develops at puncture site.
 - (b) Distal pulse is not palpable beyond the puncture site.
4. Extremity is blue or cold.
5. Check puncture site after ambulation.
6. IVF: 0.9 N.S. at a maintenance rate until patient is ambulatory.
7. Resume pre-angiogram diet.
8. Resume routine medications.
9. PO fluids 400 mL.
10. D/C IV prior to discharge.

2.14. Special techniques and situations

2.14.1. Radial or brachial artery puncture

The arteries of the upper extremity are a useful alternative to the femoral artery for both diagnostic cerebral angiography and some neurointerventional procedures. Access via the radial⁵² or brachial artery⁵³ eliminates the risk of retroperitoneal hemorrhage and the need for several hours of bed rest that are associated with femoral artery puncture. In addition, an upper extremity approach can be advantageous when vessel tortuosity makes access to the vertebral artery difficult from a femoral approach. The authors prefer the radial approach to the brachial artery approach, as the radial approach seems to be easier⁵⁴ and less prone to complications than the brachial approach.

Prior to the radial artery puncture, an Allen test is necessary to ensure adequate collateral circulation to the hand from the ulnar artery. A pulse oximeter is placed on the patient's thumb, and the patient is instructed to repeatedly clench the fist. The examiner begins by compressing both the radial artery and the ulnar artery until the pulse oximetry tracing flattens, then pressure is taken off the ulnar artery. Normal capillary refill time is 5 s or less; a refill time of greater than 10 s is abnormal and an evidence of poor collateral circulation to the hand from the ulnar artery via the palmar arch. In a series of patients undergoing coronary catheterization, an Allen test finding indicating poor collateral circulation was found in 27% of patients.⁵⁵

Once adequate circulation is confirmed by the Allen test, the forearm is prepped and draped. Injection of lidocaine is used for local anesthesia, and a micropuncture set is used to place a 4-F or 5-F sheath in the radial artery. Once the sheath is inserted, the stopcock on the sheath is opened briefly and pulsatile arterial backflow is observed to confirm adequate positioning of the sheath within the artery. A 10 mL "radial artery cocktail" is then infused into the sheath as a measure to minimize the risk of vasospasm and thrombosis of the radial artery. Unlike sheaths in the femoral artery, a continuous heparinized saline drip is not used in the radial sheath, due to the pressure and pain it can produce. An alternative to using a sheath is to use a 3-French AngiopticSM catheter (AngioDynamics, Queensbury, NY) directly in the radial artery. After completion of the angiogram, the sheath and/or catheter is removed and a pressure dressing is applied to the wrist. The patient can sit up immediately.

Radial Artery Cocktail

Ten mL of saline containing heparin (5,000 IU), verapamil (2.5 mg), cardiac lidocaine (2%, 1.0 mL), and nitroglycerin (0.1 mg)

2.14.2. Selected patient-specific considerations

1. Patients receiving heparin: The heparin infusion should be stopped 6 h prior to the angiogram.
 - (a) If the need is urgent, an angiogram can be done in patients on heparin or who are coagulopathic with minimal risk. The initial puncture should be made with a micropuncture set to minimize potential bleeding.

2. Patients receiving warfarin: Warfarin should be held (and the patient should be placed on a heparin infusion if necessary) until the INR ≤ 1.4 .
3. Patients receiving metformin. See below.
4. Thrombocytopenia: Minimum platelet count for angiography is $75,000 \mu\text{L}^{-1}$.
5. Diabetic patients:
 - (a) Patients taking insulin: The insulin dose should be reduced to half of the usual dose on the morning of the procedure, when the patient is NPO. The procedure should be done as early in the day as possible, and the patient's usual diet and insulin should be resumed.
 - (b) Patients taking metformin-containing oral anti-hyperglycemic medications: See below
 - (c) Protamine should not be used to reverse heparin if the patient has received neutral protamine Hagedorn [NPH] insulin.^{56, 57}
6. Pregnant patients: Every effort should be made to study pregnant patients non-invasively. Occasionally, a catheter angiogram is necessary (e.g., head and neck trauma with possible vascular injury, spontaneous epistaxis, intracranial AVM). Cerebral angiography can be performed safely during pregnancy.
 - (a) Informed consent of the patient or guardian should include a theoretical risk of injury to the fetus.
 - (b) Current recommendations for radiation exposure of the fetus include a maximum dose of 0.5 rem (roentgen-equivalent-man).⁵⁸
 - By shielding the uterus with a lead apron, the maximum dose to the fetus is less than 0.1 rem during cerebral angiography.⁵⁹
 - In general, fetal malformations only occur above a threshold dose of 100–200 mGy (~10–20 rem).⁶⁰
 - (c) Iodinated contrast agents are physiologically inert and pose little risk to the fetus.⁶¹
 - (d) Adequate hydration should be provided to avoid fetal dehydration.⁶²
 - (e) Fluoroscopy: Minimize time and pulse/sec rate during the procedure.
 - (f) Decrease fps during diagnostic runs to a minimum.
7. Pediatric patients. See below.

2.14.3. Contrast-induced nephropathy

Iodinated contrast-induced nephropathy usually appears as an acute worsening in renal function within 3–4 days of the procedure.⁶³ Contrast-induced nephropathy is usually defined as an increase in serum creatinine of 25–50% over baseline, or an absolute rise in serum creatinine of $0.5\text{--}1 \text{ mg dL}^{-1}$.^{64, 65} Patients with renal insufficiency are up to ten times more likely to develop contrast-induced renal failure with administration of iodinated contrast than patients in the general population.⁶⁶ Patients with renal insufficiency (creatinine $\geq 1.5 \text{ mg dL}^{-1}$)⁶⁷ require measures to minimize the risk of contrast-induced injury nephropathy during angiography. Nonionic, low-osmolality contrast agents, such as iodixanol (Visipaque[®], GE Healthcare, Princeton, NJ) and iopromide (Ultravist[®], Schering, Berlin) have been shown to be less renal-toxic when compared to iohexol (Omnipaque[®]).⁶⁸ The smallest possible amount of contrast should be used during the procedure. One of the authors was able to do a carotid angioplasty and stent procedure using a total of 27 mL of Visique[™] by diluting the contrast with saline and using it sparingly. Forty-eight hours should be allowed to elapse between procedures utilizing iodinated contrast when possible.⁶⁹ The antioxidant, N-acetylcysteine (Mucomyst[®], Bristol-Myers Squibb, New York) is thought to function as a free-radical scavenger and to stimulate intrarenal vasodilation. Acetylcysteine was shown in a randomized trial to reduce serum creatinine elevation in patients undergoing radiological procedures using non-ionic, low osmolality contrast material.⁷⁰ Prophylactic administration of acetylcysteine (600 mg PO BID) and 0.45% saline IV, before and after administration of the contrast agent, leads to a significant decrease in serum creatinine compared to patients receiving saline only. Subsequently, isotonic IV fluid was found to be superior to half-isotonic IV fluid in reducing the incidence of contrast-induced nephropathy in patients undergoing coronary angioplasty.⁷¹ Gadolinium contrast has also been used as a non-iodinated contrast agent in cerebral angiography,^{72, 73} but extensive testing has not been done to ensure the safety of gadolinium compounds in the cerebral arteries. Hemofiltration has been shown to reduce creatinine elevations after angiography.⁷⁴ For patients with dialysis-dependent renal failure, arrangements should be made with the patient's nephrologist to schedule dialysis after the angiogram.

2.15. Risk factors for contrast-induced nephropathy

- Serum creatinine level ≥ 1.5 mg dL⁻¹
- Diabetes mellitus
- Dehydration
- Cardiovascular disease and the use of diuretics
- Age ≥ 60 years
- Paraproteinemia (e.g., multiple myeloma)
- Hypertension
- Hyperuricemia

The patients at greatest risk for contrast nephrotoxicity are those with both diabetes and renal insufficiency.^{75, 76}

2.16. Methods to reduce risk of contrast-induced nephropathy

- Minimize the use of contrast
- Use Visipaque™ instead of Omnipaque™⁶⁸
- PO hydration (water, 500 mL prior to the procedure and 2,000 mL after the procedure)
- IV hydration with 0.9 sodium chloride⁷¹
- Acetylcysteine 600 mg (3 mL) PO BID on the day before and the day of the procedure⁷⁰

2.17. Metformin

Metformin is an oral anti-hyperglycemic and is used in several preparations (listed below). Metformin-associated lactic acidosis is rare but has been reported to have a mortality rate as high as 50%.⁷⁷ Metformin use should be held for 48 h after the procedure, and restarted only after serum creatinine has been checked and found to be unchanged. The procedure may be done even if the patient has taken metformin earlier on the same day of the procedure.⁷⁸ Although metformin use seems to be associated with lactic acidosis, a recent systematic review article has questioned whether there is a causal relationship.⁷⁹

2.18. Metformin-containing medications

- Metformin (generic)
- Glucophage®
- Avandamet®
- Glucovance®
- Metaglip®

2.18.1. Contrast reactions: prevention and management

Life-threatening contrast reactions are rare with the use of low-osmolality contrast agents, occurring with a frequency of 0.04%.⁸⁰ Non-life threatening reactions, including cutaneous reactions, which usually occur in a delayed fashion, have an incidence of approximately 1–2%.⁸⁰

2.19. Risk factors for contrast reactions

- History of a reaction to iodinated contrast agents (except flushing, a sensation of heat, or a single episode of nausea).
- History of serious allergic reactions to other materials
- Asthma
- Renal insufficiency
- Significant cardiac disease (e.g., patients with angina, congestive heart failure, severe aortic stenosis, primary pulmonary hypertension, severe cardiomyopathy).
- Anxiety

Previous reaction to contrast medium is the most important risk factor in the prediction of an adverse event.⁸¹ Patients who have had a previous reaction to ionic contrast may not have a reaction to nonionic agents.⁸² A history of seafood allergies, without a specific history of an iodine reaction, usually indicates a hypersensitivity to allergens in seafood, and does not indicate that the patient is unable to tolerate contrast media.⁸³

Premedication with steroids can reduce the risk of a serious contrast reaction.⁸⁴

2.20. Premedication regimen

1. Prednisone 50 mg PO (or hydrocortisone 200 mg IV) 13 h, 7 h, and 1 h prior to contrast injection
2. Diphenhydramine (Benadryl[®]) 50 mg IV, IM or PO 1 h prior to contrast injection

Steroids should be given at least 6 h prior to the procedure; administration less than 3 h prior to the procedure does not reduce the risk of an adverse reaction.⁷⁸

2.21. Acute contrast reactions: signs and symptoms

- Cutaneous signs (flushing, urticaria, pruritis)
- Mucosal edema
- Generalized edema
- Sudden loss of consciousness
- Hypotension + tachycardia (anaphylactic reaction)
- Hypotension + bradycardia (vasovagal reaction)
- Respiratory distress

2.22. Acute contrast reactions: treatment

Effective treatment depends on prompt recognition of the problem and rapid management (Table 2.4).⁸⁵

2.23. Intraoperative angiography

Intraoperative angiography is employed by some neurosurgeons during surgery for intracranial aneurysms and arteriovenous malformations. In aneurysm surgery, intraoperative angiography findings, such as residual aneurysm or parent vessel compromise, have led to reexploration and clip adjustment in up to 12.4% of cases.⁸⁶

⁸⁷ Factors associated with a need for revision include large aneurysm size,⁸⁶ the

Table 2.4 Management of acute contrast reactions in adults

Urticaria

1. Discontinue procedure if not completed
2. No treatment needed in most cases
3. Give H₁-receptor blocker: Diphenhydramine (Benadryl®) PO/IM/IV 25–50 mg. If severe or widely disseminated: Alpha agonist (arteriolar and venous constriction) Epinephrine SC (1:1,000) 0.1–0.3 mL (=0.1–0.3 mg) (if no cardiac contraindications)

Facial or Laryngeal Edema

1. Give alpha agonist (arteriolar and venous constriction): Epinephrine sc or IM (1:1,000) 0.1–0.3 mL (=0.1–0.3 mg) or, if hypotension evident, Epinephrine (1:10,000) slowly IV 1 mL (=0.1 mg). Repeat as needed up to a maximum of 1 mg
2. Give O₂ 6–10 L min⁻¹ (via mask)
3. If not responsive to therapy or if there is obvious acute laryngeal edema, seek appropriate assistance (e.g., cardiopulmonary arrest response team)

Bronchospasm

1. Give O₂ 6–10 L min⁻¹ (via mask)
2. Monitor: electrocardiogram, O₂ saturation (pulse oximeter), and blood pressure
3. Give beta-agonist inhalers [bronchiolar dilators, such as metaproterenol (Alupent®), terbutaline (Brethaire®), or albuterol (Proventil®)(Ventolin®) 2–3 puffs; repeat PRN. If unresponsive to inhalers, use SC, IM, or IV epinephrine
4. Give epinephrine SC or IM (1:1,000) 0.1–0.3 mL (=0.1–0.3 mg) or, if hypotension evident, Epinephrine (1:10,000) slowly IV 1 mL (=0.1 mg)
5. Repeat as needed up to a maximum of 1 mg

Alternatively: Give aminophylline: 6 mg kg⁻¹ IV in D₅W over 10–20 min (loading dose), then 0.4–1 mg kg⁻¹ h⁻¹, as needed (caution: hypotension)

Call for assistance (e.g., cardiopulmonary arrest response team) for severe bronchospasm or if O₂ saturation <88% persists

Hypotension with Tachycardia

1. Legs elevated 60° or more (preferred) or Trendelenburg position
2. Monitor: electrocardiogram, pulse oximeter, blood pressure
3. Give O₂ 6–10 L min⁻¹ (via mask)
4. Rapid intravenous administration of large volumes of isotonic Ringer's lactate or normal saline

If poorly responsive: Epinephrine (1:10,000) slowly IV 1 mL (=0.1 mg) (if no cardiac contraindications). Repeat as needed up to a maximum of 1 mg

If still poorly responsive seek appropriate assistance (e.g., cardiopulmonary arrest response team)

Hypotension with Bradycardia (Vagal Reaction)

1. Monitor vital signs
2. Legs elevated 60° or more (preferred) or Trendelenburg position
3. Secure airway: give O₂ 6–10 L min⁻¹ (via mask)
4. Secure IV access: Rapid fluid replacement with Ringer's lactate or normal saline
5. Give atropine 0.6–1 mg IV slowly if patient does not respond quickly to steps 2 – 4
6. Repeat atropine up to a total dose of 0.04 mg kg⁻¹ (2–3 mg) in adult
7. Ensure complete resolution of hypotension and bradycardia prior to discharge

Hypertension, Severe

1. Give O₂ 6–10 L min⁻¹ (via mask)
2. Monitor electrocardiogram, pulse oximeter, blood pressure
3. Give nitroglycerine 0.4 mg tablet, sublingual (may repeat × 3); or, topical 2% ointment, apply 1 in. strip
4. Transfer to intensive care unit or emergency department
5. For pheochromocytoma – phentolamine 5 mg IV

Seizures or Convulsions

(continued)

Table 2.4 (continued)

1. Give O₂ 6–10 L min⁻¹ (via mask)
 2. Consider diazepam (Valium®) 5 mg (or more, as appropriate) or midazolam (Versed®) 0.5–1 mg IV
 3. If longer effect needed, obtain consultation; consider phenytoin (Dilantin®) infusion 15–18 mg kg⁻¹ at 50 mg min⁻¹
 4. Careful monitoring of vital signs required, particularly of pO₂ because of risk of respiratory depression with benzodiazepine administration
 5. Consider using cardiopulmonary arrest response team for intubation if needed
- Pulmonary Edema
1. Elevate torso; rotating tourniquets (venous compression)
 2. Give O₂ 6–10 L min⁻¹ (via mask)
 3. Give diuretics – furosemide (Lasix®) 20–40 mg IV, slow push
 4. Consider giving morphine (1–3 mg IV)
 5. Transfer to intensive care unit or emergency department
 6. Corticosteroids optional

From: ACR Manual on Contrast Media, Version 5.0.⁷⁸ Reprinted with permission of the American College of Radiology

superior hypophyseal artery and clinoidal segment locations,⁸⁶ and the occurrence of an intraoperative rupture.⁸⁸ A portable C-arm digital subtraction angiography unit is necessary for intraoperative angiography, and a radiolucent head holder (Ohio Medical Instruments, Cincinnati, OH) and radiolucent operating table (Skytron, Grand Rapids, MI) are helpful, although adequate intraoperative imaging can be done even without radiolucent hardware. A femoral artery sheath should be placed prior to the operation. Use of a braided sheath will prevent kinking if the patient is moved after sheath placement. Continuous infusion of heparinized saline (5,000 U in 500 mL saline on a pressure bag at 3 mL h⁻¹) will maintain the patency of the sheath without a perceptible effect on systemic coagulation. A technique for intraoperative angiography for anterior circulation aneurysms by injection of contrast into the superficial temporal artery has also been described.⁸⁹

2.24. Pediatric cerebral angiography

Use noninvasive imaging modalities whenever possible. Although neurological complications are rare, children have higher rates of femoral artery access complications than adults do. In a series of 176 pediatric cerebral angiograms, no neurological complications occurred but puncture site complications (groin hematoma, bleeding, or reduced pedal pulse) occurred in 4.5%.⁹⁰

2.24.1. Access

1. Draping: use small aperture drape for the groin, and a regular femoral angiography drape for the rest of the angio table.
2. Newborns: the umbilical artery and vein can be used to access both arterial and venous circulations which allow for fairly easy catheterization.
3. The femoral artery is surprisingly superficial.
4. The femoral artery in children is prone to catheter-induced vasospasm, so minimize the amount of manipulation and the size of devices (e.g., use a micro-puncture kit and small catheters).
5. Work without a sheath if possible.
6. Caveat: Initial catheterization of the femoral artery is sometimes surprisingly difficult because of the integrity of the connective tissue around the femoral artery; be sure that the wire that is used to introduce the diagnostic catheter is size-matched to the catheter to facilitate entry.

7. A twisting action can be helpful as the catheter is passed into the femoral artery.
8. An 18 or 20 gauge butterfly needle is useful for the initial femoral artery puncture (hint: cut clear the plastic tubing off the butterfly needle hub).
9. Sometimes an ultrasound-guided needle (e.g., Smart-needle[®], Peripheral Systems Group, Mountain View, CA) (20 gauge or smaller) is helpful.⁹¹
10. Femoral artery puncture site management:
 - (a) When compressing the artery after removal of the catheter, pay close attention to the distal lower extremity to ensure adequate perfusion. Overly aggressive manual compression or trauma to the femoral artery can result in long-standing femoral artery stenosis or occlusion, leading to limb atrophy.
 - (b) After compression, the hip and lower extremity can be immobilized by taping or strapping it to an IV board.

2.24.2. Catheters

1. Catheters should be small in caliber and short in length (to minimize dead space in the catheter) (≤ 60 cm).
2. Newborns and young infants:
 - (a) 3-F Harwood-Nash.
 - Very peculiar curve makes it easy to access the left subclavian artery but difficult to navigate into the aortic arch
 - Requires a small guidewire (e.g., 0.018–0.025 in. steerable hydrophilic wire)
3. Older infants and young children:
 - (a) 4-F Pediatric Berenstein
 - (b) 4-F Harwood-Nash
4. All pediatric patients:
 - (a) 3-F Angioptic[™] (AngioDynamics, Queensbury, NY).
 - Comes in steam-shapeable straight or curved configurations
 - Use a 21 gauge needle and a small guidewire (e.g., 0.018–0.021 in. steerable hydrophilic wire)

2.24.3. Saline, contrast dose, and volume considerations

1. Use less heparin in the flush: Saline with 20 units of heparin per mL
2. Double flushing with heparinized saline: Be careful to aspirate the minimum amount of blood to minimize blood loss and heparin dose
3. Use small syringes (3 mL or 5 mL) to limit the amount of volume
4. Limit contrast to 4 mL of Omnipaque[®] 300 per kg body weight
5. Limiting volume is particularly critical in children with Vein of Galen malformations, as these patients often have some degree of high-output congestive heart failure

2.24.4. Imaging parameters and radiation exposure

1. Image intensifier:
 - (a) Use a small field of view.
 - (b) Remove the filter if possible.
 - (c) Lower the X-ray dose as much as possible:
2. Limit fluoroscopy time.
3. Lower the pulse rate during fluoroscopy (e.g., 3–6 fps).
4. Maximize collimation to minimize scatter.
5. Use “low-dose fluoro option” if available as a part of the imaging equipment.
6. Place a lead shield under the gonads if possible.

2.25. Tips for imaging specific vascular structures and lesions

2.25.1. Atherosclerotic carotid and vertebrobasilar disease

- Aortic arch angiogram: identifies aortic atheromas and common carotid artery lesions, and helps planning for potential carotid angioplasty and stenting procedures.
- To image the carotid bifurcation, on the PA view, place the angle of the mandible in the center of the image.
- Oblique views are sometimes necessary to obtain the optimal view of an atherosclerotic plaque.
- When high grade stenosis prevents passage of enough contrast to image the internal carotid artery (ICA), the degree of stenosis can be estimated using the diameter of the contralateral ICA.⁹²
- The vertebral artery origin is best seen with an AP Townes view, because the vertebral artery arises from the posterior wall of the subclavian artery (Fig. 1.37).
- The intracranial vertebral arteries and basilar artery are best seen with an AP Waters view, because the basilar artery travels parallel to the clivus, which is tilted anteriorly in the sagittal plane.

2.25.2. Intracranial aneurysms

- A complete four-vessel angiogram should be done in the setting of subarachnoid hemorrhage, as two or more aneurysms will be found in 15–20% of patients.⁹³
- Selective catheterization of the ICA will prevent branches of the ECA from obscuring the intracranial images.
- External carotid angiography may be needed in aneurysm cases if an extracranial to intracranial arterial bypass is anticipated for surgical treatment, in order to visualize possible donor vessels.
- If a study is done in the setting of subarachnoid hemorrhage, and no aneurysm is found on internal carotid arteriography, external carotid angiography may be useful to rule out an arteriovenous fistula (see below).
- Aneurysm dome, neck, parent vessel, and adjacent vessels should be discerned.
- Selective microcatheter angiography is helpful in imaging large and giant aneurysms.

2.25.3. Cerebral arteriovenous malformations

- All feeding arteries and draining veins should be identified; this usually requires a complete bilateral internal carotid, external carotid, and vertebral angiogram.
- High-speed runs (>5 frames per second) can help clarify anatomy of AVMs, as they are typically high-flow lesions. High-speed runs may also permit more precise measurements of arteriovenous transit times.
- Intranidal aneurysms can be identified and distinguished from enlarged veins by their location on the *arterial side* of the nidus.⁹⁴ In contrast, nidal “pseudoaneurysms” have been described in the arterial or venous side of the nidus; they can be recognized when they appear as a new finding on subsequent angiography.⁹⁵
- Small, obscure AVMs may sometimes be made to be more apparent on angiography by having the patient deliberately hyperventilate for several minutes. Normal vessels will constrict and AVM vessels will be unchanged.⁹⁶

2.25.4. Dural arteriovenous fistulas

- All feeding vessels should be identified; selective catheterization of branches of the external carotid artery is usually necessary.
- After each injection, the angiogram should be allowed to continue until the draining vein (or venous sinus) is imaged.
- On internal carotid and vertebral injections, the venous drainage pathways of the normal brain must be determined to see how it relates to the drainage pathways of the fistula.

2.25.5. Direct (high flow) carotid-cavernous fistulas

- High-speed runs (>5 frames per second) are usually helpful.
- Huber maneuver: Injection of contrast into the ipsilateral vertebral artery with manual compression of the carotid artery; reflux of contrast into the carotid artery can demonstrate the defect in the cavernous carotid artery.⁹⁷
- Slow injection into the internal carotid artery with a compression of the carotid artery below the catheter tip in the neck can also demonstrate the defect in the vessel.⁹⁸
- Special attention should be given to venous drainage and determining whether there is a retrograde cortical venous flow.

2.25.6. Aortic arch

- Angiography of the aortic arch is best done with a power injector and a pigtail catheter positioned in the ascending aorta. The optimal projection is left anterior oblique, 30°, with the patient's head rotated to the left to face the image intensifier. Power injector settings are 20 mL s⁻¹; total of 25 mL.

2.25.7. Assessment of the circle of Willis

- Patency and caliber of the posterior communicating artery can be assessed with the Huber (or Allcock) maneuver: Injection of contrast into the ipsilateral vertebral artery with manual compression of the carotid artery; reflux of contrast into the carotid artery can demonstrate posterior communicating artery.
- The anterior communicating artery can be demonstrated by “cross compression” of the carotid artery. Manual compression of the contralateral common carotid artery while wearing a lead glove during injection of contrast into the ipsilateral internal carotid artery will help visualize the anterior communicating artery.

2.25.8. Carotid siphon and MCA candelabra

- The “Houghton view” can be used to open up the carotid siphon (useful for imaging the origins of the P-comm and anterior choroidal arteries) and to unfurl the branches of the MCA within the Sylvian fissure.⁴⁸ This view is also helpful for imaging ICA and MCA aneurysms. The lateral arc is positioned as if the patient's head is tilted away from the side of the injection and away from the xray tube (Fig. 2.9). A mnemonic to remember this is: “The X-ray tube should *touch the shoulder* on the side of interest.”

The carotid siphon and MCA candelabra can often be seen most clearly by positioning the lateral arc as if the patient's head is tilted *away* from the side of injection.

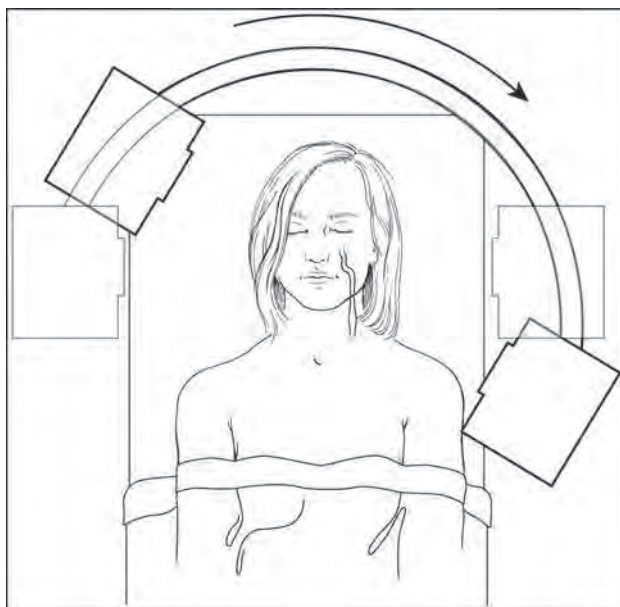


Fig. 2.9 Houghton view for imaging the carotid siphon and the MCA candelabra.

2.26. References

- Higashida RT, Hopkins LN, Berenstein A, Halbach VV, Kerber C. Program requirements for residency/fellowship education in neuroendovascular surgery/interventional neuroradiology: A special report on graduate medical education. *AJNR Am J Neuroradiol* 2000;21(6):1153-9
- Haschek E, Lindenthal OT. Ein Beitrag zur praktischen Verwerthung der Photographie nach Röntgen. *Wien Klin Wschr* 1896;9:63-4
- Krayenbühl H. History of cerebral angiography and its development since Egaz Moniz. In: Egaz Moniz Centenary: Scientific Reports. Lisbon: Comissao Executiva das Comemoracoes do Centenario do Nascimento do Prof. Egaz Moniz; 1977:63-74
- Norlén E. Importance of angiography in surgery of intracranial vascular lesions. In: Egaz Moniz Centenary: Scientific Reports. Lisbon: Comissao Executiva das Comemoracoes do Centenario do Nascimento do Prof. Egaz Moniz; 1977:31-9
- Lima A. Egaz Moniz 1874-1955. *Surg Neurol* 1973;1(5):247-8
- Damasio AR. Egaz Moniz, pioneer of angiography and leucotomy. *Mt Sinai J Med* 1975;42(6):502-13
- Moniz EL. *L'angiographie cérébrale*. Paris: Masson; 1934
- Dagi TF. Neurosurgery and the introduction of cerebral angiography. *Neurosurg Clin N Am* 2001;12(1):145-53, ix
- Ligon BL. The mystery of angiography and the "unwarded" Nobel Prize: Egaz Moniz and Hans Christian Jacobaeus. *Neurosurgery* 1998;43(3):602-11
- Sheldon P. A special needle for percutaneous vertebral angiography. *Br J Radiol* 1956;29(340):231-2
- Gould PL, Peyton WT, French LA. Vertebral angiography by retrograde injection of the brachial artery. *J Neurosurg* 1955;12(4):369-74
- Kuhn RA. Brachial cerebral angiography. *J Neurosurg* 1960;17:955-71
- Hinck VC, Judkins MP, Paxton HD. Simplified selective femorocerebral angiography. *Radiology* 1967;89(6):1048-52
- Mentzel H-J, Blume J, Malich A, Fitzek C, Reichenbach JR, Kaiser WA. Cortical blindness after contrast-enhanced CT: Complication in a patient with diabetes insipidus. *AJNR Am J Neuroradiol* 2003;24(6):1114-6
- Saigal G, Bhatia R, Bhatia S, Wakhloo AK. MR Findings of cortical blindness following cerebral angiography: Is this entity related to posterior reversible leukoencephalopathy? *AJNR Am J Neuroradiol* 2004;25(2):252-6
- Yildiz A, Yencilek E, Apaydin FD, Duce MN, Ozer C, Atalay A. Transient partial amnesia complicating cardiac and peripheral arteriography with nonionic contrast medium. *Eur Radiol* 2003;13(Suppl 4):L113-5
- Willinsky RA, Taylor SM, TerBrugge K, Farb RI, Tomlinson G, Montanera W. Neurologic complications of cerebral angiography: Prospective analysis of 2,899 procedures and review of the literature. *Radiology* 2003;227(2):522-8
- Young B, Moore WS, Robertson JT, et al. An analysis of perioperative surgical mortality and morbidity in the asymptomatic carotid atherosclerosis study. ACAS Investigators. Asymptomatic Carotid Arteriosclerosis Study. *Stroke* 1996;27(12):2216-24

19. Heiserman JE, Dean BL, Hodak JA, et al. Neurologic complications of cerebral angiography. *AJNR Am J Neuroradiol* 1994;15(8):1401-7; discussion 8-11
20. Hankey GJ, Warlow CP, Molyneux AJ. Complications of cerebral angiography for patients with mild carotid territory ischaemia being considered for carotid endarterectomy. *J Neurol Neurosurg Psychiatry* 1990;53(7):542-8
21. Cloft HJ, Joseph GJ, Dion JE. Risk of cerebral angiography in patients with subarachnoid hemorrhage, cerebral aneurysm, and arteriovenous malformation: A meta-analysis. *Stroke* 1999;30(2):317-20
22. Mani RL, Eisenberg RL. Complications of catheter cerebral arteriography: Analysis of 5,000 procedures. III. Assessment of arteries injected, contrast medium used, duration of procedure, and age of patient. *AJR Am J Roentgenol* 1978;131(5):871-4
23. Dion JE, Gates PC, Fox AJ, Barnett HJ, Blom RJ. Clinical events following neuroangiography: A prospective study. *Stroke* 1987;18(6):997-1004
24. Earnest Ft, Forbes G, Sandok BA, et al. Complications of cerebral angiography: Prospective assessment of risk. *AJR Am J Roentgenol* 1984;142(2):247-53
25. Citron SJ, Wallace RC, Lewis CA, et al. Quality improvement guidelines for adult diagnostic neuroangiography: Cooperative study between ASITN, ASNIR, and SIR. *J Vasc Interv Radiol* 2003;14(9 Pt 2):S257-62
26. Kurokawa Y, Abiko S, Okamura T, et al. Pulmonary embolism after cerebral angiography - three case reports. *Neurol Med Chir (Tokyo)* 1995;35(5):305-9
27. Katholi RE, Taylor GJ, Woods WT, et al. Nephrotoxicity of nonionic low-osmolality versus ionic high-osmolality contrast media: A prospective double-blind randomized comparison in human beings. *Radiology* 1993;186(1):183-7
28. Barrett BJ, Carlisle EJ. Metaanalysis of the relative nephrotoxicity of high- and low-osmolality iodinated contrast media. *Radiology* 1993;188(1):171-8
29. Barrett BJ, Paffrey PS, McDonald JR, Hefferton DM, Reddy ER, McManamon PJ. Nonionic low-osmolality versus ionic high-osmolality contrast material for intravenous use in patients perceived to be at high risk: Randomized trial. *Radiology* 1992;183(1):105-10
30. Barrett BJ, Paffrey PS, Vavasour HM, O'Dea F, Kent G, Stone E. A comparison of nonionic, low-osmolality radiocontrast agents with ionic, high-osmolality agents during cardiac catheterization. *N Engl J Med* 1992;326(7):431-6
31. Rosovsky MA, Rusinek H, Berenstein A, Basak S, Setton A, Nelson PK. High-dose administration of non-ionic contrast media: A retrospective review. *Radiology* 1996;200(1):119-22
32. Moran CJ, Milburn JM, Cross DT, III, Derdeyn CP, Dobbie TK, Littenberg B. Randomized controlled trial of sheaths in diagnostic neuroangiography. *Radiology* 2001;218(1):183-7
33. Kiyosue H, Okahara M, Nagatomi H, Nakamura T, Tanoue S, Mori H. 3.3F Catheter/sheath system for use in diagnostic neuroangiography. *AJNR Am J Neuroradiol* 2002;23(4):711-5
34. Weinbroum AA, Szold O, Ogorek D, Flaishon R. The midazolam-induced paradox phenomenon is reversible by flumazenil. Epidemiology, patient characteristics and review of the literature. *Eur J Anaesthesiol* 2001;18(12):789-97
35. Mancuso CE, Tanzi MG, Gabay M. Paradoxical reactions to benzodiazepines: Literature review and treatment options. *Pharmacotherapy* 2004;24(9):1177-85
36. Thurston TA, Williams CG, Foshee SL. Reversal of a paradoxical reaction to midazolam with flumazenil. *Anesth Analg* 1996;83(1):192
37. Markus H, Loh A, Israel D, Buckenham T, Clifton A, Brown MM. Microscopic air embolism during cerebral angiography and strategies for its avoidance. *Lancet* 1993;341(8848):784-7
38. Bendszus M, Koltzenburg M, Bartsch AJ, et al. Heparin and air filters reduce embolic events caused by intra-arterial cerebral angiography: A prospective, randomized trial. *Circulation* 2004;110(15):2210-5
39. Dexter F, Hindman BJ. Recommendations for hyperbaric oxygen therapy of cerebral air embolism based on a mathematical model of bubble absorption. *Anesth Analg* 1997;84(6):1203-7
40. Branger AB, Lambertsen CJ, Eckmann DM. Cerebral gas embolism absorption during hyperbaric therapy: Theory. *J Appl Physiol* 2001;90(2):593-600
41. Calvert JW, Cahill J, Zhang JH. Hyperbaric oxygen and cerebral physiology. *Neurol Res* 2007;29(2):132-41
42. LeDez KM, Zbitnew G. Hyperbaric treatment of cerebral air embolism in an infant with cyanotic congenital heart disease. *Can J Anaesth* 2005;52(4):403-8
43. Bitterman H, Melamed Y. Delayed hyperbaric treatment of cerebral air embolism. *Isr J Med Sci* 1993;29(1):22-6
44. Blanc P, Boussuges A, Henriette K, Sainty JM, Deleflie M. Iatrogenic cerebral air embolism: Importance of an early hyperbaric oxygenation. *Intensive Care Med* 2002;28(5):559-63
45. Shrinivas VG, Sankarkumar R, Rupa S. Retrograde cerebral perfusion for treatment of air embolism after valve surgery. *Asian Cardiovasc Thorac Ann* 2004;12(1):81-2
46. Gregoric ID, Myers TJ, Kar B, et al. Management of air embolism during HeartMate XVE exchange. *Tex Heart Inst J* 2007;34(1):19-22
47. Hughes DG, Patel U, Forbes WS, Jones AP. Comparison of hand injection with mechanical injection for digital subtraction selective cerebral angiography. *Br J Radiol* 1994;67(800):786-9
48. Haughton VM, Rosenbaum AE, Baker RA, Plaistowe RL. Lateral projections with inclined head for angiography of basal cerebral aneurysms. *Radiology* 1975;116(1):220-2
49. Elisevich K, Cunningham IA, Assis L. Size estimation and magnification error in radiographic imaging: Implications for classification of arteriovenous malformations. *AJNR Am J Neuroradiol* 1995;16(3):531-8
50. Fischer TH, Connolly R, Thatté HS, Schwaiblmair SS. Comparison of structural and hemostatic properties of the poly-N-acetyl glucosamine Syvek Patch with products containing chitosan. *Microsc Res Tech* 2004;63(3):168-74
51. Nikolsky E, Mehran R, Halkin A, et al. Vascular complications associated with arteriotomy closure devices in patients undergoing percutaneous coronary procedures: A meta-analysis. *J Am Coll Cardiol* 2004;44(6):1200-9
52. Levy EI, Boulos AS, Fessler RD, et al. Transradial cerebral angiography: An alternative route. *Neurosurgery* 2002;51(2):335-40; discussion 40-2
53. Uchino A. Selective catheterization of the brachiocephalic arteries via the right brachial artery. *Neuroradiology* 1988;30(6):524-7
54. Hildick-Smith DJ, Ludman PF, Lowe MD, et al. Comparison of radial versus brachial approaches for diagnostic coronary angiography when the femoral approach is contraindicated. *Am J Cardiol* 1998;81(6):770-2
55. Benit E, Vranckx P, Jaspers L, Jackmaert R, Poelmans C, Coninx R. Frequency of a positive modified Allen's test in 1,000 consecutive patients undergoing cardiac catheterization. *Cathet Cardiovasc Diagn* 1996;38(4):352-4
56. Stewart WI, McSweeney SM, Kellett MA, Faxon DP, Ryan TJ. Increased risk of severe protamine reactions in NPH insulin-dependent diabetics undergoing cardiac catheterization. *Circulation* 1984;70(5):788-92
57. Cobb CA, 3rd, Fung DL. Shock due to protamine hypersensitivity. *Surg Neurol* 1982;17(4):245-6
58. Measurements NCoRPa. Recommendations on Limits for Exposure to Ionizing Radiation (NCRP Report No. 91); 1987
59. Piper J. Fetal toxicity of common neurosurgical drugs. In: Loftus C, ed. *Neurosurgical Aspects of Pregnancy*. Park Ridge, IL: American Association of Neurological Surgeons; 1996:1-20
60. Kal HB, Struikmans H. Pregnancy and medical irradiation: summary and conclusions from the International Commission on Radiological Protection, Publication 84. *Ned Tijdschr Geneesk* 2002;146(7):299-303
61. Dalessio D. Neurologic diseases. In: Burrow G, Ferris T, eds. *Medical Complications During Pregnancy*. Philadelphia, PA: Saunders; 1982:435-47
62. Dias MS, Sekhar LN. Intracranial hemorrhage from aneurysms and arteriovenous malformations during pregnancy and the puerperium. *Neurosurgery* 1990;27(6):855-65; discussion 65-6

63. Morcos SK. Contrast media-induced nephrotoxicity – questions and answers. *Br J Radiol* 1998;71(844):357–65
64. Barrett BJ, Parfrey PS, eds. Clinical aspects of acute renal failure following use of radiocontrast agents. New York, NY: Marcel Dekker; 1992
65. Solomon R. Contrast-medium-induced acute renal failure. *Kidney Int* 1998;53(1):230–42
66. Rudnick MR, Goldfarb S, Wexler L, et al. Nephrotoxicity of ionic and nonionic contrast media in 1196 patients: A randomized trial. The Iohexol Cooperative Study. *Kidney Int* 1995;47(1):254–61
67. Porter GA. Radiocontrast-induced nephropathy. *Nephrol Dial Transplant* 1994;9 Suppl 4:146–56
68. Sharma S, Kimi A. Effect of nonionic radiocontrast agents on the occurrence of contrast-induced nephropathy in patients with mild-moderate chronic renal insufficiency: Pooled analysis of the randomized trials. *Catheter Cardiovasc Interv* 2005;65(3):386–93
69. Cohan RH, Ellis JH. Iodinated contrast material in uro-radiology. Choice of agent and management of complications. *Urol Clin North Am* 1997;24(3):471–91
70. Tepel M, van der Giet M, Schwarzfeld C, Laufer U, Liermann D, Zidek W. Prevention of radiographic-contrast-agent-induced reductions in renal function by acetylcysteine. *N Engl J Med* 2000;343(3):180–4
71. Mueller C, Buerkle G, Buettner HJ, et al. Prevention of contrast media-associated nephropathy: Randomized comparison of 2 hydration regimens in 1620 patients undergoing coronary angioplasty. *Arch Intern Med* 2002;162(3):329–36
72. Nussbaum ES, Casey SO, Sebring LA, Madison MT. Use of gadolinium as an intraarterial contrast agent in digital subtraction angiography of the cervical carotid arteries and intracranial circulation. Technical note. *J Neurosurg* 2000;92(5):881–3
73. Arat A, Cekirge HS, Saatci I. Gadodiamide as an alternative contrast medium in cerebral angiography in a patient with sensitivity to iodinated contrast medium. *Neuroradiology* 2000;42(1):34–7; discussion 7–9
74. Marenzi G, Marana I, Lauri G, et al. The prevention of radiocontrast-agent-induced nephropathy by hemofiltration. *N Engl J Med* 2003;349(14):1333–40
75. Parfrey PS, Griffiths SM, Barrett BJ, et al. Contrast material-induced renal failure in patients with diabetes mellitus, renal insufficiency, or both. A prospective controlled study. *N Engl J Med* 1989;320(3):143–9
76. Schwab SJ, Hlatky MA, Pieper KS, et al. Contrast nephrotoxicity: A randomized controlled trial of a nonionic and an ionic radiographic contrast agent. *N Engl J Med* 1989;320(3):149–53
77. Wibholm BE, Myrhed M. Metformin-associated lactic acidosis in Sweden 1977–1991. *Eur J Clin Pharmacol* 1993;44(6):589–91
78. *Manual on Contrast Media*. 5.0 ed. Reston, VA: American College of Radiology; 2004
79. Lalau JD, Race JM. Lactic acidosis in metformin therapy: Searching for a link with metformin in reports of 'metformin-associated lactic acidosis'. *Diabetes Obes Metab* 2001;3(3):195–201
80. Thomsen HS, Bush WH, Jr. Adverse effects of contrast media: Incidence, prevention and management. *Drug Saf* 1998;19(4):313–24
81. Bettmann MA, Heeren T, Greenfield A, Goudey C. Adverse events with radiographic contrast agents: Results of the SCVIR Contrast Agent Registry. *Radiology* 1997;203(3):611–20
82. Osborn AG. *Diagnostic Cerebral Angiography*. 2nd ed. Philadelphia, PA: Lippincott; 1999
83. Dewachter P, Trechot P, Mouton-Faivre C. "Iodine allergy": Point of view. *Ann Fr Anesth Reanim* 2005;24(1):40–52
84. Lasser EC, Berry CC, Mishkin MM, Williamson B, Zheutlin N, Silverman JM. Pretreatment with corticosteroids to prevent adverse reactions to nonionic contrast media. *AJR Am J Roentgenol* 1994;162(3):523–6
85. Cohan RH, Leder RA, Ellis JH. Treatment of adverse reactions to radiographic contrast media in adults. *Radiol Clin North Am* 1996;34(5):1055–76
86. Tang G, Cawley CM, Dion JE, Barrow DL. Intraoperative angiography during aneurysm surgery: A prospective evaluation of efficacy. *J Neurosurg* 2002;96(6):993–9
87. Chiang VL, Gailloud P, Murphy KJ, Rigamonti D, Tamargo RJ. Routine intraoperative angiography during aneurysm surgery. *J Neurosurg* 2002;96(6):988–92
88. Nanda A, Willis BK, Vannemreddy PS. Selective intraoperative angiography in intracranial aneurysm surgery: Intraoperative factors associated with aneurysmal remnants and vessel occlusions. *Surg Neurol* 2002;58(5):309–14; discussion 14–5
89. Lee MC, Macdonald RL. Intraoperative cerebral angiography: Superficial temporal artery method and results. *Neurosurgery* 2003;53(5):1067–74; discussion 74–5
90. Fung E, Ganesan V, Cox TS, Chong WK, Saunders DE. Complication rates of diagnostic cerebral arteriography in children. *Pediatr Radiol* 2005;35(12):1174–7
91. Vucevic M, Tehan B, Gamlin F, Berridge JC, Boylan M. The SMART needle. A new Doppler ultrasound-guided vascular access needle. *Anaesthesia* 1994;49(10):889–91
92. Dix JE, McNulty BJ, Kallmes DF. Frequency and significance of a small distal ICA in carotid artery stenosis. *AJNR Am J Neuroradiol* 1998;19(7):1215–8
93. Bjorksten G, Halonen V. Incidence of intracranial vascular lesions in patients with subarachnoid hemorrhage investigated by four-vessel angiography. *J Neurosurg* 1965;23(1):29–32
94. Marks MP, Lane B, Steinberg GK, Snipes GJ. Intracranial aneurysms in cerebral arteriovenous malformations: Evaluation and endovascular treatment. *Radiology* 1992;183(2):355–60
95. Garcia-Monaco R, Rodesch G, Alvarez H, Iizuka Y, Hui F, Lasjaunias P. Pseudoaneurysms within ruptured intracranial arteriovenous malformations: Diagnosis and early endovascular management. *AJNR Am J Neuroradiol* 1993;14(2):315–21
96. Cure JK. Personal communication. Birmingham, AL; 2007
97. Huber P. A technical contribution of the exact angiographic localization of carotid cavernous fistulas. *Neuroradiology* 1976;10(5):239–41
98. Mehlinger CM, Hieshima GB, Grinnell VS, Tsai F, Pribram HF. Improved localization of carotid cavernous fistula during angiography. *AJNR Am J Neuroradiol* 1982;3(1):82–4

3. Spinal Angiography

3.1. Introduction

Catheter angiography of the spine is much less common than cerebral angiography, but it remains the gold standard for imaging spinal vasculature. Non-invasive imaging of spinal vasculature, including high resolution MRA or CTA, can sometimes be helpful to screen for larger vascular abnormalities, but fails to provide precise information regarding flow patterns and collateral flow; many times the vessels of interest are below the spatial resolution of these non-invasive modalities. Diagnostic spinal angiography is also typically done as the first step during neurointerventional procedures involving the spine and spinal cord. The techniques and skills required for spinal angiography can overlap those required for cerebral angiography, since the upper cervical spine and spinal cord are supplied by the vertebral arteries. However, the spine extends from the base of the skull to the sacrum, and imaging the vasculature is a procedure usually entirely different from cerebral angiography.

3.2. Indications

1. Evaluation of patients with myelopathy, suspected to have spinal dural arteriovenous fistulae (most common indication).
2. Evaluation of patients with known or suspected spinal arteriovenous malformations or vascular neoplasms (e.g., with spinal intramedullary or subarachnoid hemorrhages).
3. Rarely for evaluation of suspected spinal cord ischemia (since cord blood supply is so variable, and treatment options for cord ischemia are so limited, angiography is mainly done to rule out a fistula as the cause of symptoms).
4. Planning for neurointerventional procedures on spine or spinal cord.
5. Pre-op mapping of cord vasculature prior to spinal or aortic procedures that risk occlusion of the spinal vessels.
6. Intra-operative assistance with surgery on spinal vascular lesions.
7. Follow-up imaging after treatment (e.g., after treatment of arteriovenous fistulas or malformations).

3.3. Complications of diagnostic spinal angiography

Informed consent prior to an angiogram should include a discussion of the risk of complications.

3.3.1. Neurological complications

Neurological complications in spinal angiography may include the same risk of cerebral ischemic events that may occur during cerebral angiography when the cervical region is being studied (see Chap. 2). In addition, there is the risk of vessel dissection, or embolic occlusion with thrombus, atherosclerotic plaque, or air emboli occluding the spinal cord vessels and producing myelopathy. Forbes et al reported that a series of

134 spinal angiograms had 3 (2.2%) neurological complications, all transient.¹ A more recent, but smaller series had zero complications from diagnostic spinal angiography.² High-volume contrast injection in vessels feeding the spinal cord has also been shown to produce temporary or permanent injury to the spinal cord.^{3,4}

3.3.2. Non-neurological complications

Non-neurological complications of spinal angiography via the femoral artery include the same local and systemic complications seen in cerebral angiography (as seen in Chap. 2). Forbes reported 8.2% puncture-site complications and 3.7% systemic complications from spinal angiography.¹

3.4. Selective spinal angiography: Basic concepts

3.4.1. Pre-procedure evaluation

1. Brief neurological exam should be done to establish a baseline, should a neurologic change occur during or after the procedure.
2. The patient should be asked if he or she has had a history of iodinated contrast reactions.
3. The femoral pulse, as well as the dorsalis pedis and posterior tibialis pulses should be examined.
4. Blood work, including a serum creatinine level and coagulation parameters, should be reviewed.

3.4.2. Pre-angiogram orders

1. NPO except medications for 6 h prior to the procedure.
2. Place 1 peripheral IV (2 if an intervention is anticipated)
3. Place Foley catheter (almost always, unlike cerebral angiography)

3.4.3. Sedation/Analgesia/Anesthesia

There is variable use of general anesthesia vs. conscious sedation for spinal angiography. The advantage of general anesthesia is that it allows for patient immobility including prolonged interruption of respiration while imaging tiny spinal vessels that are present in the thoracic and lumbar region. General anesthesia also spares the patient the potential discomfort of a long, involved angiographic procedure. Using non-ionic, iso-osmolar contrast, procedures can be done under local anesthesia with minimal sedation, and adequate image quality is possible in cooperative patients. The advantage of local anesthesia is the avoidance of any of the potential complications of general anesthesia and the ability to monitor the neurological status of the patient during the procedure. The limited ability to monitor the neurological status of the patient during general anesthesia may be partially mitigated by the use of neurophysiological monitoring, such as somatosensory and/or motor evoked potentials.² However, neurophysiological monitoring adds to the cost and complexity of the procedure, and may not be readily available or reliable, depending on the institution.

3.4.4. Contrast agents

Non-ionic contrast agents are almost always used due to their lower osmolality and better tolerance when injected into the small vessels feeding the spine. Iodixanol

(Visipaque™, GE Healthcare, Princeton, NJ), an iso-osmolar and a nonionic contrast agent, is more expensive and more viscous than other contrast agents commonly used but is the best tolerated agent for spinal angiography.

1. Diagnostic angiogram: Omnipaque®, 300 mg I mL⁻¹, or Visipaque™, 320 mg I mL⁻¹
2. Neurointerventional procedure: Omnipaque®, 240 mg I mL⁻¹ or Visipaque™, 270 mg I mL⁻¹

Patients with normal renal function can tolerate up to 400–800 mL of Omnipaque®, and 300 mg I mL⁻¹ without adverse effects.⁵ Contrast volumes in spinal angiography can routinely approach these limits, given the large number of injections required.

3.4.5. Femoral artery sheath

Trans-femoral spinal angiography is almost always done with a sheath.

Sheath:

1. Advantages: allows the rapid exchange of catheters and less potential for trauma to the arteriotomy site. Spinal angiography frequently requires several different catheters per case.
2. Unlike cerebral angiography, catheter position is often tenuous in the vessels being selected, and the sheath allows for more precise manipulation and positioning of the catheter.
3. Short sheath (10–13-cm arterial sheath) is used most commonly.
4. Longer sheath (25 cm) is useful when iliac or femoral artery tortuosity or atherosclerosis can impair catheter navigation. Longer sheaths may need to be pulled back, partially out of the iliac artery, when selective catheterization of the ipsilateral internal iliac artery is needed.
5. Technique: Standard arterial puncture techniques are used. Most commonly, a 5 F or 6 F sheath (Pinnacle® Sheath; Terumo Medical, Somerset, NJ) is used. The lumen of the sheath (and also of the angiographic catheter) is continuously perfused with heparinized saline (5,000 U heparin per liter of saline) under arterial pressure.

No sheath:

1. Spinal angiography without a sheath offers the advantage of a slightly smaller arteriotomy, but is rarely done.
2. Situations in which a sheath may not be needed include pediatric cases, in which a smaller arteriotomy is desired, and very limited follow-up angiograms in which only one catheter may be used for a quick procedure.

3.4.6. Suggested wires and catheters for diagnostic spinal angiography

3.4.6.1. Hydrophilic wires

- 0.035' or 0.038' J-tip wire for sheath insertion.
- The 0.035' angled Glidewire® (Terumo Medical, Somerset, NJ) is soft, flexible, and steerable.

Catheter	Use
5 F Angled Taper	Good all-purpose diagnostic catheter for supra-aortic vessels
5 F Mikaelsson	Good all-purpose catheter for intercostal and lumbar arteries
5 F Simmons 1	Alternative to Mikaelsson
4 or 5 F Cobra	Intercostal and lumbar arteries in younger patients
5.5 F RDC	Very stable and torquable, but stiff
5 F Straight	For retrograde flush aortic runs

- The 0.038' angled Glidewire® (Terumo Medical, Somerset, NJ) is slightly stiffer than the 0.035' and helpful when added wire support is needed.

3.4.7. Vessel catheterization

Selective spinal angiography may be either complete spinal angiography, or a partial, focused study for a specific lesion. Complete spinal angiography is a major undertaking, in which all vessels that may relate to the spinal canal are selectively catheterized and studied. This is most often used in the evaluation of a patient with a suspected dural arteriovenous fistula causing myelopathy. The lesion can be anywhere from the head to the sacrum, and evaluation of all vessels supplying these structures may be required. This may require selective angiography of the right and left internal and external carotid arteries, vertebral arteries, thyrocervical and costocervical trunks, subclavian arteries, intercostal and lumbar arteries, ileolumbar arteries, and anterior and lateral sacral arteries. When the lesion to be evaluated is known to be confined to a specific region of the spine, a more focused study may be more appropriate. This should include all the vessels that supply the area of interest, and the levels above and below the lesion, given the possibility of collateral flow from adjacent spinal vessels. Another useful rule of thumb is to visualize normal spinal cord vessels above and below any lesion affecting the cord.

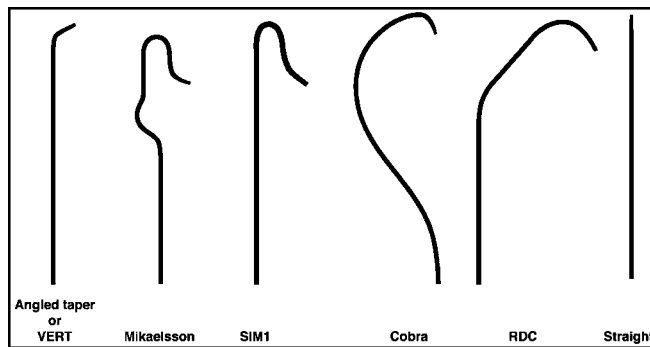


Fig. 3.1 Recommended diagnostic catheters.

Table 3.1 Blood supply to various spinal regions

Level	Feeding arteries
Upper cervical	Vertebral, ascending pharyngeal, occipital, deep cervical
Lower cervical	Vertebral, deep cervical, ascending cervical
Upper thoracic	Supreme intercostal, superior intercostal
Mid-lower thoracic	Intercostal
Upper-to-mid lumbar	Lumbar
Lower lumbar	Ileolumbar
Sacrum	Anterior and lateral sacral

3.4.8. Roadmapping

Roadmapping can be used to aid catheterization of the supra-aortic vessels, such as vertebral arteries, and the thyrocervical and costocervical trunks. Roadmapping is less helpful in catheterizing the intercostals and lumbar arteries, since respiratory motion degrades the image.

3.4.9. Double flushing

Catheter flushing technique is discussed in Chap. 2. Although some practitioners advocate double flushing of catheters only in the supra-aortic vessels, it makes more sense to use a meticulous flushing technique anywhere in the vascular system. This ensures that one will not forget to use good technique when it is most needed. Moreover, thrombus or air emboli in spinal cord vessels can be just as devastating as cerebral ischemia.

3.4.10. Continuous saline infusion

Three-way stopcock or manifolds can be used to provide a heparinized saline drip through the catheter. This is particularly useful for long spinal angiographic procedures. A rotating adapter on the stopcock is needed to prevent the stopcock from being a drag on free manipulation of the catheter. Using both a rotating three-way stopcock and a rotating hemostatic valve on the catheter allows for two pivot points to allow free rotation of the catheter. This is important as the catheter may not be in a stable position in the small lumbar and intercostal arteries.

3.4.11. Hand injection

Frequent small injections (“puffing”) of contrast can be used to help manipulate the catheter into the desired lumbar and intercostal arteries. A 20 mL syringe containing contrast can be left attached to the catheter for these injections, and then used immediately for hand injections of contrast for angiographic runs. As is done in the cerebral vasculature, the syringe is held vertically and care is taken not to allow bubbles to enter the catheter. Most spinal vessels are best imaged with hand injections of contrast, to allow for modulation of the injection rate and volume, depending on the size of the vessel and stability of the catheter. An adequate angiographic run can be usually done with a single 2–3 second injection of 4–6 mL (100% contrast) of contrast. The goal is to adequately opacify the vessel of interest without displacing the catheter or refluxing too much into the aorta or into the ever-present collaterals to other spinal vessels. Patients should be warned that they will experience warmth and/or cramping in the territory of the injected vessel, and breathing should be suspended during the angiographic run, but the phase of respiration at which the breath-holding should occur depends on the spinal level being imaged (see below).

3.4.12. Mechanical injection

A power contrast injector is necessary for thoracic or lumbar aortic angiograms, and for large vessels such as subclavian or iliac arteries. As stated in Chap. 2, the pressure and flow rate settings should not exceed the ratings of the stopcock or catheter. Common power injector settings for vessels studied in spinal angiograms using a 5 F catheter are listed in Table 3.2. Note that these rates and volumes may need to be increased or decreased depending on the size of the vessels, the stability of the catheter, and the quickness of the runoff of the contrast on your test injection. Use *extreme* caution if your catheter is wedged in the vessel and be especially careful if there is a possibility that a spinal cord vessel is arising from the branch you are injecting, since high pressure power injections can damage the cord. *When in doubt, just use careful hand-injections of contrast.*

Table 3.2 Standard power injector settings^a

Vessel	Power Injector Settings
Aortic arch	20 mL s ⁻¹ ; total of 25 mL
Retrograde aortic flush	10 mL s ⁻¹ ; total of 30 mL
Iliac artery	10 mL s; total of 20 mL
Subclavian artery	6 mL s; total of 15 mL
Vertebral artery	6 mL s; total of 8 mL
Lumbar or intercostal artery	2 mL s; total of 6 mL
For 3D imaging	0.5–2 mL s ⁻¹ ; total 7–30 ml (higher doses for high flow AVF)

^a For digital subtraction angiography using a 5 F catheter

3.4.13. Vessel selection

If the exact level of the lesion is known from non-invasive imaging, the spinal angiogram should begin with those vessels supplying that area. Following catheterization of the vessel of interest, it is then customary to work systematically above and below the lesion to include normal territory adjacent to the lesion. Lesions of the cord itself usually require mapping of the spinal cord supply above and below the lesion. For complete spinal angiography, it is particularly important to image the intercostal and lumbar arteries in a systematic fashion so that one does not inadvertently miss or repeat a level. It is helpful to maintain a worksheet during the procedure, and list the sides and vessels injected during each angiographic run. Radio-opaque marker rulers can be placed under the patient on the table or marker tapes can be affixed to the patient's back, slightly off mid-line to have a reference available on each film to help confirm the levels studied. Additionally, bony landmarks, such as the 12th rib, can also help with keeping track of the vessels being studied.

3.4.14. Angiographic images and standard views

Spinal angiography has a number of features that make it less desirable to use biplane imaging routinely. The vascular anatomy is usually quite simple compared to cerebral vessels. Moreover, when one images the spine in lateral view, higher doses of x-rays are required to adequately penetrate the thoracic or lumbar region to give good visualization of the structures. Consequently, to limit the radiation dose to the patient and operator, and to prevent over-heating the X-ray tube, usually only single plane, frontal images of the thoracic, lumbar, and sacral spine are usually performed. Lateral views are taken when the vessels supplying the lesion are found. Additionally, when a complex vascular lesion is found, 3D rotational imaging can be done when the proper imaging equipment is available. Prestigiaco et al.⁶ found that 3D imaging was better than conventional angiography for spinal AVMs in determining the relationship of lesions to the spinal cord and detecting intranidal aneurysms. Three-dimensional imaging requires general anesthesia to ensure immobility during the 15 s imaging acquisition and contrast must be slowly injected in the vessel of interest for approximately 15–17 s beginning 1 s prior to starting the acquisition to ensure that the vessels are opacified throughout the full rotation of the gantry.

1. When viewing the spinal angiographic images, the normal anatomic features should be recognized. Segmental spinal vessels have osseous branches that supply the vertebra at that level, radicular branches, variable radiculomedullary branches that connect to the anterior spinal artery, variable radiculopial branches that feed the posterolateral spinal arteries, muscular branches, and anastomoses to the contralateral and cephalad and caudal adjacent segmental branches.
2. Other imaging features worthy of attention during the performance of a spinal angiogram:

- (a) Vessel contour and size (angioarchitecture).
- (b) Presence or absence on contribution to spinal cord. Look for the hair-pin turn of the artery of Adamkiewicz and fairly straight ascending and/or descending vessels in the spinal canal.
- (c) Presence of abnormal or unexpected vascular channels (neovascularity).
- (d) Presence or absence of an abnormal vascular blush. Note that normal muscle and bone normally display a vascular blush.
- (e) Early venous filling indicative of an AV shunt.
- (f) When there is a shunt, where do the veins drain to?
- (g) Injection of intercostals or lumbar arteries that fill the anterior spinal artery should be examined for the appearance of the coronal venous plexus of the spinal cord within about 15 s after contrast injection. Lack of visualization of the veins along the cord and the radicular veins that anastomose with the epidural veins can be evidence of the presence of severe spinal venous hypertension.

3.5. Normal spinal angiographic images

Pearl

Remember the anterior spinal artery is in the midline. The posterolateral spinal arteries are slightly off midline.

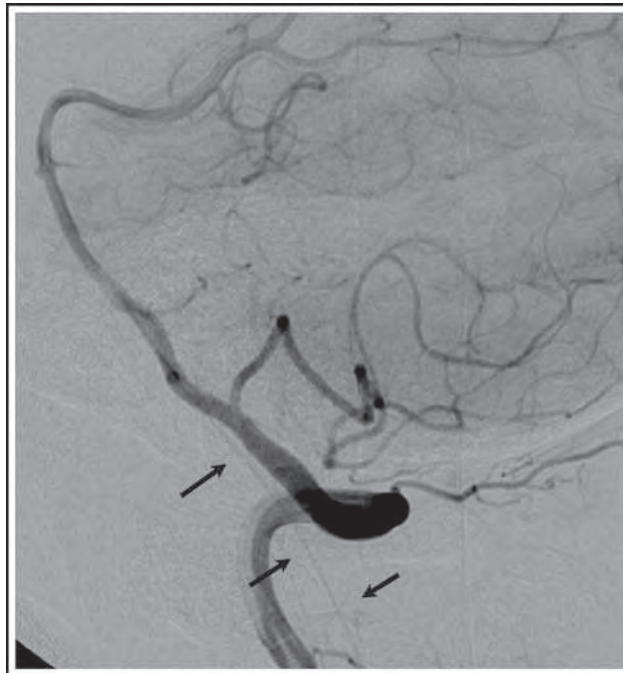


Fig. 3.2 Lateral vertebral artery angiogram showing anterior spinal artery (arrows).

3.5.1. Frame Rates for digital subtraction angiography

Most spinal angiography can be done with relatively slow frame rates of 1 or 2 frames per second (fps). Most arteriovenous fistulae in the spine are relatively slow filling. Only very high flow arteriovenous shunts would require 3 fps or faster imaging. Routine use of fast frame rate while imaging the spine below the cervical region will soon overheat the X-ray tube and may not even be possible with lower quality imaging chains. For most spinal arteriography, a 10–12s imaging sequence allows for visualization of arterial, capillary, and venous phases. However, when screening for causes of spinal venous hypertension, such as a spinal dural AVF, injection of the segmental vessel supplying the artery of Adamkiewicz may require imaging for 20–25s to visualize the venous phase of the spinal cord vasculature.

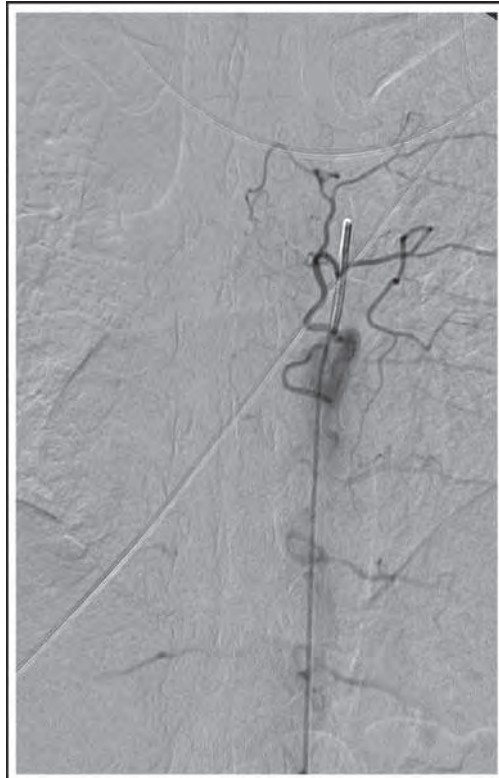

Fig. 3.3 Superior intercostal artery.

3.5.2. Calibration and measurement

Size measurements and calibration can be done as mentioned in Chap. 2. In spinal angiography, radio-opaque rulers may be placed under the patient for reference, and utilized for calibration.

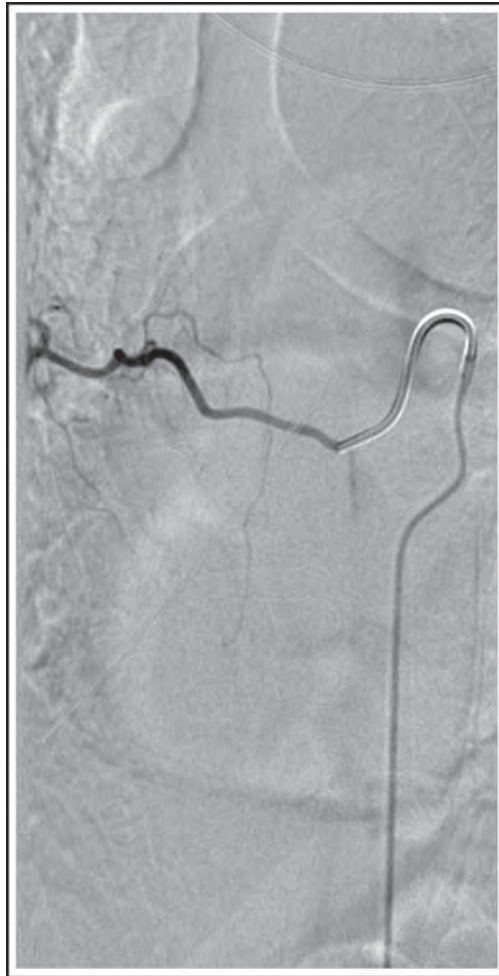

Fig. 3.4 Intercostal artery.

3.6. Spinal angiographic procedures

3.6.1. Femoral artery puncture

1. Standard arterial access is obtained (see Chap. 2).
2. A femoral arterial sheath is placed (5 or 6 French).

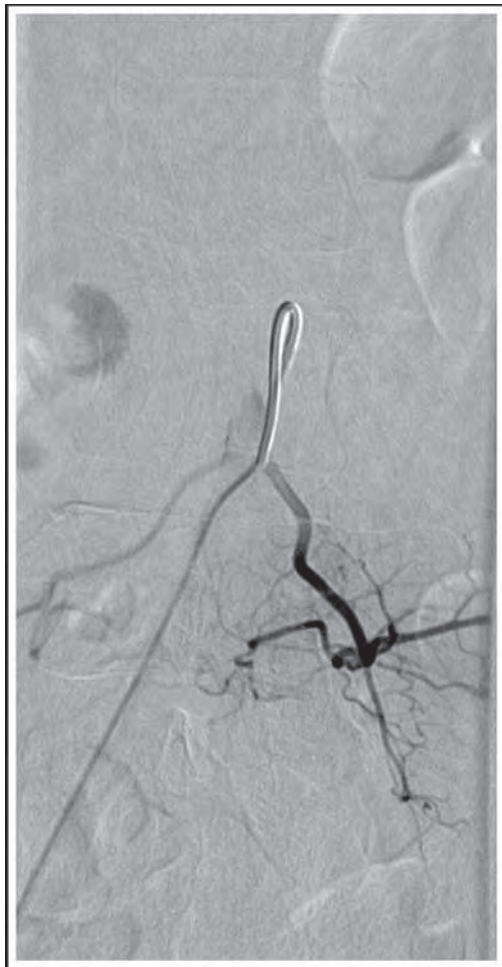

Fig. 3.5 Lumbar artery.

3.6.2. Brachial/Axillary/Radial artery catheterization

1. Very rarely, spinal angiography may require access from the arm if there are femoral, iliac, or aortic occlusions.
2. If lower lumbar arteries must be imaged using an upper extremity artery for access, use an axillary approach, since even 100 cm catheters may not reach from a radial or even brachial approach.

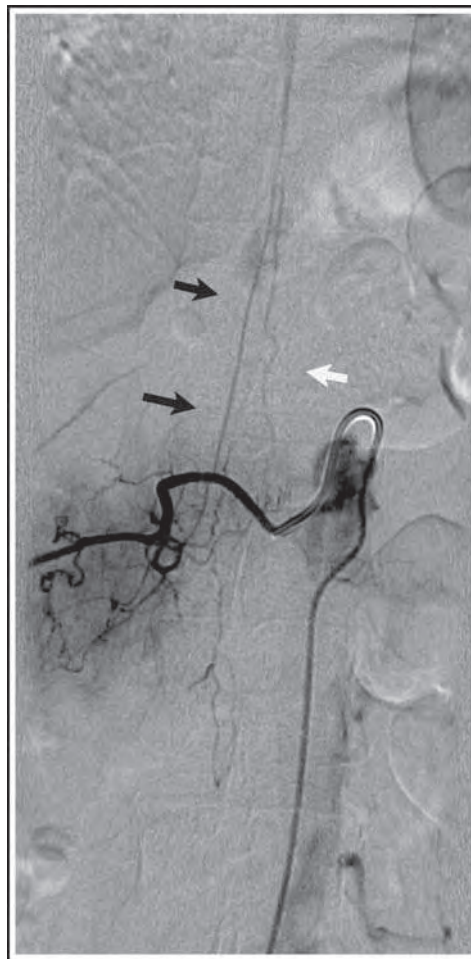


Fig. 3.6 L1 lumbar artery injection showing artery of Adamkiewicz (*black arrows*), with the characteristic hairpin turn followed by the anterior spinal artery (*white arrow*).

3.6.3. Aortic imaging

1. Screening aortic injections by pigtail catheter are a way to get a rough idea of vascular anatomy in the thoracic and lumbar region.
2. It is most helpful in elderly patients with aortic atherosclerosis or aortic aneurysms to see which segmental vessels may be occluded.
3. As a rule, aortic injections provide poor visualization of small spinal vessels, so they do not eliminate the need for selective spinal angiography.
4. In the lumbar region, pigtail catheter injections fill all the visceral vessels as well as the lumbar arteries. This can obscure even fairly extensive vascular abnormalities in the spine.
5. For most cases, it is not worth wasting the time or contrast on aortic injections.

3.6.4. Retrograde aortic flush

1. Better visualization of the segmental spinal arteries can be obtained with a retrograde aortic flush, as opposed to standard pigtail injections.^{7,8}
2. Bilateral femoral arterial sheaths are required (5 or 6 Fr).
3. A straight catheter (5 or 6 Fr) is positioned in each common iliac artery.
4. Simultaneous power injection of contrast in each catheter is needed. A sterile Y-connector that is rated for high pressure can connect the tubing from the injector to both catheters. Alternatively, two separate injector machines may be used.
5. 20 mL s⁻¹ for a total of 50 mL distributed equally between the two catheters is injected.
6. Contrast usually streams up the posterior wall of the aorta, providing visualization of the lumbar, and lower intercostal arteries, with less obscuration of the anterior visceral arteries.
7. More viscous contrast, such as Omnipaque 350 or Visipaque 320 works best with this technique.
8. Usually no more than 5 vertebral levels are well imaged by this technique. The catheters may need to be positioned in the upper lumbar aorta to visualize the higher thoracic levels.
9. This technique is still not a replacement for selective spinal angiography.
10. Retrograde aortic flush is *contraindicated* in very tortuous aorta or iliac vessels, in the presence of extensive atherosclerosis, or aortic or iliac aneurysmal disease, due to a risk of dissection or plaque disruption.

3.6.5. Intercostal and lumbar artery catheterization

1. For complete spinal angiography, these segmental vessels constitute the majority of the vessels to be studied.
2. Unless the exact site of a lesion is known from other imaging studies, the segmental spinal vessels should be studied in a systematic fashion to ensure that all are being visualized.
3. Using a Mikaelsson or Simmons catheter, it is often most efficient to go from caudal to cranial, to avoid un-forming the curve of the catheter.
4. Using most other catheters, such as Cobra catheters, it works best to go from cranial to caudal.
5. From one level to the next, the segmental vessels come off at similar positions along the wall of the aorta, so it is best to go from one level to the next and do all on one side before going back and doing all on the other side. This is much quicker than rotating the catheter from one side to the other at each level.
6. The catheter is slowly rotated and moved forward or backward while puffing small amounts of contrast until the desired vessel is engaged.
7. The catheter is gently pulled back to ensure it is seated in the vessel.

8. The catheter should be held in position with one hand to prevent it from rotating out of the vessel, and contrast injected for an angiographic run, during transient arrest of respiration.
9. Keeping the catheter at the same angle of rotation, it is then gently pushed forward (for Mikaelsson or Simmons) or withdrawn (for Cobra) to disengage from the vessel.
10. Again keeping the same angle of rotation, the catheter is moved to the next vertebral level and it should just pop into the lumbar or intercostal branch.
11. Alternatively, the catheter can be left in the branch, then slowly rotated toward the right or left until it enters the contralateral segmental branch at the same vertebral level.
12. Continue the process in a systematic fashion until all the desired vessels are studied.

3.6.6. Optimizing images by reducing respiratory or other motion

General anesthesia can be used to prevent patient motion. With or without general anesthesia, imaging the intercostals and lumbar arteries should be done during breath-holding. For lower lumbar imaging, the patients can hold their breath in either inspiration or expiration, whichever moves aerated bowel away from the area of interest. Upper lumbar and lower thoracic imaging is best if the patients hold in expiration, to keep the interface of lung and diaphragm out of the imaging field. In the mid thoracic region above the diaphragm, the patients should hold their breath in inspiration, to keep the diaphragm below the area of interest. In the upper thoracic region, catheter positioning is frequently very tenuous, and deep respirations in anticipation of breath holding can displace the catheter. In this region it is best to have the patient suspend respiration without deep inspiration or expiration.

In the lumbar region, bowel peristalsis can sometimes degrade subtraction images. Bowel movement can be temporarily slowed by injecting 1 mg of glucagon or 40 mg of hyoscine-N-butylbromide (Buscopan®; Boehringer Ingelheim GmbH, Germany) IV just prior to acquiring the images.⁹

Pearls

To facilitate catheterization of the intercostal and lumbar arteries, remember the following facts:

1. The more caudal you go, the more posterior the origins of the segmental vessels are,¹⁰ and the more symmetrical the origin of the right and left segmental vessel.
2. Upper thoracic right-sided intercostal arteries arise from the lateral wall of the aorta; the left are more posterior. Right and left lower lumbar arteries both arise from the posterior wall of the aorta.
3. Lower lumbar arteries may have a common origin of both the right and left lumbar artery from the aorta.
4. In lumbar and lower thoracic regions, segmental branches usually arise just below the level of the pedicle.
5. In the more cephalad levels in the thoracic region, the intercostal arteries are closer together, and slope cephalad to supply vertebral levels above the level of the aorta from which they arise.
6. The highest intercostal arteries are close together, and their angulation often makes it difficult to keep the catheter in a stable position in the vessel.
7. The superior intercostals are just below the aortic arch and ascend and variably supply two or three thoracic vertebral levels above the origins of the vessels.
8. Do not forget that the supreme intercostals are at the costocervical trunks (hence, the name "costo-"cervical) and supply the most cranial two or three thoracic levels.

3.6.7. Sacral and ileolumbar artery catheterization

1. The anterior sacral artery starts at the aortic bifurcation, and is usually catheterized with any reverse-curve catheter (like Mikaelsson or Simmons).
2. Ileolumbar and lateral sacral arteries come off the internal iliac arteries.
3. Common iliac injections can be done to locate the spinal vessels to be selected.
4. Iliac arteries and their branches contralateral to the femoral puncture site are catheterized by engaging the iliac with the catheter, then advancing a hydrophilic wire well down into the contralateral femoral artery. The catheter is then advanced antegrade over the wire into the external iliac. While injecting small amounts of contrast, it is slowly pulled back and rotated until the desired vessel is catheterized.
5. Iliac arteries ipsilateral to the femoral puncture require a fully formed Mikaelsson or Simmons in the aorta, which is slowly withdrawn and rotated so that it points back into the ipsilateral iliac. As small amounts of contrast are injected, it is withdrawn and rotated into the vessel of interest.
6. The ipsilateral iliac vessels can often be well imaged from a retrograde injection of a catheter or sheath with its tip in the distal external iliac artery.
7. If a sheath is used, it may have to be pulled back into the external iliac to allow catheterization of the iliac branches.
8. Truly selective injections of the ileolumbar and lateral sacral arteries may require the use of a microcatheter/micro-guidewire assembly placed coaxially through the 5-French catheter positioned with its tip at the origin of the internal iliac artery.
9. Ileolumbar arteries are at the very proximal internal iliac and the lateral sacral a little more distally off the posterior division of the internal iliac.
10. Warn patients that they will feel the heat of the contrast in very private places when injected in the iliac arteries and their branches.

3.6.8. Vertebral artery catheterization

1. For complete spinal angiography, the vertebral arteries must be studied.
2. Vertebral artery catheterization is discussed in detail in Chap. 2.
3. The vertebral arteries fill the anterior spinal arteries at the vertebrobasilar junction and the posterolateral spinal arteries proximal to, or directly from, PICA.
4. Remember that segmental branches of the vertebral may contribute also to the spinal cord. If the catheter tip is positioned too high up in the vertebral artery, lower segmental feeders to the cord may be overlooked.

3.6.9. Thyrocervical/Costocervical trunk catheterization

1. For complete spinal angiography, these subclavian artery branches must be studied.
2. For most cases, a simple curve on the catheter (Angled Taper, Vertebral, or Berenstein curves) works best.
3. Advance the catheter over a wire into the subclavian artery well beyond the origin of the vertebral artery.
4. Double flush the catheter, then slowly withdraw the catheter, keeping the tip pointed cephalad, while gently injecting small quantities of contrast until the catheter engages the desired vessel.
5. The costocervical trunk is just distal to the thyrocervical trunk, which is just distal to the vertebral artery.
6. There may be an anomalous artery of the cervical enlargement, supplying the cord directly from the subclavian.
7. With tortuous vessels or confusing anatomy, a subclavian injection, using a slight ipsilateral oblique view, can help.

3.6.10. Carotid artery catheterization

1. For complete spinal angiography, branches of the carotid arteries must be studied.
2. Carotid artery catheterization is discussed in detail in Chap. 2.
3. External and internal carotid injections, and preferably, selective injections of ascending pharyngeal and occipital arteries are needed. The middle meningeal artery may also contribute to AV fistulae that drain to the spinal cord veins.

3.6.11. Reconstituting a Mikaelsson catheter

The Mikaelsson catheter has a reverse curve that must be reconstituted after the catheter is introduced into the aorta, similar to the Simmons catheter. The Simmons 2 catheter is discussed in detail in Chap. 2. The Mikaelsson can be reconstituted if a wire is advanced into the contralateral iliac artery or a renal artery. The catheter is then advanced over the wire until the primary curve is just into the iliac or renal artery. Then the wire is pulled back and the catheter gently advanced, reforming the shape of the reverse curve. As the catheter continues to advance, it will pull out of the engaged renal or iliac artery and be fully formed in the aorta. Sometimes the catheter will spontaneously reform its shape if it is advanced up to the aortic arch distal to the left subclavian artery and rotated. Reconstitution in the left subclavian or the aortic valve is not an option due to the short length of the catheter.

Remember that pulling back on the Mikaelsson can engage intercostal arteries, lumbar arteries, and those pesky visceral vessels, which can un-form the catheter curve if it is pulled back further. The catheter should always be pulled back slowly under fluoroscopic visualization, as the catheter is constantly rotated to avoid snagging vessels along the way.

3.6.12. Femoral artery puncture site management

Arterial puncture site management and closure techniques and devices are discussed in Chap. 2.

3.6.13. Post-angiogram orders

1. Bed rest with accessed leg extended, head of bed $\leq 30^\circ$, for 6 h, then out of bed for 1 h. (If a closure device is used, bed rest, with head of bed $\leq 30^\circ$, for 1 h, then out of bed for 1 h).
2. Vital signs: Check on arrival in recovery room, then Q 1 h until discharge. Call physician for SBP < 90 mmHg or decrease 25 mmHg; pulse > 120 .
3. Check puncture site and distal pulses upon arrival in recovery room, then Q 15 min $\times 4$, Q 30 min $\times 2$, then Q 1 h until discharge. Call physician if
 - (a) Bleeding or hematoma develops at puncture site.
 - (b) Distal pulse is not palpable beyond the puncture site.
 - (c) Extremity is blue or cold.
4. Check puncture site after ambulation.
5. IVF: 0.9 N.S. at 100 mL h^{-1} until patient is ambulatory.
6. Resume pre-angiogram diet.
7. Resume routine medications.
8. PO fluids 500 mL.
9. D/C Foley catheter and IV prior to discharge.
10. Check BUN and creatinine 24–48 h post procedure if very large volumes of contrast were used.

3.7. Special techniques and situations

3.7.1. Intraoperative spinal angiography

Intraoperative spinal angiography is employed by some neurosurgeons during surgery for spinal AV fistulae and arteriovenous malformations.¹¹ It can be helpful to localize small lesions and to confirm complete removal of lesions. It correlates well with post-operative angiography in the angiography suite, and can show an unexpected residual AV shunt in up to 33% of cases.¹² Intraoperative spinal angiography poses technical challenges compared to intraoperative cerebral angiography. First, the patient is usually prone during the operation. This requires that a long (at least 25 cm) sheath be placed in the femoral artery prior to the patient being positioned prone. The sheath is only inserted a short distance, and is positioned so that its hub is along the lateral aspect of the hip, so it can be accessed after the patient is turned prone. An alternative for arterial access is a trans-radial approach.¹³ Another potential challenge is the fact that most operating room tables are not radiolucent, which can make it a challenge getting the right C-arm angle to visualize the catheter and the desired vessels. A Jackson frame should be used instead of an operating table if possible. Prone positioning can also confuse the angiographer and make catheterization of the desired vessels difficult.¹⁴ An easy aid to catheterization is to reverse the fluoroscopic image side-to-side when working the catheter on a prone patient. These challenges may be overcome, but are one reason why intraoperative spinal angiography is not more commonly practiced.

3.8. Tips for imaging specific lesions

3.8.1. Spinal intra-or perimedullary arteriovenous malformations

- All feeding arteries and draining veins should be identified; this requires visualization of the spinal cord vessels at the level of the lesion, and several segmental levels above and below the lesion.
- Normal spinal arteries should be seen above and below the lesion to ensure all feeders have been seen.
- Biplane, magnified runs are useful to evaluate the architecture and relationship to the cord.
- Rapid imaging rates of 3–5 fps can sometimes provide a better visualization of the angio-architecture of the lesion.
- Images should be carefully evaluated to determine how the lesion relates to the anterior and posterolateral spinal arteries.
- Intranidal aneurysms/pseudo-aneurysms need to be looked for.
- 3D imaging may be useful

3.8.2. Spinal perimedullary arteriovenous fistulae

- These are uncommon, congenital fistulae that are usually obvious on noninvasive imaging.
- Like other vascular malformations, normal spinal arteries should be seen above and below the lesion to ensure all feeders have been seen.
- Biplane, magnified runs are useful to evaluate the architecture and relationship to the cord.
- These are high flow lesions, requiring rapid imaging rates of 3–15 fps.
- 3D imaging may be useful.

3.8.3. Dural arteriovenous fistulas

- By far the most common suspected indication for spinal angiography.
- Even if the area of myelopathy is known from clinical symptoms and non-invasive imaging, the site of the arteriovenous fistula may be remote from the area affected, so be prepared to do complete spinal angiography.
- Look for an enlarged vein filling from a radicular or a lumbar or intercostal artery in most cases.
- Occasionally, the fistula may be found at the craniocervical junction,¹⁵ intracranially,¹⁶ or in the paraspinal region.¹³
- In cases of thoracic myelopathy from a dural AV fistula, lack of visualization of the coronal venous plexus and radicular veins after injection of the artery of Adamkiewicz provides convincing evidence for venous hypertension and confirms the diagnosis of an AV fistula.
- Conversely, good visualization of normal spinal cord veins within 15 s after seeing the artery of Adamkiewicz makes the diagnosis of AV a fistula much less likely.

3.8.4. Spinal intramedullary vascular tumors

- The most common indication is spinal hemangioblastoma, usually preoperative and/or pre-embolization.
- All feeding arteries and draining veins should be identified; this requires visualization of the spinal cord vessels at the level of the lesion, and several segmental levels above and below the lesion.
- Biplane, magnified runs are useful to evaluate the architecture and relationship to the cord.

3.8.5. Spinal extradural vascular tumors

- Usual indications are in cases of pre-operative evaluation of patients with aneurysmal bone cyst or vascular metastases such as renal or thyroid cancer.
- All feeding arteries should be identified; this requires visualization of the segmental spinal vessels bilaterally at the level of the lesion, and several segmental levels above and below the lesion.
- Normal spinal arteries at the level of the lesion or at nearby levels should be identified so that they can be carefully spared during any anticipated embolization procedure or at the time of surgery.

3.8.6. Preoperative angiography for surgery that may risk occlusion of the spinal cord blood supply

- Major spinal surgery, aortic aneurysm repair, or stent-grafts may carry a risk of ischemic myelopathy if radiculomedullary contributors to the anterior spinal artery, and adjacent segmental vessels are all occluded.
- Preoperative spinal angiography can locate the variable spinal cord vessels. If a dominant spinal cord feeder is at risk in the surgical field it could be spared, or the feeding intercostal or lumbar artery could be reimplanted into the aorta.

3.9. References

1. Forbes G, Nichols DA, Jack CR, Jr., et al. Complications of spinal cord arteriography: prospective assessment of risk for diagnostic procedures. *Radiology* 1988;169(2):479-84.
2. Niimi Y, Sala F, Deletis V, Setton A, de Camargo AB, Berenstein A. Neurophysiologic monitoring and pharmacologic provocative testing for embolization of spinal cord arteriovenous malformations. *AJNR Am J Neuroradiol* 2004;25(7):1131-8.
3. Miller DL. Direct origin of the artery of the cervical enlargement from the subclavian artery. *AJNR Am J Neuroradiol* 1993 Jan-Feb;149(10):242-4.

4. Ramirez-Lassepas M, McClelland RR, Snyder BD, Marsh DG. Cervical myelopathy complicating cerebral angiography. Report of a case and review of the literature. *Neurology* 1997 Sep;27(9):834-7.
5. Rosovsky MA, Rusinek H, Berenstein A, Basak S, Setton A, Nelson PK. High-dose administration of non-ionic contrast media: a retrospective review. *Radiology* 1996;200(1):119-22.
6. Prestigiacomo CJ, Niimi Y, Setton A, Berenstein A. Three-dimensional rotational spinal angiography in the evaluation and treatment of vascular malformations. *AJNR Am J Neuroradiol* 2003;24(7):1429-35.
7. Rauste J, Somer K. Semiselective renal angiography, a useful method for evaluating the vascular supply in both kidneys. *Radiol Clin (Basel)* 1997;46(4):281-8.
8. Ogawa R. [Semiselective renal and lumbar angiography: experimental and clinical evaluation of this new angiographic method]. *Nippon Igaku Hoshasen Gakkai Zasshi* 1995 Jan;55(1):20-33.
9. Kozak RI, Bennett JD, Brown TC, Lee TY. Reduction of bowel motion artifact during digital subtraction angiography: a comparison of hyoscine butylbromide and glucagon. *Can Assoc Radiol J* 1994;45(3):209-11.
10. Shimizu S, Tanaka R, Kan S, Suzuki S, Kurata A, Fujii K. Origins of the segmental arteries in the aorta: an anatomic study for selective catheterization with spinal arteriography. *AJNR Am J Neuroradiol* 2005;26(4):922-8.
11. Barrow DL, Colohan AR, Dawson R. Intradural perimedullary arteriovenous fistulas (type IV spinal cord arteriovenous malformations). *J Neurosurg* 1994;81(2):221-9.
12. Schievink WI, Vishteh AG, McDougall CG, Spetzler RF. Intraoperative spinal angiography. *J Neurosurg* 1999;90(1 Suppl):48-51.
13. Lang SS, Eskioglu E, Mericle RA. Intraoperative angiography for neurovascular disease in the prone or three-quarter prone position. *Surg Neurol* 2006;65(3):283-9; discussion 9.
14. Benes L, Wakat JP, Sure U, Bien S, Bertalanffy H. Intraoperative spinal digital subtraction angiography: technique and results. *Neurosurgery* 2003;52(3):603-9; discussion 8-9.
15. Pulido Rivas P, Villoria Medina F, Fortea Gil F, Sola RG. [Dural fistula in the craniocervical junction. A case report and review of the literature]. *Rev Neurol* 2004;38(5):438-42.
16. Li J, Ezura M, Takahashi A, Yoshimoto T. Intracranial dural arteriovenous fistula with venous reflux to the brainstem and spinal cord mimicking brainstem infarction - case report. *Neurol Med Chir (Tokyo)* 2004;44(1):24-8.
17. Rodesch G, Lasjaunias P. Spinal cord arteriovenous shunts: from imaging to management. *Eur J Radiol* 2003;46(3):221-32.

4. Neuroendovascular Suite

This chapter addresses the design and staffing of the endovascular suite, as well as monitoring and pharmacological considerations. The objectives of this chapter are to provide an introduction to residents and fellows new to the angio suite, and serve as a guideline for experienced operators planning a new suite.

4.1. Organization and essential equipment

The neurointerventional suite should be dedicated to the neurointerventional service. The AHA Intercouncil Report on Peripheral and Visceral Angiographic and Interventional Laboratories produced detailed recommendations for the design and equipment needed for an interventional suite.¹ Although these guidelines were not designed specifically for neurointerventional suites, they are a useful resource for planning and equipment selection. Once new equipment is installed, a medical physicist should be contracted to check out the equipment to ensure that all the specifications are met and that the image quality is adequate. In addition, annual checks by the physicist are necessary to maintain image quality and minimize radiation dose.

1. Size. The procedure room should be large enough to accommodate anesthesia personnel and their equipment, as well as additional personnel and equipment that may be needed for particular procedures. For example, electroencephalography and other electrophysiology monitoring devices are required during Wada testing. The size of a typical interventional suite is at least 30 × 25 feet, or 750 square feet, with a ceiling height of 10–12 feet.^{1,2}
2. Entrances. Separate entrances for patient transportation and for personnel, usually from the control room, facilitate rapid room turnover and reduce crowding.
3. Standard equipment.
 - (a) Wall-mounted light boxes (preferably in the control room, rather than the suite, to reduce glare)
 - (b) Sinks for waste and for cleaning
 - (c) Telephone
 - (d) Glass-fronted storage cabinets for equipment and devices.
4. Anesthesia requirements. The room should be equipped with oxygen, suction, gas evacuation lines, and a separate telephone for anesthesia personnel.
5. Lighting.
 - (a) Overhead lights should be controlled with a rheostat to allow dimming of the room lights.
 - (b) Foot pedals to control the lights and an overhead spotlight to illuminate procedures (such as during wire and catheter shaping and arterial access site closure) are helpful.
6. Tables
 - (a) Patient table. The patient's table should be capable of four-way motion, permitting wide excursion and pivot rotation. The table should also be able to be angled up to 30° from horizontal, to facilitate myelographic procedures and Trendelenburg position in cardiovascular emergencies.
 - (b) Second table. A second table, within easy reach of the operator, is used for device preparation and placement of devices and materials for use during procedures.
 - (c) Third table. A third table is needed for procedures in which some materials, such as glue or particles for embolization, must be kept separate from the other devices.
7. Power contrast injector.
 - (a) The power injector should be capable of delivering rates up to 50 mL s⁻¹.
 - (b) Ceiling-mounted or table-mounted injectors are preferred over floor models.

8. Control room.
 - (a) Contains the console for operating the angiographic equipment.
 - (b) The control room should be spacious enough to accommodate ancillary personnel, as well as medical students and visitors (at least 130 square feet).¹
 - (c) The control room window should be expansive (≥ 4 ft by 8 ft) should be equipped with a Venetian blind to provide patient privacy during procedures such as Foley catheter placement.
 - (d) The control room should also contain a computer workstation to permit viewing, storage, and analysis of images.
9. Storage space – Often not considered during room planning. There should be enough space to store plenty of device stock, both within the angiography suite and in other rooms close by. Glass-fronted storage cabinets in the suite facilitate rapid device selection during procedures. A separate, out-of-room storage space should be at least 250 square feet.¹
10. Power requirements
 - (a) Three-phase 220 V and 440 V AC power with a minimum of 100 amperes per phase.¹
 - (b) Emergency room power (sufficient to keep the room running for at least several minutes in a power outage).
11. Temperature and humidity must be kept within narrow limits:²
 - (a) Temperature: $72 \pm 10^\circ$
 - (b) Humidity: $45\% \pm 15\%$
12. Equipment room. A separate, cooled and ventilated room should contain transformers, power modules, and related equipment. The recommended size for the equipment room is 100 square feet.¹
 - (a) An alternative to a separate room is an alcove for electronics that can be partially closed off by sliding or swinging doors. Air supply and return vents are positioned over the electronics cabinets, with a separate thermostat for the area.
13. Data management
 - (a) Data storage. The system should be able to store at least several weeks worth of imaging data to allow for rapid comparison of studies on patients that return for urgent follow-up, including patients who have suspected vasospasm, in whom subtle caliber changes are easier to detect if prior studies are available real-time.
 - (b) A picture archiving and communication system (PACS) is a computer system that manages the acquisition, transmission, storage, distribution, display, and interpretation of medical images. PACS display systems are reviewed by Badano,³ and guidelines for the acquisition of and test of PACS are discussed in depth by Samei and colleagues.⁴

4.2. Angiography equipment

Isocentric biplane digital subtraction angiographic equipment is much preferable to a single plane system. Biplane technique decreases time necessary for procedures, reduces radiation exposure, minimizes contrast dose, and offers a definite technical advantage by permitting simultaneous imaging of the anteroposterior and lateral planes. Rotational 3D angiography is also useful in defining tortuous and intricate neurovascular anatomy. Ceiling-mounted equipment, such as video monitors and power-contrast injectors, are easier to manage and are less obtrusive than floor- or table-mounted devices.

4.2.1. Technical specifications

1. Generator
 - (a) Rating should be a minimum of 80 kW, $kV(p) \geq 125$, 800 mA at 100 kV(p), or 1,000 mA at 80 kV(P), with a minimum switching time of 1 ms.
 - (b) Should be a high-frequency inverter generator with a power rating of 80 to 100 kW.¹
 - (c) Should automatically compensate for voltage fluctuation.
 - (d) Should be spatially and electrically isolated, and high-voltage cables need to be shielded.

2. X-ray tube
 - (a) Focal spot indicates the size of the x-ray source. The smaller the source, the greater the resolution. At least three focal spot sizes are necessary:
 - Small, 0.3 mm, kilowatt rating 20–30 kW.
 - Medium, 0.8 mm, kilowatt rating 40–60 kW.
 - Large, 1.3 mm kilowatt rating 80–100 kW.
 - (b) Heat capacity should be at least 800,000 to 1 million units.¹
3. The target angle should be $\leq 12^\circ$.
4. The anode disk typically consists of graphite, with a surface coating of tungsten/rhenium alloy, and a minimum diameter of 150 mm.
 - (a) Anode heat unit capacity of 2.4 million heat units is typical at the present time; a unit with too few heat units will cause a lengthy procedure to be intermittently placed on standby.
5. Image intensifier (II) size should range from 9 to 12 inches. The smaller the II, the higher the resolution at high magnification (drawback: the smaller the II, the smaller the field of view). The field-of-view size can be electronically adjusted using table-side controls. The II should be selected for high resolution and high contrast ratio.
 - (a) The conversion efficiency factor should be greater than 250 candelas per meter squared per milliroentgen per second (cd/m^2)/mR/s measured at 80 kW.¹
 - (b) Spatial resolution is measured at the II tube and should be at least 2.2 line-pairs/mm in the 9 inch field of view, and 3.3 line-pairs/mm for a 6 inch field of view.
 - (c) Contrast ratio should be at least 20:1.
6. Flat panel technology can replace the imaging intensifier. With the appropriate software, it allows for rotational cone-beam 3-D CT, allowing visualization of soft tissues just like a standard CT scan.
 - (a) Advantages: No need for correction for magnetic field distortion; radiation exposure is significantly reduced; larger and more variable field of view; improved image quality; maintains image quality longer in the life of the equipment, unlike II technology in which image quality inevitably degrades.
 - (b) Drawbacks: In the fluoroscopy mode, the displayed image is quite different from II images, which takes getting used to; more expensive.
7. Monitors.
 - (a) Five angiography video monitors are necessary and should be mounted on the ceiling. Two monitors are used to view digital subtraction angiograms or roadmaps; the other two are used for live fluoroscopic imaging during procedures. The fifth is a monitor for 3D reconstructions. Yet another monitor to display hemodynamic parameters should be positioned next to the angiography monitors. The monitors should measure at least 17 inches in the diagonal and have an anti-glare coating. Two kinds of monitors are available: CRTs and flat panels.
 - Cathode ray tube (CRT) monitors.
 - Advantages: Less expensive than flat panels, good viewing angles and noise texture.
 - Disadvantages: Heavier and age faster than flat panels.
 - Minimum specs: $1,024 \times 1,024$ resolution, brightness ~ 500 nit (cd/m^2), antiglare coating.
 - Flat panel monitors
 - Advantages: Good contrast and brightness. Lighter.
 - Disadvantages: More expensive, may have viewing angle and noise texture limitations.
 - Minimum specs: $1,600 \times 1,200$ resolution, brightness ≥ 700 nit (cd/m^2), 700:1 contrast ratio, 170° viewing angle.
 - (b) The monitors should be able to display at least $1,024 \times 1,024$ resolution.⁵
 - (c) Spatial resolution should be at least 1.8 line pairs/mm in the 9 inch mode.
8. Vendors. All five angiography equipment manufacturers make equipment that features biplane DSA, flat panel technology, and 3-D imaging. Some advantages or disadvantages with each company are listed below:
 - a. Toshiba
 - Biplane imaging equipment features a variable isocenter – allows for easier adjustments in c-arm positioning. Toshiba equipment also has a unique direct x-ray-to-electronic flat panel system, which, theoretically lowers noise in the system.

- b. Siemens
 - Nice 3-D imaging algorithm. Siemens x-ray tubes have a relatively high x-ray heat capacity, which makes for fewer interruptions during procedures due to over-heating. Siemens is also unique for “Dynavision,” which produces soft tissue imaging similar to CT scanning.
- c. Philips
 - Good all-around functionality. Philips’ rapid tube rotation, for 3-D imaging, produces a faster acquisition than other systems. The “default x-ray settings” on Philips equipment can produce a lower x-ray exposure for the patient, at the cost of lower imaging quality (however, these settings can be adjusted if needed).
- d. General Electric
 - In the past, GE has tended to have a less dense imaging matrix compared to other vendors and focal spots have been larger.
- e. Shimadzu
 - Also features a variable isocenter. Shimadzu equipment has a unique motion-artifact correction feature. Shimadzu 3-D imaging is not as advanced as the other vendors.

4.3. Radiation safety

4.3.1. Patient radiation exposure

1. The overall radiation exposure with most neurointerventional procedures is low. In a series of eight neurointerventional cases, the mean effective radiation dose was 1.67 mSv (range, 0.44–3.44 mSv).⁶ The estimated risk of death by radiation-induced cancer with the highest effective dose was approximately one for every 6,000 procedures.
2. Although there is no defined maximum radiation exposure for patients, as the medical benefits are assumed to outweigh the presumed risks,⁷ radiation exposure to patients should be minimized.
3. Cornerstones of minimizing radiation dose to the patient:¹
 - (a) Minimizing exposure time (e.g., by minimizing fluoroscopy time).
 - (b) Using appropriate shielding.
 - (c) Maximizing distance from the x-ray source
4. The National Council on Radiation Protection and Measurements (NCRP) has made recommendations for the design of structural shielding⁸ and x-ray equipment.⁹

4.3.2. Staff radiation exposure

1. The National Council on Radiation Protection and Measurements has published guidelines for radiation exposure for medical personnel that are defined as “as low as reasonably achievable.”¹⁰
2. Fluoroscopy is the major source of occupational radiation exposure.¹¹
3. The operating physician is at the greatest risk of receiving the maximum occupational dose.¹ Positioning of the x-ray tube under the table minimizes scatter radiation to the operator’s head and neck.¹²
4. Moveable, ceiling-mounted clear lead glass shields can be draped with sterile plastic and positioned over the patient, protecting the patient’s lower body and the operator from radiation exposure.
5. Rolling floor mounted x-ray shields should be available to shield anesthesia or other personnel.
6. Lead aprons
 - (a) Should provide at least 0.5 mm lead equivalent thickness. All full-time physicians, technologists, and nurses should wear custom-fitted aprons to ensure optimal coverage.
 - (b) Extra aprons should be available for anesthesia staff and visitors.
 - (c) Pregnant staff members.

- The NCRP-recommended maximum gestational radiation exposure is 5 mS per year.⁷
 - Options to minimize fetal radiation exposure:
 - Wear an apron with 1.0mm lead equivalent thickness (however, these aprons are hard to find and are very heavy).
 - Wear wrap-around aprons to cover front and back.
 - Pregnant staff members should wear two radiation badges, with one under the apron to monitor fetal dose.
7. Other personal radiation protection, including thyroid shields, lead glasses, should be available.

4.4. Physiological monitoring

Meticulous monitoring of the patient's condition during a neurointerventional procedure is critical.

1. When possible, procedures should be performed with the patient awake to permit continuous assessment of neurological status.
2. Monitoring of vital signs and pulse oximetry is routine; continuous arterial line and intracranial pressure (ICP) monitoring is done as needed.
3. Equipment
 - (a) Transducers should have a linear response from -10 to 400 mmHg.¹
 - (b) Two or more pressure channels and two ECG channels should be available.
 - (c) An overhead monitor that projects the clinical data, including color-coded tracings, should be positioned next to the angiography monitors.
4. Arterial line monitoring. Patients with subarachnoid hemorrhage or intracranial hemorrhage should undergo continuous arterial line monitoring of their vital signs by means of a radial artery line placed before the procedure. Alternatively, monitoring may be done via the arterial sheath in patients undergoing elective procedures, such as endovascular treatment of intracranial aneurysms. To obtain an adequate tracing, the sheath must be larger than the guide catheter; monitoring can be done through a 7-French femoral artery sheath when a 6 French guide catheter is used.
5. Intracranial pressure monitoring. Continuous monitoring of ICP should be performed in patients with a ventriculostomy. An ICP tracing on one of the overhead angiography monitors provides immediate feedback, should an abrupt change in ICP occur during the procedure, such as during an aneurysm rupture.

4.5. Personnel

The neurointerventional team is a multidisciplinary group with expertise in neurointervention, radiology techniques, and radiation safety. At the center of this group are the interventionists, technologists, and nurses. The team is supplemented by anesthesiologists and the anesthesia monitoring staff. It is important that the individuals in the team are experienced, highly motivated, and flexible. The rapidly evolving field of neurointervention, combined with the complexity of the disorders and the procedures requires that the team functions as a cohesive, adaptable unit. Moreover, the team should be large enough to allow organization of a call schedule that will provide continuous 24-h availability.

4.5.1. Neurointerventionists

The neurointerventionist is a neurosurgeon, neuroradiologist, or neurologist who has completed a dedicated fellowship in neurointerventional radiology. Detailed knowledge of the pathophysiology of neurovascular disease must be combined with a comprehensive understanding of neuroanatomy as well as fundamentals of neurocritical care and interventional techniques.

4.5.2. Neurointerventional technologists

Technologists in the neurointerventional suite have a background in basic radiology techniques and further expertise in computerized digital subtraction imaging. They are responsible for setting up the equipment for procedures, processing of the images, trouble-shooting during procedures, and ordering and stocking of devices. They also are responsible for alerting specialized service technicians when needed; technologists are not usually responsible for maintaining and repairing imaging equipment. At some centers, technologists may also be responsible for patient positioning and the establishment and maintenance of irrigation lines.

4.5.3. Nursing staff

Neurointerventional nurses should be registered nurses with a background in neurointensive care. Neurointerventional nurses are responsible for patient preparation before the procedure, the establishment of intravenous access, the administration of sedation and analgesia, monitoring the patient's condition, and maintenance of irrigation lines. Additional specific duties of the nursing staff include evaluation of the preprocedure laboratory tests, checking for allergies or drug reactions, verifying and witnessing informed consent for the procedure, placement of a Foley catheter, ventriculostomy and lumbar drain management, performance of an Allen test before radial artery procedures, monitoring peripheral pulses, and management of the arterial access site at the completion of the procedure. At some centers, a second nurse acts as the first assistant to the neurointerventionist during procedures.

4.6. Pharmacologic considerations

Certain medications should be available for prompt access (Table 4.1). During procedures in which intravenous heparin is administered, protamine should be drawn up in a sterile syringe and placed on the back table in preparation for rapid administration in the event of a hemorrhage during the procedure. Medications used on a routine basis are listed in Table 4.2.

Table 4.1 Medications that should be easily available for prompt access or emergent use

Medication	Use
Atropine	Treatment of bradycardia or asystole during carotid angioplasty and stenting
Epinephrine	Vasopressor
Fentanyl	Analgesia
Glycoprotein (GP) IIb-IIIa inhibitor (e.g., eptifibatid or abciximab)	Rescue treatment when platelet-rich thrombosis occurs
Heparin	Anticoagulation
Labetalol hydrochloride	Blood pressure control
Lidocaine	Local anesthesia
Midazolam	Sedation
Nitroglycerin	Treatment of catheter-induced vasospasm
Protamine	Reversal of systemic heparin anticoagulation
tPA or other thrombolytic	Acute stroke treatment

Table 4.2 Routine medications

Medication	Use
Acetylcysteine	Treatment of patients with renal insufficiency
Aspirin (oral and suppository preparations)	Antiplatelet therapy
Benadryl	Treatment of allergic reactions
Clopidogrel	Antiplatelet therapy
Dobutamine	Blood pressure and heart rate support
Dopamine	Blood pressure and heart rate support
Flumazenil	Reversal of benzodiazepines
Furosemide	Management of elevated intracranial pressure
Glucagon	Control of gastric motility during spinal angiography; may be useful for treatment of anaphylaxis in patients on beta blockers
Lidocaine (preservative-free, for provocative testing)	Provocative testing of the retina or peripheral nervous system before embolization
Mannitol	Management of elevated intracranial pressure
Naloxone	Reversal of narcotics
Norepinephrine	Vasopressor
Ondansetron	Antiemetic
Phenylephrine	Blood pressure and heart rate support
Propofol	Sedation and analgesia
Sodium amobarbital (Amytal)	Provocative testing before embolization of the central nervous system or for Wada testing
Sodium methohexital (Brevital)	Provocative testing before embolization of the central nervous system
Sodium nitroprusside	Blood pressure control
Vasopressin	Vasopressor

4.7. Future developments

An array of technological advances are currently in progress that offer promise in the continued evolution of the neurointerventional suite. Flat panel angiographic imaging, currently available, can lower the x-ray dose and provide better image quality and resolution. Angiographic computed tomography enables angiographic imaging equipment to generate images of soft tissue, such as the brain, that are similar to computerized tomography images. Magnetically guided angiography, currently available at some centers, uses extracranial magnets to help catheter and wire navigation.^{13, 14} This technology offers the potential to permit more precise intravascular navigation while shortening fluoroscopy and procedure times. MRI-guided angiography, with the potential advantages of detailed tissue imaging as well as the elimination of radiation exposure, is another innovation under development.¹⁵⁻¹⁷

4.8. References

1. Cardella JF, Casarella WJ, DeWeese JA, et al. Optimal Resources for the Examination and Endovascular Treatment of the Peripheral and Visceral Vascular Systems: AHA Intercouncil Report on Peripheral and Visceral Angiographic and Interventional Laboratories. *J Vasc Interv Radiol* 2003;14(9):517S-30.
2. Larson TCI, Creasy JL, Price RR, Maciunas RJ. Angiography suite specifications. In: Maciunas RJ, ed. *Endovascular Neurological Intervention*. Park Ridge, IL: American Association of Neurological Surgeons; 1995.
3. Badano A. AAPM/RSNA Tutorial on Equipment Selection: PACS Equipment Overview: Display Systems. *Radiographics* 2004;24(3):879-89.

4. Samei E, Seibert JA, Andriole K, et al. AAPM/RSNA Tutorial on Equipment Selection: PACS Equipment Overview: General Guidelines for Purchasing and Acceptance Testing of PACS Equipment. *Radiographics* 2004;24(1):313-34.
5. General Considerations for Endovascular Surgical Neuroradiologic Procedures. *AJNR Am J Neuroradiol* 2001;22(90080):1S-3.
6. Bergeron P, Carrier R, Roy D, Blais N, Raymond J. Radiation Doses to Patients in Neurointerventional Procedures. *AJNR Am J Neuroradiol* 1994;15(10):1809-12.
7. Measurements NCoRPa. Recommendations on Limits for Exposure to Ionizing Radiation: Recommendations of the National Council on Radiation Protection and Measurements. Bethesda, MD; 1987. Report No.: NCRP report 91.
8. Measurements NCoRPa. Structural Shielding Design for Medical X-Ray Imaging Facilities. Bethesda, MD; 2004. Report No.: NCRP report 147.
9. Measurements NCoRPa. Medical X-ray, Electron Beam, and Gamma-Ray Protection for Energies up to 50MeV/G (Equipment Design, Performance, and Use): Recommendations of the National Council on Radiation Protection and Measurements. Bethesda, MD; 1989. Report No.: NCRP report 102.
10. Measurements NCoRPa. Implementation of the Principle of as Low as Reasonable Achievable (ALARA) for Medical and Dental Personnel: Recommendations of the National Council on Radiation Protection and Measurements. Bethesda, MD: The Council; 1990. Report No.: NCRP report 107.
11. Edwards M. Development of radiation protection standards. *Radiographics* 1991;11(4):699-712.
12. Boone JM, Levin DC. Radiation exposure to angiographers under different fluoroscopic imaging conditions. *Radiology* 1991;180(3):861-5.
13. Schiemann M, Killmann R, Kleen M, Abolmaali N, Finney J, Vogl TJ. Vascular guide wire navigation with a magnetic guidance system: experimental results in a phantom. *Radiology* 2004;232(2):475-81.
14. Chu JC, Hsi WC, Hubbard L, et al. Performance of Magnetic Field-Guided Navigation System for Interventional Neurosurgical and Cardiac Procedures. *J Appl Clin Med Phys* 2005;6(3):143-9.
15. Seppenwoolde JH, Bartels LW, van der Weide R, Nijssen JF, van Het Schip AD, Bakker CJ. Fully MR-Guided Hepatic Artery Catheterization for Selective Drug Delivery: A Feasibility Study in Pigs. *J Magn Reson Imaging* 2006;23(2):123-9.
16. Wacker FK, Hillenbrand C, Elgort DR, Zhang S, Duerk JL, Lewin JS. MR Imaging-Guided Percutaneous Angioplasty and Stent Placement in a Swine Model Comparison of Open- and Closed-Bore Scanners. *Acad Radiol* 2005;12(9):1085-8.
17. Wacker FK, Hillenbrand CM, Duerk JL, Lewin JS. MR-Guided Endovascular Interventions: Device Visualization, Tracking, Navigation, Clinical Applications, and Safety Aspects. *Magn Reson Imaging Clin N Am* 2005;13(3):431-9.

5. Intracranial Aneurysm Treatment

Endovascular strategies for the treatment of intracranial aneurysms include embolization (e.g., coiling or Onyx infusion) and parent vessel sacrifice.

5.1. Intracranial aneurysm embolization

5.1.1. Indications and contraindications

Indications for the endovascular treatment of intracranial aneurysms are discussed in depth in Chap. 13. General indications:

1. Aneurysmal subarachnoid hemorrhage.
2. Unruptured intracranial aneurysms
 - (a) Size ≥ 2 mm
 - (b) Poor surgical candidates
 - Elderly patients
 - Patients with significant medical problems
 - Patients requiring chronic systemic anticoagulation (i.e., patients with atrial fibrillation)
 - (c) Posterior circulation aneurysms
 - (d) Cavernous segment ICA aneurysms

Relative contraindications:

1. Vascular anatomy that is prohibitive (e.g., some giant, wide-necked aneurysms, exaggerated vessel tortuosity).
2. Significant atherosclerotic disease or other abnormalities affecting the parent vessel (e.g., significant atherosclerotic stenosis of the carotid bifurcation).
3. Coagulation disorders or heparin hypersensitivity.
4. Active bacterial infection (i.e., bacteremia at time of endovascular treatment).

5.1.2. Patient preparation

5.1.2.1. Evaluation

1. History and physical.
2. Neurological exam.
3. Blood test (CBC, Cr, PT, PTT)
4. Imaging
 - (a) Head CT and
 - (b) CTA, MRA, or catheter angiogram
 - (c) The authors' preference is to obtain a CTA in nearly every case, even if a catheter angiogram has already been done. A CTA can provide information that is complimentary to an angiogram, such as precise measurements, three dimensional views, imaging of intraluminal thrombus, and skull base imaging that can be useful, should the patient undergo craniotomy.
 - (d) Imaging considerations
 - Aneurysm location, size, shape, and neck size.
 - Parent vessel anatomy.
 - Presence or absence of intraluminal thrombus
 - Access vessel anatomy (e.g., dominant vs. hypoplastic vertebral artery or ACA, degree of tortuosity).
 - Presence or absence of atherosclerosis or fibromuscular dysplasia in the access vessel.

5.1.2.2. Treatment strategy

Prior to the case, preferably the previous day, the patient should be assessed and all the available imaging reviewed in preparation for the case. Decisions about overall strategy should be made ahead of time, to permit accurate device selection and smooth and efficient performance during the case. Plans should include:

1. Choice of access vessel
2. Coiling technique (i.e., primary coiling vs. stent-assisted or balloon-assisted coiling)
3. Device types and sizes

5.1.2.3. Pre-procedure preparation

1. Place 2 peripheral IVs.
2. Place Foley catheter.
3. NPO after midnight or 6 h prior to the procedure except for medications
4. Make sure that all devices that may be needed are available in the angio suite prior to the procedure.
5. If stent-assisted coiling is planned, antiplatelet therapy is necessary:
 - (a) Aspirin 325 mg PO QD for ≥ 3 days prior to the procedure and
 - (b) Clopidogrel (Plavix[®]) 75 mg PO QD for ≥ 3 days prior to the procedure (or 300 mg PO > 5 h prior to the procedure).
6. Patients with subarachnoid hemorrhage:
 - (a) Arterial line and central venous access are established prior to the procedure
 - (b) If a ventriculostomy is present, the catheter must be attached to a monitor, to permit continuous ICP monitoring during the case.
 - The ICP is an “early warning system” for aneurysm rupture or re-rupture during embolization.
 - The ventriculostomy should be “on monitor” (and not “to drain”), if possible, during the entire procedure, to permit continuous monitoring. Open the drain only intermittently, if CSF drainage during the procedure is necessary.

5.1.3. Endovascular technique

The technique of endovascular aneurysm treatment varies from case to case. The following is a general outline of the procedure used by the authors for most patients. The case is divided into a vascular *access* phase, and an *intervention* phase. Access consists of placing a guide catheter in the internal carotid artery or vertebral artery. The intervention phase involves placement of a microcatheter in the aneurysm and deployment of the coils, as well as adjunctive techniques such as stent-assisted or balloon-assisted coiling.

5.1.3.1. Awake or asleep?

Some operators prefer to use general anesthesia for aneurysm cases, whereas others prefer to do them with the patient awake. Each approach has advantages. Coiling with the patient awake, permits continuous neurological monitoring, eliminates the risks of general anesthesia, can shorten the length of the case, and has been shown to be safe and feasible.¹ Coiling with the patient awake is less practical in patients with reduced mental status and in those with small aneurysms (in which a small amount of patient motion can lead to aneurysm perforation). General anesthesia can eliminate patient mobility, allow the operator to focus on the procedure rather than on coaching and assessing the patient, be more palatable for anxious patients, and permit tight blood pressure control. The authors prefer to use general anesthesia, except for cases in which medical issues place the patient at elevated risk with anesthesia (e.g., severe heart disease).

5.1.3.2. Awake

1. Patient is placed on the angiography table, awake.
2. An abbreviated neurological exam is rehearsed with the patient prior to draping (e.g., patient is asked to say “Methodist Episcopal,” show their teeth and gums, wiggle their toes, and squeeze a rubber duck with the hand contralateral to the side being treated).
3. Throughout the case, the patient is reminded to stay completely still. The patient’s head can be lightly taped to the head holder with a piece of plastic tape across the forehead, to remind him or her to stay still.
4. Sedation and analgesia are kept to a minimum to facilitate the patient’s full cooperation.

5.1.3.3. Asleep

1. Patient is placed under general anesthesia on the angiography table.
2. Strict attention to blood pressure control during anesthesia induction is necessary to minimize the risk of aneurysm rupture.
- (a) A radial arterial line is not necessary for blood pressure monitoring prior to induction in patients with unruptured aneurysms.
 - If arterial monitoring is felt to be necessary prior to induction, place a 7 French femoral sheath while the patient is still awake. Placement of a femoral artery sheath is less uncomfortable than a radial artery line. A 7 French sheath is large enough to permit passage of a 6 French guide catheter, and still allow arterial line monitoring.
3. The anesthesiologist is asked to report any abrupt changes in blood pressure or heart rate during the case, which can indicate intracranial hemorrhage.

5.1.3.4. Vascular access phase

1. Dorsalis pedis and posterior tibialis pulses are assessed and marked.
2. The right or left groin is prepped, draped, and infiltrated with local anesthesia.
3. A 6 French sheath is placed in the femoral artery.
 - (a) A 7 (or rarely, 8 French) sheath should be used, if arterial monitoring through the sheath is planned, and if adjunctive techniques, such as balloon-assisted coiling, are anticipated.
4. An angiogram is done using a diagnostic catheter. Angiograms of the access vessel (carotid or vertebral artery) and PA and lateral views of the intracranial circulation are done prior to the intervention.
 - (a) Imaging of the carotid or vertebral artery is necessary for guide catheter selection, and to check for the presence of atherosclerosis and fibromuscular dysplasia.
 - (b) Intracranial images at the beginning of the case are necessary for comparison later, to assess for thromboembolic complications.
5. Systemic anticoagulation. Thromboembolic complications can occur during coiling, particularly when there is a slowing of flow in the parent vessel caused by the guide catheter. Prevention and management of these complications are reviewed.^{2,3} The importance of routine prophylactic systemic anticoagulation during aneurysm coiling, however, is unclear. Systemic anticoagulation with IV heparin appears to carry relatively low risk in patients with unruptured aneurysms, and judicious use of heparin in patients with ruptured aneurysms also appears to be relatively low-risk, particularly, as the drug can be rapidly reversed with IV or IA protamine.
 - (a) Unruptured aneurysms
 - A loading dose of IV heparin is given (70 U kg⁻¹) and 5 min later, a 5 mL specimen of blood for an activated clotting time (ACT) is drawn from the sheath. The guide catheter is placed in the ICA or vertebral artery only after the heparinization is therapeutic (usually 5 min or more after the IV loading dose is given, or after the ACT has been found to be in the target range). The ACT should be kept between 250 and 300 s for the entire duration of the procedure. Additional doses of heparin are necessary only during cases that last longer than several hours.
 - (b) Ruptured aneurysms

- Controversial
 - The authors prefer to withhold heparin until enough coils have been placed in the aneurysm to occlude the dome, which is where most aneurysms are thought to have ruptured. Then, a full or partial loading dose of IV heparin is given (50–70 U kg⁻¹).
- (c) Protamine on stand-by – *Critical*
- A syringe containing protamine, enough to reverse the total amount of heparin the patient has received, should be kept on the back table for easy access to the operator should hemorrhage occur during the case.
 - Dose of protamine required to reverse heparin: 10mg protamine/1,000U heparin.
 - The authors routinely keep a sterile syringe containing ≥50mg of protamine on the back table. The drug is infused into the guide catheter or sheath when intracranial hemorrhage occurs.
- (d) Other antithrombotic agents
- Antiplatelet agents. Some operators advocate routine pretreatment with aspirin and clopidogrel for patients with unruptured aneurysms. Others use these agents for retreatment of previously coiled aneurysms (to dissolve platelet-rich thrombus that may be within the aneurysm and vulnerable to dislodgement during the re-coiling procedure). The presence of antiplatelet agents during routine aneurysm coiling, however, can worsen potential hemorrhagic complications. The authors do not recommend routine use of antiplatelet medications, except in cases where the use of stent-assisted coiling is anticipated.
 - Bivalirudin (Angiomax™, The Medicines Company, Cambridge, MA) is a synthetic direct thrombin inhibitor that is popular in interventional cardiology and has been used in neurointervention in select cases.⁵ However, there is no rapid reversal agent for bivalirudin, and its use in patients with intracranial aneurysms is not recommended.
6. Guide catheter selection.
- (a) The authors prefer to use the Neuron™ guide catheter in nearly all cases; this device is new on the market as of this writing, but represents a significant advance in guide catheter design. See below for technique. Two older guide catheters, the Guider™ and the Envoy®, are still appropriate in some situations.
- Neuron™ Intracranial Access System (Penumbra, Inc., San Leandro, CA).
 - Advantages: Extremely soft and flexible; able to be positioned within the distal intracranial ICA or vertebral artery.
 - Disadvantages: Less stable than other catheters, very slippery. Can be pushed out of the access vessel, if the catheter is not in a distal-enough position. Only the distal tip is radio-opaque; the radiolucent shaft can be difficult to see on fluoroscopy.
 - Guider Softip™ XF guide catheter (Boston Scientific, Natick, MA)
 - Advantages: Soft, atraumatic tip. Minimizes risk of vasospasm and dissection in narrow, tortuous vessels.
 - Disadvantages: Relatively flimsy, prone to fall into the arch when the vasculature is tortuous.
 - Envoy® (Cordis Neurovascular, Miami Lakes, FL)
 - Advantages: Relatively rigid, provides a good platform in tortuous vessels, large internal lumen.
 - Disadvantages: Stiff, sharp-edged tip.
- (b) Guide catheter size
- 6 French for most cases
 - Large-lumen 6 or 7 French, if balloon-assisted coiling is anticipated
 - 5 French, if the vessel caliber is small and collateral circulation is limited
 - e.g., for use in a small vertebral artery, when the contralateral vessel is hypoplastic
 - Disadvantage: More difficult to obtain angiograms with the microcatheter in place, because of limited space within the guide catheter. Use of a smaller microcatheter can improve this.
- (c) Straight or angled?
- Straight guide catheter is useful in relatively straight vessels, or in situations where the guide catheter will be gently navigated through a convoluted vessel

- Usually requires exchanging (see below).
 - Preferred for the vertebral artery.
 - Angled guide catheter is useful, when the final position of the catheter tip is in a vessel curve
 - Angled catheters are easier to navigate through the aortic arch than straight catheters
 - (d) Alternative guide catheters
 - 6 French 90 cm Cook Shuttle® (Cook Inc., Bloomington, IN)
 - Very large, stable platform
 - See Chap. 8 for technique
 - 6 French Northstar® Lumax® Flex Catheter (Cook Inc., Bloomington, IN)
 - Device contour consists of a smooth, tapered transition between the guidewire, the inner dilator, and the catheter which minimizes trauma to the vessel walls.
 - Disadvantages:
 - (a) Very stiff
 - (b) Extremely lubricious (may cause the catheter to slide out of vessels)
7. Guide catheter placement technique
- (a) Direct navigation method
 - Useful in young patients with non-tortuous, non-atherosclerotic vessels.
 - An angled Guide catheter is gently navigated into the carotid or vertebral artery over a 0.035 inch or 0.038 inch hydrophilic wire.
 - (b) Exchange method
 - Useful in patients with tortuous anatomy, atherosclerosis, or fibromuscular dysplasia. This technique can minimize the risk of injury to the carotid or vertebral artery, particularly at the vessel origin.
 - A 5 French diagnostic catheter is guided into the CCA or vertebral artery over an exchange-length (300 cm) wire.
 - The tip of the wire is advanced into a distal branch of the ECA or into the distal extracranial vertebral artery (usually the first 90° turn of the vessel at C2), using roadmapping technique.
 - The diagnostic catheter is then gently removed while the tip of the hydrophilic wire is continuously visualized on fluoroscopy.
 - The hydrophilic wire is wiped down with a dripping-wet Telfa sponge.
 - The guide catheter is advanced over the wire, while continuously visualizing the tip of the wire.
 - (c) Neuron™ Intracranial Access System technique
 - Device selection
 - As of this writing, the two Neuron guide catheters available are the 6 French 053 lumen, which is 5 French at the tip and the 6 French 070 lumen, which is 6 French from proximal to distal.
 - Two lengths are available: 105 cm (for most patients) and 115 cm (for patients > 6 feet in height).
 - Two distal tip lengths are available: 6 cm (for most cases) and 12 cm (for cases in which a very tortuous ICA or vertebral must be traversed (e.g., a cervical ICA with a 360° loop).
 - Placement technique
 - The exchange method is easiest with Neuron guide catheters. They are soft and not shaped at the tip and are difficult to navigate directly.
 - The guide catheter can usually be placed in the petrous segment or distal cervical vertebral artery, using a hydrophilic wire. Once the microcatheter is advanced beyond the guide catheter, the guide can frequently be advanced over the microcatheter for an additional several centimeters.
 - Tips
 - Guide catheter angiograms can be of marginal quality when a microcatheter is inside the guide catheter, because of the relatively narrow lumen. Injection of 100% contrast in a 3 mL syringe, rather than a 10 mL syringe, will produce better angiograms.
 - Neuron guide catheters are more stable, the further distally they are placed (e.g., an unstable guide catheter can be stabilized by

- advancing it over a hydrophilic wire or a microcatheter by several centimeters).
- (d) **Guider and Envoy Guide catheter position**
 - **Carotid system.** Using roadmapping, the guide catheter is advanced over a hydrophilic wire into the ICA as distally as possible. A “high position” of the guide catheter will maximize stability of the guide, and improves control over the microcatheter and microwire. In a non-tortuous, healthy carotid system, the authors prefer to position the tip of the guide catheter in the vertical segment of the petrous ICA. In a cervical ICA with a significant curve in the vessel, the guide can be adequately positioned immediately proximal to the curve. Moderate curves in the vessel can be straightened out by guiding a relatively stiff hydrophilic wire (e.g., a 0.038 inch wire) through the affected segment, followed by the catheter.
 - **Vertebral artery.** Using roadmapping, the guide catheter is positioned in the distal extracranial vertebral artery, usually at the first curve (at C2).
 - Once the catheter is in position, a gentle injection of contrast through the guide catheter under fluoroscopy is done to examine the configuration of the vessel around the tip and to check for the presence of vasospasm or vessel dissection around the tip. If catheter tip-induced vasospasm is present and flow-limiting, withdrawal of the catheter tip by several millimeters is often sufficient to restore flow.
 - The catheter tip may slide up and down and rub against the vessel wall with each heart beat; be sure to take this into account when positioning the catheter.
 8. **Guide catheter irrigation**
 - (a) Continuous irrigation of the guide with heparinized saline (5,000 U heparin per 500 mL saline) is important.
 - (b) Meticulous attention to the guide catheter RHV throughout the case, is necessary to identify thrombus or bubbles, should they appear.
 9. **Tips to minimize guide catheter-induced vasospasm**
 - (a) Withdraw the catheter into a lower segment of the vessel, when significant catheter-induced vasospasm appears.
 - (b) Keep the catheter tip away from kinks and bends in the vessel, if possible.
 - A curvaceous carotid or proximal vertebral artery can sometimes be straightened by tilting the patient’s head towards the opposite shoulder (Fig. 5.1).
 - (c) Use a smaller guide catheter.
 - (d) Use a soft-tipped guide catheter (e.g., Guider Softip™ XF guide catheter (Boston Scientific, Natick, MA)).
 - (e) Use Visipaque™ (GE Healthcare, Princeton, NJ) contrast instead of Omnipaque; according to the manufacturer, this contrast material is less spasmogenic than Omnipaque®.
 - (f) Use a guide catheter with an inner obturator (e.g., Northstar® Lumax® Flex Catheter (Cook Inc., Bloomington, IN))
 - (g) Nitroglycerin paste on the patient’s neck ipsilateral to the access vessel
 - Dose: 1–5 inches
 - Efficacy is unclear, however nitroglycerin paste has been reported to improve cerebral vasospasm after subarachnoid hemorrhage.⁶
 - Drawback: Can cause hypotension and a headache in awake patients. In patients under general anesthesia, the dose (i.e., the number of inches) of paste is adjusted to maintain the blood pressure within normal limits.
 - (h) Selective injection of IA nitroglycerin (30 mcg per injection).
 - This can help distinguish vasospasm from vessel dissection, if a dissection is suspected

5.1.3.5. Aneurysm coiling phase

Preparations are made for coiling once the guide catheter is in position. A good “working view” must be obtained; several angiograms with injection of contrast through the guide catheter are usually necessary to find the optimal images. Alternatively, a 3-D angiogram can be done and the image of the aneurysm be rotated on the workstation monitor to obtain the ideal working view, and corresponding

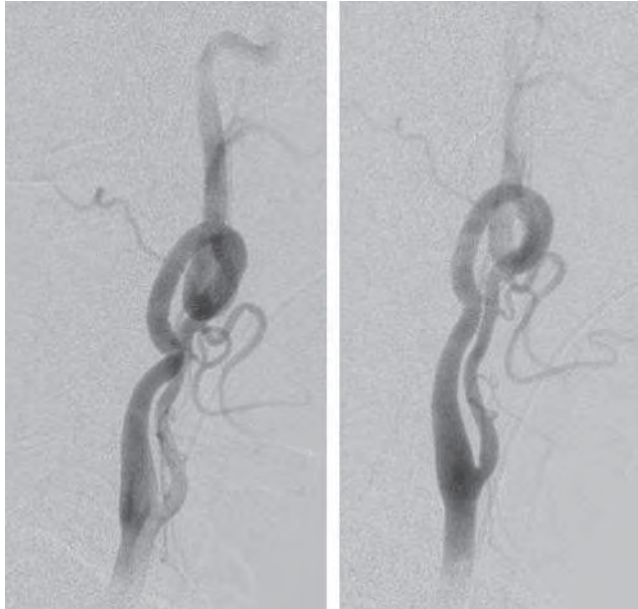


Fig. 5.1 Head tilt technique. Left carotid system in a neutral position (*left*) and with the head tilted toward the opposite shoulder (*right*).

position of the x-ray tube. Ideally, the working view should be under high magnification and should demonstrate the aneurysm, parent vessels, and guide catheter clearly. It is important to keep the guide catheter in view on at least one projection (PA or lateral) during the whole case, to permit correction of the guide catheter should the catheter be pushed down (which is not uncommon) or become unstable during passage of the microcatheter. The working view should also permit the aneurysm dome and neck to be distinguished from the parent vessel (Fig. 5.2).

5.2. Device selection

1. Microcatheters

- (a) Microcatheters vary in size and design. All available microcatheters have a hydrophilic coating, which reduces thrombogenicity.⁷ Most microcatheters are either fiber-braided or metal coil-braided, which serves to preserve the inner lumen when the catheter is curved, and enhances pushability.
- (b) The smallest catheter that will accommodate the coil size anticipated, should be used in most cases for the following reasons:
 - Small microcatheters are more likely to be soft and flexible near the tip, which will allow “paint-brushing,” permitting a more uniform distribution of the coils within the aneurysm.
 - Smaller microcatheters permit better guide catheter angiograms, particularly when smaller guide catheters (e.g., 5 French) are employed.
 - The closer the match between the inner diameter of the microcatheter and the diameter of the coil, the less likely that buckling of the coil within the microcatheter will occur (e.g., a 10-system coil will work best in a 10-system microcatheter).

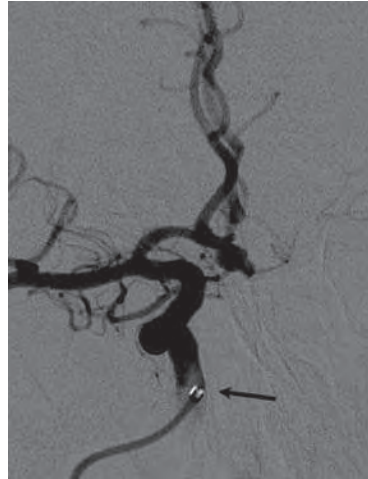


Fig. 5.2 Working view for coiling. The guide catheter (*arrow*) is in view, as are the aneurysm, aneurysm neck, and parent vessel.

- (c) Some situations call for larger and/or stiffer microcatheters.
 - Large aneurysms, or aneurysms in which the use of 18-system coils, are planned.
 - When the catheter access to the aneurysm is tenuous because of vascular anatomy, and increased microcatheter stiffness will add stability.
- (d) Obviously, two-tipped microcatheters, rather than single-tipped catheters, are necessary for aneurysm coiling. The two tips in microcatheters used in aneurysm coiling are always 3 cm apart – this feature can be used for calibration and measurements.
- (e) The authors' preferred microcatheters for most cases:
 - Excelsior[®] SL-10 (Boston Scientific, Natick, MA)
 - Accommodates both 0.010 inch and 0.014 inch microwires.
 - Can be used for 10-system and 14-system coils.
 - Has been shown to retain its shape better (after steam-shaping) than other microcatheters of the same size.⁸
 - Echelon[™] 10 (Microtherapeutics Inc., Irvine, CA)
 - The relatively small proximal outer diameter of 2.1 French (versus 2.4 French for the Excelsior[®] SL-10), permits better guide catheter angiograms when a 5 French guide catheter is used.
 - Able to accommodate 18-system coils (although it's a tight fit).
 - Very stable for a 10-size system.
 - Excelsior[®] 1018[®] (Boston Scientific, Natick, MA)
 - Accommodates both 10-system and 18-system coils
- (f) Microcatheter shape: *Pre-shaped* vs. *straight* vs. *steam-shaped*
 - A shaped microcatheter can be advantageous in accessing aneurysms that arise from the parent vessel at an acute angle, and in stabilizing the microcatheter during coiling.
 - The authors prefer pre-shaped microcatheters, which retain their shape better than steam-shaped microcatheters.⁹ Steam-shaping is reserved for obtaining catheter shapes that are not available in pre-shaped devices.
 - Steam shaping technique:
 - Shape the wire mandrel into the desired shape, with an exaggerated degree of curvature (as the microcatheter will recoil to some degree after steam-shaping).
 - Hold over steam for 10 s.
 - Cool in sterile water and remove mandrel.

- Non-braided (e.g., Tracker and FasTracker) and fiber-braided (e.g., Excelsior[®]) microcatheters are more likely to retain their shape after steam shaping, than metal coil-braided (e.g., Prowler and Echelon[™]) microcatheters.⁹
- (g) The so-called Pivot[™] (Boston Scientific, Natick, MA) is a radically different microcatheter, although its availability is limited at the time of this writing. This device contains a metal hypotube, which allows for one-to-one torque control.
 - *Steerable microcatheter catheterization tips*
 - Steam-shape a curve appropriate for the particular application. You can only steam-shape the most distal 1.5 cm. of the microcatheter. Use the shaping mandrel that comes with the catheter. Insert the mandrel in the catheter tip and bend the catheter in an angle greater than the degree of angle you want. Steam the catheter tip for 10 s. When you remove the mandrel, the curve will straighten somewhat.
 - The catheter comes in pre-shaped tips. If available in the shape needed, these may be better, as they keep their shape better than steam-shaped curves.
 - Preload an appropriate guidewire into the microcatheter, such as a 0.014" Transend[™] or Synchro[™] wire (Boston Scientific, Natick, MA)
 - Use the available peel-away introducer to allow easy introduction of the microcatheter through the rotating hemostatic valve of the guiding catheter.
 - Use a fairly robust guiding catheter that is placed as high as safely possible in the cervical carotid or vertebral artery.
 - Keep the tip of the guiding catheter in your roadmap field of view, and remember that the Pivot[™] will try to push the guiding catheter back, as you advance.
 - Carefully advance the microcatheter under roadmap guidance over the guidewire. When encountering a sharp turn in the vessel, you can rotate the catheter as you advance, to make the turn.
 - When rotating the microcatheter, it is most efficient to hold the flange at the microcatheter hub. Ensure that any slack in the microcatheter or guiding catheter is removed and that the rotating hemostatic valve on the guiding catheter is not too tight, as any of these factors can limit the transmission of torque to the tip of the microcatheter.
 - If the microcatheter tip is not moving forward as you advance at the groin, rotate it slightly, and it may move forward again.
 - Beware that the microcatheter can jump forward abruptly as it is being rotated, especially if you have been pushing forward with little response at the tip. All that pushing has stored energy into the system and it releases quickly when the catheter is rotated.
 - If the microcatheter will not advance and the guiding catheter pushes back, pull back on the microcatheter to release tension, and try again, using various combinations of forward pushing and rotating of the microcatheter, as well as gentle rotation of the guidewire.
 - The stiffness of the microcatheter can straighten small, sharply curved vessels, so you may want to consider a different catheter system for very distal catheterization of small vessels.
 - When nearing the aneurysm, slow down, remove the slack in the microcatheter and wire, and make smaller forward pushing and rotating movements, to avoid jumping into (or through) the aneurysm.
 - Plan on positioning the microcatheter tip in the proximal half of the aneurysm away from the dome. This will avoid puncturing the dome with the catheter. These catheters are a great deal more stable than most, so you don't need as deep a catheter placement to maintain position in the aneurysm during coiling.
 - In the case of stent-assisted coiling, the curve of the microcatheter can be used to direct a soft-tip wire through the desired area of the stent and into the aneurysm. The

microcatheter is then gently pushed and rotated back-and-forth, to wriggle it across the stent and into the aneurysm.

- As coils are advanced into the aneurysm, the tip of the Pivot™ may still move side-to-side (“paint-brush”) like other microcatheters, but has a lesser tendency to kick out of the aneurysm.
- If it appears that the loops of the coil are not uniformly distributing throughout all parts of the aneurysm, you can gently rotate the microcatheter to point in a different direction and more precisely deposit loops of coil in a desired distribution.
- If the microcatheter does become displaced from the desired location in the aneurysm, you may be able to rotate it back into position, even without a guidewire. Use gentle forward and rotating movements, and always keep an eye on what is happening to the catheter, more proximally in the neck. Especially, if it is pushed or rotated without a guidewire, the Pivot™ can loop on itself in the neck. The authors are convinced that someone will eventually tie one in a bow, if not too careful.
- When nearing the end of coiling an aneurysm, the microcatheter can be turned to pack areas still patent with small ultrasoft coils.
- After reaching the desired packing density in the aneurysm, you need to remove the microcatheter. As with any tightly curved microcatheter, it is desirable to pull the catheter out of the aneurysm over a guidewire, to avoid dragging a loop of coil with the angled tip out into the parent artery.

2. Microwires

- (a) A variety of microwires are available, with differing properties such as size, softness, visibility on fluoroscopy, shapeability, and steerability, trackability, and torque control.
- (b) The authors’ preferred microwires for most cases:
 - Transend™ EX 0.014 inch Platinum (Boston Scientific, Inc., Natick, MA)
 - Superior torque control, compared to other microwires.
 - Heightened radiopacity makes the tip easy to see on fluoroscopy.
 - Headliner™ J-tip 0.012 inch (Terumo Medical Corporation, Somerset, NJ)
 - J-tip is atraumatic to the vessel walls.
 - Best suited for uncomplicated vessel anatomy (tends to follow the straightest vessel).
 - Synchro®-14 0.014 inch (Boston Scientific, Inc., Natick, MA)
 - Very soft, flexible distal tip, good for navigation into small aneurysms or through difficult anatomy.
 - “Supreme torque control.”

3. Coils

- (a) A dizzying array of coils are on the market, varying in size, shape, design, stiffness, presence or absence of “bioactive” material, and detachment systems. Firm, scientific data to support one coil over another is nearly nonexistent (although the device companies would prefer to have us believe otherwise). Very good results have been obtained with all the coils. The single most important principle of coil selection, is for the operator to use whichever coil system he or she is most experienced and comfortable with.
- (b) *Fundamentals of detachable coil design*
A coil consists of a fine platinum thread tightly looped around a thicker platinum wire. The coil is connected to a “pusher wire;” the attachment site is the location of detachment mechanism, which may be electrolytic, thermal, or hydraulic in design. The coil and pusher wire come from the manufacturer in a slim plastic delivery sheath; the sheath is placed within the hub of the RHV, and the coil and pusher wire are threaded together into the microcatheter. The operator controls the pusher wire and the coil together prior to detachment, which allows sequential advancement and withdrawal of the coil, as necessary, to deploy the coil within the aneurysm in the desired configuration. The coil is designed to assume one of a number of shapes as it is pushed out of the microcatheter (Fig. 5.3).
- (c) *Framing vs. filling vs. finishing coils*
Framing coils. These three-dimensional coils are designed to “frame” the aneurysm; that is, these coils are meant to “ovalize” or “sphericize” the aneurysm with gentle outward radial force to permit packing with two-dimensional coils. Ideally, some parts, or strands, of the three-dimensional

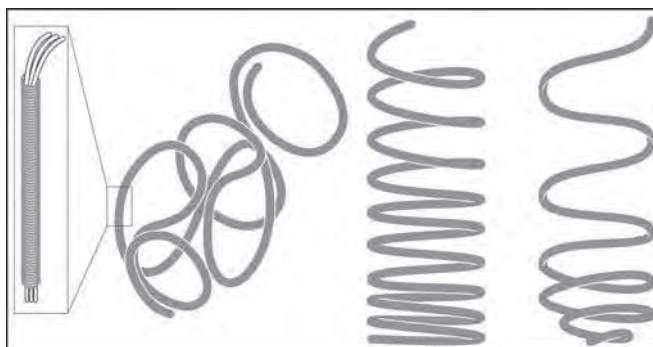


Fig. 5.3 Basic coil shapes. Three-dimensional framing coil (*left*), standard helical filling coil (*middle*), and two-diameter soft “finishing coil” (*right*). Insert demonstrates inner filament of coil surrounded by tightly wound fine platinum wire.

coil will also extend across the neck of the aneurysm, helping to narrow the effective neck area and facilitate further coil deposition. The standard design consists of a large omega followed by a small omega, followed by a large omega, and so forth.

- Examples: Micrus Spherical coils; GDC 3D and 360
- Filling coils. Intended to occupy space within the aneurysm after framing, these coils usually have a helical shape and are of intermediate stiffness.
 - Examples: Micrus Helipaq coils; GDC
- Finishing coils. The softest coils are designed for final packing of the aneurysm and “finishing off” of the neck.
 - Examples: Micrus Deltapaq coils; GDC Ultrasoft Stretch Resistant (USSR, also known as “Russian”) coils.

(d) 10-system vs. 18-system.

- The nomenclature indicating the two size categories of coils originated with the first microcatheters used for GDC coils, the Tracker-10 and the Tracker 18 (Boston Scientific, Inc., Natick, MA), designed specifically to accommodate GDC-10 coils and GDC-18 coils, respectively. The actual diameter of GDC-10 coils is 0.008 inch and for GDC-18 coils is 1.016 inch. 10-system coils are adequate for most aneurysms. 18-system coils are typically thicker and stiffer than 10-system coils, evocative of rebar (Fig. 5.4), and are appropriate for framing larger, unruptured aneurysms. An exception is the Orbit-18 system coil (Cordis, Miami Lakes, FL), which has softness that is comparable to GDC-10 coils.

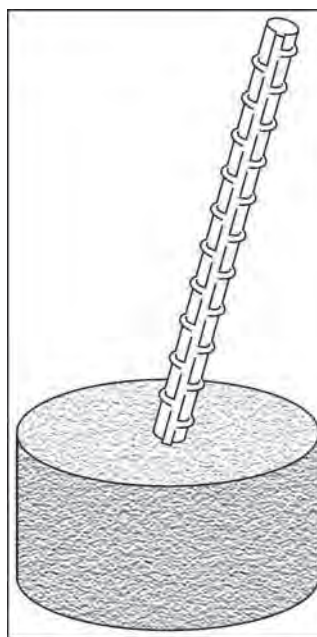


Fig. 5.4 Rebar. The astute operator will be reminded of rebar, which are reinforcing steel bars inside poured concrete, when using 18-system coils.

- (e) Platinum vs. “bioactive” coils.
- Continuing observations of aneurysm recanalization after treatment with bare platinum coils, lead to the introduction of coils containing materials meant to enhance fibrosis within the aneurysm and decrease the chance of recanalization. Several “bioactive” coil systems are on the market presently; some contain polyglycolic-polylactic acid (PGLA), a biopolymer similar to absorbable suture material. The polymer degrades by hydrolysis to glycolic acid and lactic acid, which promote fibrocellular proliferation. Matrix2™ (Boston Scientific, Inc., Natick, MA) coils consist of platinum coils covered by PGLA. Matrix coils have been found to accelerate aneurysm fibrosis and neointima formation in animals, compared to bare platinum coils.¹⁰ Cerecyte™ (Micrus Endovascular, Sunnyvale, CA) and Nexus (ev3, Irvine, CA) also incorporate PGLA. The HydroCoil® system (MicroVention, Inc., Aliso Viejo, CA) consists of platinum coils coated with an expandable hydrogel (see below).
- (f) Stretch resistance.
- Stretching of a coil occurs when the distal end of the coil become trapped, or entangled, in the aneurysm and the outer coil wire then unravels when the coil is withdrawn under tension. Coil stretching is problematic, because control over the coil is lost, and the entire coil can no longer be fully deployed into the aneurysm or withdrawn. A design modification to prevent this was to place a reinforcing filament (usually nylon) within the coil, to resist stretching. Most currently available coil lines have “stretch-resistant” models. *Stretch-resistance does not equal stretch-proof*; stretching, although less likely, is still possible with stretch-resistant coils.
- (g) Alternative coil designs
- GDC®-360° (Boston Scientific, Inc., Natick, MA). Coil design with a larger number of random “breaks” than most other coils, allowing it to conform to multiple lobes in complex aneurysms.
 - HydroCoil® (Terumo Medical/MicroVention, Inc., Aliso Viejo, CA). Platinum coil with a hydrogel coating that swells when it contacts blood. The hydrogel provides a higher filling volume than bare platinum coils by filling the interstices of the coil mass.¹¹ For instance, a “HydroCoil® 10” coil is 5 times the volume of a bare platinum coil of the same length, when fully expanded.
 - Hydrocoil® technique:
 - (1) For most applications, it is best to first frame the aneurysm with at least one 3D configuration coil that does not have hydrogel coating, then use the Hydrocoils® to fill in the basket.
 - (2) Hydrocoils® come with the electrolytic V-Trac® system. It is quicker and more reliable than most detachment systems.
 - (3) These coils are stiffer and harder to insert than bare platinum, so choose a coil with a smaller diameter loop and shorter length than you would for a similar platinum coil.
 - (4) The coils come in different wire thickness, so ensure that your microcatheter has a properly sized internal lumen. A Hydrocoil® 10 requires at least 0.015 inch lumen, Hydrocoil® 14 requires 0.019 inch lumen, and Hydrocoil® 18 requires 0.021 inch lumen.
 - (5) The hydrogel softens with heat, so it can be helpful to briefly steam the coil immediately before insertion, to soften it and allow the coil to take its helical shape.
 - (6) Do not allow the coil to contact blood or blood-stained saline, prior to insertion. This can start the swelling process.
 - (7) Insert the Hydrocoil into the microcatheter and carefully advance it into the aneurysm.
 - (8) As soon as even a small length of the coil begins to exit the microcatheter, start a timer. Theoretically you have only 5 min before the coil begins to swell and you can no longer pull it back through the microcatheter. Your

working time may be a little longer if your microcatheter has a big internal lumen.

- (9) Even though you only have a limited working time, you must be careful when advancing the relatively stiff coil into the aneurysm, and slow insertion can promote softening of the hydrogel due to the patient's body heat. This can allow the coil to more easily conform to the available space in the aneurysm.
 - (10) Detach the coil when it is in good position, with no encroachment on the parent artery, as confirmed by an angiographic run or roadmap.
 - (11) If you have to remove the coil prior to detachment, be very careful. If you start to feel resistance in pulling it back, the swelling process may have started. If the coil binds in the microcatheter, it may detach if you pull back against resistance.
 - (12) If the swelling Hydrocoil binds in the microcatheter, the only way to remove it is to withdraw the coil and microcatheter together. Be careful not to stretch the coil or dislodge the previously placed coils from the aneurysm.
 - (13) You can avoid problems by not advancing the coil against resistance and using multiple shorter coils rather than fewer longer coils.
 - (14) After you achieve fairly tight packing of the aneurysm with Hydrocoils, you can fill the remaining spaces with Microplex™ Hypersoft coils (Terumo Medical/MicroVention, Inc., Aliso Viejo, CA) or other ultrasoft, stretch resistant finishing coils.
 - (15) Consider prophylactic dexamethasone therapy and careful clinical monitoring, especially for aneurysms larger than 10 mm in diameter, as chemical meningitis¹² and hydrocephalus¹³ have been reported.
 - TruFill DCS coils (Cordis Neurovascular, Miami Lakes, FL). Coils with a slightly greater platinum wire diameter (0.012 inch compared to 0.010 inch), presumably leading to a higher packing density.¹⁴
 - Presidio™ coils (Micrus Endovascular, Sunnyvale, CA). Framing coils that are about double the length of other 3-D coils, which presumably are more stable than regular 3-D coils.
 - Axiom™ Detachable Coil System (ev3, Irvine, CA). Detachment system is unique: non-electrical "hooking/unhooking" mechanism.
- The authors' preferred coils for most cases:
- Micrus system. (One uses frequently, the other one doesn't.)
 - GDC system. (One uses frequently, the other one doesn't.)
 - *Bottom line.* Use a system that you are familiar with and that you have a good supply of different sizes and shapes.

Electrolytic Coil Detachment and the Heart

The GDC coil detachment system employs an electrical current that creates an electrical field in the patient's body. ECG perturbations have been observed during detachment with the GDC SynerG System, both at 1 mA and 2 mA power supply settings. These changes seem to occur more frequently at 2 mA and towards the end of the procedure. These observations initially raised concern that patients with or without cardiac pacemakers might be at risk for arrhythmias, but bench testing by the manufacturers and extensive clinical experience showed that the electrical fields generated did not affect cardiac electrophysiology. However, there is a theoretical risk that automatic defibrillators implanted in patients may sense the electrical activity generated during detachment, and interpret the activity as a cardiac arrhythmia, producing inadvertent defibrillator activation. Although the authors of this handbook have used GDC coils in patients with pacemakers and defibrillators without incident, they prefer to use non-electrical coil detachment systems, such as the Cordis Orbit system, in these patients.

5.2.1.1. Aneurysm access technique

1. Using a roadmap, the microcatheter is guided over the microwire into position within the parent vessel adjacent to the aneurysm (Fig. 5.5). Any redundancy (i.e., slack) in the microcatheter should be removed by gently pulling back on the microcatheter to straighten it out.
2. For an end-artery aneurysm (e.g., basilar apex aneurysms), the microwire can usually be carefully advanced directly into the aneurysm, followed by the microcatheter. For side-wall aneurysms (e.g., ophthalmic segment ICA aneurysms and SCA aneurysms), the microwire and microcatheter can sometimes be advanced directly into the aneurysm. Alternatively, if a shaped microcatheter is being used, the aneurysm can be accessed by guiding the microwire and microcatheter tip past the aneurysm neck. The microwire is pulled into the microcatheter, and the microcatheter is slowly pulled back, allowing the tip to flip into the aneurysm (Fig. 5.6).
3. The ideal position of the catheter tip within the aneurysm depends on the phase of the procedure (Fig. 5.7). When initially framing the aneurysm using a 3D-type coil, it is often best to have the tip of the microcatheter at the neck of the aneurysm to allow the coil to assume its spherical shape, to keep the coil from protruding into the parent artery, and to maximize the number of loops across the neck. Once the aneurysm is nicely framed, the microcatheter tip is placed in the center of the aneurysm, two thirds of the way to the top of the dome for added stability during the bulk of the filling phase of the procedure. During the finishing phase, you may need to reposition the microcatheter several times to fill residual pockets within the aneurysm.
4. Once the microcatheter tip is positioned within the aneurysm, the microwire should be withdrawn and advanced several times for most of the distance




Fig. 5.5 Sidewall aneurysm technique. Technique for accessing side-wall aneurysms with a J-shaped microcatheter. The microcatheter and microwire are advanced past the aneurysm neck (*left*). The microwire is withdrawn several millimeters into the microcatheter, and the microcatheter is gently pulled back until the tip flips into the aneurysm (*right*).




Fig. 5.6 Microcatheter position. Optimal position of the microcatheter tip for most aneurysms. The catheter tip is positioned between half-way and two-thirds of the way into the aneurysm dome. As the coil loops are deployed, the tip can "paintbrush" (i.e., sway) back and forth.

between the guide catheter and aneurysm. This maneuver helps to straighten out any remaining redundancy in the microcatheter, eliminating “potential energy” in the microcatheter that may cause it to leap forward unexpectedly during coiling.

5. When guide catheter angiograms are done, the RHV should be tightened around the microcatheter, securing it to prevent the microcatheter from being carried forward by the contrast as it is injected.
6. Occasionally, the anatomy of the aneurysm and the surrounding vessels (e.g., some SCA aneurysms) make it difficult to confirm that the microcatheter tip is positioned within the aneurysm. A microcatheter angiogram can clarify the position of the microcatheter and also delineate the size and configuration of the aneurysm neck.

(a) A 1 mL syringe is filled with 100% contrast and connected directly to the microcatheter hub after removal of the RHV for the angiogram.

(b) Obviously, “aneurysmograms” should be undertaken with caution in patients with subarachnoid hemorrhage.

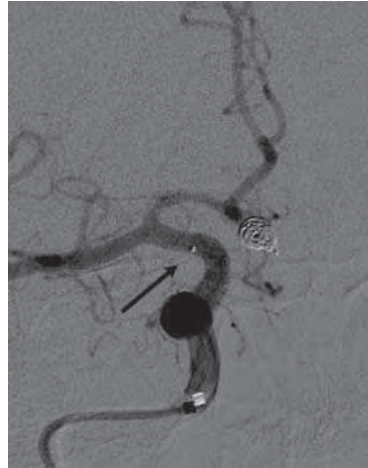


Fig. 5.7 Proximal marker position. The proximal microcatheter marker (*arrow*) is within the ICA. Attention to the proximal marker and its relationship to skull landmarks on fluoroscopy can provide information about the location of the tip of the microcatheter inside the aneurysm.

5.2.1.2. Coiling technique

1. Once the microcatheter tip is in a stable position, the framing coils are placed. The first 3-D coil should be chosen to be equal or slightly larger than the diameter of the aneurysm dome. A slightly larger 3-D coil may, it has been claimed, may “ovalize” the aneurysm and improve the effective dome-to-neck ratio.
2. During framing of the aneurysm, gentle movement of the microcatheter, either forward or backward, can help distribute the loops of the coil within the aneurysm in a more controlled fashion.
 - (a) “Paintbrushing,” i.e., the side-to-side motion of the microcatheter tip, is an indication that the microcatheter tip is in a good position, and not wedged between other coils, or between the coil mass and the dome of the aneurysm.
 - (b) Care must be taken to avoid placing any parts of a new coil between the existed coil mass and the dome of the aneurysm, as this can tear the aneurysm wall.
3. After each coil is deployed, prior to detachment, a guide catheter angiogram is done to check for:
 - (a) Coil position
 - (b) Thrombus within the parent vessel
 - (c) Perforation (i.e., contrast extravasation)
 - (d) Flow in adjacent vessels and/or vessel drop-out (e.g., when coiling a basilar apex aneurysm, flow in both PCAs should be monitored, as developing asymmetry in the filling of these vessels may be the first indication of parent artery compromise by coil or clot.
4. After detachment, the pusher wire is withdrawn under fluoroscopic visualization, to ensure that the coil has successfully detached.
5. In larger aneurysms, several 3-D coils can be placed within the aneurysm, each one smaller than the previous one (the “Russian Doll” technique).

6. After several coils are deployed, each additional coil becomes more difficult to see among the coils already in place. A *negative roadmap* can enable visualization of a coil as it is placed among other coils.
 - (a) To make a negative roadmap, the roadmap function is activated but no contrast is injected. This creates a blank white screen; during subsequent fluoroscopy, the coil being deployed will stand out as a black image.
7. Microcatheter control during coiling:
 - (a) Memorize the position of the proximal marker in relation to skull landmarks on fluoroscopy (Fig. 5.7).
 - When a negative roadmap is used, a “white dot” will appear on the screen when the proximal marker changes position.
 - (b) When advancing the microcatheter, care should be taken to avoid applying enough force to cause “buckling” of the microcatheter in the parent vessel. Buckling of the microcatheter can be an indication that a potentially hazardous amount of force is being applied to the microcatheter that could cause the tip to jump forward and puncture the aneurysm.
8. After one or more 3-D coils are deployed, for framing the aneurysm, filling coils are deployed, and then, toward the end of the coiling procedure, finishing coils are placed.
9. Decisions about when to switch from 3-D to filling coils, and then to finishing coils, depend on several factors, such as the amount of resistance encountered when advancing each coil, the appearance of the coil mass on fluoroscopy, and the position and stability of the microcatheter. Generally, any given type of coil should be continued to be deployed until resistance to coil advancement begins to rise. An increase in resistance should prompt a change to a coil with smaller dimensions, or to another, softer type of coil.
10. The authors advocate *tight packing* of the aneurysm, i.e., coiling of the aneurysm should proceed until the amount of resistance encountered with additional coils becomes prohibitive.
 - a. Some evidence indicates that the packing density (i.e., the total length of coil material placed in the aneurysm per unit of volume) is inversely related to the risk of aneurysm recurrence.^{15–17}
11. Occasionally, complex, multi-lobed aneurysms require the use of more than one shaped microcatheter. Depending on the anatomy of the aneurysm, a microcatheter of one shape can be used to coil one lobe of the aneurysm, and a second microcatheter can be used for the other lobe.
12. When coiling of the aneurysm is complete, high magnification PA and lateral angiograms should be obtained to confirm that the coiling is complete, prior to removal of the microcatheter.
13. The microcatheter is removed by advancing a microwire into the distal part of the microcatheter, to straighten out the microcatheter and prevent it from hooking on coil loops as it is removed from the aneurysm. The microcatheter and microwire are then withdrawn from the aneurysm together.
14. Final PA and lateral intracranial angiograms are done to check for vessel dropout and other abnormalities.
15. The guide catheter is withdrawn into the proximal part of the CCA or vertebral artery, and a final PA or lateral angiogram is done to check for vessel dissection.

Did you know?

Coiling of aneurysms with a branch arising from the dome may be okay. In a series of 9 patients in whom an aneurysm with a branch arising from the dome underwent coiling, the branch was preserved in 7 cases and no patients had any known thromboembolic complications¹⁸.

5.2.3. Onyx

Onyx (ev3, Irvine, CA) is an embolic agent that is supplied by the manufacturer in liquid form, dissolved in the organic solvent, dimethyl sulfoxide (DMSO). Onyx, an ethylene vinyl alcohol copolymer, is infused through a microcatheter into an aqueous environment; the DMSO diffuses outward into the surrounding tissue, allowing the material to precipitate into a spongy, space-occupying cast. The primary advantage of Onyx over other polymer embolic agents, such as n-butyl cyanoacrylate (NBCA),

is that it is non-adhesive, and carries a lower risk of binding to the microcatheter or other devices. As of this writing, Onyx embolization for the treatment of intracranial aneurysms is still investigational; Onyx has been approved by the FDA for embolization of intracranial AVMs. Onyx embolization of aneurysms requires a balloon-assist technique, to permit infusion of the material into the aneurysm without embolization into the distal circulation. All devices must be compatible with DMSO. Onyx comes in three concentrations:

1. Onyx-18 (6%) – for AVM nidus
2. Onyx-34 (8%) (more viscous)- for direct AV fistulas
3. Onyx HD (20%) (the most viscous) - for aneurysms

5.2.3.1. Onyx technique

1. Prior to the case, the patient should be placed on a combination antiplatelet regimen (Aspirin 325 mg PO daily and Clopidogrel, 75 mg PO daily for ≥ 3 days).
2. At the beginning of the procedure, the Onyx must be placed on an automated shaker for 20 min.
3. Systemic heparinization is critical.
4. Guide catheter: Must be large enough to accommodate a balloon catheter and a microcatheter – use a 6 French guide catheter or larger.
5. A compliant DMSO-compatible balloon (Hyperglide, ev3, Irvine, CA) is placed, deflated, in the parent vessel adjacent to the aneurysm.
6. A DMSO-compatible microcatheter (Rebar, ev3, Irvine, CA) is navigated into the aneurysm.
7. The balloon is inflated, and a gentle test injection of contrast is done through the microcatheter, to confirm that an adequate seal over the aneurysm neck has been made by the balloon.
8. The balloon is deflated, and the microcatheter is irrigated with heparinized saline, then primed with DMSO with a volume to match the microcatheter dead space (Rebar-10 dead space: 0.27 mL; Rebar-14 dead space: 0.29 mL).
9. A Cadence Precision Injector syringe (ev3) is filled with Onyx and attached to the hub of the microcatheter. This syringe permits controlled injection of small, precise volumes. Other DMSO-compatible syringes may be used.
10. Onyx is injected under fluoroscopic observation at a rate of about 0.1 mL per minute or slower.
11. The injection is continued, and paused after each incremental volume of approximately 0.2–0.3 mL, to allow the material to polymerize, and to allow temporary balloon deflation. Intermittent deflations of the balloon are necessary to prevent too great a volume of material, blood, and DMSO to accumulate in the aneurysm while the balloon is inflated, and to permit reperfusion of affected circulation. Several sequential re-inflations and injections may be necessary. The microcatheter position is not adjusted at all during the embolization.
12. *Important:* Do not pause the injections for more than about 2 min at a time, to avoid polymerization of the Onyx material within the microcatheter, with concurrent risk of microcatheter rupture with additional injection.
13. Periodic guide catheter angiograms should be done to monitor progress.
14. At the completion of embolization, with the balloon deflated, the microcatheter syringe is decompressed by aspiration of 0.2 mL; this prevents dribbling of Onyx material during the removal of the microcatheter.
15. Prior to removal of the microcatheter, 10 min are allowed to elapse to permit the Onyx material to set within the aneurysm.
16. For microcatheter removal, the balloon should be inflated a final time, to stabilize the Onyx mass as the microcatheter is withdrawn.
17. The patient should be kept on an antiplatelet regimen for 1 month after the procedure.

5.2.3.2. Post-procedure management

1. Complete neurological exam.
2. Admit to the NICU with neuro exams and groin checks Q 1 hr.
It is not uncommon for patients undergoing coiling of an unruptured aneurysm to have a headache in the evening after the procedure. A head CT should be obtained, if the headache is significant, to exclude hemorrhage. Most headaches in this setting are presumably due to “stretching” of the aneurysm by the coils, and resolve by the following day.

3. Most patients with unruptured aneurysms can be discharged on post-procedure day 1.
4. Routine radiographic follow-up. At 6 months: catheter angiogram and gadolinium-enhanced MRA. If the studies agree and there is no need for additional treatment, an MRA is obtained on a yearly basis indefinitely.
 - MRA protocol for imaging of coiled aneurysms:¹⁹
 - NVPA Coil
 - Axial plane
 - Pulse sequence: Vascular TOF SPGR
 - Imaging options: Variable bandwidth, Fast, 2ip512, Zip2, Smart Prep
 - TE: Minimum
 - Flip angle: 45
 - Bandwidth: 41.67
 - Freq: 320
 - Phase: 224
 - Nex: 1
 - Phase FOV: 0.75
 - Scan time: 1:01
 - FOV: 22
 - Slice thickness: 1.4
 - LOCS per slab: 60
 - Frequency direction: AP
 - User CVs screen
 - Maximum monitor period: 30
 - Image acquisition delay: 5
 - Turbo mode (1) Faster
 - Elliptical Centric (1) on

Tips and Tricks for Coiling Small Aneurysms

Coiling of small aneurysms tends to be surprisingly difficult and the risk of aneurysm perforation is higher than in larger aneurysms. A number of modifications of technique may reduce the risk of complications. Determining what size constitutes a small aneurysm is somewhat arbitrary, but for purposes of this discussion aneurysms that are 3 mm or smaller are considered “small.”

Rule#1. Avoid entering the aneurysm with the wire. Wherever possible the wire is used to get the microcatheter in the vicinity of the aneurysm, then pulled back into the microcatheter and manipulated into the aneurysm. The curved wire in the microcatheter can be rotated and often it turns the tip of the microcatheter to the desired direction.

Rule#2. Choose a curved tip microcatheter matched to the anatomy of the aneurysm. Ideally the shape of the curve should allow the microcatheter to point right into the aneurysm from the parent artery, without having to force it to make a turn into the aneurysm. That is sometimes easier said than done if the catheter curve wants to point away from the aneurysm, once in the vessel. The ideal situation is a torquable microcatheter like the Pivot™ (Boston Scientific, Natick, MA) whose curved tip can be rotated to the desired direction.

Rule #3. Whenever possible, pull the microcatheter back to engage the aneurysm rather than pushing it forward. Pushing the microcatheter forward can store kinetic energy in the catheter, and it could release suddenly and cause the catheter to jerk forward. Pulling it back releases the stored energy. Advance the microcatheter over the microwire in the parent artery distal to the aneurysm, pull the wire back into the microcatheter, and then slowly withdraw the microcatheter. If the shape of the tip of the microcatheter is correct, it will pop into the aneurysm, and not have a tendency to continue to move forward.

Rule#4. Do not advance the microcatheter deeply into the aneurysm. Many times an aneurysm can be successfully coiled with the tip at the neck, or even in the parent artery just pointing into the aneurysm. This prevents trauma to the aneurysm from the microcatheter and also allows the coils advanced into the aneurysm, to begin to curve before they reach the dome, pushing on the dome with a broad, curved surface, rather than the sharp point of the tip of the coil.

Rule#5. Always be careful to remove any slack in the microcatheter and guide catheter.

Rule#6. Advance as soft a coil as possible very, very slowly into the aneurysm.

Rule#7. Be prepared to gently adjust the microcatheter as the coil is going in to relieve any pressure the coil is putting on the aneurysm and to ensure that it is pointing in the proper direction to deploy the coil.

Rule#8. If the microcatheter backs up, consider using a softer or smaller diameter coil.
 Rule#9. If the coil prolapses into the parent artery, consider using a different design coil (3-D vs. helical configuration), a slightly firmer coil (soft vs. ultrasoft), or use balloon remodeling technique.
 Rule#10. As the coil is fully deployed, be certain that there is no forward tension on the microcatheter. (It may move forward when the coil detaches and the coil pusher wire is pulled back). The authors frequently allow the microcatheter to back well out of the aneurysm as long as the coil loops are all in the aneurysm. There is not usually a worry that the microcatheter needs to stay in the aneurysm, because often, only one coil is needed.
 Rule #11. Check again for slack, tighten the RHV on the guide catheter before doing a contrast injection, and do only low pressure hand injections to prevent launching the microcatheter forward during a run.
 Rule#12. Have a low threshold for placing a stent, even after coil detachment, if it has a wide neck.
 Rule#13. Small side-wall aneurysms may thrombose without even placing coils, if a stent redirects flow from the aneurysm.

5.2.4. Adjunctive techniques for the treatment of wide-necked aneurysms

Wide-necked aneurysms, generally defined as having a dome-to-neck ratio of $<2:1$, can be difficult to treat with coiling alone. Several strategies exist to coil wide-necked aneurysms using adjunctive techniques.

5.2.4.1. Balloon-assisted coiling

1. “Balloon remodeling” of wide-necked aneurysms is based on the concept that framing coils, placed in the aneurysm with the temporary support of a balloon, can “ovalize” the aneurysm and create a stable structure for coil packing (Fig. 5.8).
2. Systemic heparinization is critical. Consider pretreatment with anti-platelet agents. Guide catheter: Must be large enough to accommodate both a balloon catheter and a microcatheter – use a 6 French guide catheter or larger.
3. Attach either a two-headed rotating hemostatic valve (RHV) or two single RHVs in series to the guide catheter, and attach a continuous heparinized saline infusion to the RHV.
4. Watch out for bubbles in the system. The more connections on the catheter, the greater the chance of bubbles.
5. A non-detachable balloon (Hyperglide, ev3, Irvine, CA) is placed, deflated, in the parent vessel adjacent to the aneurysm.
6. A microcatheter is navigated into the aneurysm.
7. Insert one loop of coil into the aneurysm such that the tip of the coil points away from the dome. This prevents the catheter tip from getting wedged against the aneurysm dome when the balloon is inflated and limits the risk of aneurysm perforation during coil insertion.
8. The balloon is inflated under roadmap guidance, and the first framing coil is deployed.
9. The balloon is deflated prior to detachment, and the stability of the coil is assessed. If the first coil is stable, the coil is detached.
10. Additional framing coils are placed when the balloon is temporarily inflated. Caution: Coil deployment with the inflated balloon, can interfere with the smooth delivery of coils by diminishing the to- and fro- motion of the microcatheter tip.²⁰ This effect can be compensated for, to some degree, by gentle, slight movement of the catheter forward or backward as the coil is deployed.
11. As further coils are deployed, the balloon should be deflated, at least intermittently, after each coil is placed. This prevents too great a volume of coils and blood to accumulate in the aneurysm, and to allow reperfusion of the affected circulation.
12. Often, once a stable framing construct of coils has been created, additional filling and finishing coils can be safely inserted without inflating the balloon.

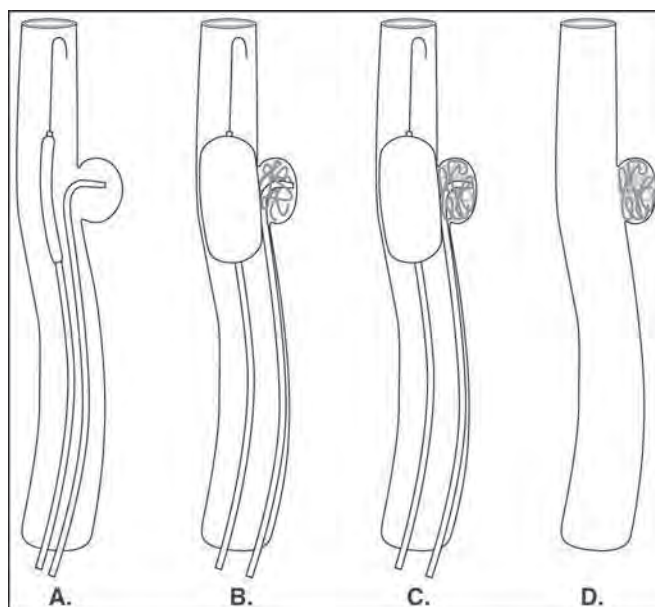


Fig. 5.8 Balloon remodeling technique. A temporary balloon inflated adjacent to a wide-necked aneurysm (A) permits placement of a framing coil, which "ovalizes" the aneurysm dome and allows packing with additional coils (B–C). The presence of the balloon forces the coils into a shape that they would not normally assume, which further contributes to the stability of the coil mass. D: final result.

13. For microcatheter removal, the balloon should be inflated a final time, to stabilize the coil mass as the microcatheter is withdrawn.

5.2.4.2. Stent-assisted coiling

Presently there are two stents designed specifically for stent-assisted coiling of wide necked intracranial aneurysms available in the US: the Neuroform³™ stent (Boston Scientific, Natick, MA) and the Enterprise™ Vascular Reconstruction Device and Delivery System (Cordis Neurovascular, Miami Lakes, FL). Both devices consist of a self-expanding Nitinol stent that is deployed in the parent vessel adjacent to the aneurysm neck; the stent then acts as a scaffold to hold coils in place inside the aneurysm (Fig. 5.9). Differences in the design between the two devices are discussed below. The use of these devices requires treatment with a dual antiplatelet regimen, and therefore, are most useful in the treatment of unruptured aneurysms. Stent-assisted coiling should be used in patients with subarachnoid hemorrhage, only when other techniques for treatment of the aneurysm, including partial coiling (see below) are not possible.

5.2.4.3. Neuroform vs. Enterprise

Each device has advantages and disadvantages.

1. Neuroform
 - (a) Advantages:
 - Older, more established device (available in the US since 2002).
 - Easy-to-see marker bands.
 - (b) Disadvantages:

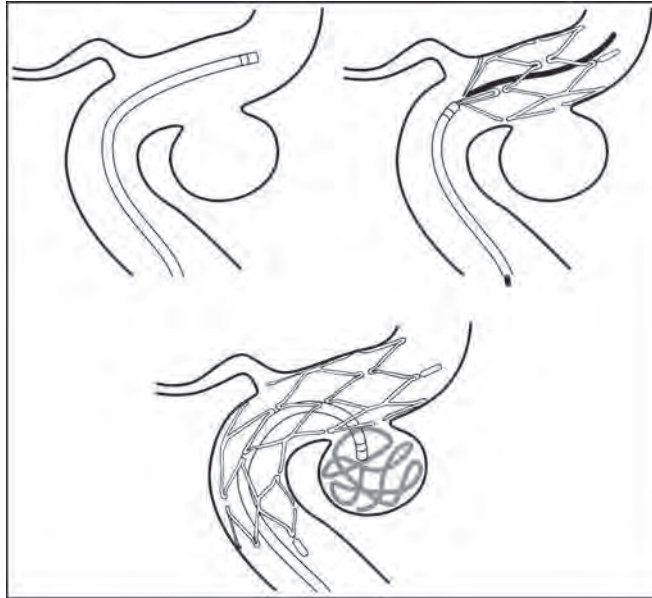


Fig. 5.9 Stent-assisted coiling technique. A microcatheter is advanced across the neck of the aneurysm (*upper left*). The stent is deployed across the aneurysm neck (*upper right*), and the aneurysm is coiled by placing a microcatheter through the stent and into the aneurysm (*lower*).

- Stiffer and harder to track than the Enterprise.
 - Designed to be tracked over an exchange-length microwire.
2. Enterprise
- (a) Advantages:
- More flexible and easier to navigate than the Neuroform.
 - Is designed to be deployed primarily, without first placing an exchange-length microwire.
 - May be pulled back into the microcatheter (recaptured) for repositioning during deployment, provided that no more than 80% of the stent has been placed outside of the microcatheter.
 - Flared ends of the stent make it easier to advance a microcatheter into the lumen of the deployed stent (in contrast to the Neuroform, which has a tendency to cause microcatheters to snag on the proximal markers).
- (b) Disadvantages:
- Newer device (available in the US in 2007).
 - Current size selection is more limited than it is for Neuroform.
 - Markers are harder to see on fluoroscopy.
 - The distal end of the delivery wire is larger in diameter than the wire immediately proximal to it (i.e., the part that is within the stent prior to deployment). This size step-off causes the delivery wire to snag on the stent after deployment in some cases.

5.2.4.4. General stent-assisted coiling procedures

1. Case selection.
- (a) Wide-necked aneurysms are generally defined as those with a neck width ≥ 4 mm or a dome-to-neck ratio of < 2 .

2. Antiplatelet therapy:
 - (b) Aspirin 325 mg PO QD for ≥ 3 days prior to the procedure and
 - (c) Clopidogrel (Plavix[®]) 75 mg PO QD for ≥ 3 days prior to the procedure.
 - Alternatively, a loading dose of Aspirin 325 mg PO and clopidogrel 300 mg PO or NG can be given the day before or at least 5 h before the procedure.
 - If the stent is used on an urgent basis (e.g., as a bail-out maneuver in procedure in which the use of a stent was not anticipated), a GPIIb/IIIa inhibitor infusion can be administered until a loading dose of aspirin and clopidogrel has had time to take effect. The authors favor abciximab, because the agent can be reversed, if needed, with platelet transfusion.
 - Abciximab 0.025 mg kg⁻¹ IV bolus followed by infusion at 10 mcg min⁻¹ IV for 12 h.
 - (a) Note: If an NG tube is going to be used for administration of clopidogrel, the tube should be placed prior to giving abciximab, to minimize the risk of nasopharyngeal bleeding.
3. In preparation for placement of the stent, measurements of the parent vessel and aneurysm neck width are made, and a stent is selected and deployed.
4. In most cases, the stent can be deployed and the aneurysm coiled during the same case. In situations where the stent placement procedure is difficult or prolonged, staging the procedure by bringing the patient back on another day for coiling can be helpful. After several weeks, the stent is endothelialized and is more stable, making trans-stent coiling somewhat easier.
5. Post-procedure management
 - (a) If manual or c-clamp compression is used when the sheath is removed, an extended compression time is needed because of the presence of aspirin and clopidogrel. Usually, 40 min is sufficient, compared to 15–20 in-patients without platelet therapy on board.
 - (b) Clopidogrel, 75 mg PO daily, should be continued for 1 month after the stent is deployed. Aspirin, either 325 mg or 81 mg PO daily, should be continued indefinitely.

5.2.4.5. Neuroform technique

1. Devices.
 - (a) The Neuroform stent comes from the manufacturer pre-loaded in a 3 French microdelivery catheter, and is positioned in the parent vessel adjacent to the aneurysm neck. A “stabilizer” catheter, which is also pre-loaded in the microdelivery catheter, is then used to stabilize and deploy the stent as the microdelivery catheter is withdrawn. The stent consists of a fine wire mesh that cannot be seen on standard fluoroscopy; platinum marker bands (four at each end) can be seen. The interstices of the fully-expanded stent are large enough to accommodate a microcatheter tip size 2.5 French or smaller (realistically, < 2.0 French) for coiling.
 - (b) Stent sizes:
 - Diameters: 2.5 mm, 3.0 mm, 3.0 mm, 3.5 mm, 4.0 mm, 4.5 mm.
 - Lengths: 15 mm, 20 mm, 30 mm.
 - (c) Stent selection. The stent must be long enough to extend at least 4 mm proximal and 4 mm distal to the aneurysm neck to avoid stent migration.
 - (d) Device preparation. The stent, loaded within the microdelivery catheter, is removed from the package and irrigated with heparinized saline. Instructions for irrigating, are on the plastic package. Care must be taken to avoid irrigating too forcefully, as the stent may be pushed distally within or even ejected from the microdelivery catheter.
2. Deployment technique.
 - (a) A microcatheter and microwire (0.010 inch or 0.014 inch) are navigated, using a roadmap, past the aneurysm.
 - (b) The microwire is removed and replaced with an exchange-length 0.014 inch microwire with a soft, J-shaped distal curve.
 - (c) *Always keep the tip of the exchange wire in sight on the fluoroscope monitor to ensure that it does not enter a small branch or perforate the vessel.*
 - (d) The wire is then wiped with a saline-soaked Telfa, and the microdelivery catheter containing the Neuroform2[™] stent is threaded onto the exchange-length wire using the brown plastic peel-away introducer.

- (e) The distal end of the microdelivery catheter is grasped between the thumb and index finger, and gentle pressure is applied to the microdelivery catheter just proximal to the stent to prevent the stent from sliding back as the catheter is advanced. The peel-away introducer is removed just before the tip of the microdelivery catheter enters the RHV.
 - (f) *While the tip of the exchange-length microwire is monitored by fluoroscopy*, the microdelivery catheter is advanced over the wire and into a position across the neck of the aneurysm.
 - (g) The stabilizer catheter is then held firmly in place as the microdelivery catheter is pulled back over the stabilizer and microwire, so that the stent is unsheathed. As the stent expands, the marker bands can be seen to spread.
 - *Important:* The exchange-length microwire position, through and past the stent, should be preserved during and after deployment of the stent. Maintaining “wire access” will ensure that the microcatheter used later for coiling, will pass within the stent and through the interstices, rather than outside the stent, between the stent and the parent vessel wall.
 - (h) The microdelivery catheter and stabilizer are then removed over the exchange-length wire. A standard-length microcatheter is then advanced over the microwire until it is past the stent. The exchange-length microwire is then removed and replaced with a standard-length microwire.
 - The microwire and microcatheter are then guided through the stent and into the aneurysm for coiling.
3. Neuroform tips:
- (a) The stent should be “unstuck” from its original position within the microcatheter, prior to deployment, by gently pushing on the stent with the stabilizer, with the stent in a relatively straight segment. Unsticking the stent will make it easier to deploy.
 - (b) If the stent is pushed back in the microdelivery catheter during its passage through the parent vessel on the way to the aneurysm, the stent can be re-advanced to the tip of the microdelivery catheter by placing the distal end of the microdelivery catheter in a relatively straight intracranial vessel (e.g., the M1 segment or the basilar artery). Straightening out the distal portion of the microdelivery catheter, will minimize the resistance as the stabilizer is used to push the stent back into optimal position 1–2 mm proximal to the tip of the microdelivery catheter.
 - (c) The Neuroform may be navigated into a position primarily (without exchanging over an exchange-length microwire), if the anatomy is favorable (i.e., non-tortuous) and the guide catheter can be placed in a very distal position. The new Neuron™ guide catheter (Penumbra, Inc., San Leandro, CA) is nicely suited for this.
 - (d) *“Y” configuration.* A single Neuroform stent placed across the neck of a basilar apex aneurysm can decrease the effective size of the neck to facilitate coiling. Some basilar apex aneurysms, however, are so wide-necked that two stents, placed in a “Y” configuration, are required.²¹ In this technique, one stent is positioned in the basilar artery, extending into one P1. A second Neuroform stent is guided through the interstices of the first stent, from the basilar artery and extending into the opposite P1 (Fig. 5.10).

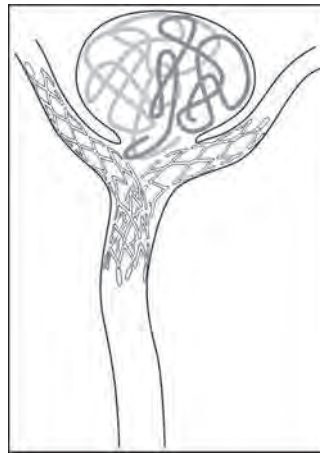


Fig. 5.10 “Y” configuration. A basilar apex aneurysm with a very wide neck is treated by extending one Neuroform stent into one P1, and another Neuroform stent into the opposite P1.

- (e) *Stent malpositioning*. Inadvertent deployment of a Neuroform stent such that one end of the device is close to the aneurysm neck, or actually extends into the aneurysm, can be managed in one of two ways:
 - In some aneurysms, even if a part of the stent has prolapsed into the aneurysm, coiling can be done successfully. In this situation, the coils can be deployed so that they encircle the stent struts or rest against the stent.
 - A second Neuroform stent can be deployed through the interstices of the first. It is important to maintain wire access after placement of the first stent, if this maneuver is going to be undertaken.
- (f) HydroCoils (MicroVention, Inc., Aliso Viejo, CA). The authors caution that using HydroCoils in combination with a Neuroform stent can be tricky. Once the hydrogel has expanded after contact with blood, there is a potential for binding or resistance between the gel and the stent struts, should the HydroCoil need to be withdrawn or repositioned through the stent.

5.3. Enterprise technique

1. Devices.
 - (a) The Enterprise stent comes from the manufacturer within a plastic sheath (the “dispenser loop”). A Prowler Select Plus microcatheter is first positioned across the neck of the aneurysm with an ordinary microwire; the microwire is then withdrawn and replaced with the stent/delivery wire assembly for stent positioning and deployment.
 - Delivery wire. A delivery wire is preloaded within the stent, and both the stent and delivery wire come from the manufacturer in the dispenser loop. The delivery wire has 3 radiopaque zones: the proximal wire, the “stent positioning marker,” (which indicates where the undeployed stent is loaded, and runs the length of the stent) and the distal tip.
 - Stent. The stent struts cannot be seen on standard fluoroscopy; each end of the four platinum marker bands can be seen, but are considerably more difficult to see compared to the markers on the Neuroform stent. The interstices of the fully-expanded Enterprise stent are large enough to accommodate a microcatheter tip with an outer diameter size ≤ 2.3 French for coiling.
 - (b) Stent sizes
 - Enterprise is indicated for use when the parent vessel diameter is 2.5 – 4.0 mm.
 - Diameter: 4.5 mm
 - Lengths: 14 mm, 22 mm, 28 mm, and 37 mm.
 - (c) Stent selection. The stent must be long enough to extend at least 4 mm proximal and 4 mm distal to the aneurysm neck, to avoid stent migration.
 - (d) Device preparation. Do not shape the tip of the delivery wire. The dispenser loop is irrigated with heparinized saline.
2. Deployment technique.
 - (a) A Prowler Select Plus microcatheter and microwire (0.010 inch or 0.014 inch) are navigated past the aneurysm using a roadmap. The tip is positioned at least 12 mm distal to the neck of the aneurysm.
 - (b) The microwire is removed and the Enterprise stent is inserted into the Prowler Select Plus microcatheter by placing the tip of the dispenser loop in the RHV and advancing the delivery wire.
 - As a final preparation, the distal end of the dispenser loop is placed in the RHV so that, the tip is about halfway in. The RHV is then tightened securely around the dispenser, and the RHV is vigorously flushed to back-irrigate the dispenser loop and purge the system of bubbles.
 - (c) The delivery wire can be advanced without fluoroscopy, until the marker on the wire is at the RHV. The marker on the delivery wire is 150 cm from the distal tip.
 - (d) The delivery wire and stent are then navigated into position across the neck of the aneurysm.

- (e) The stent is positioned for deployment by aligning the stent positioning marker on the delivery wire with the target site.
 - (f) The stent is deployed by holding the delivery wire firmly in place while carefully retracting the microcatheter.
 - If the stent position is not satisfactory, the stent may be recaptured by advancing the microcatheter (do not recapture by pulling the delivery wire). Stent recapture may be done provided that < 80% of the stent has been deployed; this is “recapturability limit” indicated by the proximal end of the stent positioning marker. If the proximal end of the stent positioning marker is still within the microcatheter, it is okay to recapture the stent.
 - The stent should be recaptured only once²². If further repositioning is needed, the stent should be removed and a new one is used.
 - (g) The microwire and microcatheter are then guided through the stent and into the aneurysm for coiling.
3. Enterprise tip:
- (a) If the delivery wire snags on the stent after deployment, readvance the microcatheter into the stent to recapture the wire.

5.3.1.1. “Double catheter” coiling technique

Some wide-necked aneurysms can be treated by using two Microcatheters to simultaneously place coils across the neck of the aneurysm.²³ One of the coils is detached in the aneurysm, and the other coil is left attached to its pusher wire to stabilize the coil construct (Fig. 5.11). The major problem with this technique is that long-term durability of the occlusion of the aneurysm with this technique, may not be very good,²⁴ possibly because tight coil packing of aneurysms is less feasible without the use of a balloon or stent.

1. Access can be accomplished with bilateral femoral artery sheaths and two guide catheters, although it is simpler to use a single large caliber guide catheter such as a 6 or 7 French Envoy[®] (Cordis Neurovascular, Miami Lakes, FL), and place both the microcatheters in one guiding catheter. The authors also like the 90 cm Cook Shuttle[®] (Cook Inc., Bloomington, IN). A 5 French Shuttle[®] will accept two 10-system microcatheters.
2. Attach either a two-headed rotating hemostatic valve (RHV) or two single RHVs in series to the guide catheter and attach a continuous heparinized saline infusion to the RHV.
3. Watch out for bubbles in the system. The more connections on the catheter, the greater the chance of bubbles.
4. Insert two low-profile microcatheters with preloaded micro guidewires into the RHVs.
5. Advance each microcatheter one after the other a few centimeters at a time.
6. Advance the microcatheters in this “leap-frog” fashion-alternatively one after the other in short increments, until they are positioned in the aneurysm.

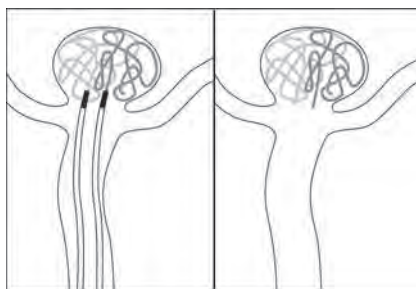


Fig. 5.11 Double microcatheter technique for coiling wide-necked aneurysm. With two microcatheters placed in the aneurysm, one coil is positioned but not detached, to act as a stabilizer as additional coils are deployed from the other microcatheter.

7. Through one microcatheter, advance a coil as large as possible, but not so large that it prolapses into the parent artery.
8. After multiple loops are in the aneurysm, advance a similar sized coil through the other microcatheter.
9. Position both coils in the aneurysm, then obtain an arteriogram with the injection of contrast through the guide catheter, and check to ensure that the coils are properly positioned and stable.
10. When you are happy with coil positioning, detach the coil with the least number of loops across the neck (this is usually the second coil deployed).
11. When the coil detaches, remove the pusher-wire.
12. Do not detach the other coil yet. That will be the stabilizer for the coil mass.
13. Advance another, slightly smaller coil through the microcatheter, and if properly positioned, detach it.
14. As long as the coil construct seems stable, you may want to alternate placing and detaching coils between the two microcatheters, to help assure uniform packing of the entire aneurysm.
15. Always be sure to have one coil positioned within the aneurysm, but not yet detached, to stabilize the system as each additional coil is advanced, positioned, and detached.
16. Confusion can arise about which coil is being detached and which is being left in place. It can help to cover the hub of the microcatheter containing the stabilizing coil with a sterile towel, to prevent mistakenly detaching that coil.
17. Note that, with bare platinum GDC® (Boston Scientific, Natick, MA) coils, you may get unintended “sympathetic detachment” of a coil in contact with one to which you pass the electrical current. This is rare, but can be avoided using coated coils or other coil types.
18. Continue this process until you achieve the desired packing density, or until the microcatheter kicks back or the coil begins to prolapse into the parent artery.

5.3.1.2. Partial coiling

In subarachnoid hemorrhage, the use of adjunctive techniques to coil wide-necked aneurysms adds complexity and risk to the procedure.²⁵ In addition, stent-supported coiling requires combination antiplatelet therapy to prevent in-stent thrombosis, which can increase the risk of rehemorrhage, and is problematic if additional surgical procedures, such as ventriculostomy, are anticipated. An alternative strategy is to partially coil the aneurysm, to protect against rehemorrhage in the acute phase, and undertake additional treatment, if necessary, in the future. Aneurysmal hemorrhage usually occurs due to a rent in the aneurysm dome, or from a daughter sack, if present. “Capping” of the aneurysm, or coiling of the apex of the dome, can protect against rebleeding in the short term.

5.3.2. Complications: avoidance and management

5.3.2.1. Overview of complications and complication rates with coiling

1. Recent large series report overall complication rates ranging from 8.4 to 18.9%.²⁵⁻²⁸
2. Risk factors for complications:
 - (a) Subarachnoid hemorrhage
 - (b) Adjunctive techniques (i.e., balloon-assisted and stent-assisted coiling)
 - (c) Small and large aneurysms
3. Experience counts: The odds of occurrence of a complication decreased with increasing operator experience.²⁹
For every five cases, the odds ratio declined by 0.69, $P = 0.03$

5.3.2.2. Aneurysm or vessel perforation

1. Mechanisms: Extrusion of the microwire, microcatheter, or a coil is most common; perforation can also occur during guide catheter angiograms.³⁰ Vessel perforations typically occur during procedures in which a device, such as an angioplasty balloon or stent, is tracked over a wire.

2. Frequency
 - (a) A meta-analysis of 17 reports found a significant difference in the frequency of perforations between ruptured and unruptured aneurysms³¹
 - Ruptured: 4.1%
 - Unruptured: 0.5% ($p < 0.001$)
 - (b) Risk factors
 - Small aneurysm size is an established risk factor for aneurysm perforation.³²⁻³⁴
 - *Vessel perforation*. Procedures involving tracking of devices with relatively high resistance (e.g., balloons and stents).
3. Avoidance
 - (a) Exercise extra caution when treating smaller aneurysms.
 - (b) Take measures to minimize antegrade force on the microcatheter and microwire
 - (c) Tighten the RHV around the microcatheter when doing guide catheter angiograms (to prevent the contrast injection from carrying the microcatheter forward).
 - (d) Avoid excessive packing.
 - (e) Avoid deploying coils between the framing coil and the dome of the aneurysm.
 - (f) *Vessel perforation*:
 - Attempt to keep the microwire in relatively larger, proximal vessels (e.g., M3 branches rather than M4 branches if possible).
 - Minimize motion of the microwire.
4. Management
 - (a) Recognition is the first step: An abrupt rise in blood pressure or ICP, or a sudden slowing of the heart rate should prompt an immediate guide catheter angiogram.
 - (b) *Resist the impulse to pull back on the perforating device!* The device may occlude or partially occlude the perforation, and withdrawal of the device may worsen the perforation.
 - (c) Reverse heparin anticoagulation with protamine.
 - (d) Continue deployment of coils, if possible. This may seal off the perforation.
 - If the microcatheter has perforated the aneurysm wall, a coil can be partially deployed into the subarachnoid space, then the microcatheter can be pulled back slightly until the microcatheter tip is inside the aneurysm again, and the remaining portion of the coil can be deployed within the aneurysm.
 - (e) 2nd Microcatheter technique:³⁵ While the perforating microwire or microcatheter is left in place, a second microcatheter can be navigated into the aneurysm to continue coiling the aneurysm.
 - (f) Occasionally, the tear in the aneurysm dome may extend into the parent vessel. In this situation, coil-occlusion of the parent vessel may be the only way to stop the hemorrhage. Obviously, this is a salvage maneuver and the patient's outcome will depend on the presence or absence of collateral circulation.
 - (g) Once the aneurysm is secured, a ventriculostomy may be necessary, particularly if the patient remains hypertensive (i.e., if there is ongoing evidence of elevated ICP).
 - (h) Once the patient is stabilized, obtain a head CT.
 - Tip: A head CT done immediately after an aneurysm perforation during coiling will always look ferocious, and possibly much worse than it actually is, due to the presence of contrast material (Fig. 5.12).

5.3.2.3. Thromboembolism

1. Mechanisms:
 - (a) Platelet-rich thrombus formation on devices used during the procedure
 - In an MRI study of thromboembolic events associated with endovascular treatment of basilar apex aneurysms, a majority of diffusion-weighted imaging lesions were found to be in arterial territories proximal to the aneurysm, indicating that most thrombi arose from catheters, wires, and balloons.³⁶
 - (b) Thrombus formation at the anode (coil) during electrolytic GDC detachment.³⁷
 - (c) Slowing of flow in the parent vessel caused by vasospasm or occlusion by the guide catheter.

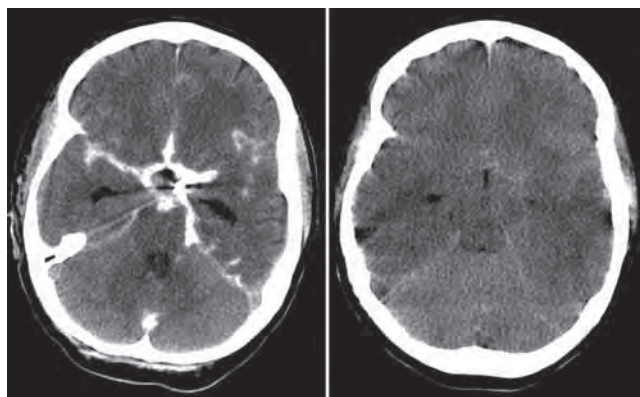


Fig. 5.12 Contrast extravasation on CT. A head CT done immediately after (*left*) and one day after (*right*) a re-rupture of a posterior communicating artery aneurysm during coiling. The presence of contrast created the appearance of more blood in the subarachnoid space than there actually was; the contrast in the subarachnoid space typically clears within a day. This particular patient was discharged from the hospital neurologically intact.

- (d) Risk factors:
 - Wide-necked aneurysms^{38–40}
 - Balloon-assisted coiling technique⁴¹
 - Loops of coil protruding into the parent vessel⁴².
- 2. Frequency
 - (a) Symptomatic thromboembolism: 2–8% of cases^{2, 38, 39, 42–44}
 - Majority of neurological complications due to thromboembolism are transient^{39, 41}
 - (b) “Asymptomatic” thromboembolism (evident on MRI): 28–61%^{39, 41, 45}
 - (c) Thrombus was identified at the coil-parent artery interface (i.e., at the neck of the aneurysm during coiling) in 4.3% of cases.⁴⁰
- 3. Avoidance
 - (a) Continuous flushing of all catheters with heparinized saline and meticulous attention to keeping all devices clear of bubbles and clot.
 - (b) Measures to prevent stasis of flow around the guide catheter
 - Adjust catheter position if guide catheter-induced vasospasm around the catheter is flow-limiting.
 - (c) Systemic anticoagulation with heparin. Although many operators undertake routine anticoagulation with IV heparin during aneurysm coiling, the data to support its use is lacking.
 - (d) Prophylactic aspirin. Some operators routinely place patients on aspirin prior to coiling procedures.⁴ In a review, Qureshi and colleagues found a lower incidence of thromboembolic events in patients treated concurrently with aspirin (6.4%) compared to patients who did not receive aspirin (8.9%).²
- 4. Management
 - (a) Recognition is the first step: Guide catheter angiograms should be done frequently to monitor for evidence of thrombosis, such as a filling-defect within the parent vessel adjacent to the aneurysm neck, or vessel drop-out.
 - (b) Most thrombotic material that appears during coiling, is likely to be platelet-rich; therefore, anti-platelet therapy is the first approach.
 - Abciximab⁴⁶ 0.25 mg kg⁻¹ IV rapid bolus followed by 125 mcg kg⁻¹ min⁻¹ infusion (to a maximum of 10 mg min⁻¹) for 12 h.
 - *Caution: Partial dosing of Abciximab should be avoided.* The authors recommend use of a full loading dose followed by IV

infusion for 12h, unless the threat of hemorrhagic complications is prohibitive. Experimental data and evidence from the interventional cardiology literature have identified a paradoxical drug-induced platelet activation effect with lower levels of platelet inhibition with abciximab, and a corresponding increase in thrombotic complications.⁴⁷⁻⁴⁹ In fact, the authors have observed two aneurysm coiling cases in which intra-arterial thrombosis seemed to worsen after partial doses of abciximab were given.

- A 2 mm diameter Amplatz Goose Neck microsnare (Microvena, White Bear Lake, MN) can be used to retrieve the thrombus,⁵⁰ or break it up, to increase the surface area of the thrombus to be exposed to the antiplatelet agent.
- (c) Thrombolytic agents are associated with a risk of significant hemorrhage, particularly during the treatment of ruptured aneurysms,⁵¹ and should be avoided.

5.3.2.4. Coil dislodgement or embolization

1. Mechanism
 - (a) Unstable or malpositioned coil.
 - (b) Wide-necked aneurysms appear to be at the greatest risk for this complication.
2. Frequency
 - (a) Uncommon - 0.5% of cases in one recent series.²⁸
3. Avoidance
 - (a) Meticulous coiling technique, use of adjunctive techniques for wide-necked aneurysms, such as stent-assisted or balloon-assisted coiling.
4. Management
 - (a) Various devices can be used to retrieve lost coils
 - 2 or 4 mm diameter Amplatz Goose Neck microsnare (Microvena, White Bear Lake, MN)
 - The Alligator Retrieval Device (Chestnut Medical Technologies, Menlo Park, CA)⁵²
 - Micro Elite snare (Vascular Solutions, Minneapolis, MN)
 - The Merci[®] Retriever device (Concentric Medical, Mountain View, CA)
 - (b) Coil extraction report.⁵³

5.3.2.5. Coil stretching

1. Mechanism
 - (a) A distal portion of the coil becomes trapped inside the aneurysm, and attempted withdrawal of the coil results in stretching of the coil. Trapping of a coil can occur when a part of the coil become ensnared in the aneurysm coil mass, jammed between the coil mass and the aneurysm dome, or hooked on a stent. Trapping can also occur if the microcatheter comes out of the aneurysm, and cannot be repositioned inside the aneurysm, after most of the coil has been deployed. Sugiu and colleagues distinguish between “stretching” of the coil, in which the distal part of the coil is trapped and the coil is only slightly elongated, and “unraveling,” in which the coil is elongated for some distance and is uncontrollable.⁵⁴
2. Frequency
 - (a) Uncommon. Reports from the dawn of the coiling era (i.e., the mid 1990s) described coil unraveling in 2% or less of cases.⁵⁵
3. Avoidance
 - (a) During deployment of a coil, do not allow any part of the coil to pass between the existing coil mass and the dome of the aneurysm.
 - (b) Do not “force” the coil; if coil resistance increases significantly during deployment, try withdrawing the coil by a small amount and re-deploying, change the position of the microcatheter tip, or try a different coil.
4. Management
 - (a) First step: Prompt recognition that the coil is trapped; avoid stretching the coil any further than it has already been stretched. A “stretched” - but not “unraveled” - coil can still be deployed with the following techniques:

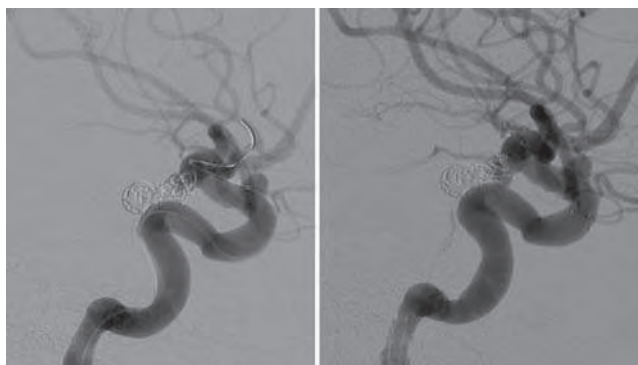


Fig. 5.13 Stent salvage of extruded coil loops. During coiling of a posterior communicating artery aneurysm, loops of coil prolapsed into the adjacent ICA (*left*). A Neuroform stent was deployed across the neck of the aneurysm (*right*); the extruded coil loops were pushed back into the aneurysm by the stent. The stent markers can be seen within the ICA.

- Stent placement.⁵⁶ A Neuroform stent can be used to trap a segment of coil that cannot be advanced into the aneurysm (**Fig. 5.13**).
 - “Rescue balloon procedure.” A non-detachable balloon is positioned adjacent to the aneurysm neck, and using balloon-assisted coiling technique, the remaining segment of the coil can be advanced into the aneurysm.⁵⁴
- (b) When a coil becomes unraveled to the point that it can no longer be advanced or withdrawn, the unraveled, elongated coil can extend for a long distance (1–2 meters or more). Three salvage maneuvers:
- “Monorail snare technique”.⁵⁷ Fiorella and colleagues described the use of a microsnares to grasp and withdraw a stretched coil (**Fig. 5.14**).
 - The elongated portion of coil can be withdrawn from the parent vessel and secured in an extracranial vessel. For example, if aneurysm is in the anterior circulation, the unraveled segment can be placed in the external carotid artery, where antegrade flow will stabilize the coil and prevent it from embolizing into the intracranial circulation. The axillary artery can be used in the same way for posterior circulation aneurysms.
 - The elongated portion of coil can be withdrawn all the way to the femoral artery, and secured there.

5.3.2.6. Vessel dissection

1. Mechanism: Wire or guide catheter-induced injury to intima.
2. Frequency
 - (a) 0.6% - 3.6% of cases.^{27, 28, 43}
 - (b) Vertebral artery dissections seem to be more common than carotid dissections.
 - (c) This complication is probably under-reported, as many operators do not do routine surveillance angiograms of the access vessel (i.e., the cervical carotid or vertebral artery) at the completion of the case, and therefore do not identify asymptomatic dissections.
3. Avoidance
 - (a) Take steps to minimize intimal trauma (see *Guide catheter placement technique* above).
4. Management
 - (a) Always do a guide catheter angiogram of the access vessel at the end of the case.

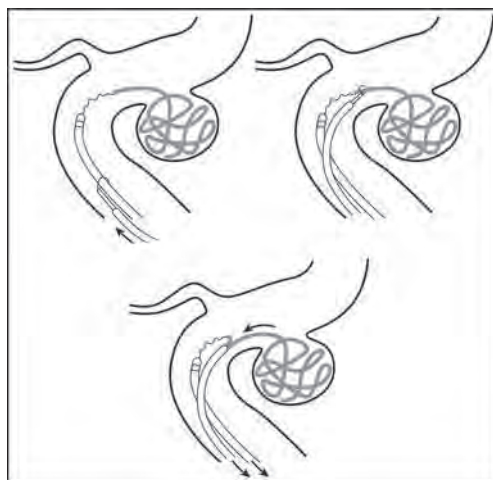


Fig. 5.14 Microsnare technique for retrieval of a stretched coil. A 2-mm Amplatz Goose Neck microsnare (Microvena Corp., White Bear Lake, MN) is placed through a second microcatheter. The hub of the indwelling microcatheter is then cut away with a scalpel, leaving the coil pusher wire intact, and removed. The open snare is then advanced over the outside of the microcatheter containing the pusher wire (*upper left*). The snare and second microcatheter are then advanced into the guide catheter over the indwelling microcatheter until the snare is in position, past the first microcatheter, to engage the unstretched portion of the coil (*upper right*). The snare can then be pulled back to grasp the coil, and both microcatheters can be removed, as a unit, to remove the coil (*lower*).

- (b) Antiplatelet therapy is usually sufficient; aspirin 325 mg suppository during or after the procedure, then PO daily. Add a second antiplatelet agent if possible (e.g., clopidogrel 75 mg PO daily).
- (c) Consider anticoagulation with IV heparin, in addition to antiplatelet therapy, if the dissection is flow-limiting and carries a risk of thrombosis.
- (d) Consider placing a stent across the lesion if it becomes necessary to continue to work in the affected vessel, or if further access through that vessel is anticipated.
- (e) Follow-up imaging should be done in 3–6 months (or at same time as the routine post-coiling angiogram is done. Most dissections treated with antiplatelet therapy will heal within 3–6 months.

5.3.2.7. Aneurysm recurrence

1. Aneurysm *recurrence* is defined as recanalization of the aneurysm on follow-up imaging, necessitating additional treatment of the aneurysm. Although aneurysm recurrence is generally not a procedural risk, it is a potential complication and should be discussed with the patient during the informed consent process.
2. Mechanism
 - (a) Coil mass compaction – thought to be the most common cause of aneurysm recurrence
 - (b) Growth of aneurysm neck or dome
3. Frequency
 - (a) UCLA series: Overall rate of aneurysm recanalization (defined as > 10% increase in contrast filling of the aneurysm compared to the immediate post-procedure angiogram), 20.9% over a mean angiographic follow-up period of 11 months⁵⁵
 - (b) Montreal series: “Major recurrence” (defined as a recurrence that is saccular and would permit re-treatment with coils), 20.7% at a mean angiographic follow-up of 16.49 months.⁵⁸

- (c) 15%.⁴³ Twelve (16%) other restudied patients have been found to have significant residual aneurysm or coil compaction/regrowth at the neck.⁴⁴
- (d) Systematic review, posterior circulation: 22.2%.²⁷
- 4. Avoidance
 - (a) "Tight packing of the aneurysm"
 - (b) "Bioactive" coils – unproven.
- 5. Management
 - (a) Repeat coiling procedure⁵⁹ or surgery.

5.4. Parent vessel sacrifice

5.4.1. Indications and contraindications

5.4.1.1. General indications

1. Large or giant aneurysms that cannot be readily treated without sacrificing the adjacent parent vessel.
2. Some cavernous segment aneurysms.
3. Arteriovenous fistulas
 - E.g., direct carotid-cavernous fistulas
4. Vascular neoplasms
5. Traumatic injury

5.4.1.2. Relative contraindications

1. Failure of balloon test occlusion (discussed in Chap. 6).
2. Existence of alternative strategies to treat the lesion while preserving the flow in the parent vessel.

5.4.2. Endovascular technique

The key step in the sacrifice of a large vessel, such as the ICA or the vertebral artery, is the temporary proximal flow arrest, to prevent inadvertent embolization into the cerebral vasculature during the procedure. In general, the vessel should be occluded either at, or immediately proximal to the lesion. Vessel occlusion can be done with either detachable coils or detachable balloons. Although detachable balloons are not commercially available in the US at the present time, they are available in Europe and Japan.

5.4.2.1. Patient preparation and vascular access

1. Adequate collateral circulation should be demonstrated by balloon test occlusion (Chap. 6).
 - (a) Alternatively, if surgical bypass is planned, then endovascular sacrifice should follow the surgical procedure promptly, to minimize the risk of graft thrombosis due to low flow.
2. Guide catheter access to the parent vessel is established.
 - (a) Single 6 French 90 cm sheath has an inner diameter large enough to accommodate two microcatheters.
 - Shuttle[®] –SL Flexor[®] Tuohy-Borst Side-Arm Introducer Set (Cook Inc., Bloomington, IN).
 - (b) Alternatively, two 5 French or 6 French guide catheters can be used.
 - Drawback: requires puncturing both femoral arteries.
3. A loading dose of IV heparin is given (70 U kg^{-1}) and 5 min later, a 5 mL specimen of blood for an activated clotting time (ACT) is drawn from the sheath. The ACT should be kept between 250 and 300 s for the duration of the procedure.

5.4.2.2. Coil embolization

1. Under roadmap guidance, the microcatheter to be used for coil deployment is positioned in the vessel where occlusion is planned.
2. A non-detachable balloon is positioned in the proximal segment of the vessel.
 - (a) Options:
 - HyperForm[®] balloon (ev3, Irvine, CA)
 - Guardwire[®] balloon (Medtronic AVE, Santa Rosa, CA)
3. A roadmap is made.
4. The balloon is inflated, and the temporary flow arrest is confirmed with gentle injection of contrast through the guide catheter under fluoroscopy.
5. The first coil is deployed.
 - (a) 18-system 3-D coils with a diameter about twice the diameter of the vessel, are usually effective.
 - (b) Prior to detachment, the balloon is briefly deflated to confirm that the first coil is stable. If there is no movement of the first coil with restoration of flow, the balloon is re-inflated and the first coil is detached.
6. Additional coils are deployed as necessary, to achieve tight packing of the vessel for several cm.
7. The balloon is then deflated and final angiographic images are obtained.

5.4.2.3. Detachable balloon embolization

The Goldvalve[™] balloon (Acta Vascular, Santa Clara, CA), is available in most of the world outside of the United States, and the vendor is working on obtaining approval for the North American market. Balloons are quicker than coils in achieving complete stasis of flow, but require a little more preparation. Occlusion of an artery with detachable balloons should always be undertaken with two balloons, placed end-to-end, with the proximal balloon functioning as a “safety” balloon to minimize the chance of distal migration of the balloons.

1. A large guide catheter is required, often 7 or 8 French (or use a 6 or 7 French, 90 cm sheath).
2. Choose a balloon size that is slightly larger than the diameter of the vessel to be occluded.
3. Prepare two balloons according to the manufacturer’s recommendations. Usually, the balloon valve should be tested using sterile water, as saline or contrast can potentially gum up the valve.
4. Attach the balloons to their recommended delivery catheters. The company’s Mini-torquer works well. You can also use an extended tip Tracker catheter (Boston Scientific, Natick, MA). The catheters should be prefilled with dilute contrast.
5. Be careful not to damage the balloon or valve as you place it on the catheter.
6. Attach an RHV to the balloon catheter, and a one-way stopcock or FloSwitch[™] (BD Medical, Franklin Lakes, NJ) to the RHV. Fill the entire system with 50:50 dilute contrast.
7. If the guide catheter is large enough, it is preferable to advance the two balloons simultaneously through the guide catheter and into the vessel, to limit the risk of premature detachment.
8. Ideally, the balloons should be positioned in a relatively straight segment. They will be less likely to move forward or backward than if they are placed within a curve or at a branch point.
9. Avoid inflating balloons next to a calcified atherosclerotic plaque. The calcium can puncture and deflate the balloon.
10. When the balloons are in proper position, inflate the balloons with contrast. If they are properly sized, they will flatten out and elongate as they are inflated.
11. Do not exceed the recommended maximum inflation volume of the balloon.
12. Leave the balloons inflated in place for a while, even if a balloon test occlusion has already been done. Observation for several minutes prior to detachment, will help ensure that the balloons are stable in that position.
13. When the balloon position and stability appears to be satisfactory, detach the distal balloon by slowly, gently pulling back on the balloon catheter. If the balloon doesn’t want to detach, gently pull back against the more proximal balloon to allow it to detach off its catheter.
14. When the balloon detaches, remove its catheter.

15. Watch the balloon for a few minutes to ensure that it stays inflated and in position.
16. The proximal balloon is then detached.
17. If the balloon will not easily detach by pulling on its delivery catheter or looks like it is sliding back proximally, you can try gently advancing the guide catheter so that, it is just proximal to the balloon. This will stabilize the balloon as the delivery catheter is pulled back. Alternatively, a non-detachable balloon may be advanced to just below the safety balloon, and inflated to stabilize the balloon.
18. Another option to facilitate balloon detachment is to have a 4 or 5 French catheter in a coaxial position over the delivery catheter prior to detachment of the balloon. This greatly facilitates balloon detachment, as the balloon can be stabilized with the coaxial catheter. However, this technique makes it nearly impossible to use two catheter systems in one guiding catheter. Therefore, both femoral arteries should be used, with two separate guide catheters, to simultaneously place two balloons.
19. In some cases, an experienced operator can then detach two balloons sequentially through a single guide catheter.
20. It is never a good policy to count on just one balloon to occlude a vessel. Valves can fail and balloons deflate and migrate. Silicone balloons can migrate distally, even if fully inflated, although the latex Goldvalve™ is less likely to do so.

5.5. References

1. Qureshi AI, Suri MF, Khan J, et al. Endovascular treatment of intracranial aneurysms by using Guglielmi detachable coils in awake patients: safety and feasibility. *J Neurosurg* 2001;94(6):880-5.
2. Qureshi AI, Luft AR, Sharma M, Guterman LR, Hopkins LN. Prevention and treatment of thromboembolic and ischemic complications associated with endovascular procedures: Part II—Clinical aspects and recommendations. *Neurosurgery* 2000;46(6):1360-75; discussion 75-6.
3. Qureshi AI, Luft AR, Sharma M, Guterman LR, Hopkins LN. Prevention and treatment of thromboembolic and ischemic complications associated with endovascular procedures: Part I—Pathophysiological and pharmacological features. *Neurosurgery* 2000;46(6):1344-59.
4. Bendok BR, Hanel RA, Hopkins LN. Coil embolization of intracranial aneurysms. *Neurosurgery* 2003;52(5):1125-30; discussion 30.
5. Harrigan MR, Levy EI, Bendok BR, Hopkins LN. Bivalirudin for endovascular intervention in acute ischemic stroke: case report. *Neurosurgery* 2004;54(1):218-22; discussion 22-3.
6. Lesley WS, Lazo A, Chaloupka JC, Weigele JB. Successful treatment of cerebral vasospasm by use of transdermal nitroglycerin ointment (Nitropaste). *AJNR Am J Neuroradiol* 2003;24(6):1234-6.
7. Kallmes DF, McGraw JK, Evans AJ, et al. Thrombogenicity of hydrophilic and nonhydrophilic microcatheters and guiding catheters [published erratum appears in *AJNR Am J Neuroradiol* 1997 Oct;18(9):1800]. *AJNR Am J Neuroradiol* 1997;18(7):1243-51.
8. Abe T, Hirohata M, Tanaka N, et al. Distal-tip shape-consistency testing of steam-shaped microcatheters suitable for cerebral aneurysm coil placement. *AJNR Am J Neuroradiol* 2004;25(6):1058-61.
9. Kiyosue H, Hori Y, Matsumoto S, et al. Shapability, memory, and luminal changes in microcatheters after steam shaping: a comparison of 11 different microcatheters. *AJNR Am J Neuroradiol* 2005;26(10):2610-6.
10. Murayama Y, Tateshima S, Gonzalez NR, Vinuela F. Matrix and bioabsorbable polymeric coils accelerate healing of intracranial aneurysms: long-term experimental study. *Stroke* 2003;34(8):2031-7.
11. Kallmes DF, Fujiwara NH. New expandable hydrogel-platinum coil hybrid device for aneurysm embolization. *AJNR Am J Neuroradiol* 2002;23(9):1580-8.
12. Meyers PM, Lavine SD, Fitzsimmons BF, et al. Chemical meningitis after cerebral aneurysm treatment using two second-generation aneurysm coils: report of two cases. *Neurosurgery* 2004;55(5):1222.
13. Brisman JL, Song JK, Niimi Y, Berenstein A. Treatment Options for Wide-Necked Intracranial Aneurysms Using a Self-Expandable Hydrophilic Coil and a Self-Expandable Stent Combination. *AJNR Am J Neuroradiol* 2005;26(5):1237-40.
14. Slob MJ, van Rooij WJ, Sluzewski M. Coil thickness and packing of cerebral aneurysms: a comparative study of two types of coils. *AJNR Am J Neuroradiol* 2005;26(4):901-3.
15. Kawanabe Y, Sadato A, Taki W, Hashimoto N. Endovascular occlusion of intracranial aneurysms with Guglielmi detachable coils: correlation between coil packing density and coil compaction. *Acta Neurochir (Wien)* 2001;143(5):451-5.
16. Sluzewski M, van Rooij WJ, Slob MJ, Bescos JO, Slump CH, Wijnalda D. Relation between aneurysm volume, packing, and compaction in 145 cerebral aneurysms treated with coils. *Radiology* 2004;231(3):653-8.
17. Slob MJ, Sluzewski M, van Rooij WJ. The relation between packing and reopening in coiled intracranial aneurysms: a prospective study. *Neuroradiology* 2005;47(12):942-5.
18. Lubicz B, Lefranc F, Levivier M, et al. Endovascular treatment of intracranial aneurysms with a branch arising from the sac. *AJNR Am J Neuroradiol* 2006;27(1):142-7.
19. Cure' JK. Brain MRA Protocol for Coiled Aneurysms. In: Birmingham, AL; 2006.
20. Phatouros CC, Halbach VV, Malek AM, Dowd CF, Higashida RT. Simultaneous subarachnoid hemorrhage and carotid cavernous fistula after rupture of a paraclinoid aneurysm during balloon-assisted coil embolization. *AJNR Am J Neuroradiol* 1999;20(6):1100-2.
21. Perez-Arjona E, Fessler RD. Basilar artery to bilateral posterior cerebral artery 'Y stenting' for endovascular reconstruction of wide-necked basilar apex aneurysms: report of three cases. *Neuro Res* 2004;26(3):276-81.
22. Cordis Neurovascular I. Instructions For Use: Cordis Enterprise™ Vascular Reconstruction Device and Delivery System. In: 2007.
23. Baxter BW, Rosso D, Lownie SP. Double microcatheter technique for detachable coil treatment of large, wide-necked intracranial aneurysms. *AJNR Am J Neuroradiol* 1998;19(6):1176-8.
24. Terada T, Tsura M, Matsumoto H, et al. Endovascular treatment of unruptured cerebral aneurysms. *Acta Neurochir Suppl* 2005;94:87-91.
25. Henkes H, Fischer S, Weber W, et al. Endovascular coil occlusion of 1811 intracranial aneurysms: early angiographic

- and clinical results. *Neurosurgery* 2004;54(2):268-80; discussion 80-5.
26. Bristra EH, Rinkel GJ, van der Graaf Y, van Rooij WJ, Algra A. Treatment of intracranial aneurysms by embolization with coils: a systematic review. *Stroke* 1999;30(2):470-6.
 27. Lozier AP, Connolly ES, Jr, Lavine SD, Solomon RA. Guglielmi detachable coil embolization of posterior circulation aneurysms: a systematic review of the literature. *Stroke* 2002;33(10):2509-18.
 28. Murayama Y, Nien YL, Duckwiler G, et al. Guglielmi detachable coil embolization of cerebral aneurysms: 11 years' experience. *J Neurosurg* 2003;98(5):959-66.
 29. Singh V, Gress DR, Higashida RT, Dowd CF, Halbach VV, Johnston SC. The learning curve for coil embolization of unruptured intracranial aneurysms. *AJNR Am J Neuroradiol* 2002;23(5):768-71.
 30. McDougall CG, Halbach VV, Dowd CF, Higashida RT, Larsen DW, Hieshima GB. Causes and management of aneurysmal hemorrhage occurring during embolization with Guglielmi detachable coils. *J Neurosurg* 1998;89(1):87-92.
 31. Cloft HJ, Kallmes DF. Cerebral aneurysm perforations complicating therapy with Guglielmi detachable coils: a meta-analysis. *AJNR Am J Neuroradiol* 2002;23(10):1706-9.
 32. Ricolfi F, Le Guerin C, Blustajn J, et al. Rupture during treatment of recently ruptured aneurysms with Guglielmi electrodetachable coils. *AJNR Am J Neuroradiol* 1999;19(9):1653-8.
 33. Doerfler A, Wanke I, Egelhof T, et al. Aneurysmal rupture during embolization with Guglielmi detachable coils: causes, management, and outcome. *AJNR Am J Neuroradiol* 2001;22(10):1825-32.
 34. Sluzewski M, Bosch JA, van Rooij WJ, Nijssen PC, Wijnalda D. Rupture of intracranial aneurysms during treatment with Guglielmi detachable coils: incidence, outcome, and risk factors. *J Neurosurg* 2001;94(2):238-40.
 35. Willinsky R, terBrugge K. Use of a second microcatheter in the management of a perforation during endovascular treatment of a cerebral aneurysm. *AJNR Am J Neuroradiol* 2000;21(8):1537-9.
 36. Soeda A, Sakai N, Murao K, et al. Thromboembolic events associated with Guglielmi detachable coil embolization with use of diffusion-weighted MR imaging. Part II. Detection of the microemboli proximal to cerebral aneurysm. *AJNR Am J Neuroradiol* 2003;24(10):2035-8.
 37. Guglielmi G, Vinuela F, Sepetka I, Macellari V. Electrothrombosis of saccular aneurysms via endovascular approach. Part I: Electrochemical basis, technique, and experimental results. *J Neurosurg* 1991;75(1):1-7.
 38. Vinuela F, Duckwiler G, Mawad M. Guglielmi detachable coil embolization of acute intracranial aneurysm: perioperative anatomical and clinical outcome in 403 patients. *J Neurosurg* 1997;86(3):475-82.
 39. Pelz DM, Lownie SP, Fox AJ. Thromboembolic events associated with the treatment of cerebral aneurysms with Guglielmi detachable coils. *AJNR Am J Neuroradiol* 1998;19(8):1541-7.
 40. Workman MJ, Cloft HJ, Tong FC, et al. Thrombus formation at the neck of cerebral aneurysms during treatment with Guglielmi detachable coils. *AJNR Am J Neuroradiol* 2002;23(9):1568-76.
 41. Soeda A, Sakai N, Sakai H, et al. Thromboembolic events associated with Guglielmi detachable coil embolization of asymptomatic cerebral aneurysms: evaluation of 66 consecutive cases with use of diffusion-weighted MR imaging. *AJNR Am J Neuroradiol* 2003;24(1):127-32.
 42. Derdeyn CP, Cross DT, 3rd, Moran CJ, et al. Postprocedure ischemic events after treatment of intracranial aneurysms with Guglielmi detachable coils. *J Neurosurg* 2002;96(5):837-43.
 43. Friedman JA, Nichols DA, Meyer FB, et al. Guglielmi detachable coil treatment of ruptured saccular cerebral aneurysms: retrospective review of a 10-year single-center experience. *AJNR Am J Neuroradiol* 2003;24(3):526-33.
 44. Ross IB, Dhillon GS. Complications of endovascular treatment of cerebral aneurysms. *Surg Neurol* 2005;64(1):12-8.
 45. Rordorf G, Bellon RJ, Budzik RF, Jr, et al. Silent thromboembolic events associated with the treatment of unruptured cerebral aneurysms by use of Guglielmi detachable coils: prospective study applying diffusion-weighted Imaging. *AJNR Am J Neuroradiol* 2001;22(1):5-10.
 46. Ng PP, Phatouros CC, Khangure MS. Use of glycoprotein IIb/IIIa inhibitor for a thromboembolic complication during Guglielmi detachable coil treatment of an acutely ruptured aneurysm. *AJNR Am J Neuroradiol* 2001;22(9):1761-3.
 47. Steinhubl SR, Talley JD, Braden GA, et al. Point-of-care measured platelet inhibition correlates with a reduced risk of an adverse cardiac event after percutaneous coronary intervention: results of the GOLD (AU-Assessing Utegra) multicenter study. *Circulation* 2001;103(21):2572-8.
 48. Quinn MJ, Plow EF, Topol EJ. Platelet glycoprotein IIb/IIIa inhibitors: recognition of a two-edged sword? *Circulation* 2002;106(3):379-85.
 49. Kleinman N. Assessing platelet function in clinical trials. In: Quinn M, Fitzgerald D, eds. Platelet function assessment, diagnosis, and treatment. Totowa, NJ: Humana Press; 2005:369-84.
 50. Fourie P, Duncan IC. Microsare-assisted mechanical removal of intraprocedural distal middle cerebral arterial thromboembolism. *AJNR Am J Neuroradiol* 2003;24(4):630-2.
 51. Cronqvist M, Pierot L, Boulin A, Cognard C, Castaings L, Moret J. Local intraarterial fibrinolysis of thromboemboli occurring during endovascular treatment of intracerebral aneurysm: a comparison of anatomic results and clinical outcome. *AJNR Am J Neuroradiol* 1998;19(1):157-65.
 52. Henkes H, Lowens S, Preiss H, Reinartz J, Miloslavski E, Kuhne D. A new device for endovascular coil retrieval from intracranial vessels: alligator retrieval device. *AJNR Am J Neuroradiol* 2006;27(2):327-9.
 53. Zoarski GH, Bear HM, Clouston JC, Ragheb J. Endovascular extraction of malpositioned fibered platinum microcoils from the aneurysm sac during endovascular therapy. *AJNR Am J Neuroradiol* 1997;18(4):691-5.
 54. Sugiu K, Martin JB, Jean B, Rufenacht DA. Rescue balloon procedure for an emergency situation during coil embolization for cerebral aneurysms. Technical note. *J Neurosurg* 2002;96(2):373-6.
 55. Cognard C, Weill A, Castaings L, Rey A, Moret J. Intracranial berry aneurysms: angiographic and clinical results after endovascular treatment. *Radiology* 1998;206(2):499-510.
 56. Fessler RD, Ringer AJ, Qureshi AI, Guterman LR, Hopkins LN. Intracranial stent placement to trap an extruded coil during endovascular aneurysm treatment: technical note. *Neurosurgery* 2000;46(1):248-51; discussion 51-3.
 57. Fiorella D, Albuquerque FC, Deshmukh VR, McDougall CG. Monorail snare technique for the recovery of stretched platinum coils: technical case report. *Neurosurgery* 2005;57(1 Suppl):E210; discussion E.
 58. Raymond J, Guilbert F, Weill A, et al. Long-term angiographic recurrences after selective endovascular treatment of aneurysms with Detachable coils. *Stroke* 2003;34(6):1398-403.
 59. Kang HS, Han MH, Kwon BJ, Kwon OK, Kim SH. Repeat endovascular treatment in post-embolization recurrent intracranial aneurysms. *Neurosurgery* 2006;58(1):60-70; discussion 60-70.

6. Provocative Testing

6.1. Introduction

Provocative testing in the field of neuroendovascular therapy consists of a number of procedures that attempt to predict what, if any, clinical deficit would result from the occlusion of some vessel or resection of the territory supplied by that vessel. The provocative testing may be mechanical, in which a vessel is temporarily occluded, usually using a balloon, or pharmacologically, in which an agent is injected to temporarily anesthetize and inactivate a neuroanatomical territory in the brain, spinal cord, or a nerve. When the provocative test is being done, the patient is examined to check for new neurological deficits that may result from either the lack of blood flow to a vascular territory in the case of balloon test occlusion, or an anesthetic infusion into the neural tissue supplied by the vessel being tested pharmacologically. These procedures may be done as a diagnostic procedure preoperatively, or may be done as part of a therapeutic endovascular procedure to ensure the safety of occluding a vessel by endovascular means. This chapter focuses on arterial procedures. The reader is invited to consult Chap. 12 in this book for additional information on similar topics on veins.

6.2. Mechanical provocative testing: Balloon test occlusion

6.2.1. Background

Temporary occlusion of a vessel has been shown to be a safe, predictable way to estimate the effect of permanent vascular occlusion. Test occlusion is done to predict whether occlusion of the vessel will have negative hemodynamic consequences, which can result in ischemic injury to neural tissue and result in a permanent functional deficit. The notion of temporarily occluding a vessel to predict the functional effects was reported by Matas¹ in the early years of the twentieth century, and therefore, the test occlusion procedure is sometimes referred to as the Matas test.² The use of an endovascular balloon allows for reversible occlusion of the vessel in a predictable fashion. Occlusion is confirmed angiographically during the procedure. As it is done via an endovascular approach, the patient can be systemically heparinized to prevent thrombotic complications of the procedure. Balloon test occlusion is generally performed in a preoperative setting when it is anticipated that one of the vessels supplying the brain might need to be occluded and resected due to tumor invasion, and involvement with a vascular lesion is in the anticipated path of a surgical approach to another lesion.

However, there are conditions that must be met to ensure the reliability of the test occlusion results. First, the vessel being occluded must be at the proper site and level to simulate the anticipated permanent occlusion. One must be careful to test occlude beyond any potential collateral vessels that may still provide flow to the brain during the test, yet may be lost after more distal permanent occlusion. In the carotid circulation, more than half the population has angiographically apparent branches of the proximal intracranial carotid that can be a pathway for collateral flow to the brain, during a test occlusion in the cervical carotid.³ The ophthalmic artery is also a significant collateral pathway in many patients and some patients who pass a test occlusion with a balloon proximal to the ophthalmic, may fail when the balloon is placed at the level of the ophthalmic, occluding the collateral flow via that vessel.⁴ A simple rule of thumb is to perform a test occlusion of a vessel with balloon inflation at the same level as the anticipated permanent occlusion.

Another condition is that the test should reliably predict neurological consequences of the vascular occlusion. Temporary occlusion of a vessel could sufficiently

lower the blood flow to an eloquent neuroanatomic region, so that a demonstrable neurological deficit occurs. The situation is simple if the test is abnormal, and the patient exhibits a neurological deficit during the test: it is very likely that the patient would suffer some hemodynamic ischemic injury due to permanent occlusion of that vessel. It may not be universally true that a permanent deficit would be expected, thanks to the potential for collateral enlargement after occlusion, and also even when neural tissue is damaged, there is some potential for plasticity in the nervous system to allow for restoration of function. However, it is not a wise policy to ignore a positive test that produces a deficit, as more often than not, it does predict that something bad will happen if that vessel is permanently occluded. More problematic is the situation in which no deficit occurs during the test occlusion. Does this imply that the patient will never have an ischemic problem from permanent occlusion of the vessel, or is there a potential for false negative test occlusions?

Carotid test occlusion is performed relatively frequently, and experience with the procedure has shown the predictive power of the test. Linskey, et al.⁵ made a systematic review of 254 patients in five studies in which an internal carotid was therapeutically sacrificed without a test occlusion and found an average stroke rate of 26%, and mortality of 12%. This contrasted with their review of 262 patients in eight studies in which the internal carotid was occluded after performing a test occlusion with an average stroke rate of 13% and mortality of 3%. This reduction in stroke and death rate reached statistical significance. The strokes and death that may occur when the carotid is occluded, based on the results of a test occlusion procedure, indicate that the test occlusion is an imperfect predictor with a significant false negative rate. Adjunctive testing was therefore added to the clinical test, to reduce the chances of a false negative test occlusion. The theory behind these tests is that, occlusion of the carotid or other vessels may produce a drop in blood flow that puts the patient at risk for stroke, yet not enough to result in detectable neurological dysfunction during a trial occlusion for a reasonable period of time. These adjunctive tests look for subtle signs of neurological dysfunction or look for the effects of the vessel occlusion on blood flow to the target territory.

6.2.2. Adjunctive tests of neurological function

- Hypotensive challenge⁶⁻¹⁰ Lowering the blood pressure magnifies the hemodynamic effect of vascular occlusion, making it more likely that a neurological deficit would occur in the case of limited collateral flow. When the carotid is occluded, and no deficit occurs in a normotensive patient, the blood pressure is pharmacologically lowered to a target pressure (e.g. 66% of mean baseline pressure⁹), or until the patient develops a focal neurological deficit or becomes too nauseated and uncomfortable to allow adequate clinical assessment. Agents that can be used for lowering blood pressure should be fast-acting and quickly reversible, such as nitroprusside or esmolol.
Advantages: Cheap and easy to perform. Does not require moving the patient from the angiography suite.
Disadvantages: Patients often get severe headaches and nausea. A small series¹⁰ had 15% false negative rate, which is no better than just a clinical test occlusion.
- Neuropsychological testing^{9, 11, 12} In addition to simple neurological testing during temporary vessel occlusion, a battery of standardized neuropsychological tests are given to test higher cortical functions.
Advantages: Cheap and easy to perform. Can be performed in the angiography suite. Standardized tests of higher cortical function can detect subtle signs of neurological dysfunction, even if the patient does not have an apparent motor or sensory deficit.¹²
Disadvantages: Requires skilled personnel to administer testing in an accurate and consistent manner. Limited experience with this adjunctive test at most centers. Unproven accuracy.
- Electroencephalography (EEG)^{13,14} Continuous EEG monitoring is done throughout the procedure. Slowing or other deviations from baseline conditions can be secondary signs of developing ischemia.
Advantages: Does not require moving patient with the balloon in place. Can still be done with patients under light general anesthesia. Monitored results can be recorded and examined carefully at a later time, to look for changes corresponding to events during the procedure.

Disadvantages: Adds cost and complexity to the procedure. Requires preplacement of EEG leads prior to starting the procedure. Requires skilled personnel to monitor the readings. Careful neurological testing will almost always reveal a deficit when EEG changes are present, making the use of this modality redundant when the patient is awake and can be tested neurologically.

- Somatosensory evoked potentials (SSEP)^{15, 16} EEG electrodes are attached and electrical stimulation of a peripheral nerve (usually the median nerve) contralateral to the hemisphere being tested, is performed. The cortical responses are recorded and the timing and amplitude of the response indicates cortical function. Testing is done prior to and following balloon inflation.
Advantages: Does not require moving the patient with the balloon in place. Can still be done with patients under light general anesthesia. Monitoring results can be recorded and examined carefully at a later time to look for changes corresponding to events during the procedure.
Disadvantages: Adds cost and complexity to the procedure. Requires preplacement of EEG leads and nerve stimulation leads prior to starting the procedure. Stimulation of the nerve can be uncomfortable and distracting to the patient. Results may be difficult to interpret in the setting of underlying spinal or peripheral nerve disease. Requires skilled personnel to monitor the readings. Unproven value compared to standard neurological testing.
- Cerebral Oximetry^{17, 18} Commercially available cerebral oximeter, such as INVOS[®] (Somanetics, Troy, MI) can be applied to the forehead and allows measurement of frontal lobe oxygenation.
Advantages: Does not require movement of the patient with the balloon in place. Seems to correlate with neurological deficits and SPECT imaging.¹⁷
Disadvantages: Gives only a limited evaluation of frontal lobe oxygenation. Results can be affected by underlying brain pathology. Unproven sensitivity and specificity.

6.2.3. Adjunctive tests of blood flow

- Back-pressure (“stump-pressure”).^{19, 20} Blood pressure is measured through the end-hole of the catheter distal to the site of balloon occlusion. The absolute value of the back pressure or better yet, minimum mean back pressure to mean systemic pressure ratio, can be recorded. A ratio of 60% or greater is thought to indicate good collateral flow and predicts tolerance to occlusion.²¹
Advantages: Quick and easy. Does not require moving the patient with the balloon in place.
Disadvantages: Requires the use of a double lumen balloon catheter, with a central lumen for a guidewire or pressure measurements, and another lumen for inflating and deflating the balloon. Stump pressure fluctuates over time as the balloon is inflated and may not absolutely correlate with Xenon-CT data.¹⁹ Back-pressure readings can be affected if the balloon catheter is in a curve and the end-hole of the catheter kinks or presses against the vessel wall.
- Angiographic control^{22, 23} This allows a qualitative or semiquantitative assessment of brain blood flow and potential collateral circulation to the occluded vascular territory. It has been shown that a posterior communicating artery less than 1 mm in diameter is a risk factor for subsequent stroke in the setting of carotid occlusion.²⁴ Similarly, the absence of a functional anterior communicating artery is associated with hemodynamic stroke after carotid occlusion.²⁵ Semiquantitative assessments consist of looking for synchronous filling of cortical veins when performing angiography of the contralateral carotid or vertebral during trial occlusion of a carotid, and measuring the difference between hemispheres in the time it takes to achieve venous filling.^{22, 23} This is a rough approximation of differences in mean transit time between the hemispheres.
Advantages: Easily done. Does not require moving the patient with the balloon in place. Can limit the time the balloon needs to be inflated. Can be done in patients who are under general anesthesia.
Disadvantages: Requires placement of multiple catheters to obtain arteriograms of contralateral carotid and vertebral arteries while the balloon is inflated. This then requires bilateral groin punctures or the use of a GuardWire[®] (Medtronic Vascular, Santa Rosa, CA) balloon wire and diagnostic

catheter placed via the same femoral sheath (as discussed below). Results are somewhat subjective. Insufficient data to determine the accuracy compared to more direct measurements of blood flow.

- Transcranial Doppler (TCD)²⁶⁻²⁸ Sonographic evaluation of the middle cerebral artery is obtained before and after balloon inflation. Mean blood flow velocity and pulsatility index that do not decrease more than 30% are highly predictive of tolerance to carotid occlusion.²⁷
Advantages: Does not require moving patient with the balloon in place. Can be done in patients under general anesthesia.
Disadvantages: Adds cost and complexity to the procedure. Visualization of the intracranial vessels can be time consuming and can distract from examination of the patient. Results may be difficult to interpret in the setting of underlying vascular disease. Requires skilled personnel to perform the study, and results can be operator-dependant. Unproven value compared to standard neurological testing.
- Xenon 133 imaging²⁹ Radioactive Xenon is administered while the carotid is occluded and the patient's brain is imaged with a detector, and blood flow data calculated.
Advantages: Can provide quantitative blood flow data.
Disadvantages: Gives only whole-brain images, so only gross side-to-side differences are visible. Use of the radioactive xenon is cumbersome.
- Xenon CT^{5, 30} Dynamic CT imaging is done as the patient inhales Xenon gas. Scans are obtained without balloon inflation to determine base-line flow, and the study is repeated with balloon inflation to determine the effect of occlusion on blood flow. Can also be done with acetazolamide injection during balloon inflation to evaluate for the presence of vascular reserve.
Advantages: Provides accurate blood flow data reliably. The hardware used for the Xenon delivery is compatible with most commercially available CT scanners. Can do repeated scans to allow scans with and without balloon inflation, and also after acetazolamide.
Disadvantages: May require moving a patient into the CT scanner with the balloon in place. (On the other hand, the scanning may be done without patient transfer if the angiography and balloon placement is done on the CT scanner table using a portable C-arm.³¹) Xenon gas is not FDA approved, and therefore currently requires an Investigational Drug Exemption (IDE) and all the associated paperwork. The hardware for delivering the gas and software for the CT computations require experienced personnel to obtain good studies. Xenon gas can produce euphoria, agitation, and/or nausea in patients, making it difficult to avoid patient motion, which greatly affects accuracy. Produces images of only a limited area of the brain.
- CT perfusion³² Dynamic CT imaging with a bolus of intravenous contrast, and postprocessing can provide blood flow, blood volume and mean-transit time. Scans are obtained without balloon inflation to determine base-line flow, and the study is repeated with balloon inflation to determine the effect of occlusion on blood flow. Can also be done with acetazolamide injection during balloon inflation, to evaluate the presence of vascular reserve.
Advantages: Readily available on most CT scanners. Quick, easy. Uses standard iodinated contrast used for any intravenous contrast-enhanced scan. Blood flow data has been validated by Xenon-CT.³³ Can do repeated scans to allow scans with and without balloon inflation and also after acetazolamide.
Disadvantages: May require moving a patient into the CT scanner with the balloon in place. Requires large-bore intravenous access. Multiple perfusion studies can add to the amount of iodinated contrast given. Produces images of only a limited section of the brain.
- PET³⁴ Short acting, radioactive tracers such as [¹⁵O] H₂O are administered and PET scanning done. Postprocessing allows blood flow calculation. Scans are obtained without balloon inflation to determine base-line flow, and the study is repeated with balloon inflation to determine the effect of occlusion on blood flow. Can also be done with acetazolamide injection during balloon inflation, to evaluate for the presence of vascular reserve.
Advantages: Can give accurate quantitative blood flow data. Can image the entire brain, allowing for visualization of secondary signs of impaired cerebral blood flow, such as crossed cerebellar diaschisis.³⁵ Crossed cerebellar diaschisis is a reflexive drop in blood flow to the contralateral cerebellar hemisphere,

when a substantial drop in blood flow to a cerebral hemisphere occurs. Can do repeated scans to allow scans with and without balloon inflation and also after acetazolamide.

Disadvantages: Requires moving the patient to the PET scanner with the balloon in place. PET scanners are not universally available. Requires immediate access to a cyclotron for making the radiotracer, such as [¹⁵O] H₂O, which has a very, very short half-life. Cyclotrons are even more scarce than PET scanners. To allow for quantitative blood flow measurements, requires an arterial access such as a larger diameter femoral sheath or a separate radial arterial line.

- Single-photon emission computed tomography (SPECT)³⁶⁻³⁹ 99mTechnetium-HMPAO is injected intravenously approximately 5 min after the balloon is inflated, and the radioactive tracer deposits in the brain in quantities proportional to the regional blood flow. After the test occlusion is completed, SPECT scanning shows activity from the tracer, and asymmetry is detected qualitatively by visual inspection of the scan and by measuring the number of radioactive counts in each region of interest.

Advantages: Quick and easy. The imaging can be done after the procedure is completed, so there is no need to transport the patient with a balloon in the vessel. Can image the entire brain, allowing for visualization of secondary signs of impaired cerebral blood flow, such as crossed cerebellar diaschisis.^{40, 41}

Disadvantages: Does not allow for accurate quantitative measurement of cerebral blood flow. Reliance on asymmetry without absolute values of cerebral blood flow can result in significant false positive and false negative results.⁴² Scans obtained with the balloon inflated and deflated cannot be obtained immediately one after the other.

- Magnetic resonance (MR) perfusion^{43, 44} Diffusion-weighted scans, perfusion imaging with a bolus of intravenous gadolinium contrast, and postcontrast T1 weighted and FLAIR imaging are performed prior to and following the balloon inflation. The diffusion and postcontrast scans are observed for signs of ischemia with the balloon inflated. Calculation of cerebral blood volume, mean transit time and blood flow can be done on a computer workstation using the MR perfusion data.

Advantages: Does not add to the iodinated contrast given to the patient. Can image the entire brain.

Disadvantages: Requires MR compatible balloon catheters and patient monitoring leads. Unless one has a combined MR and angiographic interventional suite, requires transfer of patient while the balloon is in place. Quantitative blood flow data is of uncertain validity. Significance of any changes on diffusion imaging or postcontrast scans is uncertain.

- Computer simulation^{45, 46} Proprietary software allows computer modeling of blood flow in the intracranial circulation using data from MR and digital subtraction angiography imaging.

Advantages: A small series showed computer flow modeling showing greater than 20% drop in flow in the M1 segment and A3 segment during carotid occlusion, accurately predicted the patients who developed clinical symptoms during test occlusion.⁴⁶ May theoretically replace the invasive test occlusion procedure.

Disadvantages: Unproven efficacy.

The bottom line on adjunctive tests: Nothing is perfect. The authors recommend at least one, and preferably two adjunctive tests added to the clinical test, usually angiographic analysis plus a blood flow imaging test.

6.2.4. Indications for test occlusion

To determine the potential safety of occluding a vascular structure, prior to an anticipated temporary, or permanent occlusion as treatment for:

1. Frank hemorrhage
2. Aneurysm
3. Arteriovenous malformation
4. Arteriovenous fistula
5. Tumors involving a vascular structure

6.2.5. Complications of balloon test occlusion

Informed consent prior to the procedure should include an estimate of the risk of complications.

6.2.5.1. Neurological complications

1. There is a risk of thrombosis of the structures catheterized, with resultant stroke. A Pittsburg series of 500 carotid test occlusions had 1.6% symptomatic neurological complications, of which two (0.4%) were permanent.³⁰
2. Dissection of the target vessel may occur,⁶ possibly with resultant pseudoaneurysm. Dissection was found in 1.2% and pseudoaneurysm in 0.2% in the Pittsburg series.³⁰
3. Overly aggressive balloon inflation in intracranial vessels can rupture vessels, potentially producing epidural, subdural, subarachnoid or intracerebral bleeding.
4. In the cavernous carotid, carotid cavernous fistula can occur from overinflation of the balloon.

6.2.5.2. Nonneurological complications

1. There is a risk of a profound vagal response to balloon inflation in the carotid bulb or basilar artery, potentially producing bradycardia, hypotension, and rarely cardiac arrest.
2. Balloon inflation in the basilar artery can produce unconsciousness and apnea.
3. Anaphylactoid reactions to iodinated contrast or any of the medications used can occur as with any endovascular procedure.
4. Similarly, groin hematomas, femoral or iliac dissections,⁶ puncture site infections or other access complications can occur.
5. Use of hypotensive challenges may theoretically provoke cardiac ischemia.

6.2.6. Balloon test occlusion: Procedural aspects

6.2.6.1. Preprocedure evaluation

1. Brief neurological exam should be done to establish a baseline, should a neurologic change occur during or after the procedure.
2. The patient should be asked if he or she has had a history of iodinated contrast reactions.
3. The groins should be examined. Feel for the femoral arterial pulse.
4. Bloodtest, including a serum creatinine level, serum glucose if diabetic and coagulation parameters, should be reviewed.
5. Ensure that the correct side and vascular distribution is being tested. Mistakes have been known to occur.

6.2.6.2. Preprocedure orders

1. NPO for 6 h, except for medications.
2. Patients on insulin for hyperglycemia, should get half their normal dose prior to the procedure.
3. Place a peripheral IV.
4. Place Foley catheter.
5. Consider pretreatment with 0.3–0.5 mg Atropine if planning on inflating a balloon in the carotid bulb or basilar artery.
6. Place thigh-high sequential compression device (SCD) sleeves for deep vein thrombosis prophylaxis.

6.2.6.3. Contrast agents

Standard nonionic contrast agents like Iohexol (Omnipaque[®], GE Healthcare, Princeton, NJ), are usually used for these procedures.

6.2.6.4. Femoral artery sheath

These procedures are virtually always done using a femoral sheath, most commonly a 6-French sheath. Ensure it is big enough to accommodate the balloon catheter being used. One may consider using 90-cm sheaths such as the 6-French Shuttle[®] sheath (Cook Inc., Bloomington, IN) which also acts as a guiding catheter.

6.2.6.5. Saline infusion

To reduce the risk of thrombus or air embolism, continuous drips of heparinized saline are attached to stopcocks on the sheath, guiding catheter, and possibly balloon catheter lumen (only if using a double lumen balloon).

6.2.6.6. Anticoagulation

Administer 70–100 units per kilogram intravenous heparin bolus and hourly boluses as needed to keep the activated clotting times (ACT) at least double the baseline value. One could also consider pretreating any patients that undergo test occlusion, with a dose of aspirin to limit any cascade of platelet aggregation instigated by intimal injury produced by the balloon, although most practitioners don't bother with antiplatelet treatment.

6.2.6.7. Sedation/Anesthesia

Most commonly, balloon test occlusion is performed with the patient awake, with minimal sedation in order to detect neurological changes produced by the temporary vascular occlusion. However, catheterization much above the skull base, can sometimes produce discomfort so one could make an argument to do the procedure under general anesthesia, or at least heavy sedation. That would require heavy reliance on blood flow imaging or neurophysiological monitoring rather than clinical findings to detect potential adverse effects of occluding the target vessel. A compromise would be to use heavy sedation/analgesia during the catheterization phase of the procedure and let it wear off when the actual balloon inflation is taking place.

6.2.7. Suggested catheters, balloons, and guidewires for test occlusion

6.2.7.1. Diagnostic and guiding catheters for balloon test occlusion

- Angiographic catheters (4- or 5-French size) are useful for preocclusion and postocclusion angiographic studies. The authors frequently use 4-French Angle Glidecath[®] catheters (Terumo Medical, Somerset, NJ), although other catheter curves may be required depending on the arch anatomy.
- Guiding catheters used for a coaxial approach include standard 5, 6, or 7-French large-lumen gauge guide catheters, most often 6-French angle-tip Envoy[®] (Cordis Neurovascular, Miami Lakes, FL) or 6-French Northstar[®] Lumax[®] (Cook Medical, Inc., Bloomington, IN). Make sure the internal lumen will accept the outer diameter of the balloon catheter. The package of the balloon will usually indicate the recommended guide catheter size.
- Sheaths (90 cm) (e.g. Shuttle[®] sheath, Cook Inc., Bloomington, IN) also work very well as alternative guiding catheters for test occlusions. This allows for extra stability if needed.

6.2.7.2. Balloons for balloon test occlusion

Three main categories of balloons are used today for test occlusions. Each type has advantages and disadvantages.

The first category is the double lumen balloon catheter, with a central lumen for a guidewire or pressure measurements, and another lumen for inflating and deflating the balloon. This is similar to many angioplasty balloons, but high-pressure, low-compliance angioplasty balloons are not recommended for test occlusions, as they can traumatize the vessel. Relatively softer balloons such as those on standard occlusion balloons or even Swan-Ganz balloon catheters can be used. The advantage of these balloons is that one can perfuse heparinized saline and also measure pressures through the distal lumen, and also these balloons are relatively inexpensive. The disadvantage of these balloons is that they do not maneuver well, are somewhat traumatic to vessels and consequently should not be used in very small vessels or intracranial vessels. These are not the optimal balloons for most of these procedures.

The second balloon category is the over-the-wire microballoon. The typical balloon of this type is the Hyperform™ (ev3, Irvine, CA). The balloon catheter has single lumen and when the appropriately sized wire is advanced beyond the catheter tip, an O-ring type valve in the balloon catheter seals the tip of the catheter around the wire and allows inflation and deflation of the balloon. These balloons have the advantage that they are soft, atraumatic, and very maneuverable to almost any destination. The down-side is that they have single lumen to inflate the balloon, but no way to measure backpressure when the vessel is occluded. These small balloons are advanced through a guidecatheter placed in the proximal carotid or vertebral artery, depending on the vessel being tested. Measurement of pressure through the guide-catheter will show dampening of the pressure waveform, if the balloon is inflated in the vessel a short distance beyond the guide-catheter tip. The guidewire must be advanced through the balloon catheter for at least a short segment distal to the balloon. Thus, it requires a straight segment to place the distal wire and care should be taken to keep the wire tip out of small side-branches or acute bifurcations, to prevent perforations or dissections. The risk of misadventures with the wire can be minimized by creating a tight J-shaped curve on the guidewire tip. One advantage of the use of a wire in these single lumen balloons is that, if necessary, the balloon can be rapidly deflated by withdrawing the wire. Other balloon types do not have this option for rapid deflation. These microballoons are the most common balloons currently used for cerebrovascular test occlusions.

The third balloon type is the inflatable balloon wire, typified by the GuardWire® (Medtronic Vascular, Santa Rosa, CA). This system works well especially for carotid test occlusions. This occlusion balloon is mounted on a 0.014-in wire and has a 0.028-in profile for the 2.5–5-cm balloon, or 0.036 in for the 3–6-mm balloon. The larger balloon can easily be advanced through 6-French guiding catheter. It is inflated with an inflation device, which can be removed from the wire, leaving the balloon inflated. This allows removal of the guidecatheter, which allows for placement of a diagnostic catheter via the same femoral arterial sheath for performance of control angiography of potential collateral vessels, while the balloon occludes the target vessel. Another advantage of this balloon wire is that, it has such a low profile that it allows safe moving of the patient with the balloon in place, for cerebral blood flow imaging with CT perfusion. The disadvantages of this balloon wire is that, it has the same issue as the over-the-wire microballoon, in that the distal stump pressure cannot be measured and the wire tip extends for several centimeters distal to the balloon. The GuardWire® has other disadvantages, including the fact that it is stiffer than the microballoons, so, as a general rule, should not be used in intracranial vessels or other small vessels. The need for the inflation device also means that there is a bit of a learning curve to be able to use this device efficiently. The most annoying problem associated with this device is the length of time sometimes required to deflate the balloon. The balloon should be inflated with a dilute contrast solution (e.g. 30% contrast in saline) to minimize viscosity and decrease the problems associated with inflating and deflating the balloon.

In extremely small, tortuous distal vessels, it may sometimes not be possible or safe to advance even the smallest microballoons. However, these vessels may still be accessible using low-profile, ten-system microcatheters. With the microcatheter in the vessel to be tested, a detachable coil can be advanced into the vessel to temporarily occlude it. This method will only work in vessels less than 3mm in diameter. One should use a 2–3-mm diameter coil that is stretch resistant so that, it can be easily and surely removed, and should also be ultra-soft, to fill the lumen of the vessel without traumatizing the intima. Advance as few loops of coil as necessary to occlude flow, to shorten the length of vessel occluded. Obviously, the patient must be fully heparized, so that the thrombus does not form in the vessel, and occlusion times must

be kept to a minimum. *Given the possibilities of thrombus formation and the remote possibility of coil stretching or inadvertent detachment, this method should not be routinely used for test occlusion unless everything else fails.*

Balloons must be sized to match the vessel being occluded. Measure the target vessel using a previous angiographic study, or obtain an angiogram as part of the procedure to get a measurement of the vessel.

1. Internal carotid arteries require balloons at least 5 mm in diameter in most cases.
2. Extracranial internal carotid can be occluded with Swan-Ganz double-lumen balloon (Edwards Lifesciences, Irvine, CA), 10-mm occlusion balloon catheter (Cook Medical, Bloomington, IN), 7 × 7-mm Hyperform™ microballoon (ev3, Irvine, CA), or 6-mm GuardWire® (Medtronic Vascular, Santa Rosa, CA)
3. Intracranial internal carotid is best occluded with a Hyperform™ microballoon (ev3, Irvine, CA).
4. Vertebral arteries can usually be occluded with 5-mm diameter or larger balloons.
5. The straight segment of the cervical vertebral can be occluded with a 10-mm occlusion balloon or 7 × 7-mm microballoon listed above.
6. Above C2, where the vertebral curves laterally, only flexible microballoons such as the Hyperform™ should be used.
7. Intracranial vessels such as proximal intracranial internal carotid and vertebral arteries may still be 4–5-mm in diameter. Supraclinoid carotid is usually 3.5 mm and basilar 3.2 mm. More distal branches are generally less than 3 mm in diameter.
8. Vessels greater than 4 mm can be occluded with the 7 × 7-mm Hyperform™ microballoon.
9. Vessels less than or equal to 4 mm may be occluded with the 4 × 7-mm Hyperform™ (ev3, Irvine, CA), a 4 × 10-mm Hyperglide™ microballoon (ev3, Irvine, CA)

6.2.7.3. Guidewires

- Steerable hydrophilic wires such as 0.035 or 0.038-in. angled Glidewire® (Terumo Medical, Somerset, NJ) can be used to advance a diagnostic catheter or guiding catheter into the carotid or vertebral artery.
- 0.025 or 0.035-in. Glidewire® (Terumo Medical, Somerset, NJ) are used for standard occlusion balloons.
- Transend™ 10 (Boston Scientific, Natick, MA), X-pedion™ 10 (ev3, Irvine, CA), or other 0.010-in. wire is used to advance an over-the-wire microballoon catheter to the target vessel.
- The GuardWire® (Medtronic Vascular, Santa Rosa, CA) balloon is integrated as part of a 0.014-in. wire, and can be used as a wire for relatively soft catheters.

6.2.8. Procedures

6.2.8.1. Femoral access

1. The groin area is prepped bilaterally and draped.
2. Depending on the size of the catheter being used, a sheath is placed in the right (or left) femoral artery. A 6-French works for most scenarios.
3. If a second catheter is needed for angiography of collateral vessels during the test occlusion, perform the same process, except aim for the contralateral femoral artery, and insert a diagnostic 4- or 5-French catheter and position it with its tip in the descending aorta, until it is needed for angiographic studies.
4. Once arterial access is obtained, obtain a baseline ACT and fully heparinize the patient to at least double the baseline ACT (normally 80–150 s). Bolus (50–100 unit heparin per kilogram) will usually get the ACT around 250–300.

6.2.8.2. Alternative access

1. If femoral access is limited due to severe occlusive atherosclerotic disease, brachial arterial access can be used.

2. Test occlusions can be performed using a 4-French sheath for access, although a 5-French sheath opens up a wider range of possibilities for guiding catheters.
3. Obtain an ACT and administer intravenous heparin 50–100 units kg⁻¹.

6.2.8.3. Catheter and balloon manipulation

1. Attach all the catheters to rotating hemostatic valves and attach a three-way stopcock and continuous infusion of saline containing 10,000 units heparin per liter.
2. Through the femoral (or brachial) sheath, advance the desired guiding catheter into the desired internal carotid, vertebral, or other vessel depending on the vessel being occluded.
3. Perform arteriography first to determine the best position for the balloon, and to size the vessel in order to choose the proper balloon.
4. Avoid positioning the balloon in any area containing apparent atherosclerotic plaque.
5. Obtain a roadmap mask to allow balloon positioning and inflation under roadmap guidance.
6. Warn patients that the catheter manipulation and balloon inflation may cause a feeling of pressure.
7. Use *extreme* caution when advancing or inflating a balloon in intracranial vessels.
8. Always keep track of where the tip of the guidewire is to avoid vascular perforation or dissection.
9. When the balloon reaches the desired location, pull back to remove any slack in the catheter. This will prevent the balloon from advancing forward under flow direction, as it is inflated.
10. Inflate the balloon only just enough to stop the flow. *Do not over-inflate.*
11. Measure the volume required to inflate the balloon and occlude the vessel. When performing adjunctive blood flow imaging requiring patient transfer with the balloon in place, this allows deflation and inflation of the balloon without fluoroscopic control.

6.2.8.4. Technique: double-lumen balloon catheter

1. Prepare the balloon by attaching a 10-mL syringe partially filled with contrast to the inflation port of the balloon, aspirate any air, release suction, allowing contrast to enter the inflation port.
2. Attach a one-way stopcock to the inflation port, and inflate the balloon with 50:50 contrast:saline mixture, then deflate. Angle the balloon to allow aspiration of any residual air as the balloon is deflated.
3. For those ambitious (or foolish) enough to use a Swan–Ganz (Edwards Lifesciences, Irvine, CA) for test occlusion, expect to struggle getting into the vessel of interest, as these balloons are not designed for arterial catheterization. One can use a 0.010-in. wire to help direct the catheter and partial inflation for flow direction, to help get into the vessel of interest, but it is not a pleasant experience in tortuous vessels.
4. For all other balloons, such as the 10-mm occlusion balloon catheter (Cook Medical, Bloomington, IN), it is also not easily placed and it is usually necessary to use an exchange wire, unless the patient is young, with straight vessels easily accessible with a straight catheter.
5. Using a diagnostic angiographic catheter of desired size and shape, such as a 5-French Angled Glidecath® (Terumo Medical, Somerset, NJ), catheterize the target carotid or vertebral artery that is to be tested.
6. Using a 300-cm, 0.035-in. diameter exchange wire, exchange the diagnostic catheter for the balloon catheter.
7. Advance the balloon catheter just proximal to the site of intended occlusion, and inject the contrast through the central lumen to obtain a road-map of the vessel.
8. Advance the balloon to the target site.
9. Prepare to measure pressures through the end-hole of the balloon catheter, either by attaching a pressure line to the stopcock (or manifold) attached to the central lumen of the balloon catheter, or by using a pressure-sensing guidewire.
10. Measure a baseline pressure through the central lumen of the balloon catheter.
11. Gently inflate the balloon just enough to occlude the vessel.

12. Contrast injected through the end-hole of the balloon catheter will remain in the vessel, confirming complete occlusion.
13. Measure the pressures through the central lumen of the balloon catheter again. When the vessel is occluded, there will be dampening of the pressure waveform. A drop in mean pressure by 50% after balloon inflation, is suggestive of insufficient collateral flow to the distal territory.
14. Clinically test the patient for any neurological deficits and pay particular attention to functions performed by areas supplied by the vessel being occluded.
15. At some point during the test occlusion, perform cerebral arteriography using an arterial catheter in a contralateral sheath, and check for collateral flow from other arterial pathways.
16. If the patient tolerates the balloon inflation clinically and the back pressure in the balloon catheter does not drop less than 50% post-inflation, keep the vessel occluded for an extended period of about 30 min to confirm tolerance to occlusion.
17. Consider using a supplementary test to look for other signs of hemodynamic insufficiency, when the balloon is inflated (see below).
18. If the patient develops symptoms, if the back-pressure drops, if angiography suggests poor collateral flow, or if another supplementary test shows impaired vascular reserve, the patient has "failed" the test occlusion.
19. When the patient fails the test occlusion, or if they pass for at least 30 min, the procedure is complete. One should then deflate the balloon.
20. Prior to removing the balloon, ensure that the patient's symptoms have resolved and that venous pressure has returned to baseline. If not, it may have caused some dissection or thrombosis, and leaving the balloon catheter in place provides access for diagnostic angiography and any corrective intervention.
21. The balloon catheter can be removed when all testing is completed.

6.2.8.5. Technique: microballoon catheter

1. Prepare the Hyperform™ or Hyperglide™ (ev3, Irvine, CA) by thoroughly flushing the sterile holder housing the balloon, in order to activate the hydrophilic coating.
2. Attach a one-way stopcock, or Flo-switch (BD Medical, Franklin Lakes, NJ) to a rotating hemostatic valve, and attach this to the balloon catheter.
3. Fill the balloon catheter with 50% contrast diluted with saline.
4. Insert the X-pedion™ (ev3, Irvine, CA) or other 0.010-in. wire through the rotating hemostatic valve and into the balloon catheter.
5. Make a j-tip curve on the shapeable platinum tip of the wire, to limit the risk of the wire traumatizing or perforating a vessel.
6. Using a guiding catheter of desired size and shape, usually 5-French or larger, catheterize the target carotid or vertebral artery that is to be tested.
7. Inject the contrast through the guide catheter to obtain a road-map of the vessel.
8. Advance the balloon to the target site.
9. Gently inflate the balloon just enough to occlude the vessel.
10. Confirm occlusion of the vessel by injecting the contrast through the lumen of the guide catheter. There will be stasis of the contrast in the vessel proximal to the balloon.
11. Clinically test the patient for any neurological deficits and pay particular attention to functions performed by areas supplied by the vessel being occluded.
12. At some point during the test occlusion, perform cerebral arteriography using an arterial catheter in a contralateral sheath, and check for collateral flow from other arterial pathways.
13. If the patient tolerates the balloon inflation clinically, keep the vessel occluded for an extended period of about 30 min to confirm tolerance to occlusion.
14. Consider using a supplementary test to look for other signs of hemodynamic insufficiency when the balloon is inflated (see below).
15. If the patient develops symptoms, if angiography suggests poor collateral flow, or if a supplementary test shows limited vascular reserve, the patient has "failed" the test occlusion.
16. When the patient fails the test occlusion, or if they pass for at least 30 min, the procedure is complete. Then deflate the balloon.
17. Prior to removing the balloon, ensure that the patient's symptoms have resolved and that venous pressure has returned to baseline. If not, there may be a dissection or thrombosis, and diagnostic angiography via the guide catheter can determine if any corrective intervention is needed.

18. The balloon catheter and guide catheter can be removed after testing is completed.

6.2.8.6. Technique: balloon wire

1. Prepare the balloon on the GuardWire® (Medtronic Vascular, Santa Rosa, CA) by following the manufacturer's directions.
2. Thoroughly flush the sterile holder housing the wire.
3. Fill the inflator syringe that comes in the package with 30–50% contrast.
4. Attach the tubing from the syringe to the clam-shell shaped inflation device that also comes in the package.
5. Examine the wire and find the gold marker that indicates where to insert the wire in the inflation device, and carefully place it in the inflation device.
6. Close the clam-shell and lock it.
7. Turn the dial on the device to the open position.
8. Aspirate back on the syringe and lock it in the position of maximal suction, in order to purge the balloon of air.
9. After a few minutes of maximum suction, turn and release the plunger on the syringe to release the suction and allow contrast to enter the balloon.
10. Repeat steps 7 and 8 until it looks like no more air can be aspirated from the system.
11. Turn the dial to inflate the balloon and check that it inflates and deflates properly.
12. Once the balloon is prepared, turn the dial to deflate it, and pull the plunger back on the syringe until the balloon is completely deflated.
13. Make a j-tip curve on the shapeable platinum tip of the wire, to limit the risk of the wire traumatizing or perforating a vessel.
14. Using a guiding catheter of desired size and shape, usually 5 French or larger, catheterize the target carotid or vertebral artery that is to be tested.
15. Inject contrast through the guide catheter to obtain a road-map of the vessel.
16. Advance the balloon to the target site.
17. Gently inflate the balloon by turning the dial on the inflation device just enough to occlude the vessel.
18. Confirm occlusion of the vessel by injecting contrast through the lumen of the guide catheter. There will be stasis of contrast in the vessel proximal to the balloon.
19. Clinically test the patient for any neurological deficits and pay particular attention to functions performed by areas supplied by the vessel being occluded.
20. At some point during the test occlusion, perform cerebral arteriography to check for collateral flow from other arterial pathways.
21. This is done by opening and removing the clamshell of the inflation device, leaving the Guardwire® balloon inflated, and carefully backing out the guide catheter while gently feeding in the 0.014-in. wire, making sure to not pull back on the Guardwire® or displace it.
22. When the guide catheter is completely removed from the sheath, a 4-French Glidecath® (Terumo Medical, Somerset, NJ) can be carefully advanced through the sheath alongside the 0.014-in. Guardwire® as long as the sheath is at least 5 French, and preferably 6-French size, to avoid disturbing the wire as the 4-French catheter is manipulated.
23. This catheter can then be used to perform selective arteriography of whatever vessels needed to assess collateral flow, while the balloon is still inflated.
24. If the patient tolerates the balloon inflation clinically, keep the vessel occluded for an extended period of about 30 min to confirm tolerance to occlusion.
25. Consider using a supplementary test to look for other signs of hemodynamic insufficiency when the balloon is inflated.
26. If the patient develops symptoms, or if angiography suggests poor collateral flow, the patient has "failed" the test occlusion.
27. When the patient fails the test occlusion, or if they pass for at least 30 min, the procedure is complete. Insert the gold marker on the Guardwire® into the proper position in the clamshell of the inflation device, then turn the dial to zero, and aspirate on the syringe to deflate the balloon.
28. Prior to removing the balloon, ensure that the patient's examination has returned to or remains at their baseline. If not, some dissection or thrombosis

may have taken place, and diagnostic angiography via the 4-French diagnostic catheter can determine if any corrective intervention is needed.

29. The balloon catheter and guide catheter can be removed after testing is completed.

6.2.8.7. Tips for using the Guardwire®

The authors use this balloon frequently for cervical carotid or vertebral test occlusions, and, out of approximately 25 cases, have had only one case in which balloon deflation was a problem, even though dilute contrast was used for inflation. This case involved a somewhat tortuous carotid and possibly the angulation caused the inflation/deflation port in the balloon to be pressed against the balloon material by the vessel wall. This required gently pulling back on the inflated balloon, to straighten the vessel and allow the inflation/deflation port to allow for unimpeded deflation of the balloon.

6.2.9. Postprocedure care

Once the procedure is completed, the catheters are removed and hemostasis is obtained.

The patient is kept at bed rest with the leg extended for 2 h if a hemostatic patch is used.

6.2.10. Venous test occlusion

See Chap. 12, Venous Procedures

6.3. Pharmacologic provocative testing

6.3.1. Wada test: intracarotid amobarbital procedure

6.3.1.1. A brief history of the Wada test

The procedure of pharmacologically anesthetizing certain parts of the brain began to be reported in the 1940s. W. James Gardner reported injecting procaine through burr-holes in the head, to localize speech centers.⁴⁷ Juhn Wada began using intra-carotid injections of amobarbital initially for treating patients with status epilepticus and also those with schizophrenia undergoing electroconvulsive therapy, and later used it for localizing speech and memory, particularly in patients who were candidates for epilepsy surgery.^{48, 49} The procedure was refined at the Montreal Neurological Institute and by the early 1960s, became an important part of the preoperative work-up for epilepsy surgery.⁵⁰⁻⁵² Patients undergoing temporal lobe resection to control epilepsy are at risk for developing devastating neurological and neuropsychological impairment as a complication from surgery. The carotid amobarbital injections can be used to predict which patients are at risk for developing language deficits,⁵² and also which patients are at risk for developing memory loss.⁵³ Although, initially, the amobarbital was injected in the carotid using direct needle puncture, the adoption of transfemoral catheterization for angiography in the 1960s and 1970s resulted in the adoption of transfemoral catheter technique for Wada tests as well. The availability of microcatheter technique in the 1980s and 1990s resulted in small series of superselective Wada tests.⁵⁴⁻⁵⁶ The supply of amobarbital was interrupted in the early part of the new millennium, when the Food and Drug Administration required recertification of the manufacturing facilities after a different corporation acquired the rights to make the drug.⁵⁷ This led to the use of anesthetic agents such as methohexital,⁵⁸ etomidate,⁵⁹ and propofol.^{60, 61} However, amobarbital is now readily available and the intracarotid injection procedure

remains a key component in the pre-operative workup before epilepsy surgery, and the technique remains little changed from the procedure developed by Dr. Wada in the middle of the twentieth century.

6.3.1.2. Strange, but true

The very same Dr. Wada that invented the Wada test, also published on the behavioral and EEG changes produced by intracisternal and intraventricular injection of *extracts from the urine of schizophrenic patients*.⁶² The authors of this handbook do not recommend the routine use of this particular technique.

6.3.1.3. Memory testing in the Wada test

Neuropsychological testing during the Wada test is primarily designed to predict (and hopefully prevent) disabling memory loss after epilepsy surgery. Verbal and visual/spatial memory is tested during temporary anesthesia of a hemisphere with amobarbital. Items are presented to the patient during the period of anesthetization. The number and types of stimuli that can later be recalled, indicate how robust the memory functions are in the contralateral hemisphere. Functions lost during injection of the side of the seizure focus are at the risk of injury during surgery, and, conversely, functions remaining intact during injection of the contralateral side are at risk. Verbal memory is frequently on the left and visual/spatial on the right, but the existence of lesions in the epileptogenic side may displace function, and bilateral lesions can make for unpredictable localization.

The protocol of memory testing done during Wada tests should be rigorously standardized, since the items presented and the manner in which they are presented can affect the results of the testing, and can allow for comparison of results done at different times or at different centers.⁶³ There are two fairly standardized protocols for memory testing during the Wada test, the Montreal and the Seattle tests.⁶⁴ In the Montreal test, a series of word cards and objects are presented to the patient, while the hemisphere is under the effects of the amobarbital. The patient is then tested for recall when the effect of the drug has worn off. Items spontaneously recalled are scored higher than those picked in a multiple choice test. The number and type of stimulus (verbal or spatial) recalled indicates the functions localized to the hemisphere contralateral to the injection. The Seattle test involves repeatedly displaying cards showing line drawings and sentences, which the patient is instructed to name and remember. These are interspersed with a card stating "Recall", at which point, the patient names previously shown items. This process begins prior to amobarbital injection and is continued repeatedly during the period of anesthesia, until the effects have dissipated. If, during this testing, the patient fails to recall items just presented, then that memory function is localized to that hemisphere. The Montreal test had a 46% predictive value and the Seattle test a 76% predictive value for memory deficits, after epilepsy surgery.⁶⁴

Temporal lobe resections have been used to treat medically refractory seizures, and this may involve wide resections of the temporal lobe (temporal lobectomy)⁶⁵ or more focal resections of the medial temporal lobe (amygdalohippocampectomy).⁶⁶ The hippocampal regions are usually supplied by the anterior choroidal anteriorly, and posterior cerebral arteries posteriorly. It turns out, at least by studying which areas of the brain are inactivated by the amobarbital with single photon emission computed tomography (SPECT), that the injections during the Wada test inactivate the hippocampus in less than 40% of the time.⁶⁷ This issue of the arterial supply to the hippocampus prompted the development of superselective injections in the anterior choroidal and posterior cerebral arteries.^{54, 56} However, the superselective tests may not localize speech function, require specialized equipment and expertise, and may have a higher risk of complications.⁵⁵ In spite of the lack of direct perfusion of the hippocampus on carotid injections, there still seems to be a functional effect on the hippocampus when amobarbital is injected in the carotid.⁶⁸ The importance of the frontal lobe in forming memories may explain why carotid injections can still localize memory dominance.⁶⁹ Moreover, patients who underwent temporal lobectomy in spite of a Wada test localizing memory to the surgical side, had more postoperative deficits than those whose memory was located contralateral to the surgical side on Wada testing.⁷⁰ Therefore, the standard internal carotid Wada test remains the mainstay for pre-operative evaluation in epilepsy patients.

6.3.1.4. Confounding factors possibly affecting the results of the Wada test

- Time allowed to elapse between amobarbital injections: To prevent lingering effects of an initial amobarbital injection from confounding the results of the contralateral injection, some have advocated performing the right and left injections on separate days.⁷¹ Electroencephalographic studies have shown that less than a 40-min delay between injections, can interfere with the results on the second injection.⁷²
- The order of which side is injected first: Most centers inject the side of the epileptogenic focus first, so that useful data may still be obtained even if the patient decompensates, becomes too sleepy, or the angiographic equipment fails. However, there is evidence that cerebral hemispheres containing an epileptogenic focus may take longer to recover from the effects of amobarbital than a normal hemisphere.⁷³ This is another reason to wait for at least 45 min between amobarbital injections.
- Bizarre behavior: The focal anesthesia produced by selective amobarbital can occasionally result in disinhibited behavior (in the patient, that is) which can be disruptive and prevent successful completion of the procedure.^{74, 75} Unfortunately, disruptive behavioral outbursts are unpredictable, but fortunately, they are rare.⁷⁶
- Epilepsy without a unilateral medial temporal lobe onset: The results of Wada memory testing may not be as accurate in predicting post-operative memory deficits if portions of the hemisphere other than the temporal lobe are resected.⁷⁷
- Multilingual patients: Multi-lingual patients may have variable localization of language centers for the different languages⁷⁸ and Wada testing may not necessarily accurately predict post-operative language deficits.⁷⁹
- Carbonic anhydrase inhibiting drugs: Patients receiving therapeutic agents such as topiramate, zonisamide, hydrochlorothiazide, or furosemide may display very rapid recovery from amobarbital or even no effect at all.^{80, 81} The patient should be off these medications for at least 8 weeks prior to the Wada test.

6.3.1.5. Indications for the Wada test

1. Patients being considered for surgery for medically refractory seizures
2. Arteriovenous malformation
3. Tumors

6.3.1.6. Complications of the Wada test

Informed consent prior to the procedure should include an estimate of the risk of complications.

NEUROLOGICAL COMPLICATIONS

1. There is a risk of thrombosis of the structures catheterized, with resultant stroke.
2. Dissection of the target vessel may occur, possibly with resultant occlusion or pseudoaneurysm formation.
3. Amytal in the basilar artery can produce unconsciousness and apnea.
4. Seizure.
5. Cerebral edema may occur if the drug is mixed incorrectly.

NONNEUROLOGICAL COMPLICATIONS

1. Anaphylactoid reactions to iodinated contrast or any of the medications used can occur as with any endovascular procedure.
2. Similarly, groin hematomas, femoral or iliac dissections, puncture site infections or other access complications can occur.

6.3.1.7. More strange, but true

One reported complication of Wada testing in a patient scheduled for epilepsy surgery is that, the seizures resolved and the surgery was no longer necessary. A patient had an embolic stroke after the procedure that infarcted the epileptic focus and cured his seizures.⁸² The authors of this handbook do not recommend routinely creating embolic strokes in hopes of achieving a similar result.

6.3.1.8. Wada test: Procedural aspects

PREPROCEDURE EVALUATION

1. Brief neurological exam should be done to establish a baseline, should a neurological change occur during or after the procedure.
2. The patient should be asked if he or she has had a history of iodinated contrast reactions.
3. Check if the patient has received medications with a carbonic anhydrase inhibitory effect such as topiramate, zonisamide or various diuretics. If there has been treatment with these agents in the last 8 weeks, it can make the amobarbital ineffective.
4. The groins should be examined. Feel for the femoral arterial pulse.
5. Bloodtest, including a serum creatinine level, serum glucose if diabetic and coagulation parameters, should be reviewed.
6. Determine the patient's recent seizure history. When is the last time he or she had a seizure? This is to make sure that the patient is not in a post-ictal state, which can confuse the results of the Wada testing.
7. Determine the patient's recent sleep history. If they are not well rested, it can make it difficult for the patient to pay attention during the Wada test
8. Evaluate the patient's prior imaging and EEG studies to determine the expected side containing the seizure focus. That side is generally tested first.

PREPROCEDURE ORDERS

1. NPO for 6 h, except for medications.
2. Ensure that the patient has taken his or her anti-epileptic medication.
3. Patients on insulin for hyperglycemia, should get half their normal dose prior to the procedure.
4. EEG leads placed prior to procedure.
5. EEG and video monitoring is set up in the angiography suite to record patient responses during the test.
6. Place a peripheral IV.
7. Consider placing Foley catheter.
8. Approximately 30 min prior to the procedure, the groin area is shaved, EMLA[®] (AstraZeneca Pharmaceuticals, Wilmington, DE) a topical anesthetic cream is applied over the expected puncture site, and an occlusive dressing is placed.

PERSONNEL REQUIREMENTS

- Scrubbed angiographic operator
- Scrubbed assistant(s)
- Circulating nurse(s)
- Radiographic technologist(s)
- EEG technologist
- Neuropsychologist or neurologist to do the neuropsychological testing
- Assistant(s) to record the results of that testing

CONTRAST AGENTS

Standard nonionic contrast agents like Iohexol (Omnipaque[®], GE Healthcare, Princeton, NJ), are usually used for these procedures.

FEMORAL ARTERY SHEATH

These procedures can be done with, or without using a femoral sheath. Usually 4 or 5 French size would be sufficient.

SALINE INFUSION

To reduce the risk of thrombus or air embolism, continuous drips of heparinized saline are attached to stopcocks on any sheath and catheter.

ANTICOAGULATION

Administer 70–100 units per kilogram of intravenous heparin bolus and hourly boluses as needed to keep the ACT at least double the baseline value.

SEDATION/ANESTHESIA

Most commonly, Wada testing is performed with the patient as awake as possible, with minimal sedation in order to test memory function. However, occasionally the procedure needs to be done on children or other uncooperative patients so one could make an argument to do the procedure under general anesthesia, or at least heavy sedation. That would require heavy reliance on neurophysiological monitoring rather than clinical findings to detect physiological effects of injecting the target vessel. A compromise would be to use heavy sedation/analgesia during the catheterization phase of the procedure, and let it wear off when the actual barbiturate infusion is taking place. However, the results of the Wada testing would be less convincing if not done in fully awake and cooperative patients.

SUGGESTED CATHETERS AND GUIDEWIRES FOR THE WADA TEST

- Angiographic catheters (4 or 5 French) are useful for angiographic studies and for injecting the amobarbital. The authors frequently use 4-French Angle Glidecath[®] catheters (Terumo Medical, Somerset, NJ), although other catheter curves may be required depending on the arch anatomy.
- Hydrophobic, steerable wires such as 0.035 or 0.038-in. Glidewire[®] (Terumo Medical, Somerset, NJ) allow for safe, accurate catheter placement. Ensure that the wire size is matched to the recommended wire size of the catheter.

6.3.1.9. Procedures

AMOBARBITAL PREPARATION

1. Obtain 500-mg vial of amobarbital (Amytal[®] (Lilly, Indianapolis, IN)) and sterile water
2. Under sterile conditions, mix 500 mg with 20-mL sterile water
3. Ensure all the powder is dissolved
4. Draw it up in a 20-mL syringe
5. Transfer the solution (25-mg amobarbital per milliliter) to sterile, labeled syringes using a filter needle.

AMOBARBITAL DOSAGE

The vast majority of practitioners inject 125 mg of amobarbital per hemisphere, and this dosage is used in the procedural descriptions below. Some use 2 mg per kg body weight. Still others inject 25 mg s⁻¹, until the patient becomes hemiplegic in the contralateral arm. These variable dosages can make it difficult to compare the results of tests performed at different times or at different institutions.

CATHETER PREPARATION

1. Choose a catheter for the procedure, usually a 4- or 5-French diagnostic cerebral catheter.
2. As soon as it is removed from its sterile package, connect it to the stopcock system to be used during the procedure.
3. Connect a syringe of heparinized saline to the stopcock, and carefully inject saline until a drop is seen from the distal tip of the catheter, measuring the volume of the dead-space of the catheter/stopcock assembly. For a 4-French catheter attached to a three-way stopcock, the dead-space of the catheter is approximately 1.2 mL, and slightly more for a larger catheter system.

4. Record the dead space measured, and then flush the system thoroughly as per usual angiographic technique.

FEMORAL ACCESS

1. When ready to begin, the groin area is cleaned of any topical anesthetic cream, then prepped and draped.
2. Liberal application of local anesthetic, such as 0.25% bupivacaine will now ensure pain free catheter placement and manipulation.
3. The femoral artery is punctured and a 4- or 5-French sheath is placed.
4. Alternatively, the catheter is placed in the femoral artery without a sheath.
5. Once arterial access is obtained, obtain a baseline ACT and fully heparinize the patient to at least double the baseline ACT (normally 80–150 s). Heparin (50–100 unit per kilogram bolus) will usually get the ACT around 250–300.
6. If femoral access is limited due to severe occlusive atherosclerotic disease, brachial arterial access can be used, but this is rarely, if ever necessary in this patient population.

CATHETER MANIPULATION

1. Attach all catheters to rotating hemostatic valves and attach a three-way stopcock and continuous infusion of saline containing 10,000 units heparin per liter.
2. Advance the catheter into the desired internal carotid. First do the side of the seizure focus, then later the side opposite to the seizure focus.
3. Perform arteriography first to estimate the expected distribution of the barbiturate, to ensure that there are no anomalous connections to the basilar, which could constitute a contra-indication for intra-carotid amobarbital infusion, and also to rule out incidental cerebral vascular disease.

TECHNIQUE: AMOBARBITAL TEST

1. Using a wet-to-wet connection, connect the labeled amobarbital syringe to the stopcock attached to the catheter. At least 5 mL plus the dead-space of the catheter system of amobarbital 25 mg mL⁻¹ should be in the syringe, or 6.2 mL for a 4-French system. This allows injection of single bolus of 125 mg into the patient.
2. Hold the syringe vertical, such that any bubbles rise away from the catheter.
3. Place a sterile half-sheet over the sterile field over the patient's thorax, to prevent contamination of the field during testing.
4. The patient raises his or her arms and squeezes the examiner's fingers.
5. The patient begins counting backwards from 20.
6. When the patient counts back to 15, begin to inject the 6.2 mL (or slightly more for larger catheters) over 5 s into the internal carotid via the catheter.
7. Immediately disconnect the labeled amobarbital syringe, attach a 10-mL syringe and aspirate several milliliters of blood to remove any amobarbital left in the catheter.
8. Double flush the catheter with heparinized saline.
9. If the patient shows the expected hemiparesis contralateral to the site of amobarbital injection, the catheter is pulled back into the descending aorta.
10. In the meantime, when the barbiturate is injected, neuropsychological testing is done as the patient is shown objects and cards to test speech and memory.
11. The patient is asked a standard battery of questions to distract from the previously shown objects, and to determine when the effect of amobarbital has worn off. The EEG is checked to ensure that the tracings are returned to baseline.
12. The patient is allowed to rest for 5–10 min, and the patient is then tested to determine if he or she remembers the items shown. Items spontaneously recalled are scored higher than those picked from multiple choice questions.
13. By the time the neuropsychological testing is completed, it is now approximately 20 min after the initial amobarbital injection.
14. Wait an additional time for a total of at least 45 min between amobarbital injections.
15. The process is then repeated for the contralateral internal carotid.

POSTPROCEDURE CARE

Once the procedure is completed, the catheters are removed and hemostasis is obtained.

The patient is kept at bed rest, with the leg extended for 2h, if a hemostatic patch is used.

OTHER PHARMACOLOGICAL AGENTS

FOR WADA TESTING

- Sodium methohexital⁵⁸: This is a very short acting agent with less production of drowsiness even after successive injection. Three milligrams are injected first and the patient is tested for speech function, then, when hemiparesis resolves, a second injection of 2 mg is given and memory testing can be done. If the drug effect wears off before the items are presented for memory testing, another 2-mg injection can be given.
- Etomidate⁵⁹: A bolus of 0.03–0.04 mg kg⁻¹, followed by drip infusion of 0.003–0.004 mg kg⁻¹ min⁻¹, which continues until all items are presented for memory testing. The drug wears off within 4 min of stopping the infusion. In a small series of patients, no apparent complications occurred, but some confusing EEG responses occurred.
- Propofol⁶⁰: Mixed as 10 mg in 10-mL saline, an initial bolus of 10 mg is injected, followed by an additional 3 mg as needed to produce contralateral hemiplegia. In a series of 58 patients, one third experienced some involuntary movements or increased muscle tone that was sometimes disruptive to the neuropsychological testing.⁶¹

6.3.2. Superselective Wada test

6.3.2.1. Indications for superselective Wada testing

Indications for superselective Wada testing are the same as for standard Wada testing, but with these added conditions:

- Standard testing is contra-indicated due to anomalous connections from carotid to basilar (e.g. persistent trigeminal artery).
- Standard testing results confusing or unreliable due to excessive sleepiness or inattention after amobarbital injection.
- Standard Wada testing suspect due to lack of clinical effect of intracarotid amobarbital, in cases of severe hemispheric injury, or arteriovenous malformations.
- For memory testing, superselective posterior cerebral^{54, 55} or (less commonly) anterior choroidal catheterization is done.⁵⁶
- Middle cerebral catheterization is done for language or motor function localization.⁸³

6.3.2.2. Complications of the superselective Wada test

Complications are similar to those of the standard Wada test, but with the added risks of superselective catheterization. There is a higher risk of thromboembolic complications, and local vascular injury in the intracranial circulation. Jack and colleagues reported one complication of hemiplegia out of 45 cases of attempted posterior cerebral superselective Wada.⁵⁴

6.3.2.3. Technique for superselective Wada testing

Similar to standard Wada testing with the following exceptions and caveats:

1. Femoral sheath is almost always used, most often a 5-French sheath.
2. Guiding catheters are used to catheterize the carotid or vertebral artery, most commonly a 5-French Envoy[®] (Cordis Neurovascular, Miami Lakes, FL).

3. A microcatheter is used for catheterization of the intracranial vessel of choice. For patient comfort, the authors prefer a soft, flow-directed catheter such as Magic[®] (Balt/Advanced Interventional Technology, Miami, FL), Spinaker[®] Elite (Boston Scientific, Natick, MA) or Ultraflow[®] (ev3, Irvine, CA).
4. A micro-guidewire suitable for the particular microcatheter is used for its placement. The authors prefer the 0.008-in. Mirage[®] (ev3, Irvine, CA).
5. Systemic heparinization during the procedure is mandatory.
6. Rotating hemostatic valves, three-way stopcocks, and continuous heparinized saline infusions are attached to the all catheter lumens.
7. Microcatheter is carefully advanced using roadmap guidance to the target vessel.
8. For posterior cerebral testing, place the catheter in the P2 segment. In the middle cerebral, position it in the distal M1 or M2 segment.
9. Pull back on the microcatheter to relieve any slack.
10. Perform a gentle contrast injection with a 3-mL syringe for a superselective arteriogram to ensure that the desired brain parenchyma is being perfused.
11. To limit the dead-space of the microcatheter, remove the rotating hemostatic valve and attach a three-way stopcock to the microcatheter.
12. Attach a 3–5-mL syringe of amobarbital to the microcatheter's stopcock.
13. When ready for neuropsychological testing, inject 30–50 mg of amobarbital into the target vessel, at a rate of 10 mg s⁻¹.
14. For posterior cerebral testing, adequate anesthesia is confirmed by development of a contralateral hemianopia. For middle cerebral testing, check for a contralateral hemiplegia.
15. Once it appears that adequate anesthesia for Wada testing is obtained, slowly withdraw the guiding catheter and microcatheter from the patient, leaving the sheath in place.
16. If indicated, perform either a standard Wada test of the contralateral carotid, or a superselective test, as necessary.

6.3.3. Alternatives to Wada testing

6.3.3.1. Language testing

Functional magnetic resonance imaging (fMRI) allows noninvasive localization of brain function by detecting the areas of increased oxygen utilization in the brain, while the patient performs tasks related to that brain function. This technique can be used to localize language dominance, and fMRI gave concordant results compared to Wada testing in 91% of 100 patients who underwent both procedures.⁸⁴ The incidence of false lateralization was highest when there was an epileptogenic focus outside the temporal lobe. Language mapping has also been done with noninvasive stimulation by magnetoencephalography (MEG) which correlated with results of Wada testing in 87% of 100 cases.⁸⁵ Small series using augmentation of middle cerebral blood flow velocity during a language task to locate speech lateralization, showed a high correlation with Wada testing results.^{86–88}

6.3.3.2. Memory testing

Lateralization of memory dominance can be done noninvasively using [¹⁸F] Fluorodeoxyglucose PET imaging, and the medial temporal lobe with hypometabolism tends to be the side that does not support memory function on Wada testing.^{89,90} More recently, fMRI imaging has been used to lateralize verbal memory in small series of epilepsy patients.^{91,92}

6.3.3.3. The bottom line

Wada testing is not yet dead. It remains the gold-standard for pre-operative evaluation of epilepsy surgery candidates. Other testing modalities are less proven

and may require hardware, software, or technical expertise that may not be as widely available in medical centers as the Wada test is. However as fMRI becomes increasingly available as a clinical diagnostic modality, and accuracy improves, it may in many cases supplant the catheter-based Wada test just as MR angiography replaces catheter angiography, for many applications.

6.3.4. Preembolization provocative testing

Provocative testing can be done during embolization procedures, to confirm that it is safe to occlude the intended target of the embolization. Before embolizing a vessel, it is injected with an anesthetic agent, and if no neurological deficit occurs, it is assumed that it is safe to occlude the vessel. Vessels potentially supplying the central nervous system can be tested most commonly with amobarbital,^{93,94} but also methohexital⁹⁵ or thiopental⁹⁶ can be used as a substitute. Vessels that may supply a nerve can be tested with lidocaine injections.⁹⁷ Lidocaine injections into arteries feeding the brain can cause seizures.⁹⁸ Therefore a strategy of first testing with amobarbital, then, if no deficit occurs, testing with lidocaine can greatly reduce the chances for adverse reactions to lidocaine, yet significantly increases the sensitivity of detecting deficits over the use of amobarbital alone.⁹⁹ Patients are tested clinically to determine if new neurological deficits are referable to the vascular territory at risk. Greater sensitivity is claimed (in a small series) by using a battery of cognitive neuropsychological tests during the amobarbital testing.¹⁰⁰ Larger series using EEG as well as clinical testing for superselective amobarbital showed greater sensitivity using the EEG data.^{101,102} Amobarbital testing prior to AVM embolization in 109 tests showed 23 abnormal tests by EEG criteria, but only 12 of them abnormal by clinical testing, yet three false negative tests by EEG compared to clinical testing.¹⁰¹ Amobarbital and lidocaine testing was shown to be helpful in 52 spinal arteriovenous malformations using neurophysiological monitoring with somatosensory and motor evoked potentials, and only one neurological complication that occurred even when the procedure was done under general anesthesia.¹⁰³

The problem with provocative testing in embolization procedures is that there is little evidence concerning the true impact of this testing on patient outcome. That would theoretically require a study testing a vessel, then embolizing regardless whether the testing was normal or abnormal, then determining the true predictive power of the testing. Consequently, provocative testing should probably be done in awake, cooperative patients, in whom the results would be expected to be most reliable. In embolization procedures that require general anesthesia, the provocative testing should be reserved for high-risk cases in eloquent locations and as long as good neurophysiological monitoring is available.

6.3.4.1. Procedures

AMOBARBITAL PREPARATION

1. Obtain 500-mg vial of amobarbital (Amytal® (Lilly, Indianapolis, IN)) and sterile water
2. Under sterile conditions, mix 500 mg with 20-mL sterile water
3. Ensure all the powder is dissolved
4. Draw it up in a 20-mL syringe
5. Transfer the solution (25-mg amobarbital per milliliter) to sterile, labeled syringes using a filter needle.

LIDOCAINE PREPARATION

1. Transfer the contents of a syringe of 2% cardiac lidocaine to a sterile, labeled syringe.
2. Add 1 mL of 4.2% pediatric bicarbonate to the lidocaine to buffer the acidity and reduce the discomfort on injection.

PREPARATION FOR ADJUNCTIVE TESTING

For brain embolization procedures consider using neuropsychological testing, EEG monitoring, or evoked potentials during the provocative testing, and for spinal procedures consider using somatosensory and motor evoked potentials. Any of these

adjunctive tests require that skilled personnel to do the testing. With neuropsychological testing a baseline examination should be performed prior to beginning the procedure. Similarly, when neurophysiological monitoring is done, the leads need to be applied and readings are taken to determine the original status, so that alterations can be more readily detected. These adjunctive tests are generally not required for routine external carotid territory provocative testing.

VASCULAR ACCESS

- 1) The groin area is prepped and draped, and local anesthetic, such as 0.25% bupivacaine is applied.
- 2) The femoral artery is punctured and an appropriately sized sheath is placed.
- 3) In rare cases, when femoral access is not possible, alternative access such as brachial or radial may be used.
- 4) An appropriately sized guide catheter is advanced over a steerable guidewire and placed in the artery supplying the target lesion.
- 5) Rotating hemostatic valves and continuous heparinized saline flushes are attached to all catheter systems.
- 6) The desired microcatheter is coaxially advanced through the guide catheter and positioned in the target vessel using roadmap guidance.
- 7) Perform a superselective arteriogram.
- 8) Study the superselective arteriogram for filling of the brain or spinal cord either directly, or indirectly via dangerous anastomoses.
- 9) If there is visible supply to normal neurological territory, there are three options:
 - a. Do not embolize the vessel, and try a different vessel.
 - b. If possible, reposition the microcatheter beyond any connection to normal territory, then repeat the superselective arteriogram.
 - c. If not possible to achieve catheterization beyond a connection to normal territory, consider blocking the dangerous anastomosis with a microcoil to prevent emboli from reaching the normal territory. This is *only* an option if it is certain that other vessels provide adequate flow to the normal territory.
- 10) Once a safe catheter position is confirmed by superselective arteriography, perform provocative testing.

TECHNIQUE: PROVOCATIVE TEST

1. Remove the rotating hemostatic valve, and connect a three-way stopcock to the microcatheter.
2. Using a wet-to-wet connection, connect the labeled 3–5-mL amobarbital syringe to the stopcock attached to the microcatheter.
3. Hold the syringe vertical, such that any bubbles rise away from the catheter.
4. Place a sterile half-sheet over the sterile field over the patient's thorax, to prevent contamination of the field during testing.
5. Inject the amobarbital (usually 30–50 mg) over approximately 5 s into the vessel via the microcatheter.
6. Immediately disconnect the labeled amobarbital syringe, attach a 3-mL syringe and flush with several milliliters of heparinized saline, to remove any amobarbital left in the catheter.
7. Ask the patient if he or she feels anything abnormal, then do a brief neurological examination, paying particular attention to functions at risk from the vascular territory being tested.
8. If the patient shows a new deficit, the testing is considered abnormal, and the vessel should not be embolized from that catheter position.
9. In the meantime, when the barbiturate is injected, adjunctive testing such as neuropsychological testing or EEG monitoring can be done.
10. If adjunctive testing changes from baseline status, then the testing is also considered abnormal, and the vessel should not be embolized from that catheter position.
11. If there is no change on neurological testing and adjunctive testing, the testing is normal and suggests it may be safe to embolize, or at least it is safe to test with lidocaine.
12. Connect a labeled 3-mL lidocaine syringe to the stopcock on the microcatheter.
13. Inject the lidocaine (usually 20–50 mg) over approximately 5 s into the vessel via the microcatheter.

14. The neurological and adjunctive testing is then repeated.
15. If there is no deficit, the testing is normal and it is safe to embolize.
16. If brain, retina or spinal cord deficit occurs, the testing is abnormal and the vessel should not be embolized from that catheter position.
17. If cranial nerve or peripheral nerve deficit occurs after lidocaine, it may still be possible to embolize using larger polyvinyl alcohol particles (over 350- μ m size) or microcoils.
18. During embolization of a vessel, after negative amobarbital and lidocaine testing, a change in flow pattern or visualization of different vessels may be seen after partial occlusion of the vessel. Consider repeating the provocative testing again before completing embolization of the feeder.¹⁰⁴
19. Repeat provocative testing as necessary whenever a new catheter position for embolization is achieved. However, be aware that the patient can become sleepy after repeated amobarbital injections in a short period of time.

SYRINGE SAFETY

Many of the procedures discussed in this book, require the use of multiple agents in syringes on the procedure table. For example, an embolization procedure that involves provocative testing, requires syringes containing local anesthetic, saline flush, contrast, amobarbital, lidocaine, embolic material, etc. It is imperative that these syringes containing different agents, are clearly differentiated, one from another. Confusing syringes with anesthetic agents or embolic materials for contrast or saline flush can lead to disastrous results. The authors use customized, labeled, colored syringes (Merit Medical, South Jordan, UT) of various sizes and designs for the various materials. Using the same type of syringe for a certain agent at all times and educating new team members to the routine will minimize confusion and avoid mistakes.

6.4. References

1. Matas R. Some of the problems related to the surgery of the vascular system: testing the efficiency of the collateral circulation as a preliminary to the occlusion of the great surgical arteries. Presidential address. *Trans Am Surg Assoc* 1910;28:4-54.
2. Wang H, Lanzino G, Kraus RR, Fraser KW. Provocative test occlusion or the Matas test: who was Rudolph Matas? *J Neurosurg* 2003;98(4):926-8.
3. Allen JW, Alastra AI, Nelson PK. Proximal intracranial internal carotid artery branches: prevalence and importance for balloon occlusion test. *J Neurosurg* 2005;102(1):45-52.
4. Lesley WS, Bieneman BK, Dalsania HJ. Selective use of the paraphthalmic balloon test occlusion (BTO) to identify a false-negative subset of the cervical carotid BTO. *Minim Invasive Neurosurg* 2006;49(1):34-6.
5. Linskey ME, Jungreis CA, Yonas H, et al. Stroke risk after abrupt internal carotid artery sacrifice: accuracy of preoperative assessment with balloon test occlusion and stable xenon-enhanced CT. *AJNR Am J Neuroradiol* 1994;15(5):829-43.
6. Standard SC, Ahuja A, Guterman LR, et al. Balloon test occlusion of the internal carotid artery with hypotensive challenge. *AJNR Am J Neuroradiol* 1995;16(7):1453-8.
7. McIvor NP, Willinsky RA, TerBrugge KG, Rutka JA, Freeman JL. Validity of test occlusion studies prior to internal carotid artery sacrifice. *Head Neck* 1994;16(1):11-16.
8. Dare AO, Gibbons KI, Gillihan MD, Guterman LR, Loree TR, Hicks WL, Jr. Hypotensive endovascular test occlusion of the carotid artery in head and neck cancer. *Neurosurg Focus* 2003;14(3):e5.
9. Marshall RS, Lazar RM, Pile-Spellman J, et al. Recovery of brain function during induced cerebral hypoperfusion. *Brain* 2001;124 (Part 6):1208-17.
10. Dare AO, Chaloupka JC, Putman CM, Fayad PB, Awad IA. Failure of the hypotensive provocative test during temporary balloon test occlusion of the internal carotid artery to predict delayed hemodynamic ischemia after therapeutic carotid occlusion. *Surg Neurol* 1998;50(2):147-55; discussion 55-6.
11. Lazar RM, Marshall RS, Pile-Spellman J, et al. Continuous time estimation as a behavioural index of human cerebral ischaemia during temporary occlusion of the internal carotid artery. *J Neurol Neurosurg Psychiatry* 1996;60(5):559-63.
12. Marshall RS, Lazar RM, Mohr JP, et al. Higher cerebral function and hemispheric blood flow during awake carotid artery balloon test occlusions. *J Neurol Neurosurg Psychiatry* 1999;66(6):734-8.
13. Morioka T, Matsushima T, Fujii K, Fukui M, Hasuo K, Hisashi K. Balloon test occlusion of the internal carotid artery with monitoring of compressed spectral arrays (CSAs) of electroencephalogram. *Acta Neurochir* 1989;101(1-2):29-34.
14. Cloughesy TF, Nuwer MR, Hoch D, Vinuela F, Duckwiler G, Martin N. Monitoring carotid test occlusions with continuous EEG and clinical examination. *J Clin Neurophysiol* 1993;10(3):363-9.
15. Schellhammer F, Heindel W, Haupt WF, Landwehr P, Lackner K. Somatosensory evoked potentials: a simple neurophysiological monitoring technique in supra-aortal balloon test occlusions. *Eur Radiol* 1998;8(9):1586-9.
16. Su CC, Watanabe T, Yoshimoto T, Ogawa A, Ichige A. Proximal clipping of dissecting intracranial vertebral aneurysm - effect of balloon Matas test with neurophysiological monitoring. Case report. *Acta Neurochir* 1990;104(1-2):59-63.
17. Kaminogo M, Ochi M, Onizuka M, Takahata H, Shibata S. An additional monitoring of regional cerebral oxygen

- saturation to HMPAO SPECT study during balloon test occlusion. *Stroke* 1999;30(2):407-13.
18. Takeda N, Fujita K, Katayama S, Tamaki N. Cerebral oximetry for the detection of cerebral ischemia during temporary carotid artery occlusion. *Neurol Med Chir* 2000;40(11):557-62; discussion 62-3.
 19. Barker DW, Jungreis CA, Horton JA, Pentheny S, Lemley T. Balloon test occlusion of the internal carotid artery: change in stump pressure over 15 minutes and its correlation with xenon CT cerebral blood flow. *AJNR Am J Neuroradiol* 1993;14(3):587-90.
 20. Kurata A, Miyasaka Y, Tanaka C, Ohmomo T, Yada K, Kan S. Stump pressure as a guide to the safety of permanent occlusion of the internal carotid artery. *Acta Neurochir* 1996;138(5):549-54.
 21. Morishima H, Kurata A, Miyasaka Y, Fujii K, Kan S. Efficacy of the stump pressure ratio as a guide to the safety of permanent occlusion of the internal carotid artery. *Neurol Res* 1998;20(8):732-6.
 22. Abud DG, Spelle L, Pletin M, Mounayer C, Vanzin JR, Most J. Venous phase timing during balloon test occlusion as a criterion for permanent internal carotid artery sacrifice. *AJNR Am J Neuroradiol* 2005;26(10):2602-9.
 23. van Rooij WJ, Sluzewski M, Slob MJ, Rinkel GJ. Predictive value of angiographic testing for tolerance to therapeutic occlusion of the carotid artery. *AJNR Am J Neuroradiol* 2005;26(1):175-8.
 24. Schomer DF, Marks MP, Steinberg GK, et al. The anatomy of the posterior communicating artery as a risk factor for ischemic cerebral infarction. *N Engl J Med* 1994;330(22):1565-70.
 25. Miralles M, Dolz JL, Cotillas J, et al. The role of the circle of Willis in carotid occlusion: assessment with phase contrast MR angiography and transcranial duplex. *Eur J Vasc Endovasc Surg* 1995;10(4):424-30.
 26. Giller CA, Mathews D, Walker B, Purdy P, Roseland AM. Prediction of tolerance to carotid artery occlusion using transcranial Doppler ultrasound. *J Neurosurg* 1994;81(1):15-19.
 27. Eckert B, Thie A, Carvajal M, Groden C, Zeumer H. Predicting hemodynamic ischemia by transcranial Doppler monitoring during therapeutic balloon occlusion of the internal carotid artery. *AJNR Am J Neuroradiol* 1998;19(3):577-82.
 28. Bhattacharjee AK, Tamaki N, Wada T, Hara Y, Ehara K. Transcranial Doppler findings during balloon test occlusion of the internal carotid artery. *J Neuroimaging* 1999;9(3):155-9.
 29. Marshall RS, Lazar RM, Young WL, et al. Clinical utility of quantitative cerebral blood flow measurements during internal carotid artery test occlusions. *Neurosurgery* 2002;50(5):996-1004; discussion 5.
 30. Mathis JM, Barr JD, Jungreis CA, et al. Temporary balloon test occlusion of the internal carotid artery: experience in 500 cases. *AJNR Am J Neuroradiol* 1995;16(4):749-54.
 31. Barr JD, Lemley TI, McCann RM. Carotid artery balloon test occlusion: combined clinical evaluation and xenon-enhanced computed tomographic cerebral blood flow evaluation without patient transfer or balloon reinflation: technical note. *Neurosurgery* 1998;43(3):634-7; discussion 7-8.
 32. Jain R, Hoeffner EG, Deveikis JP, Harrigan MR, Thompson BG, Mukherji SK. Carotid perfusion CT with balloon occlusion and acetazolamide challenge test: feasibility. *Radiology* 2004;231(3):906-13.
 33. Wintermark M, Thiran JP, Maeder P, Schnyder P, Meuli R. Simultaneous measurement of regional cerebral blood flow by perfusion CT and stable xenon CT: a validation study. *AJNR Am J Neuroradiol* 2001;22(5):905-14.
 34. Brunberg JA, Frey KA, Horton JA, Deveikis JP, Ross DA, Koeppel RA. [15O]H₂O positron emission tomography determination of cerebral blood flow during balloon test occlusion of the internal carotid artery. *AJNR Am J Neuroradiol* 1994;15(4):725-32.
 35. Brunberg JA, Frey KA, Horton JA, Kuhl DE. Crossed cerebellar diaschisis: occurrence and resolution demonstrated with PET during carotid temporary balloon occlusion. *AJNR Am J Neuroradiol* 1992;13(1):58-61.
 36. Moody EB, Dawson RC, III, Sandler MP. 99mTc-HMPAO SPECT imaging in interventional neuroradiology: validation of balloon test occlusion. *AJNR Am J Neuroradiol* 1991;12(6):1043-4.
 37. Peterman SB, Taylor A, Jr, Hoffman JC, Jr. Improved detection of cerebral hypoperfusion with internal carotid balloon test occlusion and 99mTc-HMPAO cerebral perfusion SPECT imaging. *AJNR Am J Neuroradiol* 1991;12(6):1035-41.
 38. Monsein LH, Jeffery PJ, van Heerden BB, et al. Assessing adequacy of collateral circulation during balloon test occlusion of the internal carotid artery with 99mTc-HMPAO SPECT. *AJNR Am J Neuroradiol* 1991;12(6):1045-51.
 39. Tomura N, Omachi K, Takahashi S, et al. Comparison of technetium Tc-99m hexamethylpropyleneamine oxime single-photon emission tomograph with stump pressure during the balloon occlusion test of the internal carotid artery. *AJNR Am J Neuroradiol* 2005;26(8):1937-42.
 40. Eckard DA, Purdy PD, Bonte F. Crossed cerebellar diaschisis and loss of consciousness during temporary balloon occlusion of the internal carotid artery. *AJNR Am J Neuroradiol* 1992;13(1):55-7.
 41. Nathan MA, Bushnell DL, Kahn D, Simonson TM, Kirchner PT. Crossed cerebellar diaschisis associated with balloon test occlusion of the carotid artery. *Nucl Med Commun* 1994;15(6):448-54.
 42. Yonas H, Linskey M, Johnson DW, et al. Internal carotid balloon test occlusion does require quantitative CBF. *AJNR Am J Neuroradiol* 1992;13(4):1147-52.
 43. Michel E, Liu H, Remley KB, et al. Perfusion MR neuroimaging in patients undergoing balloon test occlusion of the internal carotid artery. *AJNR Am J Neuroradiol* 2001;22(8):1590-6.
 44. Ma J, Mehrkens JH, Holtmannspoepter M, et al. Perfusion MRI before and after acetazolamide administration for assessment of cerebrovascular reserve capacity in patients with symptomatic internal carotid artery (ICA) occlusion: comparison with (99m)Tc-ECD SPECT. *Neuroradiology* 2007;49(4):317-26.
 45. Kailasnath P, Dickey PS, Gahbauer H, Nunes J, Beckman C, Chaloupka JC. Intracarotid pressure measurements in the evaluation of a computer model of the cerebral circulation. *Surg Neurol* 1998;50(3):257-63.
 46. Charbel FT, Zhao M, Amin-Hanjani S, Hoffman W, Du X, Clark ME. A patient-specific computer model to predict outcomes of the balloon occlusion test. *J Neurosurg* 2004;101(6):977-88.
 47. Gardner W. Injection of procaine into the brain to locate speech area in left-handed persons. *Arch Neurol Psychiatry* 1941;46:1035-8.
 48. Wada J. [Clinical experimental observations of carotid artery injections of sodium amytal]. *Igaku to Seibutsugaku* 1949;14:221-2.
 49. Wada JA. Clinical experimental observations of carotid artery injections of sodium amytal. *Brain Cogn* 1997;33(1):11-13.
 50. Rovit R, Gloor P, Rasmussen T. Effect of intracarotid injection of sodium amytal on epileptiform EEG discharges: a clinical study. *Trans Am Neuro Assoc* 1960;85:161-5.
 51. Rovit RL, Gloor P, Rasmussen T. Intracarotid amobarbital in epileptic patients. A new diagnostic tool in clinical electroencephalography. *Arch Neurol* 1961;5:606-26.
 52. Branch C, Milner B, Rasmussen T. Intracarotid sodium amytal for the lateralization of cerebral speech dominance: observations in 123 patients. *J Neurosurg* 1964;21:399-405.
 53. Milner B, Branch C, Rasmussen T. Study of short-term memory after intracarotid injection of sodium amytal. *Trans Am Neuro Assoc* 1962;87:224-6.
 54. Jack CR, Jr, Nichols DA, Sharbrough FW, Marsh WR, Petersen RC. Selective posterior cerebral artery Amytal test for evaluating memory function before surgery for temporal lobe seizure. *Radiology* 1988;168(3):787-93.
 55. Jack CR, Jr, Nichols DA, Sharbrough FW, et al. Selective posterior cerebral artery injection of amytal: new method of preoperative memory testing. *Mayo Clin Proc* 1989;64(8):965-75.

56. Wieser HG, Muller S, Schiess R, et al. The anterior and posterior selective temporal lobe amobarbital tests: angiographic, clinical, electroencephalographic, PET, SPECT findings, and memory performance. *Brain Cogn* 1997;33(1):71-97.
57. Grote CL, Meador K. Has amobarbital expired? Considering the future of the Wada. *Neurology* 2005;65(11):1692-3.
58. Buchtel HA, Passaro EA, Selwa LM, Deveikis J, Gomez-Hassan D. Sodium methohexital (brevital) as an anesthetic in the Wada test. *Epilepsia* 2002;43(9):1056-61.
59. Jones-Gotman M, Sziklas V, Djordjevic J, et al. Etomidate speech and memory test (eSAM): a new drug and improved intracarotid procedure. *Neurology* 2005;65(11):1723-9.
60. Takayama M, Miyamoto S, Ikeda A, et al. Intracarotid propofol test for speech and memory dominance in man. *Neurology* 2004;63(3):510-15.
61. Mikuni N, Takayama M, Satow T, et al. Evaluation of adverse effects in intracarotid propofol injection for Wada test. *Neurology* 2005;65(11):1813-16.
62. Wada J, Gibson WC. Behavioral and EEG changes induced by injection of schizophrenic urine extract. *AMA Arch Neurol Psychiatry* 1959;81(6):747-64.
63. Mader MJ, Romano BW, De Paola L, Silvado CE. The Wada test: contributions to standardization of the stimulus for language and memory assessment. *Arq Neuropsiquiatr* 2004;62(3A):582-7.
64. Dodrill CB, Ojemann GA. An exploratory comparison of three methods of memory assessment with the intracarotid amobarbital procedure. *Brain Cogn* 1997;33(2):210-23.
65. Serafetinides EA, Falconer MA. The effects of temporal lobectomy in epileptic patients with psychosis. *J Ment Sci* 1962;108:584-93.
66. Wieser HG, Yasargil MG. Selective amygdalohippocampotomy as a surgical treatment of mesiobasal limbic epilepsy. *Surg Neurol* 1982;17(6):445-57.
67. Setoain X, Arroyo S, Lomena F, et al. Can the Wada test evaluate mesial temporal function? A SPECT study. *Neurology* 2004;62(12):2241-6.
68. Urbach H, Kurthen M, Klemm E, et al. Amobarbital effects on the posterior hippocampus during the intracarotid amobarbital test. *Neurology* 1999;52(8):1596-602.
69. Ojemann JG, Kelley WM. The frontal lobe role in memory: a review of convergent evidence and implications for the Wada memory test. *Epilepsy Behav* 2002;3(4):309-15.
70. Lacruz ME, Alarcon G, Akanuma N, et al. Neuropsychological effects associated with temporal lobectomy and amygdalohippocampotomy depending on Wada test failure. *J Neurol Neurosurg Psychiatry* 2004;75(4):600-7.
71. Grote CL, Wierenga C, Smith MC, et al. Wada difference a day makes: interpretive cautions regarding same-day injections. *Neurology* 1999;52(8):1577-82.
72. Selwa LM, Buchtel HA, Henry TR. Electrocebral recovery during the intracarotid amobarbital procedure: influence of interval between injections. *Epilepsia* 1997;38(12):1294-9.
73. Bengner T, Haettig H, Merschhemke M, Dehnicke C, Meencke HJ. Memory assessment during the intracarotid amobarbital procedure: influence of injection order. *Neurology* 2003;61(11):1582-7.
74. Terzian H. Behavioural and EEG effects of intracarotid sodium amylal injection. *Acta Neurochir* 1964;12:230-9.
75. Masia SL, Perrine K, Westbrook L, Alper K, Devinsky O. Emotional outbursts and post-traumatic stress disorder during intracarotid amobarbital procedure. *Neurology* 2000;54(8):1691-3.
76. de Paola L, Mader MJ, Germiniani FM, et al. Bizarre behavior during intracarotid sodium amylal testing (Wada test): are they predictable? *Arq Neuropsiquiatr* 2004;62(2B):444-8.
77. Kanemoto K, Kawasaki J, Takenouchi K, et al. Lateralized memory deficits on the Wada test correlate with the side of lobectomy only for patients with unilateral medial temporal lobe epilepsy. *Seizure* 1999;8(8):471-5.
78. Rapport RL, Tan CT, Whitaker HA. Language function and dysfunction among Chinese- and English-speaking polyglots: cortical stimulation, Wada testing, and clinical studies. *Brain Lang* 1983;18(2):342-66.
79. Gomez-Tortosa E, Martin EM, Gaviria M, Charbel F, Ausman JI. Selective deficit of one language in a bilingual patient following surgery in the left perisylvian area. *Brain Lang* 1995;48(3):320-5.
80. Kipervasser S, Andelman F, Kramer U, Nagar S, Fried I, Neufeld MY. Effects of topiramate on memory performance on the intracarotid amobarbital (Wada) test. *Epilepsy Behav* 2004;5(2):197-203.
81. Bookheimer S, Schrader LM, Rausch R, Sankar R, Engel J, Jr. Reduced anesthetization during the intracarotid amobarbital (Wada) test in patients taking carbonic anhydrase-inhibiting medications. *Epilepsia* 2005;46(2):236-43.
82. Ammerman JM, Caputy AJ, Potolicchio SJ. Endovascular ablation of a temporal lobe epileptogenic focus - a complication of Wada testing. *Acta Neurol Scand* 2005;112(3):189-91.
83. Urbach H, Von Oertzen J, Klemm E, et al. Selective middle cerebral artery Wada tests as a part of presurgical evaluation in patients with drug-resistant epilepsies. *Epilepsia* 2002;43(10):1217-23.
84. Woermann FG, Jokeit H, Lueding R, et al. Language lateralization by Wada test and fMRI in 100 patients with epilepsy. *Neurology* 2003;61(5):699-701.
85. Papanicolaou AC, Simos PG, Castillo EM, et al. Magnetoencephalography: a noninvasive alternative to the Wada procedure. *J Neurosurg* 2004;100(5):867-76.
86. Knecht S, Deppe M, Ringelstein EB, et al. Reproducibility of functional transcranial Doppler sonography in determining hemispheric language lateralization. *Stroke* 1998;29(6):1155-9.
87. Rihs F, Sturzenegger M, Gutbrod K, Schroth G, Matile HP. Determination of language dominance: Wada test confirms functional transcranial Doppler sonography. *Neurology* 1999;52(8):1591-6.
88. Knake S, Haag A, Hamer HM, et al. Language lateralization in patients with temporal lobe epilepsy: a comparison of functional transcranial Doppler sonography and the Wada test. *Neuroimage* 2003;19(3):1228-32.
89. Salanova V, Morris HH, III, Rehm P, et al. Comparison of the intracarotid amobarbital procedure and interictal cerebral 18-fluorodeoxyglucose positron emission tomography scans in refractory temporal lobe epilepsy. *Epilepsia* 1992;33(4):635-8.
90. Hong SB, Roh SY, Kim SE, Seo DW. Correlation of temporal lobe glucose metabolism with the Wada memory test. *Epilepsia* 2000;41(12):1554-9.
91. Rabin ML, Narayan VM, Kimberg DY, et al. Functional MRI predicts post-surgical memory following temporal lobectomy. *Brain* 2004;127 (Part 10):2286-98.
92. Richardson MP, Strange BA, Thompson PJ, Baxendale SA, Duncan JS, Dolan RJ. Pre-operative verbal memory fMRI predicts post-operative memory decline after left temporal lobe resection. *Brain* 2004;127 (Part 11):2419-26.
93. Vinuela F, Fox AJ, Debrun G, Pelz D. Preembolization superselective angiography: role in the treatment of brain arteriovenous malformations with isobutyl-2 cyanoacrylate. *AJNR Am J Neuroradiol* 1984;5(6):765-9.
94. Pelz DM, Fox AJ, Vinuela F, Drake CC, Ferguson GG. Preoperative embolization of brain AVMs with isobutyl-2 cyanoacrylate. *AJNR Am J Neuroradiol* 1988;9(4):757-64.
95. Peters KR, Quisling RG, Gilmore R, Mickle P, Kuperus JH. Intraarterial use of sodium methohexital for provocative testing during brain embolotherapy. *AJNR Am J Neuroradiol* 1993;14(1):171-4.
96. Han MH, Chang KH, Han DH, Yeon KM, Han MC. Preembolization functional evaluation in supratentorial cerebral arteriovenous malformations with superselective intraarterial injection of thiopental sodium solution. *Acta Radiol* 1994;35(3):212-16.
97. Horton JA, Kerber CW. Lidocaine injection into external carotid branches: provocative test to preserve cranial nerve function in therapeutic embolization. *AJNR Am J Neuroradiol* 1986;7(1):105-8.
98. Usubiaga JE, Wikinski J, Ferrero R, Usubiaga LE, Wikinski R. Local anesthetic-induced convulsions in man - an electroencephalographic study. *Anesth Analg* 1966;45(5):611-20.

99. Deveikis JP. Sequential injections of amobarbital sodium and lidocaine for provocative neurologic testing in the external carotid circulation. *AJNR Am J Neuroradiol* 1996;17(6):1143-7.
100. Moo LR, Murphy KJ, Gailloud P, Tesoro M, Hart J. Tailored cognitive testing with provocative amobarbital injection preceding AVM embolization. *AJNR Am J Neuroradiol* 2002;23(3):416-21.
101. Rauch RA, Vinuela F, Dion J, et al. Preembolization functional evaluation in brain arteriovenous malformations: the superselective Amytal test. *AJNR Am J Neuroradiol* 1992;13(1):303-8.
102. Paiva T, Campos J, Baeta E, Gomes LB, Martins IP, Parreira E. EEG monitoring during endovascular embolization of cerebral arteriovenous malformations. *Electroencephalogr Clin Neurophysiol* 1995;95(1):3-13.
103. Niimi Y, Sala F, Deletis V, Setton A, de Camargo AB, Berenstein A. Neurophysiologic monitoring and pharmacologic provocative testing for embolization of spinal cord arteriovenous malformations. *AJNR Am J Neuroradiol* 2004;25(7):1131-8.
104. Rauch RA, Vinuela F, Dion J, et al. Preembolization functional evaluation in brain arteriovenous malformations: the ability of superselective Amytal test to predict neurologic dysfunction before embolization. *AJNR Am J Neuroradiol* 1992;13(1):309-14.

7. Intracranial Embolization Procedures

7.1. Introduction

Intracranial embolization procedures are therapeutic endovascular occlusions of vessels involved in vascular lesions of the cerebral circulation. One could imagine more catchy phrases to describe the procedure such as “intentional cerebral embolism” (ICE), but common parlance uses the less colorful and more awkward “intracranial embolization procedure” (IEP). This chapter covers a number of trans-arterial embolization procedures in the intracranial circulation. Trans-venous embolization procedures are discussed in Chap. 12 and specific embolization procedures on intracranial aneurysms are covered in Chap. 5. This chapter is divided into four major parts: (1) indications and contraindications; (2) general techniques and devices for intracranial vascular access and embolization; (3) procedural issues specific to particular disease processes; and (4) complication avoidance and management.

7.2. Intracranial embolization: Indications and contraindications

7.2.1. Common indications

1. Intracranial aneurysms (covered in Chap. 5)
2. Intracranial arteriovenous malformation (AVM)
 - (a) Pre-operative embolization
 - (b) Pre-radiosurgery
 - (c) Curative embolization (reported in from 4 to 27% of patients treated¹⁻⁵)
 - (d) Palliative embolization for inoperable AVMs (controversial)
 - Attempt to reduce neurological deficits from arterial steal and/or venous hypertension
 - Palliation of intractable headaches
 - Targeted embolization of higher risk AVM components (e.g. associated aneurysms⁶⁻⁸)
3. Intracranial arteriovenous fistula (AVF)
 - (a) Carotid cavernous fistula
 - (b) Dural AVFs
 - (c) Pial AVFs
 - (d) Vein of Galen malformations
 - (e) Post-traumatic fistulae
 - (f) Post-surgical fistulae
4. Bleeding intracranial vessel
 - (a) Usually when it occurs as a complication of an endovascular procedure
 - (b) Rarely for post-operative or post-traumatic bleeding
5. Intracranial vascular tumors
 - (a) Pre-operative embolization
 - (b) Palliative treatment for inoperable tumors

7.2.2. Relative contraindications

1. Vascular anatomy that is prohibitive (e.g., *en passage* feeding arteries that also supply eloquent brain, exaggerated vessel tortuosity).

2. Significant atherosclerotic disease or high-flow vasculopathy affecting the parent vessel (e.g., occlusion or stenosis of the access vessel).
3. Life-threatening contrast allergy.
4. Coagulation disorders or heparin hypersensitivity.
5. Active bacterial infection (i.e. bacteremia at time of endovascular treatment).

7.3. Intracranial vascular access and embolization: Techniques and devices

7.3.1. Evaluation

1. History and physical
2. Neurological exam
3. Blood work (CBC, BUN, Creatinine, PT, PTT)
4. Imaging
 - (a) Head CT or MRI
 - (b) CTA or MRA
 - (c) Preferably a catheter angiogram.
 - (d) Imaging considerations
 - Lesion location, potential brain territories at risk from the procedure, size and configuration.
 - Flow patterns (e.g., high flow vs. low flow arteriovenous shunt).
 - Parent vessel anatomy.
 - Angiographic architecture of lesion (e.g. nidal AVM vs. high-flow AVF vs. mixed lesion)
 - Presence of associated vascular lesion (e.g. aneurysm associated with AVM).
 - Plan site of intended deposition of embolic material.
 - Access vessel anatomy (e.g., dominant versus hypoplastic vertebral artery or ACA, degree of tortuosity).
 - Presence or absence of atherosclerosis or fibromuscular dysplasia in the access vessel.
 - Presence of recent or remote hemorrhage.
 - Associated brain edema or encephalomalacia.

7.3.2. Treatment strategy

Prior to the case, preferably the previous day or earlier, the patient should be assessed and all available imaging reviewed in preparation for the case. Decisions about the overall treatment strategy and the role of embolization in that strategy should be made well ahead of time. Plans should include:

1. Choice of access vessel
2. Guide catheter selection
3. Microcatheter and micro-wire selection
4. Embolic agent to be used
5. Target vessels to be treated
6. Staged multiple procedure vs. single embolization
7. Prepare for methods to ensure preservation of neurological function (e.g., provocative testing, neuophysiological monitoring)

7.3.3. Preprocedure preparation

1. Place two peripheral IVs.
2. NPO for 6h, except for medications.
3. Patients on insulin for hyperglycemia should get half their normal dose prior to the procedure.
4. Place Foley catheter.

5. Place thigh-high sequential compression device (SCD) sleeves on both legs for deep vein thrombosis prophylaxis.
6. Make sure that all devices that may be needed are available in the angio suite prior to the procedure.
7. If stent-assisted coiling is planned, as in stent-assisted coiling of a carotid-cavernous fistula, pre-treatment with antiplatelet therapy may be indicated:
 - (a) Aspirin 325-mg PO QD for ≥ 3 days prior to the procedure *and*
 - (b) Clopidogrel (Plavix[®], Sanofi-Aventis, Bridgewater, NJ) 75-mg PO QD for ≥ 3 days prior to the procedure (or 300-mg PO 5 h prior to the procedure).
8. Many practitioners routinely pre-treat patients with dexamethasone, 2 mg PO/IV Q6 hours for 2–3 days before any intracranial embolization procedure to attempt to reduce the risk of swelling. This is done based on a positive effect of the steroid in the setting of various brain tumors and experimental evidence of success in maintaining intact blood brain barrier using dexamethasone.⁹ There are some animal data suggesting that the drug can be helpful in reducing the effects of ischemia,¹⁰ which can be a complication of embolization. On the other hand, there are many studies showing that in the setting of acute ischemia, steroids either do not help,¹¹ or may worsen the amount of ischemic damage.¹² Dexamethasone may not aggravate ischemia if it is not given for an extended period before the procedure¹⁴ but given the limited evidence of efficacy and questions about aggravation of ischemia, the authors of this handbook do not use steroids routinely for embolization procedures, except in tumor cases.
9. *Patients with recent intracranial hemorrhage:*
 - (a) Arterial line and central venous access are established prior to the procedure
 - (b) If a ventriculostomy is present, the catheter must be attached to a monitor, to permit continuous ICP monitoring during the case.
 - The ICP is an “early warning system” for AVM rupture or re-rupture during embolization.
 - The ventriculostomy should be “on monitor” (and not “to drain”) if possible during the entire procedure, to permit continuous monitoring. Open the drain only intermittently if CSF drainage during the procedure is necessary.

7.4. Endovascular technique

The technique of intracranial embolization treatment varies considerably from case to case. The following is a general outline of the procedures and devices used by the authors for most patients. The case is divided into a vascular *access* phase, a microcatheter *access* phase, and an *embolization* phase. Each phase requires choosing a system of devices and techniques to achieve the therapeutic goals.

7.4.1. Awake or asleep?

Some operators prefer to use general anesthesia for embolization cases whereas others prefer to do them with the patient awake. Each approach has advantages. Embolization with the patient awake permits continuous neurological monitoring, eliminated the risks of general anesthesia, can shorten the length of the case, and is done in many centers. Embolizing with the patient awake is less practical in patients with reduced mental status and in those with small or very distal lesions in which a small amount of patient motion can lead to vessel perforation or inadvertent occlusion of normal vessels. Very distal catheterization, and even more proximal catheterization with larger microcatheter systems can cause considerable pain due to the sensitivity of the proximal intradural vessels, and that pain makes it difficult for even sedated patients to remain motionless. General anesthesia can eliminate this discomfort and patient mobility, allows the operator to focus on the procedure rather than on coaching and assessing the patient, can be much more palatable for anxious patients, and permits tight blood pressure and intracranial pressure control. The lower systemic pressure attainable under general anesthesia also allows some flow control in high flow AVMs or AVFs perhaps providing a lower risk of migration of embolic agents

from their intended destination. Intra-operative embolization also definitely requires general anesthesia. Neurophysiological monitoring can still be accomplished under anesthesia using EEG and/or evoked potentials. The authors of this handbook prefer to use general anesthesia in nearly all cases of intracranial embolization, except for rare cases in which medical issues place the patient at elevated risk with anesthesia (e.g., severe heart disease).

7.4.2. Awake

1. Patient is placed on the angiography table awake.
2. An abbreviated neurological exam is rehearsed with the patient prior to draping (e.g., patient is asked to say "Methodist Episcopal," show their teeth and gums, wiggle their toes, and squeeze a rubber duck with the hand contralateral to the side being treated).
3. Throughout the case the patient is reminded to stay completely still. The patient's head can be lightly taped to the head holder with a piece of plastic tape across the forehead to remind him or her to stay still.
4. Sedation and analgesia may be increased during the access phase, but are kept to a minimum if provocative testing is done to facilitate the patient's full cooperation.

7.4.3. Asleep

1. Patient is placed under general anesthesia on the angiography table.
2. Strict attention to blood pressure control during anesthesia induction is necessary to minimize risk of AVM rupture.
 - (a) A radial arterial line for blood pressure monitoring can be quite helpful especially if a modification of the flow by blood pressure control is anticipated.
 - If arterial monitoring is felt to be necessary prior to induction, place a 7-French femoral sheath while the patient is still awake. Placement of a femoral artery sheath may be less uncomfortable than a radial artery line. A 7-French sheath is large enough to permit passage of a 6-French guide catheter and still allow arterial line monitoring.
3. The anesthesiologist is asked to report any abrupt changes in blood pressure or heart rate during the case, which can indicate intracranial hemorrhage.
4. If using neurophysiological monitoring, baseline EEG and/or evoked potentials are obtained prior to any intervention. Depending on the anatomic location of the lesion, either somatosensory, motor, visual or auditory evoked potentials may be the most sensitive for monitoring functional status during the procedure.

7.4.4. Vascular access phase

For intracranial embolization procedures, this phase involves accessing the arterial system and placing a guide catheter in a position proximal to the lesion being treated.

1. The vast majority of cases are done using femoral arterial access and only rarely brachial, radial, or very rarely direct carotid puncture may be necessary.
2. Dorsalis pedis and posterior tibialis pulses are assessed and marked.
3. The right or left groin is prepped, draped, and infiltrated with local anesthesia.
4. A 6-French sheath is placed in the femoral artery.
 - (a) A 7 or (rarely, 8 French) sheath should be used if arterial monitoring through the sheath is planned, or if adjunctive techniques, such as balloon-assisted coil embolization or detachable balloon embolization, are anticipated.
 - (b) Sheaths are available in various lengths, most commonly 10 or 25 cm. The 25-cm version has the advantage that it bypasses any tortuosity in the iliac arteries. Having the distal end of the sheath in the aorta

- prevents any danger of injuring the iliac artery during catheter introduction through the sheath.
- (c) Ninety-centimeter sheaths such as the Shuttle® (Cook Inc., Bloomington, IN) can reach the carotid and can be used as a large-lumen guiding catheter or added stabilization for a standard guiding catheter (see below).
5. An angiogram is done using a diagnostic catheter. Angiograms of the access vessel (carotid or vertebral artery) and PA and lateral views of the intracranial circulation are done prior to the intervention.
- (a) Examination of the carotid or vertebral artery is necessary for guide catheter selection, and to check for the presence of atherosclerosis and fibromuscular dysplasia.
- (b) Intracranial images at the beginning of the case are necessary for comparison later, to assess for arterial thromboembolic complications or venous occlusions.
6. Systemic anticoagulation. Thromboembolic complications can occur during any intracranial catheterization, occurring in approximately one in ten patients.¹⁵ Despite this, among various institutions, the use of prophylactic systemic anticoagulation during intracranial embolization is quite variable. One group advocates systemic heparin in embolization of small AVMs, but not in those larger than 3 cm in diameter.¹⁶ Some never use heparin and other always use it. The authors of this handbook tend toward fairly universal use of systemic heparin for intracranial embolization procedures. Evidence from the cardiac catheterization literature indicates that heparinized saline flush alone is inadequate to affect clotting parameters¹⁷ but intravenous boluses of 150 units per kg body weight do not appear to provide added protection from thromboembolic complications compared to 100 U kg⁻¹.¹⁸ One could surmise that practitioners who see more thromboembolic complications tend to use heparin, while those that encounter vessel perforations and other hemorrhagic complications avoid heparin, although this hypothesis has not yet been tested. Systemic anticoagulation with IV heparin appears to carry relatively little risk in patients with unruptured AVMs, and judicious use of heparin even in patients with ruptured AVMs also appears to be of relatively low-risk, particularly since the drug can be rapidly reversed with protamine.
- (a) Dosing for heparin
- A loading dose of IV heparin is given (70 U kg⁻¹) and 5 min later, a 1–3-mL specimen of blood for an activated clotting time (ACT) is drawn from the sheath. The guide catheter is placed in the ICA or vertebral artery only after the heparinization is therapeutic (usually 5 min or more after the IV loading dose is given, or after the ACT has been found to be in the target range). The ACT should be kept between 250 and 300 s for the duration of the procedure. Additional doses of heparin are necessary only during cases that last longer than several hours.
- (b) Protamine on stand-by – *Critical*
- A syringe containing protamine, enough to reverse the total amount of heparin the patient has received, should be constantly available in the endovascular suite for easy access to the operator, should hemorrhage occur during the case.
 - Dose of protamine required to reverse heparin: 10-mg protamine/1,000-U heparin.
- (c) Other antithrombotic agents
- Antiplatelet agents. The authors do not recommend routine use of antiplatelet medications for most intracranial embolizations except in cases where the use of stent-assisted coiling is anticipated.
 - Argatroban (Novastan®, Abbott, North Chicago, IL) is an anti-thrombotic suitable for use in patients with heparin induced thrombocytopenia.^{19, 20} For neuro-interventional procedures, the authors have used the recommended coronary interventional doses of 350 µg kg⁻¹ bolus over 3–5 min, and adequacy of antithrombotic effect is monitored by ACT values around 250–300 s. A continuous drip of 10–25 µg kg⁻¹ min⁻¹ can be used for longer procedures, or, alternatively, 150 µg kg⁻¹ boluses at hourly intervals if the ACT falls below 250. The saline infusions through the catheter or sheath lumen must obviously not contain any heparin. Argatroban has no specific antidote, and the only course of action to employ in the case of active bleeding is to stop the infusion and wait for the effect to wear off. Therefore this agent must be used with caution.

- Bivalirudin (Angiomax™, The Medicines Company, Cambridge, MA) is a synthetic direct thrombin inhibitor that is popular in interventional cardiology and has been used in neuro-endovascular procedures in select cases.²¹ It can also be used in patients who cannot tolerate heparin, as in cases of heparin-induced thrombocytopenia.²² However, like argatroban, there is no rapid reversal agent for bivalirudin, and its routine use in patients for intracranial embolization is not recommended.
 - Other designer antithrombotics that can be used in patients with heparin contra-indications include lepirudin and danaparoid.²³
 - In many hospitals, many of these unusual antithrombotics may have restrictions on their use and may require a Hematology consult in order to obtain the drug from the pharmacy.
7. Guidewire selection for vascular access
- (a) Most commonly, 0.038 J-tip wires (“Safety wires”) are used for sheath placement.
 - (b) Steerable hydrophilic wires such as 0.035 or 0.038-in. angled Glidewire® (Terumo Medical, Somerset, NJ) can be used to advance a guiding catheter into the desired carotid or vertebral.
 - (c) Exchange-length (meaning at least 270-cm long) wires may be needed to exchange a curved diagnostic catheter for a straight guide catheter. The authors of this handbook frequently use the 0.035-in. diameter, 300-cm long Storz® wire (Cordis Endovascular, Miami Lakes, FL).
8. Guide catheter selection
- Guide catheters are critical to the successful performance of intracranial embolization procedures, since they provide a stable platform to send soft, flexible microcatheters into the intracranial vessels (Table 7.1).
- a. Each guide catheter has its advantages and disadvantages and the best catheter may vary, depending on the situation.
 - Berenstein Large Lumen Balloon Guide Catheter (Boston Scientific, Natick, MA)
 - Advantages: Balloon allows for proximal flow control, to prevent distal migration of embolic agent in high flow states.
 - Disadvantages: Relatively small lumen (in spite of its name). Short length (80cm) limits the use to short patients and a very proximal catheter position.
 - Envoy® (Cordis Neurovascular, Miami Lakes, FL)
 - Advantages: Relatively rigid, provides a good platform in tortuous vessels, larger internal lumen than most other guide catheters. Non-hydrophilic coating may be more stable in the vessel.
 - Disadvantages: Stiff, and traumatic to the vessel wall. May be more thrombogenic than hydrophilic coated catheters.
 - Guider Softip™ XF guide catheter (Boston Scientific, Natick, MA)
 - Advantages: Soft, atraumatic tip. Minimizes risk of vasospasm and dissection in narrow, tortuous vessels.
 - Disadvantages: Relatively flimsy and slippery with hydrophilic coating, prone to fall into the arch when the vasculature is tortuous.
 - Neuron™ (Penumbra, San Leandro, CA)
 - Advantages: Relatively rigid proximally, but very flexible distally, allowing for very distal placement intracranially, with minimal trauma to the vessel. This provides a very stable platform in tortuous vessels.
 - Disadvantages: Distal, floppy segment provides miserably poor support if the catheter not able to be placed distally. Very long lengths of catheter (at least 105cm) may use up microcatheter length within the guide catheter and thereby prevent distal access.
 - Northstar™ (Cook Medical, Bloomington, IN)
 - Advantages: Has an inner dilator that provides a smooth transition between guidewire and guide catheter, preventing the large diameter lumen from scraping along the vessel and catching on turns and plaques as it is advanced. This dilator also allows introduction without the use of a groin sheath. Relatively rigid, providing a stable platform.

Table 7.1 Common neuro guide catheters

Catheter	Manufacturer	Length (cm)	Distal flexible zone (cm)	Outer diameter (French size)	Inner diameter (inches)
Berenstein large-lumen balloon guide	Boston Scientific	80		6 (11.5-mm diameter distal balloon)	0.042
Envoy® 5 Fr	Cordis	90 or 100		5	0.056
6 Fr				6	0.067
7 Fr				7	
Guider Softip™ XF 5 Fr	Boston Scientific	90 or 100	7	5	0.053 or 0.071
6 Fr				6	0.064
7 Fr				7	0.073
8 Fr				8	0.086
9 Fr				9	0.099
Neuron™	Penumbra	105 or 115	6 or 12	6 (5 distally)	0.053
Northstar™ Lumax® 6 Fr	Cook	90		6	0.060
7 Fr				7	0.073
8 Fr				8	0.086
9 Fr				9	0.099
Pinnacle® Destination® Guiding sheath 5 Fr	Terumo	90		Approx. 7.5	0.071
6 Fr				Approx. 8.5	0.083
Shuttle® Sheath 5 Fr	Cook	90		Approx. 6.5	0.074
6 Fr				Approx. 7.5	0.087
7 Fr				Approx. 8.5	0.100
8 Fr				Approx. 9.5	0.113

- Disadvantages: Smaller internal diameter than that of other guide catheters. The rigid design, coupled with the slippery hydrophilic coating can cause the catheter to slip out of position, especially in tortuous vessels.
- Pinnacle® Destination® (Terumo Medical, Somerset, NJ)
 - Advantages: Designed as a long sheath to also act as a guide catheter. Inner dilator provides a smooth transition to guidewire as it is advanced. Relatively rigid to provides a very stable platform. Large lumen. An inner guide catheter can be placed to provide added stability (“Tower of Power”).
 - Disadvantages: Rigid sheath should not be placed too distally or in small vessels to prevent vessel injury. Somewhat less rigid and less stable than other systems.
- Shuttle® (Cook Medical, Bloomington, IN)
 - Advantages: A 90-cm sheath that can access the carotid or vertebral. Very large internal lumen. Inner dilator gives

smooth transition to a 0.038 inch wire for smooth advancement. Various 105-cm long curved inner catheters are available to facilitate selection of vessels from the aortic arch. Very rigid and very stable. Can use an inner 100 cm or longer guide catheter to create an even stiffer "Tower of Power".

- Disadvantages: Big, stiff sheath can be traumatic to the vessel. Not easily used in tortuous vessels. Care must be taken to keep large internal lumen flushes with heparinized saline because large amounts of blood collecting in lumen can create very large thrombi.

(b) Guide catheter size

- Length: Should be enough to access the vessel of choice with little excess hanging out of the groin sheath. This maximizes the distance the microcatheter can be advanced in the intracranial vessels. For the average sized patient, a 90-cm length works well to access the internal carotid or vertebral. If the Neuron™ is being used, longer lengths (105 or 120) cm may be needed since this catheter can be placed much more distally.
- Diameter: 6-French outer diameter for most cases allows good support and adequate internal diameter to place the microcatheter and have sufficient clearance to flush and inject contrast.
- High-support 6 or 7 French if the need for added support is anticipated
- Smaller 5 French if the vessel caliber is small and collateral circulation is limited (e.g., for use in a small vertebral artery when the contralateral vessel is hypoplastic)
 - Advantage: Less traumatic. May be able to place more distally than larger catheter.
 - Disadvantage: More difficult to obtain angiograms with the microcatheter in place because of limited space within the guide catheter. The use of a smaller microcatheter can improve this.
- Diagnostic 5- or even 4-French catheters can be used as a guide catheter in children or smaller adults. A catheter that accepts at least a 0.038-in. wire will accommodate a microcatheter, although it is less stable than a dedicated guide catheter.

(c) Straight or angled?

- Straight guide catheter is useful in relatively straight vessels, or in situations where the guide catheter will be gently navigated through a convoluted vessel over a wire or co-axially over a microcatheter.
 - Usually requires exchanging (see below).
 - Preferred for the vertebral artery.
 - Preferred for glue embolization since an angle can cause the tip of the guide catheter to indent the microcatheter, and can squeeze ("milk") glue out of the microcatheter if it is pulled back through the guide catheter.
- Angled guide catheter is useful when the final position of the catheter tip is in a vessel curve
 - Angled catheters are easier to navigate through the aortic arch than straight catheters

9. Guide catheter placement technique

(a) Direct navigation method

- Useful in young patients with non-tortuous, non-atherosclerotic vessels.
- The catheter is flushed with heparinized saline.
- If a long dilator is available for the guide catheter (as with the Northstar™) the dilator is inserted into the guide catheter and flushed.
- A rotating hemostatic valve with a continuous saline infusion is attached to the hub.
- Advance a wire to the very tip of the guide catheter to stiffen it and allow passage through the valve in the hub of the sheath.
- Sometimes, in younger patients, even a straight guide catheter can be manipulated into the vessel of choice using a curved, steerable wire such as the 0.038-in. Glidwire® (Terumo Medical, Somerset, NJ).

- An angled guide catheter can usually be gently navigated directly into the carotid or vertebral artery over a 0.035-in. or 0.038-in. hydrophilic wire.
- (b) Exchange method
- Useful in patients with tortuous anatomy, atherosclerosis, or fibromuscular dysplasia. This technique can minimize the risk of injury to the carotid or vertebral artery, particularly at the vessel origin.
 - A 5-French diagnostic catheter is guided into the CCA or vertebral artery over an exchange-length (270–300 cm) wire.
 - The tip of the wire is advanced into a distal branch of the ECA or into the distal extracranial vertebral artery (usually the first 90° turn of the vessel at C2) using roadmapping technique.
 - The diagnostic catheter is then gently removed while the tip of the hydrophilic wire is continuously visualized on fluoroscopy.
 - The hydrophilic wire is wiped down with a dripping-wet Telfa sponge.
 - The guide catheter is advanced over the wire while continuously visualizing the tip of the wire.
- (c) Guide catheter positioning
- Carotid system. Using roadmapping, the guide catheter is advanced over a hydrophilic wire into the ICA as distally as possible. A “high position” of the guide catheter will maximize the stability of the guide and improves control over the microcatheter and microwire. In a non-tortuous, healthy carotid system, the authors prefer to position the tip of the guide catheter in the vertical segment of the petrous ICA. In a cervical ICA with a significant curve in the vessel, the guide can be adequately positioned immediately proximal to the curve. Moderate curves in the vessel can be straightened out by guiding a relatively stiff hydrophilic wire (e.g., an 0.038-in. wire) through the affected segment, followed by the catheter.
 - Vertebral artery. Using roadmapping, the guide catheter is positioned in the distal extracranial vertebral artery, usually at the first curve (at C2).
 - Once the catheter is in position, a gentle injection of contrast through the guide catheter under fluoroscopy is done, to examine the configuration of the vessel around the tip and to check for the presence of vasospasm or vessel dissection around the tip. If catheter tip-induced vasospasm is present and flow-limiting, withdrawal of the catheter tip by several millimeters is often sufficient to restore the flow.
 - The catheter tip may slide up and down and rub against the vessel wall with each heart beat; be sure to take this into account when positioning the catheter.
10. Guide catheter irrigation
- (a) Continuous irrigation of the guide with heparinized saline (5,000-U heparin per 500-mL saline) is important.
 - (b) A three-way stopcock connects the heparinized saline flush-line to a rotating hemostatic valve (RHV) to allow continuous infusion of saline through the guide while microcatheters or other devices are being inserted. The authors attach a large-bore one-way stopcock between the RHV and the guide catheter to allow control of back-bleeding if the RHV is opened.
 - (c) *Warning:* If using a large-bore stopcock between RHV and guide catheter, do not attempt to close the stopcock when wires or microcatheters are in place in the guide catheter. They can be severely damaged.
 - (d) Meticulous attention to the guide catheter RHV throughout the case is necessary to identify thrombus or bubbles, should they appear.
 - (e) The heparinized saline drip should be periodically monitored to ensure that it is dripping slowly, but continuously, and there is still sufficient fluid in the saline bag to last for the case.
11. Maintaining guide catheter position
- (a) It is vitally important to fluoroscopically monitor the position of the guide catheter periodically during the microcatheter access phase and embolization phase of the procedure.
 - (b) The guide catheter may become displaced during microcatheter manipulation, which can result in kinking of the microcatheter, can make it

- difficult to access the desired microcatheter position and can cause sudden, undesired displacement of the microcatheter.
- (c) Guide catheter position can be easily monitored with biplane angiographic systems, by having at least one imaging plane including the tip of the guide catheter.
 - (d) Any displacement of the guide catheter tip should be corrected, and, if the catheter appears to unstable, replacement with a more stable guide catheter system should be considered.
12. Special situation: Tips on using the Neuron™.
- (a) This guide catheter is intended to be placed very distally in the carotid or vertebral artery.
 - (b) The 105-cm length is adequate for most situations. The 120-cm length is only necessary for very tall patients or very, very distal catheter placement.
 - (c) Since the Neuron catheter tip is as soft as a microcatheter, it can easily be damaged if inserted through the sheath hemostatic valve. Two techniques can be used to insert it in the sheath.
 - Insert a 0.035 or 0.038-in. hydrophilic wire backwards (stiff end first) into the Neuron with the stiff end just to the tip of the catheter, then insert the catheter just into the sheath. The wire is then removed and reversed so that the soft end of the wire leads as the catheter is advanced through the vascular system. *Never insert the stiff end of the guidewire into the vessel.*
 - It is simpler to first position a diagnostic catheter in the desired carotid or vertebral artery, then leave a 0.035 or 0.038 exchange wire in the vessel, remove the diagnostic catheter, then insert the Neuron™ over the exchange wire into the sheath and continue advancing over the exchange wire into the target vessel.
 - (d) Given the extremely floppy distal end of this guide catheter, it is usually not feasible to primarily advance it over a wire from the sheath into the brachiocephalic vessels, except in very easy, straight vascular anatomy.
 - (e) The company makes curved inner catheters to assist manipulation of the Neuron™ into position, although these catheters are very limp and provide minimal support. The authors have found it easier to use an exchange wire placed first with a curved diagnostic catheter to get the Neuron™ into the proximal carotid or vertebral.
 - (f) Once in the proximal access vessel, contrast is injected in order to obtain a mask for roadmapping. There are then two ways to get the Neuron™ into its final, distal position.
 - The guide catheter may be positioned in the intracranial carotid or vertebral by *very carefully* advancing the catheter over a 0.035 Glidewire® (Terumo Medical, Somerset, NJ). The relatively stiff wire is needed to support the floppy Neuron™, but must be used with extreme caution in the intracranial vessels.
 - The authors of this handbook prefer a coaxial technique of advancing a microcatheter over a microwire through the Neuron into the target vessel distal to the desired final position of the guide catheter. The Neuron™ is then advanced over the microcatheter to its final position. A more substantial microcatheter such as a Renegade® (Boston Scientific, Inc., Natick, MA) or Prowler® Plus (Cordis Neurovascular, Miami Lakes, FL) can provide good support to facilitate distal placement of the Neuron™.
 - (g) Optimal positioning is distal to at least two 90° turns in the vessel to provide sufficient support for the coaxial placement of a microcatheter.
 - (h) The Neuron™ will accept most microcatheters, but it may be difficult to inject contrast around 18-system microcatheters like the Renegade® (Boston Scientific, Inc., Natick, MA) or Prowler® Plus (Cordis Neurovascular, Miami Lakes, FL).
 - (i) *Warning:* When the Neuron™ is in its final intracranial position, use caution when flushing or injecting contrast. Smaller volumes and lower pressures should be used since the pressure is transmitted directly to the intracranial vessels. This can be particularly dangerous if there is an aneurysm nearby the catheter tip. *Avoid using a power-injector with the Neuron™.*

7.4.5. Microcatheter access phase

Once a stable guide catheter position is achieved, a microcatheter is coaxially advanced to a position from which the embolic material can be delivered to the target lesion.

1. Roadmap guidance:
Absolutely critical for safe and effective intracranial catheterization
 - (a) Contrast is injected and a mask image of the vascular tree is saved, and superimposed digitally on the live fluoroscopic image.
 - (b) Roadmapping ensures safe and expeditious navigation through the complicated and tortuous intracranial vascular anatomy.
 - (c) Biplane roadmapping is best.
 - (d) 3D roadmapping is available on newer angiographic suites.
 - (e) If the patient moves or if a different projection is required to negotiate a turn, another roadmap mask can be obtained.
2. Microcatheter selection
 - (a) There are many microcatheters, and the optimal choice depends on how large or how distal the target vessel is, what embolic agent will be used, and the training and experience of the operator.
 - (b) Microcatheters come in three flavors (varieties):
 - Over the wire microcatheters are by far the most common. With these microcatheters, a curved microwire is manipulated toward the target position and the microcatheter is passively advanced over the wire until it reaches the proper position. The Tracker[®] catheter was the first successful example of this variety, and was characterized by variable stiffness in its segments: The proximal end was fairly rigid to allow for advancement, gradually tapering in outer diameter, and becoming softer and more flexible, to allow for passage through small, tortuous vessels. Current versions of this type of catheter tend to have more gradual gradations from one degree of stiffness to another and have braiding or stiffeners in the wall to improve forward transmission of pushing power and to prevent kinking of the catheter as it takes sharp turns. Hydrophilic coating reduces friction between the microcatheter and guiding catheter, and with the vessels. It also may reduce the risk of clot accumulation on the catheter.²⁴
 - Advantages: Versatile. Stable position possible. Relatively large lumen accepts various guidewires and various types of embolic agents. Most are somewhat flexible. Distal tip can be steam shaped and some have available pre-shaped curves.
 - Disadvantages: Somewhat stiff. May traumatize very small, very tortuous vessels. The wire is usually advanced distal to the tip, so the wire can traumatize perforate small branches.
 - There are only a small number of flow-directed microcatheters, and some are more flow-directed than others. Many would maintain that the only true flow-directed system is the Magic[®] microcatheter (AIT-Balt, Miami, FL). These are so flexible distally that the tip is pulled along by blood flow, making this a good choice for high flow lesions such as AVMs.
 - Advantages: Very flexible and atraumatic to the vessel. Can be advanced very distally in tortuous vessels. The ideal microcatheter for vessels less than 2mm in diameter. Distal tip can be steam shaped. Flow direction limits need to use a wire beyond the tip of the catheter, reducing the risk of vessel trauma or perforation by the wire.
 - Disadvantages: Small lumen limits the size of usable micro-guidewires and also limits the type of embolic agent. Catheter position may be less stable than over-the-wire types.
 - Steerable microcatheters are the least common and are basically over-the-wire catheters that have the added benefit of a steerable tip of the microcatheter.
 - Advantages: Steerable tip may allow access to difficult angulated branches. Distal tip steam shapeable. Tend to be very stable once positioned.
 - Disadvantages: The stiffest of all microcatheters. Not suitable for very small or very distal vessels. The wire is usually

advanced beyond the tip of the catheter so can traumatize small vessels.

- (c) Two-marker, over-the-wire microcatheters, rather than single-marker catheters, are necessary for the use of detachable coils. The two markers in microcatheters used in detachable coils are always 3 cm apart to determine that the coil is properly deployed. This feature can also be used for calibration and measurements. These two markers may make the distal 3 cm minimally stiffer than one marker catheters, but do not preclude the use of embolic agents other than detachable coils.
- (d) Microcatheter shape: *Pre-shaped* versus *straight* versus *steam-shaped*
- A shaped microcatheter can be advantageous in accessing vessels that arise from the main vessel at an acute angle, and in stabilizing the microcatheter during embolization.
 - When available, pre-shaped microcatheters, are preferable since they retain their shape better than steam-shaped microcatheters.²⁵ A side-benefit of using a pre-shaped microcatheter is the peel-away introducer packaged with the pre-shaped catheters, at least the ones from ev3 and Boston Scientific. The peel-away introducer temporarily straightens the curve to allow easy introduction into the RHV of the guide catheter. Steam-shaping is reserved for obtaining catheter shapes that are not available in pre-shaped devices.

Commonly used microcatheters.

The choice of microcatheter is critical to the successful performance of intracranial embolization procedures. These devices are only those commonly used by the authors and this list is by no means exhaustive (Tables 7.2 through 7.4).

Table 7.2 Common over-the-wire microcatheters

Catheter	Manufacturer	Length (cm)	Outer diameter (French size)	Inner diameter (inches)	Comments
Echelon™ 10	ev3	150	2.1–1.7 distally	0.017	DMSO compatible. Two pre-shaped curves available
Echelon™ 14	ev3	150	2.4–1.9 distally	0.017	DMSO compatible. Two pre-shaped curves available
Excelsior® SL-10	Boston Scientific	150	2.4–1.7 distally	0.0165	Five pre-shaped curves available
Excelsior® 1018®	Boston Scientific	150	2.6–2.0 distally	0.019	Five pre-shaped curves available
Prowler® 10	Cordis	70 or 150 or 170	2.3–1.7 distally	0.015	Five pre-shaped curves available.
Prowler® 14	Cordis	70 or 150 or 170	2.3–1.9 distally	0.0165	Three pre-shaped curves available.
Prowler® Plus	Cordis	150 or 170	3.0–2.3 distally	0.021	Three pre-shaped curves available.
Rebar® 10	ev3	153	2.3–1.7 distally	0.015	DMSO compatible
Rebar® 14	ev3	153	2.4–1.9 distally	0.017	DMSO compatible
Rebar® 18	ev3	110 or 153	2.8–2.3 distally	0.021	DMSO compatible
Rebar® 027	ev3	110 or 145	2.8	0.027	DMSO compatible
Renegade® 18	Boston Scientific	150	3.0–2.5 distally	0.021	

Table 7.3 Common flow-directed microcatheters

Catheter	Manufacturer	Length (cm)	Outer diameter (French size)	Inner (distal) diameter (inches)	Comment
Magic®	Balt	155 or 165	2.7–1.8 distally	0.013	Various distal floppy segments and also “olive” available
Magic® 1.5	Balt	155 or 165	2.7–1.5 distally	0.010	Various distal floppy segments and also “olive” available
Magic® 1.2	Balt	165	2.7–1.2 distally	0.008	Various distal floppy segments and also “olive” available
Marathon™	ev3	165	2.7–1.3 distally	0.013	DMSO compatible. High burst pressure. Not very flow-directable
Ultraflow™	ev3	165	3.0–1.5 distally	0.012 or 0.013	DMSO compatible. More flow-directed than Marathon, but not as burst-resistant

Table 7.4 Common steerable microcatheters

Catheter	Manufacturer	Length (cm)	Outer diameter (French size)	Inner diameter (inches)	Comments
Pivot™	Boston Scientific	150	2.4–1.9 distally	0.017	Not currently available
Courier® Enzo™ 170	Micrus	150	3.0–2.9 distally	0.017	Tip deflects up to 90 degrees in either direction
Courier® Enzo™ 190	Micrus	150	3.1–3.0 distally	0.019	Tip deflects up to 90° in either direction

- Steam shaping technique:
 - Shape the wire mandrel into the desired shape, with an exaggerated degree of curvature (as the microcatheter will recoil to some degree after steam-shaping).
 - Hold over steam for 10 s.
 - Cool in sterile water and remove mandrel.
 - Non-braided (e.g., Tracker® and Magic®) and fiber-braided (e.g., Excelsior®) microcatheters are more likely to retain their shape after steam shaping than metal coil-braided (e.g., Prowler and Echelon™) microcatheters.²⁵

3. Microwire selection

- (a) A wide variety of microwires are available, with differing properties such as size, softness, visibility on fluoroscopy, shapeability, and steerability, trackability, and torque control.
- (b) All microwires suitable for neuro-endovascular procedures are hydrophilically coated to reduce friction.
- (c) Wires can have a shapeable distal tip or may come pre-shaped from the manufacturer.
- (d) Shapeable tips are usually made of platinum, which makes it quite visible on fluoroscopy

- (e) Sizes of microwires range from 0.008 in. for the tiny Mirage™ (ev3, Irvine, CA) to a variety of 0.10 in. and even more 0.014-in. wires up to the robust 0.016-in. Headliner™ (Terumo Medical Corporation, Somerset, NJ). Larger diameter wires are available, but are generally a tight fit in commonly used microcatheters and are too stiff for safe intracranial navigation.
 - (f) In general, 0.010 in. or smaller wires are used in flow-directed catheters, 0.014-in. wires are used in most other microcatheters. Any of the wires larger than 0.014 in. are only used rarely when a large lumen microcatheter is used and added torque or support is needed.
 - (g) Microwires can be broadly classified according to the design and composition of the core wire that forms the backbone of the microwire:
 - Stainless steel core wires like Mirage™ or Silverspeed® (ev3, Irvine, CA) or Agility® (Cordis Neurovascular, Miami Lakes, FL).
 - Superior torque control, compared with many other microwires.
 - Heightened radio-opacity makes the platinum tip easy to see on fluoroscopy.
 - Shapeable tip.
 - Easily kinked.
 - Nitinol core wires like the Headliner™ (Terumo Medical Corporation, Somerset, NJ)
 - Tip shape supplied by manufacturer.
 - J-tip is quite atraumatic to the vessel walls.
 - Best suited for uncomplicated vessel anatomy (tends to follow the straightest vessel).
 - Very kink-resistant.
 - Composite alloy flat-cores like Transend™ EX (Boston Scientific, Inc., Natick, MA)
 - Advantage: Superior torque control than most other wires.
 - Kink resistance tends to be more than that of stainless steel core, but less than that of nitinol core wires.
 - Tip shapeable. Note: Tip should be shaped in the direction of the natural curve of the wire to take advantage of the torque characteristics of the flat core.
 - Synchro®-14 0.014 in. (Boston Scientific, Inc., Natick, MA)
 - Very soft, flexible distal tip, good for navigation into small vessels or through difficult anatomy.
 - “Supreme torque control.”
4. Microcatheter irrigation
- (a) Continuous irrigation of the microcatheter as well as the guide catheter with heparinized saline (5,000-U heparin per 500-mL saline) is important.
 - (b) A three-way stopcock connects the heparinized saline flush-line to a rotating hemostatic valve (RHV) to allow continuous infusion of saline.
 - (c) Heparinized saline infusion ensures hydration of the hydrophilic coating on the microwire and minimizes friction.
 - (d) Meticulous attention to the microcatheter (and guide catheter) RHV throughout the case is necessary to identify thrombus or bubbles, should they appear.
 - (e) The heparinized saline drip should be periodically monitored to ensure that it is dripping slowly, but continuously, and there is still sufficient fluid in the saline bag to last for the case.
5. Microcatheter/microwire assembly preparation
- (a) The chosen microcatheter is removed from its package, maintaining sterile technique.
 - (b) The plastic hoop housing the microcatheter is flushed to hydrate the hydrophilic coating.
 - (c) If necessary, the tip of the microcatheter can be steam shaped over the small mandrel that usually comes packaged with the catheter.
 - (d) The hub of the microcatheter is attached to an RHV and the lumen of the RHV and microcatheter are flushed with heparinized saline to purge all air from the system.
 - (e) Using a wire introducer (which looks like a long, hollow, flat-tipped needle) the chosen microwire tip on a shapeable wire may be shaped by gently pulling the distal 5–10 mm of the wire across the shaft of the

- introducer to curve the wire. The more firmly the wire is pulled across the introducer, the sharper the curve on the wire will be.
- (f) The shaped wire is then inserted in the introducer, the introducer is inserted through the RHV down to the hub of the microcatheter, and the microwire is carefully inserted into the microcatheter.
 - (g) If a very tight curve, such as a J-shaped tip is desired, some difficulty may be encountered when trying to insert it into the wire introducer. It may be easier to first insert the microwire all the way into the microcatheter, extend the tip of the wire beyond the tip of the microcatheter, shape the wire, then pull it back to the tip of the microcatheter.
 - (h) Alternatively, one can insert the wire into the introducer, then, with the tip of the wire extending out beyond the tip of the introducer, use a second introducer to shape the tip. The wire is then pulled back such that its tip is just inside the introducer, the wire/introducer assembly is inserted through the RHV and the wire can then be inserted into the microcatheter.
 - (i) Once the microwire is well in the microcatheter, the wire-introducer can be pulled out of the RHV and removed from the wire.
 - (j) The RHV on the microcatheter is tightened slightly to ensure easy passage of wire in (or out) of the microcatheter, but without leakage of saline back out of the valve. This will ensure that the lumen of the microcatheter is perfused with heparinized saline without any back-up of blood into the microcatheter.
 - (k) Once the microwire is inserted to the tip of the microcatheter, a torque device is attached to the microwire, and all connections and infusions are checked, the assembly is ready to be advanced into the RHV of the guide catheter.
6. Over-the-wire microcatheter placement technique.
 These systems are by far the most commonly used for delivery of most embolic agents, for many different pathological conditions. The smaller "10-size" microcatheters are fairly flexible, although not as flexible as flow-directed microcatheters. Larger "14-size" are stiffer, and the "18-size" systems are extremely stiff, but have a much larger lumen. The over-the-wire microcatheter is most appropriate for relatively proximal intracranial catheterizations and where large particles or microcoils are the embolic agent of choice. If Onyx[®] (ev3, Irvine, CA) is contemplated as an embolic agent in the case, a DMSO-compatible microcatheter must be used.
- (a) Virtually all over-the-wire microcatheters have hydrophilic coating and come packaged in a plastic hoop that can be flushed with sterile heparinized saline to hydrate the coating.
 - (b) Attach an RHV and gently but thoroughly flush the system to purge all air.
 - (c) Using a wire introducer, carefully insert a suitable microwire (usually 0.014 in.) through the RHV and into the microcatheter to its distal tip. The authors use the 0.014-in. Synchron[™] Soft wire (Boston Scientific, Natick, MA) for most cases.
 - (d) An appropriate curve on the microwire, usually a 90° curve or slightly J-shaped curve, allows selection of desired branches.
 - (e) A torque device must be attached to the proximal end of the microwire. This allows torqueing of the wire to rotate the distal curved tip. It also allows controlled advancement and withdrawal of the wire.
 - (f) Carefully insert the microcatheter into the RHV of the guide catheter and advance it to the distal tip of the guidecatheter. Both the Echelon[™] and Rebar[®] (ev3, Irvine, CA) have a marker on the shaft of the catheter that indicates that the tip is approaching the tip of a 90-cm guide catheter, to limit the need for fluoroscopy.
 - (g) Under-roadmap guidance, carefully advance the microwire into the vascular system, and follow with the microcatheter.
 - (h) In straight segments of the vessel, the catheter tip can be advanced beyond the wire, which limits the risk of vessel damage or perforation.
 - (i) Around sharp turns or where the vessel branches, the microwire is carefully guided around the curve by rotating the wire.
 - (j) Fixing the microwire in space, the microcatheter can be advanced over the wire and around turns.
 - (k) To break the friction between microcatheter and microwire, the wire can be gently pulled back and/or rotated.

- (l) The guide catheter position should be monitored periodically during microcatheter positioning, since any resistance to forward motion of the microcatheter will inevitably create back-pressure on the guide catheter.
 - (m) Periodically during catheter positioning, and certainly once the desired catheter position is reached, gently pull back slightly on the microcatheter to remove any redundancy.
 - (n) Also periodically check that the heparinized saline flush lines attached to the guide catheter and microcatheter are dripping and bubble-free.
 - (o) When the microcatheter reaches the desired location, carefully remove the wire and observe the tip of the microcatheter fluoroscopically, since moving the wire can often release stored energy in the microcatheter, causing it to move (usually forward).
 - (p) Gently inject a small amount of contrast through the microcatheter to confirm catheter positioning, and also to confirm patency of the microcatheter. Too much resistance during injection could indicate kinking of the microcatheter. This kinking should be resolved by pulling back on the catheter before proceeding further. Injection of contrast or embolic material in a kinked catheter can result in catheter rupture, which can be a disaster.
 - (q) When all slack is removed, perform a high-resolution superselective arteriogram.
 - (r) Carefully evaluate the superselective arteriogram to determine:
 - that the desired position has been reached.
 - that there are no normal brain vessels filling.
 - the flow-rate in order to choose an embolic agent and the injection rate needed.
 - that there is no sign of contrast exiting the microcatheter proximal to the distal tip. This would indicate that the microcatheter has been irreparably damaged or even ruptured and must not be used for embolization.
 - (s) Once the microcatheter is in position, and confirmed by superselective arteriography provocative testing may be performed if necessary (see below). Otherwise, the embolization phase may begin (also see below).
7. Flow-directed microcatheter placement technique
- These systems are most commonly used for liquid embolic delivery, usually in the setting of an AVM or AVF. The high flow state in these conditions greatly facilitates rapid and accurate placement of the microcatheter to the desired position. If Onyx[®] (ev3, Irvine, CA) is to be used as an embolic agent in the case, a DMSO-compatible microcatheter must be used.
- (a) Most flow-directed catheters are packaged with a long mandrel that can be used to stiffen the catheter and allow insertion through the RHV into the guide catheter. *Never* advance the mandrel beyond the tip of the microcatheter or use it like a guidewire in the vascular system. The mandrel is not soft enough for intravascular use.
 - (b) Since the flow-directed catheter can be advanced more effectively using a guidewire, the authors usually use the guidewire instead of the mandrel to facilitate advancement through the RHV.
 - (c) Flush the plastic hoop in which the microcatheter is packaged to hydrate the hydrophilic coating.
 - (d) Remove the catheter from the hoop and immerse the catheter in a large bowl of sterile, heparinized saline.
 - (e) If packaged with a mandrel, gently remove the mandrel from the microcatheter. Having the microcatheter immersed in saline prevents aspirating air into the catheter as the mandrel is withdrawn.
 - (f) Attach an RHV and gently but thoroughly flush the system to purge all air.
 - (g) Using a wire introducer, carefully insert a microwire (0.010 in. or smaller) through the RHV and into the microcatheter to its distal tip. The authors use the 0.008-in. Mirage[™] (ev3, Irvine, CA).
 - (h) Carefully insert the microcatheter into the RHV of the guide catheter and advance it to the distal tip of the guidecatheter. Both the Marathon[™] and Ultraflow[™] (ev3, Irvine, CA) have a marker on the shaft of the catheter that indicates that the tip is approaching the tip of a 90-cm guide catheter, to limit the need for fluoroscopy.
 - (i) Under-roadmap guidance, advance the flow-directed microcatheter into the vascular system. Note that the tips of most flow-directed microcath-

eters are quite small and tend to move very quickly, so good fluoroscopic imaging equipment and a watchful eye are needed to keep the tip in view.

- (j) Let the blood flow carry the tip forward, and advance the catheter forward at a rate fast enough to keep the catheter moving, but not so fast that redundant loops form in the neck. It is helpful to have one plane of a biplane roadmap system include the tip of the guide catheter to ensure that the microcatheter does not loop in the neck or displaces the guide catheter.
- (k) For the most part, keep the microwire within the microcatheter, and do not advance it beyond the tip. Remember that it is much more likely that a vessel could be damaged or perforated with a wire than with a soft catheter.
- (l) A curve on the wire can be rotated within the microcatheter to redirect the tip of the catheter.
- (m) If the tip does not advance as the microcatheter shaft is advanced at the groin, sometimes pulling the wire back gently will cause the tip to advance.
- (n) Only in rare situations when a very sharp angle must be negotiated, the microwire may need to be *cautiously* advanced beyond the tip of a flow-directed microcatheter and torqued into a sharp curve or sharply angulated side-branch.
- (o) Note that there can be considerable friction between the soft microcatheter and the wire, especially with the Magic[®] microcatheters (AIT-Balt, Miami, FL). This can cause the wire to jump forward if advanced too vigorously or cause the catheter to “accordion” and crumple on itself as the wire is pulled back. These problems can be minimized by gently rotating the wire or moving it in and out slightly to break the friction.
- (p) Also note that the wire cannot be safely advanced beyond the tip of the Magic[®] 1.2 microcatheter (AIT-Balt, Miami, FL), since the distal lumen is only 0.008 in.
- (q) Another technique that can be used to facilitate catheter advancement is to remove the wire, and gently puff saline or contrast through the microcatheter. This causes the tip of the microcatheter to move proximally a millimeter or two and allow flow to carry the tip in a different direction.
- (r) Steam-shaping a 45° curve on the microcatheter can also assist keeping the tip in the center of the vessel and making the desired turn.
- (s) Another solution to the problem of insufficient flow-direction is to switch microcatheters. The Ultraflow[™] (ev3, Irvine, CA) is more flow directed than the Marathon[™] (ev3, Irvine, CA) and the Magic[®] Standard microcatheter (AIT-Balt, Miami, FL) is far more flow directed than either ev3 catheter. In the line-up of Magic[®] microcatheters, the “Olive” version has a widened tip and is carried more by the flow. The very floppy Magic[®] 1.2 microcatheter is extremely flow directed, and can even be obtained in an “Olive” version as well.
- (t) In theory, if one cannot negotiate a sharp turn into a branch from a larger vessel, a balloon catheter such as the Hyperglide[™] (ev3, Irvine, CA) into the main vessel beyond the branch, is temporarily inflated to occlude flow distally and allow the flow to carry the flow directed microcatheter into the desired side-branch. This greatly adds to the complexity of the case and, in practice, the presence of another intravascular catheter can add friction and impair the flow-directional capabilities of the microcatheter. Therefore this method is not recommended except in very unusual circumstances where no other options are available.
- (u) Periodically during catheter positioning, and certainly once the desired catheter position is reached, gently pull back slightly on the microcatheter to remove any redundancy.
- (v) Gently inject a small amount of contrast through the microcatheter to confirm catheter positioning, and also to confirm patency of the microcatheter. Too much resistance during injection could indicate kinking of the microcatheter. This kinking should be resolved by pulling back on the catheter before proceeding further. Injection of contrast or embolic material in a kinked catheter can result in catheter rupture, which can be a disaster.

- (w) When all slack is removed, perform a high-resolution superselective arteriogram.
 - (x) Carefully evaluate the superselective arteriogram to determine:
 - that the desired position has been reached.
 - that there are no normal brain vessels filling.
 - the flow-rate in order to choose an embolic agent and the injection rate needed.
 - that there is no sign of contrast exiting the microcatheter proximal to the distal tip. This would indicate that the microcatheter has been irreparably damaged or even ruptured and must not be used for embolization.
 - (y) Once the microcatheter is in position, and confirmed by superselective arteriography provocative testing may be performed if necessary (see below). Otherwise, the embolization phase may begin (also see below).
8. Steerable microcatheter positioning.
- These microcatheters are most appropriate for coil embolization. Their positioning technique is very similar to over-the-wire technique, with a number of idiosyncrasies, given the special steerable characteristics of the catheter. The Pivot™ (Boston Scientific, Natick, MA) is a radically different microcatheter, although its availability is somewhat limited at the time of this writing. It is virtually the only true steerable microcatheter available. This device is constructed of a micro-machined metal hypotube, which allows one-to-one torque control. The micro-machining produces a variable degree of stiffness along the length of the microcatheter, with almost imperceptible transitions between the various segments. This makes this a very stable catheter. The Courier® Enzo™ (Micrus Endovascular, San Jose, CA), on the other hand, is a microcatheter whose tip can deflect up to 90° in each of two planes directed 180° apart. It is not actually steerable, so is not discussed in detail, but the tip deflection capability can be used to point the catheter in the desired direction, assuming it deflects in the desired plane.
- (a) A curve must be steam-shaped on the Pivot™ as appropriate for the particular application. One can only steam-shape the most distal 1.5 cm of the microcatheter. The shaping mandrel that comes with the catheter is inserted in the catheter tip, and the catheter should be bent to an angle greater than the degree of the angle desired. Steaming the catheter tip for 10 s is sufficient. After removing the mandrel, the curve will straighten somewhat.
 - (b) The catheter comes in pre-shaped tips. If available in the shape needed, these may be better, since they keep their shape better than steam-shaped curves.
 - (c) Attach an RHV with attached heparinized saline flush to the hub of the microcatheter.
 - (d) Preload an appropriate guidewire into the microcatheter, such as a 0.014 in. Transend™ or Synchro™ wire (Boston Scientific, Natick, MA)
 - (e) Use the available peel-away introducer to allow easy introduction of the microcatheter through the rotating hemostatic valve of the guiding catheter.
 - (f) Use a fairly robust guiding catheter that is placed as high as safely possible in the cervical carotid or vertebral artery. This protects the vessel as much as possible from the irritation caused by the rotation of the microcatheter. Consider using the Neuron™ (Penumbra, San Leandro, CA) which can be placed very distally.
 - (g) The tip of the guiding catheter must be kept in full roadmap field of view. The Pivot™ will act to push the guiding catheter back as it is advanced.
 - (h) Carefully advance the microcatheter under roadmap guidance over the guidewire. When encountering a sharp turn in the vessel, the catheter can be gently rotated as it is advanced, to make the turn.
 - (i) When rotating the microcatheter, it is most efficient to hold the flange at the microcatheter hub. Ensure that any slack in the microcatheter or guiding catheter is removed and that the rotating hemostatic valve on the guiding catheter is not too tight, since any of these factors can limit the transmission of torque to the tip of the microcatheter.
 - (j) If the microcatheter tip is not moving forward as expected, rotate it slightly, and it may move forward again.
 - (k) Beware that the microcatheter can jump forward abruptly as it is being rotated, especially if it has been pushed forward with little response at the tip. All that pushing has stored energy into the system and it releases quickly when the catheter is rotated.

- (l) If the microcatheter will not advance and the guiding catheter pushes back, pull back on the microcatheter to release tension, and try again, using various combinations of forward pushing and rotating of the microcatheter, as well as gentle rotation of the guidewire.
 - (m) The stiffness of the microcatheter can straighten small, sharply curved vessels, so this system may not be appropriate for very distal catheterization of small vessels.
 - (n) When nearing the target, slow down, remove slack in the microcatheter and wire, and make smaller forward pushing and rotating movements, to avoid overshooting the target.
 - (o) These catheters tend to be extremely stable, once positioned and all slack removed.
 - (p) The Pivot™ is most suited for coil embolization, but can be used with other embolic agents such as particles or possibly nBCA glue, although it is not FDA approved for glue use.
 - (q) Do not use DMSO or Onyx® with this catheter.
9. Provocative testing (see Provocative Testing, Chap. 6) is done in an effort to confirm that the vessel being embolized does not supply eloquent neurological territory. Pharmacologic agents such as amobarbital are injected in the vessel prior to embolization and the patient is tested for new signs of neurological dysfunction. Most practitioners use this testing on awake patients, although it can be done while the patient is under general anesthesia using neurophysiological monitoring with electroencephalography (EEG), somatosensory evoked potentials (SSEP), brainstem evoked responses (BAER) and/or motor evoked potentials (MEP). It is controversial whether it adds any safety to the procedure, but provocative testing using EEG has been shown to predict some neurological complications in AVM embolizations.²⁶ SSEP has been shown to alter therapy in intracranial aneurysm treatment.²⁷ Monitoring is not free from false negatives, and the practitioner should never be lulled into a false sense of security even when testing suggests it is safe to embolize, since the pharmacological agents can go preferentially by the flow to the abnormal territory. This is especially true in high flow lesions such as AVM or AVF. The authors caution that careful attention to angiographic signs on superselective angiography may be just as sensitive as provocative testing to rule out normal territories at risk. The technique for this testing is as follows:
- (a) Once the microcatheter is in proper position and slack has been removed, provocative testing can begin.
 - (b) Remove the rotating hemostatic valve on the microcatheter, and connect a three-way stopcock to the microcatheter.
 - (c) Using a wet-to-wet connection, connect the labeled 3–5-mL amobarbital (25 mg mL⁻¹) syringe to the stopcock attached to the microcatheter.
 - (d) Hold the syringe vertical, such that any bubbles rise away from the catheter.
 - (e) In awake patients, place a sterile half-sheet over the sterile field over the patient's thorax, to prevent contamination of the field during testing.
 - (f) Inject the amobarbital (usually 30–50 mg, depending on the vessel size and flow-rate) over approximately 5 s into the vessel via the microcatheter.
 - (g) Immediately disconnect the labeled amobarbital syringe, attach a 3-mL syringe and flush with several milliliters of heparinized saline to remove any amobarbital left in the catheter.
 - (h) Ask the patient if he or she feels anything abnormal, then do a brief neurological examination, paying particular attention to functions at risk from the vascular territory being tested.
 - (i) If the patient shows a new deficit, the testing is considered abnormal, and the vessel should not be embolized from that catheter position.
 - (j) In patients under anesthesia, when the barbiturate is injected, adjunctive testing with EEG, SSEP, BAER, and/or MEP can be done.
 - (k) If adjunctive testing changes from baseline status, then the testing is also considered abnormal, and the vessel should not be embolized from that catheter position.
 - (l) If no change on neurological testing and adjunctive testing, the testing is normal and suggests that it may be safe to embolize, or at least it is safe to proceed to test with lidocaine. Lidocaine may be more sensitive to nerve and white-matter tract supply than is amobarbital. Do not inject lidocaine if the barbiturate testing is abnormal.
 - (m) Connect a labeled 3-mL syringe of 2% cardiac lidocaine to the stopcock on the microcatheter.

- (n) Inject the lidocaine (usually 20–50 mg) over approximately 5 s into the vessel via the microcatheter.
- (o) The neurological and/or adjunctive neurophysiological testing is then repeated.
- (p) If no deficit, the testing is normal and it is safe to embolize.
- (q) If a neurological or neurophysiological deficit occurs, the testing is abnormal and the vessel should not be embolized from that catheter position.
- (r) During embolization of a vessel after negative amobarbital and lidocaine testing, a change in flow pattern or visualization or different vessels may be seen after a partial occlusion of the vessel. Consider repeating the provocative testing again before completing embolization of the feeder.²⁸

7.4.6. Syringe safety

Many of the procedures discussed in this book require the use of multiple agents in syringes on the procedure table. For example, an embolization procedure that may involve provocative testing requires syringes containing local anesthetic, saline flush, contrast, amobarbital, lidocaine, embolic material, etc. It is imperative that these syringes containing different agents are clearly differentiated, one from another. Confusing syringes with anesthetic agents or embolic materials for contrast or saline flush can lead to disastrous results. The authors use customized, labeled, colored syringes (Merit Medical, South Jordan, UT) of various sizes and designs for the various materials. Using the same type of syringe for a certain agent at all times and educating new team members to the routine will minimize confusion and avoid mistakes.

7.4.7. Embolization phase

With a microcatheter in optimal position at the site of a vascular lesion and beyond supply to normal brain, the time is ripe for occluding the vessel with an appropriate embolic agent. Ideally, this should have already been chosen, given the underlying vascular pathology, the therapeutic goal of the procedure and the chosen microcatheter system. The superselective arteriogram performed once the microcatheter is in its final position should be studied to confirm that the originally chosen embolic agent is still appropriate for the flow rate and distance to the lesion. A variety of embolic agents could be delivered through microcatheters, although some are more effective than others. The single most important principle of the selection process is for the operator to use the system with which he or she is most experienced and comfortable.

1. Selecting embolic agents.

Anything that causes a vessel to occlude can theoretically be used for intracranial embolization, but the most common and most studied types of agents are discussed.

(a) Liquid embolics

These are agents that are supplied in a liquid state and hence are easily injected through small microcatheters. Partly because of this characteristic, they are the most commonly used embolic agents used in intracranial embolization procedure.

- Cyanoacrylates. (aka “glue”)

These are acrylic agents that are in a liquid state and polymerize when they contact hydroxyl ions in blood. They are the dominant embolic agents used for intracranial embolization.²⁹ Although there is histological evidence that some recanalization may occur,³⁰ in clinical practice, glue is generally considered to produce an effectively permanent occlusion.³¹ The most common acrylic agent used in the United States is n-butyl cyanoacrylate (NBCA) Trufill[®] (Cordis Neurovascular, Miami Lakes, FL). Polymerization time can be modified by the addition of oil-based contrast agents such as Ethiodol[®] (Savage Laboratories, Melville, NY) (whose hydrophobic medium “hides” the acrylic monomer from hydroxyl ions) or glacial acetic acid (the acid binds with the hydroxyl ions).^{30,32} Longer chain monomers can slow the polymerization and alter adhesive properties.³³ Neuracryl M 2-hexyl cyanoacrylate (Prohold Technologies,

El Cajon, CA) is a promising agent, but is not yet approved by the FDA.³⁴

- Advantages: NBCA is nearly always permanently occlusive.³¹ Speed of polymerization is adjustable using Ethiodol and/or glacial acetic acid. Very visible fluoroscopically when Ethiodol or tantalum powder added. With proper technique, can be used in low or high flow states. In some cases can be “pushed” to the target lesion with dextrose solution even if microcatheter is some distance from the lesion. Can be delivered via flow-directed microcatheter.
- Disadvantages: Polymerization time dependant on multifactorial criteria, including temperature, formulation of glue plus Ethiodol®, rate of blood flow, rate of injection, etc. Liquid agent can enter dangerous anastomoses easily. Requires considerable training and experience to avoid problems. Adhesive characteristics make it possible to glue the catheter in the vessel. Polymerized glue is firmer than other agents which can increase the difficulty of the surgical excision of a lesion post-embolization.
- Precipitated polymer. (aka non-adhesive liquid embolic agent)
These agents are polymers insoluble in blood or water, dissolved in a non-aqueous solvent. When injected into the vascular system, the solvent disperses and the polymer precipitates to form a solid occlusive agent. Onyx® (ev3, Irvine, CA) is the dominant example of the precipitated polymer and is FDA approved for use in AVMs. It consists of ethylene-vinyl copolymer (aka EVAL or EVOH) dissolved in dimethyl sulfoxide (DMSO) with added tantalum powder to make it radio-opaque. It comes in several versions for AVMs: Onyx® 18 is 6% EVOH and is used for deeper penetration of the nidus, and the thicker Onyx® 34 is 8% EVOH and is used for high-flow AVF feeders. When the mixture is injected into the vascular system, the DMSO diffuses away and the EVOH precipitates into a non-adhesive, soft, spongy material. Another embolic agent that forms a stable gel when injected is calcium alginate. It appears to show promise in experimental models of AVM, but requires double lumen microcatheters to simultaneously inject the alginate and the calcium chloride reactant.³⁵
 - Advantages: Onyx® creates a soft, spongy solid precipitate easier to handle than glue during surgical excision of embolized lesions.³⁶ Less of an inflammatory response than that of glue.³⁷ Non-adhesive, so that very long, and thorough injections can be made with little fear of gluing the microcatheter in place. Less stressful for the operator than glue. Very visible on imaging. With proper technique, can be used in low-flow, or high flow lesions.
 - Disadvantages: Onyx® requires DMSO-compatible microcatheters, which are less flexible than non-compatible catheters such as the Magic®. DMSO can be quite toxic to endothelium when injected quickly. The DMSO diffuses out of the precipitated Onyx and causes the patient to smell of DMSO metabolites (rather unpleasant) for several days. Microcatheter must be positioned very close to the lesion. The ability to slowly inject the Onyx® with little fear of gluing the catheter in place can make one over-confident and occlude more than perhaps is safe.
- Sclerosing agents.
One can potentially occlude a vessel by injecting thrombotic factors like thrombin, but the occlusion would potentially be short-lived, since endogenous fibrinolytic systems could dissolve the clot and restore the flow. Sclerosing agents are liquid agents that promote thrombosis but also necrosis of the intima in an attempt to limit the chance for clot lysis and recanalization. Agents used for this purpose tend to be pharmacological agents that are readily available and are toxic in high concentrations, but relatively benign in low concentrations. This strong dependence on concentration is why sclerosing agents work best in slow flow situations like tumors, and worst in high flow conditions like AVFs. Absolute ethanol is

medical-grade ethanol that is dehydrated sufficiently to be close to 100% pure ethanol. This is very thrombogenic and very toxic at this concentration. Ethanol is the most frequently used sclerosing agent for intracranial embolization.³⁸ Even 30% ethanol mixed with particulate emboli will induce thrombosis, not as permanent as pure ethanol, but sufficient for pre-operative embolization.³⁹⁻⁴¹ Other sclerosing agents that have been reported anecdotally for intracranial embolization include 50% dextrose solution for low-flow fistula⁴² and a solution of 25-mg phenytoin per milliliter saline⁴³ for meningiomas.

- Advantages: Inexpensive and readily available. Low viscosity allows easy injection through a small microcatheter. Since the toxic effect is diminished when the agent is diluted, small amounts of reflux into a large vessel may be well tolerated. High-concentration ethanol can produce permanent occlusion.³⁸
- Disadvantages: Can cause extreme pain in awake patients if the vessels injected are near a meningeal surface. The sclerosing agent is not radio-opaque making the injection somewhat uncontrolled. The effect of occlusion occurs in a delayed fashion, so it can be difficult to determine when to stop. These agents may require excessive volumes to occlude higher flow lesions. May not work in very high flow fistulas. Larger doses of ethanol risk a rare, but reported complication of cardiovascular collapse.⁴⁴ Ethanol permeates outside the vascular system and even increases the permeability of the vessels, which can allow for extravascular contrast extravasation.⁴⁵ This permeability problem may at least partially explain 47% neurological complications and 11% mortality in a small series of brain AVMs embolized with ethanol.³⁸ The authors of this handbook do not approve of routine use of ethanol or other sclerosing agents for intracranial embolization.

(b) Particles

These are agents that are supplied in a solid state but are individually small enough to be easily injected through small microcatheters, when mixed with diluted contrast material. There are far too many particulate agents to discuss in detail, but all have similarities. All particulate agents work best in lesions with a capillary bed, namely tumors. All have a tendency to clog the microcatheter if the particles are too large or injected in too large a quantity. All require a similar technique for their use.

- Polyvinyl alcohol foam. (aka "PVA")
These are irregularly shaped particles of PVA. Examples: Contour[®] emboli (Boston Scientific, Natick, MA) or PVA Foam Embolization Particles (Cook Medical, Bloomington, IN) The particles are mixed with diluted contrast and are injected through the microcatheter.⁴⁶
 - Advantages: Inexpensive. Easy to use. If sized appropriately, can be carried by the flow to the lesion even if the microcatheter tip is very proximal to lesion.
 - Disadvantages: Although they can be mixed with contrast, the PVA particles are not radio-opaque, so it is difficult to tell where they are ending up on fluoroscopy. The occlusion produced is partly related to the thrombus forming around the particles. The vessel may re-open as the thrombus breaks down. Clumping of irregular particles can occlude the microcatheter, especially with smaller sized catheters. Particles may fragment as being injected and these fragments may produce a more distal occlusion than anticipated. Not effective for high-flow fistulae. When used for AVMs, may be associated with higher risk or hemorrhagic complications than nBCA glue.^{47, 48}
- Spherical emboli.
These particles are manufactured to have a smooth, spherical shape. Examples Spherical Contour SE[™] (Boston Scientific) or Bead Block[™] (Terumo Medical, Somerset, NJ) or Embospheres[®] (Biosphere Medical, Rockland, MA). All the three are similar in behavior, although a comparative

in vitro study showed that Bead Block™ stayed suspended in contrast better than the other products and was somewhat easier to deliver through the microcatheter.⁴⁹

- Advantages: Less likely than traditional PVA to clump and clog microcatheter or produce occlusion more proximal than desired.
- Disadvantages: Smoother particles may pass through anastomoses or go more distally than intended. May still clog the microcatheter if particles are too large or in too concentrated a mixture. Vessels occluded may still recanalize over time. Not effective for high-flow fistulae.

- Silk suture

Small segments of silk suture can be cut and loaded into a microcatheter. It is propelled into the vessel by injecting contrast or saline. Other types of suture material can be used in this fashion, but are less thrombogenic.

- Advantages: Very inexpensive and almost universally available in any medical facility. Small segments of 3-0 or 5-0 suture can even be injected through the tiny lumen of a flow-directed microcatheter. More thrombogenic than other particulate agents.
- Disadvantages: Very tedious and time consuming to cut and load individual suture fragments into microcatheter. Can clog microcatheter. May require high pressures to flush suture through microcatheter. Not effective for high-flow fistulae. Intense inflammatory response to foreign proteins in silk can often produce fevers, chill, and pain after embolization.

- (c) Detachable balloons

Small balloons may be attached to a microcatheter, navigated to the desired site of occlusion, inflated to produce occlusion of the vessel, then detached from the catheter and permanently implanted. The balloons stay inflated thanks to a valve that seals once the balloon detaches. They are typically inflated with contrast to make it visible on fluoroscopy, and the integrity of the balloon and its valve are all that keeps it from deflating. However, nearly all balloons eventually leak and deflate. Polymers such as the hydrophilic 2-hydroxyethyl methacrylate (HEMA) can be used to inflate the balloon and ensure long-term stability of the occlusion.⁵⁰ At the time of this writing, the Goldvalve™ balloon (Acta Vascular, Santa Clara, CA), is available in most of the world outside of the United States, and the vendor is working on obtaining approval for the North American market.

- Advantages: Quick, predictable occlusion of large vessels. Can be flow-directed to high-flow fistulae.
- Disadvantages: Require large guiding catheters for delivery. During manipulation, balloons may prematurely detach, and embolize an undesirable territory. Smooth, deformable balloons may migrate distally to an undesired location after detachment. Balloons may rupture if over inflated or inflated against an irregular surface. Virtually all eventually leak and deflate. Valves are easily damaged during preparation, causing balloons to prematurely deflate.

- (d) Microcoils

Small, usually platinum coils that can be delivered through a microcatheter can be used for intracranial embolization. A wide variety of coils is available from many different companies. These are most commonly used for aneurysm occlusion, as discussed in Chap. 5, but can also be used for large or medium sized vessel occlusion in intracranial embolization procedures.

- Pushable coils.

These are platinum coils with thrombogenic fibers that are pushed through the microcatheter with a wire pusher. Examples include Trufill® pushable coils (Cordis Neurovascular, Miami Lakes, FL), Hilal and Tornado® Microcoils (Cook Medical, Bloomfield, IN), Fibered Platinum and Vortex® coils (Boston Scientific, Natick, MA). Small, coils such as 2 or 5-mm straight coils or 2 mm × 20 mm helical coils can also be propelled through the microcatheter and into the vessel using rapid injections of saline or contrast.

- Advantages: Inexpensive. Fibered coils tend to be fairly thrombogenic. Very well seen on fluoroscopy. When microcatheter is positioned proximal to the target lesion, small coils may be flow-directed distally by “pushing” them with injections of contrast or saline.
- Disadvantages: Fibered coils usually require at least a minimum 0.016-in. lumen microcatheter, and can clog even larger lumen microcatheters if the vessels are tortuous and the microcatheter kinks or ovalizes. These coils are not easily retrieved or repositioned, so their positioning and the eventual site of occlusion are somewhat uncontrolled. These properties make these coils much less desirable than detachable coils for intracranial embolization.
- **Injectable platinum coils.**
These mainly consisted of the Berenstein Liquid Coils® (BLC, Boston Scientific, Natick, MA), which are propelled into the vessel using rapid injections of contrast or saline. *Sadly these are no longer readily available at the time of this writing.*
 - Advantages: Smaller diameter BLC 10-coils can be deployed via flow-directed microcatheters. Platinum is very visible on imaging. Tend to tangle randomly to distribute in the space available. Can be used to form a skeleton on which to deposit glue or Onyx®.
 - Disadvantages: May be no longer available. Unless well anchored in place, may pass through fistulae or go more distally than intended in high flow states. Can take many, many coils to occlude high-flow fistulae without using a liquid embolic. Vessels occluded only with coils may still recanalize over time. Can clog the microcatheter, especially using longer length coils.
- **Detachable platinum coils.**
The prototypical version of these coils are the GDC® (Boston Scientific, Natick, MA), but similar systems include Trufill® DCS (Cordis Neurovascular, Miami Lakes, FL) ACT™ Spherical or Helipaq™ (Micrus, San Jose, CA) or Microplex™ (Microvention/Terumo Medical, Somerset, NJ), or Axiom™ (ev3, Irvine, CA). These are bare platinum coils that remain attached to its delivery wire until the operator detaches it. Normally, these are used for aneurysm therapy, but can be used to occlude vessels or fistulae. These must be deployed via 150 cm, two tip-marker over-the-wire microcatheters. They are discussed further in Chap. 5.
 - Advantages: Can position, and reposition easily, and remove the coil if a different coil appears better suited for that application. Platinum is very visible on imaging. Many variably sized and shaped coils are available.
 - Disadvantages: Expensive. Unless well anchored in place, may pass through fistulae or go more distally than intended in high flow states. Can take many, many coils to occlude high-flow fistulae. Vessels occluded may still recanalize over time. Not effective for very distal vessel occlusion. Not suitable for use in flow-directed catheters.
- **Detachable fibered coils**
These are a hybrid of the pushable fibered coil and detachable coil. Examples include the Sapphire NXT™ fibered coils (ev3, Irvine, CA) or Fibered GDC® (Boston Scientific, Natick, MA), although the availability of these may be limited.
 - Advantages: Very thrombogenic, yet with all the control of a detachable coil.
 - Disadvantages: Very stiff. May displace microcatheter from its desired position and may not deploy in tortuous vessels. Requires larger lumen microcatheters. Much more expensive than pushable coils.
- **Coated detachable coils**
These coatings were developed in an effort to promote healing and decrease the recanalization of aneurysms treated with these coils. These include, among others, the Matrix™ (Boston Scientific,

Natick, MA) and Hydrocoil® (Microvention/Terumo Medical, Aliso Viejo, CA). They are discussed further in Chap. 5.

- Advantages: Can be used wherever bare platinum coils can be used.
- Disadvantages: Expensive. May be somewhat more difficult to deploy than bare platinum coils. Although they may (or may not, the verdict is not yet out) play some role in improving the results of endovascular aneurysm treatment, they have no proven benefit over other detachable coils in other intracranial embolization procedures.

(e) Stents

Stents are most commonly used to assist with aneurysm coil embolization, as discussed in great detail in Chap. 5. These include the Neuroform™ (Boston Scientific, Natick, MA) and Enterprise™ (Cordis Neurovascular, Miami Lakes, FL) stents. In some cases of AV fistula embolization, they can also be used for preservation of the flow in large or medium sized vessels in intracranial embolization procedures. Coils can be placed in the venous side of the fistula while the stent in the artery prevents herniation of coils through the fistula into the artery. Cases of wide necked aneurysms that have ruptured into the cavernous sinus, or large post-traumatic tears in the artery are examples of situations in which it is helpful to place a stent in the parent artery in addition to using coils or other embolic agents to occlude the fistula. It is also often helpful to temporarily inflate a non-detachable balloon, like the Hyperform™ (ev3, Irvine, CA) within the stent during the placement of coils or liquid embolic agents on the venous side to provide added assurance that the coils, glue or Onyx does not find its way through the openings of the stent into the parent artery.

Standard porous intracranial stents like the Neuroform™ or Enterprise™ can sometimes channel the flow away from a side-wall aneurysm to induce thrombosis without placing coils. This spontaneous thrombosis after the stent placement would not be expected in the case of an AV fistula due to the higher flow conditions. A different type of stent that has been used to treat fistulae is the covered stent, most commonly the Jostent® (Abbott, Abbot Park, IL). This over-the-wire balloon inflatable covered stent allows rapid occlusion of a fistula without necessarily using coils. The stent is approved for repair of ruptured coronary vessels 3–5 mm in diameter.

- Neuroform™
This self-expanding hybrid open/closed design nitinol stent is packaged in a Renegade® (Boston Scientific, Natick, MA) microcatheter and can be delivered into the desired vessel using the preloaded stabilizer. This process is done over an exchange-length 0.014-in. wire placed distally via a separate microcatheter as a first step, then exchanged for the stent delivery catheter. Available in sizes from 2.5 to 4.5 mm and lengths from 1.5 to 3.0 cm.
 - Advantages: Soft and atraumatic to the vessels. Easy to traverse the stent with a microcatheter to deploy coils. MR-compatible stent material.
 - Disadvantages: Humanitarian device status means Institutional Review Board approval needed for use. Over-the-wire placement over an exchange-length wire is tedious and risks vessel injury with the wire tip during the exchange. May be difficult to deploy, especially in tortuous vessels. Long-term antiplatelet therapy post-procedure is recommended.
- Enterprise™
A self-expanding closed cell nitinol stent is advanced and deployed via a Prowler Plus™ microcatheter without the use of an exchange wire. It can be resheathed and redeployed after a partial deployment. Ends of the stent are flared. Approved for placement in arteries 3–4 mm diameter.
 - Advantages: Easy to deploy. Resheathable and redeployable. Does not require exchange technique. Flared ends mean good apposition to the vessel wall and easy microcatheter placement into the stent for coiling.

- Disadvantages: Only suitable for 3–4-mm diameter vessels. Long-term antiplatelet therapy is recommended.
 - Jostent[®]
This balloon-mounted PTFE coated stent is placed over an exchange-length 0.014-in. wire and deploys in the vessel when the balloon is inflated.
 - Advantages: Very quick occlusion of flow into an aneurysm or fistula if fully covered. Preserves parent artery.
 - Disadvantages: Stiff and difficult to navigate around sharp turns. Can traumatize vessels while navigating or inflating balloon. Not effective for very distal vessel placement. *Not FDA approved for cerebral vessels.*
2. N-BCA glue embolization technique
- (e) When a flow-directed or over-the-wire type microcatheter is in the desired position, beyond branches to normal brain, and any provocative testing has been completed and suggests that it is safe, then embolization can proceed.
 - (f) When using glue, all persons near the sterile field should wear glasses or other eye protection. If a connection comes loose during injection, the glue can spray and stick to whatever it touches.
 - (g) Double-check the superselective arteriogram performed at that catheter position, and check how long the contrast takes to reach the lesion.
 - (h) As a rule of thumb, if that time is under one second, at least a 70% glue mixture (three parts nBCA to one part Ethiodol[®]) is required. Over 2s requires a 50% (one nBCA to one Ethiodol) or more dilute mixture.
 - (i) Tantalum powder greatly increases the radio-opacity of glue, but is not absolutely necessary unless the glue mixture is greater than 70% n-BCA. Tantalum is messy and can clump, so most practitioners rarely use it.
 - (j) Draw up the Trufill[®] n-BCA (Cordis Neurovascular, Miami Lakes, FL) from its tube using a labeled, glue-compatible 3-mL syringe (avoid polycarbonate plastic...it softens).
 - (k) Draw up the Ethiodol[®] in a labeled syringe, and add the proper volume to the glue syringe to achieve the desired concentration.
 - (l) Have several labeled 3-mL syringes filled with 5% dextrose solution ready.
 - (m) Carefully pull back slightly on the microcatheter to remove any slack, and slightly loosen the rotating hemostatic valve so that it just barely prevents back-flow of blood in the guiding catheter, without binding the microcatheter too tightly.
 - (n) Re-confirm proper catheter positioning with a contrast injection via the microcatheter for a superselective arteriogram. Select a projection that shows the microcatheter tip and its relationship to any curves in the arterial feeder distal to the catheter tip, any normal branches proximal to it, and the lesion.
 - (o) Study the superselective arteriogram carefully to time the arteriovenous transit, and to determine the morphology of the target arterial feeder and nidus structure where the liquid agent will be injected.
 - (p) Attach a glue-compatible stopcock directly to the microcatheter. Cook Medical (Bloomington, IN) makes a high-pressure, white nylon plastic one, and three-way stopcocks with Luer lock fittings that hold up well during glue injections.
 - (q) One way stopcocks are sufficient, but three way are preferred since they allow a flush syringe of dextrose to remain attached even when the glue syringe is attached. This works well for doing the push technique (see below).
 - (r) Thoroughly flush the microcatheter with 5% dextrose solution. Generally, approximately 5–10 mL is sufficient to clear all saline and/or blood from the microcatheter lumen.
 - (s) As the last milliliter of dextrose is being injected, close the stopcock to prevent blood backflow into the microcatheter.
 - (t) Holding the stopcock upright, fill the Luer-lock connection fully with dextrose.
 - (u) Create a blank roadmap mask, the glue injection can be well visualized under digital subtraction.
 - (v) Attach a 3-mL syringe loaded with the prepared glue mixture.

- (w) For continuous column technique, slowly, but steadily inject the glue using roadmap imaging, such that the glue column is continuously moving forward.
- (x) Fill the arterial feeder and as much of the nidus as possible.
- (y) Be alert for any signs of reflux of glue back along the catheter, passage of glue into the vein, or reflux of glue from the nidus into other arterial branches feeding the lesion.
- (z) If any of these conditions is occurring and one is using dilute glue, one might be able to briefly pause the injection, then resume cautiously. Sometimes the glue will find another pathway through the nidus.
- (aa) The glue injection is relatively quick, but controlled. Polymerization usually occurs within a few seconds.
- (bb) The embolic agent should be deposited in the “safety zone” consisting of AVM nidus and only the artery beyond all normal branches, and vein before other venous inputs beyond the occluded nidus. (See Fig. 7.1)
- (cc) If there is any question that the glue is refluxing or going somewhere it shouldn't, or if finished filling the desired space with glue, stop injecting, aspirate the syringe to create negative pressure in the microcatheter, and quickly, smoothly withdraw the microcatheter completely from the patient and discard it. It is best to pull the guiding catheter and microcatheter as a unit, but, sometimes, using braided microcatheters, one can remove it by just pulling the microcatheter.
- (dd) Examine the rotating hemostatic valve of the guiding catheter for any retained droplets of glue, then aspirate and double flush the stopcock, rotating hemostatic valve, and guide-catheter.
- (ee) Once the guide catheter is thoroughly inspected and flushed, re-insert it to the arterial territory of interest, and perform a follow-up arteriogram to ensure that the desired result is obtained.
- (ff) The wedged technique is similar to the full-column technique, except that the microcatheter tip is wedged in the nidus or small vessel and much more dilute glue can be used.
- (gg) In wedged position, very slow, prolonged injections with dilute glue (less than 30% glue) can be done over several minutes (which seems like hours).
- (hh) When glue begins to enter the vein, or to reflux along the microcatheter, one should stop injecting, wait a minute for polymerization, aspirate back from the glue syringe, then pull the catheter out.

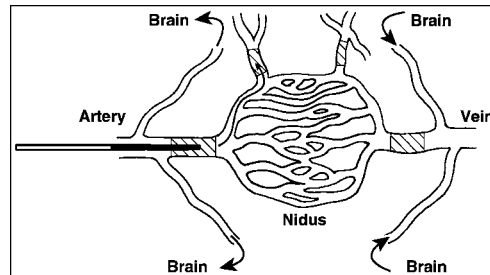


Fig. 7.1 Safety zones for AVM embolization.

The artery feeding the AVM may be occluded distal to all normal vessels feeding the brain. Hatch marks indicate the safe zone in the artery. Occlusion proximal to that can cause an ischemic stroke. The nidus is all safe to occlude, since it supplies no normal structures. The vein beyond the nidus may be occluded before any inputs from normal brain veins or even veins supplying other segments of the AVM. Hatch marks indicate the safe zone in the vein. Occlusion down-stream from that risks hemorrhage from remaining nidus or venous infarction of brain.

- (ii) Using the push technique, the microcatheter is generally some distance proximal to the lesion, but still beyond normal brain vessels.
- (jj) When ready to embolize, the microcatheter is flushed with dextrose solution.
- (kk) A three way stopcock is attached to the hub of the microcatheter, and a syringe of 5% dextrose flush is attached to one connection, and the appropriately mixed glue to another.
- (ll) Depending on the size of the vessel being embolized, 0.1–0.2 mL of glue mixture is injected into the microcatheter, the stopcock is turned and, under roadmap visualization, the glue is flushed into the vessel using the dextrose flush syringe.
- (mm) Generally, it is advisable to pull the microcatheter at this point. The exception would be when the glue bolus travels quite distal to the tip of the microcatheter, and if contrast injections via the guide catheter confirm persistent patency of the feeding vessel being embolized. A second glue bolus may be injected and pushed with dextrose as long as the microcatheter remains patent.
- (nn) The dribble technique is similar to the full column technique, except that the glue is injected very, very slowly, to allow the blood flow to fragment the glue and form small particles. These tend to travel along with the blood flow until they impact on a small nidus or capillary bed.
- (oo) Glue embolization techniques are illustrated in Fig. 7.2.

Special situation: High concentration (aka “pure glue”) nBCA embolization:

- Occasionally required for very high flow fistulae.
- It is akin to holding a burning object in one’s bare hands: It is possible to get burned.
- Everything must be done quickly and there is a real risk of refluxing glue into proximal vessels and/or gluing the microcatheter in place.
- If the mixture is less than 30% Ethiodol then tantalum powder must be added to the nBCA to make it visible fluoroscopically.
- In extreme high flow states, when using little or no Ethiodol, the pure glue may instantly polymerize in the microcatheter.
- Consider putting the glue on ice or in a freezer until immediately before use or gently flushing the microcatheter with 50% dextrose to slow the polymerization just enough to prevent clogging the microcatheter.
- Only a 0.1– to 0.3- mL bolus of glue is loaded into the dextrose-flushed microcatheter and pushed into the vessel with a quick injection of dextrose. *No hesitation.*
- *Immediately pull the microcatheter.* It is best to have at least 2 two people involved: one to inject and the other to pull the guide-catheter/microcatheter assembly as a unit. *No hesitation.*
- Now is the time to change one’s underwear and prepare to do a control angiogram to see what was accomplished.

Methods to slow down glue polymerization:

- Most common method: Adding Ethiodol.
- Adding minute amounts of glacial acetic acid.³² Twenty microliters affects polymerization more profoundly than several ml. of added Ethiodol⁵¹ and does not increase the viscosity of the mixture like the oily Ethiodol does.⁵²
- Cooling the glue also slows polymerization, but glue can warm rapidly under ambient room temperature
- Injecting 5% dextrose solution via the guiding catheter can flood the local circulation with inhibitory dextrose during the nBCA injection.⁵³

3. Onyx[®] embolization technique

- (a) Have several vials of Onyx[®] (ev3, Irvine, CA) agitating in an automatic mixer for at least 30 min while performing other parts of the procedure.
- (b) This transarterial technique is similar to the technique using n-BCA glue regarding the catheterization of the arterial feeder, except one must use a dimethyl sulfoxide (DMSO)-compatible catheter such as the over-the-wire type Rebar[®] (ev3, Irvine, CA) or more flexible Marathon[™] (ev3, Irvine, CA).

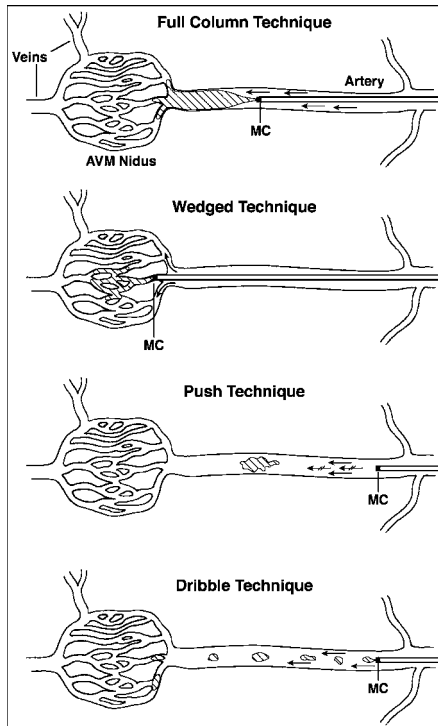


Fig. 7.2 Four techniques for AVM glue embolization.

- Full column technique**
 The microcatheter tip (MC) is close to the lesion and beyond all normal arteries. Glue (shaded) is steadily injected as a continuous column, filling the vessel lumen. If the glue polymerization time and injection rate are properly controlled, it will reach the nidus before polymerizing. The injection is stopped if the glue reaches the vein or begins to reflux back to the microcatheter tip. Arrows indicate blood flow.
- Wedged technique**
 A microcatheter is gently flow directed into a vascular channel in the nidus no bigger than the catheter tip, effectively blocking the blood flow beyond the tip. A dilute glue mixture (shaded) is then slowly injected, filling the nidus. The slowly polymerizing mixture does not get washed into the veins by the flowing blood because the wedged catheter controls the flow.
- Push technique**
 The microcatheter tip is some distance to the lesion, and a small bolus (0.1 mL) of glue (shaded) is propelled into the vessel with a bolus of 5% dextrose solution. Blood flow (arrows) plus momentum from the dextrose bolus (hatched arrows) carries the glue toward the lesion until it polymerizes. This technique is the safest way to inject high concentration (ultra-fast polymerizing) glue mixtures without gluing the microcatheter in place.
- Dribble technique**
 This can be used with the microcatheter tip somewhat proximal to a relatively low-flow lesion that has a capillary bed or nidus with small channels. A full column of relatively dilute glue (shaded) is very, very slowly injected so that the blood flow fragments the glue as it exits the microcatheter. The small drops of glue are then carried by the blood flow (arrows) into the nidus, where they wedge into the small spaces. This is usually used for preoperative tumor or small AVM embolization.

- (c) Note that provocative testing can give a false sense of security since Onyx[®] can easily find its way into places that may not be predicted by superselective angiography or barbiturate injections.
- (d) Confirm proper catheter positioning with a contrast injection via the microcatheter for a superselective arteriogram. Select a projection that shows the microcatheter tip and its relationship to any curves in the arterial feeder distal to the catheter tip, any normal branches proximal to it, and whether the tip is wedged.
- (e) Study the superselective arteriogram carefully to measure the arteriovenous transit time, and to determine the morphology of the target arterial feeder and venous structure where you will deposit the Onyx[®].
- (f) Select a pre-mixed viscosity of the agent depending on the size of the feeder and degree of arteriovenous shunting. Big feeders with fast flow need Onyx[®] 34 and small feeders or slower shunting should be treated with Onyx[®] 18.
- (g) Using the proper syringe supplied by ev3, draw up 1 mL of DMSO. The technique for handling the Onyx syringes is illustrated in Fig. 7.3.
- (h) Using a blank roadmap mask, slowly inject the Onyx[®] under roadmap visualization at a rate of approximately 0.16 mL min⁻¹. Rates of injection over 0.3 mL min⁻¹ risk vascular injury due to DMSO toxicity.
- (i) Continue injecting Onyx[®] as long as it is flowing forward into desired areas of the abnormal vessels.

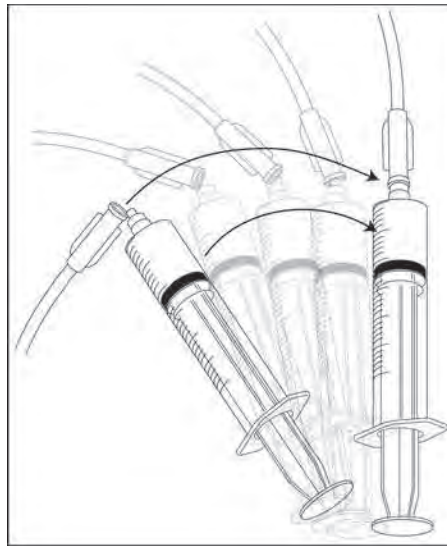


Fig. 7.3 Syringe loading technique for Onyx.

- Draw up the Onyx[®] into the syringe specified by the manufacturer. Agitate it back and forth if it will not be injected for more than a few minutes to keep the tantalum suspended.
- Attach the DMSO syringe directly to the hub of the microcatheter and fill the dead-space of the microcatheter (usually 0.2–0.3 mL) with DMSO over 1–2 min.
- Remove the DMSO syringe from the microcatheter, and, keeping the hub upright, fill the hub with DMSO.
- Holding both the catheter hub and Onyx[®] syringe at 45° to one another, quickly connect the syringe to the hub, and then keep the syringe vertical, plunger down. This keeps a sharp demarcation between the heavier Onyx[®] in the syringe, and lighter DMSO in the hub of the catheter. This will make it easier to see them radiographically than allowing the DMSO and Onyx[®] mix together.

- (j) If it refluxes along the catheter, passes into the proximal part of the vein, or refluxes into other arterial feeders, pause the injection for 15 s, then resume injecting. If the Onyx[®] continues to flow in the wrong direction, pause again for 15–30 s, then try again. If the Onyx[®] finds another, more desirable pathway, continue the slow injection.
 - (k) It is often desirable to obtain a new mask for roadmap periodically. This subtracts out the already deposited embolic agent and makes the newly injected material easier to see.
 - (l) If uncertain whether the injection is achieving the desired result, a contrast injection can be done via the guide catheter for a control angiogram. This will show if there is still portions of the feeding artery or nidus that should be occluded from this catheter position.
 - (m) The Onyx[®] injection should be done patiently and may take several minutes.
 - (n) Some reflux back along the catheter tip is not a problem, due to the non-adhesive nature of the product. Avoid more than 1 cm of reflux, however, since even Onyx[®] may glue a microcatheter into the vessel.
 - (o) Do not pause the injection for more than 2 min, for the Onyx[®] may solidify and clog the microcatheter.
 - (p) Never try to inject against resistance. A clogged microcatheter may burst if the injection continues.
 - (q) When adequate filling of the desired vascular spaces is achieved, or if the Onyx[®] repeatedly flows in the wrong direction, stop injecting, aspirate back on the syringe, and slowly, but steadily pull back on the microcatheter, disengage it from the deposited Onyx[®] and remove it. The heavy-duty catheters used for Onyx[®] can usually be pulled back on their own, without pulling the guide catheter as well.
 - (r) After the microcatheter is withdrawn from the guide catheter, examine the rotating hemostatic valve of the guiding catheter for any retained droplets of Onyx[®], then aspirate and double flush the stopcock, rotating hemostatic valve, and guide-catheter.
 - (s) Once the guide catheter is thoroughly inspected and flushed, perform a follow-up arteriogram to ensure that the desired result has been obtained.
4. Ethanol embolization technique
- (a) Although not recommended routinely for intracranial embolization, there may be rare situations in which nothing else is available.
 - (b) Some recommend prophylactic placement of a Swan-Ganz catheter for AVM embolizations with ethanol, to watch for signs of pulmonary hypertension.
 - (c) When added to mixtures of particles, the technique is essentially the same as standard particulate embolization (see below).
 - (d) When used without added particles, the technique is more like the technique for glue.
 - (e) Be sure to check that the syringes, stopcocks and microcatheter hubs will not degrade when exposed to ethanol. Often, those that can be used with glue or DMSO will withstand ethanol, but it is wise to test it first. Since it is not an FDA approved indication, manufacturers will likely state that their products are not approved for use with ethanol.
 - (f) Microcatheter positioning, and confirmation with superselective angiography and provocative testing is the same as for nBCA glue use.
 - (g) When ready to embolize, perform test injections of contrast through the microcatheter to estimate the rate and volume required to opacify the territory that is to be occluded.
 - (h) If the flow is very rapid, consider placing a coil or two to slow the flow.
 - (i) Flush the microcatheter with saline, since ethanol can cause contrast to precipitate.
 - (j) Inject the absolute ethanol at a rate similar to that which opacified the vessel, but use only approximately 50% of the volume of contrast used.
 - (k) Wait a few minutes, then repeat the contrast injection. If the vessel remains patent, inject another small bolus of ethanol, and wait again.
 - (l) If spasm is seen on repeat test injections, wait until it resolves and decrease the volume of ethanol boluses.
 - (m) After a few boluses have been given, wait at least 5–10 min between ethanol injections before checking for patency of the vessel.

- (n) If there is no change after 20 mL of ethanol, consider placement of additional coils to slow the flow and help the ethanol work, or try a better embolic agent.
 - (o) Remember that ethanol can work on the endothelium for some time and can also spread through the vessel wall into the tissues, so it is best to keep the ethanol volumes to a minimum.
5. Particulate embolization technique
- (a) Most all particles are used in a similar fashion for intracranial embolization.
 - (b) To avoid major problems with particles clogging the microcatheter, use one of the larger lumen over-the-wire types of microcatheters.
 - (c) The microcatheter tip must be close to the lesion being embolized, in a stable position distal to normal branches.
 - (d) Safe positioning is confirmed with a superselective angiogram via the microcatheter, possibly also using pharmacological provocative testing as necessary.
 - (e) Choose a particle size depending on the size of the vessels in the target lesion. In general, tumors with a capillary bed are treated with particles less than 300 μm in diameter, and AVMs require particles over 300 μm .
 - (f) Mix the particles with dilute contrast and draw up the emboli in a labeled 10-mL syringe. This acts as a reservoir for emboli.
 - (g) The particles should be fairly dilute to limit the risk of clogging the microcatheter.
 - (h) Attach the syringe to one female connection on a high-pressure three-way stopcock and attach a labeled 3-mL luer-lock syringe to the other female connection. This syringe is used to inject the embolic mixture through the microcatheter.
 - (i) The stopcock is then attached to the hub of the microcatheter.
 - (j) The stopcock is turned to connect the 10- and 3-mL syringes, and the contrast/emboli mixture is flushed into the 3-mL syringe and then back into the 10-mL syringe, back and forth several times, to ensure uniform suspension of particles.
 - (k) The 3-mL syringe is then filled with 1–2 mL of the emboli suspension.
 - (l) Obtain a blank roadmap in order to have subtracted fluoro.
 - (m) Under fluoroscopic guidance, slowly inject the emboli in small (0.2 mL) increments and ensure that the contrast freely flows from the microcatheter tip.
 - (n) Increase or decrease the rate of injection, depending on the speed of runoff away from the microcatheter.
 - (o) Every 3–5 mL of embolic suspension, or sooner if emboli are seen to collect in the hub of the microcatheter, disconnect the 3-mL syringe and reconnect another labeled 3-mL syringe filled with dilute 50:50 contrast.
 - (p) Gently flush the microcatheter with the contrast under fluoroscopy, remembering that the microcatheter is still full of emboli.
 - (q) As long as a good runoff of contrast is seen, reconnect the 3-mL emboli syringe, refill it with embolic mixture, and continue to inject emboli.
 - (r) When the 10-mL syringe is empty, consider obtaining a control superselective angiogram via the microcatheter to see whether the flow pattern is changing.
 - (s) Especially with AVMs it may require some time and a considerable amount of emboli to occlude a feeder.
 - (t) If an entire vial of emboli is injected with no change in the flow pattern, consider modifying the flow with a coil or two, or switching to a different embolic agent.
 - (u) Avoid creating reflux of the embolic mixture back along the microcatheter when injecting. Slow or stop the injections if reflux is seen.
 - (v) If resistance is encountered during the injections, stop, disconnect the 3-mL embolic syringe and check the hub of the microcatheter. If emboli are bunched up in the hub, it may be possible to rinse them out with a needle or guidewire introducer, then attempt to gently flush with contrast.
 - (w) If resistance remains, *do not attempt to force the emboli through by a forceful injection, and do not use a 1-mL syringe to achieve higher pressures.* Attempting to inject through a microcatheter clogged with particles can cause the microcatheter to rupture and even break into pieces. Certainly the newer, braided microcatheters are less prone to burst than are the softer, flimsier unbraided catheters, but no catheter is burst-proof if clogged.

- (x) When the flow in the feeder is significantly slowed, injections of emboli are stopped.
 - (y) If more definitive closure of the vessel is desired after particle embolization, a coil may be deposited to finish the job.
 - (z) Be certain to gently flush out the microcatheter with contrast or saline before inserting a coil. Retained particles in the microcatheter can cause the coil to bind in the microcatheter.
 - (aa) Even if the microcatheter seems free of particles, it is best to withdraw and discard the used microcatheter prior to attempting catheterization of another feeder with a new microcatheter.
6. Silk suture embolization technique.
- (a) Procure several microwire introducers. These can be used as delivery introducers for the silk suture fragments. An 18-gauge plastic intravenous catheter can also be used for this purpose.
 - (b) Open a sterile package of 4-0 silk suture.
 - (c) Insert a 5–10-mm segment of silk into the blunt, distal end of the introducer.
 - (d) Attach a 3-mL syringe of sterile saline to the luer-connector hub of the introducer and gently flush to expel air. Be careful not to flush the silk out of the introducer.
 - (e) When the microcatheter is properly positioned, check that all slack is removed and there are no kinks. These can impede the injection of silk.
 - (f) Also ensure that the RHV of the guiding catheter is just tight enough to prevent back-bleeding, but not too tight to pinch the microcatheter.
 - (g) There should be an RHV with continuous infusion of heparinized saline already attached to the microcatheter hub as well.
 - (h) When ready to embolize, insert the introducer containing the silk suture fragment through the RHV of the microcatheter and seat it with its blunt tip in the hub of the microcatheter.
 - (i) Inject the silk into the microcatheter with a small bolus of heparinized saline.
 - (j) Remove the introducer from the RHV, and tighten the valve of the RHV.
 - (k) Flush the microcatheter with heparinized saline using a 3 mL or larger syringe to flush the silk into the vessel. There will be a build up of pressure, then a release as the silk is expelled from the microcatheter.
 - (l) The position of the microcatheter should be checked fluoroscopically since the force of these injections can cause the tip to move.
 - (m) Periodic contrast injections are done via the microcatheter to check or changes in the flow.
 - (n) It may take several silk fragments to produce an effect on the flow.
 - (o) Consider using particles and/or coils in conjunction with silk to facilitate occlusion.
 - (p) Avoid using a 1-mL syringe for flushes or test injections, since it generates sufficient pressure to rupture most microcatheters.
 - (q) If the microcatheter does not flush easily, it may be clogged by the silk.
 - (r) In some cases, a clogged microcatheter may be unclogged by passing a coil pusher through it, but in most cases it must be removed and another microcatheter used to re-access the vessel to be embolized.
 - (s) The end-point for embolization may be difficult to assess, since silk induces a slow thrombosis that may unpredictably occlude the vessel, so frequent test injections of contrast should be done, to prevent refluxing emboli proximally from the occluded vessel.
8. Detachable balloon technique
- This discussion may be primarily of historic interest for practitioners in the United States until FDA approval is achieved.
- (a) Choose a balloon diameter that is slightly larger than the space intended for occlusion.
 - (b) Bench-test the balloon by inflating it with sterile water using a blunt-tip 25-gauge needle attached to a 3-mL syringe.
 - (c) Insert the needle very carefully into the valve of the balloon and inflate 0.1–0.3 mL, but to no more than the rated volume of the balloon.
 - (d) Withdraw the needle and confirm that the balloon remains inflated. If not discard it and obtain another balloon.
 - (e) Assuming the balloon can remain inflated, re-insert the blunt needle and deflate it, making sure to tilt the balloon to remove any air bubbles as the water is aspirated.

- (f) Inflate the balloon with an approximately iso-osmolar contrast solution. Visipaque™ (iodixanol) (GE Healthcare, Princeton, NJ) is a convenient choice.
- (g) Attach an RHV with a one way stopcock to an appropriate balloon delivery microcatheter. In general, the outer diameter of the tip should be less than 2 French.
- (h) Flush the RHV and microcatheter with iso-osmolar contrast.
- (i) Preload a microwire, stiff end first, into the microcatheter and advance it just to the catheter tip. The wire should be small enough such that contrast can be injected through the microcatheter around the wire.
- (j) Carefully load the prepared balloon onto the microcatheter. It may deflate somewhat as the microcatheter enters its valve.
- (k) Keeping a contrast syringe attached to the open stopcock on the RHV, slowly withdraw the wire, injecting contrast to fill the dead-space of the microcatheter.
- (l) Insert the wire, soft end first, back into the microcatheter after forming the desired curve on its tip.
- (m) Advance it to the tip of the microcatheter, but do not advance it into the balloon.
- (n) Attach a torque device to the microwire.
- (o) A very large-lumen guide catheter (or 90-cm sheath) large enough to accept the balloon and another balloon catheter should be in the brachiocephalic artery supplying the lesion to be embolized.
- (p) A two headed RHV (or 2 RHVs in tandem) is attached to the guide catheter.
- (q) The balloon-tipped microcatheter is carefully inserted into one RHV, and a second, non-detachable balloon such as a Hyperform™ (ev3, Irvine, CA) is carefully inserted in the other RHV.
- (r) Alternatively, each balloon can be inserted in a separate, smaller guide catheter inserted via a separate groin puncture.
- (s) The two balloons are carefully navigated into the vessel.
- (t) If possible, advance the detachable balloon catheter without inflation of the balloon to the desired site.
- (u) It may be possible to turn the tip of the microcatheter by rotating the wire inside it.
- (v) Avoid entering the balloon with the wire, since it may damage or prematurely detach it.
- (w) In some cases it may be necessary to inflate the balloon slightly to let the flow carry it forward.
- (x) Never pull back on a partly or fully inflated balloon: It may detach inadvertently.
- (y) The second balloon can sometimes be used to facilitate proper positioning of the detachable balloon. It can be inflated next to the detachable balloon to nudge it into a turn, or can be inflated distal to a fistula, to direct all the flow, and the detachable balloon directly to the fistula.
- (z) When the balloon is in its desired location, the second balloon should be positioned proximal to the detachable balloon and slightly inflated to control the flow.
- (aa) The detachable balloon is then fully inflated. Remember that flow tends to carry balloons forward as they are inflated. The balloon should therefore be slightly proximal to the desired position before inflation, or proximal flow should be stopped by fully inflating the proximal non-detachable balloon.
- (bb) Contrast injections via the guide catheter are done to confirm that the desired position and occlusion have been achieved.
- (cc) If not, the balloon should be deflated, moved to the desired position, then re-inflated.
- (dd) When the desired position is confirmed, one could do a test occlusion, if necessary (see Chap. 6, Provocative Testing)
- (ee) When the operator is confident that it is safe to proceed, the balloon may be detached. This is sometimes more difficult than it sounds.
- (ff) Inflate the non-detachable balloon fully just proximal to the detachable balloon. This can help stabilize it.⁵⁴
- (gg) Slowly, steadily, pull back on the microcatheter, continuously watching the inflated balloon. Silicone balloons may slide back in the vessel as

traction is put on the microcatheter if insufficiently sized for the vessel or if no proximal support balloon is used.

- (hh) The valve side of the balloon can often be seen to stretch as the microcatheter is pulled back, then relax suddenly as the valve slides off the microcatheter and the balloon detaches.
- (ii) It is generally a good idea to place a second balloon or some microcoils adjacent to the first balloon to ensure a stable occlusion if the valve leaks.

9. Pushable coil technique

- (a) Large lumen over-the-wire microcatheters must be used. In general, most 18-system fibered coils need at least a 0.017-in. diameter lumen.
- (b) When the microcatheter is properly positioned, check that all slack is removed and there are no kinks. These can impede the placement of the coil.
- (c) Also ensure that the RHV of the guiding catheter is just tight enough to prevent back-bleeding, but not too tight to pinch the microcatheter.
- (d) There should be an RHV with continuous infusion of heparinized saline already attached to the microcatheter hub as well.
- (e) Select an appropriately sized coil to fit in the vessel tightly.
- (f) For very high-flow states, or when precise coil positioning is required, consider using a detachable coil first.
- (g) When ready to embolize with the pushable coil, insert the introducer containing the coil through the RHV of the microcatheter and seat it with its blunt tip in the hub of the microcatheter.
- (h) Carefully push the coil into the microcatheter with the plunger supplied by the manufacturer. As an alternative, most coils can be injected into the microcatheter using a small bolus of heparinized saline.
- (i) Remove the introducer from the RHV, and tighten the valve of the RHV.
- (j) To flow-inject smaller (up to 10-mm long) microcoils, inject the microcatheter with heparinized saline using a 3 mL or larger syringe to flush the coil into the vessel. This can be monitored fluoroscopically.
- (k) To deposit the coil in a more controlled fashion, a coil pusher should be utilized.
- (l) Do not use a guidewire to push a coil because it may over-ride the coil, and possibly wedge it in the microcatheter.
- (m) The authors like the TruPush® (Cordis Neurovascular, Miami Lakes, FL) for 18-system coils and the Pusher 10 (Boston Scientific, Natick, MA) when a smaller, ten-system coil is used in a ten-system microcatheter.
- (n) Do not push the tip of the coil pusher beyond the tip of the microcatheter. The relatively stiff pusher can traumatize the vessel.
- (o) Place additional coils to achieve the desired occlusion.
- (p) If a coil does not pass easily through the microcatheter, there may be a sharp turn or kink in the microcatheter. Gently pulling it back slightly, or occasionally pushing it forward may relieve the obstruction.
- (q) The position of the microcatheter should be checked fluoroscopically since the placement of the coils and any catheter manipulation can displace the tip of the microcatheter.
- (r) Periodic contrast injections are done via the microcatheter to check or changes in the flow.
- (s) It may take several coils to produce an effect on the flow.
- (t) In high-flow fistulae, consider using a liquid embolic agent (glue or Onyx®) to fill spaces between coils and produce a secure occlusion

10. Detachable coil technique

- (a) Use of detachable coils is discussed in excruciating detail in the Intracranial Aneurysms Procedure Chap. 5.
- (b) These coils require the use of 150-cm long, two tip marker over-the-wire microcatheters.
- (c) As a general rule, deposit coils in the vascular structure to be occluded beginning from the area most distal to the point of endovascular access to the structure. Embolize from distal-to-proximal to avoid burning bridges, or painting oneself into a corner, or whatever metaphor works best.
- (d) Also, another general rule is to start with the biggest coil diameter and longest length first.
- (e) Especially in the case of a high-flow fistula, it is best to start with a detachable coil, oversized to the diameter of the vessel being occluded. If it does not appear stable, *do not detach it*. Remove it and try a larger diameter coil or a 3D configuration coil.

- (f) Sometimes it helps to get a loop or two in a side branch or sharp curve in the vessel to stabilize it.
 - (g) Once one coil adequately frames the vessel and is stable, detach it.
 - (h) Place additional detachable coils to further frame and fill the space. The softest possible coils work best to pack tightly into the space available.
 - (i) If the microcatheter has a large enough lumen, it may be helpful to intersperse some fibered coils to induce thrombosis. Be careful not to displace the microcatheter with the stiffer coils or jam the coils in the catheter, and use detachable fibered coils instead of pushable coils whenever possible, to improve the precision and controllability of the occlusion.
 - (j) Continue to pack coils in the venous structure to be occluded. Alternate between ultrasoft coils to fill small spaces and fibered coils to promote thrombosis.
 - (k) For a large vessel or high-flow fistula, it will take many, many coils to block the flow. Consider using a liquid embolic agent to complete the occlusion.
 - (l) Periodic arteriograms during the procedure will indicate when the flow in the treated vessel slows and finally stops.
11. Stent placement for AVF technique
- (a) Use of stents for aneurysm coiling is discussed in excruciating detail in the Intracranial Aneurysms Procedure Chap. 5.
 - (b) Prior to any stent procedure it is recommended to start clopidogril 75 mg daily for at least 3 days pre-procedure, and continue for 3–6 months post-procedure.
 - (c) The Neuroform™ or Jostent® requires the use of 300-cm long, 0.014 wires. Enterprise™ does not.
 - (d) Size the stent appropriately for the parent artery (usually a little wider than the parent artery) and for the lesion being stented (usually at least 4-mm coverage on either side of the lesion).
 - (e) As a general rule, the wire is first placed quite distal to the lesion being stented by first placement of a standard microcatheter, then, after placement of the 300-cm wire (with a J-shaped tip) the microcatheter is carefully removed, leaving the wire in place.
 - (f) Always keep the wire tip in view and ensure that it stays in a larger vessel and does not injure the vessel wall.
 - (g) Especially in the case of a high-flow fistula, it is best to have distal wire access to provide support.
 - (h) Slowly, carefully advance the stent delivery catheter (for Neuroform™ or Jostent®) over the wire, gently pulling back on the wire to make sure the tip remains in a stable position.
 - (i) Once the stent is in position, remove any slack in the wire and stent delivery catheter. *This is critical for obtaining easy and accurate deployment.*
 - (j) Perform a follow-up arteriogram by a contrast injection via the guide catheter.
 - (k) If the stent is not in proper positioning, change the position and repeat the arteriogram.
 - (l) When a good position is achieved across the neck of the lesion, the stent is ready for deployment.
 - (m) For a Neuroform™, the stent is deployed by stabilizing the inner stabilizer as the outer stent delivery catheter is pulled back, exposing the stent.
 - (n) The stent delivery catheter can then be removed, and a microcatheter navigated through the stent into the fistula. Coiling of the fistula can then proceed.
 - (o) Consider placing a nondetachable balloon in the stent for inflation as the coils are inserted. This prevents loops of coils from finding their way through the stent and into the parent artery. This is particularly important for cases in which many coils are deployed into the venous side of the fistula, totally obscuring the parent artery on fluoroscopy. It is also important if liquid embolic agents are used on the venous side to keep them from embolizing the artery.
 - (p) For a Jostent®, the stent is deployed by slowly inflating the balloon under roadmap guidance to match the size of the parent artery. Do not exceed the maximum recommended pressure.
 - (q) When it appears that the stent is opened up to the proper size, deflate the balloon and carefully disengage it from the open stent. It may be

stuck to the stent and require another inflation/deflation cycle to free it up. Be careful not to move the stent when trying to pull back on the balloon.

- (r) Once the balloon is deflated and disengaged, perform a follow-up arteriogram via the guide catheter.
- (s) If the stent is not fully apposed to the vessel wall, re-insert the balloon into the stent and attempt to dilate further. Do not exceed maximum pressure for the balloon. If necessary, the balloon could be exchanged for a new low-compliance coronary angioplasty balloon sized to the vessel diameter and no longer than the stent.
- (t) Remember that the outer diameter of the stent is more than that of the inner lumen, so the vessel will be dilated around the stent to a greater degree than expected for the size of the balloon used.
- (u) Assuming that the stent was properly sized and positioned in the first place, it should nicely fit the vessel and occlude the lesion (AVF) when fully deployed. If not, consider navigating a microcatheter from the venous side and place some coils to occlude the shunt.
- (v) If using an Enterprise, a 0.021-in. lumen microcatheter like the Prowler Plus™ is navigated over a suitable microwire into the vessel of interest and positioned with its tip approximately 1.5 cm distal to the lesion being covered. Always use roadmap guidance.
- (w) The microwire is removed, and slack removed from the microcatheter.
- (x) The stent is mounted on a delivery wire and this is advanced into the microcatheter to the tip of the microcatheter.
- (y) The microcatheter can be moved forward or backward until the stent markers are lined up at the desired position for the stent.
- (z) If there is any question as to the proper positioning, a follow-up arteriogram via the guide catheter prior to stent deployment will confirm whether the markers are appropriately positioned.
- (aa) The stent is deployed by slowly pulling back on the microcatheter as the delivery wire is stabilized to unsheath the stent.
- (bb) If it appears to be too proximal or distal, it can be resheathed, repositioned, and redeployed if not already deployed more than 70%. Do not resheath and redeploy it more than a couple of times.
- (cc) Once it is properly positioned and deployed, the stent delivery catheter can then be removed, and a microcatheter navigated through the stent into the fistula. Coiling of the fistula can then proceed.
- (dd) Again, consider the adjunctive use of a balloon during coiling and certainly with use of liquid embolic agents.

7.4.8. Postprocedure puncture site care

Once the procedure is completed, the catheters are removed. If systemic heparin was administered, obtain an ACT to see if the patient is still anticoagulated. Protamine can be given to reverse heparin, as long as the patient is not an insulin-dependant diabetic or has other contraindications. The sheath can be removed and hemostasis should be obtained by manual pressure. Alternatively, one can use a closure device. The authors of this handbook use the Perclose® ProGlide™ (Abbott Laboratories, Redwood City, CA). The patient should be kept at strict bed rest with the legs extended for at least 2h, depending on the sheath size. If a 5 French or smaller sheath was used, another option is to apply a Syvek hemostatic patch (Marine Polymer Technologies, Danvers, MA) then keep the patient at bed rest for two hours.

7.4.9. Postprocedure management

1. Complete the neurological exam.
2. Admit to the NICU with vital signs, neuro exams and groin checks Q 1h.
 - a. It is not uncommon for patients undergoing intracranial embolization procedures to have a headache the evening after the procedure. A head CT should be obtained, if the headache is significant, to exclude hemorrhage. Most headaches in this setting are presumably due to irritation

- produced by thrombosis. The greater the headaches are, the more thrombosis is produced.
3. Only patients that had stent-assisted coiling of an AVF should remain on antiplatelet therapy (clopidogril 75 mg daily for 3 months, aspirin 80 mg daily indefinitely). Other post-embolization patients are not routinely treated with antithrombotic agents.
 4. After embolization of high flow AVM or AVF it is advisable to strictly control blood pressure post procedure. Experimental evidence exists that induced hypotension during and after AVM embolization procedures reduces the risk of hemorrhagic complications.⁵⁵
 5. Most patients after intracranial embolization for tumors or AVMs may go to surgery within a day or two. Those with unruptured AVMs that are undergoing multiple staged procedures may be able to be discharged to home on post-procedure day 1.
 6. Depending on the lesion and if/when later surgery is scheduled, it is best to wait at least 7 days between stages.
 7. Routine radiographic follow-up. Patients who underwent what was felt to be definitive treatment of their lesion should have, at least 6 months; catheter angiogram and gadolinium-enhanced MRA. If the studies agree and there is no need for additional treatment, an MRA is obtained on a yearly basis indefinitely.

7.5. Tips on specific disease processes

1. Intracranial aneurysms
 - a. Covered in great detail in Chap. 5
2. Intracranial arteriovenous malformation (AVM)
 - (a) No evidence that incomplete embolization improves risk of hemorrhage.⁵⁶
 - (b) Most AVM embolization done as preoperative procedure.
 - (c) The use of any invasive treatment of unruptured AVMs is controversial and serious questions arise as to whether the benefits of treatment are justified by the risks.^{57, 58}
 - (d) AVMs that have bled should definitely be treated to complete cure, if possible.
 - (e) Low Spetzler-Martin grade AVMs can usually undergo successful surgery without embolization.
 - (f) Higher grade AVMs may benefit from pre-op embolization.
 - (g) The authors of this handbook prefer to wait at least a week after AVM rupture to prevent swelling from the hemorrhage from adding to swelling caused by embolization.
 - (h) Pre-operative embolization should target feeders difficult to access surgically. Depending on the planned surgical approach, this may include feeders from the posterior or anterior cerebral, large perforators, high flow fistulae, or associated aneurysms.
 - (i) Targeted pre-op embolization is less risky than being too aggressive and attempting the cure the AVM. One should carefully determine the goal of the embolization ahead of time and stick to the plan.
 - (j) When doing embolization prior to radiosurgery, use a permanently occlusive liquid embolic, target high risk features like intranidal aneurysms, but mainly attempt to occlude large, contiguous segments of the nidus (not just feeders) and avoid creating separate islands of residual nidus. This forces targeting a larger volume of AVM for radiation, which may reduce the effectiveness of therapy.
 - (k) For lesion considered inoperable, staged embolizations with a goal of curative embolization may be attempted, but these should be rare, given the proven effectiveness of both open surgery and radiosurgery for AVMs.
 - (l) For curative embolization the technique is similar to that for pre-radio-surgery embolization: Occlude contiguous segments of nidus with liquid embolic and avoid creating isolated islands of nidus.
 - (m) The most effective embolization is with glue or Onyx treatment. Recent reports on Onyx embolization suggest a possibly higher cure rate with this agent than other agents.^{2, 3}

- (n) Intranidal injections of dilute glue can be curative.^{4,16} The addition of large amounts of Ethiodol does not appear to affect the biological response or long-term occlusiveness of the n-BCA.⁵⁹
- (o) However, operators should use devices with which they are familiar and comfortable.

3. Intracranial arteriovenous fistula (AVF).

(a) Carotid cavernous fistula (CCF)

- Direct, high flow fistulae should be treated urgently if impending vision loss, high intraocular or intracranial pressure, or if clinical signs of venous hypertension or angiographic signs of venous reflux into cerebral cortical or brainstem veins.⁶⁰
- CCF can be treated transarterial, transvenous, or combined.
- In the past, CCF usually was treated by navigating detachable balloons across fistula and inflating on the venous side to occlude the shunt.⁶¹
- Multiple simultaneous balloons in the vessel can be helpful to guide the balloon through the fistula.^{54,62}
- Limited availability of balloons in the USA has required other techniques in most cases.
- Coil embolization has been helpful, especially in small-hole fistulae.^{63,64}
- Stent assisted coiling is often effective, but for high flow fistula may also require liquid embolic injection within the coil mass to occlude shunt.⁶⁵⁻⁶⁷
- Balloons should be placed to temporarily occlude the artery at the site of the fistula during liquid embolic injection to prevent reflux into the artery.⁶⁷
- Adding fibered coils or Hydrocoils to the coil mass sometimes speeds the occlusion as well.⁶⁸
- Transvenous occlusion is a helpful option in many cases with difficult or unsafe arterial access, especially in patients with vascular fragility syndromes.^{69,70} See Chap. 12.
- Covered stent occlusion of the fistula is a very quick, elegant solution,⁷¹ but the stents are stiff and difficult to navigate intracranially, there are regulatory issues since the device is not approved for intracranial use, and long term patency of covered stents is uncertain.
- Parent artery occlusion may be the only option in cases with severe disruption of the artery. Be sure that there is sufficient collateral flow to the occluded hemisphere. This is often obvious angiographically. A balloon test occlusion can be done if there is a question, but, if possible, should be done with the balloon distal to the occlusion, since a false positive test occlusion may occur due to a steal through the fistula. The authors of this handbook have also seen patients who initially fail a test occlusion pass at a later date as collateral flow improves.
- When performing parent artery occlusion of a fistula, it is best to first coil distal to the fistula, then pack the fistula itself, and only last occlude the vessel proximal to the occlusion. Just a proximal occlusion will ensure that the fistula remains open through collaterals from above. This was why carotid ligation resulted in frequent recurrences of the symptoms in the era before endovascular therapy. Even trapping proximal and distal to the CCF can rarely allow it to remain patent via collaterals to the cavernous carotid branches.
- After successful occlusion of a fistula, it is not unusual for symptoms of diplopia and proptosis to persist for some months since it can take time for edema and mass effect to subside, but most improve within a week.⁷²
- Some patients can transiently worsen post procedure when the cavernous sinus thromboses.
- If symptoms worsen or do not recover quickly, and there is evidence of a bruit or the patient hears pulsatile tinnitus, consider angiography to exclude persistent or recurrent fistula.

(b) Dural AVFs

- Most dural fistulae are accessed from an arterial standpoint through external carotid feeders.

- Rare intracranial feeders may supply dural fistulae, including pial collaterals from very distal anterior, middle, or posterior cerebral feeders.
 - If relatively few, these may be accessed and embolized via a transarterial route using glue embolization delivered via a flow-directed microcatheter.
 - More commonly, when there are pial contributors to dural fistulae, they are multiple and not easily accessible via an endovascular route. A more sensible alternative would be transvenous embolization (see Chap. 19) or open surgical disconnection.
 - It should be remembered that pial collaterals have not been shown to be a risk factor for hemorrhage or neurological decline, and the presence or absence of pial venous drainage is a more important indication of how aggressively to treat these lesions.
- (c) **Pial AVF's**
- True pial AVF's (not associated with AVM or dural AVF) are rare, with less than 100 cases published in the literature.⁷³
 - They may be associated with Osler-Weber-Rendu syndrome, and may be multiple.
 - Some are extremely high flow lesions, presenting with high-output cardiac failure.
 - The high-flow AVF's are a challenge for endovascular treatment, given the likelihood that any deposited embolic device might be sucked into the giant veins usually associated with these lesions.
 - When detachable balloons are available, these can be used to treat these fistulae, but often require two balloons simultaneously navigated to the fistula, and simultaneously inflated, to prevent the high flow from pulling a partially inflated balloon off its delivery microcatheter and out into the veins.
 - Balloon detachment in these large, distal fistulae is sometimes difficult, because they may slide back in the large feeding arteries as the microcatheter is pulled back.
 - Now that balloons are not readily available in the United States, high concentration glue, with, or without microcoil placement is the mainstay of endovascular therapy for pial AVF's.⁷³⁻⁷⁵
 - When successfully occluded, these patients should be closely monitored for signs of brain edema (normal perfusion breakthrough).
 - Keeping the patient slightly hypotensive for a day or two may help.
 - Another cause of post-procedure headache and neurological decline is thrombosis of large venous varices draining the fistula.⁷⁶ Steroid and heparin may help those symptoms.
- (d) **Vein of Galen malformations (see also Chapter 15, Appendix: Vein of Galen Malformations)**
- May require urgent therapy in very young patients to resolve high-output cardiac failure.
 - Primary goal of treatment is maintaining cardiac and brain function and allow for normal development by interruption of arterial inputs to the fistula. Complete angiographic cure is much less important.⁷⁷
 - Rarely, spontaneous occlusion of the fistula may occur.⁷⁸⁻⁸⁰ This is often associated with angiographic signs of slow AV shunting and venous outlet stenosis.⁷⁸ Spontaneous cure tends to have an excellent clinical outcome.⁸⁰
 - Vein of Galen malformations may occasionally present with hemorrhage, but this does not necessarily imply a poor prognosis.⁸¹
 - Transarterial glue embolization in the primary mode of treatment.⁷⁷
 - Transvenous embolization may be technically easier,⁸² but outcomes are worse. Normal brain veins may drain into the anomalous venous pouch that is the usual target of transvenous coil embolization.⁸³ As a rule, transvenous embolization should be done only to facilitate transarterial embolization either by loosely placing a coil or two to prevent the migration of transarterial embolic agents through the fistula into the veins, or by retrograde catheterization and occlusion of arterial feeders through the vein.
 - In newborns, the procedures are limited by fluid and contrast load. Keep the flush and contrast injections to a minimum.

- Anesthetic and critical care management of infants with heart failure can be challenging. Pulmonary hypertension can be helped using inhaled nitric oxide.⁸⁴
 - Use noninvasive imaging like ultrasound and MRA to get an idea of vascular anatomy to minimize the angiographic studies needed for diagnosis and treatment planning.
 - Using a 4-French pediatric catheter as a guide catheter, flow directed microcatheters can be used for intracranial navigation. In some cases, an over-the wire microcatheter can be navigated directly from the groin (or umbilical access) all the way intracranially, but that means that only one glue injection can be done without having to re-access the arterial system.
 - The highest-flow feeders should be embolized first, and each session should seek to occlude as many feeders as are safely possible, given the limitations on time under anesthesia and contrast load for the child.
 - As in any intracranial embolization, occlude the feeders distal to any normal brain branches.
 - May need to use high-concentration glue or use coils to slow the flow in the high flow feeders.
 - Stage the embolization as necessary, following the child's neurocognitive development, growth, and check periodic MRIs to rule out development of hydrocephalus or leukomalacia and atrophy. If the child does well, further embolization can wait longer than if there are signs that the venous hypertension is impairing brain development.
 - Morbidity from invasive procedures is higher in children less than 12 months, so it is best to wait until after the child's first birthday for the more extensive embolizations if possible.
 - It may not be necessary to shunt the hydrocephalus, since transarterial embolization may reduce the venous hypertension and mass effect from the vein and improve CSF dynamics. Some children with vein of Galen malformation may also decline neurologically after shunting.
- (e) Post-traumatic or post surgical fistulae
- Other than carotid cavernous fistulae, intracranial fistulae after closed or penetrating trauma or iatrogenic trauma are quite rare.
 - The most important step is to first understand the vascular anatomy and how it affects brain blood flow. Fistulas draining into meningeal veins or dural sinuses may be watched expectantly, since some may spontaneously thrombose. Those draining into cerebral veins require treatment.
 - Coils and/or liquid embolic agents are the endovascular treatment of choice.
2. Bleeding intracranial vessel
- (a) Usually it becomes an endovascular problem when it occurs as a complication of an endovascular procedure
 - (b) Rarely for post-operative or post-traumatic bleeding
 - (c) Seeing active bleeding angiographically is a much more ominous sign than seeing a pseudoaneurysm that is not bleeding.
 - (d) This is an acute emergency since uncontrolled intracranial bleeding can be fatal if not quickly controlled.
 - (e) Ventriculostomy can decompress the intracranial hypertension and be life-saving.
 - (f) Placement of a balloon guide catheter or nondetachable balloon catheter proximal to the bleeding site can slow the bleeding while a microcatheter is navigated to the bleeding site.
 - (g) Parent artery occlusion with coils and/or glue is generally the only option. Keep the length of vascular occlusion to a minimum to maximize potential collateral flow and minimize the size of ischemic damage.
 - (h) Avoid just doing a proximal occlusion: This does not stop bleeding from collateral sources and burns bridges since direct access to the lesion would be blocked.
 - (i) Disruptions of very proximal intracranial vessels (e.g. carotid or vertebral) may be sealed by deployment of a covered Jostent.
3. Intracranial tumors
- (a) Pre-operative embolization indications:⁸⁵
 - Control surgically inaccessible arterial feeders.

- Decrease surgical morbidity by reducing blood loss.
 - Shorten operative time.
 - Increase the chance of complete resection.
 - Decrease risk of damage to adjacent normal tissue.
 - Decrease chance of tumor recurrence.
 - Allow better visualization of the surgical field.
- (b) Most commonly embolized intracranial tumors include meningiomas, paragangliomas, and hemangioblastomas.
- (c) Feeding vessels to the tumor are often external carotid branches that are easily and safely embolized. (See Chap. 8)
- (d) Intracranial feeders from the carotid and vertebral or more distal intracranial branches may supply tumors.
- (e) For embolizing tumors, particle embolization is done most commonly, although for intracranial branch embolization, the authors more commonly use a liquid embolic agent, given the greater control and radiopacity compared with particles.
- (f) For each feeder, a risk/benefit ratio should be determined. Is the feeder easily and safely catheterized? Would occlusion provide sufficient reduction in the risk of surgery to justify the risk of embolization?
- (g) It is wise to treat the patient with dexamethasone before and after an embolization to limit the tumor swelling.
- (h) Choice of embolic agent
- The authors of this handbook favor particle embolization for almost all cases. PVA, Beadblock (Terumo Medical Corporation, Somerset, NJ), Embospheres (Biosphere Medical, Rockland, MA) and gelfoam powder may all yield adequate results. Recanalization after embolization is not a threat when surgery is planned relatively soon after embolization.
 - Beadblock and Embosphere particles may be preferable to PVA because they are spherical in shape and penetrate the tumor vasculature better. PVA particles are irregularly shaped and form agglomerates that occlude more proximally.⁸⁶
 - Particle size selection. Smaller particles (<150 μ m) are able to penetrate more deeply into the tumor and result in more complete devascularization.^{87,88} Other data suggest a higher risk of hemorrhage with smaller particles.⁸⁹
 - The authors of this handbook prefer smaller-to-intermediate size particles (100–300 μ m) for most tumors.
- (i) Timing of surgery after embolization
- Controversial: Some authors recommend surgery soon after embolization,^{90–92} while some recommend waiting 1–2 weeks, to permit necrosis and softening of the tumor.⁹³
 - In a review of 45 patients with surgery for meningiomas after embolization, resectability was greatest when surgery was done 7–9 days after embolization.⁹⁴
 - However, some patients develop delayed tumor edema and/or hemorrhage after embolization, necessitating urgent surgery.^{89,95}
 - Another argument against delayed surgery after embolization is that embolized tumors, such as meningiomas, may be over-graded on histological examination because of embolization-induced necrosis and reactive changes.^{96,97}
 - The authors of this handbook prefer to time surgery immediately after embolization or on the morning after. Occasionally, patients awaiting surgery develop post-embolization edema or intratumoral hemorrhage, necessitating prompt surgery; minimizing this risk by doing early surgery provides a greater benefit than any possible optimization of tumor resectability.
- (j) Steroids before and after treatment are important.
- Dexamethasone, 10-mg IV prior to embolization and then 4-mg PO/IV Q6 hours for 24–48 h after embolization.

7.5.1. A brief history of brain AVM embolization

The first report endovascular treatment of brain AVM's was by Alfred Luessenhop and Spence in 1960.⁹⁸ This involved performing a cut-down on the external carotid and

injecting large particulate agents retrograde into the internal carotid. These particles were usually 1–3-mm diameter silicone rubber spheres impregnated with barium to make them radiographically visible. In cases of high-flow AVMs, the flow tended to carry appropriately sized particles into the feeding arteries of the AVM. As long as the particles are large enough, they would not pass through the nidus into the venous system. The technique evolved into a strictly endovascular process with placement of a large-bore catheter from a transfemoral approach using standard Seldinger technique.⁹⁹ The spheres were then injected one-by-one through the catheter into the cerebral circulation. The appearance of the spheres traveling through the vessels on fluoroscopy was strangely fascinating, and can be compared to watching a pinball at an arcade. An element of chance was always involved, and one could never be certain where they would land. Still, because of preferential flow to the AVM, most would end up in the feeding arteries to the lesion.

In the meantime, the technique of intracranial catheterization and superselective embolization was beginning. This phase involved the use of iso-butyl cyanoacrylate (i-BCA) glue as the embolic agent. Liquid plastic material could be injected directly via intra-operative placement of angiocatheters in the feeding arteries or via an endovascular approach. The endovascular injection of i-BCA required superselective catheterization. Soft tubing with an attached balloon could be wound into an injection chamber, then forcefully injected through a guide catheter into the vessel. Inflation of the balloon would allow the blood flow to carry the balloon catheter forward. This worked well with AVMs given that their feeding arteries tend to be larger with more blood flow than normal vessels, and the balloon would preferentially go into the AVM feeders. When the balloons were prepared, a small hole was made in its apex, to allow contrast to be injected for superselective angiography, and when the balloon catheter was in proper position, the liquid cyanoacrylate glue was injected to embolize the feeding artery and nidus of the AVM.^{100–102} The balloon size was varied by the rate and pressure of injection. In the proper hands, the technique became quite elegant, since the balloon provided flow arrest during the glue injection to allow a controlled filling of the nidus.¹⁰³ However, the catheterization technique was quite involved and the use of glue required considerable training and experience. Even experienced operators would sometimes rupture vessels by over-inflating the balloon or have some problem with the glue polymerizing too fast and gluing the catheter in place, or too slow and spreading beyond the nidus into the veins. All of these issues resulted in AVM embolizations being done at only a few centers.

In the 1980s, development of variable stiffness microcatheters, specifically the Tracker, and platinum tipped microwires ushered in a new era for AVM embolization. This allowed for intracranial navigation without the complicated injection chamber or the balloon, and also opened up the option of embolizing with particles and other agents besides glue. By the late 1980s, platinum microcoils suitable for delivery via a Tracker also became available. Embolization of AVMs began to be done at an increasing number of centers and with a wide variety of embolic agents. Coincidentally, the company Ethicon stopped making i-BCA in the late 1980s and, although n-BCA (Histoacryl, Braun, Melsungen, Germany) was widely available in Europe and Canada,³⁰ glue became scarce in the United States. Thus, throughout the 1980s and 1990s, there was an increasing number of centers performing brain embolization with a heterogeneous mix of techniques and agents.

While this increasing use of embolization was going on, the next major breakthrough occurred with the development of the flow-directed Magic catheter in the late 1980s.¹⁰⁴ Then, with the availability of 0.010-in. wires, and the addition of hydrophilic coating to the catheter, intranidal catheterization was possible. While many centers were doing PVA particle and coil embolization of AVMs, a few centers that continued to use glue could now do very elegant intranidal glue injections using the flow directed catheters.¹⁶

A landmark event was the approval of Trufill nBCA (Cordis Neurovascular, Miami Lakes, FL) by the FDA on September 25, 2000.⁴⁸ This opened up the U.S. market for glue availability. In addition, FDA mandated, company sponsored training spread knowledge about techniques and improved consistency of results across the country. Glue embolization for AVMs became much more widespread and began to significantly cut back on the use of particles and coils for this procedure. It seemed possible that glue embolization could be the dominant technique for AVM embolization until the development of Onyx.¹⁰⁵ It was first used in the late 1990s and achieved FDA approval in 2003. Like Trufill glue, Onyx had required physician training which allowed for dissemination of the technical skills required for its use. These two liquid embolics and the structured dissemination of the technical skills for their use has led to a large number of centers using one or both of these agents on a routine basis, with greater success than ever before. When brain AVM embolization began, it seemed a little crazy; now it is a maturing field.

7.6. Intracranial embolization: Complication avoidance and management

Informed consent prior to the procedure should include a thorough discussion of the risk of complications.

7.6.1. Neurological complications

1. Access-related complications may include perforation or rupture of intracranial vascular structures,¹⁰⁶ causing subarachnoid, intra-parenchymal or rarely subdural bleeding.
2. A risk of thromboembolic complications from clot formation or errant embolic material.
3. There is a risk of AVM rupture and associated intraparenchymal hemorrhage if one occludes draining intracranial venous structures.¹⁰⁷ This hemorrhage can occur acutely or in a delayed fashion.
4. After occlusion of a high-flow fistula or AVM, malignant brain edema may occur.¹⁰⁸
5. Microcatheters may be glued in place and/or the catheter may break and become an embolus to an intracranial vessel.
6. Brain abscess has been rarely reported after intracranial embolization.¹⁰⁹
7. Seizures may occur after any intracranial procedure.
8. Tumors may swell and even bleed after embolization, producing a precipitous decline in neurological condition of the patient.

7.6.2. Nonneurological complications

1. Coils, glue,¹¹⁰ particles¹¹¹ or other embolic agents might embolize to the pulmonary circulation.
2. Anaphylactoid reactions to iodinated contrast or any of the medications used can occur as with any endovascular procedure.
3. Similarly, groin hematomas or other groin arterial injury can occur, as in any endovascular procedure.
4. Deep venous thrombosis and pulmonary embolism can occur.
5. Anesthesia-related complications can occur.
6. Patients with vascular fragility syndromes like Ehlers Danlos can experience a wide variety of complications related to their connective tissue fragility, including retroperitoneal hematoma and bowel perforation.^{70, 112}

7.6.3. Complications of brain AVM embolization: the big picture

A systematic review of reports of 1,246 patients up to 1995 revealed temporary morbidity in 10%, permanent morbidity in 8% and mortality in 1% after AVM embolization.¹ More recent studies report 14% neurological complications with 2% persistent disabling deficit and 1% death.¹¹³ Another study showed permanent, nondisabling stroke in 2.6% and permanent disabling stroke or death in 1.6%.¹¹⁴ The Columbia group showed that the risk of complications are dependant on the patient's age, the number of embolization procedures performed, and especially the absence of a pre-existing deficit, but not anatomical characteristics.¹¹³ Jayaraman and co-workers showed that there may also be a weak association with a basal ganglia location.¹¹⁴ Kim and colleagues found that only the number of branches embolized predicted the outcome.¹¹⁵ Ledezma and the group from Massachusetts General Hospital showed that bad outcome after embolization was associated by univariate analysis with many morphological features including deep venous drainage, Spetzler-Martin Grade III to V, and peri-procedural bleed, and by multivariate analysis with Spetzler-Martin Grade and peri-procedural bleed.¹¹⁶

Another important question is: What does embolization do to the annual risk of bleeding? Targeted embolization of higher risk features, like aneurysms resulted in approximately 3.6% annual hemorrhage rate.¹¹⁷ A less specific treatment regimen had patients with a 5.4% annual risk of bleeding and 1% risk of dying after embolization.⁵⁶ A lesser degree of occlusion and whether the patient had bled prior to the procedure were the main determinants of whether the patient hemorrhaged in the follow-up. Unfortunately, there is no randomized, prospective study looking for the effect of embolization on risk of bleeding.

7.6.3.1. Complications of intracranial tumor embolization

1. Most common reported complications of tumor embolization are fever and localized pain.⁸⁵
2. The Accreditation Council on Graduate Medical Education set a threshold total complication rate of 5% for head, neck and brain tumor embolization (the term “threshold” meant that a review should be prompted if any individual center’s complication rate exceeds that level).⁸⁵
3. Meningiomas. Most commonly embolization intracranial tumor.
 - (a) Overall neurological complication rate: 2.5%.¹¹⁸
 - (b) Other potential complications include intratumoral hemorrhage,⁸⁹ scalp necrosis,^{119, 120} and retinal embolization.¹²¹
4. Hemangioblastomas.
 - (a) Total complication rates with hemangioma embolization in reported series range from 5.6 to 12.5%.^{95, 122, 123} Tumor hemorrhage or swelling are the most common complications. A recent review of reported cases found an overall complication rate of 43% with particle embolization of cerebellar hemangioblastomas.¹²⁴

7.6.4. Discussion of selected complications

7.6.4.1. Vessel perforation

1. Mechanisms: Perforation with the microwire is the usual cause. Less commonly the microcatheter tip or a forceful contrast injection may perforate a vessel.¹²⁵
2. Frequency
 - (a) One wire perforation out of over 150 vessels treated by an experienced team using flow-directed microcatheters.¹⁶
 - (b) A large series showed 1.9% perforations in glue embolization cases and 5.8% in PVA embolization cases.⁴⁸ This may relate to the greater use of flow-directed microcatheters for glue.
3. Risk factors
 - (a) Use of over-the-wire microcatheters associated with more wire injuries.
 - (b) Procedures involving tracking of devices with relatively high resistance (e.g., balloons and stents).
4. Avoidance
 - (a) Exercise caution always.
 - (b) Always use roadmap guidance for intracranial catheter navigation.
 - (c) Take measures to minimize anterograde force on the microcatheter and microwire. If there is bucking of the wire, it is meeting resistance, and further pushing can cause problems. Better to pull back slightly then rotate the wire to get around the obstacle.
 - (d) Use a tight J-tip curve on the wire whenever possible. Keep the wire in the largest diameter vessel possible. Avoid entering small branches (e.g. lenticulostriates, basilar perforators) unnecessarily.
 - (e) Tighten the RHV around the microcatheter when doing guide catheter angiograms (to prevent the contrast injection from carrying the microcatheter forward).
5. Management
 - (a) Recognition is the first step: An abrupt rise in blood pressure or ICP, or a sudden slowing of the heart rate should prompt an immediate guide catheter angiogram.

- (b) *Resist the impulse to pull back on the perforating device!* The device may occlude or partially occlude the perforation, and withdrawal of the device may worsen the perforation.
- (c) Reverse heparin anticoagulation with protamine.
- (d) Sealing the perforation must be done quickly, but preferably occlusion of normal vascular territories should be minimized.
- (e) If possible, quickly puncture the contralateral groin and advance a second guide catheter into the vessel feeding the perforation. An appropriate nondetachable balloon (e.g. HyperformSM) can then be placed proximal to the perforation to provide proximal control and slow the bleeding. This buys time for the operator to think, consider the options and get the perforation sealed in a controlled fashion.
- (f) Occasionally, the tear in abnormal vessel may extend into the normal vessel. In this situation, coil-occlusion of the parent vessel may be the only way to stop the hemorrhage. Obviously, this is a salvage maneuver and the patient's outcome will depend on the presence or absence of collateral circulation.
- (g) If not already under anesthesia, the patient may need to be intubated to protect the airway. This scenario is one reason why it is helpful to have all intracranial embolization procedures done under general anesthesia.
- (h) Once the perforation is secured, a ventriculostomy will probably be necessary, particularly if the patient remains hypertensive (i.e., if there is ongoing evidence of elevated ICP).
- (i) Once the patient is stabilized, obtain a head CT.
- (j) If there is a parenchymal hemorrhage with significant mass effect, emergent craniotomy with evacuation should be considered.

7.6.4.2. Thromboembolism

1. Mechanisms:
 - (a) Platelet-rich thrombus formation on devices used during the procedure.
 - (b) Thrombus formation in the guide catheter or microcatheter due to inadequate flushing technique.
 - (c) Slowing of flow in the parent vessel caused by vasospasm or occlusion by the guide catheter or microcatheter.
 - (d) Air emboli.
 - (e) Inadvertent embolization of normal territories with embolic agent or device due to:
 - Reflux of liquid or particulate emboli due to overly forceful injections.
 - Displacement of guide catheter or microcatheter during embolization due to catheter instability or redundancy.
 - Breaking, stretching, or premature detachment of detachable coils or balloons during manipulation.
 - Rupture of microcatheter during injection of liquid or particulate embolic agent.
 - Fracture and separation of catheter or wire segments during manipulation.
 - Retained microcatheter after inadvertently gluing it in a vessel, especially if it breaks at the level of the aortic arch and the proximal end of the retained catheter can be pushed cephalad by the flow.
2. Frequency
 - (a) Symptomatic thromboembolism: Approximately 9–10%.¹⁵
 - (b) NBCA vs. PVA comparative study had 3.8% stroke and 1.9% thromboembolism for glue AVM embolizations and 5.8% stroke and 1.9% thromboembolism plus 3.8% TIA symptoms in PVA embolizations.⁴⁸
3. Avoidance
 - (a) Continuous flushing of all catheters with heparinized saline and meticulous attention to keeping all devices clear of bubbles and clot.
 - (b) Measures to prevent stasis of flow around the guide catheter
 - Adjust catheter position if guide catheter-induced vasospasm around the catheter is flow-limiting.
 - (c) Systemic anticoagulation with heparin. Although most operators undertake routine anticoagulation with IV heparin during embolization, prospective data to support its use are lacking.

- (d) Prophylactic antiplatelet agents. These are mainly used when there is contemplation of using a stent.
 - (e) Remove slack in guide catheter and microcatheter prior to embolizing.
 - (f) Remove any wire or catheter or embolic device immediately if there is a suspicion that it is damaged.
4. Management
- (a) Recognition is again the first step: Guide catheter angiograms should be done frequently to monitor for evidence of thrombosis, such as a filling-defect within the parent vessel adjacent to the aneurysm neck, or vessel drop-out.
 - (b) Routinely using neurophysiological monitoring (i.e. SSEPs) may detect early signs of a problem.
 - (c) Ensure that the patient is well hydrated and consider pharmacologically augmenting blood pressure to maximize the collateral flow to the impaired territory.
 - (d) Most thrombotic material that appears during embolization is likely to be platelet-rich; therefore, anti-platelet therapy is the first approach.
 - Abciximab 0.25 mg kg⁻¹ IV rapid bolus followed by 125 mcg kg⁻¹ min⁻¹ infusion (to a maximum of 10 mg min⁻¹) for 12 h.
 - *Caution: Partial dosing of Abciximab should be avoided, unless point of care testing confirms adequate receptor blockade.*¹²⁶ The authors recommend the use of a full loading dose followed by IV infusion for 12 h, unless the threat of hemorrhagic complications is prohibitive. The authors have personally witnessed paradoxical drug-induced platelet activation effect with lower levels of platelet inhibition with abciximab, and a corresponding increase in thrombotic complications.
 - A 2-mm diameter Amplatz Goose Neck microsnare (Microvena, White Bear Lake, MN), Merci Retriever[®] (Concentric Medical, Mountain View, CA), or Alligator[™] Retrieval Device (Chestnut Medical Technologies, Menlo Park, CA) may be used to remove clot, fractured wires or catheters or embolic devices.
 - Occasionally a balloon or stent can be used to restore flow in a vessel.
 - At each step, one should evaluate the potential risks and benefits and be prepared to accept a small stroke to avoid potentially worse consequences from unrestrained attempts to open a vessel at all costs.
 - In very select cases and only where there is an experienced cerebrovascular surgeon open craniotomy and embolectomy may be considered to restore flow.
 - (e) Thrombolytic agents are associated with a risk of significant hemorrhage, particularly when used on patients that have recently bled. They should be used sparingly, if at all.

7.6.4.3. AVM rupture

1. Mechanism
 - (a) A generally accepted cause of AVM bleeding after AVM embolization is embolic agents passing into the venous outlets of the AVM and producing stenosis or occlusion.¹⁰⁷
 - (b) Other have speculated that partial embolization redirects the flow into areas unaccustomed to the higher flow.
 - (c) Associated aneurysms may rupture after the change in flow.
2. Frequency
 - (a) Reports of death or disability after embolization run from 3 to 11%.^{113–116}
 - (b) Approximately 1.6% of hemorrhages occurred in a large series.¹¹⁴
 - (c) A German group reported that 10.6% of 66 patients embolized bled.¹²⁷ Greater than 60% occlusion of AVM nidus was associated with 18 times higher risk of bleeding.¹²⁷
3. Avoidance
 - (a) During embolization, avoid getting embolic agents in the veins. Consider a faster-polymerizing glue, or place a proximal coil to reduce the flow.
 - (b) Be sure to treat associated aneurysms, wherever possible.

4. Management
 - (a) First step: Prompt recognition is essential, as always. Look for a sudden headache, sudden increase in blood pressure or ICP, and worsening neurological status.
 - (b) If not intubated already, consider intubation to protect airway and allow for mechanical hyperventilation.
 - (c) Emergent CT.
 - (d) If necessary, ventriculostomy.
 - (e) If intracranial pressure high from a parenchymal hematoma, lower it with hyperventilation and pharmacological means (e.g. mannitol, hypertonic saline, propofol, etc.) but also be prepared for urgent surgical evacuation of hematoma.¹²⁸
 - (f) Craniotomy and evacuation of the clot, if necessary.

7.6.4.4. Postembolization edema or hemorrhage (aka normal perfusion breakthrough syndrome)

1. After treatment of an AVM or high flow AVF, in which there is abrupt closure of a high flow AV shunt, edema and intracerebral bleeding can occur.
2. May be a special case of AVM rupture post procedure, may be seen when entire AVM has been excised or occluded, and edema may occur without bleeding. This is why it is often considered a separate entity from just ordinary AVM rupture.
3. Mechanism
 - (a) Considered to be caused by sudden occlusion of a long-standing AV shunt, exposing vessels with disturbed autoregulation to increased flow.¹⁰⁸
 - (b) Venous thrombosis or occlusion may play a role as well
 - (c) Residual AVM nidus may also explain some cases.
4. Frequency
 - (a) Uncommon
 - (b) AVF series: 5 out of 185 cases of carotid and vertebral fistulae treated, tended to be patients with longstanding fistula that had progressive symptoms of arterial steal from the fistula prior to treatment.¹²⁹
 - (c) Three examples out of 66 AVM patients treated surgically.¹³⁰
5. Avoidance
 - (a) Consider studying patients suffering steal symptoms pretreatment with blood flow imaging to assess autoregulation.
 - (b) Consider staging multi-feeder lesions to give the brain a chance to recover between sessions.^{131, 132}
 - (c) Monitor and manage blood pressure during and after treatment.⁵⁵
 - (d) Avoid venous occlusion or leaving residual shunt.
 - (e) Worst case scenario is occluding venous outlet and leaving some residual shunt
6. Management
 - (a) Strict blood pressure control during and after treatment.
 - (b) Consider keeping patent moderately hypotensive.
 - (c) Monitor intracranial pressure with a ventriculostomy and treat intracranial hypertension aggressively.
 - (d) One center reported success using indomethacin for normal perfusion breakthrough syndrome.¹³³
 - (e) Consider surgical decompression including decompressive craniectomy if unresponsive to medical management.

7.6.4.5. Vessel dissection

1. Mechanism: Wire or guide catheter-induced injury to vessel.
2. Frequency
 - (a) 1.9% of cases⁴⁸
 - (b) Vertebral artery dissections seem to be more common than carotid dissections.
 - (c) This complication is probably under-reported, as many operators do not do routine surveillance angiograms of the access vessel (i.e., the cervical carotid or vertebral artery) at the completion of the case, and therefore do not identify asymptomatic dissections.

3. Avoidance
 - a. Take steps to minimize intimal trauma (see *Guide catheter placement technique* above).
4. Management
 - (a) Always do a guide catheter angiogram of the access vessel at the end of the case.
 - (b) Antiplatelet therapy is usually sufficient; aspirin 325 mg suppository during or after the procedure, then PO daily. Add a second antiplatelet agent if possible (e.g., clopidogrel 75-mg PO daily).
 - (c) Consider anticoagulation with IV heparin, in addition to antiplatelet therapy, if the dissection is flow-limiting and carries a risk of thrombosis.
 - (d) Consider placing a stent across the lesion if it becomes necessary to continue to work in the affected vessel, or if further access through that vessel is anticipated.
 - (e) Follow-up imaging should be done in 3–6 months. Most dissections treated with antiplatelet therapy will heal within 3–6 months.

7.6.4.6 Retained microcatheter (aka glued microcatheter)

1. If the glue bolus polymerizes around the tip of the microcatheter, it can be glued into the vessel. This is a well-known complication of n-BCA glue embolization, but it can also occur with Onyx. Pulling back on the microcatheter will sometimes cause it to break free of the glue, but if it is solidly glued in, then pulling the microcatheter just pulls on the intracranial vessels, so it may be best to leave it in place and permanently implant it. Blood flow tends to tug on the catheter extending down the descending aorta, keeping the catheter taut along the side of the vessel and can become endothelialized.¹³⁴ If, during attempted withdrawal, the microcatheter breaks above the level of the aortic arch, blood flow can carry the smaller fragment up into the intracranial vessels and potentially cause problems.¹³⁵ Catheters that remain intact are generally implanted with the cut proximal end in the femoral artery. Sporadic reports appear chronicling stories of delayed local complications in the leg or groin.^{134, 136, 137}
2. Mechanism
 - (a) Usually related to technique – glue mixture too concentrated, injected too quickly, reflux of agent around catheter tip not recognized, not pulled quickly enough.
 - (b) Similarly, Onyx injected too quickly and allowed to reflux too much for too long may result in a stuck microcatheter.
3. Frequency
 - (a) 7.4% of 54 patients treated with glue in the NBCA vs. PVA trial.⁴⁸
 - (b) None of the microcatheters used for PVA got stuck.
 - (c) 8.5% of 47 cases treated with Onyx had retained microcatheters.¹³⁸
4. Avoidance
 - (a) Avoid reflux around microcatheter.
 - (b) Have a good working view showing microcatheter tip during injection of liquid embolic.
 - (c) Remove slack in system before injecting glue.
 - (d) Pull microcatheter quickly as soon as the glue begins to approach catheter tip.
 - (e) Avoid allowing Onyx to reflux more than 1.0 cm along microcatheter or to stay in contact more than a few minutes.
 - (f) When withdrawing the microcatheter, also pull the guide catheter.
5. Management
 - (a) Usually the microcatheter is put under tension and the cut at the groin to permanently implant it.
 - (b) Consider surgical extraction acutely, if a compromise on the flow occurs.
 - (c) Surgical removal after a day or so is problematic because the catheter gets stuck along the vessel by fibrin, and later can become endothelialized.
 - (d) A microcatheter that breaks at or above the level of the aortic arch has risk of becoming an embolus to the intracranial circulation. This could be grasped with a microsnare, and pulled taut and the end pulled up into an external carotid branch and secured in place with a balloon, coil, or glue with a second microcatheter (Obviously, be careful not to glue the snare or second microcatheter in place.) An easier alternative is to

- secure the microcatheter along the periphery of the vessel by deploying a self-expanding stent in the parent artery. This would require at least a few months of clopidogril therapy.
- (e) Most would put patients on aspirin after any permanent microcatheter implantation, although the benefit of that is unproven in this setting.
 - (f) Delayed complications from the implanted catheter such as vessel thrombosis or pseudoaneurysm may require surgical repair.

7.6.4.7. Prevention of guide catheter-induced vasospasm

1. An ounce of prevention is worth a pound of cure: *Be gentle*.
2. Withdraw the catheter into a lower segment of the vessel when significant catheter-induced vasospasm appears.
3. Keep the catheter tip away from kinks and bends in the vessel if possible.
 - (a) A curvaceous carotid or proximal vertebral artery can sometimes be straightened by tilting the patient's head toward the opposite shoulder.
4. Use a smaller guide catheter.
5. Use a soft-tipped guide catheter (e.g., Guider Softip™ XF guide catheter (Boston Scientific, Natick, MA)).
6. Use Visipaque™ (GE Healthcare, Princeton, NJ) contrast instead of Omnipaque; according to the manufacturer, this contrast material is less spasmogenic than Omnipaque®.
7. Use a guide catheter with an inner obturator (e.g., Northstar® Lumax® Flex Catheter (Cook Inc., Bloomington, IN))
8. Nitroglycerin paste on the patient's neck ipsilateral to the access vessel
 - (a) Dose: 1–5 in.
 - (b) Efficacy is unclear
 - (c) Drawback: Can cause hypotension and a headache in awake patients. In patients under general anesthesia, the dose (i.e., the number of inches) of paste is adjusted to maintain the blood pressure within normal limits.
9. Selective injection of IA nitroglycerin (30 mcg per injection).
 - (a) This can help distinguish vasospasm from vessel dissection, if a dissection is suspected

7.7. References

1. Frizzel RT, Fisher WS, III. Cure, morbidity, and mortality associated with embolization of brain arteriovenous malformations: a review of 1246 patients in 32 series over a 35-year period. *Neurosurgery* 1995;37(6):1031–9; discussion 9–40.
2. van Rooij WJ, Sluzewski M, Beute GN. Brain AVM embolization with Onyx. *AJNR Am J Neuroradiol* 2007;28(1):172–7; discussion 8.
3. Weber W, Kis B, Siekmann R, Kuehne D. Endovascular treatment of intracranial arteriovenous malformations with onyx: technical aspects. *AJNR Am J Neuroradiol* 2007;28(2):371–7.
4. Yu SC, Chan MS, Lam JM, Tam PH, Poon WS. Complete obliteration of intracranial arteriovenous malformation with endovascular cyanoacrylate embolization: initial success and rate of permanent cure. *AJNR Am J Neuroradiol* 2004;25(7):1139–43.
5. Mounayer C, Hammami N, Piotin M, et al. Nidal embolization of brain arteriovenous malformations using Onyx in 94 patients. *AJNR Am J Neuroradiol* 2007;28(3):518–23.
6. Marks MP, Lane B, Steinberg GK, Snipes GJ. Intranidial aneurysms in cerebral arteriovenous malformations: evaluation and endovascular treatment. *Radiology* 1992;183(2):355–60.
7. Meisel HJ, Mansmann U, Alvarez H, Rodesch G, Brock M, Lasjaunias P. Cerebral arteriovenous malformations and associated aneurysms: analysis of 305 cases from a series of 662 patients. *Neurosurgery* 2000;46(4):793–800; discussion 2.
8. Piotin M, Ross IB, Weill A, Kothimbakam R, Moret J. Intracranial arterial aneurysms associated with arteriovenous malformations: endovascular treatment. *Radiology* 2001;220(2):506–13.
9. Forster C, Kahles T, Kietz S, Drenckhahn D. Dexamethasone induces the expression of metalloproteinase inhibitor TIMP-1 in the murine cerebral vascular endothelial cell line cEND. *J Physiol* 2007;580 (Part 3):937–49.
10. Tuor UL, Simone CS, Barks JD, Post M. Dexamethasone prevents cerebral infarction without affecting cerebral blood flow in neonatal rats. *Stroke* 1993;24(3):452–7.
11. Zausinger S, Westermaier T, Plesnila N, Steiger HJ, Schmid-Elsaesser R. Neuroprotection in transient focal cerebral ischemia by combination drug therapy and mild hypothermia: comparison with customary therapeutic regimen. *Stroke* 2003;34(6):1526–32.
12. Adachi N, Chen J, Liu K, Tsubota S, Arai T. Dexamethasone aggravates ischemia-induced neuronal damage by facilitating the onset of anoxic depolarization and the increase in the intracellular Ca²⁺ concentration in gerbil hippocampus. *J Cereb Blood Flow Metab* 1998;18(3):274–80.
13. Tsubota S, Adachi N, Chen J, Yorozuya T, Nagaro T, Arai T. Dexamethasone changes brain monoamine metabolism and aggravates ischemic neuronal damage in rats. *Anesthesiology* 1999;90(2):515–23.
14. Koide T, Wieloch TW, Siesjo BK. Chronic dexamethasone pretreatment aggravates ischemic neuronal necrosis. *J Cereb Blood Flow Metab* 1986;6(4):395–404.
15. Qureshi AI, Luft AR, Sharma M, Guterman LR, Hopkins LN. Prevention and treatment of thromboembolic and ischemic complications associated with endovascular procedures. Part 2: clinical aspects and recommendations. *Neurosurgery* 2000;46(6):1360–75; discussion 75–6.

16. Aletich VA, Debrun GM, Koenigsberg R, Ausman JI, Charbel F, Dujovny M. Arteriovenous malformation nidus catheterization with hydrophilic wire and flow-directed catheter. *AJNR Am J Neuroradiol* 1997;18(5):929-35.
17. Grady RM, Eisenberg PR, Bridges ND. Rational approach to use of heparin during cardiac catheterization in children. *J Am Coll Cardiol* 1995;25(3):725-9.
18. Bulbul ZR, Galal MO, Mahmoud E, et al. Arterial complications following cardiac catheterization in children less than 10 kg. *Asian Cardiovasc Thorac Ann* 2002;10(2):129-32.
19. Lewis BE, Ferguson JJ, Grassman ED, et al. Successful coronary interventions performed with argatroban anticoagulation in patients with heparin-induced thrombocytopenia and thrombosis syndrome. *J Invasive Cardiol* 1996;8(9):410-17.
20. Matthai WH, Jr. Use of argatroban during percutaneous coronary interventions in patients with heparin-induced thrombocytopenia. *Semin Thromb Hemost* 1999;25 Suppl 1:57-60.
21. Harrigan MR, Levy EI, Bendok BR, Hopkins LN. Bivalirudin for endovascular intervention in acute ischemic stroke: case report. *Neurosurgery* 2004;54(1):218-22; discussion 22-3.
22. Clayton SB, Acsell JR, Crumbley AJ, III, Uber WE. Cardiopulmonary bypass with bivalirudin in type II heparin-induced thrombocytopenia. *Ann Thorac Surg* 2004;78(6):2167-9.
23. Keeling D, Davidson S, Watson H. The management of heparin-induced thrombocytopenia. *Br J Haematol* 2006;133(3):259-69.
24. Kallmes DF, McGraw JK, Evans AJ, et al. Thrombogenicity of hydrophilic and nonhydrophilic microcatheters and guiding catheters. *AJNR Am J Neuroradiol* 1997;18(7):1243-51.
25. Kiyosue H, Hori Y, Matsumoto S, et al. Shapability, memory, and luminal changes in microcatheters after steam shaping: a comparison of 11 different microcatheters. *AJNR Am J Neuroradiol* 2005;26(10):2610-16.
26. Paiva T, Campos J, Baeta E, Gomes LB, Martins IP, Parreira E. EEG monitoring during endovascular embolization of cerebral arteriovenous malformations. *Electroencephalogr Clin Neurophysiol* 1995;95(1):3-13.
27. Liu AY, Lopez JR, Do HM, Steinberg GK, Cockroft K, Marks MP. Neurophysiological monitoring in the endovascular therapy of aneurysms. *AJNR Am J Neuroradiol* 2003;24(8):1520-7.
28. Rauch RA, Vinuela F, Dion J, et al. Preembolization functional evaluation in brain arteriovenous malformations: the ability of superselective Amytal test to predict neurologic dysfunction before embolization. *AJNR Am J Neuroradiol* 1992;13(1):309-14.
29. Kerber CW, Wong W. Liquid acrylic adhesive agents in interventional neuroradiology. *Neurosurg Clin N Am* 2000;11(1):85-99, viii-ix.
30. Brothers MF, Kaufmann JC, Fox AJ, Deveikis JP. *n*-Butyl 2-cyanoacrylate substitute for IBCA in interventional neuroradiology: histopathologic and polymerization time studies. *AJNR Am J Neuroradiol* 1989;10(4):777-86.
31. Wikholm G. Occlusion of cerebral arteriovenous malformations with *N*-butyl cyanoacrylate is permanent. *AJNR Am J Neuroradiol* 1995;16(3):479-82.
32. Spiegel SM, Vinuela F, Goldwasser JM, Fox AJ, Pelz DM. Adjusting the polymerization time of isobutyl-2 cyanoacrylate. *AJNR Am J Neuroradiol* 1986;7(1):109-12.
33. Barr JD, Hoffman EJ, Davis BR, Edgar KA, Jacobs CR. Microcatheter adhesion of cyanoacrylates: comparison of normal butyl cyanoacrylate to 2-hexyl cyanoacrylate. *J Vasc Interv Radiol* 1999;10(2, Part 1):165-8.
34. Komotar RJ, Ransom ER, Wilson DA, Connolly ES, Jr, Lavine SD, Meyers PM. 2-Hexyl cyanoacrylate (neuroacryl M) embolization of cerebral arteriovenous malformations. *Neurosurgery* 2006;59(4, Suppl 2):ONS464-9; discussion ONS9.
35. Becker TA, Preul MC, Bichard WD, Kipke DR, McDougall CG. Calcium alginate gel as a biocompatible material for endovascular arteriovenous malformation embolization: six-month results in an animal model. *Neurosurgery* 2005;56(4):793-801; discussion 793-801.
36. Akin ED, Perkins E, Ross IB. Surgical handling characteristics of an ethylene vinyl alcohol copolymer compared with *N*-butyl cyanoacrylate used for embolization of vessels in an arteriovenous malformation resection model in swine. *J Neurosurg* 2003;98(2):366-70.
37. Duffner F, Ritz R, Bornemann A, Freudenstein D, Wiendl H, Siekmann R. Combined therapy of cerebral arteriovenous malformations: histological differences between a non-adhesive liquid embolic agent and *n*-butyl 2-cyanoacrylate (NBCA). *Clin Neuropathol* 2002;21(1):13-17.
38. Yakes WF, Krauth L, Ecklund J, et al. Ethanol endovascular management of brain arteriovenous malformations: initial results. *Neurosurgery* 1997;40(6):1145-52; discussion 52-4.
39. Pelz DM, Fox AJ, Vinuela F, Drake CC, Ferguson GG. Preoperative embolization of brain AVMs with isobutyl-2 cyanoacrylate. *AJNR Am J Neuroradiol* 1988;9(4):757-64.
40. Fox AJ, Pelz DM, Lee DH. Arteriovenous malformations of the brain: recent results of endovascular therapy. *Radiology* 1990;177(1):51-7.
41. Lylyk P, Vinuela F, Vinters HV, et al. Use of a new mixture for embolization of intracranial vascular malformations. Preliminary experimental experience. *Neuroradiology* 1990;32(4):304-10.
42. Phatourous CC, Higashida RT, Malek AM, Smith WS, Dowd CF, Halbach VV. Embolization of the meningohypophyseal trunk as a cause of diabetes insipidus. *AJNR Am J Neuroradiol* 1999;20(6):1115-18.
43. Kasuya H, Shimizu T, Sasahara A, Takakura K. Phenytoin as a liquid material for embolisation of tumours. *Neuroradiology* 1999;41(5):320-3.
44. Wong GA, Armstrong DC, Robertson JM. Cardiovascular collapse during ethanol sclerotherapy in a pediatric patient. *Paediatr Anaesth* 2006;16(3):343-6.
45. Phatourous CC, Halbach VV, Malek AM, Meyers PM, Dowd CF, Higashida RT. Intraventricular contrast medium leakage during ethanol embolization of an arteriovenous malformation. *AJNR Am J Neuroradiol* 1999;20(7):1329-32.
46. Tadavarthy SM, Moller JH, Amplatz K. Polyvinyl alcohol (Ivalon) - a new embolic material. *Am J Roentgenol Radium Ther Nucl Med* 1975;125(3):609-16.
47. Wallace RC, Flom RA, Khayat MH, et al. The safety and effectiveness of brain arteriovenous malformation embolization using acrylic and particles: the experiences of a single institution. *Neurosurgery* 1995;37(4):606-15; discussion 15-18.
48. *N*-butyl cyanoacrylate embolization of cerebral arteriovenous malformations: results of a prospective, randomized, multi-center trial. *AJNR Am J Neuroradiol* 2002;23(5):748-55.
49. Lewis AL, Adams C, Bushy W, et al. Comparative in vivo evaluation of microspherical embolisation agents. *J Mater Sci Mater Med* 2006;17(12):1193-204.
50. Taki W, Handa H, Yamagata S, Ishikawa M, Iwata H, Ikada Y. Radiopaque solidifying liquids for releasable balloon technique: a technical note. *Surg Neurol* 1980;13(2):140-2.
51. Gounis MJ, Lieber BB, Wakhloo AK, Siekmann R, Hopkins LN. Effect of glacial acetic acid and ethiodized oil concentration on embolization with *N*-butyl 2-cyanoacrylate: an in vivo investigation. *AJNR Am J Neuroradiol* 2002;23(6):938-44.
52. Lieber BB, Wakhloo AK, Siekmann R, Gounis MJ. Acute and chronic swine rete arteriovenous malformation models: effect of ethiodol and glacial acetic acid on penetration, dispersion, and injection force of *N*-butyl 2-cyanoacrylate. *AJNR Am J Neuroradiol* 2005;26(7):1707-14.
53. Moore C, Murphy K, Gailloud P. Improved distal distribution of *n*-butyl cyanoacrylate glue by simultaneous injection of dextrose 5% through the guiding catheter: technical note. *Neuroradiology* 2006;48(5):327-32.
54. Masaryk TJ, Perl J, II, Wallace RC, Magdinec M, Chyatte D. Detachable balloon embolization: concomitant use of a second safety balloon. *AJNR Am J Neuroradiol* 1999;20(6):1103-6.
55. Massoud TF, Hademenos GI, Young WL, Gao E, Pile-Spellman J. Can induction of systemic hypotension help

- prevent nidus rupture complicating arteriovenous malformation embolization? – analysis of underlying mechanism achieved using a theoretical model. *AJNR Am J Neuroradiol* 2000;21(7):1255–67.
56. Raupp EF, Fernandes J. Does treatment with *N*-butyl cyanoacrylate embolization protect against hemorrhage in cerebral arteriovenous malformations? *Arq Neuropsiquiatr* 2005;63(1):34–9.
 57. Deruty R, Pelissou-Guyotat I, Amat D, et al. Complications after multidisciplinary treatment of cerebral arteriovenous malformations. *Acta Neurochir* 1996;138(2):119–31.
 58. Hartmann A, Mast H, Mohr JP, et al. Determinants of staged endovascular and surgical treatment outcome of brain arteriovenous malformations. *Stroke* 2005;36(11):2431–5.
 59. Sadato A, Wakhloo AK, Hopkins LN. Effects of a mixture of a low concentration of *n*-butylcyanoacrylate and ethiodol on tissue reactions and the permanence of arterial occlusion after embolization. *Neurosurgery* 2000;47(5):1197–203; discussion 204–5.
 60. Halbach VV, Hieshima GB, Higashida RT, Reicher M. Carotid cavernous fistulae: indications for urgent treatment. *AJR Am J Roentgenol* 1987;149(3):587–93.
 61. Debrun GM. Treatment of traumatic carotid-cavernous fistula using detachable balloon catheters. *AJNR Am J Neuroradiol* 1983;4(3):355–6.
 62. Teng MM, Chang CY, Chiang JH, et al. Double-balloon technique for embolization of carotid cavernous fistulas. *AJNR Am J Neuroradiol* 2000;21(9):1753–6.
 63. Guglielmi G, Vinuela F, Duckwiler G, Dion J, Stocker A. High-flow, small-hole arteriovenous fistulas: treatment with electrodetachable coils. *AJNR Am J Neuroradiol* 1995;16(2):325–8.
 64. Siniluoto T, Seppanen S, Kuurme T, Wikholm G, Leinonen S, Svendsen P. Transarterial embolization of a direct carotid cavernous fistula with Guglielmi detachable coils. *AJNR Am J Neuroradiol* 1997;18(3):519–23.
 65. Suzuki S, Lee DW, Jahan R, Duckwiler GR, Vinuela F. Transvenous treatment of spontaneous dural carotid-cavernous fistulas using a combination of detachable coils and Onyx. *AJNR Am J Neuroradiol* 2006;27(6):1346–9.
 66. Wakhloo AK, Perlow A, Linfante I, et al. Transvenous *n*-butyl-cyanoacrylate infusion for complex dural carotid cavernous fistulas: technical considerations and clinical outcome. *AJNR Am J Neuroradiol* 2005;26(8):1888–97.
 67. Luo CB, Teng MM, Chang FC, Chang CY. Transarterial balloon-assisted *n*-butyl-2-cyanoacrylate embolization of direct carotid cavernous fistulas. *AJNR Am J Neuroradiol* 2006;27(7):1535–40.
 68. Marden FA, Sinha Roy S, Malisch TW. A novel approach to direct carotid cavernous fistula repair: hydrocoil-assisted revision after balloon reconstruction. *Surg Neurol* 2005;64(2):140–3; discussion 3.
 69. Russell EJ, Reddy V, Rovin R. Combined arterial and venous approaches for cure of carotid-cavernous sinus fistula in a patient with fibromuscular dysplasia. *Skull Base Surg* 1994;4(2):103–9.
 70. Chuman H, Trobe JD, Petty EM, et al. Spontaneous direct carotid-cavernous fistula in Ehlers-Danlos syndrome type IV: two case reports and a review of the literature. *J Neuroophthalmol* 2002;22(2):75–81.
 71. Gomez F, Escobar W, Gomez AM, Gomez JF, Anaya CA. Treatment of carotid cavernous fistulas using covered stents: midterm results in seven patients. *AJNR Am J Neuroradiol* 2007;28(9):1762–8.
 72. Yang ZJ, Li HW, Wu LG, et al. Prognostic analysis and complications of traumatic carotid cavernous fistulas after treatment with detachable balloon and/or coil embolization. *Chin J Traumatol* 2004;7(5):286–8.
 73. Wang YC, Wong HF, Yeh YS. Intracranial pial arteriovenous fistulas with single-vein drainage. Report of three cases and review of the literature. *J Neurosurg* 2004;100(2 Suppl Pediatrics):201–5.
 74. Itami H, Sugiu K, Tokunaga K, Ono S, Onoda K, Date I. [Endovascular treatment of adult pial arteriovenous fistula]. *No Shinkei Geka* 2007;35(6):599–605.
 75. Limaye US, Siddhartha W, Shrivastav M, Anand S, Ghatge S. Endovascular management of intracranial pial arteriovenous fistulas. *Neuro India* 2004;52(1):87–90.
 76. Vinuela F, Drake CG, Fox AJ, Pelz DM. Giant intracranial varices secondary to high-flow arteriovenous fistulae. *J Neurosurg* 1987;66(2):198–203.
 77. Lasjaunias PL, Chng SM, Sachet M, Alvarez H, Rodesch G, Garcia-Monaco R. The management of vein of Galen aneurysmal malformations. *Neurosurgery* 2006;59(5, Suppl 3):S184–S94; discussion S3–S13.
 78. Hurst RW, Kagetsu NJ, Berenstein A. Angiographic findings in two cases of aneurysmal malformation of vein of Galen prior to spontaneous thrombosis: therapeutic implications. *AJNR Am J Neuroradiol* 1992;13(5):1446–50.
 79. Kuroki K, Uozumi T, Arita K, Takechi A, Matsuura R, Fujidaka M. Spontaneous disappearance of an aneurysmal malformation of the vein of Galen. *Neuroradiology* 1995;37(3):244–6.
 80. Nikas DC, Proctor MR, Scott RM. Spontaneous thrombosis of vein of Galen aneurysmal malformation. *Pediatr Neurosurg* 1999;31(1):33–9.
 81. Meyers PM, Halbach VV, Phatouros CP, et al. Hemorrhagic complications in vein of Galen malformations. *Ann Neurol* 2000;47(6):748–55.
 82. Mickle JP, Quistling RG. The transthoracic embolization of vein of Galen aneurysms. *J Neurosurg* 1986;64(5):731–5.
 83. Gailloud P, O'Riordan DP, Burger J, Lehmann CU. Confirmation of communication between deep venous drainage and the vein of Galen after treatment of a vein of Galen aneurysmal malformation in an infant presenting with severe pulmonary hypertension. *AJNR Am J Neuroradiol* 2006;27(2):317–20.
 84. Ashida Y, Miyahara H, Sawada H, Mitani Y, Maruyama K. Anesthetic management of a neonate with vein of Galen aneurysmal malformations and severe pulmonary hypertension. *Paediatr Anaesth* 2005;15(6):525–8.
 85. Head, neck, and brain tumor embolization. *AJNR Am J Neuroradiol* 2001;22(90080):145–5.
 86. Laurent A, Wassef M, Chapot R, Houdart E, Merland JJ. Location of vessel occlusion of calibrated tris-acryl gelatin microspheres for tumor and arteriovenous malformation embolization. *J Vasc Interv Radiol* 2004;15(5):491–6.
 87. Wakhloo AK, Juengling FD, Van Velthoven V, Schumacher M, Hennig J, Schwechheimer K. Extended preoperative polyvinyl alcohol microembolization of intracranial meningiomas: assessment of two embolization techniques. *AJNR Am J Neuroradiol* 1993;14(3):571–82.
 88. Latchaw RE. Preoperative intracranial meningioma embolization: technical considerations affecting the risk-to-benefit ratio. *AJNR Am J Neuroradiol* 1993;14(3):583–6.
 89. Kallmes DF, Evans AJ, Kaptain GJ, et al. Hemorrhagic complications in embolization of a meningioma: case report and review of the literature. *Neuroradiology* 1997;39(12):877–80.
 90. Rodesch G, Lasjaunias P. Embolization of meningiomas. In: Al-Mefty O, ed. *Meningiomas*. New York: Raven Press; 1991:285–97.
 91. Desai R, Bruce J. Meningiomas of the cranial base. *J Neurooncol* 1994;20(3):255–79.
 92. Nelson PK, Setton A, Choi IS, Ransohoff J, Berenstein A. Current status of interventional neuroradiology in the management of meningiomas. *Neurosurg Clin N Am* 1994;5(2):235–59.
 93. Ahuja A, Gibbons KJ. Endovascular therapy of central nervous system tumors. *Neurosurg Clin N Am* 1994;5(3):541–54.
 94. Kai Y, Hamada J-I, Morioka M, Yano S, Todaka T, Ushio Y. Appropriate interval between embolization and surgery in patients with meningioma. *AJNR Am J Neuroradiol* 2002;23(1):139–42.
 95. Eskridge JM, McAuliffe W, Harris B, Kim DK, Scott J, Winn HR. Preoperative endovascular embolization of craniospinal hemangioblastomas. *AJNR Am J Neuroradiol* 1996;17(3):525–31.
 96. Ng HK, Poon WS, Goh K, Chan MS. Histopathology of post-embolized meningiomas. *Am J Surg Pathol* 1996;20(10):1224–30.
 97. Perry A, Chicoine MR, Filiput E, Miller JP, Cross DT. Clinicopathologic assessment and grading of embolized meningiomas: a correlative study of 64 patients. *Cancer* 2001;92(3):701–11.

98. Luessenhop AJ, Spence WT. Artificial embolization of cerebral arteries. Report of use in a case of arteriovenous malformation. *JAMA* 1960;172:1153-5.
99. Wolpert SM, Stein BM. Catheter embolization of intracranial arteriovenous malformations as an aid to surgical excision. *Neuroradiology* 1975;10(2):73-85.
100. Kerber C. Balloon catheter with a calibrated leak. A new system for superselective angiography and occlusive catheter therapy. *Radiology* 1976;120(3):547-50.
101. Pevsner PH, Doppman JL. Therapeutic embolization with a microballoon catheter system. *AJR Am J Roentgenol* 1980;134(5):949-58.
102. Debrun GM, Vinuela FV, Fox AJ, Kan S. Two different calibrated-leak balloons: experimental work and application in humans. *AJNR Am J Neuroradiol* 1982;3(4):407-14.
103. Debrun G, Vinuela F, Fox A, Drake CG. Embolization of cerebral arteriovenous malformations with bucrylate. *J Neurosurg* 1982;56(5):615-27.
104. Dion JE, Duckwiler GR, Lylyk P, Vinuela F, Bentonson J. Progressive suppleen pursuit catheter: a new tool for superselective angiography and embolization. *AJNR Am J Neuroradiol* 1989;10(5):1068-70.
105. Jahan R, Murayama Y, Gobin YP, Duckwiler GR, Vinters HV, Vinuela F. Embolization of arteriovenous malformations with Onyx: clinicopathological experience in 23 patients. *Neurosurgery* 2001;48(5):984-95; discussion 95-7.
106. Halbach VV, Higashida RT, Dowd CF, Barnwell SL, Hieshima GB. Management of vascular perforations that occur during neurointerventional procedures. *AJNR Am J Neuroradiol* 1991;12(2):319-27.
107. Hademenos GJ, Massoud TF. Risk of intracranial arteriovenous malformation rupture due to venous drainage impairment. A theoretical analysis. *Stroke* 1996;27(6):1072-83.
108. Spetzler RF, Wilson CB, Weinstein P, Mehdorn M, Townsend J, Telles D. Normal perfusion pressure breakthrough theory. *Clin Neurosurg* 1978;25:651-72.
109. Pendarkar H, Krishnamoorthy T, Purkayastha S, Gupta AK. Pyogenic cerebral abscess with discharging sinus complicating an embolized arteriovenous malformation. *J Neuroradiol* 2006;33(2):133-8.
110. Pelz DM, Lownie SP, Fox AJ, Hutton LC. Symptomatic pulmonary complications from liquid acrylate embolization of brain arteriovenous malformations. *AJNR Am J Neuroradiol* 1995;16(1):19-26.
111. Kline JN, Ryals TJ, Galvin JR, Loftus CM, Hunter JH. Pulmonary embolization and infarction. An iatrogenic complication of transcatheter embolization of a cerebral arteriovenous malformation with polyvinyl alcohol sponge. *Chest* 1993;103(4):1293-5.
112. Horowitz MB, Purdy PD, Valentine RJ, Morrill K. Remote vascular catastrophes after neurovascular interventional therapy for type 4 Ehlers-Danlos Syndrome. *AJNR Am J Neuroradiol* 2000;21(5):974-6.
113. Hartmann A, Pile-Spellman J, Stapf C, et al. Risk of endovascular treatment of brain arteriovenous malformations. *Stroke* 2002;33(7):1816-20.
114. Jayaraman MV, Marcellus ML, Hamilton S, et al. Neurologic complications of arteriovenous malformation embolization using liquid embolic agents. *AJNR Am J Neuroradiol* 2008;29:242-246.
115. Kim LJ, Albuquerque FC, Spetzler RF, McDougall CG. Postembolization neurological deficits in cerebral arteriovenous malformations: stratification by arteriovenous malformation grade. *Neurosurgery* 2006;59(1):53-9; discussion 9.
116. Ledezma CJ, Hoh BL, Carter BS, Pryor JC, Putman CM, Ogilvy CS. Complications of cerebral arteriovenous malformation embolization: multivariate analysis of predictive factors. *Neurosurgery* 2006;58(4):602-11; discussion 11.
117. Meisel HJ, Mansmann U, Alvarez H, Rodesch G, Brock M, Lasjaunas P. Effect of partial targeted *N*-butyl-cyanoacrylate embolization in brain AVM. *Acta Neurochir (Wien)* 2002;144(9):879-87; discussion 88.
118. Probst EN, Grzyska U, Westphal M, Zeumer H. Preoperative embolization of intracranial meningiomas with a fibrin glue preparation. *AJNR Am J Neuroradiol* 1999;20(9):1695-702.
119. Chan RC, Thompson GB. Ischemic necrosis of the scalp after preoperative embolization of meningeal tumors. *Neurosurgery* 1984;15(1):76-81.
120. Adler JR, Upton J, Wallman J, Winston KR. Management and prevention of necrosis of the scalp after embolization and surgery for meningioma. *Surg Neurol* 1986;25(4):357-60.
121. Turner T, Trobe JD, Deveikis JP. Sequential branch retinal artery occlusions following embolization of an intracranial meningioma. *Arch Ophthalmol* 2002;120(6):857-60.
122. Friedrich H, Hansel-Friedrich G, Zeumer H. Intramedullary vascular lesions in the high cervical region: transoral and dorsal surgical approach. Two case reports. *Neurosurg Rev* 1990;13(1):65-71.
123. Takeuchi S, Tanaka R, Fujii Y, Abe H, Ito Y. Surgical treatment of hemangioblastomas with presurgical endovascular embolization. *Neurol Med Chir* 2001;41(5):246-51; discussion 51-2.
124. Cornelius JF, Saint-Maurice JP, Bresson D, George B, Houdart E. Hemorrhage after particle embolization of hemangioblastomas: comparison of outcomes in spinal and cerebellar lesions. *J Neurosurg* 2007;106(6):994-8.
125. Hong JW, Baik SK, Shin MJ, Choi HY, Kim BG. Successful management with glue injection of arterial rupture seen during embolization of an arteriovenous malformation using a flow-directed catheter: a case report. *Korean J Radiol* 2000;1(4):208-11.
126. Steinhubl SR, Talley JD, Braden GA, et al. Point-of-care measured platelet inhibition correlates with a reduced risk of an adverse cardiac event after percutaneous coronary intervention: results of the GOLD (AU-Assessing Ultra) multicenter study. *Circulation* 2001;103(21):2572-8.
127. Heidenreich JO, Hartlieb S, Stendel R, et al. Bleeding complications after endovascular therapy of cerebral arteriovenous malformations. *AJNR Am J Neuroradiol* 2006;27(2):313-16.
128. Carvi y Nieves M, Haas E, Hollerhage HG. Severe intracranial bleedings during endovascular procedures: outcome of surgically treated patients. *Neurol Res* 2007;29(1):81-90.
129. Halbach VV, Higashida RT, Hieshima GB, Norman D. Normal perfusion pressure breakthrough occurring during treatment of carotid and vertebral fistulas. *AJNR Am J Neuroradiol* 1987;8(5):751-6.
130. Luessenhop AJ, Ferraz FM, Rosa L. Estimate of the incidence and importance of circulatory breakthrough in the surgery of cerebral arteriovenous malformations. *Neurol Res* 1982;4(3-4):177-90.
131. Spetzler RF, Martin NA, Carter LP, Flom RA, Raudzens PA, Wilkinson E. Surgical management of large AVM's by staged embolization and operative excision. *J Neurosurg* 1987;67(1):17-28.
132. Andrews BT, Wilson CB. Staged treatment of arteriovenous malformations of the brain. *Neurosurgery* 1987;21(3):314-23.
133. Hansen PA, Knudsen F, Jacobsen M, Haase J, Bartholdy N. Indomethacin in controlling "normal perfusion pressure breakthrough" in a case of large cerebral arteriovenous malformation. *J Neurosurg Anesthesiol* 1995;7(2):117-20.
134. Zoarski GH, Lilly MP, Sperling JS, Mathis JM. Surgically confirmed incorporation of a chronically retained neurointerventional microcatheter in the carotid artery. *AJNR Am J Neuroradiol* 1999;20(1):177-8.
135. Mizoue T, Arita K, Nakahara T, Kawamoto H, Kurisu K. [A case of cerebral arteriovenous malformation with accidental migration of a microcatheter during endovascular procedure]. *No Shinkei Geka* 1997;25(5):443-6.
136. Ruckert RI, Bender A, Rogalla P. Popliteal artery occlusion as a late complication of liquid acrylate embolization for cerebral vascular malformation. *J Vasc Surg* 1999;29(3):561-5.
137. Bingol H, Sirin G, Akay HT, Iyem H, Demirkilic U, Tatar H. Management of a retained catheter in an arteriovenous malformation. Case report. *J Neurosurg* 2007;106(3):481-3.
138. Weber W, Kis B, Siekmann R, Jans P, Laumer R, Kuhne D. Preoperative embolization of intracranial arteriovenous malformations with Onyx. *Neurosurgery* 2007;61(2):244-52; discussion 52-4.

8. Extracranial Embolization

8.1. Introduction

Extracranial embolization procedures are therapeutic endovascular occlusions of vessels involved in vascular lesions outside the cranial cavity. Technically, this could involve everything in the known universe other than the brain, but, for the most part, this is used to denote head and neck embolizations in the external carotid territory. Beyond that, one can also arbitrarily include spinal vascular embolizations. This chapter covers a number of common trans-arterial embolization procedures in the extracranial circulation, and a few in the spine. Another blatantly arbitrary editorial decision is to include in this chapter percutaneous needle puncture and injection of acrylic glue or ethanol in various lesions, even though it is technically not a true endovascular procedure.

This chapter is divided into four major parts: First a brief discussion of indications and contraindications, then general techniques and devices for vascular access and embolization, followed by procedural issues specific to particular disease processes, and ending with a brief discussion of the complications. Each section discusses the topic from a standpoint of both head and neck procedures as well as spinal procedures.

8.2. Extracranial embolization: Indications and contraindications

There are many, many conditions in the head, neck and spine with abnormal vascularity that may benefit from an embolization procedure. These are some of the usual indications for endovascular treatment in the extracranial circulation, with some statement as to how often the average practitioner may expect to encounter the condition.

8.2.1. Indications: Head and neck embolization

1. Extracranial arteriovenous malformation (AVM) (uncommon)
 - (a) Superficial AVM
 - (b) Intraosseous AVM
 - (c) Diffuse AVM
 - (d) Intraorbital AVM
2. Superficial venous and lymphatic malformation (treated by direct puncture-sclerotherapy)
3. Extracranial arteriovenous fistula (AVF)
 - (a) Congenital fistula (Very rare)
 - (b) Dural AVFs (Covered in Chap. 7, Intracranial Embolization and Chap. 12, Venous Procedures)
 - (c) Post-traumatic fistulae (occasionally)
 - (d) Post-surgical fistulae (occasionally)
4. Bleeding
 - (a) Idiopathic epistaxis (exceedingly common)
 - (b) Post-traumatic (common)
 - (c) Post surgical (occasionally)
 - (d) Bleeding tumors (occasionally)
 - (e) Post-radiation changes (occasionally)
 - (f) Carotid blow-out syndrome (a particular combination of (c)–(e), above)

5. Extracranial vascular tumors, pre-operative embolization (common) or palliative embolization (rare)
 - (a) Juvenile nasopharyngeal angiofibroma
 - (b) Paraganglioma (aka chemodectoma, glomus tumor)
 - (c) A wide variety of other primary and metastatic vascular tumors.

8.2.2. Indications: Spinal embolization

1. Type I spinal dural arteriovenous fistula (dAVF) (not common, but not rare)
 - (a) Preoperative embolization
 - (b) Definitive embolization
2. Type II spinal intramedullary AVM (rare)
 - (a) Preoperative embolization
 - (b) Palliative embolization for symptom reduction
 - (c) Focused embolization of features at risk for bleeding (e.g., intranidal aneurysms)
3. Type III juvenile AVM (very rare)
 - (a) Palliative embolization for symptom reduction
4. Type IV perimedullary AVF (very rare)
 - (a) Definitive embolization
 - (b) Pre-operative embolization
5. Spinal vascular tumors:Pre-operative embolization
 - (a) Hemangioblastoma (rare)
 - (b) Primary bone lesions (e.g., aneurysmal bone cyst) (uncommon)
 - (c) Vascular metastatic tumors (e.g., renal cell cancer, thyroid cancer) (very common)

8.2.3. Relative contraindications

1. Feeding vessels feed eloquent structures (e.g., brain, eye, spinal cord)
2. Vascular anatomy that is difficult for endovascular access (e.g., exaggerated vessel tortuosity, vascular anomalies).
3. Significant atherosclerotic disease or high-flow vasculopathy affecting the parent vessel (e.g., occlusion or stenosis of the access vessel).
4. Life-threatening contrast allergy.
5. Coagulation disorders or heparin hypersensitivity.
6. Active bacterial infection (i.e., bacteremia at time of endovascular treatment).

8.3. Extracranial vascular access and embolization: Techniques and devices

8.3.1. Evaluation

1. History and physical.
2. Neurological exam.
3. Blood work (CBC, BUN, Creatinine, PT, PTT)
4. Imaging
 - (a) CT or MRI of the lesion
 - (b) CTA or MRA
 - (c) If possible, a catheter angiogram.
 - (d) Imaging considerations
 - Lesion location, potential territories at risk from the procedure, size and configuration.
 - Whether there is involvement of the skull or spine.
 - Flow patterns (e.g., high flow vs. low flow arteriovenous shunt).
 - Parent vessel anatomy.

- Angiographic architecture of lesion (e.g., nidus AVM vs. high-flow AVF vs. mixed lesion vs. tumor)
- Presence of associated vascular lesion (e.g., aneurysms, multiple AVMs or AVFs).
- Plan site of intended deposition of embolic material.
- Access vessel anatomy.
- Presence or absence of stenosis in the access vessel.

8.3.2. Treatment strategy

Prior to the case, preferably the previous day or earlier, the patient should be assessed and all the available imaging reviewed in preparation for the case. Decisions about the overall treatment strategy and the role of embolization in that strategy should be made well ahead of time. Plans should include:

1. Choice of access vessel
2. Guide catheter selection
3. Microcatheter and micro-wire selection
4. Embolic agent to be used
5. Target vessels to be treated
6. Staged multiple procedure vs. single embolization
7. Preparation for methods to ensure preservation of neurological function (e.g., provocative testing, neuophysiological monitoring)

8.3.3. Preprocedure preparation

1. Place a peripheral IV.
2. NPO for 6 h, except for medications.
3. Patients on insulin for hyperglycemia should get half their normal dose prior to the procedure.
4. Place Foley catheter.
5. Place thigh-high sequential compression device (SCD) sleeves on both legs for deep vein thrombosis prophylaxis.
6. Make sure that all devices that may be needed are available in the angio suite prior to the procedure.
7. Many practitioners routinely pre-treat patients with dexamethasone, 2 mg PO/IV Q 6h for 2–3 days before any tumor embolization procedure to attempt to reduce the risk of swelling.
8. *Patients with recent active hemorrhage:*
 - (a) Arterial line and large-caliber venous access are established prior to the procedure
 - (b) If airway is threatened, the patient should be intubated and ventilated.

8.4. Endovascular technique

The technique of extracranial embolization treatment varies considerably from case to case. The following is a general outline of the procedures and devices used by the authors of this handbook for most patients. The case is divided into a vascular *access* phase, a microcatheter *access* phase, and an *embolization* phase. Each phase requires choosing a system of devices and techniques to achieve the therapeutic goals

8.4.1. Awake or asleep?

Some operators prefer to use general anesthesia for embolization cases whereas others prefer to do them with the patient awake. Each approach has advantages. Use of glue or ethanol can cause considerable pain due to the toxic nature of these agents, and the pain makes it difficult for even sedated patients to remain motionless. General anesthesia can eliminate this discomfort and allows the operator to focus on

the procedure rather than on coaching and assessing the patient. It can make the procedure much more palatable for anxious patients. Another advantage of general anesthesia is that it allows for patient immobility including prolonged interruption of respiration while imaging tiny spinal vessels. The limited ability to monitor the neurological status of the patient during general anesthesia may be partially mitigated by the use of neurophysiological monitoring, such as somatosensory and/or motor evoked potentials.¹ Neurophysiological monitoring adds to the cost and complexity of the procedure, and may not be readily available or reliable, depending on the institution. However, the authors of this handbook find monitoring very useful for spinal embolization, and use it for virtually all embolization of intramedullary lesions, even in awake patients. Less complicated bone or paraspinal soft tissue tumor embolization can be easily done under local anesthesia with minimal sedation, and adequate image quality is possible in cooperative patients.

Embolization with the patient awake permits continuous neurological monitoring, eliminates the risks of general anesthesia, can shorten the length of the case, and is done in many centers. The authors of this handbook prefer to do most cases of extracranial embolization other than intramedullary spinal embolization awake with conscious sedation, to allow for provocative testing. Vascular navigation in the extracranial circulation is also much less challenging than in intracranial embolization procedures, so it is less critical that the patient remains motionless.

8.4.1.1. Awake

1. Patient is placed on the angiography table awake.
2. An abbreviated neurological exam is rehearsed with the patient prior to draping (e.g., patient is asked to say "methodist episcopal," show their teeth and gums, stick out their tongue, wiggle their toes, and wiggle their hands).
3. Throughout the case the patient is reminded to stay still. The patient's head can be lightly taped to the headholder with a piece of plastic tape across the forehead to remind him or her to stay still.
4. Sedation and analgesia may be increased during the access phase, but are kept to a minimum if provocative testing is done to facilitate the patient's full cooperation.

8.4.1.2. Asleep

1. Patient is placed under general anesthesia on the angiography table.
2. Most of these cases are done under anesthesia for pain control, so strict control of blood pressure is not critical. Therefore, an arterial monitoring line is not usually needed.
3. If using neurophysiological monitoring, baseline evoked potentials are obtained prior to any intervention. Depending on the anatomic location of the lesion, either somatosensory, motor, visual or auditory evoked potentials may be the most sensitive for monitoring functional status during the procedure. The authors of this handbook routinely use monitoring for procedures involving the spinal cord.

8.4.2. Vascular access phase

For extracranial embolization procedures, this phase involves accessing the arterial system and placing a guide catheter in a position proximal to the lesion being treated.

1. The vast majority of cases are done using femoral arterial access and only rarely brachial, radial, or very rarely direct puncture of the vessel of interest may be necessary.
2. Dorsalis pedis and posterior tibialis pulses are assessed and marked.
3. The right or left groin is prepped, draped, and infiltrated with local anesthesia.
4. A 5-French sheath is placed in the femoral artery for most cases.
 - (a) A 6-, or rarely, 7-French sheath should be used if the need for proximal balloon catheters is anticipated.
 - (b) Much larger sheaths may be needed if a stent-graft will be used.

- (c) Sheaths are available in various lengths, most commonly 10 or 25 cm. The 25-cm version has the advantage that it bypasses any tortuosity in the iliac arteries. Having the distal end of the sheath in the aorta prevents any danger of injuring the iliac artery during catheter introduction through the sheath.
 - (d) Ninety centimeter sheaths such as the Shuttle® (Cook Inc., Bloomington, IN) can reach the carotid or subclavian and can be used as a large-lumen guiding catheter or added stabilization for a standard guiding catheter (see below).
5. An angiogram is done using a diagnostic catheter. Angiograms of the access vessel (carotid or subclavian artery) and PA and lateral views of the circulation in and around theregion of the lesion are done prior to the intervention.
- (a) Examination of the carotid or subclavian artery is necessary for guide catheter selection, and to check for the presence of atherosclerosis and fibromuscular dysplasia.
 - (b) Intracranial imaging at the beginning of the case should be done if working in the carotid or vertebral for comparison later, to assess for later arterial thromboembolic complications or potential collateral supply to the lesion.
6. Systemic anticoagulation.
Thromboembolic complications can occur during any vascular catheterization. The senior author of this handbook favors universal use of systemic heparin for all embolization procedures whereas the junior author almost never uses heparin. Systemic anticoagulation with IV heparin appears to carry relatively little risk in patients without active bleeding, and judicious use of heparin appears to be of relatively low-risk particularly since the drug can be rapidly reversed with protamine.
- (a) Dosing for heparin
 - A loading dose of IV heparin is given (70 U kg⁻¹) and 5 min later, a 1–3 ml specimen of blood for an activated clotting time (ACT) is drawn from the sheath. The guide catheter is placed in the feeding vessel only after the heparinization is therapeutic (usually 5 min or more after the IV loading dose is given, or after the ACT has been found to be in the target range). The ACT should be kept between 250 and 300 s for the duration of the procedure. Additional doses of heparin are necessary only during cases that last longer than several hours.
 - (b) Protamine on stand-by
 - A syringe containing protamine, enough to reverse the total amount of heparin the patient has received, should be constantly available in the endovascular suite for easy access to the operator, should hemorrhage occur during the case.
 - Dose of protamine required to reverse heparin: 10 mg protamine per 1,000 U heparin.
 - (c) Other antithrombotic agents
 - Antiplatelet agents. The authors do not recommend routine use of antiplatelet medications for most extracranial embolizations.
 - Other designer antithrombotics can be used in patients with heparin contra-indications but for most extracranial embolization, it may be simpler and equally safe to avoid using heparin altogether.
7. Guidewire selection for vascular access
- Most commonly, 0.038 J-tip wires (“Safety wires”) are used for sheath placement.
 - Steerable hydrophilic wires such as 0.035 or 0.038 in. angled Glidewire® (Terumo Medical, Somerset, NJ) can be used to advance a guiding catheter into the desired carotid or vertebral.
 - Exchange-length (at least 270-cm long) wires may be needed to exchange a curved diagnostic catheter for a straight guide catheter. The authors frequently use the 0.035-in. diameter, 300-cm long Storq® wire (Cordis Endovascular, Miami Lakes, FL).
8. Guide catheter selection.
Guide catheters are helpful to achieve successful performance of any embolization procedure, since they provide a stable platform to send soft, flexible microcatheters into the smaller distal vessels.
- (a) Each guide catheter has its advantages and disadvantages and the best catheter may vary, depending on the situation. These are the usual catheters used for extracranial embolization.

- Envoy® (Cordis Neurovascular, Miami Lakes, FL)
 - *Advantages.* Relatively rigid, provides a good platform in tortuous vessels, larger internal lumen than most other guide catheters. Non-hydrophilic coating may be more stable in the vessel.
 - *Disadvantages.* Stiff, and traumatic to the vessel wall. May be more thrombogenic than hydrophilic coated catheters.²
 - Guider Softip™ XF guide catheter (Boston Scientific, Natick, MA)
 - *Advantages.* Soft, atraumatic tip. Minimizes risk of vasospasm and dissection in narrow, tortuous vessels.
 - *Disadvantages.* Relatively flimsy and slippery with hydrophilic coating, prone to fall into the arch when the vasculature is tortuous.
 - Shuttle® (Cook Medical, Bloomington, IN)
 - *Advantages:* A 90-cm sheath that can access the carotid or vertebral. Very large internal lumen. Inner dilator gives smooth transition to a 0.038-in. wire for smooth advancement. Various 105-cm long curved inner catheters are available to facilitate selection of vessels from the aortic arch. Very rigid and very stable. Can use an inner 100 cm or longer guide catheter to create an even stiffer “Tower of Power.”
 - *Disadvantages:* Big, stiff sheath can be traumatic to the vessel. Not easily used in tortuous vessels. Care must be taken to keep large internal lumen flushes with heparinized saline because large amounts of blood collecting in lumen can create very large thrombi.
- (b) Guide catheter size
- Length: Should be enough to access the vessel of choice with little excess hanging out of the groin sheath. This maximizes the distance the microcatheter can be advanced in the intracranial vessels. For the average sized patient, a 90 cm length works well to access the internal carotid or vertebral.
 - Diameter: 5-French outer diameter for most cases allows enough support and adequate internal diameter to place the microcatheter and have sufficient clearance to flush and inject contrast.
 - High-support 6 or 7 French if the need for added support is anticipated.
 - Diagnostic 5 or even 4-French catheters can be used as a guide catheter in children or smaller adults. A catheter that accepts at least a 0.038-in. wire will accommodate a microcatheter, although it is less stable than a dedicated guide catheter.
 - The authors particularly like the 4-French Berenstein II (Cordis Endovascular, Miami Lakes, FL) for external carotid territory embolizations because it can easily be placed in the distal external carotid or even super-selectively in individual branches with little trauma to the vessels. This distal positioning provides a stable platform in spite of the small outer diameter of the catheter. It acts like a mini-Envoy®.
- (c) Straight or angled?
- Straight guide catheter is useful in relatively straight vessels, or in situations where the guide catheter will be gently navigated through a convoluted vessel over a wire or co-axially over a microcatheter.
 - Usually requires exchanging (see below).
 - Preferred for the smaller vessels.
 - Preferred for glue embolization since an angle can cause the tip of the guide catheter to indent the microcatheter, and can squeeze (“milk”) glue out of the microcatheter if it is pulled back through the guide catheter.
 - The Angled guide catheter is useful when the final position of the catheter tip is in a vessel curve
 - Angled catheters are much easier to navigate through the aortic arch than straight catheters.
- (d) Spinal guide catheters: catheters used for embolization in intercostal or lumbar arteries. The guide catheters needed for spinal embolizations have two special characteristics: First, they have complex curves that allow the catheter to have relatively stable positioning in the

transversely-oriented spinal branches, and second, they are relatively short catheters (60–80 cm long) since that is all that is needed to access these vessels.

- Standard spinal angiographic catheters like 5-French Mikaelson and Simmons (Merit Medical, South Jordan, UT) are complex-curved catheters which can readily engage side-branches of the aorta.
 - *Advantages:* Reverse curve provides stability in transverse branches of the aorta. Non-hydrophilic coating may be more stable in the vessel.
 - *Disadvantages:* Catheters are somewhat soft and may back out and disengage from vessel as a microcatheter is coaxially advanced through it. Microcatheters fit tightly in these catheters, so cannot usually inject contrast through the catheter while microcatheter is in place.
 - 4-French angled Glidecath® (Terumo Medical, Somerset, NJ)³ or 4-French Berenstein II (Cordis Endovascular, Miami Lakes, FL)⁴ can be advanced distally into the intercostal or lumbar arteries. Most commonly a standard spinal angiographic catheter first engages the desired vessel and is exchanged for the 4-French catheter using an exchange wire.⁴
 - *Advantages:* Soft, atraumatic tip. Minimizes risk of vasospasm and dissection in narrow, tortuous vessels. If placed distally in the segmental vessel, it is a fairly stable platform for the advancement of a 10-system microcatheter.
 - *Disadvantages:* Relatively flimsy and prone to become displaced, especially when the vasculature is tortuous. Requires the use of an exchange wire to access the lumbar or intercostal artery. Larger caliber microcatheters may not easily pass through these catheters. Even small microcatheters are a tight fit and it is not possible to inject contrast around the microcatheter.
 - 6 or 7 French coronary guide catheters like the Runway™ (Boston Scientific, Natick, MA) can be obtained with various curves such as the Amplatz left or allRight™ curve that can engage segmental spinal vessels.
 - *Advantages:* Very stable platform. Gigantic internal lumen. Will accept various devices and microcatheters with room to spare for contrast injections.
 - *Disadvantages:* Big, stiff catheters can be traumatic to the vessel and not easily used in tortuous vessels. May not engage vessels that arise at a sharp angle from the aorta. Often require the use of an exchange wire to access the vessel of interest.
 - Standard 5- or 6-French neuro guide catheters such as the Envoy® (Cordis Neurovascular, Miami Lakes, FL) or Guider Softip™ XF (Boston Scientific, Natick, MA) work well if spinal vessels in the cervical or upper thoracic region are to be accessed through subclavian artery branches.
9. Catheter flushing technique was discussed in Chap. 2. Although some practitioners advocate double flushing of catheters only in the supra-aortic vessels, it makes more sense to use meticulous flushing technique anywhere in the vascular system. This ensures that one will not forget to use good technique when it is most needed. Moreover, thrombus or air emboli in spinal cord vessels can be just as devastating as cerebral ischemia.
10. Guide catheter placement technique: Head and neck region
- (a) Direct navigation method
 - Useful in young patients with non-tortuous, non-atherosclerotic vessels
 - The catheter is flushed with heparinized saline
 - If a long dilator is available for the guide catheter (as with the Shuttle™ or Northstar™ Cook Medical, Bloomington, IN), the dilator is inserted into the guide catheter and flushed
 - A rotating hemostatic valve with a continuous saline infusion is attached to the hub
 - Advance a wire to the very tip of the guide catheter to stiffen it and allow passage through the valve in the hub of the sheath

- Sometimes, in younger patients, even a straight guide catheter can be manipulated into the vessel of choice using a curved, steerable wire such as the 0.038-in. Glidewire® (Terumo Medical, Somerset, NJ)
 - An angled guide catheter can usually be gently navigated directly into the carotid or subclavian artery over a 0.035- or 0.038-in. hydrophilic wire
- (b) Exchange method
- Useful in patients with tortuous anatomy, atherosclerosis, or fibromuscular dysplasia. This technique can minimize the risk of injury to the carotid or subclavian artery, particularly at the vessel origin.
 - A 5-French diagnostic catheter is guided into the vessel of choice over an exchange-length (270–300 cm) wire.
 - The tip of the wire is advanced into a distal branch of the ECA or into the distal subclavian artery using roadmapping technique.
 - The diagnostic catheter is then gently removed while the tip of the exchange wire is continuously visualized on fluoroscopy.
 - The wire is wiped down with a dripping-wet Telfa sponge.
 - The guide catheter is advanced over the wire while continuously visualizing the tip of the wire.
- (c) Guide catheter positioning
- Carotid system. Using roadmapping, the guide catheter is advanced over a hydrophilic wire into the ECA into a straight segment proximal to the origin of the branch feeding the lesion. A “high position” of the guide catheter will maximize the stability of the guide and improves control over the microcatheter and microwire. In cases supplied by proximal branches of the ECA like the ascending pharyngeal, it may be necessary to position the tip of the guide catheter in the distal segment of the common carotid. In an ECA with a significant curve in the vessel, the guide can be adequately positioned immediately proximal to the curve. Moderate curves in the vessel usually cannot be straightened out by guiding a relatively stiff catheter around them, and will usually cause spasm or even dissection. Therefore, it is better to accept a relatively proximal position. If added stability is desired, a relatively stiff 0.014-in. wire can be advanced through the guide catheter as a “buddy wire,” and if the catheter has a large enough lumen, a microcatheter can be advanced along-side it. The “buddy wire” will help keep the guide catheter in place.
 - Subclavian artery. Using roadmapping, the guide catheter is positioned in the proximal artery and advanced toward the desired feeding artery. The thyrocervical and costocervical trunks may sometimes be directly catheterized with a guide catheter, but more often, it must be placed in the proximal subclavian and those branches catheterized with a microcatheter as necessary.
 - Once the catheter is in position, a gentle injection of contrast through the guide catheter under fluoroscopy is done, to examine the configuration of the vessel around the tip and to check for the presence of vasospasm or vessel dissection around the tip. If catheter tip-induced vasospasm is present and flow-limiting, withdrawal of the catheter tip by several millimeters is often sufficient to restore flow.
 - The catheter tip may slide up and down and rub against the vessel wall with each heart beat; be sure to take this into account when positioning the catheter.
11. Guide catheter placement technique: Segmental spinal vessels
- (a) Direct navigation method
- Useful in young patients with non-tortuous, non-atherosclerotic vessels, and when using a catheter with a complex, reverse curve shape.
 - The catheter is flushed with heparinized saline.
 - If a peel-away straightener is supplied with the catheter, position the straightener at the distal end of the catheter to straighten the curve and facilitate insertion in the sheath.
 - A rotating hemostatic valve with a continuous saline infusion is attached to the hub of the catheter.

- Advance a wire to the very tip of the guide catheter to stiffen it and allow passage through the valve in the hub of the sheath.
 - Insert the catheter over the wire through the sheath and into the abdominal aorta.
 - If the wire can easily be advanced into the contralateral iliac artery or a renal artery, the curve of the complex curve catheter (e.g., Mikaelson or Simmons) may be formed by advancing the catheter to just engage the renal or iliac, then withdraw the wire into the catheter and gently push and rotate the catheter to form the curve.
 - Alternatively, the shape of the catheter may be reconstructed by advancing it to the aortic arch. When the wire is pulled back it usually reforms as the catheter is rotated.
 - Withdraw the wire completely and double flush the catheter with heparinized saline.
 - The catheter is gently rotated and manipulated to the spinal level of interest, and with small puffs of contrast is manipulated to the origin of the segmental vessel to be catheterized.
 - As the catheter is gently pulled back, it should then advance into the segmental vessel for a centimeter or two to obtain a stable position.
 - If it does not advance into the vessel when pulled back, sometimes it may be necessary to park it at the origin of the vessel and attempt to select the vessel with a coaxially placed microcatheter advanced distally in the vessel over a microwire. Once the microcatheter and wire are positioned distally, it may allow the guide catheter to be pulled back, advanced forward, or rotated *very gently* to get the guide catheter into a more stable position. Too vigorous a movement could displace the catheter back into the aorta.
 - Occasionally, in younger patients with large segmental spinal arteries, even a simple curve catheter can be manipulated into the vessel of choice using a curved, steerable wire such as the 0.038-in. Glidewire® (Terumo Medical, Somerset, NJ).
- (b) Exchange method
- Useful when using a 4-French catheter as a guiding catheter, and also often when using larger coronary-type guide catheters.
 - A 5-French diagnostic spinal catheter is guided into the vessel of choice over an exchange-length (270–300 cm) wire, usually a hydrophilic wire like Glidewire® (Terumo Medical, Somerset, NJ).
 - The tip of the wire is advanced into a distal branch of the segmental spinal artery using roadmapping technique.
 - The diagnostic catheter is then gently removed while the tip of the exchange wire is continuously visualized on fluoroscopy.
 - The wire is wiped down with a dripping-wet Telfa sponge.
 - The guide catheter is advanced over the wire while continuously visualizing the tip of the wire.
- (c) Optimizing guide catheter positioning in spinal cases
- This can be a huge problem in spinal embolization cases given the continual movement of the vessels with respiration and the fairly proximal catheter position that must be accepted in many of these cases. In a lumbar or intercostal vessel with a significant proximal curve in the vessel, the guide catheter may easily advance beyond the origin of the vessel. Moderate curves in the vessel usually cannot be straightened out by guiding a relatively stiff catheter around them, and will usually cause spasm or even dissection. Therefore it is better to accept a relatively proximal position. If added stability is desired, a relatively stiff 0.014-in. wire can be advanced through the guide catheter as a “buddy wire,” and if the catheter has a large enough lumen, a microcatheter can be advanced along-side it. The “buddy wire” will help keep the guide catheter in place.
 - Buddy wires cannot be used when 5-French or smaller catheters are used as guide catheters.
 - Many times only very tenuous catheter positioning is possible, and one must keep an eye on the guide catheter position *constantly* during the case and gently adjust its position as necessary.

12. Guide catheter irrigation
 - (a) Continuous irrigation of the guide with heparinized saline (5,000 U heparin per 500 mL saline) is important.
 - (b) A three-way stopcock connects the heparinized saline flush-line to a rotating hemostatic valve (RHV) to allow continuous infusion of saline through the guide while microcatheters or other devices are being inserted. The authors of this handbook attach a large-bore one-way stopcock between the RHV and the guide catheter to allow control of back-bleeding if the RHV is opened.
 - (c) *Warning:* If a large-bore stopcock is used between RHV and guide catheter, do not attempt to close the stopcock when wires or microcatheters are in place in the guide catheter. They can be severely damaged.
 - (d) A rotating adapter on the stopcock is needed to prevent the stopcock from being a drag on free manipulation of the catheter. Using both a rotating three-way stopcock and a rotating hemostatic valve on the catheter allows for two pivot points to allow free rotation of the catheter.
 - (e) Meticulous attention to the guide catheter RHV throughout the case is necessary to identify thrombus or bubbles, should they appear.
 - (f) The heparinized saline drip should be periodically monitored to ensure that it is dripping slowly, but continuously, and there is still sufficient fluid in the saline bag to last for the case.
13. Contrast injections. Frequent small injections (“puffing”) of contrast can be used to help manipulate the catheter into the desired arteries, especially with spinal segmental vessels. A 20-mL syringe containing contrast can be left attached to the catheter for these injections, and then used immediately for hand injections of contrast for angiographic runs. As is done in the cerebral vasculature, the syringe is held vertically and care taken not to allow bubbles to enter the catheter. Spinal vessels or individual external carotid branches are best imaged with hand injections of contrast, to allow for modulation of the injection rate and volume, depending on the size of the vessel and stability of the catheter. Larger vessels (carotid or subclavian) may require power injections of contrast for good angiographic runs.
14. Maintaining guide catheter position
 - (a) It is vitally important to fluoroscopically monitor the position of the guide catheter periodically during the microcatheter access phase and embolization phase of the procedure.
 - (b) The guide catheter may become displaced during microcatheter manipulation, which can result in kinking of the microcatheter, can make it difficult to access the desired microcatheter position and can cause sudden, undesired displacement of the microcatheter.
 - (c) Guide catheter position can be easily monitored with biplane angiographic systems, by having at least one imaging plane including the tip of the guide catheter.
 - (d) Any displacement of the guide catheter tip should be corrected, and, if the catheter appears to be unstable, replacement with a more stable guide catheter system should be considered.

8.4.3. Microcatheter access phase

Once a stable guide catheter position is achieved, a microcatheter is coaxially advanced to a position from which embolic material can be delivered to the target lesion.

1. Roadmap guidance

Very helpful for fast and effective vascular catheterization

 - (a) Contrast is injected and a mask image of the vascular tree is saved, and superimposed digitally on the live fluoroscopic image.
 - (b) Roadmapping ensures safe and expeditious navigation through the potentially complicated and tortuous vascular anatomy.
 - (c) Biplane roadmapping is best.
 - (d) 3D roadmapping is available on newer angiographic suites.
 - (e) If the patient moves or if a different projection is required to negotiate a turn, another roadmap mask can be obtained.
 - (f) Roadmapping is less helpful in catheterizing the intercostal and lumbar arteries, since respiratory motion and/or peristaltic movement in the intestines degrade the image.

2. Microcatheter selection

- (a) There are many microcatheters, and the optimal choice depends on how large or how distal the target vessel is, what embolic agent will be used, and the training and experience of the operator.
- (b) Microcatheters for extracranial embolization:
 - Over the wire microcatheters. These are by far the most common and are quite sufficient for nearly all procedures.
 - Examples: Excelsior® 10–18 (Boston Scientific, Natick, MA) Prowler® (Cordis Neurovascular, Miami Lakes, FL), Echelon™ (ev3, Irvine, CA)
 - Flow-directed microcatheters. These are so flexible distally that they are ideal for catheterizing very small vessels in an atraumatic fashion. However, they are quite flimsy and unstable and are rarely used for extracranial embolization, except in some spinal AVM cases.
 - Examples: Magic® (AIT-Balt, Miami, FL) Marathon™ or Ultraflow™ (ev3, Irvine, CA)
 - Steerable microcatheters. These are the least common and are basically over-the-wire catheters that have the added benefit of a steerable tip of the microcatheter.
 - Example: Pivot™ (Boston Scientific, Natick, MA).
- (c) Two-marker, over-the-wire microcatheters, rather than single-marker catheters, are necessary for the use of detachable coils. The two markers in microcatheters used in detachable coils are always 3 cm apart to determine that the coil is properly deployed. This feature can also be used for calibration and measurements. These two markers may make the distal 3 cm minimally stiffer than one marker catheters, but do not preclude the use of embolic agents other than detachable coils.
- (d) See Chap. 7 for more detail on microcatheters.

3. Microwire selection

- (a) A wide variety of microwires is available, with differing properties such as size, softness, visibility on fluoroscopy, shapeability, and steerability, trackability, and torque control.
- (b) All microwires suitable for neuro-endovascular procedures are hydrophilically coated to reduce friction.
- (c) Wires can have a shapeable distal tip or may come pre-shaped from the manufacturer.
- (d) Shapeable tips are usually made of platinum, which makes it quite visible on fluoroscopy.
- (e) Sizes of microwires range from 0.008 in. for the tiny Mirage™ (ev3, Irvine, CA) to a variety of 0.010 in. and even more 0.014-in. wires up to the robust 0.016-in. Headliner™ (Terumo Medical Corporation, Somerset, NJ). Larger diameter wires are available, but are generally a tight fit in commonly used microcatheters and are too stiff for navigation in small vessels.
- (f) In general, 0.014-in. wires are used for extracranial embolizations, since they are torquable and will be compatible with most over-the-wire microcatheters.
- (g) The Synchro® or Transend® (Boston Scientific, Natick, MA) are very flexible, maneuverable wires that work efficiently in most instances.
- (h) The authors of this handbook often use the slippery and atraumatic J-tip Headliner™ (Terumo Medical Corporation, Somerset, NJ) in tortuous external carotid branches.

4. Microcatheter irrigation

- (a) Continuous irrigation of the microcatheter as well as the guide catheter with heparinized saline (5,000U heparin per 500 mL saline) is important.
- (b) A 3-way stopcock connects the heparinized saline flush-line to a rotating hemostatic valve (RHV) to allow a continuous infusion of saline.
- (c) Heparinized saline infusion ensures hydration of the hydrophilic coating on the microwire and minimizes friction.
- (d) Meticulous attention to the microcatheter (and guide catheter) RHV throughout the case is necessary to identify thrombus or bubbles, should they appear.
- (e) The heparinized saline drip should be periodically monitored to ensure that it is dripping slowly, but continuously, and there is still sufficient fluid in the saline bag to last for the case.

5. Microcatheter/microwire assembly preparation
 - (a) The chosen microcatheter is removed from its package, maintaining sterile technique.
 - (b) The plastic hoop housing the microcatheter is flushed to hydrate the hydrophilic coating.
 - (c) If necessary, the tip of the microcatheter can be steam shaped over the small mandrel that usually comes packaged with the catheter.
 - (d) The hub of the microcatheter is attached to an RHV and the lumen of the RHV and microcatheter are flushed with heparinized saline to purge all air from the system.
 - (e) A three-way stopcock is attached to the RHV, and tubing for a continuous infusion of heparinized saline is attached to the stopcock.
 - (f) Using a wire introducer (which looks like a long, hollow, flat-tipped needle) the chosen microwire tip on a shapeable wire may be shaped by gently pulling the distal 5–10 mm, of the wire across the shaft of the introducer to curve the wire. The more firmly the wire is pulled across the introducer, the sharper the curve on the wire will be.
 - (g) The shaped wire is then inserted in the introducer, the introducer is inserted through the RHV down to the hub of the microcatheter, and the microwire is carefully inserted into the microcatheter.
 - (h) If a very tight curve, such as a J-shaped tip is desired, some difficulty may be encountered when trying to insert it into the wire introducer. It may be easier to first insert the microwire all the way into the microcatheter, extend the tip of the wire beyond the tip of the microcatheter, shape the wire, then pull it back to the tip of the microcatheter.
 - (i) Alternatively, one can insert the wire into the introducer, then, with the tip of the wire extending out beyond the tip of the introducer, use a second introducer to shape the tip. The wire is then pulled back such that its tip is just inside the introducer, the wire/introducer assembly is inserted through the RHV and the wire can then be inserted into the microcatheter.
 - (j) Once the microwire is well into the microcatheter, the wire-introducer can be pulled out of the RHV and removed from the wire.
 - (k) The RHV on the microcatheter is tightened slightly to ensure easy passage of wire in (or out of) the microcatheter, but without leakage of saline back out of the valve. This will ensure that the lumen of the microcatheter is perfused with heparinized saline without any back-up of blood into the microcatheter.
 - (l) Once the microwire is inserted to the tip of the microcatheter, a torque device is attached to the microwire, and all connections and infusions are checked, the assembly is ready to be advanced into the RHV of the guide catheter.
6. Over-the-wire microcatheter placement technique.

These systems are by far the most commonly used for delivery of most embolic agents, for many different pathological conditions. The smaller “10-size” microcatheters are fairly flexible, although not as flexible as flow-directed microcatheters. Larger “14-size” are stiffer, and the “18-size” systems are extremely stiff, but have a much larger lumen. The over-the-wire microcatheter is most appropriate for nearly all extracranial catheterizations and definitely where large particles or microcoils are the embolic agent of choice. If Onyx[®] (ev3, Irvine, CA) is contemplated as an embolic agent in the case, a DMSO-compatible microcatheter must be used.

 - (a) Virtually all over-the-wire microcatheters have hydrophilic coating and come packaged in a plastic hoop that can be flushed with sterile heparinized saline to hydrate the coating.
 - (b) Attach an RHV and gently but thoroughly flush the system to purge all air.
 - (c) Using a wire introducer, carefully insert a suitable microwire (usually 0.014 in.) through the RHV and into the microcatheter to its distal tip. The authors use the 0.014 in. Synchro[™] Soft wire (Boston Scientific, Natick, MA) for many cases.
 - (d) For atraumatic and quick navigation through tortuous branches like the distal internal maxillary or occipital, the 0.012 in. J-tip Headliner[™] (Terumo Medical Corporation, Somerset, NJ) works well to stay in the main vessel around the curves. It is less useful for selecting side branches than other wires.

- (e) If not pre-shaped, an appropriate curve on the microwire, usually a 70–90° curve or slightly J-shaped curve, allows selection of desired branches.
- (f) A torque device must be attached to the proximal end of the microwire. This allows torquing of the wire to rotate the distal curved tip. It also allows controlled advancement and withdrawal of the wire.
- (g) Carefully insert the microcatheter into the RHV of the guide catheter and advance it to the distal tip of the guidecatheter. Both the Echelon™ and Rebar® (ev3, Irvine, CA) have a marker on the shaft of the catheter that indicates that the tip is approaching the tip of a 90 cm guide catheter, to limit the need for fluoroscopy up to that point.
- (h) Under-roadmap guidance, carefully advance the microwire into the vascular system, and follow with the microcatheter.
- (i) In straight segments of the vessel, the catheter tip can be advanced beyond the wire, which limits the risk of vessel damage or perforation.
- (j) Around sharp turns or where the vessel branches, the microwire is carefully guided around the curve by rotating the wire.
- (k) Fixing the microwire in space, the microcatheter can be advanced over the wire and around turns.
- (l) To break the friction between microcatheter and microwire, the wire can be gently pulled back and/or rotated.
- (m) The guide catheter position should be monitored periodically during microcatheter positioning, since any resistance to forward motion of the microcatheter will inevitably create back-pressure on the guide catheter.
- (n) Periodically during catheter positioning, and certainly once the desired catheter position is reached, gently pull back slightly on the microcatheter to remove any redundancy.
- (o) Also periodically check that the heparinized saline flush lines attached to the guide catheter and microcatheter are dripping and bubble-free.
- (p) When the microcatheter reaches the desired location, carefully remove the wire and observe the tip of the microcatheter fluoroscopically, since moving the wire can often release stored energy in the microcatheter, causing it to move (usually forward).
- (q) Gently inject a small amount of contrast through the microcatheter to confirm catheter positioning, and also to confirm patency of the microcatheter. Too much resistance during injection could indicate kinking of the microcatheter. This kinking should be resolved by pulling back on the catheter before proceeding further. Injection of contrast or embolic material in a kinked catheter can result in catheter rupture, which can be a disaster.
- (r) When all slack is removed, perform a high-resolution superselective arteriogram.
- (s) Carefully evaluate the superselective arteriogram to determine:
 - Whether the desired position has been reached
 - Whether there are no dangerous anastomoses filling
 - The flow-rate in order to choose an embolic agent and the injection rate needed
 - That there is no sign of contrast exiting the microcatheter proximal to the distal tip. This would indicate that the microcatheter has been irreparably damaged or even ruptured and must not be used for embolization
 - Once the microcatheter is in position, and confirmed by superselective arteriography, provocative testing may be performed if necessary (see below). Otherwise, the embolization phase may begin (also see below)

7. Flow-directed microcatheter placement technique

These systems are most commonly used for liquid embolic delivery, usually in the setting of an AVM or AVF. The high flow state in these conditions greatly facilitates rapid and accurate placement of the microcatheter to the desired position. However, in the extracranial circulation, flow rates are less than those in the intracranial circulation, even in hypervascular lesions. Therefore, the flow-directed characteristics of these microcatheters do not assist navigation in the extracranial circulation to any great extent. These catheters can still be used, but technique is virtually the same as that for over-the-wire microcatheters, except that 0.010 or smaller microwires must be used. Again, if Onyx® (ev3, Irvine, CA) is to be used as an embolic agent in the case, a DMSO-compatible microcatheter must be used.

8. Steerable microcatheter positioning.
 These microcatheters are rarely, if ever needed for extracranial embolization. They are most appropriate for coil embolization. Their positioning technique is very similar to over-the-wire technique, with a number of idiosyncrasies, given the special steerable characteristics of the catheter. The Pivot™ (Boston Scientific, Natick, MA) is a radically different microcatheter, although its availability is somewhat limited at the time of this writing. It is virtually the only true steerable microcatheter available (and even it is not readily available at the time of this writing). Further discussions on the use of this microcatheter are in Chaps. 5 and 7.
9. Provocative testing (see Chap. 6) is done in an effort to confirm that the vessel being embolized does not supply dangerous anastomoses to the central nervous system or cranial nerves. Pharmacologic agents such as amobarbital and lidocaine are injected in the vessel prior to embolization and the patient is tested for new signs of neurological dysfunction. Amobarbital injections test for nerve cell body supply in the central nervous system and lidocaine injections test for nerve axons such as cranial nerves.⁵ Most practitioners use this testing on awake patients, although it can be done while the patient is under general anesthesia using neurophysiological monitoring with electroencephalography (EEG), somatosensory evoked potentials (SSEP), brainstem evoked responses (BAER) and/or motor evoked potentials (MEP).^{1, 6, 7} Monitoring is not free from false negatives¹, and the practitioner should never be lulled into a false sense of security even when testing suggests it is safe to embolize, since the pharmacological agents can go preferentially by flow to the abnormal territory. This is especially true in high flow lesions such as AVM or AVF. The authors of this handbook caution that careful attention to angiographic signs on superselective angiography may be just as sensitive as provocative testing to rule out normal territories at risk. The technique for this testing is as follows:
 - (a) Once the microcatheter is in proper position and slack has been removed, provocative testing can begin.
 - (b) Remove the rotating hemostatic valve on the microcatheter, and connect a three-way stopcock to the microcatheter.
 - (c) Using a wet-to-wet connection, connect the labeled 3–5-ml amobarbital (25 mg ml⁻¹) syringe to the stopcock attached to the microcatheter.
 - (d) Hold the syringe vertical, such that any bubbles rise away from the catheter.
 - (e) In awake patients, place a sterile half-sheet over the sterile field over the patient's thorax, to prevent contamination of the field during testing.
 - (f) Inject the amobarbital (usually 30–50 mg, depending on vessel size and flow-rate) over approximately 5 s into the vessel via the microcatheter.
 - (g) Immediately disconnect the labeled amobarbital syringe, attach a 3-ml syringe and flush with several milliliters of heparinized saline to remove any amobarbital left in the catheter.
 - (h) Ask the patient if he or she feels anything abnormal, then do a brief neurological examination, paying particular attention to functions at risk from the vascular territory being tested. Vascular contributors to cranial nerves and other eloquent areas are discussed in excruciating detail in Chap. 1.
 - (i) If the patient shows a new deficit, the testing is considered abnormal, and the vessel should not be embolized from that catheter position.
 - (j) In patients under anesthesia, when the barbiturate is injected, adjunctive testing with EEG, SSEP, BAER, and/or MEP can be done.
 - (k) If adjunctive testing changes from baseline status, then the testing is also considered abnormal, and the vessel should not be embolized from that catheter position.
 - (l) If there is no change on neurological testing and adjunctive testing, the testing is normal and suggests that it may be safe to embolize, or at least it is safe to proceed to test with lidocaine. Lidocaine may be more sensitive to nerve and white-matter tract supply than is amobarbital. Do not inject lidocaine if the barbiturate testing is abnormal.
 - (m) Connect a labeled 3-ml syringe of 2% cardiac lidocaine to the stopcock on the microcatheter.
 - (n) Inject the lidocaine (usually 20–50 mg) over approximately 5 s into the vessel via the microcatheter.
 - (o) The neurological and/or adjunctive neurophysiological testing is then repeated.
 - (p) If there is no deficit, the testing is normal and it is safe to embolize.

- (q) If a neurological or neurophysiological deficit occurs, the testing is abnormal and the vessel should not be embolized from that catheter position.
- (r) During embolization of a vessel after negative amobarbital and lidocaine testing, a change in flow pattern or visualization or different vessels may be seen after partial occlusion of the vessel. Consider repeating the provocative testing again, and only proceed with further embolization if the provocative testing remained negative.⁸

8.4.4. Syringe safety

Many of the procedures discussed in this book require the use of multiple agents in syringes on the procedure table. For example, an embolization procedure that may involve provocative testing requires syringes containing local anesthetic, saline flush, contrast, amobarbital, lidocaine, embolic material, etc. It is imperative that these syringes containing different agents are clearly differentiated, one from another. Confusing syringes with anesthetic agents or embolic materials for contrast or saline flush can lead to disastrous results. The authors of this handbook use customized, labeled, colored syringes (Merit Medical, South Jordan, UT) of various sizes and designs for the various materials. Using the same type of syringe for a certain agent at all times and educating new team members to the routine will minimize confusion and avoid mistakes.

8.4.5. Embolization phase

With a microcatheter in optimal position at the site of a vascular lesion and beyond supply to normal brain, the time is ripe for occluding the vessel with an appropriate embolic agent. Ideally, this should have already been chosen, given the underlying vascular pathology, the therapeutic goal of the procedure and the chosen microcatheter system. The superselective arteriogram performed once the microcatheter is in its final position should be studied to confirm that the originally chosen embolic agent is still appropriate for the flow rate and distance to the lesion. A variety of embolic agents could be delivered through microcatheters, although some are more effective than others. The single most important principle of the selection process is that the operator uses the system with which he or she is most experienced and comfortable.

1. Selecting embolic agents

Anything that causes a vessel to occlude can theoretically be used for extracranial embolization, but the most common and most studied types of agents are discussed.

(a) Liquid embolics

These are agents that are supplied in a liquid state and hence are easily injected through small microcatheters. Partly because of this characteristic, they are the most commonly used embolic agents used in intracranial embolization procedure.

- Cyanoacrylates. (aka “glue”)

These are acrylic agents that are in a liquid state and polymerize when they contact hydroxyl ions in blood. They are mainly used for intracranial embolization. The most common acrylic agent used in the United States is n-butyl cyanoacrylate (NBCA) Trufill® (Cordis Neurovascular, Miami Lakes, FL). Polymerization time can be modified by the addition of oil-based contrast agents such as Ethiodol® (Savage Laboratories, Melville, NY) or glacial acetic acid. Tends to cause considerable pain on injection of extracranial vessels, so it is used mainly for spinal embolization, for rare high-flow fistulae in the head and neck for actively bleeding vessels or for direct percutaneous embolization of vascular tumors via needle puncture.

- Precipitated polymer. (aka non-adhesive liquid embolic agent)

These agents are polymers insoluble in blood or water, dissolved in a non-aqueous solvent. When injected into the vascular system, the solvent disperses and the polymer precipitates to form a solid occlusive agent. Onyx® (ev3, Irvine, CA) is the dominant example of the precipitated polymer and is FDA approved for use in

AVMs. The agent is slowly infused through the microcatheter so is not a particularly useful agent for most applications in the extracranial circulation. Another issue with Onyx[®] is the dark tantalum used to make it radio-opaque which may be visible through the skin if injected in superficial vessels. Consequently it, like the acrylic glue, is also uncommonly used in extracranial cases.

- Sclerosing agents
Sclerosing agents are liquid agents that promote thrombosis but also necrosis of the intima in an attempt to limit the chance for clot lysis and recanalization. Absolute ethanol is medical-grade ethanol that is dehydrated sufficiently to be close to 100% pure ethanol. This is very thrombogenic and very toxic at this concentration. Alcohol should be avoided or only used with utmost caution when treating lesions anywhere near the spinal cord because of this toxicity. It is also extremely painful when injected in vessels in awake patients, and can cause skin necrosis if used in superficial vessels. Consequently, it tends to be reserved for attempted palliative embolization for tumors and direct percutaneous sclerotherapy for vascular malformations or tumors in the head and neck.

(b) Particles

These agents are by far the most common agents used in the extracranial head and neck circulation. All particulate agents work best in lesions with a capillary bed, namely tumors. All have a tendency to clog the microcatheter if the particles are too large or injected in too large a quantity. All require a similar technique for their use, and are mixed with contrast and injected via a microcatheter.

- Polyvinyl alcohol foam (aka "PVA")
 - These are irregularly shaped particles of PVA. Examples: Contour[®] emboli (Boston Scientific, Natick, MA) or PVA Foam Embolization Particles (Cook Medical, Bloomington, IN).
- Spherical emboli
 - These particles are manufactured to have a smooth, spherical shape. Examples Spherical Contour SE[™] (Boston Scientific) or Bead Block[™] (Terumo Medical, Somerset, NJ) or Embospheres[®] (Biosphere Medical, Rockland, MA).
- Silk suture
 - Small segments of silk suture can be it and loaded into a microcatheter. It is propelled into the vessel by injecting contrast or saline. Other types of suture material can be used in this fashion, but are less thrombogenic.

(c) Detachable balloons

Small balloons may be attached to a microcatheter, navigated to the desired site of occlusion, inflated to produce occlusion of the vessel, then detached from the catheter and permanently implanted. In the extracranial circulation, they have rarely been used for extremely rare high-flow fistulae, or for large vessel occlusion. At the time of this writing, the Goldvalve[™] balloon (Acta Vascular, Santa Clara, CA), is available in most of the world outside of the United States, and this and other vendors are working on obtaining approval for the North American market.

(d) Microcoils

Small, usually platinum coils that can be delivered through a microcatheter can be used for embolization. A wide variety of coils is available from many different companies. These are most commonly used for large or medium sized vessel occlusion in extracranial embolization procedures.

- Pushable coils.
These are platinum coils with thrombogenic fibers that are pushed through the microcatheter with a wire pusher. Examples include Trufill[®] pushable coils (Cordis Neurovascular, Miami Lakes, FL), Hilal and Tornado[®] Microcoils (Cook Medical, Bloomfield, IN), Fibered Platinum, and Vortex[®] coils (Boston Scientific, Natick, MA). Small coils such as 2 mm or 5 mm straight coils or 2 mm × 20 mm helical coils can also be propelled through the microcatheter and into the vessel using rapid injections of saline or contrast. Since these are effective in producing vascular occlusion and are inexpensive, they are the most common coils used for extracranial embolization. Still, it is rare that medium sized vessels need occlusion with coils in the extracranial circulation. The authors of this

handbook tend to use coils in these extracranial territories mainly to block anastomotic vessels and prevent particles or liquid emboli from entering the dangerous territory.

- **Injectable platinum coils.**
These mainly consisted of the Berenstein Liquid Coils® (BLC, Boston Scientific, Natick, MA), which are propelled into the vessel using rapid injections of contrast or saline. *Sadly these are no longer readily available at the time of this writing.*
- **Detachable platinum coils.**
The prototypical version of these coils are the GDC® (Boston Scientific, Natick, MA), but are rarely, if ever used in extracranial embolizations. They are not as effective in inducing thrombosis as fibered pushable coils, and are much slower to deploy. The added precision and security they provide are not usually needed outside the cerebral circulation. They are discussed further in Chap. 5.
- **Detachable fibered coils**
These are a hybrid of the pushable fibered coil and detachable coil. Examples include the Sapphire NXT™ fibered coils (ev3, Irvine, CA) or Fibered GDC® (Boston Scientific, Natick, MA). They definitely provide the same features as pushable fibered coils, but with added precision. This precision they afford is usually unnecessary in the extracranial circulation.
- **Coated detachable coils**
These coatings were developed in an effort to promote healing and decrease the recanalization of aneurysms treated with these coils. These include, among others, the Matrix™ (Boston Scientific, Natick, MA) and Hydrocoil® (Microvention/Terumo Medical, Aliso Viejo, CA). The added cost for these coils is difficult to justify in extracranial embolizations. They are discussed further in Chap. 5.

(e) **Stents**

Stents are commonly used for aneurysm treatment in the intracranial circulation, but only very rarely for embolization in the extracranial circulation. Situations that might require the use of a stent would be the occasional pseudoaneurysm of arteriovenous fistula that may require stent-assisted coil embolization. The Neuroform™ (Boston Scientific, Natick, MA) and Enterprise™ (Cordis Neurovascular, Miami Lakes, FL) stents may be used in smaller vessels (up to 4.5-mm diameter). When dealing with AV fistula or pseudoaneurysm arising from larger vessels, the larger self-expanding carotid stents including NexStent® (Boston Scientific, Natick, MA) or Acculink™ (Abbott Laboratories, Abbott Park, IL) can be used for preservation of flow in large or medium sized vessels in extracranial embolization procedures. Coils can be placed in the pseudoaneurysm or on the venous side of an AV fistula, while the stent in the artery prevents herniation of coils into the parent artery. The authors of this handbook have done stent-assisted coiling in cases of wide necked post-traumatic extracranial carotid pseudoaneurysms, or large post-traumatic AVF in the carotid or vertebral artery. It may also be helpful to temporarily inflate a non-detachable balloon, like the Hyperform™ (ev3, Irvine, CA) within the stent during placement of coils or liquid embolic agents in the aneurysm or fistula to provide added assurance that the coils, or other agents do not find their way through the openings of the stent into the parent artery.

Standard porous intracranial stents like the Neuroform™ or Enterprise™ can sometimes channel flow away from a side-wall aneurysm to induce thrombosis without placing coils. This spontaneous thrombosis after stent placement would not be expected in the case of an AV fistula due to the higher flow conditions. A different type of stent that has been used to treat fistulae or active bleeding is the covered stent, most commonly the Jostent® (Abbott, Abbot Park, IL). This over-the-wire balloon inflatable covered stent allows rapid occlusion of a fistula without necessarily using coils. The stent is FDA approved for repair of ruptured coronary vessels 3–5 mm in diameter. Larger vessels (4–7.5 mm) require the Wallgraft™ (Boston Scientific, Natick, MA). This is a self expanding stainless steel stent-graft which may be less traumatic than balloon inflatable stents, but requires greater than 8-French sheaths for introduction of these large devices. The Viabahn® (W. L. Gore, Flagstaff, AZ) is a heparin coated self-expanding nitinol stent graft that has the added benefit

of being MRI compatible. These latter stent-grafts require 7-French sheaths for the smaller stents (5 or 6mm) or 8 French for the larger stents (7 or 8mm). None of these covered stents is FDA approved for use in the brachiocephalic vessels, but can be life-saving in some cases of active bleeding of a major vessel.⁹

2. n-BCA glue embolization technique

- (a) When a flow-directed or over-the-wire type microcatheter is in the desired position, beyond any potential supply to brain, eye, cranial nerves or spinal cord, if any provocative testing has been completed and suggests that it is safe, then embolization can proceed.
- (b) Even if embolizing a vessel that does not supply neural structures, avoid getting glue in muscular or cutaneous branches since it may cause considerable pain.
- (c) When using glue, all persons near the sterile field should wear glasses or other eye protection. If a connection comes loose during injection, the glue can spray and stick to whatever it touches.
- (d) Double-check the superselective arteriogram performed at that catheter position, and check how long the contrast takes to reach the lesion.
- (e) As a rule of thumb, if that time is under one second, at least a 70% glue mixture (three parts nBCA to one part Ethiodol®) is required. Over 2 s requires a 50% (one nBCA to one Ethiodol) or more dilute mixture.
- (f) Tantalum powder greatly increases the radio-opacity of glue, but is not absolutely necessary unless the glue mixture is greater than 70% n-BCA. Tantalum is messy and can clump, and also the pigment may be visible through the skin in superficial vessels, so most practitioners almost never use it in the extracranial circulation.
- (g) Draw up the Trufill® n-BCA (Cordis Neurovascular, Miami Lakes, FL) from its tube using a labeled, glue-compatible 3-ml syringe (avoid polycarbonate plastic...it softens).
- (h) Draw up the Ethiodol® in a labeled syringe, and add the proper volume to the glue syringe to achieve the desired concentration.
- (i) Have several labeled 3-ml syringes filled with 5% dextrose solution ready.
- (j) Carefully pull back slightly on the microcatheter to remove any slack, and slightly loosen the rotating hemostatic valve so that it just barely prevents back-flow of blood in the guiding catheter, without binding the microcatheter too tightly.
- (k) Re-confirm proper catheter positioning with a contrast injection via the microcatheter for a superselective arteriogram. Select a projection that shows the microcatheter tip and its relationship to any curves in the arterial feeder distal to the catheter tip, any normal branches proximal to it, and the lesion.
- (l) Study the superselective arteriogram carefully to time the arteriovenous transit, and to determine the morphology of the target arterial feeder and nidus structure where the liquid agent will be injected.
- (m) Attach a glue-compatible stopcock directly to the microcatheter. Cook Medical (Bloomington, IN) makes a high-pressure, white nylon plastic one, and three-way stopcocks with Luer lock fittings that hold up well during glue injections.
- (n) One-way stopcocks are sufficient, but three-way are preferred since it allows a flush syringe of dextrose to remain attached even when the glue syringe is attached. This works well for doing the push technique (see below).
- (o) Thoroughly flush the microcatheter with 5% dextrose solution. Generally, approximately 5–10 ml is sufficient to clear all saline and/or blood from the microcatheter lumen.
- (p) As the last milliliter of dextrose is being injected, close the stopcock to prevent blood backflow into the microcatheter.
- (q) Holding the stopcock upright, fill the Luer-lock connection fully with dextrose.
- (r) Create a blank roadmap mask, the glue injection can be well visualized under digital subtraction.
- (s) Attach a 3-ml syringe loaded with the prepared glue mixture.

- (t) For continuous column technique, slowly, but steadily inject the glue using roadmap imaging, such that the glue column is continuously moving forward.
 - (u) Fill the arterial feeder and as much of the nidus as possible.
 - (v) Be alert for any signs of reflux of glue back along the catheter, passage of glue into the vein, or reflux of glue from the nidus into other arterial branches feeding the lesion.
 - (w) If any of these conditions is occurring and one is using dilute glue, one might be able to briefly pause the injection, then resume cautiously. Sometimes the glue will find another pathway through the nidus.
 - (x) The glue injection is relatively quick, but controlled. Polymerization usually occurs within a few seconds.
 - (y) The embolic agent should be deposited in the “safety zone” consisting of AVM nidus and only the artery beyond all normal branches, and vein before other venous inputs beyond the occluded nidus. (See Chap. 7 and Fig. 7.1)
 - (z) If there is any question that the glue is refluxing or going somewhere it shouldn't, or if finished filling the desired space with glue, stop injecting, aspirate the syringe to create negative pressure in the microcatheter, and quickly, smoothly withdraw the microcatheter completely from the patient and discard it. It is best to pull the guiding catheter and microcatheter as a unit, but, sometimes, using braided microcatheters, one can remove it by just pulling the microcatheter.
 - (aa) Examine the rotating hemostatic valve of the guiding catheter for any retained droplets of glue, then aspirate and double flush the stopcock, rotating hemostatic valve, and guide-catheter.
 - (bb) Once the guide catheter is thoroughly inspected and flushed, re-insert it to the arterial territory of interest, and perform a follow-up arteriogram to ensure that the desired result is obtained.
 - (cc) The wedged technique is similar to the full-column technique, except that the microcatheter tip is wedged in the nidus or small vessel and much more dilute glue can be used.
 - (dd) In wedged position, very slow, prolonged injections with dilute glue (less than 30% glue) can be done over several minutes (which seems like hours).
 - (ee) When glue begins to enter the vein, or to reflux along the microcatheter, one should stop injecting, wait a minute for polymerization, aspirate back from the glue syringe, then pull the catheter out.
 - (ff) Using the push technique, the microcatheter is generally some distance proximal to the lesion, but still beyond normal vessels.
 - (gg) When ready to embolize, the microcatheter is flushed with dextrose solution.
 - (hh) A three-way stopcock is attached to the hub of the microcatheter, and a syringe of 5% dextrose flush is attached to one connection, and the appropriately mixed glue to another.
 - (ii) Depending on the size of the vessel being embolized, 0.1–0.2 ml of glue mixture is injected into the microcatheter, the stopcock is turned and, under roadmap visualization, the glue is flushed into the vessel using the dextrose flush syringe.
 - (jj) Generally, it is advisable to pull the microcatheter at this point. The exception would be when the glue bolus travels quite distal to the tip of the microcatheter, and if contrast injections via the guide catheter confirm persistent patency of the feeding vessel being embolized. A second glue bolus may be injected and pushed with dextrose as long as the microcatheter remains patent.
3. Direct percutaneous n-BCA injection technique
- This technique involves direct puncture and glue embolization of feeding vessels that may have been ligated¹⁰ or direct puncture and embolization of AVMs¹¹ or vascular tumors in the head and neck^{12–14} or spine.¹⁵
- (a) An arterial catheter is usually placed in the vascular territory to allow for roadmap imaging and control angiography.
 - (b) The skin overlying the area of interest is sterilely prepared and draped and the skin overlying the lesion is injected with local anesthetic (2% lidocaine).
 - (c) Using roadmap guidance, a trajectory is planned to allow direct needle access of the desired vessel or lesion, without hitting any vital structures. Biplane or 3D roadmapping is particularly useful.

- (d) For very superficial lesions, it may be useful to plan an oblique trajectory to allow the skin and tissues to stabilize the needle once it is positioned in the lesion.
- (e) Using a 22 gauge spinal needle with a metal hub is inserted under roadmap guidance to the desired position. When the needle seems deep enough the stylet is removed to look for blood return. If no return is obtained the needle should be advanced or withdrawn until good blood flow is obtained.
- (f) In the scalp or facial soft tissues, the tumor or vessels may be mobile and it may take some manipulation to puncture the vessel and not glance off it.
- (g) Once good blood return is obtained, gently inject contrast through the needle to confirm proper positioning, to look for any important vessels filling, and to time the volume required to fill the lesion and the arteriovenous transit.
- (h) If any vessel that supplies neural structures is not visualized, embolization may proceed.
- (i) As always, when using glue, all persons near the sterile field should wear glasses or other eye protection. If a connection comes loose during injection, the glue can spray and stick to whatever it touches.
- (j) As a rule of thumb, when injecting a high-flow fistula, a concentrated glue such as a 70% glue mixture (three parts nBCA to one part Ethiodol®) is required. Most tumors, even very vascular ones require a fairly dilute mixture, such as 20% (one part nBCA to four parts Ethiodol).
- (k) Tantalum powder greatly increases the radio-opacity of glue, but is not absolutely necessary unless the glue mixture is greater than 70% n-BCA. Tantalum is messy and can clump, and also the pigment may be visible through the skin in superficial vessels, so most practitioners almost never use it in the extracranial circulation.
- (l) Draw up the Trufill® n-BCA (Cordis Neurovascular, Miami Lakes, FL) from its tube using a labeled, glue-compatible 3-ml syringe (avoid polycarbonate plastic...it softens).
- (m) Draw up the Ethiodol® in a labeled syringe, and add the proper volume to the glue syringe to achieve the desired concentration.
- (n) Have several labeled 3-ml syringes filled with 5% dextrose solution ready.
- (o) Re-confirm proper needle positioning with a small contrast injection.
- (p) Select a projection that shows the needle tip and its relationship to any curves in the arterial feeder distal to the needle, any visible normal branches, and the lesion.
- (q) Attach a glue-compatible stopcock directly to the needle, or to a short segment of sterile tubing that is then connected to the needle. The authors usually avoid using the tubing since some plastic tubing may not be glue-compatible.
- (r) One-way stopcocks are sufficient, but three-way are preferred since it allows a flush syringe of dextrose to remain attached even when the glue syringe is attached.
- (s) Be careful not to move the needle when attaching stopcocks or syringes.
- (t) Gently, but thoroughly flush the needle with 5% dextrose solution. Generally, approximately 2–3 ml is sufficient to clear all saline and/or blood from the needle lumen.
- (u) As the last milliliter of dextrose is being injected, close the stopcock to prevent blood backflow into the needle.
- (v) Stabilizing the stopcock, fill the Luer-lock connection fully with dextrose.
- (w) Create a blank roadmap mask, the glue injection can be well visualized under digital subtraction.
- (x) Attach a 3-ml syringe loaded with the prepared glue mixture.
- (y) Slowly, but steadily inject the glue using roadmap imaging, such that the glue column is continuously moving forward.
- (z) In extremely high flow AVMs, flow can be easily controlled in the lesion during the glue injection by manual compression of draining veins or by placement of a compressive dressing or O-ring¹⁶ over the skin overlying superficial lesions.
- (aa) Fill the arterial feeder and as much of the nidus or tumor bed as possible.
- (bb) Be very alert for any signs of reflux of glue back along arterial feeders, passage of glue into the vein, or reflux of glue through the nidus or

tumor bed into other, potentially dangerous arterial branches feeding the lesion.

- (cc) If any of these conditions is occurring and one is using dilute glue, one might be able to aspirate to stop forward motion, then after a brief pause, resume cautiously. Sometimes the glue will find another pathway through the nidus.
 - (dd) When the glue injection is complete, close the stopcock, then wait. Polymerization should be complete within a few minutes.
 - (ee) Rotate the needle to break the bond with the injected glue and then remove it.
 - (ff) Once the needle is removed and hemostasis obtained at the puncture site, perform a follow-up arteriogram to ensure that the desired result is obtained.
 - (gg) If other segments of the lesion remain patent, additional needle punctures and glue injections may be done.
4. Onyx[®] embolization technique
- (a) Have several vials of the desired Onyx[®] mixture (18 and/or 34) agitating in an automatic mixer for 30 min while performing other parts of the procedure
 - (b) This transarterial technique is similar to the technique using n-BCA glue regarding the catheterization of the arterial feeder, except one must use a dimethyl sulfoxide (DMSO)-compatible catheter such as the over-the-wire type Rebar[®] (ev3, Irvine, CA) or more flexible Marathon[™] (ev3, Irvine, CA).
 - (c) Note that provocative testing can give a false sense of security since Onyx[®] can easily find its way into places that may not be predicted by superselective angiography or barbiturate injections.
 - (d) Confirm proper catheter positioning with a contrast injection via the microcatheter for a superselective arteriogram. Select a projection that shows the microcatheter tip and its relationship to any curves in the arterial feeder distal to the catheter tip, any normal branches proximal to it, and whether the tip is wedged.
 - (e) Study the superselective arteriogram carefully to time the arteriovenous transit, and to determine the morphology of the target arterial feeder and venous structure where you will deposit the Onyx[®].
 - (f) Select a pre-mixed viscosity of the agent depending on the size of the feeder and degree of arteriovenous shunting. Big feeders with fast flow need Onyx[®] 34 and small feeders or slower shunting should be treated with Onyx[®] 18.
 - (g) Using the proper syringe supplied by ev3, draw up 1 ml of DMSO.
 - Draw up the Onyx[®] into the syringe specified by the manufacturer. Agitate it back-and-forth if it will not be injected for more than a few minutes to keep the tantalum from getting suspended.
 - Attach the DMSO syringe directly to the hub of the microcatheter and fill the dead-space of the microcatheter (usually 0.2–0.3 ml) with DMSO over 1–2 min.
 - Remove the DMSO syringe from the microcatheter, and, keeping the hub upright, fill the hub with DMSO.
 - Holding both the catheter hub and Onyx[®] syringe at 45° to one another, quickly connect the syringe to the hub, and then keep the syringe vertical with the plunger down. This keeps a sharp demarcation between the heavier Onyx[®] in the syringe, and lighter DMSO in the hub of the catheter. This will make it easier to see radiographically than if the DMSO and Onyx[®] mix together.
 - (h) Using a blank roadmap mask, slowly inject the Onyx[®] under roadmap visualization at a rate of approximately 0.16 ml per minute. Rates of injection over 0.3 ml per minute risk vascular injury due to DMSO toxicity.
 - (i) Continue injecting Onyx[®] as long as it is flowing forward into desired areas of the abnormal vessels.
 - (j) If it refluxes along the catheter, passes into the proximal part of the vein, or refluxes into other arterial feeders, pause the injection for 15 s, then resume injecting. If the Onyx[®] continues to flow in the wrong direction, pause again for 15–30 s, then try again. If the Onyx[®] finds another, more desirable pathway, continue the slow injection.
 - (k) It is often desirable to obtain a new mask for roadmap periodically. This subtracts out the already deposited embolic agent and makes the newly injected material easier to see.

- (l) If uncertain whether the injection is achieving the desired result, a contrast injection can be done via the guide catheter for a control angiogram. This will show if there are still portions of the feeding artery or nidus that could be occluded from this catheter position.
 - (m) The Onyx® injection should be done patiently and may take several minutes.
 - (n) Some reflux back along the catheter tip is not a problem, due to the non-adhesive nature of the product. Avoid more than 1 cm of reflux, however, since even Onyx® may glue a microcatheter into the vessel.
 - (o) Do not pause the injection for more than 2 min, for the Onyx® may solidify and clog the microcatheter.
 - (p) Never try to inject against resistance. A clogged microcatheter may burst if the injection continues.
 - (q) When adequate filling of the desired vascular spaces is achieved, or if the Onyx® repeatedly flows in the wrong direction, stop injecting, aspirate back on the syringe, and slowly, but steadily pull back on the microcatheter, disengage it from the deposited Onyx® and remove it. The heavy-duty catheters used for Onyx® can usually be pulled back on their own, without pulling the guide catheter as well.
 - (r) After the microcatheter is withdrawn from the guide catheter, examine the rotating hemostatic valve of the guiding catheter for any retained droplets of Onyx®, then aspirate and double flush the stopcock, rotating hemostatic valve, and guide-catheter.
 - (s) Once the guide catheter is thoroughly inspected and flushed, perform a follow-up arteriogram to ensure that the desired result has been obtained.
4. Ethanol embolization technique
- (a) Although not recommended routinely for extracranial embolization, there may be rare situations in which it may be used if microcatheter access is very close to a lesion.
 - (b) It may also be used for direct needle puncture of superficial tumors or vascular malformations. (See below)
 - (c) Some recommend prophylactic placement of a Swan-Ganz catheter for AVM embolizations with ethanol, to watch for signs of pulmonary hypertension.
 - (d) When added to mixtures of particle, the technique is essentially the same as standard particulate embolization (see below).
 - (e) When used without added particles, the technique is more like that for glue.
 - (f) Be sure to check that the syringes, stopcocks and microcatheter hubs will not degrade when exposed to ethanol. Often, those that can be used with glue or DMSO will withstand ethanol, but it is wise to test it first. Since it is not an FDA approved indication, manufacturers will likely state that their products are not approved for use with ethanol.
 - (g) Microcatheter positioning, and confirmation with superselective angiography and provocative testing is the same as for nBCA glue use.
 - (h) When ready to embolize, perform test injections of contrast through the microcatheter to estimate the rate and volume required to opacify the territory that is to be occluded.
 - (i) If the flow is very rapid, consider placing a coil or two to slow the flow.
 - (j) Flush the microcatheter with saline, since ethanol can cause contrast to precipitate.
 - (k) Inject the absolute ethanol at a rate similar to that which opacified the vessel, but use only approximately 50% of the volume of contrast used.
 - (l) Wait a few minutes, then repeat the contrast injection. If the vessel remains patent, inject another small bolus of ethanol, and wait again.
 - (m) If spasm is seen on repeat test injections, wait until it resolves and decrease the volume of ethanol boluses.
 - (n) After a few boluses have been given, wait at least 5–10 min between ethanol injections before checking for patency of the vessel.
 - (o) If there is no change after 20 ml of ethanol, consider placement of additional coils to slow the flow and help the ethanol work, or try a better embolic agent.
 - (p) Remember that ethanol can work on the endothelium for some time and can also spread through the vessel wall into the adjacent tissues, so it is best to keep the ethanol volumes to a minimum.

4. Percutaneous ethanol sclerotherapy technique

This technique is used for the treatment of superficial arteriovenous malformations as well as venous and lymphatic malformations.¹⁷

- (a) Percutaneous ethanol sclerotherapy is almost always performed under general anesthesia because the ethanol injection is very painful.
- (b) When using the sclerotherapy technique for arteriovenous malformations, an arterial catheter is used to angiographically localize the target lesion and monitor progress.
- (c) Angiographic catheters are not used when treating venous or lymphatic malformations.
- (d) The area of the lesion is localized by palpation, by using ultrasonic localization, or in the case of AVM, by contrast injection in the feeding artery for roadmap guidance.
- (e) For an AVM, the lesion can be treated by puncturing the artery close to the nidus, the nidus itself, or the proximal vein close to the nidus.
- (f) For venous or lymphatic malformations, the ideal puncture site is the larger cavernous spaces within the lesion.
- (g) The skin overlying the lesion is prepared and draped and local anesthetic injected intradermally at the site of the expected needle puncture.
- (h) A 22 gauge spinal needle is inserted and the tip placed at the expected depth of the lesion.
- (i) The stylet is removed and checked for return.
- (j) Reposition the needle if good return is not obtained.
- (k) Bright red pulsatile blood is obtained when an AVM is punctured, dark blue blood in venous malformations, and straw-colored or slightly bloody fluid in lymphatic malformations.
- (l) Once good return from the needle is seen, perform test injections of contrast through the needle and obtain a digital subtraction angiogram.
- (m) Study the images to ensure that the needle is in a vascular space, and that it fills the lesion. Estimate the rate and volume required to opacify the territory that is to be occluded.
- (n) If the flow is extremely rapid, consider placing a coil or two through the needle to slow the flow. Ten system fiberoptic coils will pass through a 22 gauge needle; 18 system coils will pass through thin-wall 19 gauge or any 18 gauge needle.
- (o) Most cases will not require coils, especially if the flow can be manually slowed by manual compression of the draining veins, or by placement over the area of a compressive O-ring affixed to the skin over the lesion.
- (p) Perform a repeat contrast injection for an angiogram when venous outlets are compressed, to document the change in flow and check the rate and volume required to opacify the lesion.
- (q) For venous and lymphatic malformations, a second needle may be used to puncture another part of the now contrast-filled malformation. This second needle allows drainage of fluid from the lesion as the ethanol is injected to remove the diluting blood or fluid and reduce the risk of over-pressurizing the lesion with ethanol and creating leakage back along the needle.¹⁸
- (r) Flush the needle with saline, since ethanol can cause contrast to precipitate. It is usually easiest to attach a short extension tubing to the needle, and a one-way stopcock to the end of the tubing, to control back-bleeding through the needle.
- (s) Inject absolute ethanol at a rate similar to that which opacified the vessel, but use only approximately 50% of the volume of contrast used.
- (t) If a second needle is positioned in the lesion, remove its stylet and let it back-bleed during the ethanol injection to relieve the pressure within it.
- (u) Wait a few minutes while maintaining pressure on the veins and occluding the flow from the needles by closing the attached stopcock and/or the re-insertion of the stylet.
- (v) Let at least 5 min elapse, then release the pressure on the veins and check for back-bleeding from the injected needle. If rapid return is obtained, inject another dose of ethanol equal to 50% of the volume of contrast needed to opacify the lesion.
- (w) After waiting another 5 min, again check for return from the needle. If still brisk, repeat the contrast injection. If the vessel remains patent, inject another small bolus (1 or 2 ml) of ethanol, and wait again.

- (x) If spasm is seen on repeat test injections, wait until it resolves and decrease the volume of ethanol boluses.
 - (y) If blanching or discoloration of the skin is seen, stop the ethanol injections to prevent ischemic damage to the skin.
 - (z) After a few boluses have been given, wait at least 5–10 min between ethanol injections before checking for patency of the vessel.
 - (aa) If no change after 20 ml of ethanol, consider placement of additional coils to slow the flow and help the ethanol work, or try nBCA as the embolic agent.
 - (bb) Remember that ethanol can work on the endothelium for some time and can also spread through the vessel wall into the adjacent tissues, so it is best to keep the ethanol volumes to a minimum.
 - (cc) To minimize local tissue damage, it is best to stage the procedure rather than attempting to cure the lesion with a single session. Maximum recommended ethanol dose per session is 1 ml kg⁻¹ body weight.^{18,19}
 - (dd) When the puncture cavity appears to be thrombosed, wait another 5 min and then remove the needle and hold manual pressure for approximately 5–10 min or when hemostasis is obtained.
 - (ee) If only a few ml of ethanol has been injected, a second needle puncture (use a new needle) and additional ethanol injections may be done.
 - (ff) It is time to stop when swelling or discoloration at the puncture site is seen or if the ethanol dose gets over 20–30 ml, and absolutely if 1 ml kg⁻¹ is reached.
5. Particulate embolization technique
- (a) Most all particles are used in a similar fashion for extracranial embolization.
 - (b) To avoid major problems with particles clogging the microcatheter, use one of the larger lumen over-the-wire types of microcatheters.
 - (c) The microcatheter tip must be close to the lesion being embolized, in a stable position distal to normal branches.
 - (d) Safe positioning is confirmed with a superselective angiogram via the microcatheter, possibly also with pharmacological provocative testing as necessary.
 - (e) Choose a particle size depending on the size of the vessels in the target lesion. In general, tumors with a capillary bed are treated with particles less than 300 μm in diameter, and AVMs require particles over 300 μm.
 - (f) If there is concern about potential cranial nerve supply from the vessel being embolized keep the particles larger than 300 μm.
 - (g) Mix the particles with dilute contrast and draw up the emboli in a labeled 10-ml syringe. This acts as a reservoir for emboli.
 - (h) The particles should be fairly dilute to limit the risk of clogging the microcatheter.
 - (i) Attach the syringe to one female connection on a high-pressure 3-way stopcock and attach a labeled 3-ml luer-lock syringe to the other female connection. This syringe is used to inject the embolic mixture through the microcatheter.
 - (j) The stopcock is then attached to the hub of the microcatheter.
 - (k) The stopcock is turned to connect the 10- and 3-ml syringes, and the contrast/emboli mixture is flushed into the 3-ml syringe and then back into the 10-ml syringe, back and forth several times, to ensure uniform suspension of particles.
 - (l) The 3-ml syringe is then filled with 1–2 ml of the emboli suspension.
 - (m) Obtain a blank roadmap in order to have subtracted fluoro.
 - (n) Under fluoroscopic guidance, slowly inject the emboli in small (0.2 ml) increments and ensure that the contrast freely flows from the microcatheter tip.
 - (o) Increase or decrease the rate of injection, depending on the speed of runoff away from the microcatheter.
 - (p) Every 3–5 ml of embolic suspension, or sooner if emboli are seen to collect in the hub of the microcatheter, disconnect the 3 ml syringe and reconnect another labeled 3 ml syringe filled with dilute 50:50 contrast.
 - (q) Gently flush the microcatheter with the contrast under fluoroscopy, remembering that the microcatheter is still full of emboli.

- (r) As long as a good runoff of contrast is seen, reconnect the 3-ml embolic syringe, refill it with embolic mixture, and continue to inject emboli.
 - (s) When the 10-ml syringe is empty, consider obtaining a control superselective angiogram via the microcatheter to see whether the flow pattern is changing.
 - (t) Especially with AVMs it may require some time and a considerable amount of emboli to occlude a feeder.
 - (u) If an entire vial of emboli is injected with no change in the flow pattern, consider modifying the flow with a coil or two, or switching to a different embolic agent.
 - (v) Avoid creating reflux of the embolic mixture back along the microcatheter when injecting. Slow or stop the injections if reflux is seen.
 - (w) If resistance is encountered during the injections, stop, disconnect the 3-ml embolic syringe and check the hub of the microcatheter. If emboli are bunched up in the hub, it may be possible to rinse them out with a needle or guidewire introducer, then attempt to gently flush with contrast.
 - (x) If resistance remains, do not attempt to force the emboli through by a forceful injection, and do not use a 1-ml syringe to achieve higher pressures. Attempting to inject through a microcatheter clogged with particles can cause the microcatheter to rupture and even break into pieces. Certainly the newer, braided microcatheters are less prone to burst than are the softer, flimsier unbraided catheters, but no catheter is burst-proof if clogged.
 - (y) When the flow in the feeder is significantly slowed, injections of emboli are stopped.
 - (z) If more definitive closure of the vessel is desired after particle embolization, a coil or a tiny pledget of Gelfoam may be deposited to finish the job.
 - (aa) Be certain to gently flush out the microcatheter with contrast or saline before inserting a coil. Retained particles in the microcatheter can cause the coil to bind in the microcatheter.
 - (bb) Even if the microcatheter seems free of particles, it is best to withdraw and discard the used microcatheter prior to attempting catheterization of another feeder with a new microcatheter.
6. Silk suture embolization technique.
- (a) Procure several microwire introducers. These can be used as delivery introducers for the silk suture fragments. An 18 gauge plastic intravenous catheter can also be used for this purpose.
 - (b) Open a sterile package of 4-0 silk suture.
 - (c) Insert a 5–10mm segment of silk into the blunt, distal end of the introducer and cut the suture at the end of the introducer with sterile scissors.
 - (d) Attach a 3-ml syringe of sterile saline to the luer-connector hub of the introducer and gently flush to expel air. Be careful not to flush the silk out of the introducer.
 - (e) When the microcatheter is properly positioned, check that all slack is removed and there are no kinks. These can impede the injection of silk.
 - (f) Also ensure that the RHV of the guiding catheter is just tight enough to prevent back-bleeding, but not too tight to pinch the microcatheter.
 - (g) There should be an RHV with continuous infusion of heparinized saline already attached to the microcatheter hub as well.
 - (h) When ready to embolize, insert the introducer containing the silk suture fragment through the RHV of the microcatheter and seat it with its blunt tip in the hub of the microcatheter.
 - (i) Inject the silk into the microcatheter with a small bolus of heparinized saline.
 - (j) Remove the introducer from the RHV, and tighten the valve of the RHV.
 - (k) Flush the microcatheter with heparinized saline using a 3 ml or larger syringe to flush the silk into the vessel. There will be a build up of pressure, then a release as the silk is expelled from the microcatheter.
 - (l) The position of the microcatheter should be checked fluoroscopically since the force of these injections can cause the tip to move.
 - (m) Periodic contrast injections are done via the microcatheter to check for changes in the flow.
 - (n) It may take several silk fragments to produce an effect on the flow.
 - (o) Consider using particles and/or coils in conjunction with silk to facilitate occlusion.

- (p) Avoid using a 1-ml syringe for flushes or test injections, since it generates sufficient pressure to rupture most microcatheters.
 - (q) If the microcatheter does not flush easily, it may be clogged by the silk.
 - (r) In some cases, a clogged microcatheter may be unclogged by passing a coil pusher through it, but in most cases it must be removed and another microcatheter used to re-access the vessel to be embolized.
 - (s) The end-point for embolization may be difficult to assess, since silk induces a slow thrombosis that may unpredictably occlude the vessel, so frequent test injections of contrast should be done, to prevent refluxing emboli proximally from the occluded vessel.
8. Detachable balloon technique
- This discussion may be primarily of historic interest for practitioners in the United States until FDA approval is achieved.
- (a) Choose a balloon diameter that is slightly larger than the space intended for occlusion.
 - (b) Bench-test the balloon by inflating it with sterile water using a blunt-tip 25 gauge needle attached to a 3-ml syringe.
 - (c) Insert the needle very carefully into the valve of the balloon and inflate 0.1–0.3 ml, but to no more than the rated volume of the balloon.
 - (d) Withdraw the needle and confirm that the balloon remains inflated. If not discard it and obtain another balloon.
 - (e) Assuming the balloon can remain inflated, re-insert the blunt needle and deflate it, making sure to tilt the balloon to remove any air bubbles as the water is aspirated.
 - (f) Inflate the balloon with an approximately iso-osmolar contrast solution. Visipaque™ 270 (iodixanol (GE Healthcare, Princeton, NJ) is a convenient choice.
 - (g) Attach an RHV with a one way stopcock to an appropriate balloon delivery microcatheter. In general, the outer diameter of the tip should be less than 2 French.
 - (h) Flush the RHV and microcatheter with iso-osmolar contrast.
 - (i) Preload a microwire, stiff end first, into the microcatheter and advance it just to the catheter tip. The wire should be small enough such that contrast can be injected through the microcatheter around the wire.
 - (j) Carefully load the prepared balloon onto the microcatheter. It may deflate somewhat as the microcatheter enters its valve.
 - (k) Keeping a contrast syringe attached to the open stopcock on the RHV, slowly withdraw the wire, injecting contrast to fill the dead-space of the microcatheter.
 - (l) Insert the wire, soft end first, back into the microcatheter after forming the desired curve on its tip.
 - (m) Advance it to the tip of the microcatheter, but do not advance it into the balloon.
 - (n) Attach a torque device to the microwire.
 - (o) A very large-lumen guide catheter (or 90-cm sheath) large enough to accept the balloon and another balloon catheter should be in the brachiocephalic artery supplying the lesion to be embolized. A 7 French Shuttle™ (Cook Medical, Bloomington, IN) works for many balloon sizes.
 - (p) A two headed RHV (or 2 RHVs in tandem) is attached to the guide catheter.
 - (q) The balloon-tipped microcatheter is carefully inserted into one RHV, and a second, non-detachable balloon such as a Hyperform™ (ev3, Irvine, CA) is carefully inserted in the other RHV.
 - (r) Alternatively, each balloon can be inserted in a separate, smaller guide catheter inserted via a separate groin puncture.
 - (s) The two balloons are carefully navigated into the vessel.
 - (t) If possible, advance the detachable balloon catheter without inflation of the balloon to the desired site.
 - (u) It may be possible to turn the tip of the microcatheter by rotating the wire inside it.
 - (v) Avoid entering the balloon with the wire, since it may damage or prematurely detach it.
 - (w) In some cases it may be necessary to inflate the balloon slightly to let the flow carry it forward.
 - (x) Never pull back on a partly or fully inflated balloon: It may detach inadvertently.

- (y) The second balloon can sometimes be used to facilitate proper positioning of the detachable balloon. It can be inflated next to the detachable balloon to nudge it into a turn, or can be inflated distal to a fistula, to direct all the flow, and the detachable balloon directly to the fistula.
 - (z) When the balloon is in its desired location, the second balloon should be positioned proximal to the detachable balloon and slightly inflated to control the flow.
 - (aa) The detachable balloon is then fully inflated. Remember that flow tends to carry balloons forward as they are inflated. The balloon should therefore be slightly proximal to the desired position before inflation, or proximal flow should be stopped by fully inflating the proximal nondetachable balloon.
 - (bb) Contrast injections via the guide catheter are done to confirm that the desired position and occlusion have been achieved.
 - (cc) If not, the balloon should be deflated, moved to the desired position, then re-inflated.
 - (dd) When the desired position is confirmed, one could do a test occlusion, if necessary (see Chap. 6, Provocative Testing)
 - (ee) When the operator is confident that it is safe to proceed, the balloon may be detached. This is sometimes more difficult than it sounds.
 - (ff) Inflate the non-detachable balloon fully just proximal to the detachable balloon. This can help stabilize it.²⁰
 - (gg) Slowly, steadily, pull back on the microcatheter, continuously watching the inflated balloon. Silicone balloons may slide back in the vessel as traction is put on the microcatheter if insufficiently sized for the vessel or if no proximal support balloon is used.
 - (hh) A coaxial catheter like the guide catheter itself may sometimes be advanced up along the microcatheter just proximal to the balloon, to act as a stabilizer for the balloon as it is being detached.
 - (ii) The valve side of the balloon can often be seen to stretch as the microcatheter is pulled back, then relax suddenly as the valve slides off the microcatheter and the balloon detaches.
 - (jj) It is generally a good idea to place a second balloon (aka “safety balloon”) or some microcoils adjacent to the first balloon to ensure a stable occlusion if the valve leaks.
9. Pushable coil technique
- (a) Large lumen over-the-wire microcatheters must be used. In general, most 18-system fibered coils need at least a 0.017-in. diameter lumen.
 - (b) When the microcatheter is properly positioned, check that all slack is removed and there are no kinks. These can impede the placement of the coil.
 - (c) Also ensure that the RHV of the guiding catheter is just tight enough to prevent back-bleeding, but not too tight to pinch the microcatheter.
 - (d) There should be an RHV with continuous infusion of heparinized saline already attached to the microcatheter hub as well.
 - (e) Select an appropriately sized coil to fit in the vessel tightly.
 - (f) For very high-flow states, or when precise coil positioning is required, consider using a detachable coil first.
 - (g) When ready to embolize with the pushable coil, insert the introducer containing the coil through the RHV of the microcatheter and seat it with its blunt tip in the hub of the microcatheter.
 - (h) Carefully push the coil into the microcatheter with the plunger supplied by the manufacturer. As an alternative, most coils can be injected into the microcatheter using a small bolus of heparinized saline.
 - (i) Remove the introducer from the RHV, and tighten the valve of the RHV.
 - (j) To flow-inject smaller (up to 10-mm long) microcoils, inject the microcatheter with heparinized saline using a 3 ml or larger syringe to flush the coil into the vessel. This can be monitored fluoroscopically.
 - (k) To deposit the coil in a more controlled fashion, a coil pusher should be utilized.
 - (l) Do not use a guidewire to push a coil because it may over-ride the coil, and possibly wedge it in the microcatheter.
 - (m) The authors of this handbook like the TruPush® (Cordis Neurovascular, Miami Lakes, FL) for 18-system coils and the Pusher 10 (Boston Scientific, Natick, MA) when a smaller, 10-system coil is used in a 10-system microcatheter.

- (n) Do not push the tip of the coil pusher beyond the tip of the microcatheter. The relatively stiff pusher can traumatize the vessel.
 - (o) Place additional coils to achieve the desired occlusion.
 - (p) If a coil does not pass easily through the microcatheter, there may be a sharp turn or kink in the microcatheter. Gently pulling it back slightly, or occasionally pushing it forward may relieve the obstruction.
 - (q) The position of the microcatheter should be checked fluoroscopically since the placement of the coils and any catheter manipulation can displace the tip of the microcatheter.
 - (r) Periodic contrast injections are done via the microcatheter to check or changes in the flow.
 - (s) It may take several coils to produce an effect on the flow.
 - (t) In high-flow fistulae, consider using a liquid embolic agent (glue or Onyx®) to fill spaces between coils and produce a secure occlusion
10. Detachable coil technique
- (a) Use of detachable coils is discussed in excruciating detail in the Intracranial Aneurysms Procedure Chap. 5.
 - (b) These coils require the use of 150-cm long, two tip marker over-the-wire microcatheters.
 - (c) As a general rule, deposit coils in the vascular structure to be occluded beginning from the area most distal to the point of endovascular access to the structure. Embolize from distal-to-proximal to avoid burning bridges.
 - (d) Also, another general rule is to start with the biggest coil diameter and longest length first.
 - (e) Especially in the case of a high-flow fistula, it is best to start with a detachable coil, oversized to the diameter of the vessel being occluded. If it does not appear stable, do not detach it. Remove it and try a larger diameter coil or a 3D configuration coil.
 - (f) Sometimes it helps to get a loop or two in a side branch or sharp curve in the vessel to stabilize it.
 - (g) Once one coil adequately frames the vessel and is stable, detach it.
 - (h) Place additional detachable coils to further frame and fill the space. The softest possible coils work best to pack tightly into the space available.
 - (i) If the microcatheter has a large enough lumen, it may be helpful to intersperse some fibered coils to induce thrombosis. Be careful not to displace the microcatheter with the stiffer coils or jam the coils in the catheter, and use detachable fibered coils instead of pushable coils whenever possible, to improve the precision and controllability of the occlusion.
 - (j) Continue to pack coils in the venous structure to be occluded. Alternate between ultrasoft coils to fill small spaces and fibered coils to promote thrombosis.
 - (k) For a large vessel or high-flow fistula, it will take many, many coils to block the flow. Consider using a liquid embolic agent to complete the occlusion.
 - (l) Periodic arteriograms during the procedure will indicate when the flow in the treated vessel slows and finally stops.
11. Stent placement for AVF technique
- (a) Use of stents for aneurysm coiling is discussed in excruciating detail in the Intracranial Aneurysms Procedure Chap. 15.
 - (b) Prior to any stent procedure, it is usually recommended to start clopidogril 75 mg daily for at least 3 days preprocedure, and continue for 3–6 months post-procedure.
 - (c) The Neuroform™ or Jostent® requires the use of 300-cm long, 0.014 wires. Enterprise™ does not.
 - (d) Size the stent appropriately for the parent artery (usually a little wider than the parent artery) and for the lesion being stented (usually at least 4 mm coverage on either side of the lesion).
 - (e) Flush the stent delivery system with heparinized saline prior to insertion in the guide catheter.
 - (f) As a general rule, the wire is first placed quite distal to the lesion being stented by the first navigation of a standard microcatheter distal to the lesion, then, after the placement of the 300-cm wire (with a J-shaped tip) the microcatheter is carefully removed, leaving the wire in place.
 - (g) Always keep the wire tip in view and ensure that it stays in a larger vessel and does not injure the vessel wall.

- (h) Especially in the case of a high-flow fistula, it is best to have distal wire access to provide support.
- (i) Slowly, carefully advance the stent delivery catheter (for Neuroform™ or Jostent®) over the wire, gently pulling back on the wire to make sure the tip remains in a stable position.
- (j) Once the stent is in position, remove any slack in the wire and stent delivery catheter. This is critical for obtaining easy and accurate deployment.
- (k) Perform a follow-up arteriogram by a contrast injection via the guide catheter.
- (l) If the stent is not in proper position, change the position and repeat the arteriogram.
- (m) When a good position is achieved across the lesion, the stent is ready for deployment.
- (n) For a Neuroform™, the stent is deployed by stabilizing the inner stabilizer as the outer stent delivery catheter is pulled back, exposing the stent.
- (o) The stent delivery catheter can then be removed, and a microcatheter navigated through the stent into the fistula. Coiling of the fistula can then proceed.
- (p) Consider placing a nondetachable balloon (e.g., Hyperform™, ev3, Irvine, CA) in the stent for inflation as the coils are inserted. This prevents loops of coils from finding their way through the stent and into the parent artery. This is particularly important for cases in which many coils are deployed into the venous side of the fistula, totally obscuring the parent artery on fluoroscopy. It is also important if liquid embolic agents are used on the venous side to keep them from embolizing the artery.
- (q) If using an Enterprise, a 0.021-in. lumen microcatheter like the Prowler Plus™ is navigated over a suitable microwire into the vessel of interest and positioned with its tip approximately 1.5 cm distal to the lesion being covered. Always use roadmap guidance.
- (r) The microwire is removed, and slack removed from the microcatheter.
- (s) The stent is mounted on a delivery wire and this is advanced into the microcatheter to the tip of the microcatheter.
- (t) The microcatheter can be moved forward or backward until the stent markers are lined up at the desired position of the stent.
- (u) If there is any question as to the proper positioning, a follow-up arteriogram via the guide catheter prior to stent deployment will confirm whether the markers are appropriately positioned.
- (v) The stent is deployed by slowly pulling back on the microcatheter as the delivery wire is stabilized to unsheath the stent.
- (w) If it appears to be too proximal or distal, it can be resheathed, repositioned, and redeployed if not already deployed more than 70%. Do not resheath and redeploy it more than a couple of times.
- (x) Once it is properly positioned and deployed, the stent delivery catheter can then be removed, and a microcatheter navigated through the stent into the fistula. Coiling of the fistula can then proceed.
- (y) Again, consider the adjunctive use of a balloon during coiling and certainly with the use of liquid embolic agents.
- (z) If the artery involved with the fistula is larger than 4.5 mm in diameter, as in the cervical carotid or vertebral, the flimsy stents described above will not work. A larger self expanding stent-system like the NexStent® (Boston Scientific, Natick, MA) or Acculink™ (Abbott Laboratories, Abbott Park, IL) must be used.
- (aa) The use of self expanding stents for bleeding vessels is similar to the placement of self expanding carotid stents, as is discussed in excruciating detail in the Extracranial Angioplasty and Stent Procedure Chap. 20.
- (bb) These stents require the use of 6–7 sheaths, depending on the size of the stent. One can usually use a 6-French Shuttle™ sheath as a guide catheter in most cases and position it in the vessel leading to the fistula site. This improves the stability of the system during stent deployment and also allows repeated contrast injections as necessary.
- (cc) The stents are available in over-the-wire style, which requires a 0.014 in., 300 cm exchange wire or the rapid exchange (“RX”) version that only requires a 200-cm long wire. Filter wires are not usually used for this

- application unless significant atherosclerotic disease is present in the vessel being treated.
- (dd) Flush the delivery system with heparinized saline prior to insertion in the sheath.
 - (ee) The wire is first placed quite distal to the lesion being stented as discussed above.
 - (ff) Slowly, carefully advance the stent delivery system over the wire, gently pulling back on the wire to make sure the tip remains in a stable position.
 - (gg) When a good position is achieved across the lesion, remove all slack in the delivery system. Now, the stent is ready for deployment.
 - (hh) As in most self expanding stents, it is deployed by stabilizing the inner part of the delivery system then unlocking and retracting the pull-back handle of the outer retractable sheath of the delivery catheter, exposing the stent, and allowing it to expand. These stents are designed to be incredibly simple to deploy, since rocket scientists are not the people usually using them.
 - (ii) When the stent is fully expanded, re-advance the outer sheath of the delivery catheter, lock it, and remove the delivery catheter, leaving the wire in place.
 - (jj) A microcatheter is then advanced over the wire, manipulated through the stent on the venous side of the fistula.
 - (kk) Coiling of the fistula can then proceed.
12. Stent-graft placement for active bleeding technique
- (a) In the setting of a massive bleeding from a carotid blow-out or post-traumatic bleeding, pretreatment with antiplatelet agents is not advisable. Most practitioners would load the patient with clopidogril (usually 300–600 mg) only after the stent placement and only after the bleeding has stopped.
 - (b) A proximal balloon placed via a second guide catheter placed via a second groin puncture could be placed to reduce any active bleeding. Alternatively, external packing may control the bleeding while the endovascular procedure is underway. In a dire situation, someone may need to manually compress the bleeding site until it is controlled, but their hands will be exposed in the X-ray field and potentially make fluoroscopic imaging difficult.
 - (c) Size the stent-graft appropriately for the parent artery (usually a little wider than the parent artery) and for the lesion being stented (usually at least 4 mm coverage on either side of the lesion).
 - (d) Obtain a good roadmap mask that shows the bleeding site to be treated and also the vessel proximally and distally as much as possible.
 - (e) Consider placing an external radio-opaque marker over the bleeding site to ensure coverage by the stent-graft even if the patient moves.
 - (f) As a general rule, a 0.014 in., 300 cm exchange wire is first placed quite distal to the lesion being stented by the first placement of a standard microcatheter, then, after the placement of the wire (with a J-shaped tip) the microcatheter is carefully removed, leaving the wire in place. Great care must be taken not to traumatize the bleeding vessel during this process.
 - (g) Always keep the wire tip in view and ensure that it stays in a larger vessel and does not injure the vessel wall.
 - (h) Slowly, carefully advance the stent delivery catheter over the wire, gently pulling back on the wire to make sure the tip remains in a stable position.
 - (i) Once the stent is in position, remove any slack in the wire and stent delivery catheter. This is critical for obtaining easy and accurate deployment.
 - (j) If a proximal guide catheter is in place, perform a follow-up arteriogram by a contrast injection via the guide catheter.
 - (k) If the stent is not in proper position, change the position and repeat the arteriogram.
 - (l) When a good position is achieved across the neck of the lesion, the stent is ready for deployment.
 - (m) For a Jostent®, the stent is deployed by slowly inflating the balloon under roadmap guidance to match the size of the parent artery. Do not exceed the maximum recommended pressure, and be careful not to disrupt the site of bleeding.

- (n) When it appears that the stent is opened up to the proper size, deflate the balloon and carefully disengage it from the open stent. It may be stuck to the stent and may require another inflation/deflation cycle to free it up. Be careful not to move the stent when trying to pull back on the balloon.
- (o) Once the balloon is deflated and disengaged, perform a follow-up arteriogram via the guide catheter.
- (p) If the stent is not fully apposed to the vessel wall, re-insert the balloon into the stent and attempt to dilate further. Do not exceed maximum pressure for the balloon. If necessary, the balloon could be exchanged for a new low-compliance coronary angioplasty balloon sized to the vessel diameter and no longer than the stent.
- (q) Remember that the outer diameter of the stent is more than that of the inner lumen, so the vessel will be dilated around the stent to a greater degree than expected for the size of the balloon used.
- (r) Assuming that the stent was properly sized and positioned in the first place, it should nicely fit the vessel and occlude the lesion when fully deployed. If not, consider the placement of a second stent-graft.
- (s) The use of self expanding stent-grafts for bleeding vessels is similar to the placement of self expanding carotid stents, as is discussed in extracranial detail in the Extracranial Angioplasty and Stent Procedure Chap. 20.
- (t) The Wallgraft™ or Viabahn® requires the use of very large sheaths, making it impractical to use a separate guide catheter to deploy the stent. One can use a sufficiently large Shuttle™ sheath as a guide catheter and position it in the vessel leading to the bleeding site. This improves the stability of the system during stent deployment and also allows repeated contrast injections as necessary.
- (u) The 300-cm wire is first placed quite distal to the lesion being stented as discussed above.
- (v) Slowly, carefully advance the stent delivery over the wire, gently pulling back on the wire to make sure the tip remains in a stable position.
- (w) When a good position is achieved across the lesion, the stent is ready for deployment.
- (x) As in most self expanding stents, the stent-graft is deployed by stabilizing the inner part of the delivery system as the outer part of the delivery catheter is pulled back, exposing the stent, and allowing it to expand.
- (y) The stent delivery catheter can then be removed, and a follow up arteriogram will determine whether the stent-graft has sealed the bleeding site.
- (z) If the stent is not fully apposed to the vessel wall, insert an appropriately sized angioplasty balloon into the stent and attempt to dilate further. Use the minimum pressure required to slightly dilate the stent. Do not inflate the balloon outside the stent.
- (aa) Consider the placement of a second self-expanding stent or stent-graft to seal any continued leak.

8.4.5.1. Post-procedure puncture site care

Once the procedure is completed, the catheters are removed. If systemic heparin was administered, obtain an ACT to see whether the patient is still anticoagulated. Protamine can be given to reverse heparin, as long as the patient is not an insulin-dependant diabetic or has other contraindications. The sheath can be removed and hemostasis should be obtained by manual pressure. Alternatively, one can use a closure device. The authors usually use the Perclose® Proglide™ (Abbott Laboratories, Redwood City, CA). The patient should be kept at strict bedrest with the legs extended for at least 2h, depending on the sheath size. If a 5 French or smaller sheath was used, another option is to apply a Syvek hemostatic patch (Marine Polymer Technologies, Danvers, MA) then keep the patient at bedrest for two hours.

8.4.5.2. Post-procedure management

1. Complete the neurological exam.
2. Admit to the ICU with vital signs, neuro exams and groin checks Q 1h.

- (a) It is not uncommon for patients undergoing embolization procedures to have some pain in the area treated the evening after the procedure.
- 3. IV fluids (normal saline) at 100 ml h⁻¹ until the patient is taking oral fluids well.
- 4. Only patients that had stent-assisted coiling or stent-graft placement should remain on antiplatelet therapy (clopidogril 75 mg daily for 3 months, aspirin 80 mg daily indefinitely). Other post-embolization patients are not routinely treated with antithrombotic agents.
- 5. After embolization of high flow AVF or active bleeding it is advisable to closely monitor the blood pressure post procedure.
- 6. Most patients after embolization for tumors or AVMs may go to surgery within a day or two.
- 7. Those who do not have planned surgery after extracranial embolization procedures may be able to be discharged to home later the same day or on post-procedure day 1.
- 8. Patients undergoing embolization of tumors or AVMs involving the spinal cord should be observed for a few days to watch for signs of swelling and/or venous congestion.
- 9. If there is a suspicion of venous congestion, consider heparin therapy. The authors rarely use heparin post-procedure.
- 10. Depending on the lesion treated, there may or may not be a need for routine radiographic follow-up, and are usually followed clinically and with cross-sectional imaging.
- 11. Patients who underwent what was felt to be definitive treatment of a spinal vascular lesion should have, at least 6 months: catheter angiogram and gadolinium-enhanced MRA. If the studies agree and there is no need for additional treatment, an MRA is obtained on a yearly basis indefinitely.

8.5. Tips on specific disease processes

8.5.1. Tips: Head and neck embolization

1. Extracranial arteriovenous malformation (AVM)
 - (a) Indications for extracranial AVM embolization include pre-operative flow reduction or palliation for bleeding, cosmetic deformity or pain.
 - (b) Since these are infiltrative lesions that intimately involve normal structures, complete cure is rare, even with radical embolization plus surgery.
 - (c) Particle embolization is effective for preoperative embolization, but is less desirable for palliative treatment since the occlusion may be temporary and the clinical benefits transient.
 - (d) Embolization with nBCA glue provides long-term occlusion if an intranidal deposit of glue is achieved.
 - (e) Transarterial embolization with the microcatheter positioning in or near the nidus is possible.
 - (f) An effective way to occlude the nidus of superficial AVMs is a direct puncture and embolization with glue¹⁶ or sclerotherapy with ethanol.¹⁷
 - (g) Flow control with either transarterial embolization or percutaneous needle injections can be achieved by direct external compression of external draining veins during the glue or ethanol injection.
 - (h) In patients whose external carotid arteries have been previously ligated in a desperate attempt to treat the lesion, embolization may still be possible by a direct needle puncture of the feeding vessels and embolization with glue distal to the ligation.¹⁰
 - (i) A more complicated solution is to surgically reconstruct the ligated vessel, which can be a reasonable option if ischemic symptoms are present in the territory distal to the ligation.²¹
 - (j) Especially when using the liquid embolic agents, extreme care should be taken not to allow the occlusive agent to enter dangerous anastomoses to brain, spinal cord, or eye. (see Chap. 1 for descriptions of the many anastomoses)

- (k) It is also important to keep glue, ethanol, or even small (less than 300 μm) particles out of the vessels supplying cranial nerves, by doing provocative testing, if possible, or at least keeping the embolic agent strictly within the nidus.
 - (l) It is also important to keep liquid embolics or small particles out of cutaneous branches of the superficial temporal or facial. That can result in severe pain and ischemic injury to the skin that can cause blistering and necrosis.
 - (m) The bottom line with these extracranial AVMs: Less is more. Do not be too aggressive and the risk of complications will be reduced.
2. Superficial venous and lymphatic malformation
- (a) These lesions are usually cosmetic problems that were present at birth and can usually be accurately diagnosed on MRI imaging.
 - (b) The lack of a bruit or palpable pulsations differentiates these lesions from an AVM.
 - (c) Unlike AVMs, there is absolutely no role for transarterial embolization of any kind. Sadly, the authors have seen too many patients who have been mis-diagnosed and previously treated by transarterial embolization with absolutely no benefit.
 - (d) Percutaneous sclerotherapy and/or laser treatments and/or surgical excision are the effective treatments.¹⁷
3. Extracranial arteriovenous fistula (AVF)
- (a) Congenital head and neck AVF are rare, but often present with a pulsatile mass and may have high-output cardiac failure. They seem to have a predilection for arising from the internal maxillary artery.^{22, 23}
 - (b) These congenital AVFs were previously treated with detachable balloons, but more recently, transarterial embolization using GDC coils and glue has been successful.²⁴
 - (c) The goal is to occlude the fistula directly because proximal occlusion is destined to fail thanks to the generous facial collaterals.
 - (d) In high-flow AVFs, care must be taken to size the coils (or balloon) large enough to prevent passage through the fistula into the veins, and eventually into the lungs.
 - (e) Post-traumatic and post-surgical AVFs in the head and neck can occur in a wide variety of locations and the treatment depends on the symptoms and vascular anatomy.
 - (f) In an expandable vessel, such as an external carotid branch, coil and/or glue occlusion of both the fistula and parent artery, or trapping may be an option. If at all possible, the fistula and proximal vein should be occluded to prevent the possibility of collateral flow maintaining the patency of the fistula.
 - (g) If thoroughly disrupted and in the presence of adequate collateral flow to the brain, trapping to occlude carotid or vertebral fistulae can also be done after test occlusion. Detachable coils or detachable balloons (where available) are the usual embolic agents.
 - (h) Sporadic reports of stent-grafts to treat carotid or vertebral AVFs have shown the devices are effective in occluding the fistula and maintaining the flow in the parent artery, at least acutely.²⁵⁻²⁷ However long-term patency of these devices is unknown.
 - (i) Vertebral venous AVF are usually post-traumatic, but may be spontaneous,^{28, 29} especially in children, or those with underlying vascular fragility syndromes such as Ehlers Danlos or neurofibromatosis.
 - (j) Vertebral venous AVF can often be treated with balloons or coils on the venous side of the fistula preserving flow.^{30, 31}
4. Bleeding
- (a) Idiopathic epistaxis
 - Endovascular treatment for nosebleeds usually consists of superselective catheterization with particle embolization of the nasal vessels, usually the sphenopalatine arteries.
 - The authors plead against use of coil embolization for idiopathic epistaxis: They only block access for later re-embolization when the inevitable collateral vessels allow bleeding to return.
 - Rarely, post-traumatic epistaxis may be associated with vessel disruption and pseudoaneurysm formation for which coil placement and/or glue injection at the site of vessel disruption may be appropriate.

- A study of 70 patients embolized for epistaxis showed 86% had effective relief of bleeding, and only one had a serious neurological complication.
 - Other series with over 100 patients has up to 17% acute complication rate for epistaxis embolization and 1–2% long-term deficits.^{32, 33}
 - Complications can be minimized by careful attention to angiographic anatomy and awareness of dangerous anastomoses.
 - Provocative testing with amobarbital and lidocaine prior to embolization is an added safety factor.⁵
 - Always check the contralateral sphenopalatine artery angiographically, even if the bleeding is obviously unilateral, because there can be side-to-side collaterals.³⁴ The authors frequently embolize the contralateral sphenopalatine in all cases, just to be certain, but use large (at least 500µm) particles to minimize the risk of nasal mucosal necrosis.
 - Ethmoidal branches from the ophthalmic may be the cause of treatment failure after embolization of the internal maxillary artery. There has been a case report of using embolization of the ophthalmic for epistaxis³⁵ but this is decidedly not recommended due to the risk to vision and the availability of a fairly easy and safe surgical procedure to ligate these vessels.
 - Accessory meningeal arteries may also rarely be a source of bleeding in epistaxis and can be embolized.³⁶
 - A review of embolization compared to internal maxillary ligation suggested that ligation was more effective and, although the complications were more frequent than for embolization, the major complications of embolization (stroke) were more serious.³⁷
 - In some centers, endoscopic ligation of the sphenopalatine artery is becoming a minimally invasive, safe, and effective first choice for the treatment of epistaxis.³⁸
 - Embolization may become a second line choice after a failed endoscopic ligation, or where the expertise for endoscopic ligation is unavailable.
- (b) Post-traumatic and post-surgical bleeding
- The considerations for treating post-traumatic or post-surgical bleeding are very similar to those described for post-traumatic and post-surgical AVF (above). The main difference is that there is a much more acute sense of urgency to occlude active bleeding as opposed to the more controlled situation of an AVF.
 - A general rule is that disrupted, bleeding vessels should be occluded definitively, except in cases when an obvious major neurological deficit would be expected.
 - For quick, definitive closure of the bleeding vessels, the main endovascular tools needed are detachable balloons (if available), detachable (preferably fibered to speed thrombosis) coils (for larger vessels) or nBCA glue (for smaller vessels).
 - Consider the use of a proximal balloon catheter to control bleeding while catheterization and embolization is going on.
 - For disruption of carotid or vertebral arteries, the use of stent-assisted coiling of any pseudoaneurysm may be an option for subacute to chronic lesions that have an organized, fibrotic wall. However, for an acute pseudoaneurysm with active bleeding, placement of coils in the pseudoaneurysm is not a good idea, because the walls of the pseudoaneurysm may be quite friable and the coils will not prevent further expansion and bleeding of the pseudoaneurysm.
 - If occlusion of the carotid does not appear to be an option based on limited collateral flow to the brain or a positive test occlusion, stent-graft placement may be the only endovascular option.
 - Prior to any major vascular occlusion, consider the surgical options of vascular repair or bypass, if the anatomic location is favorable.
- (c) Bleeding tumors
- Embolization of tumors is most commonly accomplished using particles, since they tend to lodge in the small vessels of the tumor bed and produce sufficient devascularization for surgical excision.

- Particles may also be used in the case of actively bleeding tumors, but, if possible, it may be quicker and more definitive to stop the bleeding with nBCA glue, as long as a close microcatheter position is attainable and no dangerous anastomoses are present.
- If endovascular microcatheter access to the bleeding vessel is not possible, direct needle puncture and glue injection may be possible.

(d) Carotid blow-out syndrome

- The term carotid blow-out has been used to indicate catastrophic, sudden bleeding from the carotid in patients after surgical treatment for head and neck malignancy.³⁹
- In popular jargon the term often refers to any sudden, spontaneous bleeding from the carotid.
- It occurs in 5% or fewer cases of advanced cancer patients after surgery and does not seem to be necessarily related to preoperative radiation therapy⁴⁰ although anecdotally, it may be seen soon after radiation therapy.⁴¹
- In any case, it tends to occur in patients whose carotid may be minimally covered by healthy connective tissue.
- Carotid blow-out is one of the most urgent situations imaginable, since patients can bleed to death, often drowning in their own blood, in minutes.
- The airway should be secured by intubation, if not already done.
- The bleeding site is packed to control bleeding and emergent angiography is helpful if there is time, since often the exact site of bleeding may be uncertain.
- A large caliber sheath should be placed to maximize options for devices.
- In patients that are not actively bleeding at the time of the arteriogram, pseudoaneurysm is the usual angiographic sign of the bleeding site.⁴²
- Parent artery occlusion is the usual treatment, unless the collateral flow is limited by angiographic criteria. Test occlusion could be performed if the patient is clinically stable.
- Delayed ischemic complications occur in 15–20% of cases with carotid occlusion, so there is greater interest in stent-graft placement for carotid blow-out.⁹
- Results with self-expanding stent-grafts is promising, but long-term patency rates are unknown. In a series of three patients treated for carotid with stent-grafts two became thrombosed and/or exposed.⁴³
- The disorder can be a long-term problem since multiple episodes of massive bleeding were encountered in 26% of patients with carotid blow-out.⁴⁴

5. Extracranial vascular tumors

(a) Juvenile nasopharyngeal angiofibroma

- This is a hypervascular tumor in young boys that usually presents with nasal bleeding and nasal obstruction. In females, hemangiopericytoma can have a similar clinical presentation.
- Angiographically, these show an intense tumor blush supplied mainly by the distal internal maxillary artery branches with variable contributions from the accessory meningeal, and ascending pharyngeal. Larger tumors may be fed from the petrous and cavernous carotid branches, the middle meningeal, and even the transverse facial.
- Preoperative particle embolization of the feeding arteries is effective in reducing blood loss, especially in larger tumors.⁴⁵
- Vision loss from central artery embolization⁴⁶ and facial nerve palsy⁴⁷ have been reported as a complication of angiofibroma embolization. This emphasizes the need for careful attention to technique, vigilance for dangerous anastomoses, and the use of provocative testing.
- Direct tumor needle puncture and embolization with glue is an option for these tumors.⁴⁸ Tumors may have feeders from the carotid, potentially allowing retrograde flow of glue to the carotid, so constant vigilance for visualization of dangerous collaterals during the glue injection is mandatory.

- (b) Parangioma (aka chemodectoma, glomus tumor)
- These include glomus jugulare, glomus tympanicum, carotid body tumors, glomus vagale, or rare paragangliomas of the larynx, orbit, paranasal sinuses, or elsewhere in the head and neck.
 - The jugulare, tympanicum, carotid body, and vagale tumors all tend to have dominant vascular supply from one or more branches of the ascending pharyngeal artery.
 - On angiography, these lesions have an intense tumor blush, often with some arteriovenous shunting.
 - When they become very large, it is sometimes difficult to decide from which location it arose. It may have intracranial, even intradural extension, usually in the posterior fossa, with blood supply from the anterior-inferior cerebellar artery or other intracranial branches in the posterior fossa.
 - The primary indication for endovascular treatment is preoperative embolization. Very rarely, inoperable lesions may be embolized in an effort to slow the progression of the tumor.
 - Embolization is usually accomplished using particle embolization from a transarterial route.⁴⁹ Given the usual blood supply from vessels with a dominant supply to cranial nerves, it is prudent to perform provocative testing before embolization. If a deficit occurs with lidocaine injection, one can still embolize with larger particles (over 300 μm).
 - The vascular tumor may be directly punctured with a needle and injected with nBCA glue to devascularize it.^{12-14, 50}
 - Direct puncture with glue embolization still carries a risk of stroke through reflux of glue into carotid branches.⁵¹
 - Onyx[®] embolization of both the arteries and veins may provide even greater hemostasis for the surgeon removing large paragangliomas.⁵²
- (c) Other vascular tumors.
- Very vascular metastases and other rare tumors in the head and neck can undergo preoperative embolization.
 - Transarterial particle embolization is most commonly done for any lesion with a capillary bed to trap small particles.
 - Rarely, direct puncture with glue injection may be done when arterial access is difficult.^{12, 14}
 - Large hemangiomas of the head and neck (usually in infants) can develop platelet consumption in the Kasabach-Merritt syndrome. Along with the medical treatment using corticosteroids and alpha-interferon, transarterial embolization can help control the coagulopathy associated with this rare disease.^{53, 54}

8.5.2. Tips on spinal embolization

- (a) Type I spinal dural arteriovenous fistula (dAVF)
- Particle embolization of fistulae has been shown to be a temporary solution, and recurrence is by far the rule, not the exception.^{55, 56}
 - Glue embolization is much more effective, with 55% improvement in gait and 15% recurrence rate.⁵⁷
 - A contra-indication for embolization is a spinal cord feeder arising from the same radicular artery supplying the fistula in approximately 6% of cases.⁵⁸
 - Endovascular treatment consists of full-column nBCA injection in the radicular artery feeding the fistula with glue dilute enough to be pushed through the fistula into the intradural vein.
 - The authors frequently place a microcoil in the lumbar or intercostal feeder beyond the radicular branch, to prevent the glue from entering muscular branches and causing pain.
 - Post-embolization CT confirming intradural venous location of the glue column seems to be a good way to predict who will have a long-term cure.⁵⁹
 - Either surgery or endovascular treatment helps with gait disability, but not for bladder dysfunction if the symptom duration prior to treatment is over a year.⁶⁰

- Several groups advocate an attempt at endovascular treatment first, reserving surgical treatment for unsuccessful embolization.^{61, 62}
 - Close clinical and imaging follow-up is needed in all spinal fistula patients. Recurrence of symptoms after apparently successful treatment should prompt a full angiographic workup, since collaterals may enlarge to supply the fistula and even remote new fistulae may develop.⁵⁸
- (b) Type II spinal intramedullary AVM
- High-quality spinal angiography must be carefully studied to determine all arterial feeders, the relationship with normal spinal cord vessels and associated intranidal aneurysms.
 - A good rule of thumb is to not treat the lesion until the complex anatomy is thoroughly understood and a plan of action has been formulated.
 - Slow PVA particle embolization has been advocated for intramedullary AVMs.^{63, 64}
 - The endpoint of particle embolization can be objectively determined by the serial provocative testing (stop when it becomes positive) and serial pressure measurements from the microcatheter (stop when it rises to 90% of systemic pressure).⁸
 - Lesions embolized with particles frequently recanalize.^{55, 65}
 - Embolization with nBCA may give more effective and safer treatment in experienced hands.^{1, 66}
 - Monitoring with SSEP and MEP as well as provocative testing prior to any embolization is very helpful in reducing complications.^{1, 6, 7, 67}
 - Catheterization of the nidus with a flow directed microcatheter is the goal, with a careful full column glue injection after a negative provocative testing.
 - Aneurysms associated with the AVM should be specifically targeted for embolization to reduce the risk of AVM bleeding.⁶⁸
 - Reports of embolization of intramedullary AVMs with Onyx^{®69, 70} have a 37% acute cure rate, 82% good clinical result and no neurological procedural complications in an initial series of 17 patients.
 - A study of functional and emotional quality of life in spinal cord AVM patients after embolization showed significantly worse scores compared to patients with post-traumatic spinal cord problems.⁷¹ This suggests that further improvements in treatment of these patients are necessary.
- (c) Type III juvenile AVM
- These diffuse AVMs with cord and segmental spinal and paraspinal nidus are difficult to treat, or at least to cure, but are extremely rare.
 - Palliative embolization with glue or Onyx[®] for symptom reduction has been sporadically reported.^{72, 73}
- (d) Type IV perimedullary AVF
- These are rare perimedullary fistulae without an intervening nidus, usually presenting with progressive myelopathy. They can have multiple arterial feeders and prominent congestion of the perimedullary veins that can make the angiographic pictures challenging to figure out.
 - As with all spinal vascular malformations, high quality spinal angiography and a thorough visualization and understanding of the vascular anatomy and pathology are mandatory before considering treatment.
 - Pre-operative embolization via a transarterial route has been successful and reported in several small series.⁷⁴⁻⁷⁷
 - Surgical treatment is often used for easily accessible fistulae along the posterior aspect of the cord and for those in which embolization failed to occlude the fistula.^{78, 79}
 - AVM or AVF of the conus medularis or filum terminale is usually best treated surgically.^{66, 79}
 - For the large fistulae (so-called Type IV-c) occasionally one can do transvenous coil occlusion of the fistula either via a standard trans-femoral venous approach⁷⁸ or through an intra-operative access to the dilated veins.⁸⁰
 - Primary endovascular treatment for giant fistulae with detachable balloons in ten patients reported six good clinical results and one complication caused by migration of the balloon into the draining vein.⁸¹ In the United States, detachable balloons are currently not an option, however.
 - A French group uses glue via transarterial embolization with 67% angiographic cure, 22% transient neurological deficits, but improvement in

- all at follow-up.⁸² The group reports stable clinical improvement even if complete angiographic cure is not obtained.⁸³
- For the high flow fistulae, a highly concentrated glue preparation is needed.
 - Careful and complete angiographic follow-up is needed in these patients, since they can develop co-existing separate Type-1 dural fistulae, likely acquired due to the venous hypertension.⁸⁴
- (e) Epidural and paraspinal AVF
- These are rare congenital or acquired fistulae often presenting with radiculopathy, but occasionally with myelopathy if venous drainage backs up into the spinal cord veins.^{85, 86}
 - Treatment may be transarterial embolization, or surgical interruption of the radicular veins that provide the conduit for arterialized blood to the intradural veins.
- (f) Spinal vascular tumors:Pre-operative embolization
- Hemangioblastoma of the cord is sporadically reported to benefit from preoperative embolization.^{87, 88}
 - Hemangioblastomas in the thoracolumbar region underwent preoperative particle embolization with transient worsening myelopathy in 1/4 cases treated.⁸⁹
 - Primary bone lesions (e.g., aneurysmal bone cyst) are rare, but can benefit from preoperative particle embolization.
 - Vascular tumors in the spinal region, most commonly metastatic renal cell cancer or less commonly thyroid cancer seem to benefit greatly from preoperative embolization with particles.⁹⁰⁻⁹²
 - *Vigilant* angiographic search for coexistent or collateral supply from the feeding vessels to spinal cord vessels should be done and serial provocative testing with clinical and/or SSEP and MEP monitoring can reduce the risk of inadvertent passage of emboli to the spinal cord circulation.⁹¹
 - Symptomatic spinal osseous hemangiomas may benefit from transarterial preoperative embolization⁹³ or percutaneous vertebroplasty that involves injection of polymethyl methacrylate (PMMA) via a large-bore bone biopsy needle into the lesion.⁹⁴
 - Hemangiomas in the spine may also be treated with direct needle puncture and ethanol injection, but volumes should be kept below 15ml to prevent complications.⁹⁵

8.6. Complications: Avoidance and management

8.6.1. Complications of extracranial embolization

Informed consent prior to any interventional procedure must include a discussion of the risk of complications. Published reports of series of embolization procedures should not be relied on to indicate the true risk of complications. It is human nature to rush to publicize good results and gloss over the bad. Especially in the case of extracranial embolization, the procedures are widely varied in the techniques and agents used and territories involved, so results and complications of, for example, epistaxis embolization with particles cannot be used to predict results from facial AVMs with nBCA. The operator's personal experience and complication rates should also be disclosed if known.

8.6.1.1. Neurological complications

1. A risk of thromboembolic complications from clot formation, causing cerebral or spinal cord ischemia.
2. Stroke, blindness, or spinal cord infarct may occur from reflux of embolic material or passage through dangerous anastomoses.

3. Cranial nerve defect can occur with embolic material entering the blood supply to the nerve.
4. In spinal AVM or AVF, passage of emboli into the veins, or even thrombosis induced by the embolization may worsen venous congestion of the cord and cause worsening symptoms.^{58, 81}
5. Large AVFs with large draining veins may swell and compress neural structures after embolization.
6. Access complications may occur with dissection of access vessels, specifically the common carotid or subclavian.
7. Microcatheters or wires may fracture and become an embolus.
8. When using glue, the microcatheter may be glued in place and/or the catheter may break and become an embolus to an intracranial vessel.

8.6.1.2. Nonneurological complications

1. Embolization of superficial vessels in the head and neck can result in ischemia and necrosis of skin, mucosa, or other tissues.
2. In high-flow AV fistulae embolic agents might embolize to the pulmonary circulation.
3. Anaphylactoid reactions to iodinated contrast or any of the medications used can occur as with any endovascular procedure.
4. Similarly, groin hematomas or other groin arterial injury can occur, as in any endovascular procedure.
5. Deep venous thrombosis and pulmonary embolism can occur.
6. Anesthesia-related complications can occur if using general anesthesia.

8.6.2. How to avoid extracranial embolization complications in ten easy steps

1. Obtain and study the angiographic evaluation of the lesion and surrounding structures to have a clear understanding of the anatomy and pathology in the case.
2. Carefully study superselective microcatheter arteriograms obtained prior to embolization to look for reflux into normal territories or filling of dangerous anastomoses.
3. One should familiarize oneself with the devices that will be used during the case, particularly if it is a device not commonly used (like stent-grafts or detachable balloons).
4. Always pay attention to basic technique, including flushing technique, check heparinized saline infusions, and be gentle with all device manipulation.
5. In awake patients do provocative testing with amobarbital and lidocaine.
6. Even when using general anesthesia in spinal embolization cases use neurophysiological monitoring and provocative testing.
7. When embolizing with any agent, inject no faster than was done for the contrast injection during the superselective microcatheter arteriogram.
8. Immediately stop if reflux occurs or if different vessels (potentially dangerous anastomoses) appear.
9. Periodic guide catheter or microcatheter contrast injections for arteriograms to monitor progress during the case and to decide when to stop.
10. Always pay attention to the patient: their vital signs, neurological function, any neurophysiological monitoring, and comfort level. It is all too easy to expend all of one's attention on the procedural aspects and forget the person underneath the sterile drape.

8.7. References

1. Niimi Y, Sala F, Deletis V, Setton A, de Camargo AB, Berenstein A. Neurophysiologic monitoring and pharmacologic provocative testing for embolization of spinal cord arteriovenous malformations. *AJNR Am J Neuroradiol* 2004;25(7):1131-8
2. Kallmes DF, McGraw JK, Evans AJ, et al. Thrombogenicity of hydrophilic and nonhydrophilic microcatheters and guiding catheters. *AJNR Am J Neuroradiol* 1997;18(7):1243-51

3. Touho H, Ohnishi H, Karasawa J. Endovascular treatment with an ultra-thin 4-French guiding catheter via the femoral and transbrachial routes – technical note. *Neurol Med Chir (Tokyo)* 1995;35(10):759–64.
4. Fanning NF, Pedroza A, Willinsky RA, terBrugge KG. Segmental artery exchange technique for stable 4F guiding-catheter positioning in embolization of spinal vascular malformations. *AJNR Am J Neuroradiol* 2007;28(5):875–6.
5. Deveikis JP. Sequential injections of amobarbital sodium and lidocaine for provocative neurologic testing in the external carotid circulation. *AJNR Am J Neuroradiol* 1996;17(6):1143–7.
6. Katayama Y, Tsubokawa T, Hirayama T, Himi K, Koyama S, Yamamoto T. Embolization of intramedullary spinal arteriovenous malformation fed by the anterior spinal artery with monitoring of the corticospinal motor evoked potential – case report. *Neurol Med Chir (Tokyo)* 1991;31(7):401–5.
7. Sala F, Niimi Y, Krzan MJ, Berenstein A, Deletis V. Embolization of a spinal arteriovenous malformation: Correlation between motor evoked potentials and angiographic findings: Technical case report. *Neurosurgery* 1999;45(4):932–7; discussion 7–8.
8. Touho H, Karasawa J, Ohnishi H, Yamada K, Ito M, Kinoshita A. Intravascular treatment of spinal arteriovenous malformations using a microcatheter – with special reference to serial xylocaine tests and intravascular pressure monitoring. *Surg Neurol* 1994;42(2):148–56.
9. Lesley WS, Chaloupka JC, Weigle JB, Mangla S, Dogar MA. Preliminary experience with endovascular reconstruction for the management of carotid blowout syndrome. *AJNR Am J Neuroradiol* 2003;24(5):975–81.
10. Gobin YP, Pasco A, Merland JJ, Aymard AA, Casasco A, Houdart E. Percutaneous puncture of the external carotid artery or its branches after surgical ligation. *AJNR Am J Neuroradiol* 1994;15(1):79–82.
11. Han MH, Seong SO, Kim HD, Chang KH, Yeon KM, Han MC. Craniofacial arteriovenous malformation: Preoperative embolization with direct puncture and injection of *n*-butyl cyanoacrylate. *Radiology* 1999;211(3):661–6.
12. Casasco A, Herbreteau D, Houdart E, et al. Devascularization of craniofacial tumors by percutaneous tumor puncture. *AJNR Am J Neuroradiol* 1994;15(7):1233–9.
13. Abud DG, Mounayer C, Benndorf G, Piotin M, Spelle L, Moret J. Intratumoral injection of cyanoacrylate glue in head and neck paragangliomas. *AJNR Am J Neuroradiol* 2004;25(9):1457–62.
14. Chaloupka JC, Mangla S, Huddle DC, et al. Evolving experience with direct puncture therapeutic embolization for adjunctive and palliative management of head and neck hypervascular neoplasms. *Laryngoscope* 1999;109(11):1864–72.
15. Schirmer CM, Malek AM, Kwan ES, Hoit DA, Weller SJ. Preoperative embolization of hypervascular spinal metastases using percutaneous direct injection with *n*-butyl cyanoacrylate: Technical case report. *Neurosurgery* 2006;59(2):E431–2; author reply E-2.
16. Ryu CW, Whang SM, Suh DC, et al. Percutaneous direct puncture glue embolization of high-flow craniofacial arteriovenous lesions: A new circular ring compression device with a beveled edge. *AJNR Am J Neuroradiol* 2007;28(3):528–30.
17. Deveikis JP. Percutaneous ethanol sclerotherapy for vascular malformations in the head and neck. *Arch Facial Plast Surg* 2005;7(5):322–5.
18. Puig S, Aref H, Brunelle F. Double-needle sclerotherapy of lymphangiomas and venous angiomas in children: A simple technique to prevent complications. *AJR Am J Roentgenol* 2003;180(5):1399–401.
19. Mason KP, Michna E, Zurakowski D, Koka BV, Burrows PE. Serum ethanol levels in children and adults after ethanol embolization or sclerotherapy for vascular anomalies. *Radiology* 2000;217(1):127–32.
20. Teng MM, Chang CY, Chiang JH, et al. Double-balloon technique for embolization of carotid cavernous fistulas. *AJNR Am J Neuroradiol* 2000;21(9):1753–6.
21. Riles TS, Berenstein A, Fisher FS, Persky MS, Madrid M. Reconstruction of the ligated external carotid artery for embolization of cervicofacial arteriovenous malformations. *J Vasc Surg* 1993;17(3):491–8.
22. Halbach VV, Higashida RT, Hieshima GB, Hardin CW. Arteriovenous fistula of the internal maxillary artery: Treatment with transarterial embolization. *Radiology* 1988;168(2):443–5.
23. Gabrielsen TO, Deveikis JP, Introcaso JH, Coran AG. Congenital arteriovenous fistulas supplied by a single branch of the maxillary artery. *AJNR Am J Neuroradiol* 1994;15(4):653–7.
24. Kim BS, Lee SK, terBrugge KG. Endovascular treatment of congenital arteriovenous fistulae of the internal maxillary artery. *Neuroradiology* 2003;45(7):445–50.
25. Redekop G, Marotta T, Weill A. Treatment of traumatic aneurysms and arteriovenous fistulas of the skull base by using endovascular stents. *J Neurosurg* 2001;95(3):412–9.
26. du Toit DF, Leith JG, Strauss DC, Blaszczyk M, Odendaal Jde V, Warren BL. Endovascular management of traumatic cervicothoracic arteriovenous fistula. *Br J Surg* 2003;90(12):1516–21.
27. Schonholz CJ, Uflacker R, De Gregorio MA, Parodi JC. Stent-graft treatment of trauma to the supra-aortic arteries. A review. *J Cardiovasc Surg (Torino)* 2007;48(5):537–49.
28. Yoshida S, Nakazawa K, Oda Y. Spontaneous vertebral arteriovenous fistula – case report. *Neurol Med Chir (Tokyo)* 2000;40(4):211–5.
29. Passos Filho PE, Mattana PR, Pontalti JL, da Silva FM. Endovascular treatment of spontaneous vertebral arteriovenous fistula in children: Case report. *Arq Neuropsiquiatr* 2002;60(2-B):502–4.
30. Merland JJ, Reizine D, Riche MC, et al. Endovascular treatment of vertebral arteriovenous fistulas in twenty-two patients. *Ann Vasc Surg* 1986;1(1):73–8.
31. Halbach VV, Higashida RT, Hieshima GB. Treatment of vertebral arteriovenous fistulas. *AJR Am J Roentgenol* 1988;150(2):405–12.
32. Tseng EY, Narducci CA, Willing SJ, Sillers MJ. Angiographic embolization for epistaxis: A review of 114 cases. *Laryngoscope* 1998;108(4 Pt 1):615–9.
33. Elden L, Montanera W, Terbrugge K, Willinsky R, Lasjaunias P, Charles D. Angiographic embolization for the treatment of epistaxis: A review of 108 cases. *Otolaryngol Head Neck Surg* 1994;111(1):44–50.
34. Shaw SM, Kamani T, Ali A, Manjaly G, Jeffree M. Sphenopalatine-sphenopalatine anastomosis: A unique cause of intractable epistaxis, safely treated with microcatheter embolization: A case report. *J Med Case Reports* 2007;1(1):125.
35. Moser FG, Rosenblatt M, De La Cruz F, Silver C, Burde RM. Embolization of the ophthalmic artery for control of epistaxis: Report of two cases. *Head Neck* 1992;14(4):308–11.
36. Duncan IC, Dos Santos C. Accessory meningeal arterial supply to the posterior nasal cavity: Another reason for failed endovascular treatment of epistaxis. *Cardiovasc Intervent Radiol* 2003;26(5):488–91.
37. Cullen MM, Tami TA. Comparison of internal maxillary artery ligation versus embolization for refractory posterior epistaxis. *Otolaryngol Head Neck Surg* 1998;118(5):636–42.
38. Snyderman CH, Goldman SA, Carrau RL, Ferguson BJ, Grandis JR. Endoscopic sphenopalatine artery ligation is an effective method of treatment for posterior epistaxis. *Am J Rhinol* 1999;13(2):137–40.
39. Borsanyi SJ. Rupture of the carotids following radical neck surgery in irradiated patients. *Eye Ear Nose Throat Mon* 1962;41:531–3.
40. Marcial VA, Gelber R, Kramer S, Snow JB, Davis LW, Vallecillo LA. Does preoperative irradiation increase the rate of surgical complications in carcinoma of the head and neck? A Radiation Therapy Oncology Group Report. *Cancer* 1982;49(6):1297–301.
41. Gupta S. Radiation induced carotid artery blow out: A case report. *Acta Chir Belg* 1994;94(5):299–300.
42. Chaloupka JC, Putnam CM, Citardi MJ, Ross DA, Sasaki CT. Endovascular therapy for the carotid blowout syndrome in head and neck surgical patients: Diagnostic and managerial considerations. *AJNR Am J Neuroradiol* 1996;17(5):843–52.

43. Warren FM, Cohen JJ, Nesbit GM, Barnwell SL, Wax MK, Andersen PE. Management of carotid "blowout" with endovascular stent grafts. *Laryngoscope* 2002;112(3):428-33
44. Chaloupka JC, Roth TC, Putman CM, et al. Recurrent carotid blowout syndrome: Diagnostic and therapeutic challenges in a newly recognized subgroup of patients. *AJNR Am J Neuroradiol* 1999;20(6):1069-77
45. Moulin G, Chagnaud C, Gras R, et al. Juvenile nasopharyngeal angiofibroma: Comparison of blood loss during removal in embolized group versus nonembolized group. *Cardiovasc Intervent Radiol* 1995;18(3):158-61
46. Onerci M, Gumus K, Cil B, Eldem B. A rare complication of embolization in juvenile nasopharyngeal angiofibroma. *Int J Pediatr Otorhinolaryngol* 2005;69(3):423-8
47. Ikram M, Khan K, Murad M, Haq TU. Facial nerve palsy unusual complication of percutaneous angiography and embolization for juvenile angiofibroma. *J Pak Med Assoc* 1999;49(8):201-2
48. Tranbahuy P, Borsik M, Herman P, Wassef M, Casasco A. Direct intratumoral embolization of juvenile angiofibroma. *Am J Otolaryngol* 1994;15(6):429-35
49. Valavanis A. Preoperative embolization of the head and neck: Indications, patient selection, goals, and precautions. *AJNR Am J Neuroradiol* 1986;7(5):943-52
50. Harman M, Etlik O, Unal O. Direct percutaneous embolization of a carotid body tumor with *n*-butyl cyanoacrylate: An alternative method to endovascular embolization. *Acta Radiol* 2004;45(6):646-8
51. Krishnamoorthy T, Gupta AK, Rajan JE, Thomas B. Stroke from delayed embolization of polymerized glue following percutaneous direct injection of a carotid body tumor. *Korean J Radiol* 2007;8(3):249-53
52. Rimbot A, Mounayer C, Loureiro C, et al. Preoperative mixed embolization of a paraganglioma using Onyx. *J Neuroradiol* 2007;34(5):334-9
53. Komiya M, Nakajima H, Kitano S, Sakamoto H, Kurimasa H, Ozaki H. Endovascular treatment of huge cervicofacial hemangioma complicated by Kasabach-Merritt syndrome. *Pediatr Neurosurg* 2000;33(1):26-30
54. Bornet G, Claudet I, Fries F, et al. Cervicofacial angioma and the Kasabach-Merritt syndrome. *Neuroradiology* 2000;42(9):703-6
55. Hall WA, Oldfield EH, Doppman JL. Recanalization of spinal arteriovenous malformations following embolization. *J Neurosurg* 1989;70(5):714-20
56. Nichols DA, Rufenacht DA, Jack CR, Jr., Forbes GS. Embolization of spinal dural arteriovenous fistula with polyvinyl alcohol particles: Experience in 14 patients. *AJNR Am J Neuroradiol* 1992;13(3):933-40
57. Song JK, Gobin YP, Duckwiler GR, et al. *N*-butyl 2-cyanoacrylate embolization of spinal dural arteriovenous fistulae. *AJNR Am J Neuroradiol* 2001;22(1):40-7
58. Niimi Y, Berenstein A, Setton A, Neophytides A. Embolization of spinal dural arteriovenous fistulae: Results and follow-up. *Neurosurgery* 1997;40(4):675-82; discussion 82-3
59. Cognard C, Miaux Y, Pierot L, Weill A, Martin N, Chiras J. The role of CT in evaluation of the effectiveness of embolization of spinal dural arteriovenous fistulae with *N*-butyl cyanoacrylate. *Neuroradiology* 1996;38(7):603-8
60. Song JK, Vinuela F, Gobin YP, et al. Surgical and endovascular treatment of spinal dural arteriovenous fistulae: Long-term disability assessment and prognostic factors. *J Neurosurg* 2001;94(2 Suppl):199-204
61. Westphal M, Koch C. Management of spinal dural arteriovenous fistulae using an interdisciplinary neuroradiological/neurosurgical approach: Experience with 47 cases. *Neurosurgery* 1999;45(3):451-7; discussion 7-8
62. Van Dijk JM, TerBrugge KG, Willinsky RA, Farb RI, Wallace MC. Multidisciplinary management of spinal dural arteriovenous fistulae: Clinical presentation and long-term follow-up in 49 patients. *Stroke* 2002;33(6):1578-83
63. Horton JA, Latchaw RE, Gold LH, Pang D. Embolization of intramedullary arteriovenous malformations of the spinal cord. *AJNR Am J Neuroradiol* 1986;7(1):113-8
64. Theron J, Cosgrove R, Melanson D, Ethier R. Spinal arteriovenous malformations: Advances in therapeutic embolization. *Radiology* 1986;158(1):163-9
65. Biondi A, Merland JJ, Reizine D, et al. Embolization with particles in thoracic intramedullary arteriovenous malformations: Long-term angiographic and clinical results. *Radiology* 1990;177(3):651-8
66. Meisel HJ, Lasjaunias P, Brock M. Modern management of spinal and spinal cord vascular lesions. *Minim Invasive Neurosurg* 1995;38(4):138-45
67. Sala F, Beltramello A, Gerosa M. Neuroprotective role of neurophysiological monitoring during endovascular procedures in the brain and spinal cord. *Neurophysiol Clin* 2007;37(6):415-21
68. Konan AV, Raymond J, Roy D. Transarterial embolization of aneurysms associated with spinal cord arteriovenous malformations. Report of four cases. *J Neurosurg* 1999;90(1 Suppl):148-54
69. Molyneux AJ, Coley SC. Embolization of spinal cord arteriovenous malformations with an ethylene vinyl alcohol copolymer dissolved in dimethyl sulfoxide (Onyx liquid embolic system). Report of two cases. *J Neurosurg* 2000;93(2 Suppl):304-8
70. Corkill RA, Mitsos AP, Molyneux AJ. Embolization of spinal intramedullary arteriovenous malformations using the liquid embolic agent, Onyx: A single-center experience in a series of 17 patients. *J Neurosurg Spine* 2007;7(5):478-85
71. Lundqvist C, Andersen O, Blomstrand C, Svendsen P, Sullivan M. Spinal arteriovenous malformations. Health-related quality of life after embolization. *Acta Neurol Scand* 1994;90(5):337-44
72. Miyatake S, Kikuchi H, Koide T, et al. Cobb's syndrome and its treatment with embolization. Case report. *J Neurosurg* 1990;72(3):497-9
73. Soeda A, Sakai N, Iihara K, Nagata I. Cobb syndrome in an infant: Treatment with endovascular embolization and corticosteroid therapy: Case report. *Neurosurgery* 2003;52(3):711-5; discussion 4-5
74. Barrow DL, Colohan AR, Dawson R. Intradural perimedullary arteriovenous fistulas (type IV spinal cord arteriovenous malformations). *J Neurosurg* 1994;81(2):221-9
75. Hida K, Iwasaki Y, Goto K, Miyasaka K, Abe H. Results of the surgical treatment of perimedullary arteriovenous fistulas with special reference to embolization. *J Neurosurg* 1999;90(2 Suppl):198-205
76. Sure U, Wakat JP, Gatscher S, Becker R, Bien S, Bertalanffy H. Spinal type IV arteriovenous malformations (perimedullary fistulas) in children. *Childs Nerv Syst* 2000;16(8):508-15
77. Mourier KL, Gobin YP, George B, Lot G, Merland JJ. Intradural perimedullary arteriovenous fistulae: Results of surgical and endovascular treatment in a series of 35 cases. *Neurosurgery* 1993;32(6):885-91; discussion 91
78. Halbach VV, Higashida RT, Dowd CF, Fraser KW, Edwards MS, Barnwell SL. Treatment of giant intradural (perimedullary) arteriovenous fistulas. *Neurosurgery* 1993;33(6):972-9; discussion 9-80
79. Cho KT, Lee DY, Chung CK, Han MH, Kim HJ. Treatment of spinal cord perimedullary arteriovenous fistula: Embolization versus surgery. *Neurosurgery* 2005;56(2):232-41; discussion 41
80. Touho H, Monobe T, Ohnishi H, Karasawa J. Treatment of type II perimedullary arteriovenous fistulas by intraoperative transvenous embolization: Case report. *Surg Neurol* 1995;43(5):491-6
81. Ricolfi F, Gobin PY, Aymard A, Brunelle F, Gaston A, Merland JJ. Giant perimedullary arteriovenous fistulas of the spine: Clinical and radiologic features and endovascular treatment. *AJNR Am J Neuroradiol* 1997;18(4):677-87
82. Rodesch G, Hurth M, Alvarez H, Tadie M, Lasjaunias P. Spinal cord intradural arteriovenous fistulae: Anatomic, clinical, and therapeutic considerations in a series of 32 consecutive patients seen between 1981 and 2000 with emphasis on endovascular therapy. *Neurosurgery* 2005;57(5):973-83; discussion 83
83. Rodesch G, Hurth M, Alvarez H, David P, Tadie M, Lasjaunias P. Embolization of spinal cord arteriovenous shunts: Morphological and clinical follow-up and results - review of 69 consecutive cases. *Neurosurgery* 2003;53(1):40-9; discussion 9-50
84. Krings T, Coenen VA, Weinzierl M, et al. Spinal dural arteriovenous fistula associated with a spinal perimedullary

- fistula: Case report. *J Neurosurg Spine* 2006;4(3):241-5
85. Cognard C, Semaan H, Bakchine S, et al. Paraspinal arteriovenous fistula with perimedullary venous drainage. *AJNR Am J Neuroradiol* 1995;16(10):2044-8
 86. Silva N, Jr., Janel AC, Tall P, Cognard C. Spinal epidural arteriovenous fistulas associated with progressive myelopathy. Report of four cases. *J Neurosurg Spine* 2007;6(6):552-8
 87. Tampieri D, Leblanc R, TerBrugge K. Preoperative embolization of brain and spinal hemangioblastomas. *Neurosurgery* 1993;33(3):502-5; discussion 5
 88. Eskridge JM, McAuliffe W, Harris B, Kim DK, Scott J, Winn HR. Preoperative endovascular embolization of craniospinal hemangioblastomas. *AJNR Am J Neuroradiol* 1996;17(3):525-31
 89. Biondi A, Ricciardi GK, Faillot T, Capelle L, Van Effenterre R, Chiras J. Hemangioblastomas of the lower spinal region: Report of four cases with preoperative embolization and review of the literature. *AJNR Am J Neuroradiol* 2005;26(4):936-45
 90. Breslau J, Eskridge JM. Preoperative embolization of spinal tumors. *J Vasc Interv Radiol* 1995;6(6):871-5
 91. Guzman R, Dubach-Schwizer S, Heini P, et al. Preoperative transarterial embolization of vertebral metastases. *Eur Spine J* 2005;14(3):263-8
 92. Olerud C, Jonsson H, Jr., Lofberg AM, Lorelius LE, Sjöström L. Embolization of spinal metastases reduces perioperative blood loss. 21 patients operated on for renal cell carcinoma. *Acta Orthop Scand* 1993;64(1):9-12
 93. Smith TP, Koci T, Mehringer CM, et al. Transarterial embolization of vertebral hemangioma. *J Vasc Interv Radiol* 1993;4(5):681-5
 94. Acosta FL, Jr., Dowd CF, Chin C, Tihan T, Ames CP, Weinstein PR. Current treatment strategies and outcomes in the management of symptomatic vertebral hemangiomas. *Neurosurgery* 2006;58(2):287-95; discussion 95
 95. Doppman JL, Oldfield EH, Heiss JD. Symptomatic vertebral hemangiomas: Treatment by means of direct intralaminar injection of ethanol. *Radiology* 2000;214(2):341-8

9. Thrombolysis for Acute Ischemic Stroke

9.1. Thrombolysis for acute stroke: General considerations

The elements of successful thrombolysis for acute stroke are:

1. Rapid evaluation and decision making
 2. Careful patient selection
 3. Rapid and effective pharmacologic or mechanical thrombolysis
- Speed is critical.* Any potential candidate for thrombolysis should be approached with an eye towards administering IV t-PA, or getting the patient on the angio suite table as soon as possible. The overall strategy consists of the following steps:
1. Make a correct diagnosis of acute ischemic stroke and determine the time of onset.
 2. Focus on the patient examination, *essential tests*, and imaging.
 3. For IA cases:
 - (a) Alert the angio suite technicians and nurses as soon as possible, to permit room and device preparation.
 - (b) Obtain vascular access for the endovascular procedure as soon as possible.
 - If the patient is unable to undergo the procedure awake, he or she should be transferred to the angio suite, placed on the table, and undergo femoral artery sheath placement while the anesthesia service is called. A quick diagnostic angiogram can be done prior to the induction of anesthesia; if necessary, the catheter can be withdrawn into the aortic arch while the patient is intubated.
 - (c) The devices and thrombolytic medications should be obtained and prepared early.
 - Catheters, wires, thrombolytic drugs, and other anticipated devices should be placed on the sterile table and prepared while the patient is being brought to the angio suite, or while the vascular access is being obtained.
 - (d) A decision about the thrombolysis technique (i.e., drug vs. mechanical thrombolysis) should be made as soon as the first angiographic images of the craniocervical circulation are obtained.
 - (e) IA thrombolysis often requires a combination of techniques (e.g., thrombolytic drug infusion plus angioplasty and stenting). As each maneuver is done, the next step should be anticipated and planned.

9.1.1. The art of speed

Numerous thrombolysis trials have demonstrated that the earlier the treatment, the better the chance of a favorable outcome. Treatment within 90min is superior to treatment within 3h,^{1,2} and treatment within 3h is superior to treatment within 6h,^{3,4} and so on. Therefore, every ischemic stroke patient must be evaluated and treated as efficiently and swiftly as possible. The importance of speed was underscored by the scientific statement published by the American Heart Association in 2006 entitled "Reducing Delay in Seeking Treatment by Patients with Acute Coronary Syndrome and Stroke^{5p}":

1. Non-essential tests should be deferred, and the treatment methods (i.e., the angio suite or t-PA) should be made available and prepared rapidly.
 - (a) Non-essential tests, such as a CXR in most cases, should not be allowed to interfere with the work-up. A CXR is not necessary during the initial work-up for most patients with acute stroke.⁶
2. According to the 2003 *Guidelines for the Early Management of Patients With Ischemic Stroke*, patients who are candidates for pharmacologic thrombolysis should complete the CT examination within 25 min of arrival at the emergency department, and the study should be interpreted within an additional 20 min (door to interpretation time of 45 min).⁷

3. Importantly, CT perfusion examination and/or transportation of the patient to the angio suite *should not be delayed while awaiting the blood test results.*
 - (a) Serum creatinine measurement is typically required prior to the procedures using iodinated contrast. However, the 2004 *American College of Radiology Manual on Contrast Media* recommends checking of creatinine only for patients who have established risk factors for contrast-induced nephropathy.⁸ The authors of this handbook will proceed with CT perfusion and with angiography in patients with acute ischemic stroke prior to the blood test results, if necessary, on the grounds that checking of creatinine is really not necessary in many patients, and that the benefit of rapid diagnosis and treatment justifies the relatively low risk of nephropathy.
 - (b) Likewise, pending platelet count and coagulation studies should not delay transportation of the patient to the angio suite, if IA thrombolysis is anticipated. The endovascular procedure can be started and the vascular access can be accomplished while awaiting the laboratory results.
4. Effective triage should be implemented; elective cases and other clinic activities should be bumped or rescheduled to accommodate the patient suffering from acute stroke.

9.1.2. Thrombolytic agents

Several thrombolytic agents are available (Table 9.1). Most work by converting plasminogen to plasmin. The plasmin then cleaves the fibrin meshwork of the thrombus, leading to lysis. Urokinase and streptokinase are the first-generation agents and are not fibrin- (i.e., clot) specific. Urokinase, a naturally occurring serine protease with low antigenicity, was withdrawn from the market in the United States for several years, but has recently been reintroduced. Streptokinase, an activator of plasminogen but not an enzyme, despite the name, has limited usefulness because many patients have pre-formed antistreptococcal antibodies and have the potential for an anaphylactic reaction to this agent. The second-generation agents are fibrin-specific and include prourokinase (aka pro-UK, or saruplase) and alteplase. They have the drawback of lowering the levels of fibrinogen and plasminogen, leading to an increased risk of hemorrhagic complications. Prourokinase is a precursor of urokinase and is converted on the surface of the thrombus to urokinase by fibrin-bound plasmin, resulting in superior fibrin specificity and lytic efficacy, compared to urokinase. Prourokinase has the distinction of being the agent used in the Prolyse in Acute Cerebral Thromboembolism (PROACT) trials,^{9,10} but is not currently available for clinical use in the US. Presently, t-PA is the only agent approved by the FDA specifically for IV thrombolysis for ischemic stroke. The third-generation agents include reteplase and tenecteplase and offer the theoretical advantages of longer half-lives and greater penetration into the thrombus matrix when compared to the second-generation agents. Reteplase is a deletion mutant in which the finger, epidermal growth factor, and kringle-1 domains have been deleted from the wild-type t-PA molecule. Tenecteplase is also a t-PA mutant.

Three main thrombolytic agents are currently available in the United States: alteplase (Activase, Genentech, San Francisco, CA); urokinase (Abbokinase, Abbott Laboratories, Abbott Park, IL); and reteplase (Retavase, Centocor, Malvern, PA). Five milligrams of alteplase are considered equivalent to 1 unit (U) of reteplase. Although each agent has its own theoretical advantages, a direct comparison of the effectiveness of these agents in acute stroke is not available. In a retrospective comparison of t-PA to urokinase for IA thrombolysis, no differences in recanalization rates were found with respect to the thrombolytic agent or dosage.¹¹ Reversal of all thrombolytics can be done by administering fresh frozen plasma in the event of hemorrhagic complication.

Other novel fibrinolytic agents are tenecteplase and desmetoplasase. Tenecteplase is a genetically modified form of t-PA, that has 14-fold greater fibrin specificity, a longer half-life, and 80-fold greater resistance to inhibition by plasminogen activator inhibitor type-1.¹² Treatment with tenecteplase has been found to avoid the systemic plasminogen activation and plasmin generation commonly seen after t-PA therapy. In addition, the absence of a procoagulant effect caused by tenecteplase may reduce the risk of early reocclusion. In a pilot dose-escalation study, 75 stroke patients were treated with IV tenecteplase for < 3 h after symptom onset.¹³ The patients were treated with one of the three doses of tenecteplase: 0.1, 0.2, and 0.4 mg kg⁻¹. No case of symptomatic intracranial hemorrhage was observed during the first 72 h after treatment. Currently, tenecteplase is being evaluated in a larger phase 2 trial.

Desmetopase is one of the four proteases found in the saliva of the blood-feeding vampire bat *Desmodus rotundus*, collectively referred to as *D rotundus* salivary plasminogen activators (DSPAs). Desmetopase is the α -1 variant among the DSPAs and has >72% of amino acid sequence identity with human t-PA. DSPA α -1 induces faster and more sustained recanalization than t-PA, and produces less anti-plasmin consumption and fibrinogenolysis. Furthermore, unlike t-PA, DSPA α -1 does not enhance *N*-methyl-D-aspartate-mediated neurodegeneration.¹⁴ Desmetopase has shown promise in two phase 2 ischemic stroke trials.^{15, 16}

Ancred is a protease derived from Malaysian pit viper venom. In contrast to thrombolytic agents which act on plasminogen, ancred produces a rapid decrease in serum fibrinogen by accelerating cleavage of the fibrinogen A-[alpha] chain.¹⁷ Reduction in serum fibrinogen levels produces anticoagulation by depleting the substrate needed for thrombus formation. Depletion of fibrinogen also reduces blood viscosity.¹⁸

Table 9.1 Intra-arterial thrombolytic agents

		Half-life (min)	Intra-arterial dose	Description
First generation	Urokinase	14–20	500,000–1,000,000 units	Serine protease
Second generation	Prourokinase (NA)	20	6–9 mg	Proenzyme precursor of urokinase
	Alteplase (t-PA)	3–5	5–40 mg	Serine protease
Third generation	Retepase	15–18	4–8 units	Deletion mutant of t-PA

NA Not available, t-PA Recombinant tissue plasminogen activator

9.1.2.1. Patient preparation

EVALUATION

1. History, physical, and neurological exam.
 - (a) Make an accurate diagnosis and pinpoint the time of onset of the stroke symptoms.
 - For patients with stroke symptoms, upon awakening, the time of onset is assumed to be the time the patient was last known to be symptom-free.
 - (b) Localize the stroke symptoms and assess the severity of the stroke (see below: Appendix 2: NIH Stroke Scale).
 - Several conditions can mimic stroke:⁷
 - Seizure
 - Confusional state
 - Syncope
 - Toxic or metabolic syndromes
 - Hypoglycemia
 - Subdural hematoma
 - Brain tumor
2. Blood test (CBC, Cr, PT, PTT).
3. EKG
4. Imaging
 - (a) Essential: Noncontrast head CT.
 - The primary role of CT is to check for an intracranial hemorrhage, which is present in some 15% of the patients presenting with acute stroke. Other potential findings on CT, such as indications of cerebral ischemia, are secondary (see below: Primer on Imaging in Acute Stroke).
 - (b) Optional but very helpful: CT perfusion/CT angiography
 - The authors prefer to obtain a noncontrast head CT and a CT perfusion study on all patients suspected of having an acute ischemic stroke. Routinely combining a CT perfusion and CT angiography study with the screening CT scan eliminates the need for two separate trips to the CT scanner and streamlines the decision making process.

PRE-PROCEDURE PREPARATION

1. IV thrombolysis cases: Obtain t-PA.
2. IA cases: Call the angio suite and make sure that all the nurses, technicians, devices that may be needed are available in the angio suite prior to the procedure.
3. Place 2 peripheral IVs.
 - (a) Glucose-containing solutions should be avoided.⁷
4. Place foley catheter
5. NPO except for medications

9.2. Patient selection for thrombolysis

The following applies mostly to patients with anterior circulation stroke; patient selection for basilar artery thrombolysis is discussed separately below.

9.2.1. Indications

1. Acute ischemic stroke with an onset of symptoms within 3–8 h prior to anticipated treatment
2. Significant neurological symptoms (NIHSS > 4 except for patients with isolated aphasia or hemianopia)
3. Other causes of acute neurological symptoms are excluded (e.g., intracranial hemorrhage, seizures, confusional states, toxic or metabolic states, and brain tumors).

9.2.2. Absolute contraindications

1. Acute intracranial hemorrhage
2. Large hypoattenuating region or mass effect on CT

9.2.3. Relative contraindications

1. Improving neurological symptoms
2. Lacunar stroke
3. Coma
4. Seizure
5. Major stroke (NIHSS >30)
6. Recent history of surgery or intracranial hemorrhage
7. Recent myocardial infarction¹⁹
8. History of anaphylaxis to thrombolytic drugs or iodinated contrast media

9.2.4. Decision-making: IV or IA thrombolysis?

Although IA thrombolysis is FDA-approved for the treatment of selected patients with acute ischemic stroke, IA thrombolysis has emerged as a valid alternative for some patients, depending on the clinical setting. Selection between the two treatments requires consideration of a number of factors (Table 9.2). In brief, the most suitable candidates for IV thrombolysis are patients with relatively small regions of affected cerebral territory who can be treated within 3 h of symptom onset. The most suitable candidates for IA thrombolysis are those with larger vessel occlusions, who can be treated within 6–8 h of symptom onset. A detailed discussion of the factors that favor each particular approach follows the table.

Table 9.2 Patient selection for intravenous or intra-arterial thrombolysis

IV Thrombolysis	
Relative indications	Relative contraindications
<ul style="list-style-type: none"> • Symptom onset < 3 h prior to treatment • Mild to moderate symptoms (NIHSS < 20) 	<ul style="list-style-type: none"> • Major stroke (NIHSS > 22) • Minor symptoms, such as isolated sensory loss, dysarthria, or ataxia
<ul style="list-style-type: none"> • Small, distal vessel occlusion 	<ul style="list-style-type: none"> • Improving neurological symptoms
<ul style="list-style-type: none"> • Significant territory (> 20% of affected volume) of salvageable tissue on perfusion imaging 	<ul style="list-style-type: none"> • Hypertension: SBP > 185 mm Hg; DBP > 110 mm Hg
<ul style="list-style-type: none"> • Intolerance to iodinated contrast 	<ul style="list-style-type: none"> • Head trauma, prior stroke, or myocardial infarction within 3 months
<ul style="list-style-type: none"> • High risk for anesthesia complications (if use of general anesthesia is needed for IA thrombolysis) 	<ul style="list-style-type: none"> • Gastrointestinal or urinary tract hemorrhage within 21 days
<ul style="list-style-type: none"> • Age < 75 	<ul style="list-style-type: none"> • Major surgery within 14 days
	<ul style="list-style-type: none"> • Arterial puncture at a noncompressible site within 7 days
	<ul style="list-style-type: none"> • History of previous intracranial hemorrhage
	<ul style="list-style-type: none"> • Evidence of active bleeding or acute trauma
	<ul style="list-style-type: none"> • Blood glucose concentration < 50 mg dL⁻¹ (2.7 mmol L⁻¹)
	<ul style="list-style-type: none"> • Age > 75
	<ul style="list-style-type: none"> • Early signs of ischemia on CT (>30% of hemisphere)
	<ul style="list-style-type: none"> • INR > 1.5 or platelet count < 100,000 mm³
	<ul style="list-style-type: none"> • Recent history (within 21 days) of head injury or other trauma, major operation, myocardial infarction, or bleeding
IA Thrombolysis	
Relative indications	Relative contraindications
<ul style="list-style-type: none"> • Symptom onset due to ICA or MCA occlusion < 6–8 h prior to treatment 	<ul style="list-style-type: none"> • Elongated aortic arch or otherwise difficult vascular access
<ul style="list-style-type: none"> • Symptom onset due to vertebrobasilar occlusion < 12–24 h prior to treatment 	<ul style="list-style-type: none"> • High risk for anesthesia complications (if use of general anesthesia is anticipated)
<ul style="list-style-type: none"> • Significant territory (> 20% of affected volume) of salvageable tissue on perfusion imaging 	<ul style="list-style-type: none"> • Anticipated delay in beginning interventional procedure
<ul style="list-style-type: none"> • Angio suite and staff is promptly available 	<ul style="list-style-type: none"> • Intolerance to iodinated contrast
<ul style="list-style-type: none"> • Contraindications to IV thrombolysis (e.g., recent surgery or head injury) 	<ul style="list-style-type: none"> • Major stroke (NIHSS > 22)
<ul style="list-style-type: none"> • Accessible vascular anatomy 	<ul style="list-style-type: none"> • INR > 1.5
<ul style="list-style-type: none"> • Concomitant arterial stenosis or dissection 	<ul style="list-style-type: none"> • Recent history (within 14 days) of larger ischemic stroke
<ul style="list-style-type: none"> • Hyperdense MCA sign 	
<ul style="list-style-type: none"> • Suspected “hard embolus” (i.e., calcified debris or some other occlusive material that may respond better to mechanical embolectomy than IV thrombolysis) 	
<ul style="list-style-type: none"> • Failure to improve after systemic thrombolysis 	

Sources: References [7, 15, 16, 20–23]

9.2.4.1. Patient selection for IV thrombolysis

Subgroup analysis of the IV t-PA trials have identified a number of factors that predict a favorable result with IV thrombolysis: NIHSS < 10²⁴ or NIHSS < 20,^{1, 25} a normal baseline CT scan, a normal pretreatment blood glucose level, normal pretreatment blood pressure,²⁴ and age < 75.^{1, 25}

9.2.4.2. Patient selection for IA thrombolysis

The clinical criteria for enrollment in the PROACT studies may be considered during patient evaluation for IA therapy of acute stroke. The PROACT selection criteria should not be regarded as rigid criteria for day-to-day decision making, as they were formulated in the setting of a randomized trial, and patients with complicated issues, such as coexisting arterial dissection, may have confounded the results of the trial and were necessarily excluded. The leading factor in patient selection in the PROACT studies was the time from symptom onset, generally within 6 h for anterior circulation occlusions. In PROACT II, the typical interval, from initiation of IA infusion of thrombolytic drug to completion of recanalization, was 90–120 min; therefore, the 6-h treatment window may be viewed as an 8-h recanalization window.¹⁰ Thus, for situations in which recanalization can be accomplished more rapidly than in the PROACT trials, such as with mechanical thrombolysis, the time window for recanalization may be extended to 8 h. For patients with basilar artery occlusions, IA thrombolysis can be undertaken up to 24 h after symptom onset^{21, 22}. Additional clinical inclusion criteria for PROACT II were a minimum NIHSS score of 4, except for isolated aphasia or hemianopia, and ages 18–85 years.

Angiographic findings were graded according to the TIMI scale (Table 9.3). Only patients with angiographic evidence of complete occlusion (TIMI grade 0) or contrast penetration with minimal perfusion (TIMI grade 1) were included. Exclusion criteria for PROACT II are listed in Table 9.4.

Table 9.3 Thrombolysis in myocardial infarction (TIMI) scale

Grade	Definition
0	No flow
1	Some penetration past the site of occlusion but no flow distal to occlusion
2	Distal perfusion but delayed filling in distal vessels
3	Distal perfusion with adequate perfusion of distal vessels

Source: Reference [27]

Table 9.4 Exclusion criteria for PROACT II

NIHSS score > 30
Coma
Rapidly improving neurologic signs
Stroke within the previous 6 weeks
Seizures at onset of presenting stroke
Clinical presentation suggestive of subarachnoid hemorrhage
Previous intracranial hemorrhage, neoplasm, or subarachnoid hemorrhage
Septic embolism
Suspected lacunar stroke
Surgery, biopsy of a parenchymal organ, trauma with internal injuries or lumbar puncture within 30 days
Head trauma within 90 days
Active or recent hemorrhage within 30 days

(continued)

Table 9.4 (continued)

Known hemorrhagic diathesis, baseline international normalized ratio > 1.7, activated partial thromboplastin time > 1.5 times normal, or baseline platelet count < 100 × 10 ⁹ L ⁻¹
Known sensitivity to contrast agents
Uncontrolled hypertension defined by a blood pressure ≥ 180 mmHg systolic or ≥100 mmHg diastolic on three separate occasions at least 10 min apart or requiring IV therapy
CT evidence of hemorrhage, intracranial tumors except for small meningiomas, significant mass effect from the infarction, and acute hypodense parenchymal lesion or effacement of cerebral sulci in more than one-third of the MCA territory
Angiographic evidence of arterial dissection, arterial stenosis precluding safe passage of a microcatheter into the MCA, nonatherosclerotic arteriopathy, no visible occlusion, or occlusion of an artery other than the M1 or M2 segments of the MCA

Source: Reference [10]

The TIMI scale is limited by not considering occlusion location or collateral circulation; Qureshi and colleagues introduced an alternative classification scheme for acute ischemic stroke that incorporates these angiographic findings (Table 9.5).²⁶

Table 9.5 Qureshi grading system for acute ischemic stroke^a

Grade 0	No occlusion		
Grade 1	MCA occlusion (M3 segment)	ACA occlusion (A2 or distal segments)	1 BA/VA branch occlusion
Grade 2	MCA occlusion (M2 segment)	ACA occlusion (A1 and A2 segments)	≥ 2 BA/VA branch occlusions
Grade 3	MCA occlusion (M1 segment)		
3A	Lenticulostriate arteries spared and/or leptomeningeal collaterals visualized		
3B	No sparing of lenticulostriate arteries nor leptomeningeal collaterals visualized		
Grade 4	ICA occlusion (collaterals present)	BA occlusion (partial filling direct or via collaterals)	
4A	Collaterals fill MCA	Anterograde filling ^a	
4B	Collaterals fill ACA	Retrograde filling ^a	
Grade 5	ICA occlusion (no collaterals)	BA occlusion (complete)	

ACA Anterior cerebral artery, BA Basilar artery, ICA Internal carotid artery, MCA Middle cerebral artery, VA Vertebral artery

^aThe predominant pattern of filling (Source: Reference [26])

9.3. Intravenous thrombolysis for acute ischemic stroke

Intravenous t-PA is currently the only FDA-approved treatment for acute ischemic stroke in selected patients.

9.3.1. IV t-PA protocol⁷

1. Infuse 0.9 mg kg⁻¹ (maximum of 90 mg) over 60 min with 10% of the dose given as a bolus over 1 min.
 - (a) Mnemonic for remembering the dose: 0–9–9–0 (0.9 mg kg⁻¹ for max 90 mg)
2. Admit the patient to the ICU or a stroke unit.
3. Neurological exam Q 15 min during the infusion and Q 30 min for next 6 h, then Q 1 h for a total of 24 h after treatment.
4. Vital signs Q 15 min for first 2 h, Q 30 min for 6 h, and Q 1 h for a total of 24 h after treatment. Maintain SBP < 180 mm Hg and SBP < 105 mm Hg.
 - (a) Antihypertensive medication regimen:
 - Labetalol 10 mg IV over 1–2 min; may repeat every 10–20 min as needed to a maximum dose of 300 mg. Alternatively, start with a labetalol bolus and use an infusion of 2–8 mg min⁻¹.
 - If blood pressure is not controlled, start an infusion of sodium nitroprusside at 0.5 mg kg⁻¹ min.
5. Discontinue the infusion (if the drug is still being given) and obtain a head CT if the patient develops severe headaches, acute hypertension, nausea.
6. Avoid placement of NG tubes, foley catheters, or intra-arterial catheters.

9.3.1.1. Ultrasound augmentation of IV thrombolysis

Transcranial Doppler (TCD) can augment IV thrombolysis. Ultrasound can induce reversible changes in the thrombus fibrin mesh, creating microstreams of plasma through the thrombus and accelerating the transport and penetration of t-PA into the clot, resulting in more complete and faster clot lysis.²⁸ A randomized trial of 2 MHz TCD in patients receiving IV t-PA for MCA occlusion showed a significantly higher rate of recanalization in the TCD group without a difference in the rate of symptomatic hemorrhage.²⁹ TCD augmentation can be further enhanced with the addition of gaseous microbubbles.^{30,31} A trial of low frequency TCD (300 KHz) terminated after a significantly higher rate of hemorrhage was observed in the target group.³²

9.3.2. Patient management after thrombolysis

1. No anticoagulation or antiplatelet therapy for 24 h.
2. Surveillance head CT on post-procedure day 1 to monitor for hemorrhage.

9.3.3. Complications (*management of complications is discussed below*)

A pooled analysis of data on 2,639 patients in 15 studies of IV t-PA for acute stroke, found a rate of symptomatic intracerebral hemorrhage of 5.2%.³³ The rate of all hemorrhage (symptomatic and asymptomatic) was 11.5%. The mean total death rate was 13.4%, and the proportion of patients achieving a very favorable outcome was 37.1%. Other reported risks associated with IV thrombolysis include:

1. Hemi-oro-lingual angioedema occurs in 1.3–5.1% of patients.^{34–36}
2. Myocardial rupture may occur in patients who were given IV thrombolytics, within a few days of myocardial infarction (MI).¹⁹ In a series of patients receiving IV thrombolysis for MI, 1.7% had a myocardial rupture. Most occurred in patients receiving thrombolytic within 48 h of the MI, and all were fatal.

9.4. Intra-arterial thrombolysis for acute ischemic stroke

9.4.1. Endovascular technique

Thrombolysis cases can be divided into an access phase and a thrombolysis phase. Access consists of femoral artery puncture, brief diagnostic angiography, and placement of a guide catheter in the carotid or vertebral artery. The thrombolysis phase concerns reopening of the occluded cervical or intracranial vessel.

9.4.1.1. Awake or asleep?

Patients with non-dominant hemisphere strokes can often tolerate emergent angiography and thrombolysis, with adequate coaching. The authors have obtained good results even in aphasic patients with dominant hemisphere ischemic strokes, in whom the vascular anatomy was favorable, and the procedure could be accomplished swiftly. Intubation and sedation should be used in patients with posterior circulation strokes and others who simply cannot cooperate adequately. To save time, patients requiring general anesthesia should be intubated in the emergency room, or in the angio suite while vascular access is underway. A key point is that a vascular access and a diagnostic angiogram can be accomplished prior to the induction of anesthesia, if necessary.

9.4.1.2. Access phase

1. Patient is placed on the angiography table.
2. The right or left groin is prepped, draped, and infiltrated with local anesthesia.
3. A 6 F sheath is placed in the femoral artery.
 - (a) Use of a micropuncture set may reduce the risk of potential bleeding at the puncture site.³⁷
4. A focused diagnostic angiogram is obtained using a diagnostic catheter. The objectives are to confirm the diagnosis of a major arterial occlusion and to map out the pertinent anatomy.
 - (a) Cervical AP and lateral views of the involved carotid or vertebral artery, and intracranial AP and lateral views of the affected arterial system are usually all that is necessary.
 - Additional vessels should be imaged only if they can be catheterized rapidly. A complete four-vessel angiogram, if time permits, can provide information about collateral circulation and filling of vessels distal to the acute occlusion.
 - (b) An aortic arch angiogram can be helpful in patients who are elderly and have a tortuous aortic arch.
 - (c) If the occluded intracranial artery is difficult to discern, then a “stroke-o-gram” can be helpful (Fig. 9.1).

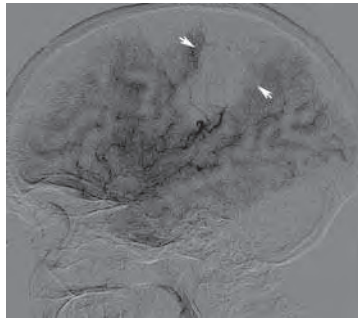


Fig. 9.1 Stroke-o-gram. Capillary phase of ICA angiogram showing a filling defect in the parietal region, corresponding to an occluded distal MCA branch in a patient with an acute ischemic stroke. The contrast has been dialed up and the brightness turned down of this DSA image to accent the region of filling defect (arrowheads).

- Manipulation of the contrast and brightness of the digital subtraction image of the intracranial capillary phase of the arteriogram can make the affected brain territory more apparent.
- (d) In patients with posterior circulation stroke, imaging of the ipsilateral subclavian artery, or the innominate artery, may identify proximal lesions.
5. The diagnostic catheter is then exchanged for a 6 F guide catheter, which is placed as high as possible in the cervical carotid or vertebral artery.
- (a) The authors of this handbook usually prefer to exchange the diagnostic catheter for a guide catheter over an exchange-length hydrophilic wire.
- Catheter options:
 - Envoy® (Cordis Neurovascular, Miami Lakes, FL)
 - (a) Advantages: Relatively rigid, provides a good platform in tortuous vessels, large internal lumen. Good choice in many stroke patients, as they tend to be elderly and have ectatic vessels.
 - (b) Disadvantages: Stiff, sharp-edged tip.
 - Guider Softip™ XF guide catheter (Boston Scientific, Natick, MA).
 - (a) Advantages: Soft, atraumatic tip. Minimizes risk of vasospasm and dissection in narrow, tortuous vessels.
 - (b) Disadvantages: Relatively flimsy, prone to fall into the arch when the vasculature is tortuous.
 - Merci guide catheter – if use of the Merci device is planned.
 - A 6 F 90 cm sheath (e.g. Shuttle® sheath, Cook Inc., Bloomington, IN), if extracranial carotid angioplasty and stenting is anticipated, in combination with thrombolysis.
 - (b) Alternatively, to save time, a guide catheter can be advanced into the carotid or vertebral system primarily, and be used for the initial diagnostic angiogram. This strategy is usually the most successful in younger patients with straightforward anatomy.
 - A 6 F Simmons 2 Envoy® (Cordis Neurovascular, Miami Lakes, FL) catheter can be advanced primarily into the common carotid artery in patients with tortuous anatomy. Disadvantage: less stable than other guide catheters which can be placed in the upper cervical internal carotid artery.

HEPARIN OR NO HEPARIN?

Some operators use full systemic heparinization for all intracranial interventions. In the setting of thrombolysis for acute stroke, systemic heparin may exacerbate potential bleeding related to thrombolytic enzyme infusion. The authors of this handbook prefer to reserve systemic heparin for selected cases, usually in which there is stasis of flow caused by the guide catheter. If IV heparin is given, a 2,000 unit bolus and a 500 unit per hour infusion is commonly used, and a syringe containing protamine is kept on the back table for emergent use, should hemorrhage occur during the case.

9.4.1.3. Thrombolysis phase

Once the guide catheter is in position, a good “working view” is obtained. The working view should be under high magnification and should demonstrate the occluded vessel, as well as a clear intravascular path to the occlusion, clearly. It is also important to keep the guide catheter in view on at least one projection (PA or lateral) during the whole procedure, to permit correction of the guide catheter, should the catheter be pushed down (which is not uncommon) or become unstable during passage of the microcatheter.

DEVICE SELECTION

1. Microcatheter
 - (a) The choice of microcatheter depends on two factors: How difficult microcatheter access is likely to be, and whether thrombolytic drug infusion alone is planned, or if mechanical thrombolysis in combination with drug infusion is anticipated.

- The UltraFlow™ microcatheter (ev3, Irvine, CA) is relatively easy to maneuver in tortuous anatomy and into distal vessels. It requires a small microwire and cannot be used with a snare.
 - If the use of a snare is anticipated, requiring an ID \geq 0.018 in., then the following microcatheters will work:
 - Rapid Transit™ microcatheter (Cordis, Miami Lakes, FL)
 - Prowler™ Plus microcatheter (Cordis, Miami Lakes, FL)
 - Excelsior™ 1018 microcatheter (Boston Scientific, Natick, MA)
2. Microwire
- (a) A relatively soft-tipped microcatheter should be used, to minimize the chance of vessel perforation. Stiffer microwires should be avoided. The authors' preferred microwires for most stroke cases:
- Mirage™ 0.008 in. (ev3). Good for use with the UltraFlow™ microcatheter.
 - J-tipped Headliner® 0.012 in. (Microvention/Terumo)
 - Synchro®-14 0.014 in. (Boston Scientific, Inc., Natick, MA)
 - Transend™ EX 0.014 in. Soft Tip (Boston Scientific, Inc., Natick, MA)

PHARMACOLOGICAL THROMBOLYSIS

1. Microcatheter technique and infusion of thrombolytic.
 - (a) Form a J-shape at the tip of the microwire.
 - (b) Using a road map, gently navigate the microwire into the occluded vessel and into the region of occlusion. Try to avoid jabbing small perforating vessels as the microwire is advanced.
 - (c) Once the microwire tip is in or slightly beyond the region of occlusion, pin the microwire and carefully advance the microcatheter tip into the region of occlusion.
 - Advance the microcatheter tip for a distance likely to be distal to the embolus or thrombus. This point is typically at the next branch point of the occluded vessel (e.g., in M1 occlusion, the embolus is often lodged in the vessel at the MCA bifurcation).
 - (d) The microwire is then withdrawn, and a microcatheter angiogram is obtained to clarify the extent and position of the occlusion.
 - (e) The microcatheter is then drawn back into the occluded portion of the vessel and the thrombolytic agent is injected through the microcatheter. Each injection is given slowly, over several minutes. After each dose is given, the microcatheter is gradually withdrawn through the area of occlusion, in order to distribute the thrombolytic agent within the clot.
 - (f) A guide catheter angiogram is done after each dose of the agent is administered to track the progress of thrombolysis, and to monitor for vessel perforation by looking for contrast extravasation. Periodic microcatheter angiograms can be helpful too.
 - (g) Mechanical thrombolysis maneuvers can be done to supplement drug infusion (see below)
2. Choice of thrombolytic drug
 - (a) The authors of this handbook prefer to use whichever thrombolytic agent can be obtained and prepared quickly. Although they each have advantages and disadvantages, no particular agent has been found to be superior to the others in direct comparison. Each agent is listed in [Table 9.1](#).
3. When to stop
 - (a) The procedure is complete once recanalization of the vessel has been obtained or when the maximum dose of the thrombolytic agent has been administered and all other maneuvers, such as mechanical thrombolysis, have been undertaken. Another signal to stop is any sign of possible hemorrhage, such as severe headache or nausea, or an abrupt change in blood pressure or heart rate (although patients can expect a bad headache after any intracranial thrombolysis procedure).
 - *Migrating clot*. In some cases the large vessel thrombus may break up and migrate into distal branches. The temptation in this situation, is to chase the clot into the distal branches and continue to infuse thrombolytic. However, occluded distal branches will often recanalize spontaneously after successful reopening of the proximal vessel, due to increased flow in the vessels and after the distal branches have incubated for a period of time with the thrombolytic agent that is already present. Also, it is generally not worth the

added risk to continue to infuse additional thrombolytic drug, after the larger vessels have been reopened.

- **Reocclusion.** Reocclusion of a vessel, such as an M1 segment, is not uncommon after thrombolysis. This may be due to vasospasm, a platelet-rich thrombus, pre-existing atherosclerosis, or an iatrogenic dissection. Options are:
 - IA infusion of nitroglycerin, 30–60 mcg, into the affected area. The vessel will usually reopen quickly, if vasospasm is present. This can be effective as a diagnostic maneuver as well as a therapeutic one.
 - Addition of an antiplatelet agent, such as a GP IIB/IIIa inhibitor. Pharmacological and mechanical thrombolysis can disrupt the endothelium and cause the formation of a platelet-rich thrombus. Angiographic evidence of this may be present, such as a fluffy filling defect in the region of reocclusion. IA or IV infusion of an antiplatelet agent may dissolve the clot, however, this will increase the chance of hemorrhagic complications. The wisdom of adding an antiplatelet agent should be weighed against the cost of continued reocclusion of the vessel.
 - Atherosclerotic stenosis or a dissection can be treated with intracranial angioplasty and stenting. Again, these maneuvers increase the risk of bleeding and should be used only when the weight of the evidence indicates that the reocclusion will be long-lasting and clinically significant. See below, *Associated Intracranial Stenosis + Stroke*.

9.4.1.4. Postprocedure care

1. The femoral artery sheath may be left in place while the thrombolytic drug wears off, and removed later.
2. A head CT scan is obtained to check for hemorrhage.
3. The patient is admitted to the intensive care unit for observation and blood pressure control.

MECHANICAL EMBOLECTOMY

An array of mechanical thrombolysis techniques exist, which may be employed as an alternative to or in combination with pharmacological thrombolysis:

1. Merci® Retriever: Discussed separately below.
2. Snares. Microsnares can be used to retrieve foreign bodies, such as detached coils or catheter fragments, or to treat acute ischemic stroke. Although snare-retrieval of intracranial arterial thrombi can be done,^{38–41} the authors of this handbook prefer to use snares in combination with a fibrinolytic drug, to break up the thrombus and increase the surface area available for lysis. Other authors have found the device to most useful in the treatment of basilar artery occlusion.⁴²
 - (a) Devices
 - Amplatz Goose Neck® microsnare (ev3, Irvine, CA). Available sizes: 2, 4 and 7 mm.
 - Microcatheter. Any microcatheter with an ID ≥ 0.018 in. is large enough. The following microcatheters will work:
 - Rapid Transit™ microcatheter (Cordis, Miami Lakes, FL)
 - Prowler™ Plus microcatheter (Cordis, Miami Lakes, FL)
 - Excelsior™ 1018 microcatheter (Boston Scientific, Natick, MA)
 - (b) Techniques
 - *Clot retrieval.*⁴¹ The microcatheter is positioned so that the tip is just proximal to the occlusion. A snare with a diameter slightly larger than the occluded vessel is advanced out of the microcatheter so that the loop of the snare is opened fully. The microcatheter is then pushed together with the snare into the clot. The snare is then pulled back into the microcatheter, so that only a small portion of the snare can be seen outside of the microcatheter tip on fluoroscopy. The microcatheter and snare are then withdrawn several centimeters into a relatively straight segment. A guide catheter angiogram is done with gentle injection of contrast, to

avoid disengaging of the thrombus. If the clot is caught in the snare, the microcatheter and snare are withdrawn as a unit into the guide catheter, and suction is applied to the proximal end of the guide catheter with a 60 mL syringe to permit removal of the snare and microcatheter from the patient, without disengaging the clot.

- *Clot maceration.* The microcatheter is positioned in the occluded vessel and the thrombolytic drug is infused. If guide catheter angiograms show persistent occlusion, the microcatheter is advanced past the occlusion and a 4 mm snare is deployed. The microcatheter and snare are then gently withdrawn so that the snare is within the thrombus. The microcatheter and snare are then withdrawn through the embolus or thrombus in back-and-forth movements, to macerate the clot and increase the surface area available for pharmacologic thrombolysis.
3. The Alligator[™] Retriever device. This is a claw-like micro-forceps deliverable through a microcatheter works well to grasp and retrieve misplaced coils and other intravascular foreign bodies. It can also be used to retrieve thrombus.⁴³
- (a) Devices
- Alligator[™] Retriever device. (Chestnut Medical Technologies, Inc., Menlo Park, CA). Available sizes: 2, 3, 4 and 5 mm. For best results, the nominal size should match the size of the vessel containing the obstructive object.
 - Microcatheter. Any microcatheter with an ID \geq 0.021 in. is large enough. The following microcatheters will work:
 - Merci[®] 18 L[™] microcatheter (Concentric Medical, Mountain View, CA)
 - Prowler[™] Plus microcatheter (Cordis, Miami Lakes, FL)
 - Renegade[®] microcatheter (Boston Scientific, Natick, MA)
- (b) Techniques
- Clot retrieval. The microcatheter is positioned so that the tip is just proximal to the occlusion. An Alligator with a diameter close to the size of the occluded vessel, is inserted into the microcatheter using the supplied introducer. It is then advanced to the tip of the microcatheter, but not yet into the vessel. Do not rotate the device. The microcatheter is then pulled back as the Alligator wire is stabilized to unsheathe the jaws of the Alligator. Very carefully advance the Alligator forward into the clot. The microcatheter is then advanced over the stabilized Alligator wire, so that the jaws begin to close. Keep tension on the Alligator wire, but do not pull it completely into the microcatheter, as that will release whatever is grasped in the jaws. The microcatheter and Alligator are then withdrawn as a unit. Using a large-diameter Merci[®] balloon guide catheter may also be useful to temporarily occlude the parent artery and apply suction to the proximal end of the guide catheter with a 60 mL syringe to permit removal of the Alligator and microcatheter from the patient, without disengaging the clot. Completely withdraw the microcatheter from the guide catheter and thoroughly aspirate any clot from the guide catheter. If blood does not freely aspirate, a large thrombus may be present and the guide catheter must be removed from the patient and flushed of any debris.
 - Foreign body retrieval. The steps are the same as clot retrieval, but it is much easier to determine if a radio-opaque coil or other foreign body is effectively grasped by the Alligator by fluoroscopic imaging.
4. Suction thrombectomy. Proximal large vessel occlusions can be treated with suction thrombectomy.⁴⁴⁻⁴⁶
- (a) Technique. A 6 or 7 F guide catheter is navigated over a hydrophilic wire and placed in the proximal third of the thrombus. A 60 mL syringe is used to aspirate the thrombus while moving the guide catheter in and out of the thrombus several times. Aspiration is continued for about 10 s each time.
- (b) Distal suction thrombectomy may be performed using the Penumbra Retrieval system (see below).
5. Intracranial angioplasty. Balloon angioplasty can augment thrombolysis in occlusions with underlying stenosis caused by atherosclerosis or a dissection. This strategy is most useful in the treatment of M1 segment thrombosis, which tends to be the result of thrombosis superimposed on atherosclerotic lesions, in contrast to distal basilar occlusions, which tend to be embolic.⁴⁷ Angioplasty in this setting

can reduce the risk of re-thrombosis.⁴⁸ Several authors have reported favorable results with *rescue angioplasty*, in which angioplasty is used to obtain recanalization in vessel occlusions that are resistant to thrombolytic agents alone. Two retrospective series have reported recanalization using angioplasty in a total of 10 of 16 occluded arteries that were resistant to pharmacologic thrombolysis.^{49, 50}

- (a) *Technique*. Thrombolytic drug infusion and mechanical embolectomy with other means (e.g., Merci device or snare) is undertaken first. Once these attempts at recanalization of the vessel are unsuccessful, the diameter of the proximal segment of the occluded artery is measured on angiography to determine the appropriate size of the angioplasty balloon. A microwire is then advanced past the occlusion into a distal vessel; the microwire tip is placed in the most distal position safely possible to maximize purchase. The angioplasty balloon is then advanced to the point of stenosis under roadmap guidance and inflated to nominal pressure. The balloon is then oscillated to 1–2 atmospheres above nominal pressure for 10–30 s before deflation. The balloon is then withdrawn into a larger proximal vessel to permit follow-up angiography.
- (b) *Devices*. Small, noncompliant coronary angioplasty balloons useful in this setting, such as a 2 × 9 mm Maverick^{2™} Monorail™ Balloon Catheter balloon (Boston Scientific, Natick, MA).

MERCI® RETRIEVER

The Merci® Retrieval systems (Concentric Medical, Mountain View, CA) was the first FDA-approved treatment options for acute stroke aside from IV t-PA. The Merci Retriever systems are based on a flexible nitinol wire that assumes a helical shape once it emerges from the tip of the microcatheter. The microcatheter, containing the wire, is passed distal to the thrombus, the catheter is withdrawn, and the helical configuration taken by the wire ensnares the clot for removal from the vasculature. Vessels amenable to embolectomy with the Merci devices, include the ICA, M1 and M2 segments, vertebral artery, basilar artery, and PCA. The Merci Retriever (Models X5 and X6) first received FDA 510(k) clearance for sale in the US in August 2004, based on data from the MERCI trial.⁵¹ The Centers for Medicare and Medicaid Services established an ICD-9 procedure code (39.74) for Merci retrievers in October 2006. FDA 510(k) clearance for the L5 model was granted in February 2007, based on data from the Multi-Merci trial.⁵²

1. Devices (Fig. 9.2)

- (a) *Merci® Balloon Guide catheters*. The balloon guide catheter is designed to allow temporary occlusion of the carotid or vertebral artery during clot retrieval. It is available in 7, 8 and 9 F sizes; in general the 7 F is recommended for a small vertebral artery and the 9 F is for a large carotid artery. It is packaged with an obturator for smooth vessel introduction and may be inserted through a femoral artery sheath, or exchanged directly into the femoral artery without a sheath. Usage without a sheath is usually not recommended, as the guide catheter may frequently get clogged as clots are extracted, and this may require removal of the guide catheter. The proximal end of the guide catheter includes a straight hub for device insertion and an angled hub for distal balloon inflation. An RHV with a three-way stop clock is connected to the straight hub, to allow continuous flushing with heparinized saline. The compliant silicone balloon at the distal end of the guide catheter inflates to a 10 mm diameter with the maximum inflation volume of 0.8 mL is used. A 3 mL syringe, prepared with 50% contrast in saline, is used for balloon inflation.
- (b) *Microwire*. A microwire is used to advance the Merci microcatheter into the target vessel. The authors prefer the 0.012 in. J-tip Headliner™ (Terumo Medical, Somerset, NJ)
- (c) *Merci® Microcatheters*. These microcatheters have a single radio opaque marker at the tip.
 - *14X microcatheter*. Used for X-6 retrievers, it has a 0.017 in. inner lumen.
 - *18L microcatheter*. Used for L and V-series retrievers and has a 0.021 in. lumen.
- (d) *Merci® Retrievers*. The retrievers are mounted on nitinol pusher wires, and each retriever is packaged with an introducer and a torque device.
 - X-series retrievers. The X6 retriever has six tapered helical loops from 3 mm down to 1.5 mm and looks like a corkscrew. The X5 retriever has been discontinued.

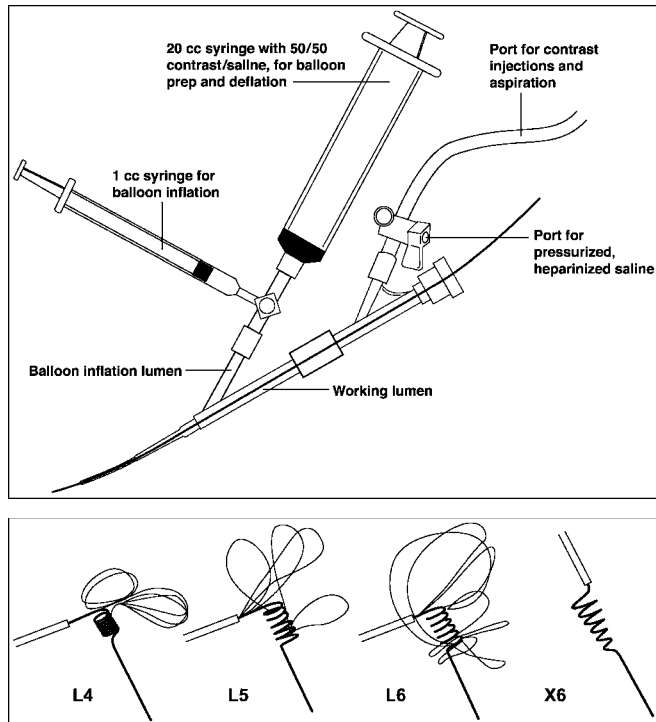


Fig. 9.2 The Merci® Balloon guide catheter set up (above), the Merci® Retrievers (below).

- V-series retrievers. These are a hybrid of both the X and L series retrievers.
 - L-series retrievers. The L4, L5 and L6 retrievers have four, five and six non-tapering helical loops, respectively. These are arranged at a 90 degree angle to the pusher wire. These are the “hairy retrievers” with suture threads bound to the nitinol wire to augment thrombus engagement. Loop diameter of the helix is 2.0 mm on the L4, 2.5 mm on the L5 and 2.7 mm on the L6. The L6 having a stiffer coil design, is more stretch resistant than the L5, and is most suitable for use in the larger and more proximal vessels (i.e. M1, ICA).
- (e) *3mL and 60mL syringes.* The 3 mL syringe is used to inflate the guide catheter balloon and the 60 mL syringe is used for aspiration through the guide catheter during clot retrieval.
2. Technique
- (a) Femoral artery access is obtained and a diagnostic catheter is placed in the target carotid, subclavian, or vertebral artery.
 - (b) IV heparin (2,000 unit bolus and a 500 unit per hour infusion) is given. A syringe containing protamine (50 mg) should be on the back table, in case a hemorrhage occurs.
 - (c) The balloon guide catheter is prepared.
 - The balloon is purged of air with the 3 mL syringe containing 50% contrast.
 - The catheter is flushed with heparinized saline.

- (d) The diagnostic catheter is then exchanged over a hydrophilic wire (0.035 or 0.038 in.) for the balloon guide catheter. Alternatively, the balloon guide catheter may be navigated directly into the carotid or vertebral artery over the hydrophilic wire. The balloon guide catheter should be positioned as distally as possible in the ICA or vertebral artery.
 - (e) The Merci Microcatheter is then advanced over a microwire with a J-tip curve through the balloon guide catheter and into the target vessel. The microwire is delicately advanced past the clot; the microwire is then stabilized and the microcatheter is navigated into a large vessel distal to the clot. The microwire is removed and a microcatheter angiogram (using a gentle injection with a 3 mL syringe containing 100% contrast) is done to confirm that the microcatheter tip is distal to the clot, and that a vessel perforation has not occurred.
 - (f) The Merci Retriever is then advanced through the microcatheter, until upto four loops of the helix are visible past the tip of the microcatheter. The microcatheter and the retriever are then withdrawn as a unit into the clot. The retriever loops are then tightened by rotating the retriever wire counterclockwise by two revolutions. The remaining loops are then advanced into the thrombus, and the retriever wire is turned counterclockwise as many as five times to further engage the clot.
 - (g) Do not overdo the rotations, as over-aggressive rotation could kink or even fracture the retriever.
 - (h) The balloon on the guide catheter is then inflated to stop antegrade flow in the ICA or vertebral artery. Adequate inflation of the balloon is obtained when “ovalization” of the balloon is seen on fluoroscopy, indicating that the compliant balloon has conformed to the walls of the surrounding vessel.
 - (i) The engaged clot-retriever-microcatheter assembly is then brought back as a unit into the guide catheter and then out of the patient, while forceful suction with the 60 mL syringe is applied to the angled port of the RHV.
 - (j) Thoroughly aspirate all debris before flushing the guide catheter with heparinized saline.
 - (K) The balloon is then deflated and a guide catheter angiogram is done to assess arterial recanalization.
 - (l) Several passes with the retrieval device may be required.
 - (m) If re-using a retriever for another pass, inspect it to be certain that it is undamaged and free of clot fragments. It can be manually straightened as it is back-loaded into the introducer.
 - (n) The L4, 5, and 6 retrievers often get twisted and the fibers get tangled after one pass, so the authors rarely re-use these devices and instead try a new retriever for each pass.
 - (o) The authors rarely attempt more than 3 passes of the retriever to minimize the chance of vessel injury.
 - (p) Femoral artery access site closure. The sizable hole in the femoral artery created by the 8 or 9 F Merci Balloon catheter can be closed effectively with a Perclose ProGlide device (Abbott Laboratories, Abbott Park, IL).⁵³
3. Merci Technique Tips
- (a) The balloon guide catheter may be positioned in the subclavian artery – rather than the vertebral artery – for posterior circulation cases, if access to the vertebral artery itself is difficult.
 - (b) The Merci system may be used in patients who have been treated with IV t-PA. In the Multi-Merci trial, the use of IV t-PA before conventional angiography and attempted thrombectomy with the device did not increase the incidence of intracranial hemorrhage compared to patients not treated with IV t-PA.⁵²
 - (c) The Merci system may be augmented with IA fibrinolytic infusion. In the Multi-Merci trial, use of up to 24 mg t-PA was allowed in cases of treatment failure with the device, or to treat distal emboli that were not accessible with the device after successful proximal embolectomy.⁵² Recanalization was achieved in 72% of patients in whom adjunctive IA t-PA was used, compared to 64% of patients treated with the device only; rates of hemorrhage were similar between the groups.
 - (d) Consider advancing a coaxial assembly consisting of the microcatheter inserted in Concentric Medical’s Distal Access Catheter into the intracranial circulation to provide additional stability.

PENUMBRA SYSTEM™

The Penumbra System™ (Penumbra, Inc., San Leandro, CA) is the second FDA-approved mechanical treatment for acute stroke. The system primarily involves clot aspiration using a microcatheter attached to a power Aspiration Pump, capable of producing 25 mm Hg of suction. (The authors will refrain from making cheap jokes concerning the various attributes of this system). The Separator™ is a soft wire with a tear-drop-shaped enlargement of 6 mm proximal to its tip and is inserted via the microcatheter to physically break up the clot and keep the microcatheter tip from clogging. A major advantage over the Merci system is the fact that the Penumbra System works at the proximal face of the clot, eliminating the need to blindly position the microcatheter distal to the occlusion. This system also does not require the gigantic guiding catheters needed for Merci retrieval systems, since the clot is fragmented and aspirated through a small microcatheter. FDA 510(k) clearance for the system was granted in January 2008, after a Pivotal Trial of 125 patients showed safety and efficacy that were favorable compared to other acute stroke treatments.

1. Devices

- (a) *Penumbra Neuron delivery catheter*. This 6 F guide catheter is designed to allow for intracranial catheterization of the carotid or vertebral artery, and can be used during clot retrieval procedures with the smaller-diameter microcatheter systems. It is discussed in detail in Chap. 5
- (b) *Microwire*. A soft, J-tip microwire can be used to advance the Reperfusion microcatheter into the target vessel. However, in some cases, with very distal positioning of the guide catheter, the microcatheter may be advanced to the clot primarily without a wire.
- (c) *Reperfusion microcatheters*. These microcatheters consist of a proximal stainless steel hypotube for pushability and stability, and stainless steel wire reinforcement distally for more flexibility. Stainless steel is not as kink resistant as other materials, so caution must be exercised in tortuous vessels to avoid kinking the catheter. These microcatheters have a single radio opaque marker at the tip.
 - 026 microcatheter. A catheter 150 cm long, 3.9 F tapering to 2.8 F distally with a 0.026 in. lumen. Used for clot retrieval in small, distal vessels.
 - 032 microcatheter. This 150 cm catheter is 4.1 F tapering to 3.4 F distally with a 0.032 in. lumen. Used for middle sized vessel occlusions.
 - 041 microcatheter. Slightly shorter at 137 cm long, but a generous 4.1 F both proximal and distal and a 0.041 in. lumen. Used for larger vessel, proximal clots.
- (d) *The Separator™*. These wires are used to break up clot and keep the distal Reperfusion catheter clear of obstruction. A tear-drop swelling on the wire, of about 6 mm from its tip is indicated by a radio-opaque gold marker. The Separator wire is sized and matched to the particular Reperfusion catheter. All are 200 cm long and have a soft tip.
 - 026. Sized for the PSC026 catheter. Proximal wire is 0.018 in. with a 30 cm distal 0.010 in. segment.
 - 032. Sized for the PSC032 catheter. Proximal wire is 0.018 in. with a 20 cm distal 0.010 in. segment.
 - 041. Only works in the big PSC041 catheter. Proximal 0.020 wire with distal 43 cm 0.014 in. segment.
- (e) Aspiration Pump and connecting tubing. The necessary sterile connecting tubing for the aspiration pump, comes packaged with the Penumbra System devices.

2. Technique

- (a) Femoral artery access is obtained and a diagnostic catheter is placed in the target carotid, subclavian, or vertebral artery.
- (b) Determine the size of the vessel occluded and choose an appropriately sized reperfusion catheter.
- (c) IV heparin (2,000 unit bolus and a 500 unit per hour infusion) is given. A syringe containing protamine (50 mg) should be on the back table in case a hemorrhage occurs.
- (d) The guide catheter is prepared.
 - Generally, a 6 F or larger guide catheter is needed.
Note: the Penumbra 6 F Neuron guide catheter cannot be used for the two larger Penumbra Reperfusion catheters. In most cases, a 6 F Envoy or Guider guide catheter is necessary.

- The catheter is flushed with heparinized saline.
- (e) The diagnostic catheter is then exchanged over a hydrophilic wire (0.035 or 0.038 in.) for the guide catheter. Alternatively, the guide catheter may be navigated directly into the carotid or the vertebral artery over the hydrophilic wire. The balloon guide catheter should be positioned as distally as possible in the ICA or vertebral artery. If using a Neuron guide catheter, consider positioning the tip as distally as possible in the target artery (see Chap. 6 for tips on using the Neuron).
- (f) The Reperfusion catheter is then advanced over a microwire with a J-tip curve through the guide catheter and into the target vessel. The microcatheter need only be navigated into a large vessel just proximal to the clot. An angiogram via the guide catheter can be done to confirm that the microcatheter tip is at the proximal face of the clot, and that a vessel perforation has not occurred.
- (g) The Separator is then carefully positioned through the microcatheter, until the gold radio-opaque marker on the Separator is visible just past the opaque tip of the microcatheter.
- (h) The RHV of microcatheter is then connected to the Aspiration Pump using the supplied sterile tubing. All tubing is flushed with sterile heparinized saline and tightened connections.
- (i) Turn on the Aspiration Pump and gently move the Separator in and out of the microcatheter to fragment clot and keep the tip of the catheter free of obstructing clot.
- (j) Be gentle with the Separator and keep in mind, that the tip extends beyond the tip of the catheter and can injure the vessel, especially if it is advanced into a small branch or at a sharp curve.
- (k) Only aspirate for short periods at a time, and recheck with contrast injections via the guide catheter to determine the progress.
- (l) If large quantity of blood is aspirated, it may be that the microcatheter tip is too proximal.
- (m) If arteriograms through the guide catheter show incomplete arterial recanalization, consider adding an intra-arterial thrombolytic agent and/or additional passes with the Penumbra system.
- (n) Several passes with the device may be required.
- (o) Firm clot that will not break up or be aspirated, may require a pass with a Merci retriever, an Alligator, or a larger Penumbra Reperfusion catheter.
- (p) Femoral artery access site closure. The hole in the femoral artery created by the catheterization can be closed effectively with a Perclose ProGlide device (Abbott Laboratories, Abbott Park, IL).

ALTERNATIVE DEVICES FOR MECHANICAL THROMBECTOMY

A number of devices are presently available for foreign body retrieval, or are in evaluation in clinical trials for use in acute ischemic stroke:

1. *Neuronet Retriever thrombectomy device (Guidant Corporation, Temecula, CA).* The Neuronet device is FDA-approved, for use in foreign body retrieval. The device consists of a shapeable platinum-tipped wire with a self-expanding retrieval basket attached to its distal tip. This device is somewhat bulky but can be useful in relatively straight vessels, such as the M1 segment.⁴² The microcatheter is advanced so that the tip is approximately 2 cm beyond the occlusion. The device is then unsheathed by withdrawing the microcatheter 3–4 cm. The microcatheter and Neuronet device are then withdrawn together as a unit, to ensnare the embolus or thrombus.
2. *In-Time[™] Retriever (Boston Scientific Target, Fremont, CA).* The In-Time device is FDA-approved for use in foreign body retrieval. The In-Time Retriever is a bulky device with a wire mesh that expands and bows when opened. It is available in 4-strand and a 6-strand model. The basket is mounted on a wire that is preassembled in a 3 F catheter. The basket is expanded by pulling on the wire, and can be used in vessel diameters ranging from 2 to 4 mm. It is most useful for larger vessels, such as the ICA or the vertebral artery.
3. *EnSnare (Medical Device Technologies, Gainesville, FL).* The EnSnare device is FDA-approved for foreign body retrieval. The EnSnare has a tulip-shaped three-loop design requiring a catheter with a 0.027-in. lumen. It opens distally, which may not allow sufficient capture of emboli.⁴²

4. *Angiojet*[®] (Possis Medical, Inc., Minneapolis, MN). The Angiojet is a two-lumen device that combines local suction with mechanical disruption, an approach that has been termed *rheolytic thrombectomy*. Multiple retrograde high pressure saline jets are directed into the primary evacuation lumen of the catheter to create a vortex that draws in, traps, and fragments thrombus. The debris is simultaneously removed by suction via the recovery lumen. The Angiojet was originally developed for coronary and peripheral artery revascularization; neurovascular uses have been essentially limited to the carotid artery or intracranial venous sinuses.^{42, 54, 55} The 5 F AngioJet can be advanced through a 6 F guide catheter and guided over a 0.014 in. microwire.
 - (a) The Neurojet (Possis Medical) was a smaller, single-lumen device that can be advanced through a 3 F catheter. It was designed for the intracranial circulation, but development of this device was halted after vessel dissection was noted in an initial feasibility and safety trial.⁵⁶
5. *EKOS MicroLysUS infusion catheter* (EKOS Corporation, Bothell, WA). This device consists of a 2.5 F drug infusion catheter with a 2.1 mm distal ultrasonic transducer. A microwire is first advanced past the occlusion. Then, the EKOS microcatheter is advanced into the proximal portion of the clot and the microwire is retracted. Infusion of t-PA is then done in conjunction with simultaneous ultrasonography for up to an hour. Preliminary trial results with this device have been positive.⁵⁷
6. *Endovascular Photo Acoustic Recanalization (EPAR) system* (Endovaxis, Inc., San Francisco, CA). The EPAR system obtained mechanical thrombolysis by conversion of photonic energy (delivered by a laser) into acoustic energy at the fiberoptic tip through creation of microcavitation bubbles.⁵⁸ The tip of the 3 F microcatheter is 1 mm in diameter with five laterally-facing windows. The vaporization and re-liquification of the cavitation pocket causes suction of the thrombus through the windows into the tip. The 3 F EPAR microcatheter can be advanced through a 6 F guide catheter, over a 0.014 in. microwire. The microcatheter is placed within the occlusive thrombus and the device generator is activated to emulsify the thrombus. During thrombolysis, the microcatheter is continuously flushed with blue indigo carmine (0.8% in saline), which absorbs green wavelength light and functions as a coolant. The EPAR system has been discontinued because of lack of funds.⁵⁹
7. The Phenox[®] Clot Retriever (Phenox, GmbH, Bochum, Germany) has a dense network of firm polyamid fibers attached to a wire core, and can be passed via a > 0.021 in. inner lumen microcatheter to extract occlusive intracranial thrombi.⁶⁰ It has advantages over other mechanical retrievers, in that it is less likely to fragment the clot.⁶¹ However, the device is currently not available in the United States.

9.4.2. Perfusion augmentation: The Neuroflo™ system

This system is radically different from other strategies to improve blood flow to the brain. It involves placement of a large diameter double balloon NeuroFlo™ catheter (CoAxia, Maple Grove, MN) in the abdominal aorta and the balloons are temporarily inflated to partially obstruct flow in the abdominal aorta. This system appears to provide some benefit both by cerebral blood flow parameters and by clinical outcome in the setting of symptomatic vasospasm after subarachnoid hemorrhage,⁶² and the device was given a Humanitarian Device Exemption by the FDA in March 2005 for this application. Studies are ongoing for its use in ischemic stroke, including the SENTIS (Safety and Efficacy of Neuroflo Technology in Ischemic Stroke) trial comparing the use of the Neuroflo plus standard medical therapy to standard medical therapy alone in stroke patients up to 10 h after symptom onset. There is also a small Flo24 study evaluating safety and feasibility in patients upto 24 h after symptom onset. The system is simple to use with low risk, and may be an important option for stroke treatment in centers without expertise in intracranial thrombolysis or thrombectomy techniques.

9.4.3. Patient management after IA thrombolysis

1. Admit the patient to the ICA or a stroke unit.
2. Neurological exam Q 15 min during the infusion and Q 30 min for next 6 h, then Q 1 h for a total of 24 h after treatment.

3. Vital signs Q 15 min for first 2h, Q 30 min for 6h, and Q 1h for a total of 24h after treatment. Maintain SBP < 180 mm Hg and SBP < 105 mm Hg.
 - (a) Antihypertensive medication regimen
 - Labetalol 10 mg IV over 1–2 min; may repeat every 10–20 min as needed to a maximum dose of 300 mg. Alternatively, start with a labetalol bolus and use an infusion of 2–8 mg min⁻¹.
 - If blood pressure is not controlled, start an infusion of sodium nitroprusside at 0.5 mg kg⁻¹min⁻¹.
4. Obtain a head CT if the patient develops severe headaches, acute hypertension, nausea.
 - (a) In PROACT II, symptomatic ICH occurred in IA thrombolysis patients on an average of 10.2 h after the start of treatment; mortality was 83% in these patients.⁶³
5. Avoid placement of NG tubes, foley catheters, or intra-arterial catheters, until the day after treatment, if possible.
6. Surveillance head CT on post-procedure day 1 to monitor for hemorrhage.

9.4.4. Complications (management of complications is discussed below)

A pooled analysis of data on 852 patients in 27 studies of IA thrombolysis found a rate of symptomatic intracerebral hemorrhage of 9.5%.⁶⁴ The death rate was 27.2% and the proportion of patients achieving a favorable outcome was 41.5%. In PROACT II, procedural complications included systemic hemorrhage (primarily hemorrhages at the puncture site) in 7% of patients, worsening of neurologic symptoms (1%) and anaphylaxis (1%).¹⁰

9.4.5. Combined IV + IA strategies

Treatment with early administration of IV thrombolytics followed by IA thrombolysis has been investigated in several studies. Sequential IV and IA fibrinolytic therapy have shown somewhat modest results. Preliminary trials of IV GP IIB/IIIa inhibitor combined with IA thrombolysis have also been done or are in progress.

1. IV + IA t-PA.
 - (a) In the Emergency Management of Stroke Bridging Trial, 35 patients were randomized to receive either IV t-PA (0.6 mg kg⁻¹, 60 mg maximum over 30 min) or placebo, followed by IA injection of t-PA (average dose 11 mg).⁶⁵ There were no difference in the outcomes between the groups, but the TIMI 3 recanalization rate was better in the IV/IA group compared to the placebo/IA group (55% vs. 10%, *P* = 0.03). There was only one symptomatic ICH, in an IV/IA patient.
 - (b) In the NIH Interventional Management of Stroke trial, 80 patients with an NIHSS ≥ 10 received IV t-PA (0.6 mg kg⁻¹, 60 mg maximum over 30 min) within 3h of symptom onset. Additional t-PA was then administered via microcatheter at the site of the thrombus upto a total dose of 22 mg over 2h.⁶⁶ Compared to historical controls treated with conventional IV t-PA, rates of mortality, hemorrhage were not significantly different. The combined IV/IA patients showed a modest trend to improved outcome at three months (odds ratios ≥ 2).
2. IV GP IIB/IIIa + IA.
 - (a) In the Combined Local Fibrinolysis and Intravenous Abciximab in Acute Vertebrobasilar Stroke Treatment study, 47 patients were treated with an IV bolus of abciximab (0.25 mg kg⁻¹) followed by a 12-h infusion (0.125 μg kg⁻¹ min⁻¹) and low-dose IA t-PA (median dosage: 20 mg).⁶⁷ Additional angioplasty and/or stenting was done in 14 patients. Compared to historical controls treated IA t-PA only (median dosage: 40 mg), symptomatic ICH was not significantly different, but the rates of

TIMI 3 recanalization and favorable outcome were significantly higher in the combined treatment group.

9.4.6. Thrombolysis complications: Management

1. Intracranial Hemorrhage
 - (a) A head CT should be done to check for hemorrhage:
 - IV thrombolysis: Obtain a head CT for any patient complaining of a severe headache or exhibiting a neurologic change. A surveillance post-thrombolysis head CT hospital day 2 is standard in some centers.
 - IA thrombolysis: Obtain a CT immediately after the endovascular procedure to establish a baseline. It is common to see minor extravasation of contrast in the affected region of the brain (“*contrastoma*”), particularly in the basal ganglia; this is *not* a sign of hemorrhage. Obviously, a head CT should be obtained in any patient with a severe headache or neurologic change.
 - (b) Asymptomatic and small hemorrhages (< 30 mL) can often be managed conservatively.
 - Reverse blood thinning agents.
 - Reverse heparin if patient is heparinized (protamine IV, 10 mg per 1,000 units of heparin).
 - Consider fresh frozen plasma and platelet transfusion.
 - Tight blood pressure control (maintain SBP ≤ 160 mmHg).
 - Frequent neuro exams, keep patient in ICU.
 - (c) Symptomatic, significant hemorrhage (> 30 mL).
 - Reverse blood thinning agents.
 - Reverse heparin if patient is heparinized (protamine IV, 10 mg per 1,000 units of heparin).
 - Consider fresh frozen plasma and platelet transfusion.
 - Intubate, if needed to control airway.
 - Mannitol 50 g IV.
 - Consider ventriculostomy if symptomatic hydrocephalus is present.
 - Consider craniotomy for evacuation of clot.
2. Femoral artery hemorrhage
 - (a) Most common site of extracranial hemorrhage with IA thrombolysis.
 - (b) Signs of groin hemorrhage:
 - Obvious bleeding at site or an enlarging subcutaneous hematoma.
 - *Ripping*, severe pain at the puncture site (a sign of a dissection).
 - Hypotension and bradycardia.
 - (c) Management:
 - Manual compression.
 - Pelvic and abdominal CT scan to check for hemorrhage.
 - If the sheath is still in place, upsize to a larger-gauge sheath.
 - Volume expansion with IV fluids and transfusions if needed. Consider Vascular Surgery consultation for surgical repair of vessel.
 - Consider reversal of anticoagulation and antiplatelet agents (i.e., platelet transfusion) if the hemorrhage is life-threatening.
3. Angioedema
 - (a) Defined as localized swelling of the tongue, lips or oropharynx within 6 h after the start of IV thrombolytic infusion.⁶⁸
 - (b) Symptoms are typically mild, transient, and contralateral to the ischemic hemisphere; in some cases, however, progression can be rapid and life-threatening due to airway obstruction.
 - (c) Patients on angiotensin-converting-enzyme inhibitors appear to be at increased risk of this complication.³⁶ Evidence of frontal and insular ischemia on CT is also an associated risk factor.³⁴
 - (d) Management:
 - Prepare for intubation or cricothyroidotomy, if needed for airway control.
 - Obtain a CT of the face and head to rule out tongue hemorrhage.
 - Consider a brief course of high-dose steroids (e.g., Decadron 10 mg IV, then 6 mg IV Q 6h × 24h).

9.5. Special situations

9.5.1. Basilar artery occlusion

The incidence of acute basilar artery occlusion is about 25% that of acute MCA occlusion.⁶⁹ Vertebrobasilar artery occlusion syndromes are discussed in detail in Chap. 17, *Acute Ischemic Stroke*.

9.5.1.1. Radiographic evaluation

Imaging in patients with posterior circulation acute stroke is somewhat different from that in patients with anterior circulation stroke. Of course, all patients must be evaluated for the presence of intracranial hemorrhage; non-contrast CT is adequate for this purpose. Because of bone artifact and the difficulty with imaging the brainstem and cerebellum, CT perfusion is less useful in this setting, although PCA territory ischemia may be well characterized. CT angiography (CTA) can be very helpful in patients with basilar artery occlusion,⁷⁰ particularly in defining the extent of the occlusion and in assessing collateral circulation. A CTA can be obtained at the same time as the initial screening CTA, and some centers routinely combine CTA with CT perfusion for the evaluation of all patients with acute ischemic stroke. MRI, combined with MR angiography (MRA) can also be helpful.

9.5.1.2. Patient selection for thrombolysis

Patient selection criteria for thrombolysis for basilar artery occlusion are controversial,^{71, 72} largely because the condition is uncommon, two modalities exist (IA and IV thrombolysis), and because all of the existing published data comes from small, nonrandomized series, except for one randomized trial, which was terminated because of poor enrollment.⁷³ The Basilar Artery International Cooperation Study (BASICS) is an ongoing international prospective database of patients with acute basilar artery occlusion (<http://www.strokecenter.org/trials/TrialDetail.aspx?tid=477>).

INCLUSION CRITERIA

1. Acute or progressive onset of significant brainstem, cerebellar, or PCA territory symptoms within 12–24 h of treatment.⁷⁴
 - (a) In the Australian Urokinase Stroke Trial, a 24 h window was not associated with an increased rate of adverse outcomes.⁷³
2. Basilar artery occlusion, as shown by CTA, angiography, or MRA.
3. Relative inclusion criteria (i.e., factors that predict a favorable response to thrombolysis)
 - (a) Embolic origin of occlusion.²¹
 - (b) Distal basilar artery occlusion, or short segment occlusion.^{21, 75}
 - (c) Evidence of good collateral circulation.
 - (d) Younger patient.

EXCLUSION CRITERIA

1. Acute intracranial hemorrhage.
2. Examination compatible with brain death, or near-brain death.
3. Widespread, severe ischemic injury on imaging (e.g., hypoattenuation and brain edema throughout the brainstem and cerebellum on CT).
4. Relative exclusion criteria:
 - (a) Atherosclerotic occlusion.²¹
 - (b) Proximal basilar artery occlusion, or longer segment occlusion.^{21, 75}
 - (c) Older patient.

9.5.1.3. Technique

IA THROMBOLYSIS

1. Femoral artery access is obtained and a diagnostic catheter is placed in the subclavian artery proximal to the origin of the vertebral artery.
 - (a) If a pre-procedure CTA or MRA was done, select the vertebral artery that is largest in caliber and patent. If noninvasive imaging of the cervical vessel is not available, a diagnostic angiogram, beginning with the right subclavian artery, is necessary. Be sure to image the origin of the vertebral artery prior to placing the diagnostic catheter in the vessel, to check for vertebral artery origin stenosis. Bilateral ICA angiograms are also helpful, to assess collateral circulation via the P-comm arteries.
 - (b) If both vertebral arteries are occluded, angiography of the thyrocervical costocervical trunks and ICAs should be done. IA thrombolysis by injection of t-PA into the ascending cervical branch of the thyrocervical trunk has been reported.⁷⁶
2. IV heparin (2,000 unit bolus and a 500 unit per hour infusion) is given. A syringe containing protamine (50 mg) should be on the back table in case a hemorrhage occurs.
3. The diagnostic catheter is then exchanged for a guide catheter, which is positioned as distal as possible within the vertebral artery.
4. Thrombolysis is done, as described above in the *Endovascular Technique* section.

IV THROMBOLYSIS

Some data suggest that IV thrombolytic treatment is effective for basilar artery occlusion. A systematic review concluded that recanalization rates are better for patients treated with IA thrombolysis, but the clinical outcome is similar for either modality.⁷⁷ The dosage for IV t-PA is: 0.9 mg kg⁻¹ (maximum of 90 mg) over 60 min with 10% of the dose given as a bolus over 1 min.

9.5.1.4. Outcomes and complications

The following data are from a systematic review of series consisting of 420 patients treated with IA (344 patients) or IV thrombolysis (76 patients) for basilar artery occlusion.⁷⁷

1. Frequency of recanalization
 - (a) IA: 65%
 - (b) IV: 53% ($p = 0.05$)
2. Death or dependency
 - (a) IA: 76%
 - (b) IV: 78% ($p = 0.82$)
3. Survival rates
 - (a) IA: 45%
 - (b) IV: 50% ($p = 0.48$)
4. Good outcome rates
 - (a) IA: 24%
 - (b) IV: 22% ($p = 0.82$)
 - (c) Without recanalization: 2%

9.5.2. Associated carotid stenosis + stroke

Acute ischemic stroke in the presence of atherosclerotic carotid stenosis can be effectively treated with IA thrombolysis and carotid angioplasty and stenting (CAS) during the same procedure. CAS procedures are discussed in detail in Chap. 10, *Extracranial Angioplasty and Stenting*. The key issues for combined thrombolysis and CAS are:

1. If thrombus is present in the cervical ICA, thrombolysis or embolectomy in this vessel should be done prior to CAS.
2. Antiplatelet therapy is mandatory to avoid acute stent thrombosis due to platelet activation. Parenteral GP IIB/IIIa inhibitors are the fastest-acting

antiplatelet agents available; the authors of this handbook prefer abciximab, because it is reversible with platelet transfusion if necessary.

- (a) Note: Use of antiplatelet agents, in addition to thrombolytics, increases the risk of hemorrhage. Therefore, the use of thrombolytic drugs should be minimized as much as possible if a stent is to be used.

9.5.2.1. Technique

1. Femoral artery access is obtained and a diagnostic catheter is placed in the CCA.
2. If angiography shows significant stenosis of the cervical ICA (> 50%), preparations are made for CAS.
 - (a) CAS devices are obtained and prepared.
 - (b) Antiplatelet agents are ordered and prepared.
3. An exchange-length hydrophilic wire is placed in the ECA (or an Amplatz Extra Stiff Guidewire 0.035" (Cook Inc., Bloomington, IN) is placed in the CCA if the ECA is not accessible). The diagnostic catheter and groin sheath are exchanged over the wire for a 6F 90 cm sheath (e.g. Shuttle® sheath, Cook Inc., Bloomington, IN) or an 8F guide catheter.
4. Heparin IV 2,000 unit bolus and a 500 unit per hour infusion given.
 - (a) Protamine on stand-by
 - A syringe containing protamine, enough to reverse the total amount of heparin the patient has received, should be kept on the back table for easy access to the operator, should the hemorrhage occur during the case.
 - Dosage of protamine required to reverse heparin: 10 mg protamine/1,000 U heparin.
 - The authors routinely keep a sterile syringe containing ≥ 50 mg of protamine on the back table. The drug is infused into the guide catheter or sheath when intracranial hemorrhage occurs.
5. Navigate a microwire and microcatheter into the ICA, past the region of stenosis. A microcatheter angiogram can clarify the anatomy distal to the stenosis. Generally speaking, there are two possible locations for the symptomatic occlusion, and each calls for a different strategy:
 - (a) *Cervical ICA*. A relatively small amount of thrombus in the cervical ICA may respond to selective injection of a lytic agent through the microcatheter. Larger, occlusive thrombosis approached in one of the several ways:
 - *Microcatheter navigation into the intracranial vessels*. Even in cases in which the ICA is completely occluded, a microwire (with a "J" shape at the tip) and microcatheter can be gently navigated through the region of occlusion, into the intracranial vessels.⁷⁸
 - *Suction thrombectomy*. A large clot burden in the ICA may be treated with suction thrombectomy by aspiration through the guide catheter. However, caution should be used when positioning the guide catheter adjacent to the origin of the ICA, as a friable atherosclerotic plaque may be disrupted or a dissection may occur. Alternatively, a 4 or 5 F diagnostic catheter may be used for the suction thrombectomy.
 - (b) *Intracranial vessel*. If the anatomy permits, a microwire and microcatheter can be guided through the stenotic ICA and into the occluded intracranial vessel. Recanalization of the vessel via selective administration of a thrombolytic drug is then followed by CAS. Note: once the cervical carotid is revascularized and antegrade flow is improved, intracranial occluded and stenotic regions may then significantly improve. In elective CAS, it is axiomatic that distal tandem stenoses will often improve after treatment of the proximal lesion.
6. Thrombolytic agent. Options include:
 - (a) *GP IIB/IIIa inhibitor*. In some cases, the authors have had good results with intra-arterial injection of abciximab; this strategy accomplishes two goals: (1) Acute thrombi, even predominantly fibrin-rich ones (i.e., "red clot") will dissolve with direct administration of a GP IIB/IIIa inhibitor; (2) The GP IIB/IIIa inhibitor will provide anti-platelet protection after deployment of the stent.
 - *Abciximab dose*: The authors use the systemic loading dose for IA administration: 0.25 mg kg⁻¹ in a concentration of 2 mg mL⁻¹ saline.

The injection is given over several minutes. This is followed by a 12-h IV infusion at a rate of $10 \mu\text{g min}^{-1}$.

- Note: Partial loading doses of abciximab should be avoided, as there is some data from the cardiology literature to indicate that partial loading doses of abciximab have a paradoxical pro-thrombotic effect.⁷⁹⁻⁸¹

(b) *Fibrinolytic*. If a fibrinolytic drug is used, such as t-PA, every effort should be made to minimize the amount used and to reduce the risk of hemorrhage (e.g., tight blood pressure control), as simultaneous administration of both fibrinolytic and antiplatelet drugs elevates the risk of hemorrhage.

7. Once the distal lesion has been treated, standard CAS procedure is used to treat the stenotic lesion.
8. After the procedure, if not already done, the patient is given a loading dose of ASA and clopidogrel (ASA 325 mg PO/NG/PR and clopidogrel 300 mg PO/NG), followed by ASA (325 mg PO QD) and clopidogrel (75 mg PO QD) for one month. ASA is continued beyond one month indefinitely.

9.5.3. Extracranial carotid or vertebral dissection + stroke

Spontaneous or traumatic dissection of the cervical vessels can cause stroke one or both of two mechanisms:

1. Thromboembolism (most common)
2. Hemodynamic impairment (less common)

Angiographic findings that indicate a dissection, rather than atherosclerotic stenosis, include a tapering stenosis, string sign, double lumen, and scalloping.⁸² Extracranial dissection syndromes are discussed in Chap. 18, *Extracranial Cerebrovascular Occlusive Disease*.

In most arterial dissection cases, thrombolysis without stenting is sufficient. Non-flow limiting dissections frequently cause some degree of thrombosis at the dissection site, which is usually platelet-rich (i.e., "white clot") and will respond to treatment with antiplatelet agents. A common scenario is a non-occlusive dissection with associated thrombus and embolization with occlusion of intracranial vessels. In these situations, the authors of this handbook have obtained good results with IA or IV injection of a GP IIB/IIIa inhibitor, followed by long-term treatment (3 months) with a combination antiplatelet regimen (e.g., ASA and clopidogrel).

Stenting is usually only necessary when:

1. The dissection is flow-limiting and the patient is symptomatic because of hemodynamic failure.
2. Treatment of the dissection is necessary to provide access to a distal lesion.

9.5.3.1. Technique

1. Femoral artery access is obtained and a diagnostic catheter is placed in the cervical vessel proximal to the lesion.
2. An angiogram is done to characterize the lesion. If stenting is necessary, then:
3. The diagnostic catheter is exchanged for a guide catheter or sheath large enough to accommodate a stent.
 - (a) 6 F 90 cm sheath (e.g. Shuttle® sheath, Cook Inc., Bloomington, IN) or an 8 F guide catheter.
 - (b) In rare cases, the dissection originates in the aortic arch or subclavian artery. In these situations, the access catheter should be positioned in the aorta or subclavian proximal to the dissection; stabilization of the guide catheter can be obtained by passage of a "buddy wire" into the subclavian or innominate artery.
4. Heparin IV 2,000 unit bolus and a 500 unit per hour infusion given.
 - (a) Protamine on stand-by.
5. *Gently* navigate a microwire with a J-shaped tip and microcatheter into and past the region of dissection. A microcatheter angiogram is then done to determine if the microcatheter is in the true lumen, rather than the false lumen.
 - (a) It is critical that access to the true lumen, distal to the dissection, is obtained. Inadvertent stenting of the false lumen will likely cause a complete occlusion.

6. If thrombus is present in the dissection site, then IA infusion of a GP IIB/IIIa inhibitor or a thrombolytic agent may dissolve the thrombus and permit stenting of the lesion without the risk of embolization.
 - (a) Note: Use of antiplatelet agents, in addition to thrombolytics, increases the risk of hemorrhage. Therefore, the use of thrombolytic drugs should be minimized as much as possible if a stent is used.
 - (b) The authors of this handbook prefer to use abciximab in these cases.
 - The authors of this handbook prefer to use abciximab in these cases.
 - Abciximab is reversible with platelet transfusions should bleeding complications arise, and it will provide the necessary protection against platelet activation once the stent is deployed.
 - Abciximab dose: 0.25 mg kg⁻¹ in a concentration of 2 mg mL⁻¹ saline. The injection is given over several minutes. This is followed by a 12-h IV infusion at a rate of 10 µg min⁻¹.
 - Note: Partial loading doses of abciximab should be avoided, as there is some data from the cardiology literature to indicate that partial loading doses of abciximab have a paradoxical pro-thrombotic effect.⁷⁹⁻⁸¹
7. An embolic protection device is then advanced across the lesion and deployed in the true lumen of the vessel distal to the dissection.
 - (a) An embolic protection device should always be used in this setting, when feasible. Even in cases where there is no apparent thrombus or atherosclerosis associated with the stenosis, non-angiographically apparent debris may be released when the stent is deployed.
8. A self-expanding stent is then deployed. The stent is sized and positioned to extend from the normal vessel proximal to the dissection, to cover as much of the dissection as possible. For long dissections, particularly spiral dissections that extend from the CCA into the ICA, coverage of the proximal portion of the dissection is usually sufficient, to plaster the dissection flap against the wall of the vessel and re-establish antegrade flow.
9. After the procedure, if not already done, the patient is given a loading dose of ASA and clopidogrel (ASA 325 mg PO/NG/PR and clopidogrel 300 mg PO/NG), followed by ASA (325 mg PO QD) and clopidogrel (75 mg PO QD) for one month. ASA is continued beyond one month indefinitely.

9.5.4. Associated intracranial stenosis + stroke

Atherosclerotic stenosis may underlie an acute occlusion. This combination of disorders – acute thrombosis on top of a stenotic lesion – may be apparent immediately on imaging, or only after thrombolysis fails to reopen a narrowed segment. Indications of concomitant stenosis on imaging in acute stroke include:

1. Calcification in the wall of the affected vessel on CT or CTA.
2. Long segment occlusion.
3. Clinical risk factors for atherosclerosis.

Treatment options include angioplasty or angioplasty with stent placement. The optimal strategy depends largely on the size and accessibility of the lesion. Angioplasty alone has the advantages of (1) not requiring antiplatelet therapy, (2) being easier and safer than stenting, particularly in tortuous anatomy. Stenting is more likely to maintain patency of the vessel, at least for the short term, and is the best option for treatment of occlusive dissections.

9.5.4.1. Technique

Intracranial angioplasty technique is discussed in detail in Chap. 11, *Endovascular Treatment of Intracranial Stenosis and Vasospasm*.

1. An accurate diagnosis of significant intracranial stenosis is established. This typically follows an attempt at primary thrombolysis.
2. Assuming that guide catheter- and microcatheter-access to the affected vessel are established, a microwire and microcatheter are then guided past the area of stenosis. The microwire is removed and a microcatheter angiogram is done, to assess the distal vessels and further characterize the region of stenosis.

3. Angiographic measurements are made to determine the size of the angioplasty balloon that is needed.
 - (a) For atherosclerotic stenoses, a non-compliant coronary angioplasty balloon is useful, such as an Maverick²™ Monorail™ balloon catheter (Boston Scientific, Natick, MA).
 - If a dissection is the cause of the stenosis, stenting without angioplasty may be sufficient.
 - (b) *Size*: A balloon with a diameter slightly smaller than the normal diameter of the vessel should be selected. The length of the balloon should be relatively short, to maximize the ease of navigation of the balloon into the target vessel.
 - (c) The angioplasty balloon and inflator are prepared. The balloon is deflated and loaded with 50/50 contrast in heparinized saline.
4. An exchange-length microwire is advanced through the microcatheter, and the microcatheter is then exchanged for the angioplasty balloon.
5. The angioplasty balloon is gently guided into the proximal region of stenosis or occlusion, and inflated to nominal pressure. The balloon is kept inflated for 40–50 s, and then deflated.
 - (a) A guide-catheter angiogram is done after each balloon inflation, to reassess the lesion and check for contrast extravasation.
6. Several balloon inflations are often necessary to reopen an occluded, atherosclerotic intracranial artery.
7. Addition of a stent is indicated for some atherosclerotic vessels that will not stay open despite angioplasty, and for some dissections.
8. If stent deployment is planned, then antiplatelet therapy is important.
 - (a) An IV GP IIB/IIIa inhibitor will provide immediate antiplatelet protection once the stent is deployed. Later, the patient may be given ASA and a loading dose of clopidogrel for long-term antiplatelet therapy.
 - (b) *Note*: Addition of antiplatelet agents significantly increases the risk of hemorrhagic complications.
9. Choice of stent:
 - (a) A self-expanding stent, such as the Wingspan™ Stent System (Boston Scientific), is first-line in most situations, because this device was developed specifically for the treatment of intracranial stenosis and is therefore, highly trackable and flexible. Wingspan technique is discussed in detail in Chap. 11. Neuroform stent-assisted revascularization for acute stroke has been reported.⁸³
 - (b) Coronary balloon-expandable stents are rigid and difficult to maneuver safely in through the carotid siphon or distal vertebral artery. Use of these stents to treat intracranial stenosis is associated with complication rates in the neighborhood of 20–25%.^{84, 85} Use of a balloon expandable stent is acceptable in carefully selected cases, in which stent-assisted recanalization is critical and self-expanding stent is not available.
10. *Sizing of stent*: The stent diameter should be about 0.5 mm less than the normal diameter of the vessel.
11. *Post-procedure antiplatelet therapy*: Dual antiplatelet therapy is standard in any stent procedure.
 - (a) Clopidogrel 75 mg PO/NG QD for one month and ASA 325 PO/NG QD indefinitely.

9.5.5. Central retinal artery occlusion

IA thrombolysis for acute central retinal artery occlusion has been found to benefit a minority of patients in small, retrospective, single center series. Significant visual improvement has been reported in some 22–30% of cases.^{86–89} A meta-analysis of 100 cases of IA thrombolysis for central retinal artery occlusion found that, significant visual improvement (visual acuity of 20/40 or better) occurred in 27%; the overall rate of complications was 6%, and all were transient.⁹⁰ No cases of intracranial or retinal bleeding were reported. A prospective, randomized, multicenter trial of IA thrombolysis by the European Assessment Group for Lysis in the Eye (EAGLE), is currently in progress.⁹¹

The retina is irrigated primarily by the central retinal artery. In some 15–30% of eyes, a cilioretinal artery arises from the ciliary arteries, and contributes to the

retinal blood supply.⁹² Experimental occlusion of the central retinal artery up to 97 minutes in rhesus monkeys causes no detectable damage.⁹³ Ischemic injury occurs beyond 98 min and correlates with the length of occlusion, and occlusion for 240 min results in massive, irreversible retinal damage. In humans with central retinal artery occlusion, the success rate with IA thrombolysis declines with time since onset of symptoms with the best results occurring in patients treated within 6 h of onset,^{86, 89, 94}. Although good results have been obtained in some 9% of patients treated > 14 h after symptom onset,⁸⁹ this may not be significantly different from the natural history, in which 8% of patients report significant recovery without therapy.^{94, 95}

Predictors of a good response to IA thrombolysis includes a short time symptom onset and younger age.⁸⁸ Risk factors for complications with IA thrombolysis are advanced age and high grade ipsilateral ICA atherosclerotic stenosis.⁸⁷

9.5.5.1. Diagnosis

1. Central retinal artery occlusion manifests as sudden, *painless*, unilateral visual loss.
 - (a) In contrast, occlusion of the *ophthalmic artery* can cause orbital and eye pain and conjunctival injection, in addition to visual loss.
 - (b) *Branch retinal artery occlusion* most commonly affects the temporal retinal vessels, and the resulting visual deficit is characteristically incomplete.⁹⁶
 - (c) *Central retinal vein occlusion* can be identified by the presence of retinal vein dilatation in all four quadrants and retinal hemorrhages. Central retinal vein occlusion may occur along with central retinal artery occlusion.
 - IA thrombolysis for central retinal vein occlusion leads to improvement in visual acuity in 23% of the patients in one series.⁹⁷
2. An ophthalmological examination is necessary to confirm the diagnosis of central retinal artery occlusion. Funduscopic examination findings include ischemic macular edema, a cherry red spot, and reduced or no retinal blood flow.

9.5.5.2. Non-endovascular treatment

A variety of management options exist, and the efficacy of the various techniques are controversial.⁹⁸ Some can be administered by non-ophthalmologists, while anterior paracentesis requires an ophthalmologist.

1. Laying the patient flat.
2. Acetazolamide, 500 mg IV.⁹⁸
3. *Ocular massage*. The patient is instructed to digitally apply pressure to the closed eyelids of the affected eye for 15–30 min.
4. Anterior chamber paracentesis. Intraocular pressure can be reduced by direct aspiration of aqueous fluid.

9.5.5.3. Technique

1. A diagnostic angiogram of the cervical and intracranial carotid systems is done. Isolated occlusion of the central retinal artery is frequently not apparent on a diagnostic angiogram, but concomitant abnormalities in the carotid or ophthalmic arteries, such as intraluminal thrombus or atherosclerosis, should be checked. Also, a baseline intracranial angiogram is important, to check for the presence of other vessel occlusions and to establish a baseline, should an intracranial thromboembolic event occur later in the case or afterwards.
2. IV heparin: 5,000 unit bolus.
 - (a) Protamine on stand-by
3. Guide catheter access is obtained. The higher in the ICA, the better.
4. Selective catheterization of the ophthalmic artery is done under roadmap guidance. The tip of the microcatheter does not have to be in a very distal position for the access to the central retinal artery.
 - (a) Any small microcatheter and microwire will do. The authors prefer to use an UltraFlow™ microcatheter (ev3, Irvine, CA) and Mirage™ 0.008 in. (ev3).

- (b) If the ICA or ophthalmic artery is occluded, or if the ophthalmic artery cannot be accessed, then the selective injection of thrombolytics into the distal internal maxillary artery can be done.
- 5. A microcatheter angiogram is done.
 - (a) *Note:* The choroidal blush on angiography should not be confused with the retina. The choroidal blush results from contrast filling of the ciliary arteries; the presence or absence of the choroidal blush has no bearing on the outcome of IA thrombolysis.⁸⁶
- 6. Infusion of thrombolytic. Favorable results have been reported with both t-PA and urokinase. The authors use whichever agent that can be obtained most quickly. The drug is infused slowly over an hour, approximately.
 - (a) Urokinase: 100,000–1,000,000 units.^{86–89}
 - (b) t-PA: 15–50 mg.^{87, 91, 99}
- 7. Ophthalmological examinations may be done during the infusion of the thrombolytic drug; funduscopic evidence of retinal artery recanalization is sometimes apparent during the procedure.
- 8. The procedure is stopped when the vision is significantly improved or when the maximum dose of thrombolytic agent (900,000–1,000,000 units urokinase or 40–50 mg t-PA) has been given.
- 9. Final intracranial and cervical angiograms are done, to check for vessel dropout or carotid artery guide catheter-induced vasospasm or dissection.

9.5.6. Venous occlusion

Treatment of intracranial venous occlusion is discussed in Chap. 12, *Venous Procedures*.

9.6. Appendix 1: Primer on imaging in stroke

Imaging in acute ischemic stroke has three main purposes:

1. Diagnosis of ischemic stroke
2. Exclusion of hemorrhage
3. Distinguish tissue that is still viable (i.e., the penumbra) from regions of completed infarction

9.6.1. Noncontrast computed tomography

Emergent, noncontrast-enhanced brain CT is the initial procedure of choice in most cases of suspected acute ischemic stroke.^{7, 100} The primary role of CT is to exclude hemorrhage and other nonvascular causes of abrupt neurologic change. The 1994 *Guidelines for the Management of Patients with Acute Ischemic Stroke* recommended that CT be the primary diagnostic brain imaging study for evaluation of patients with suspected stroke.¹⁰¹

In CT scan interpretation, the terms, “hypoattenuation” and “hyperattenuation” are preferred to “hypodense” and “hyperdense”.²⁰ Attenuation indicates the degree of x-ray absorption that occurs within tissue. In patients with stroke, hypoattenuated tissue tends to be edematous, and hyperattenuated tissue tends to be hemorrhagic.

9.6.1.1. Noncontrast CT diagnosis of acute ischemia

Brain CT appears normal in < 50% of patients with acute ischemic stroke.¹⁰² It identifies ischemic lesions with a sensitivity of 65% and a specificity of 90% within 6 h of stroke onset.¹⁰³ Hemispheric stroke can cause brain edema that is detectable within

1–2h of stroke. The peak period for identifying brain ischemia on CT is 3–10 days after the ictus. The presence of evidence of ischemia on CT within 6h of stroke onset has been associated with poor outcomes,¹⁰⁴ although a recent single-center series contradicted this.¹⁰⁵ A large, hypoattenuated area detected within 6h of stroke onset is an indication that the treatment with thrombolytics will not be effective because, life-threatening brain edema is already in progress.¹⁰³

SPECIFIC FINDINGS THAT MAY INDICATE ISCHEMIA

1. *Loss of cortical gray–white differentiation.* may be detected within 6h of onset of stroke symptoms in 82% of patients with MCA territory ischemia.¹⁰⁶
 - (a) “Insular ribbon sign” The insular cortex is a watershed arterial zone; loss of white differentiation in the insular cortex can be an early sign of MCA ischemia.¹⁰⁷
2. Hemispheric sulcal effacement.
3. Attenuation of the lentiform nucleus.
4. Subtle regions of subcortical hypoattenuation
5. “MCA sign.” Hyperattenuation of the M1 segment due to thromboembolism.^{108, 109}
6. “Sylvian dot sign.” Distal MCA (M2 or M3 branches) occlusion indicated by hyperattenuation in the Sylvian fissure.¹¹⁰ Sensitivity 38%, specificity 100%, positive predictive value 100%, negative predictive value 68%.¹¹¹

The combined presence of the insular ribbon sign (Fig. 9.4), hemispheric sulcal effacement, and attenuation of the lentiform nucleus is predictive of ICA occlusion.¹¹² CT evidence of widespread infarction is correlated with a higher risk of hemorrhagic transformation with thrombolytic agents. In a trial of IV rt-PA given within 3h of stroke onset, CT signs of edema and mass effect were associated with an eightfold increase in the risk of symptomatic hemorrhage.²⁵

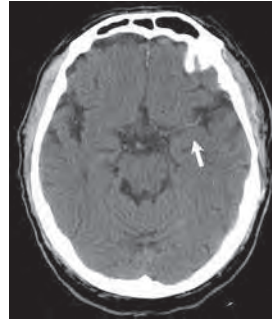


Fig. 9.3 MCA sign
Hyperattenuation of the M1 segment due to thromboembolism (arrow).

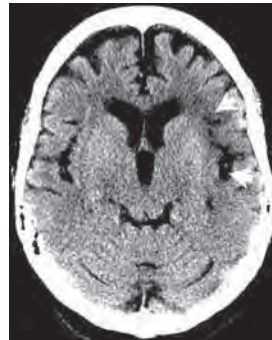

Fig. 9.4 Insular ribbon sign
Insular ribbon sign. Loss of gray-white differentiation in the insula (arrow heads) can be an early sign of MCA territory ischemia.

9.6.2. CT perfusion

CT perfusion provides quantitative data about CBF, and is becoming widely available as a software package included with most high-speed CT scanners. CT perfusion involves the administration of a single-bolus dose of intravenous iodinated contrast material, followed by spiral CT imaging during the passage of the contrast bolus through the cerebral vasculature. The integrated change in tissue density during the passage of the contrast bolus, is used to yield quantitative information about CBF as well as CBV and time-to-peak (TTP) or mean transit time (MTT). Acquisition and processing of the data are accomplished seconds to minutes. The concept of CT perfusion was introduced more than 20 years ago¹¹³, but had to await the development of high-speed helical CT scanners, fast computers, and software capable of rapid data analysis to make the technique clinically useful.

Normal Values of CBF and CBV

Cerebral blood flow is normally maintained within a narrow range by autoregulation. Normal CBF is approximately 80 mL per 100 g min⁻¹ in human gray matter and approximately 20 mL per 100 g min⁻¹ in white matter. Global CBF, as well as average CBF in the cortical mantle, which is roughly a 50:50 mix of gray matter and white matter, is approximately 50 mL per 100 g min⁻¹. Protein synthesis in neurons ceases when CBF falls below 35 mL per 100 g min⁻¹.¹¹⁴ At a CBF ≤ 20 mL per 100 g min⁻¹, however, electrical failure occurs and synaptic transmission between neurons is disturbed, leading to loss of function of still-viable neurons.^{115–117} Metabolic failure and cell death occur at CBF ≤ 10 mL per 100 g min⁻¹. CBV is defined as the amount of blood in a given quantity of brain tissue. Normal CBV is approximately 4–5 mL per 100 g.^{118, 119} CBV can be decreased or increased during cerebral ischemia, depending on the degree of cerebral autoregulation activation.^{119–122}

9.6.2.1. CT perfusion technique

PARAMETERS

CT perfusion produces the following data:

1. Cerebral blood flow (CBF), measured in mL per 100 g of brain tissue per minute (mL per 100 g min⁻¹) or as mL per 100 mL of brain tissue per minute (mL per 100 mL min⁻¹).
2. Cerebral blood volume (CBV), measured in mL per 100 g or mL per 100 mL.
3. Time to peak (TTP) is defined as the time delay (in seconds) between the first arrival of contrast within major arteries included in the section imaged and the local bolus peak in the brain tissue.
4. Mean transit time (MTT) indicates the time (in seconds) required for contrast material to pass from the arterial side to the venous side of the intracranial circulation. Because of the different pathways that can be followed, blood elements – or contrast material – flowing through the vascular network of the brain will require different lengths of time (i.e., transit times) to travel from artery to vein. The average of all possible transit times is MTT.
 - (a) TTP and MTT are parameters unique to CBF techniques (e.g., CT perfusion and MRI perfusion) that utilize an intravascular indicator and track the passage of the indicator through the brain over the course of time to determine CBF.

CONCEPTS

There are three methods of CT perfusion (Table 9.6). Two methods, known as the first pass bolus tracking techniques, are based on the indicator dilution principle and provide information about CBF, CBV, and MTT or TTP. A third method, the whole brain technique, (aka the slow-infusion method), provides information about CBV only.

In CT perfusion techniques utilizing the indicator dilution principle, a known amount of a nondiffusible indicator or tracer (e.g., iodinated contrast material) is injected into a cubital vein, and the concentration of this indicator is measured against time during its first pass through an intracranial vessel. Rapid injection of a contrast bolus leads to a transient change in brain tissue enhancement, as the material travels through the intracranial vasculature. This change is linearly proportional to the serum concentration of the contrast agent. With spiral CT scanning, these changes can be graphed as a time-density curve for every voxel in a CT-imaging slice.

Two different mathematical approaches are commonly used to calculate CT perfusion data from the time-density curve, *deconvolution* and *maximum slope*. The *deconvolution method* is based on the Fick principle. The attenuation values of an artery in the field of view (the arterial input function), such as the anterior cerebral artery, are integrated with time-density information of the brain tissue on a voxel-by-voxel basis in a mathematical operation called deconvolution. In mathematical terms:

$$C_t(t) = \text{CBF} \cdot [C_a(t) \otimes R(t)]$$

Table 9.6 CT perfusion methods

	First-pass techniques		Whole brain method
	Deconvolution method	Maximum slope method	
Parameters	CBF, CBV, MTT	CBF, CBV, TTP	PBV
Amount of brain imaged	4–8 slices	4–8 slices	Entire brain
Amount of contrast material	40–50 ml	50 mL	100 mL
Rate of contrast injection	4 mL s ⁻¹	8 mL s ⁻¹	3 mL s ⁻¹
Principle sources of error	Choice of AIF, blood–brain barrier leakage, recirculation of contrast material	Delay in appearance of contrast material in the brain (e.g., due to diminished cardiac output or proximal vessel occlusion)	Diminished cardiac output or proximal vessel occlusion or stenosis

AIF Arterial input function, CBF Cerebral blood flow, CBV Cerebral blood volume, MTT Mean transit time, TTP, Time to peak, PBV Perfused cerebral blood volume

where $C(t)$ is the tissue time-density curve; $C_a(t)$ is the arterial time-density curve; $R(t)$ is the impulse residue function, and \otimes is the convolution operator. The impulse residue function is an idealized tissue time-density curve that would result if the entire bolus (the *impulse*) of contrast material was administered instantaneously into the artery supplying a given area of the brain. The plateau of impulse residue function reflects the length of time during which the contrast material (the *residue*) is passing through the capillary network. Both $C_a(t)$ and $C(t)$ can be measured, and the deconvolution process uses the information to calculate CBF and CBV. MTT is then derived by using the central volume principle, which relates CBF, CBV, and MTT in the following relationship:

$$CBF = CBV/MTT$$

The deconvolution-based method is employed by the General Electric (Milwaukee, WI) and Philips Medical Systems (Best, the Netherlands) CT perfusion software. The accuracy of this method depends upon an intact blood–brain barrier, as leakage of the contrast material out of the intravascular space can lead to artifactually high perfusion parameters. Accuracy can also be influenced by the choice of the reference artery¹²³ and recirculation of contrast material.

In the *maximum slope method*, the maximum slope of the time-density curve is used to calculate CBF (Fig. 9.5).^{124–126} Values for CBV are calculated from the maximum-enhancement ratio, which is the maximum enhancement of the time-density curve in a given voxel compared to that of the superior sagittal sinus.^{124, 127, 128} Software using this method, such as the program used by Siemens (Syngo, Erlangen, Germany), reports TTP rather than MTT. The accuracy of this method depends on a rapid bolus injection of contrast material because, a delay in the appearance of contrast material in the intracranial vasculature will lead to a decrease in the maximum slope of the time-density curve, and CBF will be underestimated.¹²⁴

A third CT perfusion method is the *whole brain technique*, in which CBV data about the entire brain is obtained.¹²⁸ In this technique, a CT scan of the head without contrast enhancement is obtained, followed by an intravenous infusion of iodinated contrast material (approximately 100 mL). Scanning begins after a delay of about 25 s to allow passage of contrast material into the venous circulation. Subtraction of the unenhanced scan from the enhanced scan yields images of contrast concentrations only. Normalization of brain tissue enhancement values with density measurements in a large vessel such as the superior sagittal sinus, produces “relative CBV” maps.

In patients with cerebral ischemia, delivery of contrast material to the affected region of the brain is diminished, and true CBV may not be accurately measured. Therefore, the term *perfused* CBV (PBV) distinguishes the parameter measured by the whole brain technique from the actual CBV value.¹²⁸ Cerebral blood flow, TTP, and MTT are not determined with this method because there are no timed data. Some authors have used this technique in combination with CT angiography, for the evaluation of patients with acute ischemic stroke.^{129, 130} The accuracy can be impaired by the presence of proximal vessel stenosis or occlusion and collateral channels; delay of contrast arrival beyond the time of CT image acquisition may result in an underestimation of the true PBV, and lead to an over-interpretation of ischemia.¹²⁸

Validation

Quantitative CBF measurement by CT perfusion has been validated by comparison to other techniques for measuring CBF such as microspheres,¹³¹ xenon CT,^{133, 134} and PET.^{135, 136} CT perfusion imaging using the deconvolution technique has been shown to demonstrate little variability within individuals.¹³⁵ The use of CT perfusion in the identification of cerebral ischemia has been validated in experimental models.^{137–139} Further validation of CT perfusion in human subjects by comparison with other brain imaging techniques in the setting of acute stroke, has been extensive and is discussed below.

Limitations

CT perfusion imaging has several practical limitations. Brain regions close to the skull base are difficult to image because of bone artifact. A peripheral IV is required for intravenous administration of the contrast material, which can be a nuisance for some intensive care unit patients. The study requires iodinated contrast, which can be problematic.

An important limitation concerns the use of an intravascular indicator in first-pass CT perfusion methods. In distinction to more established techniques like xenon-CT and PET, in which diffusible tracers are used and only capillary perfusion is measured, all intracranial vessels are included in CT perfusion. This difference leads to an over-estimation of CBF in regions that include large vessels, such as around the Sylvian fissure.¹⁴⁰ Moreover, this aspect of CT perfusion makes it difficult to compare CT perfusion results to CBF values obtained by the use of other methods. Furthermore, depending on the method of calculation used, the results can be affected by blood–brain barrier breakdown, choice of the arterial input function, and recirculation (deconvolution method) or by inadequate delivery of the contrast bolus to the intracranial vasculature, such as in patients with significant cardiovascular disease (maximum slope method).

9.6.2.2. Interpretation of CT perfusion data

Validity has been demonstrated for each commonly used mathematical technique for CT perfusion by comparison with other CBF measurement techniques. However, each method has inherent limitations and sources of systematic error; hence, the description of CT perfusion as being “semiquantitative” by some authors.^{141, 142} Therefore, assessment of cerebral perfusion based on absolute values for CBF and CBV should be made with caution.^{143, 144} CT perfusion results for any given ROI, are most reliable and useful when they are interpreted in the context of data from the whole image (i.e., by comparing the data in one ROI with other ROIs in the image). Thus, for the identification of cerebral ischemia using the deconvolution method, Wintermark and colleagues found that a threshold value for regional CBF of 34%, compared to CBF values in the corresponding region in the non-ischemic hemisphere, accurately identified regions of cerebral ischemia.¹⁴⁵ Similarly, using the maximum slope method, Koenig and colleagues found that a threshold value for CBF of 48%, compared to the CBF values in non-ischemic regions, best identified areas of cerebral ischemia.¹⁴²

Although CBV can be increased during cerebral ischemia as a result of autoregulation-induced vasodilation, in CT perfusion using the deconvolution method, CBV values < 2.5 mL per 100 g indicate cerebral infarction.^{128, 145–147} Using the maximum slope method, a reduction of CBV of 60%, compared to non-ischemic regions of the brain, best identified cerebral ischemia.¹⁴² Using the whole brain technique for CT perfusion, normal PBV values are approximately 4.6 mL per 100 mL in gray matter and 1.75 mL per 100 mL in white matter.¹²⁸

Mean transit time is extended in regions of cerebral ischemia. In a series of patients with acute ischemic MCA stroke, Eastwood and colleagues found average MTT to be 7.6 s in the affected MCA territories and 3.6 s in the unaffected MCA territories.¹⁴⁸ Areas of reduced perfusion were defined as MTT > 6 s because that value represented at least three standard deviations greater than the average MTT values in unaffected MCA territories.

In normal brain tissue, TTP is typically < 8 s because of unimpaired antegrade flow. In ischemic regions, TTP is extended, reflecting a delay in perfusion because of collateral flow through alternative pathways, such as leptomeningeal vessels. TTP maps are useful for accurate identification of areas of impaired perfusion.¹⁴² A regional TTP > 8 s raises the suspicion of cerebral ischemia. However, TTP maps can provide false-positive findings when TTP is extended due to carotid stenosis or occlusion and regional CBF is compensated for by collateral vessels.¹⁴⁷

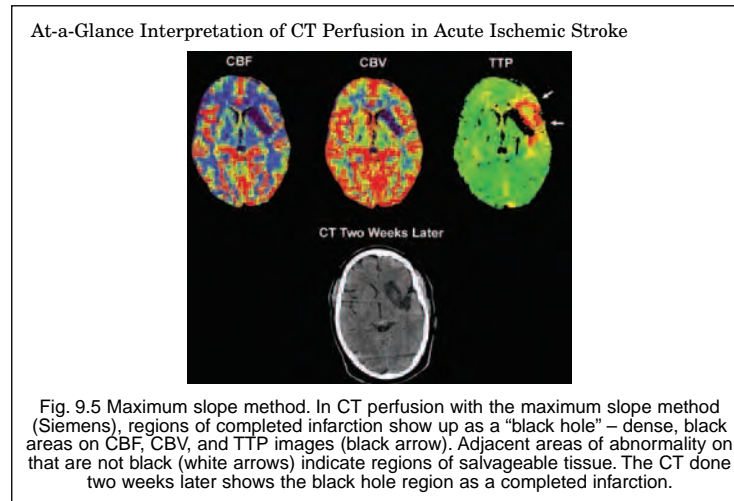
Both MTT and TTP maps can be used to identify cerebral ischemia. MTT maps offer advantages over CBF and CBV maps. MTT appears to be affected by ischemia at an earlier stage than CBF or CBV, although it is less specific.¹⁴⁵ Color-coded TTP and MTT maps appear to demonstrate regions of cerebral ischemia more readily than CBF and CBV maps. TTP and MTT are usually homogenous in normal areas of brain tissue, permitting easy identification of abnormal hemodynamics.¹⁴⁵ Moreover, CBF and CBV data are over-estimated when the ROI includes major vessels, such as MCA branches.¹³⁶ In comparison, TTP and MTT do not seem to be influenced by the presence of large vessels within ROIs. The absence of regions of extended TTP or MTT is usually a reliable indication that ischemia is not present.

9.6.2.3. CT perfusion in ischemic stroke

CT perfusion can be done at the same time as the initial screening CT scan in patients with acute ischemic stroke and can distinguish viable tissue from regions of completed infarction.

1. CT perfusion can be used to exclude poor candidates for thrombolysis, such as patients with lacunar strokes and without arterial occlusions, which account for up to 25%¹⁴⁹ and 29%¹⁵⁰ of patients with acute stroke, respectively.
2. CT perfusion imaging can provide prognostic information because patients with profound, widespread ischemia can be expected to have poorer outcomes than those with borderline ischemia.^{130, 145}

CT perfusion is able to distinguish treatable tissue at risk of infarction.^{145, 151} Using the deconvolution method, a mismatch between regional MTT, CBF, and CBV maps can indicate the presence of ischemic but potentially salvageable brain.^{132, 137, 141, 147} In a series of patients with acute stroke, CBV < 2.0 mL per 100 g best identified infarcted brain, and a region of MTT < 145% compared to the corresponding territory in the contralateral hemisphere best identified the entire ischemic region (infarction + penumbra).¹⁵² These values can be used to generate threshold maps on CT perfusion images Fig. 9.6. Using the maximum slope method, the relative values of CBF and



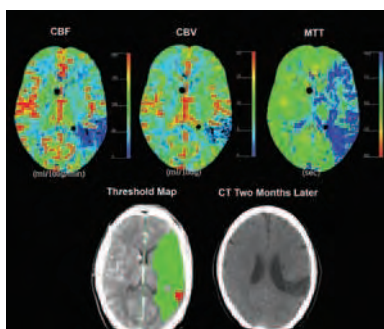


Fig. 9.6 Deconvolution method

In deconvolution CT perfusion (General Electric, Philips), the “black hole” technique is not a reliable way to identify regions of completed infarction. Threshold maps, however, can provide the same information. Here, the ischemic core (*dark threshold area – red on the color image – black arrow*) is defined as absolute CBV < 2 mL per 100 g, and the penumbra (*light threshold area – green on the color image – white arrows*) is defined as the region of brain with MTT values 1.45 times the MTT values in the corresponding area of the opposite hemisphere.¹⁵² The follow-up CT shows an infarction that corresponds to the ischemic core region.

CBV can be used to distinguish infarcted from ischemic tissue. In a series of patients undergoing CT perfusion studies within 6 h of stroke onset, the thresholds for best discrimination between infarcted and non-infarcted tissue were 48% of normal values for CBF, and 60% of normal values for CBV.¹⁴² The lowest relative CBF and CBV values among brain regions not developing infarctions, were 29% and 40% of normal values, respectively.

VALIDATION OF CT PERFUSION IN ACUTE ISCHEMIC STROKE

The deconvolution method has been validated in the diagnosis of acute ischemic stroke by comparison to CT imaging¹⁴⁸ and to MR T2-weighted imaging,¹⁴⁸ diffusion imaging,^{145, 153} and perfusion imaging.¹⁴⁸ In a series of patients with acute ischemic stroke, undergoing both CT perfusion and MRI diffusion studies on admission, infarct size on CBF maps correlated highly with the size of the abnormality on the diffusion-weighted imaging (DWI) map ($r = 0.968$).¹⁵³ Similarly, infarct size assessed by CT perfusion studies done on admission in patients with ischemic stroke, correlated highly with infarct size measured by follow-up MRI-DWI maps obtained an average of 3 days after admission ($r = 0.958$).¹⁴⁵

The maximum slope method has been validated in acute stroke by comparison to CT, MRI, and SPECT.¹⁴⁷ In a series of patients with acute stroke, who underwent both CT perfusion and SPECT studies on admission, the areas of ischemia indicated by CT perfusion CBF maps correlated well with those indicated by SPECT imaging ($r = 0.81$).¹²⁶ In a series in which ischemic areas on admission of CT perfusion images, were compared to the follow-up CT or MR images showing final infarctions, infarction was found to develop in all patients with > 70% CBF reduction and in 50% of patients with 40–70% CBF reduction.¹⁴⁷ Based on a threshold of CBF < 60% (compared with CBF in normal vascular territories), CBF maps predicted the extent of infarction with high sensitivity (93%) and specificity (98%). Similarly, TTP > 3 s predicted infarction with a sensitivity of 91% and a specificity of 93%. Notably, in the same study, a negative predictive value for TTP > 3 s of 99% was found, indicating that the absence of extended TTP is usually accurate in excluding the presence of ischemia. In a series of CT perfusion studies done in patients with acute stroke < 6 h after onset, and compared to the follow-up CT or MRI, threshold values of 48% and 60% of normal, for CBF and CBV, respectively, were found to discriminate best between the areas of infarction and the areas of non-infarction.¹⁴²

The whole brain technique for CT perfusion has been combined with CT angiography in the assessment of patients with acute ischemic stroke.^{128–130, 154} Whole brain technique measurement is limited to PBV, but has the advantage of imaging the entire brain, and the CTA can identify large vessel occlusions with high sensitivity and specificity. Cerebral ischemia is indicated by a reduction in regional PBV. In one study in which PBV-CTA was compared to follow-up imaging, PBV-CTA was 100% sensitive and 92% specific in the detection of large infarcts.¹³⁰ Among a series of patients undergoing intra-arterial thrombolysis for MCA occlusions, initial PBV-CTA lesion volumes correlated significantly with final infarct volume on follow-up CT or MRI imaging.¹²⁹ Prediction of final infarct volume depended on the occurrence of vessel recanalization. For patients with complete vessel recanalization, the relationship between initial and final infarct volume was strong ($R^2 = 0.94$), whereas for those without recanalization, there was progression of lesion volume on follow-up imaging ($R^2 = 0.50$, slope of the regression line = 1.61). All patients with either a lesion volume > 100 mL or no recanalization, had a poor outcome (Rankin scores, 4 to 6).

9.6.3. CT Angiography

CT angiography (CTA) is useful in identifying large vessel occlusion, and can complement CT perfusion. The time required for acquisition, processing, and analysis of CTA studies of patients with acute ischemic stroke, averages 15 min.¹⁵⁵ Compared to catheter angiography, CTA has sensitivity and specificity for the detection of large vessel occlusion of 98.4 and 98.1%, respectively.¹⁵⁵ CTA may be prone to false-positive results; in two series of CTA in acute stroke, a minority of patients was found to have lesions on CTA that could not be found with catheter angiography.^{156, 157} CTA can be particularly useful in assessment of vertebrobasilar occlusion,⁷⁰ as CT perfusion imaging of the posterior circulation territory is limited because of bone artifact. However, basilar artery lesions can be better assessed with CTA than vertebral artery lesions.¹⁵⁸ CTA combined with CT perfusion shows good agreement with MRI in the assessment of infarct size, cortical involvement, and internal cerebral artery occlusion.¹⁵⁹

9.6.4. MRI

Magnetic resonance imaging is based on the interaction between a powerful, uniform magnetic field and body tissues. Protons absorb energy from pulsed magnetic waves and are deflected from their alignment. As the nuclei return to rest from a state of excitement, energy is released and signals are induced in a receiver and converted into diagnostic images. During the process of energy release, tissue-specific relaxation constants can be used to construct weighted images to demonstrate specific tissues. A wide array of MRI imaging sequences are available (Table 9.7). Most MRI images accentuate T1 or T2 signal; T1 is longitudinal, or spin-lattice relaxation time and T2 is transverse, or spin-spin relaxation time. In T1-weighted images, fat has increased signal and water appears dark. In T2-weighted images, water has increased signal relative to brain. Brain tissue water content is typically increased in regions of edema,

Table 9.7 MRI signal characteristics of cerebral infarction

Time since ictus	DWI image	ADC map	FLAIR	T1	T2
Minutes or sooner	Not apparent	Dark	Not apparent	Not apparent	Not apparent
Minutes to hours	Bright	Dark	Not apparent	Not apparent	Not apparent
> 6h	Bright	Dark	Bright	Hazy	Bright
Hours to days	Bright	Dark	Bright	Dark	Very bright
1–2 week	Bright	Not apparent	Bright	Dark	Very bright
> 2 weeks	Not apparent or dark	Bright	Bright	Dark	Bright

ischemia, and hemorrhage, thus changing the appearance of the tissue on MRI. T2-weighted images usually show only tissue changes caused by severe and prolonged ischemia – apparent only after some 6–24 h following onset – and are not particularly useful in imaging acute ischemia.

DIFFUSION-WEIGHTED IMAGING

Diffusion-weighted imaging (DWI) measures the Brownian motion of water protons in tissue. In ischemia, sodium-potassium pump failure occurs, water moves from the extracellular space to the intracellular space, and the extracellular space shrinks. Proton motion is more restricted in the intracellular space, causing regions of ischemia to appear bright on DWI. These changes occur within minutes after ischemic stroke.^{160, 161} Areas of ischemia appear bright on DWI in the acute phase and become unapparent or dark after about two weeks. DWI images are substantially better than plain CT and conventional MRI in the detection of acute ischemia.¹⁶² The sensitivity of DWI in detecting cerebral ischemia is 96.6% and the sensitivity is 100%.¹⁶³

Diffusion-weighted images are influenced by other parameters such as spin density, T1, T2, TR, and TE. Calculation of the apparent diffusion coefficient (ADC) eliminates these influences and indicates pure diffusion information.¹⁶⁴ ADC combines at least two diffusion-weighted images that are differently sensitized to diffusion but are identical with respect to spin density, T1, T2, TR, and TE. The resulting “map” indicates the calculated ADC for each pixel in the MRI image. Areas of ischemia appear dark on ADC maps in the acute phase and become bright after about 2 weeks, because of T2 shine-through. Decreased ADC values indicate with good sensitivity (88%) and specificity (90%) that, an infarct is less than 10 days old.¹⁶⁵ Venous infarctions, in contrast, cause an increase in ADC values in the acute phase because of vasogenic edema, although in later stages, the ADC map appearance becomes complex because of the coexistence of cytotoxic and vasogenic edema and the presence of hemorrhage.¹⁶⁶

Diffusion-weighted imaging can be useful in the workup of patients with TIA.¹⁶⁷ “Dots of hyperintensity” on DWI, indicating microinfarctions that are too small to cause permanent neurological symptoms, are found in some 40–50% of patients with TIA.¹⁶⁸

Diffusion-weighted imaging and ADC maps are dynamic. Areas of ischemic injury may enlarge by 43% in the first 52 h after onset,¹⁶⁹ although in most patients, lesion size appears to reach a maximum by 24 h.¹⁷⁰ Conversely, DWI hyperintensity and ADC map hypointensity do not necessarily indicate infarction, as bright regions on DWI can be reversed by reperfusion. In a series of patients with acute stroke, 19.7% demonstrated “normalization” of ADC abnormalities after reperfusion.¹⁷¹ Tissue with ADC values 75–90% of ADC values in normal brain, are likely to proceed to infarction, whereas tissue with ADC values > 90% are more likely to recover.¹⁷² Nevertheless, DWI hyperintensity is a necessary stage on the path to infarction,¹⁶⁷ and the volume of DWI abnormalities do correlate with clinical severity.^{169, 173}

PERFUSION IMAGING

MRI perfusion imaging employs a first pass tracking technique and deconvolution method (Fig. 9.6) for calculating the brain perfusion parameters. Deconvolution is described in detail above, in the discussion of CT perfusion technique. In MRI perfusion, a bolus of gadolinium is injected rapidly into a peripheral vein, and tissue- and arterial-input curves are used to generate CBF, CBV, TTP and MTT images. The information is not quantitative because, the MR signal change after IV administration of gadolinium is not proportionally related to the plasma concentration of gadolinium. MRI perfusion is subjected to many of the limitations of CT perfusion, such as the dependence of lesion volume on arterial input function selection,¹⁷⁴ and controversy about the optimal perfusion parameters for the identification of affected tissue.¹⁷⁵ The value of MRI perfusion imaging lies in the *perfusion-diffusion mismatch* hypothesis, which holds that regions of abnormality identified by perfusion imaging, but not seen on diffusion weighted imaging, are equal to the penumbra, and comprise regions of potentially salvageable tissue. A perfusion-diffusion mismatch pattern is present in some 70% of patients with anterior circulation stroke scanned within 6 h of onset,¹⁷⁶ is strongly associated with proximal MCA occlusion,¹⁷⁶ and resolves on reperfusion.^{177, 178}

The penumbra on perfusion imaging has been defined as regions where DWI is normal and TTP > 4 s,¹⁷⁹ although, for practical purposes, any region that is abnormal on perfusion imaging but normal on DWI may represent salvageable tissue.¹⁸⁰ Among MRI perfusion parameters, CBF, MTT and TTP appear to best identify all affected tissue (and thereby distinguish penumbra when compared to DWI),^{181, 182} and CBV seems to best predict the final infarct volume.¹⁸³ Compared to final infarct volumes imaged on MRI, the sensitivities of CBF, CBV, and MTT for detection of perfusion

abnormalities were 84%, 74%, and 84%, respectively, and the specificities were 96%, 100%, and 96%, respectively.¹⁸³

Together, perfusion imaging and DWI can identify tissue that is at the risk of infarction but amenable to salvage with revascularization.¹⁸⁴ In a series of patients receiving IV thrombolytics for acute ischemic stroke and imaged both before and after 2 h of treatment, 78% of patients had complete resolution of perfusion lesions and 41% had resolution of DWI lesions.¹⁸⁵ Perfusion–diffusion imaging has been used in clinical trials to select patients for thrombolysis. Intravenous desmoplas was given only to patients with a DWI-PWI mismatch $\geq 20\%$, and the drug was found to be potentially effective in improving clinical outcomes.^{15, 16}

MR ANGIOGRAPHY

MRA techniques fall into three categories:

1. Time of flight.
 - (a) Depends on a strong signal from the blood, and the effect of flow on signal.
 - Advantage: No contrast agent is used.
 - Disadvantages: Acquisition times are relatively long and spin dephasing in areas of turbulent flow causes signal loss that may lead to overestimation of stenosis. Also, high signal from methemoglobin in a blood clot can simulate the signal from flow, making it possible to miss a thrombosed vessel with this technique.
2. Phase contrast.
 - (a) Obtains image contrast from differences in phases accumulated by stationary and moving spins in a magnetic field gradient.
 - Advantages: No contrast agent is used. Less likely to mistaken fresh clot for flowing blood as it is strictly flow-dependent.
 - Disadvantages: Dependent on flow and prone to artifact.
3. Contrast-enhanced MRA.
 - (a) Based on a combination of rapid 3D imaging and the T1-shortening effect of IV gadolinium.
 - Advantages: High signal-to-noise ratios, robustness irrespective of blood flow patterns or velocities, and fast image acquisition, allowing for the evaluation of larger anatomic segments (from the aortic arch to the circle of Willis).
 - Disadvantage: Requires IV gadolinium, which carries a small risk of complications, particularly in patients with renal insufficiency (see below).

Gadolinium and Nephrogenic Systemic Fibrosis

Gadolinium is a chemical element with an atomic number of 64. It has 7 unpaired electrons in its outer shell which hasten T1 relaxation and increase signal in the area of interest. Gadolinium alone is toxic, but not when combined with a chelating agent. Several FDA-approved gadolinium preparations are available. A study of high-dose gadolinium administration in a population with a high prevalence of baseline renal insufficiency, showed no renal failure associated with its administration.¹⁸⁶ The rate of anaphylactic reactions is also very low; in a survey of > 700,000 patients receiving gadolinium, the rate of serious allergic reactions was < 0.01% and most reactions were limited to mild nausea or urticaria.¹⁸⁷

Nephrogenic systemic fibrosis (aka nephrogenic fibrosing dermopathy) is strongly associated with gadodiamide (Omniscan™; GE Healthcare, Princeton, NJ).^{188, 189} Although most patients have a history of exposure to gadodiamide, other gadolinium-based agents have been implicated.¹⁹⁰ It appears to occur only in patients with renal insufficiency, generally in those requiring dialysis,¹⁹⁰ and is dose-dependent.¹⁸⁹ The condition consists of thickening and hardening of the skin of the extremities, due to increased skin deposition of collagen. The condition may develop rapidly and result in wheelchair-dependence within weeks. There may also be involvement of other tissue such as the lungs, skeletal muscle, heart, diaphragm, and esophagus.¹⁹¹ The mechanism is not understood. An estimate of the incidence of this syndrome comes from an internet-based medical advisory originating in Denmark, which reported that, of about 400 patients with severely impaired renal function, 5% were subsequently diagnosed with nephrogenic systemic fibrosis.¹⁹²

Management consists of correction of renal function (usually dialysis), which may result in a cessation or reversal of symptoms.¹⁹³

IDENTIFICATION OF HEMORRHAGE ON MRI

Acute hemorrhage characteristics on MRI are summarized in Table 9.8. Susceptibility-weighted imaging indicates signal loss caused by the presence of deoxyhemoglobin, and can help identify acute cerebral hemorrhage, “microbleeds,” and intravascular clot.¹⁹⁴ Asymptomatic microbleeds are caused by hypertension and amyloid angiopathy, and are found in up to 6% of elderly patients and 26% of patients with prior ischemic stroke¹⁶⁷. The finding of microbleeds in patients with acute ischemic stroke, may predict an increased risk of hemorrhage transformation after thrombolysis. In a study of patients undergoing IA thrombolysis for acute ischemic stroke, microbleeds were found in 12% of patients prior to treatment.¹⁹⁵ Symptomatic hemorrhages occurred in 20% of patients with an evidence of prior microbleeds, compared to 11% of patients without prior microbleeds.

Table 9.8 MRI signal characteristics of cerebral hemorrhage

Time since ictus (days)	Tissue characteristics	T1-weighted image	T2-weighted image	Susceptibility-weighted image
< 1	Oxyhemoglobin	Isointense to dark	Bright	Isointense to dark
1–3	Deoxyhemoglobin formation	Isointense to dark	Dark	Dark
3–7	Intracellular methemoglobin	Bright	Isointense to dark	Dark
Weeks	Cell breakdown, extracellular methemoglobin	Bright	Bright	Dark
Long term	Hemosiderin formation	Isointense, may have dark rim	Very dark rim	Dark

9.7. Appendix 2: NIH stroke scale

The National Institutes of Health Stroke Scale (NIHSS) is widely used and it provides important prognostic information.^{196–199}

A detailed description of the NIHSS can be downloaded at http://www.ninds.nih.gov/doctors/NIH_Stroke_Scale.pdf and a helpful booklet about the scale can be downloaded from http://www.ninds.nih.gov/doctors/NIH_Stroke_Scale_Booklet.pdf.

Higher scores indicate greater stroke severity (Tables 9.9 and 9.10). A score of ≥ 16 predicts a high probability of death or severe disability whereas a score of ≥ 6 predicts a good recovery.¹⁹⁹ Some 60–70% of acute ischemic stroke patients with a baseline NIHSS score < 10 will have a favorable outcome after one year, compared to only 4–16% of patients with a score > 20 .²⁰⁰

Table 9.9 NIH stroke scale

1(a) Level of consciousness	Alert	0
	Drowsy	1
	Stuperous	2
	Coma	3
1(b) LOC questions	Answers both correctly	0

(continued)

Table 9.9 (Continued)

	Answers one correctly	1
	Incorrect	2
1(c) LOC commands	Obeys both correctly	0
	Obeys one correctly	1
	Incorrect	2
2. Best gaze	Normal	0
	Partial gaze palsy	1
	Forced deviation	2
3. Visual	No visual loss	0
	Partial hemianopia	1
	Complete hemianopia	2
	Bilateral hemianopia	3
4. Facial palsy	Normal	0
	Minor paralysis	1
	Partial paralysis	2
	Complete paralysis	3
5. Motor arm	No drift	0
	Drift	1
	Some effort against gravity	2
	No effort against gravity	3
	No movement	4
	UN = Amputation or join fusion	
6. Motor leg	No drift	0
	Drift	1
	Some effort against gravity	2
	No effort against gravity	3
	No movement	4
	UN = Amputation or join fusion	
7. Limb ataxia	Absent	0
	Present in one limb	1
	Present in two limbs	2
	UN = Amputation or join fusion	
8. Sensory	Normal	0
	Mild-to-moderate sensory loss	1
	Severe to total sensory loss	2
9. Best language	No aphasia	0
	Mild-to-moderate aphasia	1
	Severe aphasia	2
	Mute, global aphasia	3
10. Dysarthria	Normal	0
	Mild-to-moderate dysarthria	1
	Severe dysarthria	2
	UN = Intubated or other physical barrier	
11. Extinction and inattention	No abnormality	0
	Visual, tactile, auditory, spatial, or personal inattention	1
	Profound hemi-inattention or extinction to more than one modality	2

Administer the stroke scale items in the order listed. Record performance in each category after each subscale exam. Each score should indicate what the patient does, not what the examiner thinks the patient can do. Source: http://www.ninds.nih.gov/doctors/NIH_Stroke_Scale.pdf

Table 9.10 NIH stroke scale score severity

Group	NIHSS score
Mild	≤ 6
Moderate	7–10
Moderately severe	11–15
Severe	15–22
Very severe	≤ 23

Source: Reference [201]

9.8. References

- Generalized efficacy of t-PA for acute stroke. Subgroup analysis of the NINDS t-PA Stroke Trial. *Stroke* 1997;28(11):2119–25
- Marler JR, Tilley BC, Lu M, et al. Early stroke treatment associated with better outcome: the NINDS rt-PA stroke study. *Neurology* 2000;55(11):1649–55
- Steiner T, Bluhmki E, Kaste M, et al. The ECASS 3-hour cohort. Secondary analysis of ECASS data by time stratification. ECASS Study Group. *European Cooperative Acute Stroke Study. Cerebrovasc Dis* 1998;8(4):198–203
- Hacke W, Donnan G, Fieschi C, et al. Association of outcome with early stroke treatment: pooled analysis of ATLANTIS, ECASS, and NINDS rt-PA stroke trials. *Lancet* 2004;363(9411):768–74
- Moser DK, Kimble LP, Alberts MJ, et al. Reducing delay in seeking treatment by patients with acute coronary syndrome and stroke: A scientific statement from the American heart association council on cardiovascular nursing and stroke council. *Circulation* 2006;114(2):168–82
- Sagar G, Riley P, Vohrah A. Is admission chest radiography of any clinical value in acute stroke patients? *Clin Radiol* 1996;51(7):499–502
- Adams HP, Jr., Adams RJ, Brott T, et al. Guidelines for the early management of patients with ischemic stroke: A scientific statement from the Stroke Council of the American Stroke Association. *Stroke* 2003;34(4):1056–83
- Manual on Contrast Media. 5.0 ed. Reston, VA: American College of Radiology; 2004
- del Zoppo GJ, Higashida RT, Furlan AJ, Pessin MS, Rowley HA, Gent M. PROACT: a phase II randomized trial of recombinant pro-urokinase by direct arterial delivery in acute middle cerebral artery stroke. PROACT investigators. *Prolyse in acute cerebral thromboembolism. Stroke* 1998;29(1):4–11
- Furlan A, Higashida R, Wechsler L, et al. Intra-arterial prourokinase for acute ischemic stroke. The PROACT II study: a randomized controlled trial. *Prolyse in Acute Cerebral Thromboembolism. JAMA* 1999;282(21):2003–11
- Eckert B, Kucinski T, Neumaier-Probst E, Fiehler J, Rother J, Zeumer H. Local intra-arterial fibrinolysis in acute hemispheric stroke: effect of occlusion type and fibrinolytic agent on recanalization success and neurological outcome. *Cerebrovasc Dis* 2003;15(4):258–63
- Davydov L, Cheng JW. Tenecteplase: a review. *Clin Ther* 2001;23(7):982–97; discussion 1
- Haley EC, Jr., Lyden PD, Johnston KC, Hemmen TM, the TNKISI. A pilot dose-escalation safety study of tenecteplase in acute ischemic stroke. *Stroke* 2005;36(3):607–12
- Liberatore GT, Samson A, Bladin C, Schleuning W-D, Medcalf RL. Vampire bat salivary plasminogen activator (desmoteplase): A unique fibrinolytic enzyme that does not promote neurodegeneration. *Stroke* 2003;34(2):537–43
- Hacke W, Albers G, Al-Rawi Y, et al. The desmoteplase in acute ischemic stroke trial (DIAS): A phase II MRI-based 9-hour window acute stroke thrombolysis trial with intravenous desmoteplase. *Stroke* 2005;36(1):66–73
- Furlan AJ, Eyding D, Albers GW, et al. Dose escalation of desmoteplase for acute ischemic stroke (DEDAS): Evidence of safety and efficacy 3–9 hours after stroke onset. *Stroke* 2006;37(5):1227–31
- Ewart MR, Hatton MW, Basford JM, Dodgson KS. The proteolytic action of Arvin on human fibrinogen. *Biochem J* 1970;118(4):603–9
- Ehrly AM. Influence of Arwin on the flow properties of blood. *Biorheology* 1973;10(3):453–6
- Becker RC, Hochman JS, Cannon CP, et al. Fatal cardiac rupture among patients treated with thrombolytic agents and adjunctive thrombin antagonists: Observations from the thrombolysis and thrombin inhibition in myocardial infarction 9 study. *J Am Coll Cardiol* 1999;33(2):479–87
- Adams HP, del Zoppo GJ, von Kummer R. Management of stroke: A practical guide for the prevention, evaluations and treatment of acute stroke. 2nd ed. Caddo, OK: Professional Communications, Inc.; 2002
- Brandt T, von Kummer R, Muller-Kupfers M, Hacke W. Thrombolytic therapy of acute basilar artery occlusion. Variables affecting recanalization and outcome. *Stroke* 1996;27(5):875–81
- Kirtan A, Wong JH, Mah J, et al. Successful endovascular therapy for acute basilar thrombosis in an adolescent. *Pediatrics* 2003;112(3 Pt 1):e248–51
- Agarwal P, Kumar S, Hariharan S, et al. Hyperdense middle cerebral artery sign: can it be used to select intra-arterial versus intravenous thrombolysis in acute ischemic stroke? *Cerebrovasc Dis* 2004;17(2–3):182–90
- Demchuk AM, Tanne D, Hill MD, et al. Predictors of good outcome after intravenous tPA for acute ischemic stroke. *Neurology* 2001;57(3):474–80
- Tissue plasminogen activator for acute ischemic stroke. The National Institute of Neurological Disorders and Stroke rt-PA Stroke Study Group. *N Engl J Med* 1995;333(24):1581–7
- Qureshi AI. New grading system for angiographic evaluation of arterial occlusions and recanalization response to intra-arterial thrombolysis in acute ischemic stroke. *Neurosurgery* 2002;50(6):1405–15
- Chesebro JH, Knatterud G, Roberts R, et al. Thrombolysis in Myocardial Infarction (TIMI) Trial, Phase I: A comparison between intravenous tissue plasminogen activator and intravenous streptokinase. Clinical findings through hospital discharge. *Circulation* 1987;76(1):142–54
- Francis CW, Blinc A, Lee S, Cox C. Ultrasound accelerates transport of recombinant tissue plasminogen activator into clots. *Ultrasound Med Biol* 1995;21(3):419–24

29. Alexandrov AV, Molina CA, Grotta JC, et al. Ultrasound-enhanced systemic thrombolysis for acute ischemic stroke. *N Engl J Med* 2004;351(21):2170-8
30. Viguier A, Petit R, Rigal M, Cintas P, Larue V. Continuous monitoring of middle cerebral artery recanalization with transcranial color-coded sonography and Levovist. *J Thromb Thrombolysis* 2005;19(1):55-9
31. Molina CA, Ribo M, Rubiera M, et al. Microbubble administration accelerates clot lysis during continuous 2-MHz ultrasound monitoring in stroke patients treated with intravenous tissue plasminogen activator. *Stroke* 2006;37(2):425-9
32. Daffertshofer M, Gass A, Ringleb P, et al. Transcranial low-frequency ultrasound-mediated thrombolysis in brain ischemia: increased risk of hemorrhage with combined ultrasound and tissue plasminogen activator: results of a phase II clinical trial. *Stroke* 2005;36(7):1441-6
33. Graham GD. Tissue plasminogen activator for acute ischemic stroke in clinical practice: A meta-analysis of safety data. *Stroke* 2003;34(12):2847-50
34. Hill MD, Lye T, Moss H, et al. Hemi-orolingual angioedema and ACE inhibition after alteplase treatment of stroke. *Neurology* 2003;60(9):1525-7
35. Hill MD, Buchan AM. Thrombolysis for acute ischemic stroke: results of the Canadian Alteplase for Stroke Effectiveness Study. *Cmaj* 2005;172(10):1307-12
36. Engelter ST, Fluri F, Buitrago-Tellez C, et al. Life-threatening orolingual angioedema during thrombolysis in acute ischemic stroke. *J Neurol* 2005;252(10):1167-70
37. Kumpke DA. Thrombolysis of Acute Stroke Syndromes. In: K. K. Aruny JE, eds. *Handbook of Interventional Radiologic Procedures*. Philadelphia: Lippincott Williams & Wilkins; 2002:47-62
38. Chopko BW, Kerber C, Wong W, Georgy B. Transcatheter snare removal of acute middle cerebral artery thromboembolism: technical case report. *Neurosurgery* 2000;46(6):1529-31
39. Kerber CW, Barr JD, Berger RM, Chopko BW. Snare retrieval of intracranial thrombus in patients with acute stroke. *J Vasc Interv Radiol* 2002;13(12):1269-74
40. Fourie P, Duncan IC. Microsnare-assisted mechanical removal of intraprocedural distal middle cerebral arterial thromboembolism. *AJNR Am J Neuroradiol* 2003;24(4):630-2
41. Wikholm G. Transarterial embolectomy in acute stroke. *AJNR Am J Neuroradiol* 2003;24(5):892-4
42. Nesbit GM, Luh G, Tien R, Barnwell SL. New and future endovascular treatment strategies for acute ischemic stroke. *J Vasc Interv Radiol* 2004;15(1):103S-10
43. Kerber CW, Wanke I, Bernard J, Jr, Woo HH, Liu MW, Nelson PK. Rapid intracranial clot removal with a new device: the alligator retriever. *AJNR Am J Neuroradiol* 2007;28(5):860-3
44. Lutsep HL, Clark WM, Nesbit GM, Kuether TA, Barnwell SL. Intraarterial suction thrombectomy in acute stroke. *AJNR Am J Neuroradiol* 2002;23(5):783-6
45. Chapot R, Houdart E, Rogopoulos A, Mounayer C, Saint-Maurice JP, Merland JJ. Thromboaspiration in the basilar artery: report of two cases. *AJNR Am J Neuroradiol* 2002;23(2):282-4
46. Nedelchev K, Remonda L, Do DD, et al. Acute stenting and thromboaspiration in basilar artery occlusions due to embolism from the dominating vertebral artery. *Neuroradiology* 2004;46(8):686-91
47. Cross DT, 3rd, Moran CJ, Akins PT, Angtuaco EE, Derdeyn CP, Diringer MN. Collateral circulation and outcome after basilar artery thrombolysis. *AJNR Am J Neuroradiol* 1998;19(8):1557-63
48. Nakayama T, Tanaka K, Kaneko M, Yokoyama T, Uemura K. Thrombolysis and angioplasty for acute occlusion of intracranial vertebrobasilar arteries. Report of three cases. *J Neurosurg* 1998;88(5):919-22
49. Mori T, Kazita K, Mima T, Mori K. Balloon angioplasty for embolic total occlusion of the middle cerebral artery and ipsilateral carotid stenting in an acute stroke stage. *AJNR Am J Neuroradiol* 1999;20(8):1462-4
50. Ringer AJ, Qureshi AI, Fessler RD, Guterman LR, Hopkins LN. Angioplasty of intracranial occlusion resistant to thrombolysis in acute ischemic stroke. *Neurosurgery* 2001;48(6):1282-90
51. Smith WS, Sung G, Starkman S, et al. Safety and efficacy of mechanical embolectomy in acute ischemic stroke: Results of the MERC1 trial. *Stroke* 2005;36(7):1432-8
52. Smith WS. Safety of mechanical thrombectomy and intravenous tissue plasminogen activator in acute ischemic stroke. Results of the multi mechanical embolus removal in cerebral ischemia (MERC1) trial, part I. *AJNR Am J Neuroradiol* 2006;27(6):1177-82
53. Layton KF, White JB, Cloft HJ, Kallmes DF. Use of the Perclose ProGlide device with the 9 French Merci retrieval system. *Neuroradiology* 2006;48(5):324-6
54. Opatowsky MJ, Morris PP, Regan JD, Mewborne JD, Wilson JA. Rapid Thrombectomy of superior sagittal sinus and transverse sinus thrombosis with a rheolytic catheter device. *AJNR Am J Neuroradiol* 1999;20(3):414-7
55. Bellon RJ, Putman CM, Budzik RF, Pergolizzi RS, Reinking GF, Norbush AM. Rheolytic thrombectomy of the occluded internal carotid artery in the setting of acute ischemic stroke. *AJNR Am J Neuroradiol* 2001;22(3):526-30
56. Molina CA, Saver JL. Extending reperfusion therapy for acute ischemic stroke: Emerging pharmacological, mechanical, and imaging strategies. *Stroke* 2005;36(10):2311-20
57. Mahon BR, Nesbit GM, Barnwell SL, et al. North American clinical experience with the EKOS MicroLysUS infusion catheter for the treatment of embolic stroke. *AJNR Am J Neuroradiol* 2003;24(3):534-8
58. Berlis A, Lutsep H, Barnwell S, et al. Mechanical thrombolysis in acute ischemic stroke with endovascular photoacoustic recanalization. *Stroke* 2004;35(5):1112-6
59. Lutsep HL. Thrombolytic and newer mechanical device treatment for acute ischemic stroke. *Expert Rev Neurother* 2006;6(7):1099-105
60. Henkes H, Reinartz J, Lowens S, et al. A device for fast mechanical clot retrieval from intracranial arteries (Phenox clot retriever). *Neurocrit Care* 2006;5(2):134-40
61. Liebig T, Reinartz J, Hannes R, Miloslavski E, Henkes H. Comparative in vitro study of five mechanical embolectomy systems: effectiveness of clot removal and risk of distal embolization. *Neuroradiology* 2008;50(1):43-52
62. Lylyk P, Vila JF, Miranda C, Ferrario A, Romero R, Cohen JE. Partial aortic obstruction improves cerebral perfusion and clinical symptoms in patients with symptomatic vasospasm. *Neuro Res* 2005;27 Suppl 1:S129-35
63. Kase CS, Furlan AJ, Wechsler LR, et al. Cerebral hemorrhage after intra-arterial thrombolysis for ischemic stroke: the PROACT II trial. *Neurology* 2001;57(9):1603-10
64. Lisboa RC, Jovanovic BD, Alberts MJ. Analysis of the safety and efficacy of intra-arterial thrombolytic therapy in ischemic stroke. *Stroke* 2002;33(12):2866-71
65. Lewandowski CA, Frankel M, Tomsick TA, et al. Combined intravenous and intra-arterial r-TPA versus intra-arterial therapy of acute ischemic stroke: Emergency Management of Stroke (EMS) Bridging Trial. *Stroke* 1999;30(12):2598-605
66. The IMSSL. Combined intravenous and intra-arterial recanalization for acute ischemic stroke: The interventional management of stroke study. *Stroke* 2004;35(4):904-11
67. Eckert B, Koch C, Thomalla G, et al. Aggressive therapy with intravenous abciximab and intra-arterial rTPA and additional PTA/stenting improves clinical outcome in acute vertebrobasilar occlusion: Combined local fibrinolysis and intravenous abciximab in acute vertebrobasilar stroke treatment (FAST): Results of a multicenter study. *Stroke* 2005;36(6):1160-5
68. Hill MD, Barber PA, Takahashi J, Demchuk AM, Feasby TE, Buchan AM. Anaphylactoid reactions and angioedema during alteplase treatment of acute ischemic stroke. *Cmaj* 2000;162(9):1281-4
69. Brandt T. Diagnosis and thrombolytic therapy of acute basilar artery occlusion: a review. *Clin Exp Hypertens* 2002;24(7-8):611-22
70. Brandt T, Knauth M, Wildermuth S, et al. CT angiography and Doppler sonography for emergency assessment in acute basilar artery ischemia. *Stroke* 1999;30(3):606-12

71. Schellinger PD, Hacke W. Intra-arterial thrombolysis is the treatment of choice for basilar thrombosis: pro. *Stroke* 2006;37(9):2436-7
72. Ford GA. Intra-arterial thrombolysis is the treatment of choice for basilar thrombosis: con. *Stroke* 2006;37(9):2438-9
73. Mactloed MR, Davis SM, Mitchell PJ, et al. Results of a multicentre, randomised controlled trial of intra-arterial urokinase in the treatment of acute posterior circulation ischaemic stroke. *Cerebrovasc Dis* 2005;20(1):12-7
74. Davis SM, Donnan GA. Basilar artery thrombosis: recanalization is the key. *Stroke* 2006;37(9):2440
75. Hacke W, Zeumer H, Ferbert A, Bruckmann H, del Zoppo GJ. Intra-arterial thrombolytic therapy improves outcome in patients with acute vertebralbasilar occlusive disease. *Stroke* 1988;19(10):1216-22
76. Wang H, Fraser K, Wang D, Alvernia J, Lanzino G. Successful intra-arterial basilar artery thrombolysis in a patient with bilateral vertebral artery occlusion: technical case report. *Neurosurgery* 2005;57(4 Suppl):E398; discussion E
77. Lindsberg PJ, Mattle HP. Therapy of basilar artery occlusion: A systematic analysis comparing intra-arterial and intravenous thrombolysis. *Stroke* 2006;37(3):922-8
78. Nesbit GM, Clark WM, O'Neill OR, Barnwell SL. Intracranial intraarterial thrombolysis facilitated by microcatheter navigation through an occluded cervical internal carotid artery. *J Neurosurg* 1996;84(3):387-92
79. Steinhubl SR, Talley JD, Braden GA, et al. Point-of-care measured platelet inhibition correlates with a reduced risk of an adverse cardiac event after percutaneous coronary intervention: results of the GOLD (AU-Assessing Ultegra) multicenter study. *Circulation* 2001;103(21):2572-8
80. Quinn MJ, Plow EF, Topol EJ. Platelet Glycoprotein IIb/IIIa Inhibitors: Recognition of a two-edged sword? *Circulation* 2002;106(3):379-85
81. Kleinman N. Assessing Platelet Function in Clinical Trials. In: Quinn M, Fitzgerald D, eds. *Platelet Function Assessment, Diagnosis, and Treatment*. Totowa, NJ: Humana Press; 2005:369-84
82. Fisher CM, Ojemann RG, Roberson GH. Spontaneous dissection of cervico-cerebral arteries. *Can J Neurol Sci* 1978;5(1):9-19
83. Fitzsimmons BFM, Beeske T, Nelson PK. Rapid stent-supported revascularization in acute ischemic stroke. *AJNR Am J Neuroradiol* 2006;27(5):1132-4
84. Kessler IM, Mounayer C, Piotin M, Spelle L, Vanzin JR, Moret J. The use of balloon-expandable stents in the management of intracranial arterial diseases: A 5-year single-center experience. *AJNR Am J Neuroradiol* 2005;26(9):2342-8
85. Kiyosue H, Okahara M, Yamashita M, Nagatomi H, Nakamura N, Mori H. Endovascular stenting for restenosis of the intracranial vertebralbasilar artery after balloon angioplasty: two case reports and review of the literature. *Cardiovasc Intervent Radiol* 2004;27(5):538-43
86. Weber J, Remonda L, Mattle HP, et al. Selective intra-arterial fibrinolysis of acute central retinal artery occlusion. *Stroke* 1998;29(10):2076-9
87. Butz B, Strotzer M, Manke C, Roeder J, Link J, Lenhart M. Selective intraarterial fibrinolysis of acute central retinal artery occlusion. *Acta Radiol* 2003;44(6):680-4
88. Arnold M, Koerner U, Remonda L, et al. Comparison of intra-arterial thrombolysis with conventional treatment in patients with acute central retinal artery occlusion. *J Neurol Neurosurg Psychiatr* 2005;76(2):196-9
89. Schmidt DP, Schulte-Monting J, Schumacher M. Prognosis of central retinal artery occlusion: local intraarterial fibrinolysis versus conservative treatment. *AJNR Am J Neuroradiol* 2002;23(8):1301-7
90. Beatty S, Au Eong KG. Local intra-arterial fibrinolysis for acute occlusion of the central retinal artery: a meta-analysis of the published data. *Br J Ophthalmol* 2000;84(8):914-6
91. Feltgen N, Neubauer A, Jurklics B, et al. Multicenter study of the European assessment group for lysis in the eye (EAGLE) for the treatment of central retinal artery occlusion: design issues and implications. EAGLE Study report no. 1. *EAGLE Study report no. 1. Graefes Arch Clin Exp Ophthalmol* 2006;244(8):950-6
92. Lorentzen SE. Incidence of cilioretinal arteries. *Acta Ophthalmol (Copenh)* 1970;48(3):518-24
93. Hayreh SS, Zimmerman MB, Kimura A, Sanon A. Central retinal artery occlusion. Retinal survival time. *Exp Eye Res* 2004;78(3):723-36
94. Schmidt D, Schumacher M, Wakhloo AK. Microcatheter urokinase infusion in central retinal artery occlusion. *Am J Ophthalmol* 1992;113(4):429-34
95. Atebara NH, Brown GC, Cater J. Efficacy of anterior chamber paracentesis and Carbogen in treating acute nonarteritic central retinal artery occlusion. *Ophthalmology* 1995;102(12):2029-34; discussion 34-5
96. Ros MA, Magargal LE, Uram M. Branch retinal-artery obstruction: a review of 201 eyes. *Ann Ophthalmol* 1989;21(3):103-7
97. Paques M, Vallee JN, Herbreteau D, et al. Supersselective ophthalmic artery fibrinolytic therapy for the treatment of central retinal vein occlusion. *Br J Ophthalmol* 2000;84(12):1387-91
98. Beatty S, Au Eong KG. Acute occlusion of the retinal arteries: current concepts and recent advances in diagnosis and management. *J Accid Emerg Med* 2000;17(5):324-9
99. Richard G, Lerche RC, Knosp V, Zeumer H. Treatment of retinal arterial occlusion with local fibrinolysis using recombinant tissue plasminogen activator. *Ophthalmology* 1999;106(4):768-73
100. Jacobs L, Kinkel WR, Heffner RR, Jr. Autopsy correlations of computerized tomography: experience with 6,000 CT scans. *Neurology* 1976;26(12):1111-8
101. Adams HP Jr., Brott TG, Crowell RM, et al. Guidelines for the management of patients with acute ischemic stroke. A statement for healthcare professionals from a special writing group of the Stroke Council, American Heart Association. *Circulation* 1994;90(3):1588-601
102. Culebras A, Kase CS, Masdeu JC, et al. Practice guidelines for the use of imaging in transient ischemic attacks and acute stroke. A report of the Stroke Council, American Heart Association. *Stroke* 1997;28(7):1480-97
103. von Kummer R, Bourquain H, Bastianello S, et al. Early prediction of irreversible brain damage after ischemic stroke at CT. *Radiology* 2001;219(1):95-100
104. Hacke W, Kaste M, Fieschi C, et al. Intravenous thrombolysis with recombinant tissue plasminogen activator for acute hemispheric stroke. The European Cooperative Acute Stroke Study (ECASS). *JAMA* 1995;274(13):1017-25
105. Aronovich BD, Reider G, II, Segev Y, Bornstein NM. Early CT changes and outcome of ischemic stroke. *Eur J Neurol* 2004;11(1):63-5
106. von Kummer R, Nolte PN, Schnitger H, Thron A, Ringelstein EB. Detectability of cerebral hemisphere ischaemic infarcts by CT within 6 h of stroke. *Neuroradiology* 1996;38(1):31-3
107. Truwit CL, Barkovich AJ, Gean-Marton A, Hibri N, Norman D. Loss of the insular ribbon: another early CT sign of acute middle cerebral artery infarction. *Radiology* 1990;176(3):801-6
108. Tomsick TA, Brott TG, Olinger CP, et al. Hyperdense middle cerebral artery: incidence and quantitative significance. *Neuroradiology* 1989;31(4):312-5
109. Barber PA, Demchuk AM, Hill MD, et al. The probability of middle cerebral artery MRA flow signal abnormality with quantified CT ischaemic change: targets for future therapeutic studies. *J Neurol Neurosurg Psychiatr* 2004;75(10):1426-30
110. Barber PA, Demchuk AM, Hudon ME, Pexman JH, Hill MD, Buchan AM. Hyperdense sylvian fissure MCA "dot" sign: A CT marker of acute ischemia. *Stroke* 2001;32(1):84-8
111. Leary MC, Kidwell CS, Villablanca JP, et al. Validation of computed tomographic middle cerebral artery "dot" sign: an angiographic correlation study. *Stroke* 2003;34(11):2636-40
112. Koga M, Saku Y, Toyoda K, Takaba H, Ibayashi S, Iida M. Reappraisal of early CT signs to predict the arterial occlusion site in acute embolic stroke. *J Neurol Neurosurg Psychiatry* 2003;74(5):649-53

113. Axel L. Cerebral blood flow determination by rapid sequence computed tomography. *Radiology* 1980;137:679-86
114. Mies G, Ishimaru S, Xie Y, Seo K, Hossmann KA. Ischemic thresholds of cerebral protein synthesis and energy state following middle cerebral artery occlusion in rat. *J Cereb Blood Flow Metab* 1991;11(5):753-61
115. Astrup J, Symon L, Branston NM, Lassen NA. Cortical evoked potential and extracellular K⁺ and H⁺ at critical levels of brain ischemia. *Stroke* 1977;8(1):51-7
116. Morawetz RB, Crowell RH, DeGirolami U, Marcoux FW, Jones TH, Halsey JH. Regional cerebral blood flow thresholds during cerebral ischemia. *Fed Proc* 1979;38(11):2493-4
117. Morawetz RB, DeGirolami U, Ojemann RG, Marcoux FW, Crowell RM. Cerebral blood flow determined by hydrogen clearance during middle cerebral artery occlusion in unanesthetized monkeys. *Stroke* 1978;9(2):143-9
118. Sakai F, Nakazawa K, Tazaki Y, et al. Regional cerebral blood volume and hematocrit measured in normal human volunteers by single-photon emission computed tomography. *J Cereb Blood Flow Metab* 1985;5(2):207-13
119. Muizelaar JP, Fatorous PP, Schroder ML. A new method for quantitative regional cerebral blood volume measurements using computed tomography. *Stroke* 1997;28(10):1998-2005
120. Nabavi DG, Cenic A, Dool J, et al. Quantitative assessment of cerebral hemodynamics using CT: stability, accuracy, and precision studies in dogs. *J Comput Assist Tomogr* 1999;23(4):506-15
121. Hatazawa J, Shimosegawa E, Toyoshima H, et al. Cerebral blood volume in acute brain infarction: A combined study with dynamic susceptibility contrast MRI and 99mTc-HMPAO-SPECT. *Stroke* 1999;30(4):800-6
122. Todd NV, Picozzi P, Crockard HA. Quantitative measurement of cerebral blood flow and cerebral blood volume after cerebral ischaemia. *J Cereb Blood Flow Metab* 1986;6(3):338-41
123. Latchaw RE, Yonas H, Hunter GJ, et al. Guidelines and recommendations for perfusion imaging in cerebral ischemia: A scientific statement for healthcare professionals by the writing group on perfusion imaging, from the Council on Cardiovascular Radiology of the American Heart Association. *Stroke* 2003;34(4):1084-104
124. Klotz E, König M. Perfusion measurements of the brain: using dynamic CT for the quantitative assessment of cerebral ischemia in acute stroke. *Eur J Radiol* 1999;30:170-84
125. Miles K. Measurement of tissue perfusion by dynamic computed tomography. *Br J Radiol* 1991;64:409-12
126. Koenig M, Klotz E, Heuser L. Perfusion CT in acute stroke: Characterization of cerebral ischemia using parameter images of cerebral blood flow and their therapeutic relevance. *Electromedica* 1998;66:61-6
127. Steiger HJ, Aaslid R, Stooss R. Dynamic computed tomographic imaging of regional cerebral blood flow and blood volume. A clinical pilot study. *Stroke* 1993;24(4):591-7
128. Hunter GJ, Hamberg LM, Ponzio JA, et al. Assessment of cerebral perfusion and arterial anatomy in hyperacute stroke with three-dimensional functional CT: early clinical results. *AJNR Am J Neuroradiol* 1998;19(1):29-37
129. Lev MH, Segal AZ, Farkas J, et al. Utility of perfusion-weighted CT imaging in acute middle cerebral artery stroke treated with intra-arterial thrombolysis: prediction of final infarct volume and clinical outcome. *Stroke* 2001;32(9):2021-8
130. Ezzeddine MA, Lev MH, McDonald CT, et al. CT angiography with whole brain perfused blood volume imaging: added clinical value in the assessment of acute stroke. *Stroke* 2002;33(4):959-66
131. Gobbel G, Cann C, Fike J. Measurement of regional cerebral blood flow using ultrafast computed tomography. Theor aspects. *Stroke* 1991;22:768-71
132. Cenic A, Nabavi DG, Craen RA, Gelb AW, Lee TY. Dynamic CT measurement of cerebral blood flow: a validation study. *AJNR Am J Neuroradiol* 1999;20(1):63-73
133. Gobbel GT, Cann CE, Fike JR. Comparison of xenon-enhanced CT with ultrafast CT for measurement of regional cerebral blood flow. *AJNR Am J Neuroradiol* 1993;14(3):543-50
134. Wintermark M, Thiran JP, Maeder P, Schnyder P, Meuli R. Simultaneous measurement of regional cerebral blood flow by perfusion CT and stable xenon CT: a validation study. *AJNR Am J Neuroradiol* 2001;22(5):905-14
135. Gillard JH, Minhas PS, Hayball MP, et al. Assessment of quantitative computed tomographic cerebral perfusion imaging with H₂(15O) positron emission tomography. *Neurol Res* 2000;22(5):457-64
136. Kudo K, Terae S, Katoh C, et al. Quantitative cerebral blood flow measurement with dynamic perfusion CT using the vascular-pixel elimination method: comparison with H₂(15O) positron emission tomography. *AJNR Am J Neuroradiol* 2003;24(3):419-26
137. Nabavi DG, Cenic A, Craen RA, et al. CT assessment of cerebral perfusion: experimental validation and initial clinical experience. *Radiology* 1999;213(1):141-9
138. Nabavi DG, Cenic A, Henderson S, Gelb AW, Lee TY. Perfusion mapping using computed tomography allows accurate prediction of cerebral infarction in experimental brain ischemia. *Stroke* 2001;32(1):175-83
139. Hamberg LM, Hunter GJ, Maynard KI, et al. Functional CT perfusion imaging in predicting the extent of cerebral infarction from a 3-hour middle cerebral arterial occlusion in a primate stroke model. *AJNR Am J Neuroradiol* 2002;23(6):1013-21
140. Roberts H. Neuroimaging techniques in cerebrovascular disease: computed tomography angiography/computed tomography perfusion. *Semin Cerebrovasc Dis Stroke* 2001;1:303-16
141. Rother J, Jonetz-Mentzel L, Fiala A, et al. Hemodynamic assessment of acute stroke using dynamic single-slice computed tomographic perfusion imaging. *Arch Neurol* 2000;57(8):1161-6
142. Koenig M, Kraus M, Theek C, Klotz E, Gehlen W, Heuser L. Quantitative assessment of the ischemic brain by means of perfusion-related parameters derived from perfusion CT. *Stroke* 2001;32(2):431-7
143. Sorensen AG. What is the meaning of quantitative CBF? *AJNR Am J Neuroradiol* 2001;22(2):235-6
144. Tomandl BF, Klotz E, Handschu R, et al. Comprehensive imaging of ischemic stroke with multislice CT. *Radiographics* 2003;23(3):565-92
145. Wintermark M, Reichhart M, Thiran JP, et al. Prognostic accuracy of cerebral blood flow measurement by perfusion computed tomography, at the time of emergency room admission, in acute stroke patients. *Ann Neurol* 2002;51(4):417-32
146. Lee KH, Cho SJ, Byun HS, et al. Triphasic perfusion computed tomography in acute middle cerebral artery stroke: a correlation with angiographic findings. *Arch Neurol* 2000;57(7):990-9
147. Mayer TE, Hamann GF, Baranczyk J, et al. Dynamic CT perfusion imaging of acute stroke. *AJNR Am J Neuroradiol* 2000;21(8):1441-9
148. Eastwood JD, Lev MH, Azhari T, et al. CT perfusion scanning with deconvolution analysis: pilot study in patients with acute middle cerebral artery stroke. *Radiology* 2002;222(1):227-36
149. Chamorro A, Sacco RL, Mohr JP, et al. Clinical-computed tomographic correlations of lacunar infarction in the Stroke Data Bank. *Stroke* 1991;22(2):175-81
150. Derex L, Tomsick TA, Brott TG, et al. Outcome of stroke patients without angiographically revealed arterial occlusion within four hours of symptom onset. *AJNR Am J Neuroradiol* 2001;22(4):685-90
151. Koroshetz WJ, Lev MH. Contrast computed tomography scan in acute stroke: "You can't always get what you want but...you get what you need". *Ann Neurol* 2002;51(4):415-6
152. Wintermark M, Flanders AE, Velthuis B, et al. Perfusion-CT Assessment of infarct core and penumbra: Receiver operating characteristic curve analysis in 130 patients suspected of acute hemispheric stroke. *Stroke* 2006;37(4):979-85

153. Wintermark M, Reichhart M, Cuisenaire O, et al. Comparison of admission perfusion computed tomography and qualitative diffusion- and perfusion-weighted magnetic resonance imaging in acute stroke patients. *Stroke* 2002;33(8):2025-31.
154. Lev MH, Nichols SJ. Computed tomographic angiography and computed tomographic perfusion imaging of hyperacute stroke. *Top Magn Reson Imaging* 2000;11(5):273-87.
155. Lev MH, Farkas J, Rodriguez VR, et al. CT angiography in the rapid triage of patients with hyperacute stroke to intraarterial thrombolysis: accuracy in the detection of large vessel thrombus. *J Comput Assist Tomogr* 2001;25(4):520-8.
156. Verro P, Tanenbaum LN, Borden NM, Sen S, Eshkar N. CT Angiography in acute ischemic stroke: Preliminary Results. *Stroke* 2002;33(1):276-8.
157. Wildermuth S, Knauth M, Brandt T, Winter R, Sartor K, Hacke W. Role of CT angiography in patient selection for thrombolytic therapy in acute hemispheric stroke. *Stroke* 1998;29(5):935-8.
158. Graf J, Skutta B, Kuhn FP, Ferbert A. Computed tomographic angiography findings in 103 patients following vascular events in the posterior circulation: potential and clinical relevance. *J Neurol* 2000;247(10):760-6.
159. Wintermark M, Meuli R, Browaeys P, et al. Comparison of CT perfusion and angiography and MRI in selecting stroke patients for acute treatment. *Neurology* 2007;68(9):694-7.
160. Li F, Silva MD, Sotak CH, Fisher M. Temporal evolution of ischemic injury evaluated with diffusion-, perfusion-, and T2-weighted MRI. *Neurology* 2000;54(3):689-96.
161. Moseley ME, Cohen Y, Mintorovitch J, et al. Early detection of regional cerebral ischemia in cats: comparison of diffusion- and T2-weighted MRI and spectroscopy. *Magn Reson Med* 1990;14(2):330-46.
162. Mullins ME, Schaefer PW, Sorensen AG, et al. CT and conventional and diffusion-weighted MR imaging in acute stroke: study in 691 patients at presentation to the emergency department. *Radiology* 2002;224(2):353-60.
163. Davis DP, Robertson T, Imbesi SG. Diffusion-weighted magnetic resonance imaging versus computed tomography in the diagnosis of acute ischemic stroke. *J Emerg Med* 2006;31(3):269-77.
164. Diffusion Imaging: From Basic Physics to Practical Imaging. RSNA, 1999. (Accessed February 17, 2007, at http://ej.rsna.org/ej3.0095_98_fin/index.htm.)
165. Lansberg MG, Thijs VN, O'Brien MW, et al. Evolution of apparent diffusion coefficient, diffusion-weighted, and T2-weighted signal intensity of acute stroke. *AJNR Am J Neuroradiol* 2001;22(4):637-44.
166. Lovblad KO, Bassetti C, Schneider J, et al. Diffusion-weighted mr in cerebral venous thrombosis. *Cerebrovasc Dis* 2001;11(3):169-76.
167. Sitburana O, Koroshetz WJ. Magnetic resonance imaging: implication in acute ischemic stroke management. *Curr Atheroscler Rep* 2005;7(4):305-12.
168. Gass A, Ay H, Szabo K, Koroshetz WJ. Diffusion-weighted MRI for the "small stuff": the details of acute cerebral ischaemia. *Lancet Neurol* 2004;3(1):39-45.
169. Baird AE, Warach S. Magnetic resonance imaging of acute stroke. *J Cereb Blood Flow Metab* 1998;18(6):583-609.
170. Schwamm LH, Koroshetz WJ, Sorensen AG, et al. Time course of lesion development in patients with acute stroke: serial diffusion- and hemodynamic-weighted magnetic resonance imaging. *Stroke* 1998;29(11):2268-76.
171. Fiehler J, Knudsen K, Kucinski T, et al. Predictors of apparent diffusion coefficient normalization in stroke patients. *Stroke* 2004;35(2):514-9.
172. Desmond PM, Lovell AC, Rawlinson AA, et al. The value of apparent diffusion coefficient maps in early cerebral ischemia. *AJNR Am J Neuroradiol* 2001;22(7):1260-7.
173. Kidwell CS, Saver JL, Mattiello J, et al. Thrombolytic reversal of acute human cerebral ischemic injury shown by diffusion/perfusion magnetic resonance imaging. *Ann Neurol* 2000;47(4):462-9.
174. Thijs VN, Somford DM, Bammer R, Robberecht W, Moseley ME, Albers GW. Influence of arterial input function on hypoperfusion volumes measured with perfusion-weighted imaging. *Stroke* 2004;35(1):94-8.
175. Rivers CS, Wardlaw JM, Armitage PA, et al. Do acute diffusion- and perfusion-weighted MRI lesions identify final infarct volume in ischemic stroke? *Stroke* 2006;37(1):98-104.
176. Barber PA, Davis SM, Darby DG, et al. Absent middle cerebral artery flow predicts the presence and evolution of the ischemic penumbra. *Neurology* 1999;52(6):1125-32.
177. Staroselskaya IA, Chaves C, Silver B, et al. Relationship between magnetic resonance arterial patency and perfusion-diffusion mismatch in acute ischemic stroke and its potential clinical use. *Arch Neurol* 2001;58(7):1069-74.
178. Seitz RJ, Meisel S, Moll M, Witsack HJ, Junghans U, Siebler M. Partial rescue of the perfusion deficit area by thrombolysis. *J Magn Reson Imaging* 2005;22(2):199-205.
179. Sobesky J, Zaro Weber O, Lehnardt FG, et al. Which time-to-peak threshold best identifies penumbral flow? A comparison of perfusion-weighted magnetic resonance imaging and positron emission tomography in acute ischemic stroke. *Stroke* 2004;35(12):2843-7.
180. Kidwell CS, Alger JR, Saver JL. Beyond mismatch: evolving paradigms in imaging the ischemic penumbra with multimodal magnetic resonance imaging. *Stroke* 2003;34(11):2729-35.
181. Sorensen AG, Copen WA, Ostergaard L, et al. Hyperacute stroke: simultaneous measurement of relative cerebral blood volume, relative cerebral blood flow, and mean tissue transit time. *Radiology* 1999;210(2):519-27.
182. Parsons MW, Yang Q, Barber PA, et al. Perfusion magnetic resonance imaging maps in hyperacute stroke: relative cerebral blood flow most accurately identifies tissue destined to infarct. *Stroke* 2001;32(7):1581-7.
183. Schaefer PW, Hunter GJ, He J, et al. Predicting cerebral ischemic infarct volume with diffusion and perfusion MR imaging. *AJNR Am J Neuroradiol* 2002;23(10):1785-94.
184. Neumann-Haefelin T, Witsack HJ, Wenserski F, et al. Diffusion- and perfusion-weighted MRI. The DWI/PWI mismatch region in acute stroke. *Stroke* 1999;30(8):1591-7.
185. Chalela JA, Kang DW, Luby M, et al. Early magnetic resonance imaging findings in patients receiving tissue plasminogen activator predict outcome: Insights into the pathophysiology of acute stroke in the thrombolysis era. *Ann Neurol* 2004;55(1):105-12.
186. Prince MR, Arnoldus C, Frisoli JK. Nephrotoxicity of high-dose gadolinium compared with iodinated contrast. *J Magn Reson Imaging* 1996;6(1):162-6.
187. Murphy KP, Szopinski KT, Cohan RH, Mermillod B, Ellis JH. Occurrence of adverse reactions to gadolinium-based contrast material and management of patients at increased risk: a survey of the American Society of Neuroradiology Fellowship Directors. *Acad Radiol* 1999;6(11):656-64.
188. Thomsen HS. Nephrogenic systemic fibrosis: A serious late adverse reaction to gadodiamide. *Eur Radiol* 2006;16(12):2619-21.
189. Collidge TA, Thomson PC, Mark PB, et al. Gadolinium-enhanced MR imaging and nephrogenic systemic fibrosis: Retrospective study of a renal replacement therapy cohort. *Radiology* 2007;245:1070353.
190. Kuo PH, Kanal E, Abu-Alfa AK, Cowper SE. Gadolinium-based MR contrast agents and nephrogenic systemic fibrosis. *Radiology* 2007;242(3):647-9.
191. Cowper SE, Boyer PJ. Nephrogenic systemic fibrosis: an update. *Curr Rheumatol Rep* 2006;8(2):151-7.
192. Stenver DI. Investigation of the safety of MRI contrast medium Omniscan. In: Danish Medicines Agency; 2006.
193. Cowper SE. Nephrogenic systemic fibrosis: the nosological and conceptual evolution of nephrogenic fibrosing dermopathy. *Am J Kidney Dis* 2005;46(4):763-5.
194. Hermier M, Nighoghossian N. Contribution of susceptibility-weighted imaging to acute stroke assessment. *Stroke* 2004;35(8):1989-94.
195. Kidwell CS, Saver JL, Villablanca JP, et al. Magnetic resonance imaging detection of microbleeds before thrombolysis: an emerging application. *Stroke* 2002;33(1):95-8.

196. Muir KW, Weir CJ, Murray GD, Povey C, Lees KR. Comparison of neurological scales and scoring systems for acute stroke prognosis. *Stroke* 1996;27(10):1817-20
197. Brott T, Adams HP, Jr., Olinger CP, et al. Measurements of acute cerebral infarction: a clinical examination scale. *Stroke* 1989;20(7):864-70
198. Goldstein LB, Bertels C, Davis JN. Interrater reliability of the NIH stroke scale. *Arch Neurol* 1989;46(6):660-2
199. Adams HP, Jr., Davis PH, Leira EC, et al. Baseline NIH stroke scale score strongly predicts outcome after stroke: A report of the Trial of Org 10172 in acute stroke treatment (TOAST). *Neurology* 1999;53(1):126-31
200. Kwiatkowski TG, Libman RB, Frankel M, et al. Effects of tissue plasminogen activator for acute ischemic stroke at one year. *N Engl J Med* 1999;340(23):1781-7
201. Wiebers DO, Feigin VL, Brown RDJ. *Handbook of Stroke*. 2nd ed. Philadelphia: Lippincott Williams & Wilkins; 2006

10. Extracranial Angioplasty and Stenting

10.1. Carotid bifurcation lesions

10.1.1. Indications and contraindications

The indications for carotid angioplasty and stenting (CAS) are in evolution. The original CAS trials and registries examined the use of CAS in patients considered to be at high risk of complications with CEA; therefore, most available clinical data on CAS is in this setting. Guidelines for CAS developed by a collaborative panel of interventional neuroradiologists (Table 10.1) emphasized that CAS be used in patients at high risk of complications with surgery. On August 30, 2004, the FDA approved the AccUNET™ embolic protection device and the Acculink™ stent (Guidant, Santa Clara, CA) for the treatment of patients at high risk for adverse events from CEA who require carotid revascularization and meet the following criteria:

1. Patients with neurological symptoms and $\geq 50\%$ stenosis of the common or internal carotid artery by ultrasound or angiogram OR patients without neurological symptoms and $\geq 80\%$ stenosis of the common or internal carotid artery by ultrasound or angiogram, and
2. Patients must have a reference vessel diameter within the range of 4.0 and 9.0mm at the target lesion.

On September 1, 2004, the Centers for Medicare and Medicaid Services (CMS) announced that CAS with EPD is reasonable and necessary and would be covered for the following patients:

1. High risk for CEA, symptomatic, $> 70\%$ (must use FDA approved device)
2. High risk, symptomatic, $> 50\%$, (and enrolled in a post-approval trial)
3. High risk, asymptomatic, $> 80\%$ (and enrolled in a post-approval trial)

Patients at high risk for CEA were defined as having significant comorbidities or anatomic risk factors (i.e., recurrent stenosis and/or previous radical neck dissection), and would be poor candidates for CEA in the opinion of a surgeon. Significant comorbid conditions included but were not limited to:

- Congestive heart failure (CHF) class III/IV;
- Left ventricular ejection fraction (LVEF) $< 30\%$;
- Unstable angina;
- Contralateral carotid occlusion;
- Recent myocardial infarction (MI);
- Previous CEA with recurrent stenosis;
- Prior radiation treatment to the neck;
- Other conditions that were used to determine patients at high risk for CEA in the prior carotid artery stenting trials and studies, such as ARCHER, CABERNET, SAPPHIRE, BEACH, and MAVERIC II.

In addition, the CMS has indicated which US facilities are eligible for reimbursement. A list of these centers is available at www.cms.hhs.gov/coverage/carotid-stent-facilities.asp (Table 10.1).

Table 10.1 Indications and contraindications for carotid angioplasty and stenting

A. Acceptable Indications for CAS
1. Symptomatic, severe stenosis that is surgically difficult to access (e.g., high bifurcation requiring mandibular dislocation)
2. Symptomatic, severe stenosis in a patient with a significant medical disease that would make the patient high risk for surgery
3. Symptomatic severe stenosis <i>and</i> one of the following conditions:
(a) Significant tandem lesion that may require endovascular therapy
(b) Radiation-induced stenosis
(c) Restenosis after CEA
(d) Refusal to undergo CEA after proper informed consent
(e) Stenosis secondary to arterial dissection
(f) Stenosis secondary to fibromuscular dysplasia
(g) Stenosis secondary to Takayasu arteritis
4. Severe stenosis associated with contralateral carotid artery occlusion requiring treatment before undergoing cardiac surgery
5. Severe underlying carotid artery stenosis revealed after recanalization of carotid occlusion after thrombolysis for acute stroke (presumed to be the etiology of the treated occlusion) or to enable thrombolysis for acute stroke
6. Pseudoaneurysm
7. Asymptomatic preocclusive lesion in a patient otherwise meeting criteria 1–3
B. Relative Contraindications
1. Asymptomatic stenosis of any degree, except in particular circumstances, as described above (A4, A6, A7)
2. Symptomatic stenosis associated with an intracranial vascular malformation
3. Symptomatic stenosis in a patient with a subacute cerebral infarction
4. Symptomatic stenosis in a patient with a significant contraindication to angiography
C. Absolute Contraindications
1. Carotid stenosis with angiographically visible intraluminal thrombus
2. A stenosis that cannot be safely reached or crossed by an endovascular approach

Definitions: *Severe stenosis* is 70% or greater diameter stenosis by NASCET measurement criteria. *Preocclusive stenosis* is 90% or greater diameter stenosis by NASCET criteria or NASCET definition of "near occlusion"¹

From: Quality Improvement Guidelines for the Performance of Cervical Carotid Angioplasty and Stent Placement: Developed by a Collaborative Panel of the American Society of Interventional and Therapeutic Neuroradiology, the American Society of Neuroradiology, and the Society of Interventional Radiology.² Reprinted with permission from the American Society of Neuroradiology

10.1.2. Patient preparation

10.1.2.1. Evaluation

1. History and physical.
2. Neurological exam.
3. Blood work (CBC, Cr, PT, PTT)
4. EKG
5. Imaging
 - (a) Baseline carotid duplex exam
 - (b) Confirmatory study (e.g. CTA, MRA, or catheter angiogram).

10.1.2.2. Preprocedure preparation

1. Antiplatelet therapy:
 - (a) Aspirin 325-mg PO QD for ≥ 3 days prior to the procedure *and*
 - (b) Clopidogrel (Plavix[®]) 75-mg PO QD for ≥ 3 days prior to the procedure.³

Or

 - (c) Aspirin 325-mg PO QD for ≥ 3 days prior to the procedure *and*
 - (d) Ticlopidine (Ticlid[®]) for ≥ 3 days prior to the procedure.⁴
 - Adverse reactions include rash, gastrointestinal side effects, neutropenia (2.4%), thrombocytopenia, aplastic anemia, and thrombotic thrombocytopenic purpura.⁵
 - Neutropenia occurs in 2.4% of patients and may appear within a few days.
 - Monitoring for neutropenia: CBC with absolute neutrophil count and peripheral smear should be done prior to initiation of therapy and every 2 weeks through the third month of therapy.
2. Alternatively, a loading dose of Aspirin 325-mg PO and clopidogrel 300-mg PO can be given the day before or at least 5 h before the procedure.
3. Place two peripheral IVs
4. Place foley catheter
5. NPO after midnight or 6 h prior to the procedure except for medications
6. Hold routine antihypertensive medications on the morning of the procedure.
7. Make sure that all devices that may be needed are available in the angio suite prior to the procedure.

10.1.3. Endovascular technique

The technique of CAS varies slightly from case to case, depending on the clinical situation. The following is a general outline of the procedure used by the authors for most patients. As with any neurointerventional procedure, the case can be divided into an *access* phase, and an *intervention* phase. In CAS, access consists of placing a guide catheter in the common carotid artery; as many patients in this setting have extensive atherosclerotic disease and a tortuous aortic arch and great vessels, a variety of techniques and devices exist to facilitate this procedure. The intervention phase involves negotiating the stenotic lesion, deployment of the embolic protection device, pre-stent angioplasty, stent deployment, post-stent angioplasty, and embolic protection device retrieval. These techniques also call for an assortment of tips and tricks to handle difficult situations.

10.1.3.1. Access phase

1. Patient is placed on the angiography table awake.
2. An abbreviated neurological exam is rehearsed with the patient prior to draping (e.g., patient is asked to say "Methodist Episcopal," show their teeth and gums, wiggle their toes, and squeeze a rubber duck (Fig. 10.1) with the hand contralateral to the carotid being treated).
3. Dorsalis pedis and posterior tibialis pulses are assessed and marked.
4. The right or left groin is prepped, draped, and infiltrated with local anesthesia.
5. A 5-French sheath is placed in the femoral artery.
6. If the use of a femoral artery closure is planned, a femoral artery angiogram is done at the beginning of the case (because a short femoral artery 5-French sheath is easier to use to do a femoral artery angiogram with than a 90-cm sheath, as will be in place at the end of the case).
7. A loading dose of IV heparin is given (70 U kg^{-1}) and 5 min later, a 1–5-mL specimen of blood for an activated clotting time (ACT) is




Fig. 10.1 Rubber Duck – Other squeaky toys may be substituted if a rubber duck is not available.

drawn from the sheath (the volume of blood required depends on the type of ACT machine used). The ACT should be kept between 250 and 300s for the duration of the procedure. Typically this may require a second IV loading dose if needed, but not more.

8. A three-vessel diagnostic angiogram is obtained using a diagnostic catheter. PA, lateral, and ipsilateral oblique angiograms are done of the target vessel and quantitative measurements of the target vessel and stenotic lesion are made. A PA and lateral intracranial angiogram with injection of contrast into the ipsilateral CCA is necessary for later comparison to check for the possibility of thromboembolism within the intracranial circulation suspected during or after the procedure.
 - (a) Optimal angiographic view of the carotid bifurcation is obtained – usually the lateral view. (Biplane imaging is best.)
 - (b) Diameters of the CCA, the ICA, the region of greatest stenosis, and the length of the lesion (that needs to be covered by the stent) should be calculated.
 - (c) Devices are selected based on these vessel measurements: Embolic protection device, pre-dilation angioplasty balloon, stent, and post-dilation angioplasty balloon.
9. The diagnostic catheter is then placed in the target CCA. An exchange-length wire is placed in the carotid system for exchange of the diagnostic catheter for a 6-F 90-cm sheath (e.g. Shuttle® sheath, Cook Inc., Bloomington, IN).
 - (a) If the ECA is widely patent and is accessible with the exchange wire without contacting the atherosclerotic plaque, then a 0.035 in. stiff 300-cm hydrophilic wire is advanced through the diagnostic catheter, and into a distal branch of the ECA, such as the internal maxillary artery or the occipital artery.
 - (b) If the ECA is occluded, or if the atherosclerotic plaque extends into the CCA for a significant degree, a stiff J wire (e.g., Amplatz Extra Stiff Guidewire 0.035 in. (Cook Inc., Bloomington, IN) can be advanced through the diagnostic catheter and positioned in the distal CCA immediately below the lesion.
10. When the stiff guidewire has been positioned, the 5-French groin sheath is exchanged, over a tapered obturator, for the 6-French 90-cm sheath. The distal end of this system is positioned approximately 2 cm proximal to the carotid bifurcation (the tip of the Shuttle may undulate up and down with each cardiac cycle; the tip should therefore be positioned at a safe distance from the lesion, yet distal enough in the common carotid to maximize stability of the shuttle, and to allow the tip of the Shuttle to be seen on the fluoroscopic image). The exchange-length wire and the obturator can be removed from the sheath together; 5–10 mL of blood should be aspirated through the RHV into a waste bowl as the wire and obturator are removed. All catheter systems are flushed continuously with heparinized saline.
 - (a) 6-French 90-cm sheath device options;
 - Shuttle® –SL Flexor® Tuohy-Borst Side-Arm Introducer Set (Cook Inc., Bloomington, IN).
 - Robust, stable sheath.
 - Tip: Remove the Tuohy-Borst valve that comes with the introducer set and replace it with a standard RHV.
 - Super Arrow-Flex® Percutaneous Sheath Introducer Set (Arrow International, Reading, PA).
 - Braided sheath, resistant to kinking if left in place after procedure.
 - Disadvantage: It can stretch if pulled back against resistance.
 - Pinnacle® Destination™ Guiding Sheath (Terumo Medical Corp., Somerset, NJ).
 - Low profile, slick.

10.1.3.2. Tips for difficult access cases

1. Femoral artery access is limited (i.e. high grade iliac or femoral artery stenosis or occlusion)
 - (a) Brachial artery approach⁶
 - (b) Angioplasty and possible stenting of the iliac or femoral artery
2. Aortic arch or great vessels are tortuous
 - (a) Use the ECA to anchor the wire.

- During the initial placement of the diagnostic catheter in the CCA, use an 0.035-in. hydrophilic wire to advance the diagnostic catheter into a branch of the ECA.
 - Then remove the wire and replace it with a stiffer exchange-length wire, such as a 0.038-in. hydrophilic wire or an Amplatz X.
 - Then exchange the diagnostic catheter for the 90-cm sheath.
 - This technique works well in the left CCA using a Simmons 2 catheter as the diagnostic catheter.
 - (b) “Tower of power” technique to add stability to the 90-cm sheath:
 - Advance an 8-F guide catheter (e.g., 8-F straight Envoy® (Cordis Neurovascular, Miami Lakes, FL) inside of an 8-F 90-cm sheath.
 - (c) Larger diameter 90-cm sheath (e.g., 7 F or 8 F) will add stability.
 - (d) Buddy wire technique.
 - Use a larger diameter 90-cm sheath (e.g., 8-F sheath) and an 0.014 or 0.018-in. wire anchored into a branch of the ECA.
 - (e) Direct percutaneous CAS.⁷
3. If you lose access to the carotid during the exchange for the 90-cm sheath, access to the common carotid artery may be obtained using a 105cm 6.5-F Slipcath® curved hydrophilic catheter (Cook Inc., Bloomington, IN) placed through the sheath. The curved catheter is used to select the origin of the common carotid, and a 0.038-in. hydrophilic wire is again placed in the common carotid or external carotid. The catheter and sheath can then be advanced into position.
 4. Tandem stenoses (e.g., atherosclerotic stenosis both at the origin of the CCA and at the bifurcation).
 - (a) CAS of the origin lesion (see below), followed by CAS of the bifurcation lesion.
 - Note: after CAS of the origin lesion, it is important to maintain wire access through the first stent. Once an ostial stent is placed, with a small amount of the stent extending into the aortic arch (as planned), it is difficult to navigate a wire through the newly placed stent. If a EPD is used during treatment of the ostial lesion, once the first stent is placed, re-capture the EPD with a retrieval catheter and then, before withdrawing the retrieval catheter, advance the 90-cm sheath (or guide catheter) over the retrieval catheter and into the CCA through the first stent.

10.1.3.3. Intervention phase

Once the guide catheter is in place, a four-stage procedure for CAS is undertaken. First, the embolic protection device is positioned. Second, pre-stent deployment angioplasty is performed to enlarge the stenotic region sufficiently to permit passage of the stent. Third, the stent is deployed; and fourth, post-stent deployment angioplasty is done, if needed, to remodel and fully expand the stent. After each step, high-resolution biplane angiograms are obtained and neurologic exams are performed to allow for prompt recognition of any changes from the patient’s baseline status.

1. Advance EPD.
 - (a) Make a roadmap
 - (b) Select a relatively straight segment of the ICA for placement of the distal protection device that will also permit the device to be at least 2–3cm distal to the lesion.
 - (c) Guide the EPD through the region of stenosis, slowly and carefully to avoid dislodging plaque.
2. Deploy EPD.
 - (a) The radio-opaque markers on the EPD should be well visualized and closely apposed to the wall of the vessel.
 - (b) The tip of the EPD wire should be in view on the fluoroscope (i.e., it should not be allowed to migrate too far into the intracranial ICA).
 - (c) Do abbreviated neurological exam.
 - (d) Do angiogram.
3. Pre-dilation angioplasty
 - (a) Objective: to open the stenotic region only enough to accommodate the stent.
 - (b) A relatively small balloon should be used – typically 2.0 or 2.5-mm diameter angioplasty balloon, and long enough to cover the plaque.
 - (c) Blood pressure cuff is placed on continuous mode during angioplasty.

- (d) A circulating nurse should be standing by to administer atropine and dopamine if necessary.
 - Pre-treat with atropine, 0.75-mg IV, for HR < -60.
 - If not pre-treated, administer atropine, 0.75-mg IV if the patient becomes bradycardic during the angioplasty.
 - Start dopamine infusion at 2–5 mcg kg⁻¹ min⁻¹ (and increase as needed to a maximum of 50 mcg kg⁻¹ min⁻¹) for a significant drop in blood pressure during angioplasty (~SBP ≥25% below baseline, or SBP <110 mmHg).
 - (e) Once the balloon is in position, inflate to nominal pressure *briefly* (for 1–2s), then deflate.
 - A brief balloon inflation is usually sufficient to “crack” the plaque while minimizing the chance of bradycardia and hypotension.
 - (f) Remove the pre-dilation angioplasty balloon.
 - (g) Do abbreviated neurological exam.
 - (h) Do angiogram.
4. Advance stent across lesion.
- (a) On the angiogram (and roadmap image), decide on the optimal position of the stent, and identify the precise location of the planned distal stent end location (i.e. where the self-expanding stent will begin deployment).
 - (b) On an *unsubtracted* angiogram image, identify bony landmarks for the stent deployment targets (e.g., middle of the body of C2) that will allow precise deployment of the stent if the patient should move and the roadmap become degraded.
 - (c) Carefully advance the stent into position.
 - The EPD position should be monitored during this maneuver.
 - (d) Do abbreviated neurological exam.
 - (e) Do angiogram.
5. Deploy stent.
- (a) Deploy smoothly and swiftly.
 - (b) Okay to cross the origin of the ECA with the stent.
 - (c) Do abbreviated neurological exam.
 - (d) Do angiogram.
6. Post-dilation angioplasty (if needed).
- (a) Objective:
 - To widen the stenotic region if the degree of stenosis after stent deployment is still significant (>30–40%).
 - To seat the stent against the vessel wall if it does not appear to be firmly apposed to the plaque and vessel wall after the initial deployment.
 - (b) The size of the angioplasty balloon is critical
 - Diameter should be smaller than the diameter of the normal portion of the ICA, to minimize the risk of bradycardia, asystole, and dissection.
 - The length of the balloon should be less than the length of the deployed stent; an angioplasty balloon longer than the stent can cause a dissection.
 - (c) Again, the blood pressure cuff is placed on continuous mode and a circulating nurse should be standing by to administer atropine and dopamine if necessary.
 - (d) Once the balloon in position, entirely within the stent, inflate to nominal pressure briefly for 1–2s, then deflate.
 - (e) Remove the balloon.
 - (f) Do abbreviated neurological exam.
 - (g) Do angiogram.
7. Retrieval of EPD.
- (a) The retrieval catheter should be advanced carefully through the stent.
 - (b) The EPD should be retrieved in a relatively straight segment of the ICA.
 - (c) Do abbreviated neurological exam.
 - (d) Do angiogram.
8. Final angiographic images are obtained.
- (a) Cervical PA and lateral, and intracranial PA and lateral angiograms.
9. The shuttle is removed.
- (a) Options for management of the femoral artery puncture site:
 - The 90-cm sheath can be exchanged over a 150-cm 0.035-in. hydrophilic wire for a closure device.

- The 90-cm sheath can be exchanged for a short sheath (of equal or greater F size), and the short sheath can be removed later (when the heparin has worn off) and a compression applied to the puncture site.
 - The 90-cm sheath can be partially withdrawn – so that only 10–20 cm remain in the femoral artery – and looped up and taped to the patient’s groin. It can be removed later, and compression applied.

10.1.3.4. Postprocedure management

1. Complete neurological exam.
2. Admit to the NICU or step-down unit with neuro exams and groin checks Q 1h.
3. Antiplatelet therapy:
 - (a) Antiplatelet therapy: Aspirin 325-mg PO QD indefinitely *and*
 - (b) Clopidogrel (Plavix[®]) 75-mg PO QD for 30 days after the procedure

Or

 - (c) Antiplatelet therapy: Aspirin 325-mg PO QD indefinitely *and*
 - (d) Ticlopidine (Ticlid[®]) for 30 days after the procedure.
 - i. Note: Must monitor for neutropenia (see above)
4. For patients with hypotension, requiring dopamine infusion:
 - (a) Hypotension after CAS is usually self-limited and resolves within 1–2 days.
 - (b) A cardiac work-up should be done to exclude an MI
 - EKG
 - Cardiac enzymes
5. Routine follow-up carotid duplex exam
 - (a) After procedure or on post-procedure day 1.
 - (b) After one month.
 - (c) After 6 months, then annually after that.

10.1.3.5. CAS tips

1. Operator experience and careful patient selection is critical. Patients with risk factors for complications with CAS (see below) should be managed by experienced operators or not treated by endovascular methods at all. Carotid endarterectomy (CEA) is still the “gold standard” for the treatment of atherosclerotic carotid stenosis.
2. Prepare all of the devices needed for the procedure before the case, immediately prior to the groin stick. Place them in a stack on the back table or at the foot of the patient’s table, with each device separated by a sterile towel in the order that they will be used (e.g., put the EPD at the top, followed by the pre-dilation balloon directly underneath, etc). This will permit rapid and efficient access to each device as it is needed.
3. Use embolic protection whenever possible.
4. Do a hand-injection angiogram after each step, to check for dissections, intraluminal thrombi, positioning of devices, and documentation. If a complication should arise during or after the case, a complete set of angiograms can help sort out and manage the problem.
5. Examine the patient after each step of the procedure (e.g., “Everything’s going fine, Mr. Smith. How are you? Wiggle your toes. Squeeze the rubber duck. Show me your teeth. Say, “Today’s a sunny day.””).
6. Do not over-dilate during angioplasty. It is better to under-size the angioplasty balloons than to over-size them, to minimize the risk of bradycardia and hypotension and also embolic complications.⁸

10.1.3.6. Tips for handling difficult CAS situations

1. The region of stenosis is too narrow to permit navigation of a distal EPD.
 - (a) May consider predilation of the lesion without distal protection, followed by placement of the EPD
 - The greatest risk of embolic events appears to occur during stent deployment.⁹ Also, emboli can even occur during passage of the EPD, even without a high grade stenosis. Therefore, careful

- predilation with a small-diameter balloon, to permit the use of a distal EPD, can be done in some cases with acceptable risk
- (b) Consider using a proximal balloon-occlusion system (e.g., MO.MA (Invatec, Roncadelle, Italy)), or a flow reversal device (e.g., Parodi Anti-Emboli System (W.L. Gore & Associates, Newark, DE)) if available.
 2. The EPD cannot be retrieved (the retrieval catheter cannot be advanced through the stent, or the EPD cannot fold up into the retrieval catheter.
 - (a) Advance the 90-cm sheath up into and through the stent, if possible
 - (b) Bring the EPD into the sheath.
 - (c) Try using a curved retrieval catheter.
 3. Carotid is too tortuous to deploy EPD
 - (a) Try tilting the patient's head toward the opposite shoulder, to straighten out the vessel
 - (b) Consider using a balloon-occlusion device (e.g., Guardwire[®] Temporary Occlusion and Aspiration System (Medtronic AVE, Santa Rosa, CA))
 4. In-stent restenosis
 - (a) Consider endovascular treatment *only if* the in-stent stenosis is symptomatic
 - CAS changes the physiology of carotid artery disease. Most strokes from carotid atherosclerosis are embolic. CAS stabilizes the plaque, and restenosis after CAS may not have the same natural history as native carotid stenosis.
 - (b) If treatment is necessary, consider using a cutting balloon.¹⁰
 5. Cryotherapy balloons are available (Polarcath[®] Boston Scientific, Natick, MA) and may reduce the rate of restenosis caused by intimal hypertrophy, but these have not been tested in the carotid or coronary circulations.

10.1.4. Risk factors for CAS complications

Patient's factors that elevate risk with CAS. Consider strategies to minimize risk in these patients or alternatives such as medical management or CEA.

1. Tortuous anatomy.
 - (a) Can impede access or positioning of the EPD.
 - (b) Interferes with stability of the devices
2. Long lesion or multiple lesions
 - (a) Plaque debris may overwhelm EPD.
3. Tandem lesions
 - (a) e.g. CCA origin stenosis and bifurcation disease
 - (b) Increases complexity of procedure
4. Ulcerated lesion
5. Bilateral carotid disease.
6. Intraluminal thrombus
 - (a) One of the two published absolute contraindications to CAS.²
7. Echolucency on carotid ultrasound (grey-scale median ≤ 25).¹¹
 - (a) Dialysis-dependent renal failure In ARChE_R, patients with dialysis-dependent renal failure had a stroke, death, and myocardial infarction rate of 28.6%.¹²
8. Absence of hypercholesterolemia.¹³

10.1.5. Management of neurological complications during or after CAS

1. Prompt recognition of a neurologic change is critical.
2. If a neurological change occurs during the case:
 - (a) Perform angiograms of the cervical carotid system and the intracranial circulation
 - (b) Look for intraluminal thrombus, intracranial vessel dropout, or slowing of contrast passage through distal intracranial vessels (indicates a *shower of emboli* into multiple small branches).
 - (c) Look for signs of dissection caused by the angioplasty balloon or a distal dissection produced by the EPD.

3. Options for thrombolysis if needed:
 - (a) IV GP IIb/IIIa inhibitor (e.g., eptifibatid or abciximab)
 - Advantages: Powerful antiplatelet agent, particularly useful for platelet-rich thrombosis, which can occur with stent deployment
 - Disadvantages: Carries a risk of ICH,¹⁴ relatively long half-life.
 - The authors prefer abciximab, which, unlike eptifibatid, can be reversed with platelet transfusion if necessary.
1. Abciximab
 - (a) Loading dose of 0.25 mg kg⁻¹, followed by a 12 h intravenous infusion at a rate of 10 µg min⁻¹.
2. Eptifibatid
 - (a) Loading dose of 135 µg kg⁻¹ followed by a 20–24-h infusion of 0.5 µg kg⁻¹.
 - (b) Intra-arterial thrombolytic (e.g., tPA or urokinase)
 - Advantage: Short half-life
 - Disadvantage: May not be as effective as a GP IIb/IIIa inhibitor if the thrombus is platelet-rich. Also carries a risk of ICH.
4. Suspect ICH:
 - (a) If angiogram does not show an occlusion to explain neurological change, or shows signs of mass-effect.
 - (b) Particularly if the patient complains of a headache, and a Cushing's response (i.e., hypertension and bradycardia) occurs.
 - (c) Obtain a head CT if an ICH is suspected; leave the sheath in place, if possible, for the trip to the scanner
 - The 90-cm sheath tip can be pulled down into the aorta and secured at the groin by looping and taping the excess sheath to the patient.
 - Include a CT perfusion study along with the non-contrast head CT, if there is no evidence of ICH
 - May identify ischemic regions, clarify diagnosis.
 - If ICH is identified:
 - Reverse heparin with protamine (10-mg IV per 1,000 units of heparin given).
 - Maintain vigilant blood pressure control.
5. *Hyperperfusion syndrome*
 - (a) Has been seen to occur in up to 5% of CAS cases;¹⁵ associated with ICH in 0.67%.¹⁶ Also a recognized complication of CEA.
 - (b) Defined as: ipsilateral headache, nausea, focal seizures, or focal neurologic deficit without radiographic evidence of infarction.
 - (c) Presumed mechanism: A chronic low blood flow state because of carotid stenosis leads to compensatory cerebral vasodilation in the affected territory, and loss of autoregulatory capacity. With carotid revascularization, an abrupt increase in CBF occurs without autoregulatory control.
 - (d) Time course: Symptoms can appear 6 h to 4 days after CAS.¹⁶
 - (e) Risk factors (derived from CEA literature):^{17, 18}
 - ICA stenosis ≥90%
 - Contralateral ICA stenosis or occlusion
 - Poor collateral flow
 - Hypertension
 - Recent cerebral ischemic event
 - Younger patient
 - (f) Management: Vigilant blood pressure control, observation.
6. Neurological change + unremarkable angiogram: Consider *transient contrast encephalopathy*.¹⁹
 - (a) Head CT: cortical enhancement and edema.
 - (b) Syndrome is self-limited; prognosis is good.
7. Post-procedure neurological change
 - (a) Some 25–30% of cerebral ischemic events with CAS occur 2–14 days after the procedure.^{13, 20}
 - (b) Work-up:
 - Head CT
 - Carotid duplex exam
 - (c) Consider return to the angio suite for a diagnostic angiogram and possible intra-arterial thrombolysis
 - Angiographic improvement has been seen in 80% of patients and clinical improvement in 40% in this setting.²⁰

8. When angiography or CT imaging does not explain a neurological change, consider MRI with diffusion-weighted imaging, which can identify subtle ischemic changes.

10.1.6. CAS pearls

1. Previously, GP IIB/IIIa inhibitors were used routinely during CAS. However, an increased risk of ICH was observed with these medications.¹⁴ The use of GP IIB/IIIa inhibitors during CAS is now reserved for select cases.
2. Pre-dilation angioplasty may reduce long-term stroke risk.²¹
 - (a) Possible mechanism: improved remodeling of the plaque prior to stent placement may stabilize the plaque.²²
3. The primary advantage of self-expanding stents for CAS, compared to balloon-mounted stents, is that self-expanding stents are less vulnerable to compression.²³
4. All filter devices have a pore size of 100 μm or larger; this may explain why the PercuSurge balloon has been found to capture significantly more particles than filter devices.^{24, 25}
5. Intraluminal thrombi are more easily seen on high speed unsubtracted angiograms (7.5 or 15 fps) than on subtracted angiograms.²⁶
6. It is not unheard of to see some spasm in the vessel distal to the stent. This will resolve spontaneously. It should be differentiated from residual stenosis not covered by the stent, or a dissection, which may require placement of a second stent to treat the residual stenosis.

10.1.6.1. Embolic protection devices

Cerebral embolization of debris and thrombotic material during CAS is a major source of morbidity during CAS. Embolic protection devices have evolved to prevent embolization during CAS. The first report of an embolic protection technique described a triple coaxial catheter with a latex balloon mounted at the distal end.²⁷ The ICA was occluded during stent placement, and debris was flushed and aspirated after stent deployment. Since then, ICA filters and flow-reversal techniques²⁸ have also been introduced. The use of embolic protection devices has been wide-spread since about 2000; filter devices are currently most commonly used.

10.1.6.2. Filter devices

The primary advantage of filter devices is the preservation of the flow through the ICA. Several devices are available. At this writing, the only FDA-approved device is the AccUNET™ (Guidant, Menlo Park, CA).

1. AccUNET™ (Guidant, Menlo Park, CA)
 - (a) Device sizes (target vessel diameter)(mm): 4.5 (3.25–4.0); 5.5 (4.0–5.0); 6.5 (5.0–6.0); 7.5 (6.0–7.0)
 - (b) Trials: ARChER, CREST, CAPTURE
 - (c) Comments: Polyurethane filter, 150- μm pore size. FDA-approved for CAS in high-risk patients.
2. FilterWire EX™ (Boston Scientific Corp, Santa Clara, CA)
 - (a) Size: One size fits all, for vessel diameter 3.5–5.5 mm
 - (b) Trials: BEACH, CABERNET
 - (c) Comments: Polyurethane filter, 110- μm pore size. Cleared for marketing in U.S. for saphenous vein grafts.
3. Angioguard™ (Cordis Corp., Minneapolis, MN)
 - (a) Device sizes (vessel diameter)(mm): 5 (3.5–4.5); 6 (4.5–5.5); 7 (5.5–6.5); 8 (6.5–7.5)
 - (b) Trials: SAPPHIRE, CASES
 - (c) Comments: Polyurethane filter, 100- μm pore size.
4. Emboshield™ (Abbott Laboratories, Abbott Park, IL)
 - (a) Device sizes (mm): 3.0, 4.0, 5.0, 6.0.
 - (b) Trials: SECURITY, EXACT
 - (c) Comments: Polyurethane filter, 140- μm pore size.
5. SpideRX™ (ev3, Irvine, CA)
 - (a) Sizes (mm): 3.0, 4.0, 5.0, 6.0, 7.0.
 - (b) Trial: CREATE II

- (c) Comments: Wire mesh filter. Design permits advancement of an 0.014-in. microwire alone across stenotic region first, then placement of EPD over the microwire. Crossing profile: 2.9 F.
- 6. Interceptor[®] PLUS (Medtronic, Inc., Santa Rosa, CA)
 - (a) Offered in sizes to fit vessel diameters from 4.25 to 6.25 mm.
 - (b) Trial: MAVERIC III
 - (c) Comments: Nitinol wire mesh filter. Crossing profile: 2.7 F. Has been commercially released to European markets.
- 7. Rubicon[®] (Rubicon Medical, Salt Lake City, UT)
 - (a) Crossing profiles: 2.1, 2.4, 2.7 F. 100- μ m pore size. Compatible with 6-F guide catheters.

10.1.6.3. Balloon-Occlusion devices

Balloon occlusion techniques involve inflation of a balloon and interruption of flow in the ICA distal to the stenosis for the duration of the stenting procedure. After CAS, aspiration of the proximal carotid system is done prior to balloon deflation remove embolic material.

1. Guardwire[®] Temporary Occlusion and Aspiration System (Medtronic AVE, Santa Rosa, CA)
 - (a) Sizes (mm): 2.5–5.0 and 3.0–6.0.
 - (b) Trials: MAVERIC I and II.
 - (c) Crossing profile: 2.8 F.
 - (d) Comments: Formally known as PercuSurge. Approved in the U.S. for saphenous vein grafts. Export[®] Catheter (Medtronic AVE, Santa Rosa, CA) is designed to be used with the Guardwire for aspiration of debris.
 - (e) Transient neurological changes have been seen in up to 5% of patient undergoing CAS with distal balloon occlusion.^{29, 30}
2. MO.MA (Invatec, Roncadelle, Italy)
 - (a) “Endovascular clamping device,” emulates surgical clamping by simultaneous endovascular occlusion of the CCA (up to 13 mm in diameter) and the ECA (up to 6 mm in diameter). Blood is aspirated during or after the CAS procedure.
 - (b) Trials: MO.MA, PRIAMUS.³¹
 - (c) Comments: Not available in the U.S.
3. Medicorp occlusive balloon (Medicorp, Nancy, France)³²
 - (a) Comments: Not available in the U.S.

10.1.6.4. Flow-Reversal device

The flow-reversal technique involves placement of balloons in the ECA and CCA to interrupt flow in these vessels and cause retrograde flow in the ICA to prevent embolization into the intracranial circulation.²⁸

1. Parodi Anti-Emboli System (W.L. Gore & Associates, Flagstaff, AZ)
 - (a) Temporarily reverses flow in the ICA during CAS. Balloons are inflated in the CCA and the ECA, and an outside connector with a filter creates an “external arteriovenous fistula” during CAS.
 - (b) Comments: Requires an 11-F sheath.
 - (c) Of all embolic protection devices, flow-reversal devices theoretically have the greatest chance of significantly reducing the cerebral blood flow during CAS, but this has not been systematically tested.

10.1.6.5. Stents

Most stents currently in use for CAS are self-expanding stents, and are available in tapered or straight designs. *Open cell* stents have struts that can extend into the lumen and can potentially interfere with passage of the EPD retrieval catheter, whereas *closed cell* stents do not have exposed struts. Selection of the stent is determined by lesion length and the normal diameter of the artery. The stent should be oversized by 1–2 mm more than the normal arterial caliber and should completely cover the lesion. At diameters less than that of full expansion, self-expanding stents exert a chronic outward radial force that serves to maintain apposition of the stent to the vessel wall after deployment. If the stent will extend from the CCA into the ICA the stent should be sized according to the larger caliber of the CCA. Tapered stents are also available to accommodate the tapering of the vessel.

1. Acculink™ (Guidant, Menlo Park, CA)
 - (a) Tapered stent diameters (proximal/distal)(mm): 10/7, 8/6.
 - (b) Tapered stent lengths (mm): 30, 40.
 - (c) Straight stent diameters (mm): 5, 6, 7, 8, 9, 10.
 - (d) Straight stent lengths (mm): 20, 30.
 - (e) Material: nitinol
 - (f) Trials: CREST, CREATE II, ARChER
 - (g) Comments: Open cell design. FDA approved.
2. Xact™ (Abbott Laboratories, Abbott Park, IL)
 - (a) Tapered stent diameters (proximal/distal)(mm): 10/8, 9/7, 8/6.
 - (b) Tapered stent lengths (mm): 30, 40.
 - (c) Straight stent diameters (mm): 7, 8, 9, 10.
 - (d) Straight stent lengths (mm): 20, 30.
 - (e) Material: nitinol.
 - (f) Trials: ACT I, SECuRITY, EXACT
 - (g) Comments: Closed cell design.
3. Precise (Cordis Neurovascular, Miami Lakes, FL)
 - (a) Tapered stent diameters: Auto-tapering
 - (b) Tapered stent lengths (mm): 20, 30, 40.
 - (c) Straight stent diameters (mm): 5, 6, 7, 8, 9, 10.
 - (d) Straight stent lengths (mm): 20, 30, 40.
 - (e) Material: nitinol
 - (f) Trials: CASES, CREATE
4. Wallstent (Boston Scientific Scimed, Maple Grove, MN)
 - (a) Straight stent diameters (mm): 6, 8, 10.
 - (b) Straight stent lengths (mm): 20, 30, 40.
 - (c) Material: stainless steel
 - (d) Trial: BEACH
 - (e) Comments: Stainless steel produces extensive artifact on MRI imaging.
5. NexStent (Endotex)
 - (a) Tapered stent diameters: self-tapering, all diameters 4–9 mm.
 - (b) Tapered stent lengths (mm): 30.
6. Exponent RX (Medtronic)
 - (a) Tapered stent diameters (proximal/distal)(mm): 10/8, 9/7, 8/6.
 - (b) Tapered stent lengths (mm): 30, 40.
 - (c) Straight stent diameters (mm): 7, 8, 9, 10.
 - (d) Straight stent lengths (mm): 20, 30.
 - (e) Material: nitinol
 - (f) Trials: MAVERIC, PASCAL
7. Vivexx (Bard Peripheral Vascular)
 - (a) Tapered stent diameters (proximal/distal)(mm): 12/8, 10/7, 8/6.
 - (b) Tapered stent lengths (mm): 30, 40.
 - (c) Straight stent diameters (mm): 5, 6, 7, 8, 9, 10, 12.
 - (d) Straight stent lengths (mm): 20, 30, 40.
 - (e) Material: nitinol
 - (f) Trial: VIVA.
8. Protege (ev3, Irvine, CA)
 - (a) Tapered stent diameters (proximal/distal)(mm): 10/7, 8/6.
 - (b) Tapered stent lengths (mm): 30, 40.
 - (c) Straight stent diameters (mm): 6, 7, 8, 9, 10.
 - (d) Straight stent lengths (mm): 20, 30, 40, 60.
 - (e) Material: nitinol
 - (f) Trial: CREATE

10.1.6.6. Carotid stenting for dissection or pseudoaneurysm

1. Indication: *Symptomatic, hemodynamically significant* carotid dissection or pseudoaneurysm despite therapy with antiplatelet agents or anticoagulation.
2. Pre-medication with antiplatelet agents is critical. In an emergency, treatment with an IV GP IIb/IIIa inhibitor can be given as a “bridge to therapy,” until an appropriate loading dose of ASA and clopidogrel has been given and allowed time to take effect (2–5 h after oral administration).
3. Use an EPD if possible

- (a) Thromboembolic material may be present in the area of dissection even if not visible on angiography.
- 4. Entire area of dissection should be covered by the stent, if possible; if not possible, then the proximal part of the dissection should be covered by the stent.
- 5. The technique is generally the same as for CAS of atherosclerotic carotid bifurcation disease, although angioplasty is not usually needed for dissections.
- 6. Be sure the guidewire and EPD is within the true lumen and not subintimal, otherwise angioplasty can make the dissection worse. If there is any question, advance a catheter distal to the dissection, do a gentle contrast injection for an arteriogram, and check that the catheter is in the true lumen and appropriate branches can be seen.

10.2. Vertebral artery lesions

This section focuses on the treatment of vertebral artery origin stenosis, as symptomatic disease attributable to extracranial vertebral artery stenosis distal to the origin is less common.

10.2.1. Extracranial vertebral artery stenosis distal to the origin

10.2.1.1. Tips

1. A CTA should be done prior to angioplasty, to exclude the presence of extrinsic factors (e.g., osteophytes).³³
2. The vertebral angiograms should be studied carefully to determine if spinal cord vessels arise near the stenotic lesion to be treated. Care must be taken to preserve these vessels and protect them from occlusion by emboli or shifting plaque. A balloon test occlusion may be helpful prior to angioplasty and stent placement if there is concern the spinal cord vessels could be at risk of occlusion.
3. A history of cervical spine manipulations and VBI symptoms should raise suspicion of vertebral artery injury.³⁴
4. If VBI symptoms occur with rotation of the head to one side, think *Bow Hunter's Stroke Syndrome* (aka rotational VBI):
 - (a) Characterized by occlusion or stenosis of the vertebral artery at C1–C2 with head rotation
 - (b) Usually caused by extrinsic compression of the vertebral artery, such as by osteophytes, a fibrous band,³⁵ or a cervical disk herniation.³⁶
 - (c) Associated with a hypoplastic vertebral artery ending in PICA.³⁷
 - (d) Consider surgical decompression.^{38–40}

10.2.2. Indications

1. Symptoms of VBI (must include at least two of the following symptoms):⁴¹
 - (a) Motor or sensory symptoms
 - (b) Dysarthria
 - (c) Imbalance
 - (d) Dizziness or vertigo
 - (e) Tinnitus
 - (f) Alternating paresthesias
 - (g) Homonymous hemianopia
 - (h) Diplopia
 - (i) Other cranial nerve palsies
 - (j) Dysphagia
2. Although traditionally vertigo or dizziness in the absence of other symptoms has not been regarded as indicative of VBI, recent evidence suggests that the opposite is true.⁴²

3. MRI evidence of ischemic injury to the posterior circulation.
4. $\geq 50\%$ stenosis of the vertebral artery by CTA, angiography, or MRA.
5. Hypoplasia or stenosis affecting the contralateral vertebral artery.

10.2.3. Contraindication

Intraluminal thrombus.

10.2.4. Patient preparation

Same as for carotid bifurcation lesions (see above).

10.2.5. Endovascular technique (vertebral artery origin lesions)

The technique for treating vertebral artery origin stenoses is similar to the technique for treating carotid bifurcation lesions, however, the critical difference is that balloon-expandable stents are preferred, as these stents allow more precise deployment than self-expanding stents, and are less prone to watermelon-seed.

1. Patient is placed on the angiography table awake.
2. An abbreviated neurological exam is rehearsed with the patient prior to draping. Exam should include posterior circulation elements (e.g., visual fields, extraocular movements, facial symmetry).
3. Access may be undertaken from the femoral artery; however, an ipsilateral upper extremity approach (i.e., radial artery or brachial artery) may be more favorable, depending on the patient's anatomy.
 - (a) 6-F or 7-F sheath. 4 or 5 F might be sufficient if a low-profile coronary stent is being used.
4. A diagnostic angiogram should be done, including the ipsilateral subclavian artery and vertebral artery. Angiography of the contralateral vertebral artery can help clarify distal vertebrobasilar anatomy.
5. A loading dose of IV heparin is given (70 U kg^{-1}) and 5 min later, a 1–5-mL specimen of blood for an ACT is drawn from the sheath. The ACT should be kept between 250 and 300 s for the duration of the procedure. Typically this may require a second IV loading dose if needed, but not more.
6. A 6-F guide catheter is placed in the subclavian artery adjacent to the vertebral artery.
 - (a) The guide catheter can be stabilized if necessary by the passage of a 0.014 or 0.018-in. buddy wire into the ipsilateral axillary artery.
 - (b) Wire: 0.035-in. or larger
 - (c) Requires a larger guide catheter.
7. Advance and deploy embolic protection device (EPD) if possible.
 - (a) Use an EPD if:⁴³
 - Vertebral artery diameter is $> 3.5 \text{ mm}$
 - Ulcerated target lesion.
 - (b) Deploy EPD in a straight segment of the cervical vertebral artery $\geq 2 \text{ cm}$ distal to lesion.
 - (c) Do abbreviated neurological exam.
 - (d) Do angiogram.
8. Pre-dilation angioplasty
 - (a) Objective: to open the stenotic region only enough to accommodate the stent.
 - (b) A relatively small balloon should be used – typically 2.0 or 2.5-mm angioplasty balloon, and long enough to cover the plaque. Once the balloon is in position, inflate to nominal pressure, then deflate.
 - Inflation of the balloon for a minute or more is necessary to “crack” the plaque while minimizing the chance of bradycardia and hypotension.
 - (c) Remove the pre-dilation angioplasty balloon.
 - (d) Do abbreviated neurological exam.
 - (e) Do angiogram.

9. Advance stent across lesion.
 - (a) Measure the diameter of the normal-appearing vertebral artery distal to the lesion and select a stent matched to that diameter, and long enough to both cross the region of stenosis, extend into the subclavian artery by 2–3 mm, and extend distal to the lesion by 3–5 mm.
 - (b) On the angiogram (and roadmap image), decide on the optimal position of the stent, and identify the precise location of the planned distal stent end location (i.e. where the self-expanding stent will begin deployment). The stent should extend just barely into the subclavian artery.
 - Failure to position the stent so that it extends into the subclavian artery increases the risk of recurrent stenosis. (The stenosis can “watermelon-seed” the stent: displace it distally into the vessel beyond the stenosis.)
 - (c) On an *unsubtracted* angiogram image, identify bony landmarks for the stent deployment targets (e.g., transverse process of C7 – check this) that will allow precise deployment of the stent if the patient should move and the roadmap become degraded.
 - (d) Carefully advance the stent into position.
 - The EPD position should be monitored during this maneuver.
 - (e) Do abbreviated neurological exam.
 - (f) Do angiogram.
10. Deploy stent.
 - (a) Inflate the balloon to nominal pressure and allow it to stay inflated for 10–15 s if possible, to seat the stent.
 - (b) Deflate the balloon.
 - (c) Do abbreviated neurological exam.
 - (d) Do angiogram.
11. Post-dilation angioplasty (if needed).
 - (a) Objective:
 - To widen the stenotic region if the degree of stenosis after stent deployment is still significant.
 - To seat the stent against the vessel wall if it does not appear to be firmly apposed to the plaque after the initial deployment.
12. Retrieval of EPD.
 - (a) The retrieval catheter should be advanced carefully through the stent.
 - (b) The EPD should be retrieved in a relatively straight segment of the vertebral artery.
 - (c) Do abbreviated neurological exam.
 - (d) Do angiogram.
13. Final angiographic images are obtained.
 - (a) Cervical PA intracranial PA and lateral angiograms.
14. Note: Obtaining access to the distal vertebral artery can be difficult once the stent is placed (because the stent extends into the brachial artery). If access to the distal vertebral artery is needed (e.g., for treatment of a tandem stenosis), wire-access to the vertebral artery should be preserved until all procedures are completed.
 - (a) Technique:
 - Retrieve the EPD with the EPD retrieval catheter, but keep the EPD retrieval catheter in the vertebral artery, distal to the stent.
 - Use the EPD retrieval catheter like a guidewire to navigate the guide catheter into position directly adjacent to the mouth of the stent.
 - Advance a guidewire through the stent and into the distal vertebral artery.
 - Remove the EPD retrieval catheter.

10.3. Carotid artery origin lesions

10.3.1. Indications

1. Symptomatic stenosis $\geq 50\%$ by CTA, angiography, or MRA.
2. Significant CCA origin stenosis in tandem with a distal carotid artery lesion for which endovascular treatment is planned.

10.3.2. Contraindication

Intraluminal thrombus.

10.3.3. Patient preparation

Same as for carotid bifurcation lesions (see above).

10.3.4. Endovascular technique

The technique for treating CCA origin stenoses is similar to the technique for treating vertebral artery origin lesions. Balloon-expandable stents are preferred, as these stents allow more precise deployment than self-expanding stents, and are less prone to watermelon-seed. Begin by following steps

1. Patient is placed on the angiography table awake.
2. An abbreviated neurological exam is rehearsed with the patient prior to draping.
3. Dorsalis pedis and posterior tibialis pulses are assessed and marked.
4. The right or left groin is prepped, draped, and infiltrated with local anesthesia.
5. A 5-F sheath is placed in the femoral artery.
6. A diagnostic angiogram should be done, including aortic arch images.
7. A loading dose of IV heparin is given (see above section under Carotid Bifurcation Lesions, *Access Phase*).
8. A 90-cm 6-F sheath is placed in the aortic arch or innominate artery adjacent to the CCA (for technique see above section under Carotid Bifurcation Lesions, *Access Phase*).
 - (a) The 90-cm sheath can be stabilized if necessary by passage of a buddy wire into the right axillary artery.
 - Wire: 0.035 in. or larger
 - Requires a larger 90-cm sheath.
9. Advance and deploy EPD.
 - (a) Deploy EPD in a straight segment of the CCA ≥ 2 cm distal to lesion, but only if the vessel is appropriate for the rated size of the EPD. If the CCA diameter is too large, the EPD may be deployed in the internal carotid.
 - (b) Do abbreviated neurological exam.
 - (c) Do angiogram.
10. Pre-dilation angioplasty
 - (a) Objective: to open the stenotic region only enough to accommodate the stent.
 - (b) A relatively small balloon should be used – typically 2.0 or 2.5 mm angioplasty balloon, and long enough to cover the plaque. Once the balloon is in position, inflate to nominal pressure *briefly* (for 1–2 s), then deflate.
 - A brief balloon inflation is usually sufficient to “crack” the plaque while minimizing the chance of bradycardia and hypotension.
 - (c) Remove the pre-dilation angioplasty balloon.
 - (d) Do abbreviated neurological exam.
 - (e) Do angiogram.
11. Advance stent across lesion.
 - (a) Measure the diameter of the normal-appearing CCA distal to the lesion and select a stent matched to that diameter, and long enough to both cross the region of stenosis and extend into the carotid artery by 1–2 mm.
 - (b) On the angiogram (and roadmap image), decide on the optimal position of the stent, and identify the precise location of the planned distal stent end location. The stent should extend 1–2 mm into the innominate artery or aortic arch.
 - (c) Carefully advance the stent into position.
 - The EPD position should be monitored during this maneuver.
 - (d) Do abbreviated neurological exam.
 - (e) Do angiogram.
12. Deploy stent.
 - (a) Inflate the balloon to nominal pressure and allow it to stay inflated for 10–15 s if possible, to deploy and seat the stent.
 - (b) Deflate the balloon.

- (c) Do abbreviated neurological exam.
 - (d) Do angiogram.
13. Post-dilation angioplasty (if needed).
- (a) Objective:
 - To widen the stenotic region if the degree of stenosis after stent deployment is still significant.
 - To seat the stent against the vessel wall if it does not appear to be firmly apposed to the plaque after the initial deployment.
14. Retrieval of EPD.
- (a) The retrieval catheter should be advanced carefully through the stent.
 - (b) The EPD should be retrieved in a relatively straight segment of the CCA.
 - (c) Do abbreviated neurological exam.
 - (d) Do angiogram.
15. Final angiographic images are obtained.
- (a) Cervical PA intracranial PA and lateral angiograms.
16. Note: Obtaining access to the distal carotid artery can be difficult once the stent is placed (because the stent extends into the aortic arch or innominate artery). If access to the distal carotid artery is needed, wire-access to the CCA should be preserved until all procedures are completed.
- (a) Technique:
 - Retrieve the EPD with the EPD retrieval catheter, but keep the EPD retrieval catheter in the CCA, distal to the stent.
 - Use the EPD retrieval catheter like a guidewire to navigate the guide catheter into a position directly adjacent to the mouth of the stent.
 - Advance a guidewire through the stent and into the distal CCA or ECA.
 - Remove the EPD retrieval catheter.

10.4. References

1. Beneficial effect of carotid endarterectomy in symptomatic patients with high-grade carotid stenosis. North American Symptomatic Carotid Endarterectomy Trial Collaborators. *N Engl J Med* 1991;325(7):445-53.
2. Barr JD, Connors JJ, III, Sacks D, et al. Quality improvement guidelines for the performance of cervical carotid angioplasty and stent placement: developed by a collaborative panel of the American Society of Interventional and Therapeutic Neuroradiology, the American Society of Neuroradiology, and the Society of Interventional Radiology. *AJNR Am J Neuroradiol* 2003;24(10):2020-34.
3. Gruber L, Beyar R. Optimized combination of antiplatelet treatment and anticoagulation for percutaneous coronary intervention: the final word is not out yet! [letter; comment]. *J Invasive Cardiol* 2002;14(5):251-3.
4. Schleinitz MD, Olkin I, Heidenreich PA. Cilostazol, clopidogrel or ticlopidine to prevent sub-acute stent thrombosis: a meta-analysis of randomized trials. *Am Heart J* 2004;148(6):990-7.
5. Bennett CL, Kiss JE, Weinberg PD, et al. Thrombotic thrombocytopenic purpura after stenting and ticlopidine. *Lancet* 1998;352(9133):1036-7.
6. Al-Mubarak N, Vitek JJ, Iyer SS, New G, Roubin GS. Carotid stenting with distal-balloon protection via the transbrachial approach. *J Endovasc Ther* 2001;8(6):571-5.
7. Perez-Arjona EA, DelProsto Z, Fessler RD. Direct percutaneous carotid artery stenting with distal protection: technical case report. *Neurol Res* 2004;26(3):338-41.
8. Sadato A, Satow T, Ishii A, Ohta T, Hashimoto N. Use of a large angioplasty balloon for predilation is a risk factor for embolic complications in protected carotid stenting. *Neurol Med Chir (Tokyo)* 2004;44(7):337-42; discussion 43.
9. Al-Mubarak N, Roubin GS, Vitek JJ, Iyer SS, New G, Leon MB. Effect of the distal-balloon protection system on microembolization during carotid stenting. *Circulation* 2001;104(17):1999-2002.
10. Tamberella MR, Yadav JS, Bajzer CT, Bhatt DL, Abou-Chebl A. Cutting balloon angioplasty to treat carotid in-stent restenosis. *J Invasive Cardiol* 2004;16(3):133-5.
11. Biasi GM, Froio A, Diethrich EB, et al. Carotid plaque echolucency increases the risk of stroke in carotid stenting: the imaging in carotid angioplasty and risk of stroke (ICAROS) study. *Circulation* 2004;110(6):756-62.
12. Wholey M. ARChER trial: prospective clinical trial for carotid stenting in high surgical risk patients-preliminary 30-day results. In: American College of Cardiology Annual Meeting, Chicago, IL; 2003.
13. Qureshi AI, Luft AR, Janardhan V, et al. Identification of patients at risk for periprocedural neurological deficits associated with carotid angioplasty and stenting. *Stroke* 2000;31(2):376-82.
14. Qureshi AI, Saad M, Zaidat OO, et al. Intracerebral hemorrhages associated with neurointerventional procedures using a combination of antithrombotic agents including abciximab. *Stroke* 2002;33(7):1916-19.
15. Meyers PM, Higashida RT, Phatouros CC, et al. Cerebral hyperperfusion syndrome after percutaneous transluminal stenting of the craniocervical arteries. *Neurosurgery* 2000;47(2):335-45.
16. Abou-Chebl A, Yadav JS, Reginelli JP, Bajzer C, Bhatt D, Krieger DW. Intracranial hemorrhage and hyperperfusion syndrome following carotid artery stenting: risk factors, prevention, and treatment. *J Am Coll Cardiol* 2004;43(9):1596-601.
17. Ouriel K, Shortell CK, Illig KA, Greenberg RK, Green RM. Intracerebral hemorrhage after carotid endarterectomy: incidence, contribution to neurologic morbidity, and predictive factors. *J Vasc Surg* 1999;29(1):82-7; discussion 7-9.
18. Sharigia E, Speziale F, Giannoni MF, Colonna M, Panicò MA, Fiorani P. Post-carotid endarterectomy hyperperfusion syndrome: preliminary observations for

- identifying at risk patients by transcranial Doppler sonography and the acetazolamide test. *Eur J Vasc Surg* 1993;7(3):252-6.
19. Dangas G, Monsein LH, Laureno R, et al. Transient contrast encephalopathy after carotid artery stenting. *J Endovasc Ther* 2001;8(2):111-13.
 20. Wholey MH, Wholey MH, Tan WA, et al. Management of neurological complications of carotid artery stenting. *J Endovasc Ther* 2001;8(4):341-53.
 21. Bossiers M, Peeters P, Deloose K, et al. Does carotid artery stenting work on the long run: 5-year results in high-volume centers (ELOCAS Registry). *J Cardiovasc Surg* 2005;46(3):241-7.
 22. Wholey MH. What's new in carotid artery stenting. *J Cardiovasc Surg* 2005;46(3):189-92.
 23. Wholey MH, Wholey MH, Tan WA, Eles G, Jarmolowski C, Cho S. A comparison of balloon-mounted and self-expanding stents in the carotid arteries: immediate and long-term results of more than 500 patients. *J Endovasc Ther* 2003;10(2):171-81.
 24. Reimers B, Corvaja N, Moshiri S, et al. Cerebral protection with filter devices during carotid artery stenting. *Circulation* 2001;104(1):12-15.
 25. Macdonald S, Venables GS, Cleveland TJ, Gaines PA. Protected carotid stenting: safety and efficacy of the MedNova NeuroShield filter. *J Vasc Surg* 2002;35(5):966-72.
 26. Vitek JJ, Roubin GS, Al-Mubarek N, New G, Iyer SS. Carotid artery stenting: technical considerations. *AJNR Am J Neuroradiol* 2000;21(9):1736-43.
 27. Theron J, Courtheoux P, Alachkar F, Bouvard G, Maiza D. New triple coaxial catheter system for carotid angioplasty with cerebral protection. *AJNR Am J Neuroradiol* 1990;11(5):869-77.
 28. Parodi JC, Schonholz C, Ferreira LM, Mendaro E, Ohki T. "Seat belt and air bag" technique for cerebral protection during carotid stenting. *J Endovasc Ther* 2002;9(1):20-4.
 29. Whitlow PL, Lylyk P, Londero H, et al. Carotid artery stenting protected with an emboli containment system. *Stroke* 2002;33(5):1308-14.
 30. Henry M, Henry I, Klonaris C, et al. Benefits of cerebral protection during carotid stenting with the PercuSurge GuardWire system: midterm results. *J Endovasc Ther* 2002;9(1):1-13.
 31. Coppi G, Moratto R, Silingardi R, et al. PRIAMUS - proximal flow blockage cerebral protection during carotid stenting: results from a multicenter Italian registry. *J Cardiovasc Surg* 2005;46(3):219-27.
 32. Henry M, Amor M, Klonaris C, et al. Angioplasty and stenting of the extracranial carotid arteries. *Tex Heart Inst J* 2000;27(2):150-8.
 33. Cagnie B, Barbaix E, Vinck E, D'Herde K, Cambier D. Extrinsic risk factors for compromised blood flow in the vertebral artery: anatomical observations of the transverse foramina from C3 to C7. *Surg Radiol Anat* 2005:1-5.
 34. Cagnie B, Jacobs F, Barbaix E, Vinck E, Dierckx R, Cambier D. Changes in cerebellar blood flow after manipulation of the cervical spine using Technetium 99m-ethyl cysteinate dimer. *J Manipulative Physiol Ther* 2005;28(2):103-7.
 35. Mapstone T, Spetzler RF. Vertebrobasilar insufficiency secondary to vertebral artery occlusion from a fibrous band. Case report. *J Neurosurg* 1982;56(4):581-3.
 36. Vates GE, Wang KC, Bonovich D, Dowd CF, Lawton MT. Bow hunter stroke caused by cervical disc herniation. Case report. *J Neurosurg* 2002;96(1 Suppl):90-3.
 37. Frisoni GB, Anzola GP. Vertebrobasilar ischemia after neck motion. *Stroke* 1991;22(11):1452-60.
 38. Hanakita J, Miyake H, Nagayasu S, Nishi S, Suzuki T. Angiographic examination and surgical treatment of bow hunter's stroke. *Neurosurgery* 1988;23(2):228-32.
 39. Shimizu T, Waga S, Kojima T, Niwa S. Decompression of the vertebral artery for bow-hunter's stroke. Case report. *J Neurosurg* 1988;69(1):127-31.
 40. Matsuyama T, Morimoto T, Sakaki T. Comparison of C1-2 posterior fusion and decompression of the vertebral artery in the treatment of bow hunter's stroke. *J Neurosurg* 1997;86(4):619-23.
 41. Charbel F, Guppy K, Carney A, Ausman J. Extracranial vertebral artery disease. In: Winn H, ed. *Youmans Neurological Surgery*, Fifth edn. Philadelphia, PA: Saunders; 2004:1691-714.
 42. Kumar A, Mafee M, Dobben G, Whipple M, Pieri A. Diagnosis of vertebrobasilar insufficiency: time to rethink established dogma? *Ear Nose Throat J* 1998;77(12):966-9, 72-4.
 43. Wehman JC, Hanel RA, Guidot CA, Guterman LR, Hopkins LN. Atherosclerotic occlusive extracranial vertebral artery disease: indications for intervention, endovascular techniques, short-term and long-term results. *J Interv Cardiol* 2004;17(4):219-32.

11. Endovascular Treatment of Intracranial Stenosis and Vasospasm

This chapter discusses techniques for intracranial angioplasty and stenting for atherosclerotic arterial stenosis, and angioplasty and intra-arterial drug infusion for cerebral vasospasm after aneurysmal SAH.

11.1. Intracranial atherosclerotic stenosis

11.1.1. Indications for intracranial angioplasty and stenting

Position Statement on Intracranial Angioplasty and Stenting for Cerebral Atherosclerosis by the ASITN, SIR, and ASNR^{*,1}:

1. For symptomatic patients with >50% intracranial stenosis who have failed medical therapy, balloon angioplasty with or without stenting should be considered.
2. Patients who have an asymptomatic intracranial arterial stenosis should first be counseled regarding optimizing medical therapy. There is insufficient evidence to make definite recommendations regarding endovascular therapy in asymptomatic patients with severe intracranial atherosclerosis. They should be counseled regarding the nature and extent of their disease, monitored for new neurological symptoms, and have periodic noninvasive imaging at regular intervals of 6–12 months (MRA or CTA) initially, and later with cerebral angiography if warranted. Optimal prophylactic medical therapy should be instituted, which might include antiplatelet and/or statin therapy.
3. Continued evaluation and improvements in both pharmacological and catheter-based therapies are needed to reduce the possibility of stroke from intracranial atherosclerosis.

11.1.2. Contraindications

1. Patient inability to have antiplatelet therapy and/or anticoagulation.
2. Highly calcified lesions or anatomy which prevent endovascular access.

11.1.3. Patient preparation

11.1.3.1. Evaluation

1. History and physical.
2. Neurological exam.
3. Blood work (CBC, Cr, PT, PTT).
4. EKG.
5. Imaging:
 - (a) Brain CT or MRI.
 - (b) Brain vascular study (CTA, MRA, or catheter angiogram).

* ASITN, American Society of Interventional and Therapeutic Neuroradiology; SIR, Society of Interventional Radiology; and ASNR, American Society of Neuroradiology.

- (c) CBF study (e.g., PET, xenon CT with acetazolamide challenge, or SPECT) can confirm diagnosis of intracranial hemodynamic failure and identify cerebral territories at risk of ischemic injury.

11.1.3.2. Preprocedure preparation

1. Antiplatelet therapy:
 - (a) Aspirin 325 mg PO QD for ≥ 3 days prior to the procedure *and*
 - (b) Clopidogrel (Plavix[®]) 75 mg PO QD for ≥ 3 days prior to the procedure.²

Or

 - (c) Aspirin 325 mg PO QD for ≥ 3 days prior to the procedure *and*
 - (d) Ticlopidine (Ticlid[®]) for ≥ 3 days prior to the procedure³:
 - Adverse reactions include rash, gastrointestinal side effects, neutropenia (2.4%), thrombocytopenia, aplastic anemia, and thrombotic thrombocytopenic purpura.⁴
 - Neutropenia occurs in 2.4% of patients and may appear within a few days.
 - Monitoring for neutropenia: CBC with absolute neutrophil count and peripheral smear should be done prior to initiation of therapy every 2 weeks through the third month of therapy.
2. Alternatively, a loading dose of Aspirin 325 mg PO and clopidogrel 300 mg PO can be given the day before or at least 5 h before the procedure.
3. Place two peripheral IVs.
4. Place foley catheter.
5. NPO after midnight or 6 h prior to the procedure except for medications.
6. Ensure all devices required are available in the angio suite prior to the procedure.

11.1.4. Endovascular technique

The access phase involves placing a guide catheter in the internal carotid or vertebral artery. The intervention phase includes advancing a microwire across the stenotic lesion, followed by angioplasty with or without stent deployment.

11.1.4.1. Awake or asleep?

Intracranial angioplasty can be uncomfortable, as stretching and pulling on intracranial vessels are painful. Although the authors of this handbook use general anesthesia in most cases, good results are obtained without anesthesia. The avoidance of anesthesia permits continuous neurological surveillance and eliminates anesthesia-associated risks:

1. Patients who are awake should rehearse the neurological exam on the angio suite table prior to draping. A squeeze toy should be placed in the patient's hand contralateral to the side being treated.
2. In a report of 37 intracranial angioplasty and stenting cases without general anesthesia, technical success was achieved in all patients.⁵ About 61% experienced intra-procedural symptoms that led to some alteration of the interventional technique. Headache was the most common symptom, and, when persistent, signaled the occurrence of intracranial hemorrhage.

11.1.4.2. Access phase

Patients with intracranial atherosclerosis are also prone to extracranial disease. The reader is referred to Chap. 10, *Extracranial Angioplasty and Stenting* for a detailed discussion of access techniques and tips for difficult situations. Compared to other intracranial procedures, angioplasty procedures require extra-rigid guide catheter support:

1. The patient is placed on the angiography table and placed under general anesthesia, if anesthesia is planned.
2. Dorsalis pedis and posterior tibialis pulses are assessed and marked.
3. The right or left groin is prepped, draped, and infiltrated with local anesthesia.
4. A 6 French sheath is placed in the femoral artery:

- (a) A 7 or (rarely, 8 French) sheath should be used if arterial monitoring through the sheath is planned.
5. An angiogram is done using a diagnostic catheter. Angiograms of the access vessel (carotid or vertebral artery) and PA and lateral views of the intracranial circulation are taken prior to the intervention.
- (a) Examination of the carotid or vertebral artery is necessary for guide catheter selection and also to check the presence of atherosclerosis and fibromuscular dysplasia.
- (b) Before and after intracranial images are necessary for comparison and to assess for thromboembolic complications.
6. Systemic anticoagulation. Thromboembolic complications can occur during angioplasty, when there is slowing of flow in the parent vessel caused by the guide catheter, or in the target vessel by the microwire or angioplasty balloon.
- (a) A loading dose of IV heparin is given (70 U kg^{-1}) and 5 min later, a 5 mL specimen of blood for an activated clotting time (ACT) is drawn from the sheath. The guide catheter is placed in the ICA or vertebral artery only after the heparinization is therapeutic (usually 5 min or more after the IV loading dose is given, or after the ACT has been found to be in the target range). The ACT should be kept for 250–300 s for the duration of the procedure. Additional doses of heparin are necessary only for cases lasting several hours.
- (b) Protamine on standby – *Critical*:
A syringe containing enough protamine to reverse the total amount of heparin the patient has received should be kept on the back table for easy access to the operator, should hemorrhage occur:
- Dose of protamine required to reverse heparin: 10 mg protamine/1,000 U heparin.
7. Guide catheter selection:
- (a) The authors prefer to use one of two guide catheters, depending on the situation:
- Neuron™ Intracranial Access System (Penumbra, Inc., San Leandro, CA).
 - Advantages: Extremely soft and flexible; able to be positioned within the distal intracranial ICA or vertebral artery.
 - Disadvantages: Less stable than other catheters, very slippery. Can be pushed out of the access vessel if the catheter is not in a distal-enough position. Only the distal tip is radiopaque; the radiolucent shaft can be difficult to see on fluoroscopy.
 - Guider Softip™ XF guide catheter (Boston Scientific, Natick, MA):
 - Advantages: Soft, atraumatic tip. Minimizes risk of vasospasm and dissection in narrow, tortuous vessels.
 - Disadvantages: Relatively flimsy, prone to fall into the arch when the vasculature is tortuous.
 - Envoy® (Cordis Neurovascular, Miami Lakes, FL):
 - Advantages: Relatively rigid, provides a good platform in tortuous vessels, large internal lumen.
 - Disadvantages: Stiff, sharp-edged tip.
- (b) Guide catheter size:
- The guide catheter should be 90 cm long (and not longer) for use with the Wingspan stent system.
 - 6 French for most cases.
 - 5 French if the vessel caliber is small and collateral circulation is limited:
 - e.g., for use in a small vertebral artery when the contralateral vessel is hypoplastic.
 - Disadvantage: Angiograms with a microcatheter or balloon in place are more difficult to obtain because of limited space within the guide catheter.
- (c) Straight or angled?
- Straight guide catheter is useful in relatively straight vessels, or in situations where the guide catheter is gently navigated through a convoluted vessel:
 - Usually requires exchanging (see below).
 - Preferred for the vertebral artery.

- Angled guide catheter is useful when the final position of the catheter tip is in a vessel curve:
 - Angled catheters are easier to navigate through the aortic arch than straight catheters.
 - (d) Alternative guide catheters:
 - 6 French 90 cm Cook Shuttle® (Cook, Inc., Bloomington, IN):
 - Very large, stable platform.
 - See Chap. 10 for technique.
 - 6 French Northstar® Lumax® Flex Catheter (Cook, Inc., Bloomington, IN):
 - Device contour consists of a smooth, tapered transition between the guidewire, inner dilator, and catheter, which minimizes trauma to vessel walls.
 - Disadvantages:
 - (a) Very stiff.
 - (b) Extremely lubricious (may cause the catheter to slide out of vessels).
8. Guide catheter placement technique:
- (a) Direct navigation method:
 - Useful in patients with nontortuous, nonatherosclerotic vessels.
 - An angled Guide catheter is gently navigated into the carotid or vertebral artery over a 0.035 or 0.038 in. hydrophilic wire.
 - (b) Exchange method:
 - Useful in patients with tortuous anatomy, atherosclerosis, or fibromuscular dysplasia. This technique minimizes risk of injury to the carotid or vertebral artery, particularly at the vessel origin.
 - A 5 French diagnostic catheter is guided into the CCA or vertebral artery over an exchange-length (300 cm) wire.
 - The tip of the wire is advanced into a distal branch of the ECA or the distal extracranial vertebral artery (usually the first 90° turn of the vessel at C2) using road mapping technique.
 - The diagnostic catheter is then gently removed while the tip of the hydrophilic wire is continuously visualized on fluoroscopy.
 - The hydrophilic wire is wiped down with a dripping-wet Telfa sponge.
 - The guide catheter is advanced over the wire while continuously visualizing the tip of the wire.
 - (c) Guide catheter position:
 - Guide catheter support is more important for intracranial angioplasty procedures than most other intracranial interventions. Angioplasty balloons and stents are relatively rigid and difficult to navigate; forward motion of these devices can cause unexpected high amounts of downward-directed force on the guide catheter. Therefore, due caution may be observed in guiding catheter selection and positioning.
 - Carotid system. Using road mapping, the guide catheter is advanced over a hydrophilic wire into the ICA as distally as possible. A “high position” of the guide catheter maximizes stability of the guide and improves control over the microcatheter and micro-wire. In a nontortuous, healthy carotid system, the authors prefer to position the tip of the guide catheter in the vertical segment of the petrous ICA. In a cervical ICA with a significant curve in the vessel, the guide can be adequately positioned immediately proximal to the curve. Moderate curves in the vessel can be straightened out by guiding a relatively stiff hydrophilic wire (e.g., a 0.038 in. wire) through the affected segment, followed by the catheter.
 - Vertebral artery. Using road mapping, the guide catheter is positioned in the distal extracranial vertebral artery, usually at the first curve (at C2).
 - Once the catheter is in position, a gentle injection of contrast through the guide catheter under fluoroscopy is done, to examine the configuration of the vessel around the tip and to check for the presence of vasospasm or vessel dissection around the tip. If catheter tip-induced vasospasm is present and flow-limiting, withdrawal of the catheter tip by several millimeters is often sufficient to restore flow.

- The catheter tip may slide up and down and rub against the vessel wall with each heart beat; this is to be taken into account when positioning the catheter.
9. Guide catheter irrigation:
 - (a) Continuous irrigation of the guide with heparinized saline (5,000 U heparin per 500 mL saline) is important.
 - (b) Meticulous care is necessary throughout the operation to guide catheter RHV to identify thrombus or bubbles, should they appear.
 10. Tips to minimize guide catheter-induced vasospasm:
 - (a) Withdraw the catheter into a lower segment of the vessel when significant catheter-induced vasospasm appears.
 - (b) Keep the catheter tip away from kinks and bends in the vessel if possible.
 - (c) Use a smaller guide catheter.
 - (d) Use a soft-tipped guide catheter (e.g., Guider Softip™ XF guide catheter (Boston Scientific, Natick, MA)).
 - (e) Use Visipaque™ (GE Healthcare, Princeton, NJ) contrast instead of Omnipaque; according to the manufacturer, this contrast material is less spasmogenic than Omnipaque®.
 - (f) Use a guide catheter with an inner obturator (e.g., Northstar® Lumax® Flex Catheter (Cook, Inc., Bloomington, IN)).
 - (g) Use nitroglycerin paste on the patient's neck ipsilateral to the access vessel:
 - Dose: 1–5 in.
 - Efficacy is unclear; however nitroglycerin paste has been reported to improve cerebral vasospasm after subarachnoid hemorrhage.⁶
 - Drawback: Can cause hypotension and headache in awake patients. In patients under general anesthesia, the dose (i.e., the number of inches) of paste is adjusted to maintain blood pressure within normal limits.
 - (h) Selective injection of IA nitroglycerin (30 mcg per injection):
 - This can help distinguish vasospasm from vessel dissection, if a dissection is suspected.

11.1.4.3. Intervention phase

Once the guide catheter is in position, a good “working view” must be obtained. The working view should be under high magnification and demonstrate the target lesion and distal vessels, and guide the catheter clearly. In most situations, a microcatheter is advanced through the stenotic intracranial vessel over an exchange-length microwire. The purpose of the microcatheter is to facilitate atraumatic and smooth passage of the microwire into a distal vessel; the microcatheter is then removed and the balloon is guided over the microwire into position within the region of stenosis. If stenting is planned, the “pre-dil” balloon is removed and the stent, either a self-expanding (e.g., Wingspan™ (Boston Scientific, Natick, MA)) or a balloon-mounted stent is navigated into position and the stent is deployed.

11.1.4.4. Device selection

Essential devices for intracranial angioplasty include an exchange-length microwire, a microcatheter, and a balloon. The Wingspan™ Stent System with Gateway™ PTA Balloon Catheter (Boston Scientific, Natick, MA) has been specifically designed for intracranial angioplasty and stenting. It has been recently introduced and is available on a Humanitarian Device Exemption basis; the use of the Wingspan system currently requires IRB approval. The Wingspan devices and technique are discussed in detail in a separate section below.

1. Microwires:
 - (a) “Beefiness,” trackability and torque control are microwire properties that are most important for intracranial angioplasty. A relatively soft distal tip is helpful as well, to minimize the chances of distal vessel vasospasm and perforation.
 - (b) The authors preferred microwire for most cases:
 - Transend™ 0.014 in. 300 cm Floppy Tip (Boston Scientific, Inc., Natick, MA):
 - Superior torque control, compared to other microwires.

- Heightened radiopacity makes the tip easy to see on fluoroscopy.
 - X-Celerator™ 0.014 in. 300 cm (ev3, Irvine, CA):
 - Soft tip, relatively supportive body, very lubricious.
2. Microcatheters:
 - (a) A low profile, straight microcatheter, usually of any kind, is sufficient.
 - (b) The 1.7 French Echelon-10 microcatheter (ev3, Irvine, CA) can be pushed through tortuous and stenotic vessels better than other microcatheters.
 3. Angioplasty balloons:
 - (a) Noncompliant coronary angioplasty balloons are designed to create sufficient radial force to dilate vessels thickened by atherosclerotic plaque. NC: noncompliant:
 - Selected balloons:
 - Gateway™ PTA Balloon Catheter (to be used with the Wingspan stent – see below).
 - Maverick™ Monorail™ Balloon Catheter (Boston Scientific, Natick, MA).
 - NC Ranger™ Balloon Catheter (Boston Scientific, Natick, MA).
 - NC Raptor™ (Cordis, Miami, FL).
 - (b) Size:
 - The diameter of the balloon should correspond to or be smaller than the normal diameter of the vessel; 2.0–2.5 mm diameter balloons are usually appropriate.
 - The length of the balloon should be kept to a minimum, to optimize trackability.
 4. Stents:
 - (a) Wingspan (see below).
 - (b) Balloon-mounted stents are problematic in intracranial circulation, as they are fairly rigid and difficult to track in tortuous vessels. More importantly, the intracranial arteries, which float freely in CSF, are not surrounded by fibrous connective tissue like coronary arteries and they are more vulnerable to dissection and perforation during deployment of balloon-mounted stents. Relatively high complication rates have been reported with balloon-mounted stents.^{5,7,8} The introduction of the Wingspan stent has made balloon-mounted stents nearly obsolete for intracranial stenting procedures:
 - If a balloon-mounted stent must be used, cobalt–chromium coronary stents are the easiest to deliver compared to other balloon-mounted stents.⁵

11.1.4.5. Angioplasty without stent deployment

Angioplasty alone is less morbid than angioplasty and stenting with balloon-expandable stent. By itself, angioplasty is a reasonable option for patients with symptomatic intracranial stenosis, particularly because intracranial stenting has not yet been shown to reduce the risk of stroke, and the use of a stent (even the Wingspan system) adds complexity and expense to the procedure. The balloon should be sized to cover the length of the lesion, and the diameter should be \leq the normal diameter of the vessel. Refer to Wingspan Gateway angioplasty procedure, described below, for a discussion of technique.

11.1.4.6. Balloon-Expandable stent deployment

The use of balloon-expandable stents in the intracranial circulation is associated with relatively high complication rates^{5,7,8} and should be avoided if possible. Balloon-expandable stents are appropriate in selected cases, when the Wingspan system is not available, such as symptomatic intracranial stenotic lesions that do not respond to angioplasty alone, or intracranial dissections.

11.1.4.7. Wingspan procedure

The manufacturer of the Wingspan™ Stent System with Gateway™ PTA Balloon Catheter has obtained a Humanitarian Device Exemption from the United States

FDA. The system is authorized for use in improving cerebral artery lumen diameter in patients with intracranial atherosclerotic disease, refractory to medical therapy, in intracranial vessels with $\geq 50\%$ stenosis that are accessible to the system. An IRB approval is currently necessary to use the system.

1. Devices:

- (a) Guide catheter should be ≥ 6 French and ≤ 90 cm long, to accommodate the Wingspan system.
- (b) Microwire. Transend™ 0.014 in. 300 cm Floppy Tip (Boston Scientific, Inc., Natick, MA) is the recommended microwire.
- (c) Gateway™ PTA Balloon Catheter:
 - The Gateway is a modified version of the Maverick^{2™} Balloon Catheter, with silicone coating on the balloon and hydrophilic coating on the catheter to facilitate access. Radio-opaque markers on the balloon permit visualization of the proximal and distal ends of the balloon on fluoroscopy.
 - Available sizes:
 - Balloon diameters (mm): 1.5, 2.0, 2.25, 2.75, 3.0, 3.25, 3.5, 3.75, 4.0.
 - Balloon lengths (mm): 9, 15, 20.
 - Nominal inflation pressure: 6 atm. Rated burst pressure: 12 atm. (14 atm. for 2.25–3.25 mm diameters only).
 - Size selection:
 - Plan angioplasty to achieve approximately 80% of normal vessel diameter. For example, for a vessel with a 3.0 mm normal diameter, angioplasty to produce a diameter of about 2.4 mm would be appropriate.
 - If the target vessel has different diameters proximal and distal to the lesion, size the balloon to the smaller of the two.
 - Preparation:
 - Use 50/50 mixture of contrast in heparinized saline.
 - Prepare the insufflator and attach it with a three-way stopcock and an empty 20 mL syringe to the balloon catheter.
 - Apply suction to the balloon but do not pre-inflate it.
 - Continuously flush through the lumen of the balloon catheter with heparinized saline via a stopcock and a rotating hemostatic valve.
- (d) Wingspan™ Stent:
 - The Wingspan is a 3.5 French nitinol over-the-wire (OTW) self-expanding stent. The design is very similar to the Neuroform^{2™} stent (Boston Scientific, Natick, MA); it has four platinum markers at each end for visualization, and is deployed from the delivery microcatheter (called the “outer body”) with the “inner body”; the inner body is analogous to the “stabilizer” device which is used to deploy Neuroform stents.
 - Available sizes:
 - Stent diameters (mm): 2.5, 3.0, 3.5, 4.0, 4.5.
 - Stent lengths (mm): 9, 15, 20.
 - Size selection:
 - Select a stent length which extends a minimum of 3 mm on both sides of the lesion.
 - If the target vessel has different diameters proximal and distal to the lesion, size the stent to the larger of the two.
 - After deployment, the stent may shorten up to 2.4% in 2.5 mm stents and up to 7.1% in 4.5 mm stents.⁹
 - Preparation
 - The Wingspan system should be flushed with heparinized saline, as indicated in the diagram on the package.
 - The more flushes, the better. Continuous flushes with heparinized saline should be connected via stopcocks and RHVs to both the Wingspan deployment catheter (the “outer body”) and the inner body.
 - The tapered tip of the inner body should be loosened slightly, with about 1 mm of space between the spearhead-shaped tip of the inner body and the distal end of the outer body, to allow adequate flushing and prevent “corking,” or binding of the inner body tip to the outer body catheter. During flushing,

heparinized saline should be seen dripping from the inner lumen and from between the inner and outer bodies.

2. Technique:

(a) Angioplasty:

- The Gateway balloon may be taken up primarily, over a nonexchange-length microwire, if the anatomy is favorable. Alternatively, an exchange-length microwire can be advanced into a distal intracranial vessel within a microcatheter, which can be exchanged for the Gateway balloon.
- After flushing, advance the balloon catheter over the microwire into the guide catheter. When positioned at the RHV, a marker on the balloon catheter shaft indicates the guide catheter tip. This feature saves fluoro time.
- With roadmap guidance, advance the balloon until the balloon markers are across the lesion. Perform a guide catheter angiogram with the balloon in position, to confirm proper positioning.
- Inflate the balloon slowly to nominal pressure, at a rate of ~1 atm./10 s, under fluoroscopy. When the balloon is fully inflated, leave it up for another 10–20 s and then deflate. Do a guide catheter angiogram prior to removing the balloon.
- In most cases a single inflation will be sufficient. Occasionally, a second inflation, at a slightly higher pressure (e.g., 8 atm.) is helpful.

(b) Stent deployment:

- Tighten the RHV on the inner body to prevent its migration – and advance the outer body of the Wingspan system over the exchange-length microwire:
 - The delivery system should be advanced only by grasping the outer body, to avoid inadvertently advancing the inner body and prematurely deploying the stent.
- Advance the outer body slightly past the region of stenosis.
- Using the marker bands to identify the position of the stent, advance the inner body just proximal to the stent.
- Pull back on the outer body, to bring the outer body tip into position just past the region of stenosis; this should be the final maneuver prior to stent deployment.
- Deploy the stent by holding the inner body in a stable position with the right hand, while, with the left hand, slowly withdraw the outer body.
 - Do not attempt to change the position of the stent during deployment.
- Once the stent is deployed, bring the deployment system into the proximal part of the vessel, or into the guide catheter, while leaving the microwire in position. Do a guide catheter angiogram.

3. Gateway and Wingspan tips⁵:

- (a) Do not over tighten the RHV around the balloon catheter shaft.
- (b) If the balloon is difficult to inflate, remove it and use another device.
- (c) If the balloon watermelon-seeds (i.e., slips forward or backward during inflation)
 - Apply gentle traction to the balloon catheter during inflation, to stabilize the balloon and prevent it from migrating distally during inflation, or
 - Select a longer balloon.
- (d) If the stent system binds with the microwire during navigation through tortuous vessels:
 - Affirm that adequate flush is being applied to both the inner and outer body catheters.
 - Try a softer microwire (e.g., Synchro2[®]-14, Boston Scientific, Natick, MA).
- (e) Keep in mind that the tapered tip of the inner body extends for 10–12 mm past the distal tip of the outer body, and is radiolucent (in contrast to the Neuroform system, which does not have anything that extends out of the deployment catheter). Care should be taken to avoid jamming the distal end of the system into a curving vessel.
- (f) Once the stent catheter is advancing over the microwire, advantage may be taken of the forward momentum and tracking continued to a site distal to the lesion. It is easier to move the system from distal to proximal than vice versa.

- (g) If the stent is malpositioned during deployment, consider placing a second stent.

11.1.4.8. Postprocedure management

1. Complete neurological exam.
2. Admit to the NICU or step-down unit with neuro exams and groin checks Q 1h.
3. Antiplatelet therapy:
 - (a) Antiplatelet therapy: Aspirin 325 mg PO QD indefinitely *and*
 - (b) Clopidogrel (Plavix[®]) 75 mg PO QD for ≥ 30 days after the procedure:
 - Note: Some operators maintain patients on dual antiplatelet therapy for 3–6 months, longer than is usually done for cervical carotid or Neuroform stent cases. Cardiologists are recently moving toward longer periods of dual antiplatelet treatment (3, 6, or 12 months) after coronary angioplasty and stenting.¹⁰ It can be argued that atherosclerotic intracranial arteries are similar in size and pathology to similarly-diseased coronary arteries.

Or

 - (c) Antiplatelet therapy: Aspirin 325 mg PO QD indefinitely *and*
 - (d) Ticlopidine (Ticlid[®]) for 30 days after the procedure:
 - Note: Monitor for neutropenia.
4. Most patients can be discharged from the hospital postprocedure day 1 or 2.

11.1.4.9. Intracranial angioplasty tips

1. Operator experience and careful patient selection is critical. No Class I data exists yet to show that intracranial angioplasty and stenting is beneficial to patients; therefore, the odds must be stacked in the patient's favor. Patients undergoing intracranial angioplasty should be managed by experienced operators or not treated by endovascular methods at all.
2. All devices needed for the procedure are to be prepared before the case, immediately prior to the groin stick and placed in a stack on the back table or at the foot of the patient's table, with each device separated by a sterile towel in the order that they will be used. This will permit rapid and efficient access to each device as required.
3. A hand-injection angiogram has to be done after each step, to check for contrast extravasation, dissection, intraluminal thrombi, positioning of devices, and documentation. If a complication should arise during or after the case, a complete set of angiograms can help sort out and manage the problem.
4. If the patient is awake, a brief neurological exam after each step of the procedure has to be completed.
5. Overdilation during angioplasty should be avoided. It is better to undersize the angioplasty balloons than to oversize them.
6. In-stent restenosis:
 - (a) Consider endovascular treatment *only if* the in-stent stenosis is symptomatic.
 - (b) If treatment is necessary, consider doing a redo angioplasty with or without another stent.

11.1.5. Management of intracranial complications during or after intracranial angioplasty

1. Prompt recognition of a change is critical.
2. If an abrupt change in blood pressure or heart rate occurs, or if a neurological change occurs in an awake case:
 - (a) Obtain AP and lateral intracranial angiograms.
 - (b) Look for contrast extravasation and other signs of vessel perforation (such as a wire tip in the wrong location) intraluminal thrombus, intracranial vessel dropout, or slowing of contrast passage through distal intracranial vessels (indicates a shower of emboli into multiple small branches).

- (c) Look for signs of dissection caused by devices.
- 3. Options for thrombolysis if needed:
 - (a) IV GP IIb/IIIa inhibitor (e.g., eptifibatid or abciximab):
 - Advantages: Powerful antiplatelet agent, particularly useful for platelet-rich thrombosis, which can occur with stent deployment.
 - Disadvantages: Carries a risk of ICH,¹¹ relatively long half-life.
 - The authors prefer abciximab, which, unlike eptifibatid, can be reversed with platelet transfusion if necessary:
 - Abciximab: Loading dose of 0.25 mg kg⁻¹, followed by a 12-h intravenous infusion at a rate of 10 µg min⁻¹.
 - Eptifibatid: Loading dose of 135 µg kg⁻¹ followed by a 20–24 h infusion of 0.5 µg kg⁻¹ min⁻¹.
 - (b) Intra-arterial thrombolytic (e.g., tPA or urokinase):
 - Advantage: Short half-life.
 - Disadvantage: May not be as effective as a GP IIb/IIIa inhibitor if the thrombus is platelet-rich. Also carries a risk of ICH.
- 4. Intracranial hemorrhage:
 - (a) Suspect a hemorrhage if sudden hypertension or bradycardia occurs, or if the patient complains of a headache.
 - (b) Do an angiogram – look for contrast extravasation.
 - (c) If ICH is identified:
 - Reverse heparin with protamine (10 mg IV per 1,000 units of heparin given).
 - Maintain tight blood pressure control.
 - Platelet transfusion (to reverse antiplatelet medications).
 - (d) Obtain a head CT; leave the sheath in place for the trip to the scanner.
- 5. Postprocedure neurological change:
 - (a) Obtain head CT.
 - (b) Consider return to the angio suite for a diagnostic angiogram and possible intra-arterial thrombolysis.
- 6. When angiography or CT imaging does not explain a neurological change, consider MRI with diffusion-weighted imaging, which can identify subtle ischemic changes.

11.2. Endovascular treatment of cerebral vasospasm

11.2.1. Indications for endovascular treatment of cerebral vasospasm

1. New onset of a neurologic change not due to other causes.
2. Radiographic evidence of ischemia due to vasospasm in a brain territory that corresponds to the neurologic deficit, with or without prior treatment with hyperdynamic therapy:
 - (a) Some operators advocate a trial of hyperdynamic therapy for vasospasm prior to performing angioplasty,¹² while others prefer to do angioplasty on an emergent basis.¹³
 - (b) In contrast to treatment of acute ischemic stroke, evidence of infarction on CT is *not necessarily* a contraindication to treatment:
 - In a series of 17 cases in which angioplasty was done despite a CT scan showing a new hypodensity, there was no hemorrhages or worsening of symptoms.¹⁴ There was resolution of the CT hypodensities in 5 of the 17 patients and a majority of the patients improved clinically.
3. *Balloon angioplasty* is an option for symptomatic vasospasm affecting intracranial arteries >1.5 mm in diameter,¹⁵ such as the intracranial ICA, the M1, A1, and the vertebral and basilar arteries and P1 segments.

4. *Intra-arterial injection of pharmacologic agents* is an option for vessels that are not accessible or safely treatable with a balloon, such as distal ACA or MCA branches, or the A1 segment (which can be difficult to reach with a balloon).

11.2.1.1. Awake or asleep?

Symptomatic vasospasm typically manifests as confusion and a decline in the level of consciousness, making it difficult for patients to cooperate with an endovascular procedure. General anesthesia makes the procedure easier and safer. A practical alternative to general anesthesia is to intubate the patient prior to the procedure (usually in the Neuro ICU) and place him or her on a mechanical ventilator with chemical paralysis and continuous analgesia and sedation.

11.2.2. Techniques

11.2.2.1. Access phase

The procedure for carotid or vertebral artery access for vasospasm is nearly identical to that used for angioplasty for atherosclerotic intracranial stenosis as seen above. Several issues pertinent to treatment of vasospasm are:

1. Speed. Endovascular treatment of vasospasm is a variant of endovascular treatment of acute ischemic stroke – see Chap. 9, *Thrombolysis for Acute Ischemic Stroke* – therefore treatment should proceed as swiftly as possible. For example, if general anesthesia is planned but not quickly available, the patient can be brought to the angio suite, prepped, and groin access obtained while anesthesia is arranged.
2. Guide catheter positioning depends on whether balloon angioplasty is planned, or if IA drug infusion only is anticipated. Balloon angioplasty requires the guide catheter be placed as high as possible, for maximal support, whereas drug infusion through a microcatheter can be accomplished with the guide catheter in a relatively low position.
3. Use of systemic heparin:
 - (a) Systemic heparinization can be used in selected patients, but is associated with theoretical increased risk of hemorrhage in postcraniotomy patients:
 - Procedural anticoagulation with systemic heparinization can be done safely in SAH patients with a ventriculostomy.^{16,17}
 - Systemic heparinization in patients with a recent craniotomy carries a 1.8% risk of major hemorrhage.¹⁸
 - (b) Systemic heparin should be reserved for cases in which there is guide catheter-induced interruption of antegrade flow in the access vessel, or a relatively long period of interruption of flow in an intracranial vessel due to the microcatheter or angioplasty balloon:
 - A loading dose of IV heparin is given (70 U kg^{-1}) and 5 min later, a 5 mL specimen of blood for an activated clotting time (ACT) is drawn from the sheath. The ACT should be kept between 250 and 300 s for the duration of the procedure.

11.2.2.2. Balloon angioplasty

1. Device selection:
 - (a) There are two views about the kind of balloon to use to treat vasospasm, i.e., compliant or noncompliant balloons. The arguments for and against each kind of device are summarized in Table 11.1. Good results have been obtained with either device¹⁹; the authors of this handbook are evenly divided in their preference:
 - Compliant balloons:
 - HyperGlide™ (ev3, Irvine, CA):
Available sizes: 4 × 10 mm; 4 × 15 mm; 4 × 20 mm; 4 × 30 mm.
 - HyperForm™ (ev3, Irvine, CA):

Table 11.1 Balloon selection for angioplasty for vasospasm

Advantages	Disadvantages
Compliant balloons	
<ul style="list-style-type: none"> • More easily placed in small, tortuous vessels 	<ul style="list-style-type: none"> • The diameter of the balloon varies greatly with the amount of inflation. Overdilation and rupture of the vessel is a greater threat than with noncompliant balloons
<ul style="list-style-type: none"> • Balloon and catheter are softer and less traumatic to vessels 	
<ul style="list-style-type: none"> • Smaller, softer microwires are less likely to traumatize or perforate the vessel 	
<ul style="list-style-type: none"> • Balloon can be inflated and deflated repeatedly, since it deflates completely. (Noncompliant balloons get “krinkly” after one inflation) 	<ul style="list-style-type: none"> • Lower inflation pressure may require multiple inflations to adequately dilate the target vessel. Occasionally, the low pressure balloon will not adequately open the affected vessel
<ul style="list-style-type: none"> • With slow, careful, low pressure inflation, the balloon gently teases open the vessel 	
<ul style="list-style-type: none"> • Single-lumen balloons, such as the Hyperglide and Hyperform, can be deflated quickly and easily by withdrawing the wire (Note: the balloon cannot be reinflated after it is deflated by pulling back on the wire) 	
Noncompliant balloons	
<ul style="list-style-type: none"> • If appropriately sized for the target vessel, they will be less likelihood of overdilation and/or rupture of the vessel, since they reach the nominal size and then stop inflating 	<ul style="list-style-type: none"> • Heavier, bulkier, and more rigid than compliant balloons
<ul style="list-style-type: none"> • They are used with a 0.014 in. microwire, which provides more torquability and support than smaller wires 	<ul style="list-style-type: none"> • They require a heavier microwire for support, which may carry a greater risk of vessel injury or perforation
<ul style="list-style-type: none"> • Because they are difficult to navigate into small distal vessels, angioplasty is usually limited to larger proximal vessels, where one is less likely to face problems 	<ul style="list-style-type: none"> • Noncompliant balloons get “krinkly” after one inflation, increasing possibility of vessel injury when maneuvering a balloon that has already been inflated and deflated

Available sizes: 4 × 7 mm; 7 × 7 mm.

- For most cases the HyperGlide™ 4 × 10 mm balloon is most suitable.
 - **Microwires:**
 - (a) X-pedion™ 0.010 in. microwire (ev3, Irvine, CA). This wire comes with the HyperGlide balloon and is useful in most cases.
 - (b) Synchro2®-10 (Boston Scientific, Natick, MA). This wire is more steerable than the X-pedion and has an added advantage of being slightly smaller, so that slow contrast leakage will occur from the balloon when it is inflated, which helps prevent overinflation of the balloon.
 - **Noncompliant balloons:**
 - Maverick™ Monorail™ Balloon Catheter (Boston Scientific, Natick, MA).
 - (a) A wide range of sizes are available; the 1.5 × 9 mm and the 2.0 × 9 mm sizes are most suitable.
 - NC Ranger™ Balloon Catheter (Boston Scientific, Natick, MA).
 - NC Raptor™ (Cordis, Miami, FL).
2. Compliant balloon technique with the HyperGlide system:
- (a) Preparation:
 - Attach the HyperGlide balloon catheter to an RHV and flush with 50/50 contrast in heparinized saline.

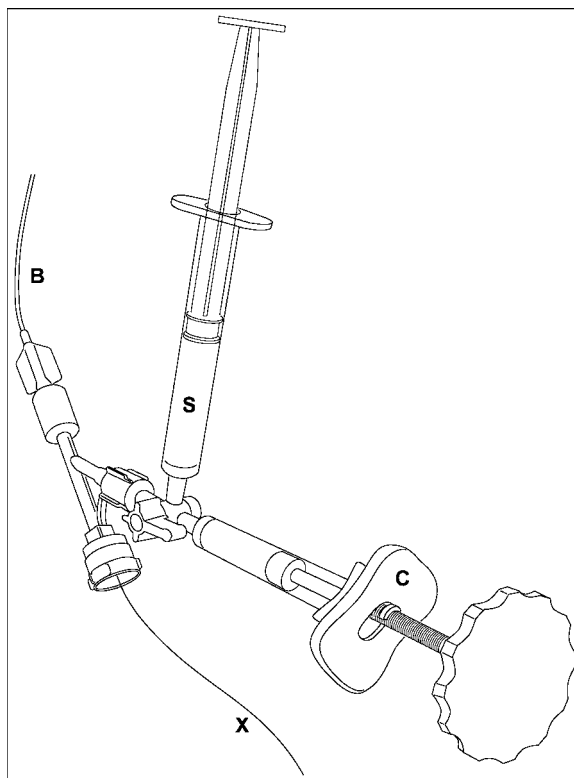


Fig. 11.1 Set-up for using the HyperGlide™ and Hyperform systems. Cadence™ 1 mL syringe (C), 3 mL syringe containing 50/50 contrast in heparinized saline (S), X-pedion microwire (X), and balloon catheter (B).

Compliant balloon catheter assembly

- Fill a Cadence™ Precision Injector (1 mL syringe) (ev3, Irvine, CA) with 50/50 contrast in heparinized saline and attach it to the side port of the RHV (Fig. 11.1).
- Insert the X-pedion microwire through the RHV until the distal tip emerges from the distal tip of the balloon catheter, and shape the tip.
- Note: The microwire should not be allowed to extend more than 10 cm beyond the tip of the balloon catheter; if it extends any further than 10 cm the balloon will not function correctly. To prevent this, advance the microwire until the tip of the microwire is 4–5 cm and then tighten the torque device onto the microwire at the mouth of the RHV.
- Test inflation. Place the distal end of the balloon catheter in a bowl of sterile saline and use the Cadence syringe to fully inflate the balloon under direct visualization (the maximum rated volume for the 4 × 10 mm HyperGlide balloon in 0.16 mL). During the first inflation, the balloon typically inflates in an eccentric manner, which is why a test inflation is required. Subsequent balloon inflations should be symmetric.

Table 11.2 HyperGlide balloon inflation volumes

Infusion volume (mL)	Balloon size (mm)
0.02	2.0
0.04	2.6
0.06	3.0
0.08	3.3
0.10	3.5
0.12	3.7
0.14	3.9
0.16	4.1

Infusion volume required for the 4 × 10 mm HyperGlide balloon²²

- (b) Angioplasty technique:
 - Advance the microwire and balloon into the target vessel under roadmap fluoroscopy.
 - *Carefully and gently* inflate the balloon under fluoroscopic visualization:
 - For the 4 × 10 mm HyperGlide balloon, see [Table 11.2](#) for infusion volumes required to obtain each balloon diameter.
 - Deflate the balloon with the Cadence syringe:
 - Note: Do not withdraw the microwire into the tip of the balloon catheter unless rapid deflation of the balloon is needed, as this will introduce blood into the balloon catheter; the manufacturer recommends the balloon not be inflated once this happens.
 - Reposition the balloon for additional angioplasties as needed.
- 3. Noncompliant balloon technique with the Maverick angioplasty balloon:
 - (a) Preparation:
 - Use 50/50 mixture of contrast in heparinized saline.
 - Prepare the insufflator and attach it with a three-way stopcock and an empty 20 mL syringe to the balloon catheter.
 - Apply suction to the balloon but do not pre-inflate it.
 - Continuously flush through the lumen of the balloon catheter with heparinized saline via a stopcock and a rotating hemostatic valve.
 - (b) Angioplasty technique:
 - The balloon can be taken up primarily, without exchanging over an exchange-length microwire, when the target vessel is fairly proximal, like the ICA or the vertebral artery, and sometimes the basilar artery. For treatment of the M1 and A1 segments, and frequently the basilar artery, exchange-length microwire should be advanced within a microcatheter first. With the microwire tip positioned in a distal vessel, the microcatheter is then exchanged for the balloon catheter.
 - The balloon is advanced into position under roadmap guidance and inflated to the appropriate pressure briefly, for 1–2 s. It has to be ensured that the balloon is completely deflated before it is repositioned.
 - Eskridge and Song²⁰ recommend a four-step angioplasty technique, in which the balloon is sequentially inflated and deflated at progressively larger diameters and advanced a slight distance after each inflation (25% inflation, deflation, 50% inflation, deflation, 75% inflation, deflation, and then 100% inflation).
 - Reposition the balloon for additional angioplasties as needed.
- 4. Angioplasty tips:
 - (a) In general, the smaller and shorter the balloon, the better.
 - (b) Work in a proximal-to-distal direction. Improvement in the caliber of proximal vessels will sometimes lead to the same in distal vessel calibers.
 - (c) In cases of severe vasospasm, when the target vessel is too constricted to accept the balloon, pretreatment by intra-arterial injection of

nitroglycerin, 20mcg, can help. A microcatheter is positioned in the proximal part of the vessel and the drug is slowly infused. A very limited amount of papaverine is usually safe and effective for this maneuver; other drug options include nitroglycerine, nicardipine and verapamil. Nitroglycerin works faster than other agents used for vasospasm, such as nicardipine and verapamil:

- Some operators recommend that pharmacologic dilation prior to angioplasty should be avoided, on the basis that predilation makes angioplasty less likely to work. Theoretically, angioplasty is effective because it stretches the vessel wall, and dilation of the vessel before angioplasty may make this less likely to occur.
- (d) When both the A1 and M1 segments require treatment, angioplasty of the A1 segment should be attempted first.²¹ If infusion of a vasodilating agent into the A1 segment after successful treatment of the M1 segment, the drug may be diverted away from the A1 segment and into the M1 segment:
- Alternatively, temporary balloon occlusion of the M1 segment can help divert the drug into the ACA.²⁰

11.2.2.3. Infusion of pharmacologic agents

Intra-arterial administration of the calcium channel blockers nicardipine, nimodipine, and verapamil has been reported. No single agent has been shown to be more efficacious than the others. Parenteral nimodipine is not currently available in the United States. IA infusion of these agents can be used to treat vessels that cannot be dealt with, or are difficult to treat with balloon angioplasty, such as distal branches and the A1 segment. IA papaverine administration is no longer recommended. See Chap. 13, *Intracranial Aneurysms and Subarachnoid Hemorrhage*, for a discussion of the published data.

1. Nicardipine.
 - (a) Regimen: Nicardipine (Cardene IV; ESP Pharma, Inc., Edison, NJ) is diluted in 0.9% NaCl to a concentration of 0.1 mg mL⁻¹. Inject 1 mL aliquots through the microcatheter to a maximal dose of 5 mg per vessel.²³
2. Verapamil:
 - (a) Regimen: Verapamil HCl Injection. Dilute a 5 mg vial with 0.9% NaCl to a concentration of 1 mg mL⁻¹. Inject 10–20 mg per vessel for a maximum of 20 mg per carotid. Watch vital signs for transient hypotension and bradycardia.

11.2.3. Treatment-related complications

A review of published reports indicate major complications with endovascular treatment was seen at 5%, for vasospasm with an incidence of 1.1% vessel rupture²⁴:

1. Reported complications include thromboembolism, arterial dissection, reperfusion hemorrhage, branch occlusion, bleeding from untreated aneurysms, retroperitoneal hemorrhage, groin hematoma, and vessel rupture.²⁵

11.3. References

1. Intracranial Angioplasty & Stenting for Cerebral Atherosclerosis: A Position Statement of the American Society of Interventional and Therapeutic Neuroradiology, Society of Interventional Radiology, and the American Society of Neuroradiology. *Am J Neuroradiol* 2005;26(9):2323–7.
2. Gruberg L, Beyar R. Optimized combination of antiplatelet treatment and anticoagulation for percutaneous coronary intervention: the final word is not out yet. *J Invasive Cardiol* 2002;14(5):251–3.
3. Schleinitz MD, Olkin I, Heidenreich PA. Cilostazol, clopidogrel or ticlopidine to prevent sub-acute stent thrombosis: a meta-analysis of randomized trials. *Am Heart J* 2004;148(6):990–7.
4. Bennett CL, Kiss JE, Weinberg PD, et al. Thrombotic thrombocytopenic purpura after stenting and ticlopidine. *Lancet* 1998;352(9133):1036–7.
5. Abou-Chebl A, Krieger DW, Bajzer CT, Yadav JS. Intracranial angioplasty and stenting in the awake patient. *J Neuroimaging* 2006;16(3):216–23.
6. Lesley WS, Lazo A, Chaloupka JC, Weigele JB. Successful treatment of cerebral vasospasm by use of transdermal nitroglycerin ointment (Nitropaste). *Am J Neuroradiol* 2003;24(6):1234–6.

7. Kiyosue H, Okahara M, Yamashita M, Nagatomi H, Nakamura N, Mori H. Endovascular stenting for stenosis of the intracranial vertebralbasilar artery after balloon angioplasty: two case reports and review of the literature. *Cardiovasc Intervent Radiol* 2004;27(5):538-43.
8. Kessler JM, Mounayer C, Piotin M, Spelle L, Vanzin JR, Morat J. The use of balloon-expandable stents in the management of intracranial arterial diseases: a 5-year single-center experience. *Am J Neuroradiol* 2005;26(9):2342-8.
9. Wingspan™ Stent System with Gateway™ PTA Balloon Catheter Product In-Service CD. 2005.
10. Coolong A, Mauri L. Clopidogrel treatment surrounding percutaneous coronary intervention: when should it be started and stopped? *Curr Cardiol Rep* 2006;8(4):267-71.
11. Qureshi AI, Saad M, Zaidat OO, et al. Intracerebral hemorrhages associated with neurointerventional procedures using a combination of antithrombotic agents including abciximab. *Stroke* 2002;33(7):1916-9.
12. Macdonald RL. Management of cerebral vasospasm. *Neurosurg Rev* 2006;29:179-93.
13. Rosenwasser RH, Armonda RA, Thomas JE, Benitez RP, Gannon PM, Harrop J. Therapeutic modalities for the management of cerebral vasospasm: timing of endovascular options. *Neurosurgery* 1999;44(5):975-9; discussion 9-80.
14. Jabbour P, Veznedaroglu E, Liebman K, Rosenwasser RH. Is radiographic ischemia a contraindication for angioplasty in subarachnoid hemorrhage? In: AANS Annual Meeting. San Francisco: American Association of Neurological Surgeons, 2006.
15. Mechanical and pharmacologic treatment of vasospasm. *Am J Neuroradiol* 2001;22(9):0080:26S-7.
16. Bernardini GL, Mayer SA, Kossoff SB, Hacein-Bey L, Solomon RA, Pile-Spellman J. Anticoagulation and induced hypertension after endovascular treatment for ruptured intracranial aneurysms. *Crit Care Med* 2001;29(3):641-4.
17. Hoh BL, Nogueira RG, Ledezma CJ, Pryor JC, Ogilvy CS. Safety of heparinization for cerebral aneurysm coiling soon after external ventriculostomy drain placement. *Neurosurgery* 2005;57(5):845-9; discussion 9.
18. Raabe A, Gerlach R, Zimmermann M, Seifert V. The risk of haemorrhage associated with early postoperative heparin administration after intracranial surgery. *Acta Neurochir (Wien)* 2001;143(1):1-7.
19. Terry A, Zipfel G, Milner E, et al. Safety and technical efficacy of over-the-wire balloons for the treatment of subarachnoid hemorrhage-induced cerebral vasospasm. *Neurosurg Focus* 2006;21(3):E14.
20. Eskridge JM, Song JK. A practical approach to the treatment of vasospasm. *Am J Neuroradiol* 1997;18(9):1653-60.
21. Murayama Y, Song JK, Uda K, et al. Combined endovascular treatment for both intracranial aneurysm and symptomatic vasospasm. *Am J Neuroradiol* 2003;24(1):133-9.
22. ev3. Package insert, Occlusion Balloon System, 2007.
23. Badjatia N, Topcuoglu MA, Pryor JC, et al. Preliminary experience with intra-arterial nicardipine as a treatment for cerebral vasospasm. *Am J Neuroradiol* 2004;25(5):819-26.
24. Hoh BL, Ogilvy CS. Endovascular treatment of cerebral vasospasm: transluminal balloon angioplasty, intra-arterial papaverine, and intra-arterial nicardipine. *Neurosurg Clin N Am* 2005;16(3):501-16, vi.
25. Sayama CM, Liu JK, Couldwell WT. Update on endovascular therapies for cerebral vasospasm induced by aneurysmal subarachnoid hemorrhage. *Neurosurg Focus* 2006;21(3):E12.

12. Venous Procedures

12.1. Introduction

Venous neuroendovascular procedures include venography, venous test occlusion, venous sampling, transvenous embolization, venous thrombolysis and thrombectomy, and venous stenting. The reader is invited to consult related chapters in the book which provide additional information on the same topics about arteries.

12.2. Venous access: Basic concepts

12.2.1. Femoral venous access

1. The femoral vein can be localized by advancing an 18 gauge needle with a syringe half-full of heparinized saline just medial to a palpable femoral arterial pulse. As the needle is advanced, continuous suction is applied to the syringe by pulling back the plunger.
2. In case the arterial pulse is not palpable, the fluoroscopic landmark is that the vein lies over the most medial aspect of the femoral head. In many cases, it can even be medial to the femoral head.
3. In some cases, needle puncture of the femoral vein can be facilitated by using ultrasound guidance to look for the vein, or a Doppler-assisted needle (*SmartNeedle*™ Escalon Medical, New Berlin, WI) to hear the flow in the vein. Venous flow sounds like wind whistling through trees, while arterial flow has that familiar, strongly pulsatile sound on Doppler.
4. When the vein is punctured, there may or may not be good spontaneous blood return from the needle. If blood can be freely aspirated, the needle is in the vein.
5. A J-tip 0.038 in. wire is then carefully advanced under fluoroscopic visualization, and intravenous positioning is confirmed by visualization of the wire in the inferior vena cava to the right of the spine.
6. A sheath of the desired size is then advanced into the vein. The authors frequently use a 6 French, 25 cm long sheaths.
7. Due to the large size of the femoral vein and the lower risk of bleeding from the puncture site compared to arterial punctures, even larger sheaths are usually well tolerated.

12.2.2. Alternative venous access

1. The jugular vein can be used for access to the ipsilateral dural venous sinuses. Retrograde jugular punctures can be easily done using a small vessel access system. The carotid pulse is palpated and the 21 gauge needle is inserted just lateral to the pulse, angling cephalad. A syringe attached to the needle is gently aspirated as the needle is advanced until dark venous blood freely aspirates. (If the blood is bright red and pulsatile, you hit the artery. Pull out and hold pressure for 5–10 min, then try more laterally.)
2. When the needle is in the vein, the 0.018 in. platinum-tip wire of the access kit is advanced carefully up the jugular vein, the needle is removed, and the coaxial dilator is inserted.
3. Microcatheters may be advanced directly through the outer 4 French coaxial dilator. (Always attach a rotating hemostatic valve with a continuous flush of heparinized saline to the hub of the dilator, if you are using it as access for the microcatheter.)

4. If larger catheter systems need to be used, the dilator may be exchanged over a 0.035–0.038 in. J-tip wire for a 10 cm long sheath of appropriate size. Since there is less soft tissue support and only a short length of guidewire can usually be advanced up the jugular, it can sometime be challenging to get the sheath to enter the vessel without buckling the wire and potentially losing access. It can help to use progressively larger dilators to dilate the tract. Rotating the dilators and sheath as they are advanced over the wire can help.
5. Arm or subclavian veins can also be used to access the venous system. However, the angulation at the entry of the jugular veins to the brachiocephalic veins as well as the valves in these locations can make it difficult to access the jugular or more cephalad venous structures from an arm approach.

12.2.3. Catheter navigation

Catheters should usually be advanced over a steerable hydrophilic wire. The wire serves to keep the tip of the catheter from rubbing against the wall of the vessel and causing a dissection or puncturing the vein. When advancing the wire and catheter cephalad from the femoral vein, the tip of the wire should be followed by direct fluoroscopic visualization. When the tip of the wire enters the junction of the inferior vena cava and right atrium, keep the curved tip of the wire pointing laterally to facilitate passage into the superior vena cava. Ensure that the wire does not poke at the wall of the right atrium or enter into the right ventricle. Keep one eye on the electrocardiographic (ECG) monitor, since arrhythmias can be induced when the wall of the heart is irritated.

Once the catheter is advanced into the superior vena cava, it can either be advanced straight up the right internal jugular, or angled sharply to the left to enter the left brachiocephalic vein. It must then be advanced cephalad if catheterization of the left internal jugular is desired. Valves in the proximal internal jugular veins sometimes can impede advancement of the guidewire up the internal jugular veins. The valves can be gently probed with an angled Glidewire® (Terumo Medical, Somerset, NJ) as the patient breathes deeply. The authors have had success using a 0.016 in. Gold-tip Glidewire® (Terumo Medical, Somerset, NJ) to quickly get past the valves. The catheter can then be advanced into the more cephalad jugular vein.

Although the most caudal aspects of the inferior petrosal sinuses can be gently catheterized with 4 or 5 French catheters, catheterization of more cephalad venous structures requires use of a coaxial microcatheter/microwire assembly, usually placed through a 5 or 6 French guiding catheter. When advancing a microcatheter through any guiding catheter, always remember that movement of the microcatheter forward creates retrograde force on the guiding catheter. Attempts at advancing the microcatheter very distally or through tortuous vessels can create enough retrograde force to push the guiding catheter proximally. Not only can this displace the guiding catheter out of proper position in the jugular vein, it also frequently buckles in the right atrium, often causing transient arrhythmias. These resolve when the slack is taken out of the guiding catheter, and it no longer contacts the wall of the right atrium. The problem of buckling of the guiding catheter may be solved by using a stiffer catheter, such as a 6 or 7 French Northstar® Lumax® (Cook Medical, Inc., Bloomington, IN) or use a “Tower of Power” by combining a 90 cm sheath, with a 100 cm guide catheter to create a stiffer platform for microcatheter advancement.

12.2.4. Tips for catheter navigation in difficult situations

- Veins are more mobile and less supportive than arteries, and are therefore less supportive to the catheter. One generally needs somewhat stiff guide catheters for support.
- Veins are generally tortuous, requiring a good, steerable soft-tip wire to help one get to the target vessel.

- Veins are more variable in their anatomy than arteries. Moreover, situations like arteriovenous fistulas, may be associated with venous occlusive disease.
- When in doubt, inject contrast through the catheter to see where one is.
- Veins are designed to carry blood toward the heart, and thanks to valves and vessel contour, it is often easier to navigate catheters in the direction of the blood flow, rather than against it. Again, it is usually the steerable wire, and steerable catheters, that will allow the catheterization.
- There may be difficulty accessing a target by a direct route, yet it may still be accessible via a more circuitous pathway. A multiple catheter, snare-assisted technique may help in accessing the target in this situation (Fig. 12.1).

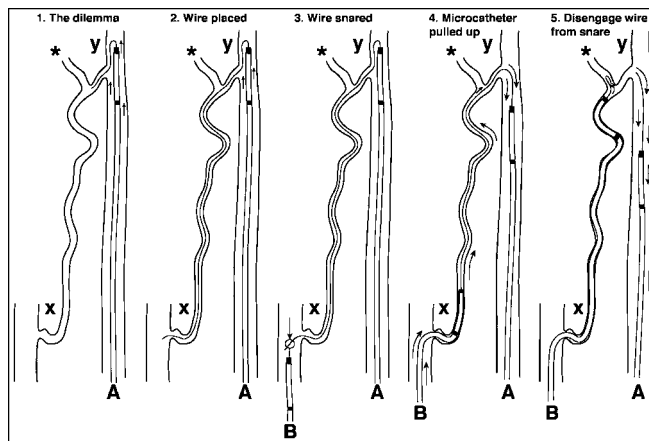


Fig. 12.1 Snare-assisted catheterization.

1. *The dilemma.* In an attempt to obtain transvenous access to the site of a fistula (\ast), difficult angles make it impossible to advance a microcatheter (A) directly. Neither the microcatheter, nor the microwire can be navigated up the direct route via the small venous channel (X). A wire may be advanced into an indirect pathway (Y), but the microcatheter does not make the sharp turn and displaces the wire and pushes beyond the turn.
2. *Wire placed.* With some careful manipulation, a soft microwire can be manipulated all the way down the small venous channel (X), and even into the larger vessel below, but still it does not provide sufficient support to allow the microcatheter to follow around the turn.
3. *Wire snared.* The clever operator then positions a second microcatheter (B) with its tip near the end of the microwire. A small snare is then advanced through this microcatheter, and manipulated around the end of the microwire. The snare is pulled back into the microcatheter to grasp the wire.
4. *Microcatheter pulled up.* Gently, but persistently, the microwire (now snared) is pulled back into the first microcatheter (A) and the second microcatheter (B) is pushed to slowly advance it up the small arterial pedicle (X).
5. *Disengage wire from snare.* The snare is then pushed out slightly from the second microcatheter (B) tip to disengage the wire. The wire and first microcatheter (A) can then be withdrawn. The second microcatheter can then be advanced to the desired target over either the snare itself, or, preferably, the snare can be removed and a microwire is used to guide the microcatheter into position.

12.2.5. Roadmapping

Roadmapping is less effective for venous procedures compared to arterial procedures. It is difficult to opacify the venous structures for any distance proximal to the tip of the catheter, since the contrast is injected against the flow of blood. Excellent roadmap images of the target venous structures can be obtained by injecting contrast in the arterial feeding vessels via a separate angiographic catheter in the arterial side when performing venous catheterization for transvenous embolization of arteriovenous fistulas.

12.2.6. Double flushing

Double flushing is discussed in Chap. 2. Although small clot emboli are less likely to create clinically evident problems on the venous side, it is better to utilize good angiographic techniques including double flushing at all times to limit the risk of complications.

12.2.7. Continuous saline infusion

Three-way stopcock or manifolds must be used to provide a heparinized saline drip through the catheter. This is particularly useful if there is a rotating hemostatic valve on the catheter, so that the catheter hub is never left open to the air. When the catheter is in the venous system, low venous pressure may allow air to enter the catheter. Careful double flushing is still required if a wire is inserted and removed or if any blood is present in the lumen. The use of hemostatic valves and continuous infusions is mandatory for any coaxial catheterization.

12.2.8. Anticoagulation

Heparinization is helpful to prevent thrombus formation in the catheter system, which can impair normal functioning of these systems. Moreover, thrombus in or around the catheter can cause venous thrombosis, potentially resulting in deep venous thrombosis, pulmonary emboli, and/or local thrombotic occlusion of the cerebral venous structures being catheterized. However, there has been no systematic study to determine whether systemic heparin is effective in preventing the complications of venous procedures.

12.2.9. Hand injection

A 10 mL syringe containing contrast should be attached to the stopcock on the catheter, and the syringe should be snapped with the middle finger several times to release bubbles stuck to the inside surface of the syringe. The syringe should be held in a vertical position, with the plunger directed upward, to allow bubbles to rise away from the catheter. Contrast injections through a microcatheter are usually done using 3 mL syringes.

12.2.10. Mechanical injection

There is generally little role for power injections during venous procedures.

12.2.11. Puncture site care

Once the venous procedure is completed, the catheters are removed. If systemic heparin was administered, obtain an ACT to see if the patient is still anticoagulated. Protamine can be given to reverse heparin, as long as the patient is not an insulin-dependant diabetic or has other contraindications. The sheaths can be removed and

hemostasis should be obtained by manual pressure. Alternatively, one can leave the sheaths in place until the ACT returns to normal. Closure devices are generally not necessary for venous punctures. The patient should be kept at strict bed rest with the legs extended for at least 2 h, depending on the sheath size. The authors apply a Syvek hemostatic patch (Marine Polymer Technologies, Danvers, MA) then keep the patient at bed rest for 2 h for 6 French sheath sizes.

12.3. Venography

12.3.1. Background

Venography – the imaging of veins is rarely done in the head and neck using direct catheterization, due to the availability of excellent noninvasive imaging techniques, such as magnetic resonance venography (MRV) to study the venous system.¹ Most commonly, direct catheter angiography of the venous system is only performed as part of another venous procedure.

12.3.2. Indications for venography

1. To confirm catheter placement and to assess venous drainage patterns in venous sampling procedures.
2. To evaluate for stenosis or occlusion in patients with suspected venous hypertension.
3. To evaluate for stenosis or occlusion in patients with unexplained tinnitus.
4. To assess collateral pathways in anticipation of surgical or endovascular occlusion of dural venous sinuses.
5. To evaluate for potential routes of access for transvenous embolization procedures.
6. In cases of transarterial embolization of arteriovenous shunts, venous catheterization may be done to monitor pressure, and determine the degree of reduction of venous hypertension.

12.3.3. Complications of venography

Informed consent prior to the procedure should include an estimate of the risk of complications.

12.3.3.1. Neurological complications

1. Since venography is usually performed as part of another venous procedure, the patient should be informed of the potential complications of the more involved procedure.
2. Statistics on complications of venography alone are lacking, since it is not a commonly performed procedure.
3. Theoretically, there is always a risk of venous infarction and hemorrhage whenever one deals with intracranial venous structures, but the risk of these complications is unknown.

12.3.3.2. Non-Neurological complications

1. Anaphylactic reactions to iodinated contrast or any of the medications used can occur as with any endovascular procedure.
2. Similarly, groin hematomas can occur, but are less common and less severe than in arterial punctures.
3. Venous thrombosis can occur, producing symptoms of deep venous thrombosis, or pulmonary emboli.

12.3.4. Venography: Procedural aspects

12.3.4.1. Preprocedure evaluation

1. A brief neurological exam should be done to establish a baseline, should a neurologic change occur during or after the procedure.
2. The patient should be asked if he or she has had a history of iodinated contrast reactions.
3. The groins should be examined. Feel for the femoral arterial pulse, which provides a landmark for femoral venous access.
4. Ask the patient about any history of deep venous thrombosis that may require using special sites for venous access.
5. Blood tests, including a serum creatinine level, serum glucose if diabetic and coagulation parameters, should be reviewed.

12.3.4.2. Preprocedure orders

1. NPO except medications for 6 h prior to the procedure.
2. Patients on insulin for hyperglycemia should get half their normal dose prior to the procedure.
3. Place a peripheral IV.
4. Place Foley catheter if an involved procedure is anticipated.

12.3.4.3. Contrast agents

Nonionic contrast agents are well tolerated and are usually used for these procedures. Iohexol (Omnipaque®, GE Healthcare, Princeton, NJ), a low osmolality, nonionic contrast agent, is relatively inexpensive and probably the most commonly used agent in venographic procedures. In patients with a history of severe anaphylactic reactions to iodinated contrast, the authors have used small quantities of Gadolinium-based MR contrast agents with good results.

12.3.4.4. Femoral venous sheath

Venous procedures are virtually always done using a femoral venous sheath, most commonly a 6 French sheath.

12.3.4.5. Saline infusion

As with any endovascular procedure, continuous drips of heparinized saline are attached to stopcocks on the sheath, guiding catheter, and microcatheter lumen.

12.3.4.6. Anticoagulation

Systemic heparin (50–70 units kg⁻¹ body weight) is administered after sheath placement.

12.3.4.7. Sedation/Anesthesia

Most commonly, if the venogram is performed as part of another venous procedure, the use of general anesthesia vs. local anesthesia with or without sedation depends on the expected discomfort of the more complicated procedure. Venography itself would not be expected to produce much discomfort, unless very distal intracranial catheterization was required. As a general rule, catheterization above the skull base is usually done with general anesthesia, and up to the skull base is performed with small amounts of sedation and analgesia.

- Midazolam (Versed®) 1–2 mg IV for sedation; lasts approximately 2 h.
- Fentanyl (Sublimaze®) 25–50 mcg IV for analgesia; lasts 20–30 min.

12.3.5. Suggested wires and catheters for venography

12.3.5.1. Hydrophilic wires

- The 0.035 in. angled Glidewire® (Terumo Medical, Somerset, NJ) is soft, flexible, and steerable.
- The 0.038 in. angled Glidewire® (Terumo Medical, Somerset, NJ) is slightly stiffer than the 0.035 in. and helpful when added wire support is needed, but is too stiff to routinely use it in smaller veins or intracranially.
- Softer, yet torquable wires such as the Headliner™ or Gold-tip Glidewire® (Terumo Medical, Somerset, NJ) can be helpful for navigating the sometimes difficult valves in the lower internal jugular and for accessing the intracranial sinuses.

12.3.5.2. Catheters for venography

There is one principle to keep in mind when doing venography; blood flows back toward the heart. Therefore, contrast injected in head or neck veins through a catheter placed via a femoral approach will flow back toward the heart and opacify the vessel caudal to the tip of the catheter. Especially in the larger dural sinuses, it is unlikely that one will opacify much of the vessel cranial to the tip of the catheter, since one is injecting against the blood flow. Standard soft-tip, simple angle 4 or 5 French catheters placed in the jugular bulbs can be used to study the jugular veins. The catheters can also be positioned in the very caudal aspects of the inferior petrosal sinuses to opacify those vessels and the posterior cavernous sinuses. More cephalad venous structures are studied by injecting contrast via a microcatheter coaxially placed through 6 French guiding catheters in the jugular veins:

- Soft-tip, simple angle catheters for catheterizing the caudal IPS or jugular bulb: 4 or 5 French Berenstein curve Soft-Vu® (Angiodynamics, Queensbury, NY) or 4 or 5 French Angled Glide-catheter® (Terumo Medical, Somerset, NJ).
- Guiding catheters used for coaxial approach include standard 5 or 6 French large-lumen gauge guide catheters such as the 5 or 6 French angle-tip Envoy® (Cordis Neurovascular, Miami Lakes, FL).
- Microcatheters used for the coaxial approach should be braided with a relatively large internal lumen, such as RapidTransit® (Cordis Neurovascular, Miami Lakes, FL).
- Study of the intracranial sinuses such as the superior sagittal sinus in adults, is likely to require a microcatheter longer than standard 150 cm catheters. The RapidTransit® (Cordis Neurovascular, Miami Lakes, FL) is available in a 170 cm length, and works well for this purpose. Remember to use a 200 cm or longer microguidewire. The authors like the 0.012 in. J-Tip Headliner™ (Terumo Medical, Somerset, NJ) or the 0.014 in. Soft-tip Transend™ (Boston Scientific, Natick, MA).

12.3.6. Procedures

12.3.6.1 Femoral venous access

1. The groin area is prepped bilaterally and draped.
2. The femoral pulse is palpated at the inguinal crease, and local anesthesia (2% lidocaine containing sodium bicarbonate (1 mL per 10 mL of lidocaine)) is infiltrated medial to the pulse, both by raising a wheal and injecting deeply toward the vein.
3. 5 mm incision is made parallel to the inguinal crease with an 11-blade scalpel.
4. An 18 gauge Potts needle is advanced with the bevel facing upward. The needle is advanced at a 45° angle to the skin.
5. Dark red blood aspirated from the needle using a 10 cc syringe confirms puncture of the femoral vein.
6. A 0.038 in. J-wire is advanced under fluoroscopic visualization into the inferior vena cava.

7. Depending on the size of the catheter being used, a 5 or 6 French sheath is placed in the right (or left) femoral vein.

12.3.6.2. Catheter manipulation

1. Attach all catheters to rotating hemostatic valves and attach a three-way stopcock and continuous infusion of saline containing 10,000 units heparin per liter.
2. Through the femoral venous sheath, advance the catheter into the desired internal jugular vein.
3. Once in the internal jugular vein, direct the catheter superomedially to point into the inferior petrosal sinuses, or superolaterally to point to the jugular bulb.
4. If the venous structures being studied are more cephalad than the jugular bulb or IPS, advance a large-lumen microcatheter coaxially through the rotating hemostatic valve of the guiding catheter.
5. Warn awake patients that the catheter manipulation may cause discomfort.
6. Carefully and gently advance the microcatheter over a soft-tip guidewire into the venous sinus cephalad to the area one wishes to opacify.
7. Perform a gentle test injection of 1–2 mL of contrast, to ensure proper position and to estimate the amount of contrast required for a selective venogram.
8. Intracranial venograms are performed with hand injections of contrast.
9. Large dural venous sinuses may require injection volumes of 3–5 mL or more, and smaller sinuses, like the IPS may only require 1–3 mL.
10. Cortical veins or deep veins like the internal cerebral veins should be cautiously injected with small volumes of contrast.
11. Perform the venogram with high-quality DSA imaging systems using 2–4 frames per second.

12.3.6.3. Tips for evaluating venogram images

- Inevitably, when using microcatheters for venography of large dural sinuses, a streaming of contrast and unopacified blood from tributary veins will be seen, creating apparent filling defects in the vein.
- Apparent filling defects from streaming will change in size and configuration from frame-to-frame during the angiographic run, and have vague margins, whereas true filling defects or stenoses are static and more clearly demarcated.
- If it is not clear if a filling defect is real or not, adjusting the catheter position and repeating the run may help confirm the presence of a real defect.
- Remember that potentially large pacchionian granulations are normally expected within the dural sinuses, usually in lateral aspect of the transverse sinuses, and smaller ones can be seen in the superior sagittal sinus.

12.3.6.4. Venous pressure measurements

Stenosis seen on venography may, or may not be hemodynamically significant. Therefore, a full check-up of patients with suspected venous hypertension should include venous pressure measurements obtained proximal and distal to any potential stenosis. The simplest method is to connect saline-filled extension tubing from a three-way stopcock or manifold connected between the catheter and a standard pressure transducer. For full evaluation of the intracranial sinuses, it is necessary to take the measurements using a microcatheter that can be advanced into the superior sagittal sinus, ipsilateral and contralateral transverse and sigmoid sinuses and jugular veins, obtaining pressure measurements at each of these sites, and certainly on either side of any obvious stenosis. Waveforms of pressure measurements obtained via a microcatheter will inevitably be inaccurate, but studies have shown the mean values to be reasonably accurate.² If the pressure waveform is completely flat, it may be necessary to change the display scale on the monitor. If it is flat and the numbers do not seem correct, the microcatheter may be wedged against the wall of the vessel, or it may be kinked, so gentle withdrawal of the catheter may be attempted to see if that improves the reading. More accurate pressure measurements may be obtained by inserting a 0.014 in. PressureWire® (Radi Medical Systems, Wilmington, MA) in the microcatheter. This wire has a micromachined pressure transducer 3 cm proximal to

the tip of the wire. However, the added accuracy comes with the added cost of the wire and its associated monitoring display.

Venous pressure measurements can also be useful when performing transarterial embolization of arteriovenous malformation or fistulas. Especially in the case of extensive lesions that may not be curable, but are being treated to palliate symptoms of venous hypertension, measurement of intracranial venous pressure provides an objective endpoint to aim at. Reduction of pressure to more normal levels suggests the patient will gain a clinical benefit from the procedure. In similar fashion, a Doppler guidewire can document alterations in blood flow by measuring changes in velocity in the veins draining arteriovenous shunts as the arterial feeders are embolized.³

12.3.6.5. Postprocedure care

Once the venogram and all associated procedures are completed, the catheters removed and hemostasis obtained, postprocedure care will be as discussed in the general comments above.

12.4. Venous test occlusion

12.4.1. Background

Venous test occlusion is usually performed in a preoperative setting when it is anticipated that one of the major dural venous sinuses might need to be occluded and resected due to tumor invasion, involvement with a vascular malformation or is in the anticipated path of a surgical intervention of another lesion. Test occlusion is done to predict whether occlusion of the vein will have negative hemodynamic consequences. However, there are considerable differences between arterial and venous test occlusion. On the arterial side, occlusion of the vessel can quickly cause a sufficient drop in blood flow to a vascular territory to cause transient neuronal dysfunction, meaning the patient develops a demonstrable neurological deficit. However, there is less of a linear relationship of blood flow to patency of a particular venous structure; hence neurological deficits may not occur quick enough to be detected during the test. Moreover, some of the potentially disabling signs and symptoms of venous occlusive disease, such as intractable headaches and visual loss may only develop weeks or months after the occlusion took place. There are reports of balloon test occlusions failing to predict disastrous venous hypertension and brain swelling after permanent occlusion of the tested venous sinus.⁴ Venous sinuses have reportedly been safely occluded when collateral venous flow appears adequate on angiographic studies and if the pressure proximal to the site of occlusion increased by less than 10mmHg as measured at the time of surgical occlusion.^{5,6} Therefore, endovascular venous test occlusion attempts to assess tolerance for occlusion by measuring pressure changes produced by occlusion and by evaluating drainage patterns angiographically, as well as clinical testing of the patient. The need for pressure measurements beyond the balloon requires the use of over-the-wire angioplasty balloons to permit monitoring pressure through the end-hole of the catheter⁷; the 0.014 in. PressureWire® (Radi Medical Systems, Wilmington, MA) can also be used to advance through the balloon catheter. Assessing the diameter of the venous structure being occluded is necessary to choose an appropriately sized balloon. The usual soft, flexible occlusion balloons used in the intracranial arterial circulation are too small to occlude most dural sinuses, and cannot be used for pressure measurements.

Another characteristic that can be determined from venous test occlusion is whether turbulent flow in a venous structure is causing a symptomatic pulsatile tinnitus. Temporary occlusion of the offending vessel would be expected to eliminate the sound. If permanent occlusion of the venous structure is planned as treatment for the symptoms, it will be necessary to confirm that the vessel can safely be occluded as indicated by clinical criteria, pressure measurements and angiographic criteria. A more physiologic solution to the problem will be to place a stent in the vessel to redirect flow (see *Transvenous Stenting* section).

12.4.2. Indications for venous test occlusion

1. To determine the potential safety of occluding a venous structure, prior to anticipated occlusion as treatment for tumors, arteriovenous malformations or fistulas involving a venous sinus.
2. To determine the potential safety of occluding a venous structure, prior to anticipated occlusion to permit proper surgical exposure when that venous structure is in the way.
3. To confirm a venous etiology in patients with unexplained tinnitus.

12.4.3. Complications of venous test occlusion

Informed consent prior to the procedure should include an estimate of the risk of complications.

12.4.3.1. Neurological complications

1. There is a risk of thrombosis of the venous structures catheterized, with resultant venous infarction.
2. Overly aggressive balloon inflation in intracranial vessels can rupture venous structures, potentially producing epidural, subdural, subarachnoid or intracerebral bleeding.
3. Statistics on complications of venous test occlusion alone are lacking, since it is a rarely performed procedure.

12.4.3.2. Non-neurological complications

1. There is a risk of a profound vagal response to balloon inflation in the jugular vein or sigmoid sinus, potentially producing bradycardia, hypotension, and even cardiac arrest.
2. Anaphylactic reactions to iodinated contrast or any of the medications used can occur as with any endovascular procedure.
3. Similarly, groin hematomas can occur, but are less common and less severe compared to arterial punctures.
4. Venous thrombosis can occur anywhere in the venous system.

12.4.4. Venous test occlusion: Procedural aspects

12.4.4.1. Preprocedure evaluation

1. Brief neurological exam should be done to establish a baseline, should a neurologic change occur during or after the procedure.
2. The patient should be asked if he or she has had a history of iodinated contrast reactions.
3. The groins should be examined. Feel for the femoral arterial pulse, which provides a landmark for femoral venous access.
4. Ask the patient about any history of deep venous thrombosis that may require using special sites for venous access.
5. Blood tests, including a serum creatinine level, serum glucose if diabetic and coagulation parameters, should be reviewed.

12.4.4.2. Preprocedure orders

1. NPO for 6 h, except for medications.
2. Patients on insulin for hyperglycemia should get half their normal dose prior to the procedure.
3. Place a peripheral IV.
4. Place Foley catheter.
5. Consider pretreatment with 0.3–0.5 mg Atropine if planning on inflating a balloon in the jugular vein or sigmoid sinus.

12.4.4.3. Contrast agents

Standard nonionic contrast agents like Iohexol (Omnipaque[®], GE Healthcare, Princeton, NJ), are usually used for these procedures.

12.4.4.5. Femoral venous sheath

Venous procedures are virtually always done using a femoral venous sheath, most commonly a 6 French sheath. One may consider using 90 cm sheaths such as the 6 French Shuttle[®] sheath (Cook, Inc., Bloomington, IN) which also acts as a guiding catheter.

12.4.4.6. Saline infusion

To reduce the risk of thrombus or air embolism, continuous drips of heparinized saline are attached to stopcocks on the sheath, guiding catheter, and microcatheter lumen.

12.4.4.7. Anticoagulation

Administer 50–70 units kg⁻¹ intravenous heparin bolus and hourly boluses as needed to keep the activated clotting times at least double the baseline value. One can also consider pretreating any patient undergoing test occlusion with a dose of aspirin to limit any cascade of platelet aggregation instigated by intimal injury produced by the balloon, although most practitioners do not bother with antiplatelet treatment.

12.4.4.8. Sedation/Anesthesia

Most commonly, venous test occlusion is performed with the patient conscious, with minimal sedation in order to detect neurological changes produced by the temporary venous occlusion. However, catheterization much above the skull base can sometimes produce discomfort so it can be argued that the procedure should be done under general anesthesia. Given the heavy reliance on pressure measurements and angiographic evaluation during these procedures, the neurological examination is of secondary importance. A compromise would be to use heavy sedation/analgesia during the catheterization phase of the procedure and let it wear off when the actual balloon inflation takes place.

12.4.5. Suggested wires and catheters for venous test occlusion

12.4.5.1. Access wires

- Steerable hydrophilic wires such as 0.035 or 0.038 in. angled Glidewire[®] (Terumo Medical, Somerset, NJ) can be used to advance a guiding catheter into the jugular vein.
- Softer, yet torquable wires such as the Headliner[™] or Gold-tip Glidewire[®] (Terumo Medical, Somerset, NJ) can be helpful for navigating the sometimes pesky valves in the lower internal jugular.
- Soft-tip Transend[™] (Boston Scientific, Natick, MA) or other 0.014 in. wire is used to advance the balloon catheter to the target vessel.

12.4.5.2. Guiding catheters and balloons for venous test occlusion

- Guiding catheters used for coaxial approach include standard 5, 6 or 7 French large-lumen gauge guide catheters, such as 6 French angle-tip Envoy[®] (Cordis Neurovascular, Miami Lakes, FL) or 6 French Northstar[®] Lumax[®] (Cook Medical, Inc., Bloomington, IN). It has to be ensured the internal lumen will

accept the outer diameter of the balloon catheter. The package of the balloon will usually indicate the recommended guide catheter size.

- 90 cm sheaths (e.g., Shuttle® sheath, Cook, Inc., Bloomington, IN) also work very well as alternative guiding catheters for test occlusions. This allows for extra stability if needed.
- Balloons must be sized to match the vessel being occluded. The target vessel must be measured using a previous MR venogram, or a venogram obtained as part of the procedure to get a measurement of the vessel.
- If the target vessel is 6 mm or smaller, theoretically one can use soft flexible balloons such as the 7 mm Hyperform™ (ev3, Irvine, CA), but a significant disadvantage is that one cannot use these single-lumen balloons to measure pressures beyond the site of occlusion.
- Better suited for venous test occlusions are over-the-wire angioplasty balloons that have an internal lumen through which one can measure distal pressure either directly through the lumen or by using a 0.014 in. PressureWire® (Radi Medical Systems, Wilmington, MA) advanced through the balloon catheter.
- The shaft of the balloon catheter must generally be at least 120 cm and preferably 150 cm to reach the target vessel. The Savvy® balloon (Cordis Endovascular, Miami, FL) is available in various balloon diameters and lengths and has a large enough inner lumen for obtaining pressure measurements.
- A 4 or 5 French diagnostic catheter is useful to have in the arterial system, to obtain cerebral arteriography during the test occlusion. This allows visualization of venous drainage patterns as the balloon is inflated.

12.4.6. Procedures

12.4.6.1. Femoral access

1. The groin area is prepped bilaterally and draped.
2. The femoral pulse is palpated at the inguinal crease, and local anesthesia (2% lidocaine containing sodium bicarbonate (1 mL per 10 mL of lidocaine)) is infiltrated medial to the pulse, both by raising a wheal and injecting deeply toward the vein.
3. 5 mm incision is made parallel to the inguinal crease with an 11-blade scalpel.
4. An 18 gauge Potts needle is advanced with the bevel facing upward. The needle is advanced at a 45° angle to the skin.
5. Dark red blood aspirated from the needle using a 10 cc syringe confirms puncture of the femoral vein.
6. A 0.038 in. J-wire is advanced under fluoroscopic visualization into the inferior vena cava.
7. Depending on the size of the catheter being used, a sheath is placed in the right (or left) femoral vein.
8. In the contralateral groin, the same process is performed, except that the femoral artery has to be aimed at, and the diagnostic 4 or 5 French catheter inserted and positioned with its tip in the descending aorta, until it is needed for angiographic studies.

12.4.6.2. Catheter manipulation

1. Attach all catheters to rotating hemostatic valves and attach a three-way stopcock and continuous infusion of saline containing 10,000 units heparin per liter.
2. Through the femoral venous sheath, advance the desired guiding catheter into the desired internal jugular vein. If needed, one may have to perform arteriography first to determine the best access to the venous structure being tested.
3. Once in the internal jugular vein, advance an appropriately sized balloon catheter coaxially through the rotating hemostatic valve of the guiding catheter.
4. Warn awake patients that the catheter manipulation may cause discomfort.
5. Carefully and gently advance the balloon catheter over a soft-tip guidewire into the venous sinus up to the site one wishes to occlude.
6. Perform a gentle test injection of 1–2 mL of contrast through the end-hole of the balloon catheter, to ensure proper position.

12.4.6.3. Test occlusion

1. With the appropriately sized balloon catheter positioned at the site to be tested, inject contrast through the central lumen of the catheter, to confirm proper positioning and to obtain a roadmap of the vessel.
2. Prepare to measure venous pressures, either by attaching a pressure line to the stopcock (or manifold) attached to the central lumen of the balloon catheter, or by using a pressure-sensing guidewire.
3. Measure a baseline pressure through the central lumen of the balloon catheter.
4. Gently inflate the balloon just enough to occlude the vessel. Less than one atmosphere is required to occlude the vein with an appropriately sized balloon.⁷
5. Measure the pressures through the central lumen of the balloon catheter again. This now indicates the back pressure in the venous system proximal to the occlusion. Stable pressure indicates adequate collateral flow. Rising pressure, especially if it increases by at least 10mmHg indicates limited collaterals and is one element of a “failed” test occlusion.
6. Clinically test the patient for any neurological deficits and check for some of the more subtle signs and symptoms, including headache, vertigo, ringing in the ears, and visual changes.
7. At some point during the test occlusion, perform cerebral arteriography using the arterial catheter, and check for venous drainage patterns and look for angiographic signs of venous congestion. These signs include slowing of the arteriovenous transit time congestion and dilatation of cortical veins, and stasis of flow in venous sinuses. It is helpful to compare the flow patterns before and after balloon inflation in the venous structure.
8. If the patient tolerates the balloon inflation clinically and back pressure in the balloon catheter does not rise, keep the vein occluded for an extended period of about 30 min to confirm tolerance to occlusion.
9. If the patient develops symptoms, if the back pressure rises at least 10 mm mercury, or if angiography suggests venous congestion, the patient has “failed” the test occlusion.
10. When the patient fails the test occlusion, or if they pass for at least 30 min, the procedure is complete. The balloon must then be deflated.
11. Prior to removing the balloon, ensure that the patient’s symptoms have resolved and that venous pressure has returned to baseline. If not, some venous thrombosis may have been caused; leaving the balloon catheter in place provides access for any corrective intervention.
12. In the vast majority of cases, deflating the balloon relieves any symptoms produced. The balloon catheter can then be removed.

12.4.6.4. Postprocedure care

Once the procedure is completed, the catheters are removed and hemostasis obtained, as is discussed in the general comments above.

12.5. Venous sampling

12.5.1. Background

Neoplasms that secrete endocrine factors can produce significant alterations in the physiological state of the affected patient, even when the tumor is small in size. Imaging studies may fail to detect very small lesions that do not distort the tissues from which they arise. Blood samples taken from the venous outlets of structures suspected to harbor the tumor can confirm the presence of the lesion by detecting elevated levels of the secretory factors produced. Cushing’s disease is a relatively common example of a condition in which an adrenocorticotropic hormone (ACTH)-producing microadenoma otherwise undetectable on imaging studies in the pituitary can produce profound endocrine effects. The pituitary gland can be surgically removed, but subtotal hypophysectomy may fail to remove the entire tumor. Total hypophysectomy produces severe endocrine deficits of its own, and may still not cure the Cushing’s syndrome if the lesion is outside the pituitary gland. Endovascular

operators skilled in catheter techniques and familiar with the venous anatomy of the head and neck are able to catheterize veins draining the pituitary gland, namely the inferior petrosal and/or cavernous sinuses. Sampling the venous blood from the sinuses and measuring the levels of ACTH allows one to confidently localize the tumor to the pituitary gland, and possibly even lateralize to one half of the gland, allowing for precise surgical removal of the lesion. This chapter will focus on venous sampling in the context of Cushing's disease.

12.5.2. Indications for inferior petrosal sinus sampling (IPSS)

1. ACTH-dependant Cushing's syndrome.
2. Biochemical testing and MRI imaging of the pituitary do not clearly differentiate between pituitary or ectopic ACTH source.
3. MRI imaging does not clearly lateralize the tumor, even if biochemical tests strongly suggest a pituitary location.
4. Any situation in which greater confidence is required to localize the ACTH-producing tumor, such as recurrent Cushing's syndrome after pituitary surgery.

12.5.3. Complications of petrosal sinus sampling

Informed consent prior to the procedure should include an estimate of the risk of complications.

12.5.3.1. Neurological complications

1. Permanent neurological complications at highly experienced centers are rare: one out of 1,200, or 0.083%.⁸
2. Realistically, neurological complications may be higher when less experienced operators are involved, but are generally under 1%.
3. Reported neurological complications include transient or permanent brainstem ischemia,^{9,10} brainstem hemorrhage,⁹ subarachnoid hemorrhage¹¹ and transient sixth cranial nerve palsy.¹²

12.5.3.2. Non-neurological complications

1. Anaphylactic reactions to iodinated contrast or any of the medications used can occur as with any endovascular procedure.
2. Similarly, groin hematomas can occur, but are less common and less severe compared to arterial punctures.
3. Venous thrombosis can occur. Two out of 34 (5.9%) patients undergoing IPSS had deep venous thrombosis, and one of these died from resultant pulmonary embolism.¹³
4. Theoretically, Cushing's patients may be expected to be at risk for infectious complications, but these have not been reported after venous sampling procedures.

12.5.4. Petrosal sinus sampling: Procedural aspects

12.5.4.1. Preprocedure evaluation

1. Brief neurological exam should be done to establish a baseline, should a neurological change occur during or after the procedure.
2. The patient should be asked if he or she has had a history of iodinated contrast reactions.
3. The groins should be examined. These patients may have superficial yeast or bacterial infections that may require using alternative sites for venous access.
4. Blood work, including a serum creatinine level, serum glucose if diabetic and coagulation parameters, should be reviewed.

12.5.4.2. Preprocedure orders

1. NPO except medications for 6 h prior to the procedure.
2. Patients on insulin for hyperglycemia should get half their normal dose prior to the procedure.
3. Place a peripheral IV.
4. Place Foley catheter.

12.5.4.3. Preprocedure preparations

1. Some time before the procedure, 5 mL purple-top sample tubes are obtained and labeled with the patient information and numbered.
2. Ensure that a vial of ovine corticotrophin releasing hormone (oCRH) will be available.
3. Just prior to the procedure, a suitable container filled with ice should be obtained to transport the samples to the laboratory.

12.5.4.4. Contrast agents

For venous sampling procedures, only small amounts of contrast are required to confirmed proper catheter placement. Nonionic contrast agents are well tolerated and are usually used for these procedures. Iohexol (Omnipaque®, GE Healthcare, Princeton, NJ), a low osmolality, nonionic contrast agent, is relatively inexpensive and probably the most commonly used agent in venous sampling procedures. In patients with a history of severe anaphylactic reactions to iodinated contrast, the authors have used small quantities of Gadolinium-based MR contrast agents with good results.

12.5.4.5. Personnel requirements

Venous sampling procedures and IPSS procedures in particular require a number of assistants in the room to help obtain the samples and then assist in placing the samples in the laboratory tubes and then organizing them in a meaningful way. Three samples must be simultaneously obtained, requiring three people (e.g., one attending physician, one fellow, and one scrub nurse) to be scrubbed and at the sterile field. Two or three circulating nurses or other nonsterile personnel take the syringes containing the samples. One of them should be responsible to check each sample is placed in its proper vial and then placed in the iced container for transport to the lab.

12.5.4.6. Femoral venous sheath

Bilateral femoral venous sheaths are necessary for IPSS procedures. It is helpful to have one sheath of appropriate size for the catheter and another sheath, one French-size larger to allow a peripheral venous sample to be obtained from the femoral sheath. For example, when using 5 F catheters, the right-sided sheath is 5 F and the left, 6 F.

12.5.4.7. Saline infusion

As with any endovascular procedure, continuous heparinized saline drips (10 units heparin per milliliter of 0.9% normal saline) are attached to stopcocks on the sheath, guiding catheter, and microcatheter lumen.

12.5.4.8. Anticoagulation

Systemic heparin (50–70 units kg⁻¹ body weight) is administered intravenously when the sheaths are in place.

12.5.4.9. Sedation/Analgesia

The use of sedation should be minimized, since many drugs can temporarily affect baseline ACTH production.

12.5.5. Suggested wires and catheters for petrosal sinus sampling

12.5.5.1. Hydrophilic wires

- The 0.035 in. angled Glidewire® (Terumo Medical, Somerset, NJ) is soft, flexible, and steerable.
- The 0.038 in. angled Glidewire® (Terumo Medical, Somerset, NJ) is slightly stiffer than the 0.035 in. and helpful when added wire support is needed, but is too stiff to routinely use it in the petrosal sinuses.
- Softer, yet torquable wires such as the Gold-tip Glidewire® (Terumo Medical, Somerset, NJ) can be helpful in navigating occasional awkward valves in the lower internal jugular and for accessing the inferior petrosal sinuses.

12.5.5.2. Catheters for petrosal sinus sampling

There are two schools of thought regarding the general types of catheters used for petrosal sinus sampling. The more traditional method has been to use soft-tip, simple angle 4 or 5 French catheters placed in the very caudal aspects of the inferior petrosal sinuses. A second method is to use 4, 5 or 6 French guiding catheters in the jugular veins at the orifice of the inferior petrosal sinus and then obtain the samples via a microcatheter coaxially placed through the guiding catheter and into the inferior petrosal sinus:

- Soft-tip, simple angle catheters for sampling the caudal IPS: 4 or 5 French Berenstein curve Soft-Vu® (Angiodynamics, Queensbury, NY) or 4 or 5 French Angled Glide-catheter® (Terumo Medical, Somerset, NJ).
- Guiding catheters used for coaxial approach include standard 5 or 6 French large-lumen gauge guide catheters such as the 5 or 6 French multipurpose curve Envoy® (Cordis Neurovascular, Miami Lakes, FL).
- Microcatheters used for the coaxial approach should be braided with a relatively large internal lumen, such as RapidTransit® (Cordis Neurovascular, Miami Lakes, FL).

12.5.6. Procedures

12.5.6.1. Femoral venous access

1. The groin area is prepped bilaterally and draped.
2. The femoral pulse is palpated at the inguinal crease, and local anesthesia (2% lidocaine containing sodium bicarbonate (1 mL per 10 mL of lidocaine)) is infiltrated medial to the pulse, both by raising a wheal and injecting deeply toward the vein. Do not forget to aspirate from the needle before each injection of local anesthesia to prevent intravascular injection.
3. 5 mm incision is made parallel to the inguinal crease with an 11-blade scalpel.
4. An 18 gauge Potts needle is advanced with the bevel facing upward. The needle is advanced at a 45° angle to the skin.
5. Dark red blood aspirated from the needle using a 10 cc syringe confirms puncture of the femoral vein.
6. A 0.038 in. J-wire is advanced under fluoroscopic visualization into the inferior vena cava.
7. Depending on the size of the catheter being used, a 5 or 6 French sheath is placed in the right femoral vein and another in the left femoral vein. When using 5 French catheters, for example, one sheath can be 5 French and the other 6 French, to allow aspiration of peripheral venous samples from around the catheter in the larger diameter sheath.

12.5.6.2. Catheter manipulation

1. Attach the two 5 French catheters to rotating hemostatic valves and attach a three-way stopcock and continuously infuse saline containing 10,000 units heparin per liter.

2. Through each femoral venous sheath, advance a 5 French catheter into the contralateral internal jugular vein. This crossed catheterization method allows for optimal mechanical advantage in catheterizing the more difficult left internal jugular from the closer right femoral sheath.
3. Once in the internal jugular veins, direct each catheter superomedially to point into the inferior petrosal sinuses. If the catheter curve matches the angle of the IPS, the catheter can be gently advanced into inferior part of the sinus.
4. If the catheter does not easily pass into the sinus, a steerable, soft tip 0.035 in. or smaller guidewire can *very, very gently* manipulate the antero-supero-medially into the IPS, and the catheter gently advanced over the wire.
5. Warn the patient that the catheter manipulation may cause discomfort.
6. Contrast injected at the jugular bulb may opacify a part of the IPS, and can be used as a roadmap. Once one IPS is successfully catheterized, a gentle contrast injection can be used to obtain a roadmap of the other IPS, due to reflux up into the cavernous sinus across the circular sinus into the contralateral cavernous sinus and IPS.
7. Aim for the largest venous channel draining from the cavernous sinus, since the IPS may consist of a number of distinct vessels.
8. If the wire and or catheter head *inferomedially*, one is in the condylar vein and needs to reposition the catheter. Note that the condylar vein and IPS may connect together as they join the jugular.
9. Once the right and left IPS catheters are in position, perform a gentle injection of 2–5 mL of contrast for a selective venogram. The catheter is in a good position if contrast refluxes up into the cavernous sinus. The venogram is also studied for venous drainage patterns that may affect the lateralization of tumors with the IPS sampling (e.g., dominant drainage of both cavernous sinuses into one IPS).
10. If using microcatheters to aspirate the samples, with 5 or 6 French guiding catheters placed in the internal jugular pointing toward the IPS, gently advance a large-lumen (0.021 in. or larger) microcatheter over a soft-tip micro-wire into the IPS using roadmap guidance. The tip should be in the straight part of the IPS, and preferably not below any large connecting veins between right and left IPS.
11. Venous samples can then be obtained.

Venous access tips

- Cushing's patients may be quite obese, which makes palpating the artery difficult. Moreover, the femoral vein may be surprisingly medial on some patients.
- If one femoral vein can be accessed, but not the other, a reverse-curve catheter like Simmons 1 should be advanced through the sheath and into the contralateral iliac vein. A wire can then be advanced into the common femoral vein and used to fluoroscopically localize the vein or advance the catheter over the wire into the femoral vein, inject contrast, and obtain a roadmap image to guide needle placement in the vein.
- Patients with deep venous thrombosis may have chronic occlusion of the femoral veins. As long as one femoral vein is patent, the vein is usually big enough to place two sheaths in the patent vein, one slightly more distal than the other.
- The authors have also placed two sheaths in one femoral vein in patients having a superficial infection in one groin, or in patients with venous anomalies such as a left iliac vein that does not connect to the inferior vena cava.
- If there is occlusion of one internal jugular, or the IPS has an anomalous connection to the vertebral-venous system rather than the jugular bulb, it may not be possible to obtain IPS samples from that side. However, if the other IPS can be catheterized, it may be possible to advance one microcatheter into the ipsilateral cavernous sinus. Then, using a second catheter placed in the same jugular or through the same guiding catheter if a 6 or 7 French catheter is used, a second microcatheter may be advanced into the cavernous sinus, then across the posterior intercavernous sinus and into the contralateral cavernous sinus. Thus, bilateral cavernous sinus sampling can be performed.

12.5.6.3. Inferior petrosal sinus sampling

1. *Simultaneous* 3 mL venous samples are obtained from the right and left IPS catheters as well as a peripheral venous sample obtained from the larger femoral venous sheath. Therefore, three scrubbed operators are needed to draw the samples.
2. Before each sample is obtained, attach a “waste syringe” to the catheter and aspirate the dead-space of the catheter, usually 2 mL for a 5 French catheter or 0.3 mL for a microcatheter.
3. One or more sets of samples are obtained to determine baseline ACTH values.
4. The author obtains three sets of baseline samples, at 5 min intervals, to ensure a greater likelihood that an ACTH peak would be observed, given the known pulsatile secretion of an ACTH.^{14,15}
5. Draw the right IPS, left IPS and peripheral venous samples all simultaneously. Aspirate the samples slowly and steadily for approximately 60 s, to prevent collapsing the vein around the catheter and also the dilution of the petrosal sinus sample from blood pulled retrograde from the jugular or condylar veins by too vigorous an aspiration.
6. The three syringes are handed to circulating assistants who place each blood sample into an appropriately labeled tube, which is then put in an ice-filled container.
7. It has to be ensured that the correct sample syringe is used to fill the correct sample tube. The authors use sterile colored stickers on the syringes (Table 12.1). This color coordination can be used to make a similar sterile marking on the proper stopcock of the respective catheter. The receiving sample tubes are also prelabeled with an identifying number. A preprinted worksheet (Table 12.2) with the tube numbers, the time of sampling, and the site, acts as a key, allowing one to later interpret the results obtained from the lab.
8. After each sample is obtained, the catheter and sheath are gently flushed with heparinized saline to clear the blood from the lumen.
9. Care must be taken during all these maneuvers to avoid pushing, pulling or torquing the catheters.
10. Repeat selective venograms should be obtained via the IPS catheters after the baseline samples are obtained, to confirm that good catheter position is maintained.
11. Via a peripheral venous access, the patient is given $1\mu\text{g kg}^{-1}$ body weight oCRH up to a maximum of $100\mu\text{g}$.
12. At least two sets of samples are obtained at timed intervals after the oCRH is flushed into the venous line. The authors obtain sample sets 1, 3, 5, and 10 min after the CRH administration.

Table 12.1 Color codes for specimen tube labels

R = RED	RED = right inferior petrosal sinus (RIPSS)
L = YELLOW	YELLOW = left inferior petrosal sinus (LIPSS)
P = BLUE	BLUE = peripheral

12.5.6.4. Cavernous sinus sampling

1. The procedure is very similar to the procedure of inferior petrosal sinus sampling using microcatheters.
2. Bilateral femoral venous sheaths are inserted; one side is one French larger than the size of the guiding catheter used to allow peripheral venous sampling via the sheath.
3. 5, 6, or even 7 French, multipurpose curve guiding catheters are advanced via the femoral sheaths into the contralateral internal jugular veins, pointing toward the inferior petrosal sinuses.
4. The authors use standard 5 French, soft-tip catheters, which can be placed in the inferior aspect of the IPS with little discomfort to the patient. The bigger, stiffer catheter sizes should be kept in the jugular to minimize discomfort.
5. Gentle contrast injections can be used to obtain a roadmap of the IPS.
6. Through a rotating hemostatic valve attached to the guide catheter, advance a large-lumen microcatheter such as RapidTransit® (Cordis Neurovascular, Miami Lakes, FL).
7. Gently advance the microcatheter over a steerable, soft-tip microwire such as a 0.014" Soft-tip Transend™ (Boston Scientific, Natick, MA) into the IPS.

Table 12.2 IPS sampling worksheet

Venous Sampling				
Patient _____		Date _____		
Diagnosis _____				
Sample no.	Sample site	Time (min)	Actual time	Comments
1	RIPS	-15		
2	LIPS			
3	PERIPHERAL			
4	RIPS	-10		
5	LIPS			
6	PERIPHERAL			
7	RIPS	-5		
8	LIPS			
9	PERIPHERAL			
10	RIPS	0		CRH dose _____
11	LIPS			mcg @
12	PERIPHERAL			
13	RIPS	1		
14	LIPS			
15	PERIPHERAL			
16	RIPS	3		
17	LIPS			
18	PERIPHERAL			
19	RIPS	5		
20	LIPS			
21	PERIPHERAL			
22	RIPS	10		
23	LIPS			
24	PERIPHERAL			

8. Whenever possible, advance the microcatheter though straight segment of the sinus with the wire pulled back into the catheter, to minimize the risk of wire perforation.
9. Warn the patient that some discomfort may result as the catheter is advanced up the IPS.
10. Gently position the tip of the microcatheters in the posterior cavernous sinus bilaterally.
11. One is then ready to obtain samples as described above for sampling in the IPS.

12.5.6.5. Jugular venous sampling

Sampling from the jugular bulb can be obtained in cases in which the IPS is difficult to catheterize directly, or if the operator is inexperienced with catheterization of the sinus.

Catheter navigation is essentially the same as for IPS sampling, up to the point of positioning a 5 French catheter at each jugular bulb. Samples are then obtained from the 5 French catheters, and again a peripheral sample from one of the femoral sheaths, as described for IPS sampling.

12.5.6.6. Puncture site care

Once the samples are obtained, the catheters are removed and hemostasis obtained, as discussed above in the general comments. Since Cushing's patients

frequently have received insulin for their hyperglycemia, it may not be advisable to use protamine to reverse heparin, as protamine administration can cause hypotension. Unless the patient has never received NPH insulin, it is best to leave the sheaths in place until the ACT returns to normal. The sheaths can then be removed and hemostasis should be obtained by manual pressure. Closure devices are generally not necessary for venous punctures. The patient should be kept on strict bed rest with legs extended for at least 2h, depending on the sheath size. The authors apply a Syvek hemostatic patch (Marine Polymer Technologies, Danvers, MA) then keep the patient at bed rest for 2h for 6 French sheath sizes.

Petrosal sinus sampling: tips for avoiding complications

- Use soft-tip catheters and guidewires under roadmap guidance, and be extremely gentle to prevent venous injury or perforation.
- Use systemic heparin and meticulous flushing technique to prevent thrombosis.
- Pay attention to the patient: Severe pain, dizziness, nausea, facial/oral numbness or double vision could indicate something bad is happening.
- Unexplained labile hypertension can be a sign of impending brainstem ischemia, and could indicate that it is time to pull back the catheters.⁸

12.5.7. Venous sampling: Interpretation of results

12.5.7.1. Petrosal sinus sampling

Sampling for Cushing's is done to confirm a pituitary source ("Cushing's disease") vs. an ectopic origin of abnormal ACTH production. To evaluate the results of the petrosal sinus sampling, ratios of the ACTH level in the IPS divided by the ACTH level in the peripheral sample is calculated. A ratio of 2:1, IPS:peripheral before CRH or 3:1 after CRH is considered diagnostic of a pituitary source of ACTH.¹⁶ Reports from the National Institutes of Health have the greatest number of patients and show that, using the 2:1 ratio as a threshold, basal IPS sampling correctly identified 205 out of 215 surgically confirmed cases of Cushing's disease for a sensitivity of 95% and no false positives for a specificity of 100%.¹⁶ After CRH administration, and using a 3:1 ratio as a threshold, sampling identifies all the Cushing's disease patients, resulting in 100% sensitivity and 100% specificity with no false positives.¹⁶ Other studies with smaller numbers of patients with somewhat lower success rates, have still shown sensitivity and specificity over 90%.¹⁷⁻¹⁹ The Italian Study Group¹⁹ found that the best success with IPS:peripheral ratios of 2.1:1 for basal IPS sampling and 2.15:1 for post-CRH sampling; however other reports²⁰ confirmed the validity of the 2:1 and 3:1 ratios.

IPS sampling can indicate that the patient's abnormal ACTH levels are produced by a pituitary adenoma with a fair degree of certainty, but can it determine the side of the pituitary adenoma? In vivo experiments showed that mixing of blood between the cavernous sinuses is minimal, and therefore sampling of blood from the petrosal sinus gives an accurate sample of what is coming from each cavernous sinus.²¹ There was early enthusiasm that petrosal sinus sampling could be used to pinpoint the side of the pituitary in which the causative adenoma was located.²² The NIH group found that, using a threshold of a difference of at least 1.4 times the contralateral IPS the ACTH-producing lesion would be correctly located around 68% of the time, based on baseline samples and 71% after CRH.¹⁶ One cause of unsuccessful lateralization of the tumor by IPS sampling is a hypoplastic IPS,²³ associated with asymmetric drainage of both cavernous sinuses to one IPS. Side-to-side IPS ratios were better at lateralizing the lesion when selective venograms showed symmetric drainage of the cavernous sinuses to their respective IPS.²⁴ There may be a limit to the ability to lateralize the lesion since there is a tendency for one side of the pituitary to be dominant, even in normal individuals.²⁵ Other causes of false lateralization include multiple adenomas, which were found in 13 out of 660 (2%) patients undoing surgery for Cushing's disease.²⁶ Even more unusual are ectopic adenomas within the cavernous sinus²⁷ as a potential cause of false localization.

Petrosal sinus sampling: ratios to remember

- IPS:peripheral ratio of 2 or more pre-CRH indicates a pituitary adenoma producing ACTH (Cushing's disease).
- IPS:peripheral ratio of 3 or more post-CRH indicates Cushing's disease.
- IPS:IPS ratio of 1.4 or more indicates the side of the lesion.
- If the IPS:IPS ratios pre- and post-CRH each suggest a different side of the lesion, the results cannot be relied upon to lateralize the lesion.²⁸

Examples of IPSS results: three real-life cases, with analysis of results

Sample patient A

Sample no.	Sample site	Time	ACTH level
1	RIPS	-10	
2	LIPS		
3	PERIPHERAL		
4	RIPS	-5	561
5	LIPS		26
6	PERIPHERAL		10
7	RIPS	0	823
8	LIPS		29
9	PERIPHERAL		9
10	RIPS	1 min post-CRH	
11	LIPS		
12	PERIPHERAL		
13	RIPS	3	12,823
14	LIPS		611
15	PERIPHERAL		24
16	RIPS	5	5,796
17	LIPS		319
18	PERIPHERAL		27
19	RIPS		3,792
20	LIPS		299
21	PERIPHERAL		19

Discussion: A classic result. IPS:peripheral ratio is over 2 for all IPS samples pre-CRH and much more than 3 post-CRH. Therefore the lesion must be in the pituitary. The right IPS is greater than 1.4 times the left IPS, so the lesion should be on the right. All samples dramatically exceed the threshold ratios. Diagnosis: A right-sided pituitary adenoma was successfully located and removed at surgery.

Sample patient B

Sample no.	Sample site	Time	ACTH level
1	RIPS	-10	59
2	LIPS		321
3	PERIPHERAL		28
4	RIPS	-5	184
5	LIPS		236
6	PERIPHERAL		27
7	RIPS	0	127
8	LIPS		405

Sample patient B (continued)

Sample no.	Sample site	Time	ACTH level
9	PERIPHERAL		26
10	RIPS	1 min post-CRH	26
11	LIPS		266
12	PERIPHERAL		322
13	RIPS	3	5,154
14	LIPS		4,912
15	PERIPHERAL		26
16	RIPS	5	1,086
17	LIPS		1,757
18	PERIPHERAL		50
19	RIPS	10	1,159
20	LIPS		1,422
21	PERIPHERAL		74

Discussion: MRI suggested a right pituitary adenoma. All readings show a 2:1 IPS:peripheral ratio pre-CRH and almost all readings show at least 3:1 IPS:peripheral ratio post-CRH, indicating Cushing's disease from a pituitary adenoma. Notice at 1 min post-CRH the RIPS value is the same as the previous peripheral value. This likely indicates the samples were mixed up somehow. It may also be noted that at 3 min post-CRH, there is higher ACTH in the right IPS, even though the remaining times show higher values in the left IPS. Therefore, one would predict a left pituitary source of ACTH, in contradiction to the right-sided prediction by MRI.

Diagnosis: A right-sided adenoma was removed at surgery. The IPSS therefore was incorrect as to the side. The venography during the study showed no venous anomalies or asymmetry. This shows the major limitation to IPSS, since it correctly lateralizes the lesion only about 70% of the time.¹⁶

Sample patient C

Sample no.	Sample site	Time	ACTH level
1	RIPS	-10	46
2	LIPS		141
3	PERIPHERAL		12
4	RIPS	-5	35
5	LIPS		157
6	PERIPHERAL		11
7	RIPS	0	46
8	LIPS		201
9	PERIPHERAL		14
10	RIPS	1	255
11	LIPS		477
12	PERIPHERAL		14
13	RIPS	3	542
14	LIPS		1,185
15	PERIPHERAL		24
16	RIPS	5	827
17	LIPS		1,416
18	PERIPHERAL		41
19	RIPS	10	600
20	LIPS		1,419
21	PERIPHERAL		77

Discussion: Consistently higher values are seen in either IPS compared to peripheral and left compared to right.

Diagnosis: A left-sided pituitary adenoma was removed and the patient's serum ACTH and cortisol returned to normal.

12.5.7.2. Cavernous sinus sampling

The results of cavernous sinus sampling are variable. A group of 93 patients studied by an experienced endovascular group had successful catheterization of the cavernous sinuses with zero complications and sampling successfully diagnosed a pituitary source of ACTH in 93% of cases pre-CRH and 100% post-CRH correctly predicting the side of the lesion in 83% of all cases, and 89% of those with symmetrical venous anatomy and good catheter position.²⁰ This is similar to the larger IPS sampling studies in terms of safety and accuracy, although cavernous sinus sampling seems better for lateralizing the lesion. Another series of over 90 patients from an experienced endovascular group also had no complications but showed accuracy of diagnosing Cushing's disease of 86% for cavernous sinus sampling compared to 97% for IPS sampling and 100% using both sites, but successful lateralization in only 62–68%.²⁹ Cavernous sinus sampling accuracy suffers when CRH is not used^{30,31} or if samples from each sinus are not obtained simultaneously.³² There was one report of complications from cavernous sinus sampling, consisting of transient sixth cranial nerve palsies in two cases.³³ Most centers prefer IPS sampling since it is simpler, less invasive, and there is more experience with that technique. The authors use cavernous sinus sampling in selected cases when venous anatomic variants make IPS sampling more difficult or in cases in which IPS sampling results are equivocal.

12.5.7.3. Jugular venous sampling

In centers where there is limited experience with petrosal sinus catheterization, jugular venous catheterization is a much simpler, and presumably safer, alternative. A comparative study showed sensitivity of jugular venous sampling of 83% with 100% specificity compared to a sensitivity of 94% with 100% specificity for IPS sampling.³⁴ Consequently, if jugular venous sampling is positive for Cushing's disease, then the patient should respond to trans-sphenoidal surgery, and if the sampling results are negative or equivocal, the patient could be referred to a center with more experience in IPS or cavernous sinus sampling.

12.5.7.4. Venous sampling in suspected ectopic ACTH production

If IPS:peripheral ACTH gradients are less than two pre-CRH or less than three post-CRH, the test is considered negative for a pituitary source (Cushing's disease) and an ectopic source of ACTH is then presumed. The first step is to exclude a false negative test. The NIH group had 0.8% false negative IPSS results related to a hypoplastic IPS on the same side as a pituitary adenoma.²³ Therefore, one should review the venograms obtained during the study, and, if there are venous anomalies, repeating the study with cavernous sinus sampling may be considered. One could even consider surgical exploration of the sella if there is elevation of ACTH to CRH in peripheral blood samples, and no other source of ACTH is found on body imaging.³⁵ If body imaging is not conclusive for an ectopic source of ACTH such as a bronchial carcinoid, sampling from various sites throughout the venous system may help focus the search for the lesion. The authors had a case with negative IPSS, and on a repeat sampling procedure, samples from the jugular veins, facial veins, vertebral veins, subclavian veins, and vena cava showed high ACTH in only one jugular and the highest levels in the ipsilateral facial vein. That patient had a maxillary sinus lesion that resembled a polyp on MRI, but was on endoscopic surgery found to be a secretory adenoma producing ACTH.

12.5.7.5. Venous sampling in acromegaly

Using techniques identical to those used in the setting of Cushing's syndrome, IPSS to measure growth hormone levels can be done in patients suspected to have acromegaly, but who have equivocal laboratory and imaging studies. IPSS was found useful to make the diagnosis of acromegaly in a small group of patients with equivocal imaging studies.³⁶ Side-to-side gradients of growth hormone have not proved to be reliable.^{36,37}

12.5.8. Other venous sampling procedures

Venous sampling has been shown to be useful to locate secretory adenomas in cases of recurrent hyperparathyroidism after parathyroid surgery.³⁸ This sampling involves taking samples from various neck veins, including the internal and external jugular, the inferior thyroid veins, and brachiocephalic veins. Sampling of the internal thoracic and vertebral veins has been advocated to look for ectopic locations of parathyroid adenomas.³⁹ Other endocrine tumors can be localized by venous sampling, but those procedures are beyond the scope of this handbook.

12.6. Transvenous embolization

12.6.1. Background

Some arteriovenous fistulas may comprise multiple arterial feeders converging on a single venous structure. In this situation, it may be more efficient to perform transvenous embolization rather than occluding a large number of individual arterial feeders. The target venous structure may be occluded without any detrimental effects on venous drainage of the brain or other normal tissues in the region, since, due to the arteriovenous shunt, venous drainage theoretically is away from, rather than toward this draining vein or sinus. A number of conditions must be met, however, to ensure that transvenous embolization can be successfully performed with relatively low risk of complications. The target venous structure should be at the site of entry of the arterial feeders. Occluding the venous outflow too far downstream will allow the fistula to remain patent, draining by collateral pathways and potentially creating dangerous venous hypertension in these collateral vessels. Imaging studies, especially angiographic studies, must be carefully studied to ensure that no veins draining the brain or other normal structures drain toward the vessel to be embolized. It should only be occluded if normal veins drain away from, rather than toward it. For pial arteriovenous shunts, *there must not be an intervening arteriovenous malformation nidus* between the artery and vein to be occluded. Blocking veins of a true arteriovenous malformation prior to occluding the arterial feeders and nidus is a recipe for disaster with a high risk of hemorrhage from the nidus. Similarly, in direct arteriovenous fistulas that have aneurysms on the feeding arteries, occlusion of the draining vein risks aneurysm rupture as the pressure on the arterial side suddenly increases.

Another crucial condition for performance of transvenous embolization is that the venous target must be accessible. Some fistulas drain into veins that may be small or tortuous before they enter a larger collecting venous structure. For example, pial arteriovenous fistulas often drain into a series of extremely tortuous cortical veins before draining into cavernous or transverse sinuses, making transvenous access to the fistula difficult, if not impossible. Moreover, arteriovenous fistula may be associated with considerable venous occlusive disease, often blocking direct venous access to the fistula. Dural fistulas, in particular, are thought to arise in association with venous thrombosis. It is precisely those fistulas having occlusion of the primary venous outlets and reflux into tortuous cortical veins that are the most dangerous lesions requiring definitive occlusion. Fistulas that are inaccessible via an endovascular route for transvenous therapy may still be treated using direct intraoperative access to the draining vein, allowing deposition of coils or liquid embolic agents to occlude the fistula.

12.6.2. Indications for transvenous embolization

1. Cavernous dural arteriovenous fistula (dAVF).
2. Direct carotid-cavernous fistula (CCF) patients who are poor candidates for transarterial embolization (e.g., Ehlers–Danlos or other connective tissue disorder, recent trauma, difficult arterial access, etc.).
3. Transverse, sigmoid, or superior sagittal sinus dAVF draining into a sinus adjacent to a site of occlusion of that sinus.
4. Vein of Galen aneurysmal malformations of the typical mural-type and with certain caveats (see below).

5. Vertebral-venous fistula (VVF).
6. Certain, rare direct pial fistulas.
7. Certain, rare spinal fistulas.

12.6.3. Complications of transvenous embolization

Informed consent prior to the procedure should include an estimate of the risk of complications.

12.6.3.1. Neurological complications

1. Access-related complications may include perforation or rupture of intracranial venous structures, causing subarachnoid or subdural bleeding.
2. There is a risk of venous infarction and associated intraparenchymal hemorrhage if one occludes vital intracranial venous structures.
3. There can be worsening of symptoms of venous hypertension if a venous outlet is occluded and the arteriovenous fistula remains patent, redirecting flow into other venous pathways.
4. A risk of arterial-side complications can occur if a related arterial embolization is performed as part of the procedure.
5. Transvenous liquid acrylic embolization of an arteriovenous fistula risks reflux of glue into arterial feeders and further reflux into normal arterial territories if the injection is overly aggressive, or if it is done without optimal biplane fluoroscopic imaging.
6. Brain abscess has been reported after transvenous embolization.⁴⁰
7. Given the relative infrequency of the use of this procedure, estimates of complication rates are only rough guesses, although a recent series of 31 cases treated with transvenous embolization suffered approximately 10% neurological complications, with no permanent deficits.⁴¹ In a series of 135 cases of cavernous dural fistulas, 6% had complications and 2% had permanent deficits, but an unspecified number of these cases underwent transarterial embolization along with, or instead of transvenous embolization.⁴²
8. Even after successful transvenous embolization of a dural fistula, delayed development of a second fistula at a different site can occur.^{43,44}

12.6.3.2. Non-Neurological complications

1. Coils or other embolic agents might embolize to the pulmonary circulation.
2. Anaphylactic reactions to iodinated contrast or any of the medications used can occur as with any endovascular procedure.
3. Similarly, groin hematomas can occur, but are less common and less severe compared to arterial punctures.
4. Venous thrombosis can occur anywhere along the catheter path or in the pulmonary circulation.
5. Anesthesia-related complications can occur.
6. Patients with Ehlers–Danlos syndrome can experience a wide variety of complications related to their connective tissue fragility, including retroperitoneal hematoma and bowel perforation.^{45,46}

12.6.4. Transvenous embolization: Procedural aspects

12.6.4.1. Preprocedure evaluation

1. A brief neurological exam should be done to establish a baseline, should a neurologic change occur during or after the procedure.
2. The patient should be asked if he or she has had a history of iodinated contrast reactions.
3. The groins should be examined. Feel for the femoral arterial pulse, which provides a landmark for femoral venous access.
4. If jugular access is anticipated, examine the neck. Observe the jugular venous pulsation, if visible. Palpate the carotid pulse.

5. Ask the patient about any history of deep venous thrombosis which may require using special sites for venous access.
6. Blood tests, including a serum creatinine level, serum glucose if diabetic and coagulation parameters, should be reviewed.
7. Airway issues, history of previous general anesthesia, and any other coexisting medical issues that could impact the use of general anesthesia should be checked.

12.6.4.2. Preprocedure orders

1. NPO for 6 h, except for medications.
2. Patients on insulin for hyperglycemia should get half their normal dose prior to the procedure.
3. Place a peripheral IV.
4. Place Foley catheter.

12.6.4.3. Contrast agents

Standard nonionic contrast agents like Iohexol (Omnipaque[®], GE Healthcare, Princeton, NJ), are generally used for these procedures.

12.6.4.4. Venous access sheath

Transvenous embolization procedures are almost always done using a femoral venous sheath, most commonly a 6 French, 25 cm sheath. Alternatively, one can use a 5 or 6 French 90 cm sheath, like the Shuttle[®] sheath (Cook, Inc., Bloomington, IN) which also acts as a guiding catheter. In rare cases, to improve access to the intracranial sinuses, using ipsilateral retrograde jugular venous access may be considered. In such cases, use a short, 10 cm 4 or 5 French sheath for jugular access.

12.6.4.5. Anticoagulation

Use of systemic heparin varies among practitioners of transvenous embolization, but jugular and femoral venous thrombosis has occurred in patients with fistulas embolized without systemic heparin.⁴¹ The authors think it is prudent to use heparin in these procedures. During the procedure, after access is obtained, administer 50–70 units kg⁻¹ intravenous heparin bolus.

12.6.4.6. Sedation/Anesthesia

Most commonly, transvenous embolization is performed with the patient under general anesthesia. Any catheterization above the skull base can produce significant discomfort, and the procedure may take considerable time, so it is advisable to use general anesthesia. The lower systemic pressure attainable under general anesthesia also allows coil embolization with a lower risk of migration of coils from their intended destination. Intraoperative embolization also definitely requires general anesthesia.

12.6.5. Suggested wires and catheters for transvenous embolization

12.6.5.1. Access wires

- Steerable hydrophilic wires like 0.035 or 0.038 in. angled Glidewire[®] (Terumo Medical, Somerset, NJ) can be used to advance a guiding catheter into the jugular vein.
- Softer, yet torquable wires like the Headliner[™] or Gold-tip Glidewire[®] (Terumo Medical, Somerset, NJ) can be helpful for navigating occasional pesky valves in the lower internal jugular.

- Soft-tip Transend™, or Synchro™ (Boston Scientific, Natick, MA) or other 0.014 in. wire is used to advance the microcatheter to the target vessel.
- If using 170 cm microcatheters, a 200 cm guidewire will be necessary.

12.6.5.2. Guide catheters

If guide catheters are used, a fairly supportive catheter, such as the 6 French Northstar® Lumax® (Cook Medical, Inc., Bloomington, IN) is useful for transvenous embolization; it can however be placed only as high as the jugular bulb for access. Occasionally, a guide catheter may be required in the inferior petrosal sinus or transverse sinus to improve access to the target lesion. This requires a smaller, more flexible catheter, like the 4 or 5 French Angled Glide-catheter® (Terumo Medical, Somerset, NJ) or 5 French Guider Softip™ XF (Boston Scientific, Natick, MA).

12.6.5.3. Microcatheters

Large-lumen microcatheters, like a RapidTransit® (Cordis Neurovascular, Miami Lakes, FL), or Excelsior® 1018® (Boston Scientific, Natick, MA) are helpful for transvenous embolization, since they accept a wide variety of guidewires to facilitate access, and also allow use of various embolic agents, including pushable fibered platinum coils. In cases with associated venous stenosis or tortuosity, it may be necessary to use lower-profile microcatheters, such as the 1.7 French Excelsior® SL-10® (Boston Scientific, Natick, MA) or Echelon™ 10 (ev3, Irvine, CA). Access to the anterior superior sagittal sinus or vessels entering usually requires a 170 cm microcatheter (see *Venography* section). However, detachable coils are designed to be deployed via 150 cm microcatheters, which may limit the types of embolic agents that can be used with longer microcatheters.

12.6.5.4. Saline infusion

As with any endovascular procedure, continuous drips of heparinized saline are attached to stopcocks on the sheath, guiding catheter, and microcatheter lumen.

12.6.5.5. Embolic agents

- Detachable platinum coils: Very controllable and allow repeated use of the microcatheter. However, this approach requires large numbers of coils to close high-flow fistulas.
- Detachable fibered coils: Very controllable and more thrombogenic than bare platinum, but quite stiff; they require a larger lumen microcatheter.
- Pushable fibered coils: Help promote thrombosis better than bare platinum, but not easily retrievable if not properly positioned; they also require a larger lumen microcatheter.
- Liquid embolic agents: Injectable through a small microcatheter and achieves quick, secure occlusion, but hard to control in high-flow lesions and can potentially reflux into arterial structures.

12.6.6. Procedures

12.6.6.1. Venous access

1. The groin area is prepped bilaterally and draped.
2. The femoral pulse is palpated at the inguinal crease, and local anesthesia (0.25% bupivacaine) is infiltrated medial to the pulse, both by raising a wheal and injecting deeply toward the vein. (This reduces puncture site discomfort after the procedure.)
3. 5 mm incision is made parallel to the inguinal crease with an 11-blade scalpel.
4. An 18 gauge Potts needle is advanced with the bevel facing upward. The needle is advanced at a 45° angle to the skin.
5. Dark red blood aspirated from the needle using a 10 cc syringe confirms puncture of the femoral vein.

6. A 0.038 in. J-wire is advanced under fluoroscopic visualization into the inferior vena cava.
7. Successive dilators are used to dilate up to one French-size greater than the nominal sheath size being used.
8. Depending on the size and type of stent being used, a sheath is placed in the right (or left) femoral vein. Usually a 6 French, 90 cm Shuttle® sheath (Cook, Inc., Bloomington, IN).
9. The 90 cm sheath is advanced into the dominant jugular vein, or other major vein draining the venous structure to be embolized.
10. Alternatively, the jugular vein can be used for access to the ipsilateral dural venous sinuses. Retrograde jugular puncture is performed using a small vessel access system, as discussed in the general venous access comments above.
11. When the needle is in the vein, the 0.018 in. platinum-tip wire of the access kit is carefully advanced up the jugular vein, the needle removed, and the coaxial dilator inserted.
12. A 0.038 J-tip wire or Glidewire® (Terumo Medical, Somerset, NJ) retrograde is gently advanced into the jugular vein, as high as one can easily get it, to provide added support.
13. The tract may have to be dilated with a 5.5 French dilator; wire access should not be lost, and it must be ensured the wire does not traumatize the venous structure it is in.
14. A 10 cm long, 4 or 5 French sheath is advanced to the upper jugular vein.

12.6.6.2. Arterial access

With any transvenous embolization, an arterial catheter is helpful to allow for roadmap images and periodic arteriograms to monitor the progress of the embolization procedure:

1. Access the femoral artery contralateral to your venous access site.
2. Palpate the femoral pulse and make a skin wheal with local anesthetic.
3. Make a small dermatomy with the 11-blade scalpel.
4. Puncture the femoral artery with an 18 gauge Potts needle.
5. Insert a 0.035 or 0.038 J-wire through the needle into the abdominal aorta under fluoroscopic control.
6. Remove the needle and insert a 4 French, 10 cm sheath into the artery.
7. Through the sheath, advance a 4 French diagnostic arteriography catheter into the arterial system that supplies the fistula being treated.
8. Attach the catheter to a three-way stopcock for continuous infusion of heparinized saline.
9. Perform an arteriogram to determine the optimal site of transvenous embolization and optimal views to see the venous approach to the fistula.
10. Periodically inject contrast via the arterial catheter for roadmap imaging of the target vein and venous pathways emanating from it.
11. During the embolization, periodically perform arteriographic runs to ensure the embolization is progressing as planned, and determine the endpoint of the embolization.

12.6.6.3. Intracranial access

1. Through the venous sheath or guiding catheter in the jugular, advance the desired large-lumen microcatheter, such as the RapidTransit® (Cordis Neurovascular, Miami Lakes, FL) over a wire, the 0.012 in. J-Tip Headliner™ (Terumo Medical, Somerset, NJ) or the 0.014 in. Soft-tip Transend™ (Boston Scientific, Natick, MA) gently through the jugular into the intracranial venous sinuses and advance the catheter to the venous structure to be embolized.
2. One may need to periodically remove the guidewire and contrast through the microcatheter to confirm that the pathway is right. Even if one is using an arterial catheter for roadmap imaging, at times, closely parallel venous structures may appear to be heading toward the target on roadmap images, but really be leading in the wrong direction.
3. Place the microcatheter at the venous structure to be embolized, and, if it has not already been done, perform venography to confirm proper positioning of the catheter.
4. Be gentle with catheter and wire manipulation, and use *extreme caution* when catheterizing deep venous structures, cortical veins, or small venous structures. These are very fragile and deformable by stiff catheter systems.

5. Even if a venous sinus appears thrombosed angiographically, it may be possible to gently probe with a soft-tip wire and advance a low-profile microcatheter through the occlusion.
6. If a stenosis or occlusion of a sinus that may have drained the fistula can be crossed with a microcatheter, one may consider stenting the lesion to reduce venous hypertension, as is discussed in *Transvenous Stenting* section.

12.6.6.4. Coil embolization

- As a general rule, deposit coils in the venous structure one wants to occlude, beginning from the area most distal to the point of endovascular access to the structure. Embolize from distal-to-proximal to ensure correct procedure.
- Also, be sure to block any potential outlets into cortical or brainstem veins, so that one is certain that dangerous cerebral venous hypertension will be relieved, even if the procedure fails to completely cure the fistula.
- In the case of a high-flow fistula, it is best to start with a detachable coil, oversized to the diameter of the vein being occluded. If it does not appear stable, *do not detach it*. Remove it and try a larger diameter coil or a 3D configuration coil.
- Once a coil is obtained to frame the vein and be stable, detach it.
- Place additional detachable coils to further frame and fill the space. The softest possible coils work best to pack tightly into the space available.
- If the microcatheter has a large enough lumen, it is helpful to intersperse some fibered coils to induce thrombosis. Care may be taken not to displace the microcatheter with the stiffer coils or jam the coils in the catheter.
- If a 170 cm microcatheter is being used, pushable fibered coils and not detachable coils (they require 150 cm catheters) would be required. These can be injected with a bolus of saline, although often the coil will not exit the catheter tip if the catheter takes a tortuous route or if the coil meets any resistance as it enters the vessel. A 180 cm or longer guidewire can be used to push out the coil; one must use a big enough diameter wire is to be certain that it cannot slide alongside the coil in the catheter.
- The injectable Berenstein Liquid Coil[®] (Boston Scientific, Natick, MA) can be delivered via a wide variety of catheters, but works best for occluding small vessels.
- Continue to pack coils in the venous structure being occluded. Alternate between ultrasoft coils to fill small spaces and fibered coils to promote thrombosis.
- Some operators advocate injection of 5 mm fragments of 2-0 silk suture via the microcatheter to promote thrombosis,⁴⁷ but these can jam in the catheter and are less predictable or controllable than pushable, detachable, or injectable coils.
- For a large venous sinus or venous varix, it will take a number of coils to block flow. At times even 20–40, or more coils have been used in a case.
- Periodic arteriograms during the procedure will indicate when the arteriovenous shunting slows and finally stops.

12.6.6.5. Liquid embolic embolization

There are two different methods of using liquid embolic agents in the setting of transvenous embolization. One involves first packing of the venous outlet of an arteriovenous fistula with coils placed by a transvenous approach. A catheter is then placed in a dominant arterial feeder via a transarterial approach. The other method involves direct injection of the liquid embolic agent via a transvenous catheter in the venous outlet of the fistula.

12.6.6.6. Transarterial n-BCA Injection

- This technique is used most commonly in high-flow fistulas to achieve quicker and more complete occlusion than transvenous coil embolization alone.
- Coils placed in the venous side of the fistula act like a filter to catch the embolic agent and prevent distal migration of embolic agent into the venous system.
- A 5 or 6 French guide catheter is necessary.
- Perform transvenous coil deposition in the venous outlet of the fistula, as discussed above.
- When one has achieved the desired packing density, and created a filter within the vein, the tip of the transvenous microcatheter can be withdrawn from the coil mass, so that it does not get glued in place.

- Advance either a flow-directed or over-the-wire type microcatheter to the arterial feeder supplying the fistula.
- Position the microcatheter distal to any normal branches.
- Carefully pull back slightly on the microcatheter to remove any slack, and gradually loosen the rotating hemostatic valve so that it just barely prevents backflow of blood in the guiding catheter, without binding the microcatheter too tightly.
- Confirm proper catheter positioning with a contrast injection via the microcatheter for a superselective arteriogram. One should select a projection that shows the microcatheter tip and its relationship to any curves in the arterial feeder distal to the catheter tip, any normal branches proximal to it, and the coil basket placed in the venous outlet.
- Study the superselective arteriogram carefully to schedule the arteriovenous transit time, and determine the morphology of the target arterial feeder and venous structure where the liquid agent will be deposited.
- Assuming one is using an acrylic adhesive glue like Trufill® *n*-BCA (Cordis Neurovascular, Miami Lakes, FL) prepare with Ethiodol oil at a dilution appropriate for the velocity of flow through the fistula. It is necessary to remember that as soon as the *n*-BCA contacts the coils, flow will start to slow, so the glue will need to be slightly more dilute than one might predict. With a fairly dense coil mass in the vein a 4:1, oil:glue mix often works well.
- Attach a glue-compatible stopcock directly to the microcatheter. Cook Medical (Bloomington, IN) makes a high-pressure, white nylon plastic, and three-way stopcocks with Luer-lock fittings that hold up well during glue injections.
- Thoroughly flush the microcatheter with 5% dextrose solution. As the last milliliter of dextrose is being injected, close the stopcock to prevent blood backflow into the microcatheter.
- Holding the stopcock upright, fill the Luer-lock connection fully with dextrose.
- Create a blank roadmap mask, so that one can view the glue injection under digital subtraction.
- Attach a 3 mL syringe loaded with the prepared glue mixture.
- Slowly, but steadily inject the glue using roadmap imaging, so that the glue column continuously moves forward.
- Fill the arterial feeder and the desired portions of the proximal part of the draining vein.
- Be alert for any signs of reflux of glue back along the catheter, passage of glue beyond the coil mass in the vein, or reflux of glue from the vein into other arterial branches feeding the fistula.
- If any of these conditions occur and one is using dilute glue, the injection may be briefly paused, then resumed cautiously. Sometimes the glue will find another pathway into the coil mass.
- If there is any question that the glue is refluxing or going elsewhere or if one has finished filling the desired space with glue, stop injecting, aspirate the syringe to create negative pressure in the microcatheter, and quickly, smoothly withdraw the microcatheter completely from the patient and discard it. It is best to pull the guiding catheter and microcatheter as a unit, but, if braided microcatheters are used one can just pull the microcatheter.
- Examine the rotating hemostatic valve of the guiding catheter for any retained droplets of glue, then aspirate and double flush the stopcock, rotating hemostatic valve, and guide catheter.
- Once the guide catheter is thoroughly inspected and flushed, reinsert it to the arterial territory of interest, and perform a follow-up arteriogram to ensure that the goal is accomplished.

12.6.6.7. Transarterial onyx® injection

- Have several vials of Onyx® (ev3, Irvine, CA) agitating in an automatic mixer for at least 30 min while performing other parts of the procedure.
- Coils are placed in the venous side of the fistula via a transvenous approach, and the venous microcatheter is withdrawn from the coil mass.
- This transarterial technique is similar to the technique using *n*-BCA glue regarding the catheterization of the arterial feeder, except one must use a dimethyl sulfoxide (DMSO)-compatible catheter like the over-the-wire type Rebar® (ev3, Irvine, CA) or more flexible Marathon™ (ev3, Irvine, CA).

- Confirm proper catheter positioning with a contrast injection via the microcatheter for a superselective arteriogram. One should select a projection that shows the microcatheter tip and its relationship to any curves in the arterial feeder distal to the catheter tip, any normal branches proximal to it, and the coil basket placed in the venous outlet.
- Study the superselective arteriogram carefully to schedule the arteriovenous transit time, and determine the morphology of the target arterial feeder and venous structure where one will deposit the Onyx[®].
- Select a premixed viscosity of the agent depending on the size of the feeder and degree of arteriovenous shunting. Big feeders with fast flow need Onyx[®] 34 and small feeders or slower shunting should be treated with Onyx[®] 18.
- Use the proper syringe supplied by ev3, draw up 1 mL of DMSO. The technique for handling Onyx syringes is illustrated in Fig. 7.3.
- Using a blank roadmap mask, slowly inject the Onyx[®] under roadmap visualization at a rate of approximately 0.2 mL min⁻¹.
- Continue injecting Onyx[®] as long as it flows forward into the desired areas.
- If it refluxes along the catheter, passes beyond the proximal part of the vein, or refluxes into other arterial feeders, pause the injection for 15 s, then resume injection. If the Onyx[®] continues to flow in the wrong direction, pause again for 15–30 s, and try again. If the Onyx[®] finds another, more desirable pathway, continue the slow injection.
- When adequate filling of the desired vascular spaces has been achieved, or if the Onyx[®] repeatedly flows in the wrong direction, stop injecting, aspirate back on the syringe, and slowly, but steadily pull back on the microcatheter, disengage it from the deposited Onyx[®] and remove it. The heavy-duty catheters used for Onyx[®] can usually be pulled back on their own, without pulling the guide catheter as well.
- After the microcatheter has been withdrawn from the guide catheter, examine the rotating hemostatic valve of the guiding catheter for any retained droplets of Onyx[®], then aspirate and double flush the stopcock, rotating hemostatic valve, and guide catheter.
- Once the guide catheter is thoroughly inspected and flushed, perform a follow-up arteriogram to ensure that all tasks have been accomplished.

12.6.7. Transvenous embolization: Tips on specific disease processes

12.6.7.1. Direct carotid-cavernous fistula

Direct CCFs tend to be high-flow fistulas, with considerable enlargement of venous outlets. These lesions also tend to present early, before high-flow venopathy produces stenosis or occlusion of potential venous access vessels. These characteristics create a paradox of easier access to the cavernous sinus via the transvenous route; but also greater necessity to completely close the fistula because of the high flow. In the era of detachable balloon therapy for CCF, transarterial embolization was aided by the high flow through the arteriovenous fistula, guiding the balloon through the fistula and into the cavernous sinus. Transvenous approaches were required when technical difficulties were encountered with the arterial access to the fistula.⁴⁸ Transvenous embolization should also be considered in patients with vessel wall fragility syndromes, such as Ehlers–Danlos, which can make transarterial embolization riskier.^{45,49} Thus transvenous embolization is more attractive, due to lower pressures on the venous side, which decreases the likelihood of catastrophic bleeding.⁴⁶

Venous access to the cavernous sinus can often be obtained via the inferior petrosal sinus,⁴⁵ and direct cut-down on the superior ophthalmic vein (SOV) in the orbit⁵⁰; or by various transfemoral approaches, like the pterygoid plexus.⁵¹ The aim is to have stable microcatheter placement for insertion of sufficiently large quantities of coils. This helps achieve thrombosis of the fistula itself and the cavernous sinus, as well as potentially dangerous outlets to cerebral cortical or brainstem veins; and the origin of the ophthalmic veins, since arterialized drainage into those veins is generally the source of symptoms in these patients. The general rule is to occlude the parts of the sinus that drain to dangerous or symptomatic outlets, going from the region most distal to the venous access point first, and ending with the region closest to the access point to the sinus. When placing coils near the actual site of the fistula, one has to

be careful not to let the coils pass through the fistula into the arterial side. This can sometimes be difficult in the case of a much dilated cavernous sinus, with large coil mass which may obscure the carotid. One can place a balloon, such as a Hyperform™ (ev3, Irvine, CA) in the carotid across the neck of the fistula, and inflate it periodically as coils are placed in the cavernous sinus. This will limit the risk of coils prolapsing through the fistula into the artery. However, the 0.010 in. guidewire of the balloon need to be placed well into the middle cerebral artery to stabilize the balloon and prevent it from being sucked into the cavernous sinus by the high-flow shunt. It is necessary to have a J-shape curve on the wire and this should not be allowed to get into a small branch or perforate the vessel. It may be simpler to place a Neuroform™ stent (Boston Scientific, Natick, MA) in the carotid across the fistula, to prevent coils from migrating from the cavernous sinus into the artery.

Direct access to the cavernous sinus through surgical exposure can allow coiling of the cavernous sinus.⁵² However, this approach is not commonly required, unless the venous anatomy is truly unfavorable or if failed transarterial and transvenous embolizations have blocked endovascular access.

12.6.7.2. Cavernous dural arteriovenous fistula

Cavernous dAVF treatment is routinely accomplished with transvenous embolization.⁴⁷ Since these fistulas flow slower than direct fistulas, one can achieve complete closure with only a few well-placed coils in the cavernous sinus. Transvenous access to the cavernous sinus is most directly and effectively accomplished via the inferior petrosal sinus (IPS). This can be successful even when the IPS appears to be occluded or absent on angiographic studies.⁴⁷ Passage of a J-tip hydrophilic wire and low-profile microcatheter can be done safely if done gently and carefully.⁵³ Fistulas that drain into the contralateral cavernous sinus via the circular sinus may be accessible by catheterization of the contralateral posterior cavernous sinus via the IPS, with passage of the catheter across the intercavernous sinus to the sinus draining the fistula. However, care needs to be exercised to determine the exact site of the fistula before starting to deploy coils in the cavernous sinus. If one is not certain about exactly where the shunt starts, one might block venous access to the fistula and redirect drainage into cortical or brainstem veins, or possibly worsen ocular venous hypertension if one blocks some of the venous outlets without fully occluding the fistula. To make matters worse, some cavernous dAVFs are bilateral, with arteriovenous shunts involving both cavernous sinuses. This may require packing of both sinuses, but before one does that:

1. Be absolutely sure there are bilateral shunts, rather than just drainage from one cavernous sinus to another.
2. Have a plan of attack so that one does not inadvertently block access to one cavernous sinus as the other is coiled.
3. Remember that, after one cavernous sinus has been coiled, it will obscure the contralateral cavernous sinus on a straight lateral view.
4. Try using some craniocaudal angulation on the lateral view to keep the two cavernous sinuses from overlapping and to get the coils in one cavernous sinus out of one's way for visualizing the contralateral sinus.

The SOV itself can be accessed via direct surgical exposure, passage of a detachable balloons⁵⁴ or coils⁵⁵ through a venotomy for embolization of the sinus.⁵⁴ As catheterization techniques have become more sophisticated, access to the cavernous sinus via the SOV can often be done through the facial vein without using a direct cut-down.^{56,57} This approach requires good imaging systems and finesse to navigate a soft wire and low-profile microcatheter around the curves as the straight angular vein connects to the loopy eyelid veins and into the SOV. The direct venotomy should be reserved for cases in which the more indirect endovascular approach has failed, since direct venotomy carries risk of local hematoma or nerve injury, especially if the vein is small.⁵⁸⁻⁶⁰ An even more extreme measure is to perform percutaneous direct puncture of the SOV deep in the orbit, when transvenous or direct cut-down fails.⁶¹ However, if one does get a hematoma in the deep orbit, it can be hard to control and result in optic nerve compression. The situation is within control if one directly exposes the vein surgically. For surgical exposure deep in the orbit, a craniotomy may be required. Various other access routes to the SOV can be done, including puncture of the jugular or facial veins to improve access, or percutaneous puncture of the frontal vein in the forehead⁶² or superficial temporal vein in the temporal scalp.⁶³

When transfemoral venous access via the IPS or SOV is not possible, other routes of entry may be required. Passage of a microcatheter from the jugular bulb and up the

sigmoid sinus to the superior petrosal sinus may allow catheterization of the cavernous sinus in selected cases.⁶⁴ When everything else fails, direct surgical exposure of the cavernous sinus can be performed where a microcatheter is inserted via a cortical vein⁶⁵ or other tributary⁶⁶ into the cavernous sinus. The authors have resorted to these open surgical approaches only in the case of dangerous fistulas with cortical venous drainage where less invasive endovascular approaches have been unsuccessful. It is to be understood that it is precisely those dangerous fistulas that will have a great deal of cortical venous congestion, and considerable bleeding is possible during the open procedure.

Although most transvenous embolization is done using coils, liquid embolic agents such as dilute *n*-butyl cyanoacrylate glue⁶⁷ (Trufill® *n*-BCA, Cordis Neurovascular, Miami Lakes, FL) or ethylene vinyl copolymer⁶⁸ (Onyx® ev3, Irvine, CA); these can be injected via a transvenous catheter to cast the cavernous sinus and occlude the fistula. The advantage of glue is that it polymerizes faster, can be used in a variety of catheter systems, and does not make the patient smell of DMSO like Onyx® does. The advantage of Onyx® is that it permits very slow and controlled deposition. Both agents must be injected very slowly and carefully, with constant vigilance for signs of reflux into some of the arterial feeders of the fistula, which could reflux into the ophthalmic or carotid arteries and cause serious neurological complications. One could inflate a balloon in the ipsilateral cavernous carotid during the liquid embolic injection, but that will not prevent reflux into the ophthalmic artery, which can blind the patient, or even to the contralateral cavernous carotid artery via parasellar and clival anastomoses from side to side. Either agent can be used in conjunction with coils placed in the cavernous sinus, but large numbers of coil may make it difficult to see the path of the liquid embolic agent. Needless to say, this procedure can only be tried by persons with considerable experience with either *n*-BCA or Onyx®.

Occasionally, a true intraorbital fistula may mimic cavernous dural fistulas clinically; even the angiographic studies may look like a cavernous dAVF if it drains both posteriorly toward the cavernous sinus and anteriorly to the SOV. These intraorbital fistulas are successfully treated by transvenous embolization^{69,70} provided the site of the fistula is accurately determined. Orbital fistulas may connect directly to the SOV, so coils must be placed in that vessel at the site of the fistula, rather than in the cavernous sinus, as is usually done in cavernous dAVFs. This shows that it is always important to carefully evaluate high-quality angiographic studies before planning and executing a therapeutic procedure.

12.6.7.3. Transverse/Sigmoid sinus dAVF

Dural AVFs involving transverse and sigmoid sinuses may have numerous arterial feeders, making it more efficient to occlude the recipient dural sinus via a transvenous approach. Cure rates are high with transvenous embolization of these lesions⁷¹ and therefore this approach often proposed as the treatment of choice for these lesions.⁷² However, most of these lesions have a benign natural history, and occlusion of a major dural venous sinus is a drastic solution for benign disease. Short-term symptoms of venous hypertension have been reported in small series after transvenous embolization⁷³ and long-term data on results of transvenous sinus occlusion is lacking. The authors recommend transvenous sinus occlusion in the transverse/sigmoid sinus only in the case of high risk lesions that reflux into cerebral cortical veins implying there should be pre-existing venous occlusive disease in these patients. As a rule in these situations, there is an occlusion of the normal drainage of the affected sinus, and transvenous embolization will only extend the occlusion to involve the site of fistulization. Transvenous embolization can still be done in cases of apparently thrombosed access. Microcatheters may be passed through the thrombosed sinus for occlusion of the site of the fistula with coils.^{74,75} The outlets into any cortical veins should always be occluded first; later the sinus at the site of the fistula should be taken. When using liquid embolic agents, it is also helpful to follow this rule: Coils should be placed at the entry point of any cortical veins, and later the sinus should be filled with the liquid embolic; this will prevent *n*-BCA or Onyx® spreading out into cortical veins.

Certain dangerous fistulas have arterial feeders that converge to an isolated segment of sinus which may not be accessible via a transvenous approach. The sinus is occluded on either side of the fistula and all drainage is by reflux into cerebral cortical veins. In that situation, an option exists to perform open surgical exposure of the isolated sinus segment and insert a microcatheter either directly into the sinus or into one of the tributary vessels draining from the sinus. Coils and/or liquid embolic agents can then be used to occlude the sinus segment and fistula.^{71,76}

dAVF development is thought to be related to venous occlusive disease; it is ironic that the treatment involves occluding a venous sinus. A more physiological treatment would be to resolve the venous occlusive disease. Stenting the affected sinus is proven to be effective in relieving symptoms and sometimes curing the fistula.⁷⁷ Greater use of physiologic therapy for these dAVFs may make transvenous embolization a less commonly employed therapy (see *Transvenous Stenting* section).

12.6.7.4. Superior sagittal sinus and other anterior cranial fossa dAVF

The superior sagittal sinus may be the site of a dAVF, but, as a rule, occlusion of the sinus itself is not recommended, except in its far anterior aspect. Consequently, transvenous embolization in these cases is reserved for selected cases of anterior fossa dAVFs which first drain into a cortical vein before draining into the sinus. The cortical vein may be occluded at the site of the fistula.^{78,79} Fistulas draining into the anterior aspect of the sinus may require extra-long (170 cm) microcatheters to perform the transvenous embolization from a femoral venous access. The authors have had success with transvenous placement of coils at the site of the fistula in the cortical vein, followed by a transarterial glue embolization to cast the vein. The coils on the venous side prevent inadvertent spillage of glue into the superior sagittal sinus or beyond.

More posterior fistulas which drain directly into the superior sagittal sinus and are associated with stenosis of the sinus that produces cortical venous, may respond to stenting of the stenotic sinus (see *Transvenous Stenting* section).

12.6.7.5. Tentorial dAVF

These fistulas have arterial feeders converging on a tentorial sinus or cortical vein above or below the tentorium. They are often dangerous lesions that reflux into cortical veins, and may present with hemorrhage.⁸⁰ They may have numerous arterial feeders, but often the tentorial sinus or dilated cortical vein can be safely and effectively occluded by transvenous coil embolization.^{81,82} Access to the fistula is often via a circuitous pathway. This means one needs a very stable guide catheter in the jugular vein (at least 6 French) and a flexible, braided microcatheter that will not kink as it negotiates the turns, and a variety of soft guidewires to get one where required. The wire has to be treated gently, especially along curves, to prevent perforation. The authors like the Echelon™ 10 (ev3, Irvine, CA) and 0.012in. J-Tip Headliner™ (Terumo Medical, Somerset, NJ), but different cases may require different systems to facilitate access. After depositing coils at the fistula site via transvenous access, transarterial glue injection into the coil mass may sometimes be required to fully occlude the fistula. These dangerous lesions must be treated to completely close the fistula, if possible.

Like other dAVFs, tentorial fistulas may be associated with venous occlusive disease. Endovascular treatment of the stenosis by transvenous stenting can be accomplished to reduce intracranial venous hypertension⁸³ (see *Transvenous Stenting* section).

12.6.7.6. Vein of Galen aneurysmal malformation (VOGM)

These arteriovenous fistulas constitute a complex collection of anomalies of the deep venous system with associated arteriovenous shunts. The stereotypical clinical scenario is a newborn or infant with congestive heart failure and failure to thrive, as a consequence of this arteriovenous shunt. Often these lesions have multiple arterial feeders emptying into a dilated, anomalous vein of Galen; there may also be tortuosity of the arterial feeders. These and the other technical challenges associated with arterial access in small newborns or infants, led to the development of transvenous embolization of these lesions. As a life-saving measure to treat the rapid arteriovenous shunting, transtorcular coil embolization of the vein of Galen was developed.⁸⁴ However this approach requires craniotomy and direct puncture of the venous sinus. Transfemoral venous access to the vein of Galen is less traumatic for the patient and renders craniotomy unnecessary.⁸⁵ Transfemoral access to the vein of Galen also permits retrograde catheterization of larger arterial feeders, allowing coil occlusion of some of these feeders.⁸⁵ If transvenous embolization in VOGMs is used without regard for the arterial and venous anatomy, complications may occur. Any lesion with an associated arteriovenous nidus, as in the Yasargil type IV lesions, should never

undergo transvenous occlusion of the venous outlet.⁸⁶ Blind occlusion of the vein also impairs venous drainage of the brain when there is drainage of the deep veins into the vein.⁸⁷⁻⁸⁹ Moreover, placement of a large number of coils in the vein creates a permanent mass that possibly compresses the cerebral aqueduct contributing to hydrocephalus. Consequently, given currently available techniques for transarterial embolization of the fistulas in VOGM, transvenous embolization is rarely, if ever, required to treat these lesions.

12.6.7.7. Other intracranial dAVFs

dAVFs are rarely located at the superior petrosal sinus,⁹⁰ inferior petrosal sinus,⁹¹ anterior condylar vein,⁹²⁻⁹⁴ or jugular bulb.⁹⁵ Successful treatment requires a thorough arteriogram and careful evaluation of drainage patterns of the fistula and normal venous drainage in the region. Then, it is only a matter of obtaining a catheter position on the venous side of the fistula for occlusion with coils.

12.6.7.8. Extracranial head-and-neck AVF

Mandibular AVFs that converge on the inferior alveolar vein can result in problems of oral bleeding, tooth loss, and bone resorption, but may be effectively treated by transvenous coil embolization of the vein.⁹⁶⁻⁹⁸ Usually some injection of transarterial glue may be needed to completely close the fistula, but the procedure can provide complete cure with good restoration of bone in the mandible. The authors have also treated scalp and facial AVMs with direct percutaneous puncture of the venous outlet and injection of *n*-BCA glue. The venous outlets can be manually compressed during the glue injection to allow controlled retrograde filling of the AVM nidus without causing too much venous embolization.

12.6.7.9. Spinal AVF

Transvenous embolization of spinal fistulas is extremely rare, due to the usual tortuosity of spinal venous structures. A high-flow perimedullary fistula was reportedly treated by direct, intraoperative access to the venous outlet and transvenous injection of glue.⁹⁹ Extradural fistulas may be more accessible to standard endovascular transvenous coil embolization techniques.¹⁰⁰

12.7. Venous thrombolysis/thrombectomy

12.7.1. Background

Cerebral venous thrombosis (CVT) is a condition affecting 3–4 per million adults and 7 per million children.¹⁰¹ It may be in the form of cortical venous thrombosis, venous sinus thrombosis, deep venous thrombosis, jugular venous thrombosis, or various combinations of the above. CVT produces a spectrum of clinical manifestations, ranging from headache, declining visual acuity, global decline in cognitive ability, focal neurological deficits including hemiparesis, hemianesthesia, aphasia, disturbance of consciousness, coma, and even death. Cortical or dural sinus thrombosis may also manifest as subarachnoid hemorrhage.¹⁰²⁻¹⁰⁴ The widely variable manifestation makes CVT a disorder that is often under-recognized and considerable delays in making the correct diagnosis may occur. A study of 91 patients admitted for CVT showed the median time of hospital admission after symptom onset was 4 days, and only 25% were admitted within the first 24 h.¹⁰⁵ In a study of 624 adult patients with CVT, 4.3% of died acutely and 3.4% within 30 days.¹⁰⁶ Factors predicting a higher risk of death included seizures, coma, disturbed consciousness, deep cerebral venous thrombosis, right-sided intraparenchymal bleed, posterior fossa involvement, and progressive focal neurological deficits.¹⁰⁶ Patients over 65 years old had a 27% chance of death and 22% chance of dependency compared to 7% death and 2% incapacitation in younger adults.¹⁰⁷ A series of 38 children with CVT had no mortality from the condition.¹⁰⁸ Underlying conditions predisposing to CVT include a hypercoagulable state in 31% of cases.¹⁰⁹ Predisposing factors include factor V Leiden mutation,¹¹⁰ oral contraceptive

use,¹¹⁰ complicated pregnancy,¹¹¹ mastoiditis and otitis media,¹¹² central nervous system infection,¹⁰⁶ a history of cancer,^{106,107} and postoperative thrombosis.^{113,114}

Just as there are spectrums of clinical findings in CVT, there can also be a spectrum of imaging findings, although some general principles may apply to most cases. In the acute phase of the disease, unenhanced CT or T1 weighted MR scans may show the bright thrombus in the affected venous structure. As the venous thrombosis affects drainage of the brain, generalized brain swelling or focal edema may be present in a distribution that is not typical for standard arterial territories. For instance, sagittal sinus thrombosis affects parasagittal cortex bilaterally, potentially spanning arterial territories of both anterior and posterior cerebral arterial territories. Involvement of multiple arterial territories is a feature that distinguishes CVT from arterial occlusion. Thrombus within the transverse sinus can affect the temporal and occipital lobes, in both middle and posterior cerebral arterial territories, and even the ipsilateral cerebellar hemisphere, which corresponds to the superior cerebellar artery territory. Deep cerebral venous thrombus often causes bithalamic region edema, which would involve thalamoperforating arteries arising from posterior communicating and proximal posterior cerebral arteries, whereas the remaining portions of the posterior cerebral artery territories are spared.

As the impairment of blood flow progresses to venous infarction, further edema and hemorrhagic transformation may occur.¹¹⁵ Subdural and subarachnoid bleeding may be present as well. MR imaging is ideal for CVT screening, since it facilitates visualization of the venous clot, the brain edema and associated bleeding, and MR venography. It can also confirm absence of flow in the veins especially using phase-contrast technique. Catheter angiography may demonstrate sluggish arteriovenous transit and can depict intraluminal clot or absence of flow in the affected veins. Direct catheter venography also confirms the presence of clot in the venous sinuses, although it is not often helpful for isolated cortical venous thrombosis.

CVT can be effectively treated. Essential measures include isotonic saline hydration and aggressive management of intracranial hypertension, since transtentorial herniation is the most common cause of mortality in the acute phase of the disease.¹¹⁶ Intravenous heparinization is undertaken with the rationale that, although heparin will not remove the clot that is already present, it can prevent further propagation of the thrombus and reocclusion as the natural fibrinolytic processes take place. Einhaupl and colleagues reported a small randomized, controlled study and a larger retrospective study that demonstrated significantly better outcomes in CVT patients treated with heparin, even in the presence of intracerebral hemorrhage.¹¹⁷

Endovascular techniques can be used to treat CVT in an attempt to speed the restoration of flow in the involved venous structure, as some patients may not respond to heparin therapy alone. A retrospective study of 79 cases of CVT treated with heparin showed that eight died despite heparinization.¹¹⁸ Microcatheters placed via a transvenous approach and positioned in the occluding thrombus can deliver thrombolytic agents directly to the lesion.^{115,119,120} An animal study of abciximab infusion for dural venous sinus thrombosis indicated recanalization rates comparable to tPA with a better functional outcome.¹²¹ However, there is insufficient clinical experience to determine the role of antiplatelet agents in this disease. Some have advocated transarterial injections of thrombolytic agents for resolving the venous clot for cortical vein thrombosis,¹²² or deep cerebral venous thrombosis.¹²³ Early reports¹¹⁹ describe prolonged thrombolytic infusions over many hours, but more recently, thrombolysis of the dural sinuses has been facilitated with mechanical clot disruption using curved guidewires, angioplasty balloons,¹²⁴ microsnare,¹²⁵ or rheolytic thrombectomy catheters like the AngioJet[®] catheter (Possis Medical, Minneapolis, MN).^{122,126} No controlled, randomized study has compared endovascular thrombolysis with medical management, although several nonrandomized comparisons^{115,127} showed that outcomes after local thrombolytic therapy are at least as good as those after heparin alone. This makes it reasonable to recommend endovascular therapy for those who do not respond to heparin, or who are in the previously mentioned high risk categories – including patients with seizures, coma, disturbed consciousness, deep cerebral venous thrombosis, posterior fossa involvement, and progressive focal neurological deficits.¹⁰⁶

12.7.2. Indications for venous thrombolysis/thrombectomy

1. Symptomatic CVT unresponsive to medical management (hydration, heparin, and ICP management).
2. CVT patients with contraindications to heparin (recent surgery, trauma, bleeding diathesis, heparin antibodies).

3. CVT patient at higher risk of mortality (seizures, coma, disturbed consciousness, deep cerebral venous thrombosis, posterior fossa involvement, and progressive focal neurological deficits).

12.7.3. Complications of venous thrombolysis/thrombectomy

Informed consent prior to the procedure should include an estimate of risk of complications.

12.7.3.1. Neurological complications

1. Development of, or worsening pre-existing intracerebral edema and/or hemorrhage from venous infarction.
2. Venous perforation by guidewires, stiff catheters, or retrieval devices may produce intracranial bleeding.
3. Retrombosis of a revascularized venous structure may occur.
4. Good statistics on complications of cerebral venous revascularization procedures are lacking, since the series reported are small, and everyone knows that the best results tend to get reported.

12.7.3.2. Non-neurological complications

1. Anaphylactic reactions to iodinated contrast or any of the medications used can occur as with any endovascular procedure.
2. Groin hematomas can occur, especially if heparin, antiplatelet agents, and thrombolytic agents are administered.
3. Venous thrombosis can occur anywhere along the pathway of the catheter.
4. Mechanical clot disruption in the dural venous sinuses and jugular veins may result in pulmonary emboli.

12.7.4. Venous thrombolysis/thrombectomy: Procedural aspects

12.7.4.1. Preprocedure evaluation

1. A brief neurological exam should be done to establish a baseline, should a neurologic change occur during or after the procedure.
2. Check if the patient has a history of iodinated contrast reactions.
3. The groins should be examined. Feel for the femoral arterial pulse, which provides a landmark for femoral venous access.
4. If jugular access is anticipated, examine the neck. Observe the jugular venous pulsation, if visible. Palpate the carotid pulse.
5. Check any history of deep venous thrombosis that may require using special sites for venous access.
6. Blood tests, including a serum creatinine level, serum glucose if diabetic and coagulation parameters, be reviewed.
7. Check if there are contraindications to heparin use, such as a history of heparin-induced thrombocytopenia.
8. Check for airway issues, history of previous general anesthesia, or any other coexisting medical issues that could impact the use of general anesthesia.

12.7.4.2. Preprocedure orders

1. NPO for 6h, if possible, but most of these procedures are emergent. Just make the patient NPO as soon as possible.
2. Most acutely ill patients require a radial arterial line for monitoring.
3. Place two good peripheral IVs.

4. Place Foley catheter.
5. Most patients will already be intubated and ventilated.

12.7.4.3. Contrast agents

Standard nonionic contrast agents like Iohexol (Omnipaque[®], GE Healthcare, Princeton, NJ) are usually used for these procedures.

12.7.4.4. Venous access sheath

Venous revascularization procedures are usually always undertaken using a femoral venous sheath, most commonly a 6 or 7 French Shuttle[®] sheath (Cook, Inc., Bloomington, IN) which also acts as a guiding catheter. One needs big lumen access to allow for more options, including microcatheters, balloon catheters, rheolytic catheters, etc. However, if using ipsilateral retrograde jugular venous access a short, 10 cm 6 or 7 French sheath is to be used.

12.7.4.5. Anticoagulation

During the procedure, after access is obtained, administer approximately 50 units kg⁻¹ intravenous heparin bolus.

12.7.4.6. Saline infusion

As with any endovascular procedure, continuous drips of heparinized saline are attached to stopcocks on the sheath, guiding catheter, and microcatheter lumen.

12.7.4.7. Sedation/Anesthesia

Most commonly, venous thrombolysis/thrombectomy is performed with the patient under general anesthesia. Most patients are already intubated, so at least deep sedation should be administered as mechanical thrombectomy can be unpleasant for the patient.

12.7.5. Suggested wires and catheters for venous thrombolysis/thrombectomy

12.7.5.1. Access wires

- Steerable hydrophilic wires such as 0.035 or 0.038 in. angled Glidewire[®] (Terumo Medical, Somerset, NJ) can be used to advance a guiding catheter into the jugular vein.
- Softer, yet torquable wires such as the Headliner[™] or Gold-tip Glidewire[®] (Terumo Medical, Somerset, NJ) can be helpful to navigate the sometimes pesky valves in the lower internal jugular.
- Soft-tip Transend[™], or Synchro[™] (Boston Scientific, Natick, MA) or other 0.014 in. wire is used to advance the microcatheter to the target vessel.
- A good wire for passing through thrombus is the 0.012 in. J-Tip Headliner[™] (Terumo Medical, Somerset, NJ) which is less likely to go into a small branch and perforate the vessel.
- Often, extra-support platinum-tipped, stainless steel coronary wires may be required to advance the stiff rheolytic catheter.

12.7.5.2. Guiding catheters for venous thrombolysis/thrombectomy

- Guiding catheters used for these procedures should be supportive and have a large lumen to allow for a multimodal therapeutic approach.

- The authors like to use a 90cm sheath (e.g., Shuttle® sheath, Cook, Inc., Bloomington, IN) which works as well as a guiding catheter.
- An alternative approach includes standard 6 or 7 French large-lumen gauge guide catheters, such as 6 French angle-tip Envoy® (Cordis Neurovascular, Miami Lakes, FL) or 6 French Northstar® Lumax® (Cook Medical, Inc., Bloomington, IN). It must be ensured the internal lumen will accept the outer diameter of whatever devices (Microcatheters, balloons, rheolytic catheters) one plans to use. The package of the device will usually indicate the recommended guide catheter size.

12.7.5.3. Microcatheters

Large-lumen microcatheters, such as a RapidTransit® (Cordis Neurovascular, Miami Lakes, FL), are used for intracranial venography (see *Venography* section). If the thrombus is in the superior sagittal sinus, one of 170cm length will be required. Occasionally a lower-profile system may be needed to penetrate firm thrombus or navigate beyond underlying stenoses. Microcatheters with a 1.7 French distal tip work well and include the Echelon-10™ (ev3, Irvine, CA), Excelsior® SL-10 (Boston Scientific, Natick, MA), or Prowler-10® (Cordis Neurovascular, Miami Lakes, FL).

12.7.5.4. Balloons for venous thrombolysis/thrombectomy

- Balloons *must* be sized smaller than the vessel being treated. As a rule, one can start small (say 2–3 mm diameter).
- One can use soft flexible balloons such as the 3.5 mm diameter Hyperglide™ (ev3, Irvine, CA) to disrupt clot, but this very soft balloon only works on soft clot.
- Better suited for these procedures are over-the-wire, low-compliance angioplasty balloons which have an internal lumen through which one can infuse thrombolytic agents as well as use the balloon to disrupt clot.
- The shaft of the balloon catheter must generally be 150 cm to reach the target vessel. The over-the-wire NC Ranger™ (Boston Scientific, Natick, MA) or NC Raptor™ (Cordis Endovascular, Miami, FL) can be used for this application.

12.7.5.5. Rheolytic catheters

- Penumbra Reperfusion catheters (Penumbra, Inc., Alameda, CA) come in 0.041, 0.032, and 0.026 in. lumen sizes. Each has matching separator wires used to prevent clogging of the catheter by clot. This will require a 6 French, 0.070 in. lumen minimum guide catheter.
- AngioJet® XMI® catheter (Possis Medical, Minneapolis, MN) comes in both over-the-wire and rapid-exchange versions and the AngioJet® Spiroflex™ (Possis Medical, Minneapolis, MN) is a flexible rapid-exchange system. These are 4 French catheters that are compatible with 6 French guide catheters and are flexible enough to reach the intracranial dural venous sinuses. The downside is that they may only aspirate small volumes of clot in a reasonable period of time. The company makes larger catheters for heavier-duty clot aspiration, but the larger systems are stiffer and harder to navigate through the sigmoid sinus. These rheolytic catheters fragment and aspirate clot with a high-flow jet of saline that aspirates the clot using the Bernoulli principle; this requires the sterile connection set and pump console made specifically for this system.

12.7.6. Procedures

12.7.6.1. Venous access

1. The groin area is prepped bilaterally and draped.
2. The femoral pulse is palpated at the inguinal crease, and local anesthesia (2% lidocaine containing sodium bicarbonate (1 mL per 10 mL of lidocaine) is infiltrated medial to the pulse, both by raising a wheal and injecting deeply toward the vein.
3. 5 mm incision is made parallel to the inguinal crease with an 11-blade scalpel.

4. An 18 gauge Potts needle is advanced with the bevel facing upward. The needle is advanced at a 45° angle to the skin.
5. Dark red blood is aspirated from the needle using a 10 cc syringe confirms puncture of the femoral vein.
6. A 0.038 in. J-wire is advanced under fluoroscopic visualization into the inferior vena cava.
7. Depending on the size of the catheter being used, a sheath is placed in the right (or left) femoral vein.
8. In patients with CVT, it will not be unexpected if there is also femoral or iliac thrombosis, preventing access from that route. The other groin may be tried in that case.
9. If femoral venous access fails, direct jugular access can be tried, taking care not to get a neck hematoma, especially when using thrombolytics. Neck hematomas can compress the airway if they get too large.
10. If all else fails, a burr hole may be placed over the dural sinus to be treated with a rheolytic catheter,¹²⁸ but this more invasive technique would limit the options for using heparin and/or thrombolytic agents because of concerns of postoperative bleeding.

12.7.6.2. Catheter manipulation

1. Attach all catheters to rotating hemostatic valves and attach a three-way stopcock and continuous infusion of saline containing 10,000 units heparin per liter.
2. Since usually femoral venous access will be used, advance the 90 cm sheath, or guide the catheter over a steerable Glidewire® (Terumo Medical, Somerset, NJ) into the desired internal jugular vein.
3. If the venous structures being treated are more cephalad than the jugular bulb or IPS, advance a microcatheter coaxially through the rotating hemostatic valve of the guiding catheter.
4. Warn conscious patients that the catheter manipulation may cause discomfort.
5. Carefully and gently advance the microcatheter over a soft-tip guidewire into the venous sinus cephalad one wishes to treat. The authors like to use the J-Tip Headliner™ (Terumo Medical, Somerset, NJ) to advance the microcatheter through the clot in an atraumatic fashion. Try to get as far as possible in the thrombus to allow for treatment of the largest volume of clot.
6. Perform a gentle test injection of 1–2 mL of contrast for a venogram, to confirm the presence of thrombus and to ensure that the catheter is in good position.
7. Cortical veins or deep veins like the internal cerebral veins should be very cautiously catheterized injected with only minute volumes of contrast.
8. Perform this venogram with high-quality DSA imaging systems using 2–4 frames per second.

12.7.6.3. Thrombolysis

1. Draw up your thrombolytic agent of choice and fill specially marked 3 mL syringes with the agent. The authors use tPA Activase® (Genentech, South San Francisco, CA) mixed at a dilution of 1 mg mL⁻¹ and injected at a rate of approximately 1 mL min⁻¹.
2. Slowly withdraw the microcatheter through the thrombus and readvance, to lace the clot with the tPA.
3. Periodically use the soft guidewire to gently probe the clot to create fissures, and increase the surface area on which the tPA can act.
4. A convenient technique is to use a large-lumen microcatheter, such as the Rapid Transit® (Cordis Neurovascular, Miami Lakes, FL), and use a 0.012 in. J-Tip Headliner™ (Terumo Medical, Somerset, NJ) or other small wire to maintain wire access and continually probe the clot with the wire, since the tPA can be infused through the microcatheter around the wire.
5. Periodically (say, every 15 min) perform gentle contrast injections through the microcatheter to see if the thrombus is breaking up.
6. After every 10 mg of tPA has been infused, one may want to advance the microcatheter to a new area of clot, and lace that region with tPA as well.
7. As a rule, one would not want to exceed 0.9 mg tPA kg⁻¹ body weight, and generally it is enough to inject 30–40 mg in the average patient.

8. One need not expect, or even try to get complete resolution of thrombus by the thrombolytic agent. All that is required is a continuous channel through the clot, and the tPA and endogenous plasminogen activators will continue to work for hours after the procedure.
9. If, after about 30 min of tPA infusion and gentle guidewire probing, there is no significant improvement in flow through the vessel, the addition of balloon or rheolytic catheter thrombectomy may be considered to speed the process.
10. Although many hours of thrombolytic infusion to thoroughly clean out all the thrombus have been used in some cases, it is usually good enough to stop after achieving some flow through the sinus. This can usually be accomplished in an hour or two of treatment.
11. If, after restoration of flow in the vein, an underlying stenosis is seen, placement of a self-expanding stent to improve flow may be considered (see *Venous Stenting* section).

12.7.6.4. Balloon-assisted thrombolysis

1. This is only advisable in larger dural venous sinuses.
2. Use a soft-tip, 0.014 in. exchange wire, such as a floppy-tip Transend™, or Synchro™ (Boston Scientific, Natick, MA) with a wire tip shaped in a tight J-shaped configuration.
3. Advance the wire as distal as one can safely get in the thrombosed venous sinus.
4. Exchange the microcatheter for a low-compliance, 2–3 mm diameter angioplasty balloon such as an NC Ranger™ (Boston Scientific, Natick, MA) or NC Raptor™ (Cordis Endovascular, Miami, FL).
5. Alternatively, one can use a more flexible balloon catheter such as a Hyperglide™ (Micro Therapeutics/ev3, Irvine, CA). More often than not, these types of balloons are best advanced primarily from the guide catheter and into the clot, without using an exchange wire.
6. Once the balloon is positioned in the thrombus, slowly inflate under low pressure to create a small channel. Try keeping the balloon positioned centrally in the sinus to avoid exerting pressure on the wall.
7. Keeping wire access in the sinus, slowly withdraw the uninflated balloon and perform repeated inflations and deflations as the balloon is pulled back through the clot.
8. When the balloon has reached the end of the clot, either readvance the balloon repeating with slightly larger volume inflations, or exchange it for a balloon with a slightly larger diameter.
9. Insert the balloon back into the thrombus, inflating and deflating as one advances a short distance at a time.
10. The goal is to slowly and gently dilate a channel though the full extent of the clot to restore flow.
11. If using an over-the-wire balloon, one can either periodically remove the wire or use a small 0.010 in. wire to allow further injections of thrombolytic agent through the balloon catheter's central lumen.
12. If, after restoration of flow in the vein, one sees an underlying stenosis, placement of a self-expanding stent to improve flow may be considered (see *Venous Stenting* section).

12.7.6.5. Rheolytic catheter use

The main benefit of using a rheolytic catheter is that it physically removes clot to quickly restore flow and decrease the likelihood of embolization of clot fragments to the lung. This technique works best when used in conjunction with thrombolytic therapy, since the thrombolytic aids in softening and fragmenting the clot into smaller pieces suitable for aspiration into the rheolytic catheter. However, it can also be used without attendant use of thrombolytic drugs and provides a treatment option for patients who have had recent trauma, surgery or extensive intracranial bleeding, making the use of thrombolytic agents riskier for hemorrhagic problems. The relatively stiff rheolytic catheters are only suitable for use in larger dural venous sinuses, such as the sigmoid and transverse sinuses and the larger, posterior aspect of the superior sagittal sinus:

1. Be sure one has a stable guide catheter position, with a system big enough to accept the rheolytic catheter one plans to use.

2. After obtaining microcatheter access to the intracranial venous sinuses, one should try to advance a 300 cm 0.014 in. exchange wire across the torcula, into the contralateral transverse and sigmoid sinus, and, preferably, down the contralateral internal jugular and well down the vena cava into the contralateral iliac and femoral veins. This provides very stable wire support.
3. The microcatheter should be removed, leaving the 0.014 in. exchange wire in place.
4. The rheolytic catheter be prepared according to the manufacturer's recommendations. If using the AngioJet® XMI® catheter (Possis Medical, Minneapolis, MN), one will need to prepare the Drive Unit and Pump Set, according to the recommended set up procedures to the letter. No steps should be skipped as the system will not then work properly.
5. The rheolytic catheter may be advanced over the exchange wire.
6. If resistance is encountered, the guidewire should be gently pulled back, either by rotating the wire, or rapidly pushing forward and pulling back on the catheter a few millimeters at a time to reduce friction.
7. The guide catheter should be tracked. If it pushes back and buckles in the right atrium, it can cause arrhythmias.
8. If guide catheter stability is a problem, using a larger, stiffer system, or "Tower of Power," consisting of a 100 cm guide catheter within a 90 cm sheath may be considered.
9. Another option is to advance a relatively flexible guide catheter, like a 6 French Neuron™ 070 Guide catheter (Penumbra, Inc., Alameda, CA) into the sigmoid sinus as distal as possible to bypass the curves in this region.
10. If guidewire stability is the problem, use of a stiffer, coronary exchange wire system may be considered.
11. Once the rheolytic catheter is reached to the thrombosed sinus, one should try to advance it through the clot as distal as possible.
12. The stopcocks be opened and the suction pump operated according to manufacture's directions. A pass may be made through the clot while aspirating, keeping wire access in place.
13. The catheter may be readvanced into the clot, and the aspiration repeated as necessary, until flow is restored.
14. If aspiration is not possible, the catheter may be clogged and will have to be removed and replaced.
15. If only pure blood appears to be aspirating, a channel in the clot may already have already created. One may consider repositioning the wire in a different part of the clot, or attempt to get a larger catheter system in place to increase the size of the patent channel.
16. No attempt be made to remove every bit of thrombus as too much blood is likely to be aspirated in the process.
17. Once again, if, after restoration of flow in the vein, one sees an underlying stenosis, one may want to consider placement of a self-expanding stent to improve flow (see *Venous Stenting* section).

12.7.6.6. Puncture site care

Once the venous procedure is completed, the catheters are removed. If thrombolytic agents have been used, one can leave a short sheath in place at the access site, usually, until the following morning. The sheaths can then be removed and hemostasis should be obtained by manual pressure. Closure devices are generally not necessary for venous punctures. The authors apply a Syvek hemostatic patch (Marine Polymer Technologies, Danvers, MA) and keep the patient in bed for 2 h for 6 French sheath sizes.

After the procedure, patients will require close monitoring and intensive medical management. Intracranial pressure must be monitored and controlled. In extreme cases, this may require decompressive craniectomy and/or barbiturate coma induction.¹¹⁵ Periodic imaging studies should be done to confirm resolution of edema, and to scan for hemorrhagic transformation or rethrombosis of the venous structures. If possible, the patient should be continued on heparin and later placed on warfarin therapy to prevent rethrombosis. Consider adding an antiplatelet agent such as aspirin or clopidogrel, especially if a stent was placed. Long-term anticoagulation may be required, since recurrent CVT or other venous thrombosis may occur after 3–6 months in 5.5–26% of these patients.¹²⁹

12.8. Transvenous stenting

12.8.1. Background

As in the case of arterial stenosis, venous stenosis can be effectively treated with endovascular therapy. Unlike some arterial lesions, however, venous sinus stenosis rarely responds to balloon angioplasty alone, due to the elastic recoil of the walls of the sinus and the lack of adequate high pressure in the vessel to maintain patency. Therefore stent placement is required to ensure continued patency of the vessel. Another peculiarity of dural sinus stenosis is that the target vessel normal diameter is generally fairly large, requiring a stiff delivery system; yet the jugular bulb and sigmoid sinuses may be sharply angulated, making it advantageous to have a more flexible delivery system. The challenges of performing endovascular stenting of venous sinuses arise from this dilemma.

Endovascular treatment of venous stenosis is an emerging field with only a few isolated case reports or very small series. Stenting has commonly been reported used in the treatment of benign intracranial hypertension, or pseudotumor cerebri, caused by dural sinus stenosis.^{130–136} Pseudotumor is a potentially disabling condition classically seen in obese females in the reproductive years, producing headache, papilledema, cognitive decline and potentially permanent vision loss if the high CSF pressure is not relieved. Traditional therapy includes medical therapy with analgesics, corticosteroids, acetazolamide, cerebrospinal fluid diversion with periodic lumbar puncture or ventriculoperitoneal shunting, and optic nerve sheath decompression to relieve pressure on the nerve.¹³⁷ Given the role of dural venous sinuses in the removal of cerebrospinal fluid from the intracranial compartment, and the observation of elevated venous pressures on intracranial venography in 10 out of 10 patients with pseudotumor, Karahalios and coworkers proposed that venous hypertension may be the final common pathway for production of elevated CSF pressure.¹³⁸ It may be premature to implicate venous hypertension universally as the cause of high CSF pressure in pseudotumor cerebri, as in some cases, it may be the intracranial hypertension that causes the venous hypertension, not the other way around.¹³⁹ Venous stenting in the setting of 12 patients with pseudotumor resulted in complete resolution of symptoms in 5, significant improvement in 2, and no change in 5.¹³⁴ Thus, correction of venous stenosis improves symptoms more often than not, and may provide a minimally invasive treatment for a potentially disabling condition.

Venous stenosis may also contribute to intracranial venous hypertension in the setting of a dAVF. It is also thought that underlying venous occlusive disease may be instrumental in the development of dural fistulas, suggesting that treatment of the stenosis may take care of both the symptomatic venous hypertension and the underlying cause of the disorder. Stenting can improve symptoms of intracranial venous hypertension, especially when performed with some transarterial embolization of the arterial feeders supplying the fistula.^{83,140} Three out of four cases of transverse or sigmoid sinus dural AVFs were completely cured by stenting after partial transarterial embolization, and some even without adjunctive embolization.⁷⁷

Patients with pulsatile tinnitus, whose symptoms abate with external jugular compression or with venous test occlusion may have a venous etiology for the audible sound. If the tinnitus is caused by a stenosis, stenting the lesion may reduce the turbulence and relieve the symptoms. The authors have successfully treated such a patient, with long-term relief of the tinnitus. Similarly, some patients with a sigmoid diverticulum, or "aneurysm" may be successfully treated by stent placement with, or without associated coiling of the aneurysmal area.^{141,142} Preservation of flow in the stenotic or aneurysmal sinus is a far more elegant and physiological solution than either endovascular occlusion of the sinus or surgical ligation of the jugular vein.

12.8.2. Indications for venous stenting

1. Symptoms of intracranial venous hypertension due to venous stenosis.
2. Venous stenosis-producing intracranial hypertension in the setting of dAVFs.
3. Pulsatile tinnitus caused by venous stenosis, varix or jugular diverticulum.

12.8.3. Complications of venous stenting

Informed consent prior to the procedure should include an estimate of the risk of complications.

12.8.3.1. Neurological complications

1. Transient headaches are common. It is likely related to the continual stretching of the dural walls of the sinus by the self-expanding stent, and may last 1–3 weeks.
2. There is a risk of acute or delayed thrombosis of the venous structures catheterized, with resultant venous infarction.
3. Oversized stent placement or aggressive balloon angioplasty in intracranial vessels can rupture venous structures, potentially producing epidural, subdural, subarachnoid or intracerebral bleeding.
4. In-stent stenosis, due to neointimal hyperplasia, with recurrent symptoms of venous hypertension.¹⁴³
5. Statistics on complications of venous stenting are lacking, as it is a rarely performed procedure.

12.8.3.2. Non-neurological complications

1. As mentioned above, there is a risk of a profound vagal response to balloon inflation in the jugular vein or sigmoid sinus, potentially producing bradycardia, hypotension, and even cardiac arrest. A self-expanding stent placed in the same region may produce a similar response.
2. Anaphylactic reactions to iodinated contrast or any of the medications used can occur as with any endovascular procedure.
3. Groin hematomas can occur, but are less common and less severe compared to arterial punctures.
4. Deep vein thrombosis, pulmonary emboli, and other thrombotic events may occur.

12.8.4. Venous stenting: Procedural aspects

12.8.4.1. Preprocedure evaluation

1. A brief neurological exam should be done to establish a baseline, should a neurologic change occur during or after the procedure.
2. The patient should be asked if he or she has had a history of iodinated contrast reactions.
3. The groins should be examined. Feel for the femoral arterial pulse, which provides a landmark for femoral venous access.
4. If jugular access is anticipated, the neck should be examined. The jugular venous pulsation is to be observed, if visible. Palpate the carotid pulse.
5. Ask the patient about any history of deep venous thrombosis that may require using special sites for venous access.
6. Blood tests, including serum creatinine level, serum glucose, if diabetic, and coagulation parameters, should be reviewed.
7. Check for airway issues, history of previous general anesthesia, and any other coexisting medical issues that could impact the use of general anesthesia.

12.8.4.2. Preprocedure orders

1. NPO for 6 h, except for medications.
2. Patients on insulin for hyperglycemia should get half their normal dose prior to the procedure.
3. Place a peripheral IV.
4. Place Foley catheter.
5. Consider pretreatment with 0.3–0.5 mg Atropine if planning stenting in the jugular vein or sigmoid sinus.

12.8.4.3. Contrast agents

Standard nonionic contrast agents like Iohexol (Omnipaque®, GE Healthcare, Princeton, NJ) are usually used for these procedures.

12.8.4.4. Venous access sheath

Venous stenting procedures are usually done using a femoral venous sheath, most commonly a 6 or 7 French Shuttle® sheath (Cook, Inc., Bloomington, IN) which also acts as a guiding catheter. However, to improve access to the intracranial sinuses, use of ipsilateral retrograde jugular venous access may be considered. In that case, a short, 10 cm 6 or 7 French sheath for jugular access may be used.

12.8.4.5. Anticoagulation

One should pretreat any patient undergoing stenting with at least 3 days of a daily dose of 75 mg. clopidogrel to limit any cascade of platelet aggregation instigated by stent placement. Aspirin 325 mg daily can be used as an alternative, or can be used in addition to clopidogrel. There is little evidence supporting any one particular antiplatelet regimen. However, given the experience with antiplatelet use in arterial stenting, it is reasonable to advocate some antiplatelet therapy whenever stents are placed.

During the procedure, after access is obtained, administer 50–70 units kg⁻¹ intravenous heparin bolus and hourly boluses as needed to keep the activated clotting times at least double the baseline value.

12.8.4.6. Saline infusion

As with any endovascular procedure, continuous drips of heparinized saline are attached to stopcocks on the sheath, guiding catheter, and microcatheter lumen.

12.8.4.7. Sedation/Anesthesia

Most commonly, venous stenting is performed with the patient under general anesthesia. The authors can vouch that catheterization much above the skull base can often produce significant discomfort, so the more reasonable thing to do is to use general anesthesia.

12.8.5. Suggested wires and catheters for venous stenting

12.8.5.1. Access wires

- Steerable hydrophilic wires such as 0.035 or 0.038 in. angled Glidewire® (Terumo Medical, Somerset, NJ) can be used to advance a guiding catheter into the jugular vein.
- Softer, yet torquable wires such as the Headliner™ or Gold-tip Glidewire® (Terumo Medical, Somerset, NJ) can be helpful for navigating the sometimes pesky valves in the lower internal jugular.
- Soft-tip Transend™, or Synchro™ (Boston Scientific, Natick, MA) or other 0.014 in. wire is used to advance the stent delivery catheter to the target vessel.
- Often, extra-support platinum-tipped, stainless steel coronary wires may be required to advance the stiff stent delivery catheter.

12.8.5.2. Venography catheters

Large-lumen microcatheters, such as a RapidTransit® (Cordis Neurovascular, Miami Lakes, FL), are used for intracranial venography prior to stent placement, and to allow wire access across the stenosis.

12.8.5.3. Stents for venous stenting

- Self-expanding stents allow for slow, atraumatic expansion of the stenosis.
- Nitinol (as opposed to stainless steel) stents cause limited artifact on MRI, allowing for follow-up brain imaging.
- The stent should be sized to cover the area of stenosis and have a diameter 1–2mm larger than the normal vessel on either side of the stenosis. Intracranial sinuses generally measure between 5 and 8mm in diameter.
- Over-the-wire stent delivery catheters may require exchange-length (300cm) guidewires, which can be awkward, but sometimes they may advance easier through a tight curve or stenosis compared with the more convenient rapid-exchange version of the stent.
- Precise[®] Stents (Cordis/Johnson and Johnson, Piscataway, NJ) come in sizes from 5 to 10mm diameter and have a relatively flexible delivery system. They can also accept up to a 0.018in. guidewire for added support.
- The Acculink[™] stent (Guidant, Santa Clara, CA) also comes in a variety of sizes and has a very smooth, tapered distal tip which crosses stenoses easily, but the delivery catheter is a bit stiff, making it tricky to negotiate tight curves.
- Balloon-expandable stents are generally not recommended for venous stenting, since rapid balloon dilatation carries risk of rupturing the vessel.

12.8.6. Procedures

12.8.6.1. Femoral access

1. The groin area is prepped bilaterally and draped.
2. The femoral pulse is palpated at the inguinal crease, and local anesthesia (2% lidocaine containing sodium bicarbonate (1 mL per 10 mL of lidocaine) is infiltrated medial to the pulse, both by raising a wheal and injecting deeply toward the vein.
3. 5mm incision is made parallel to the inguinal crease with an 11-blade scalpel.
4. An 18 gauge Potts needle is advanced with the bevel facing upward. The needle is advanced at a 45° angle to the skin.
5. Dark red blood aspirated from the needle using a 10cc syringe confirms puncture of the femoral vein.
6. A 0.038 in. J-wire is advanced under fluoroscopic visualization into the inferior vena cava.
7. Using successive dilators, dilate up to one French-size greater than the nominal sheath size being used.
8. Depending on the size and type of stent being used, a sheath is placed in the right (or left) femoral vein. Usually a 6 or 7 French, 90cm Shuttle[®] sheath (Cook, Inc., Bloomington, IN).
9. Advance the 90cm sheath into the dominant jugular vein draining the venous structure to be stented.
10. Alternatively, the jugular vein can be used to access to the ipsilateral dural venous sinuses. Retrograde jugular puncture is performed using a small vessel access system.
11. When the needle is in the vein, advance the 0.018 in. platinum-tip wire of the access kit carefully up the jugular vein, remove the needle, and insert the coaxial dilator.
12. Gently advance a 0.038 J-tip wire or Glidewire[®] (Terumo Medical, Somerset, NJ) retrograde into the jugular vein, and as high as one can easily get, to provide added support.
13. One may have to dilate the tract with a 5.5–7 French dilator. Be sure not to lose wire access, but also ensure the wire does not traumatize the venous structure it is in.
14. Advance a 10cm 6, or 7 French sheath up to the upper jugular vein.

12.8.6.2. Intracranial access

1. Through the venous sheath in the jugular, advance the desired large-lumen microcatheter, such as the RapidTransit[®] (Cordis Neurovascular, Miami Lakes, FL) over a wire, such as the 0.012in. J-Tip Headliner[™] (Terumo Medical,

Somerset, NJ) or the 0.014 in. Soft-tip Transend™ (Boston Scientific, Natick, MA) gently through the jugular into the intracranial venous sinuses and advance the catheter across the stenosis to be stented.

2. One may need to periodically remove the guidewire and inject contrast through the microcatheter to obtain roadmap images to see where you are going. Alternatively, one can use an angiographic catheter placed in the arterial system to inject contrast in the arterial territory feeding the desired venous sinus for roadmap imaging.
3. Place the microcatheter across the lesion, and, if not already done, perform venography to confirm the presence of a stenosis, and do pressure measurements to confirm that it is hemodynamically significant (produces at least 10 mm mercury gradient).
4. Once the stenosis is localized, characterized and measured, select a stent that will cover the lesion sufficiently in length, and that has a nominal diameter 1–2 mm greater than the normal vessel proximal and distal to the lesion.
5. Using the microcatheter, advance a 0.014 in., 300 cm wire, such as a Transend™, or Synchro™ (Boston Scientific, Natick, MA), or consider a high-support coronary wire.
6. If possible, advance the wire as far as possible beyond the stenosis. If the lesion to be stented is in the transverse or sigmoid sinuses, try to advance the wire across the torcular Herophili, into the contralateral transverse sinus, sigmoid sinus, jugular vein, and even well caudal to that if one can. This will require as much wire support as one can get.
7. If the stenosis is in the superior sagittal or straight sinus, choices for wire access are more limited. It has to be ensured the tip of the wire is in a reasonably large and straight vein and not against the wall of the vein, to limit the risk of wire perforation.
8. Once the wire is appropriately positioned, one needs to remove the microcatheter, being careful to leave the exchange-length wire in position.

12.8.6.3. Stent placement

1. If, and only if, the stenosis measures less than the crossing diameter of the stent delivery system, one may have to predilate with a small, low-compliance angioplasty balloon. Usually a 3–4 mm balloon, very slowly inflated under low pressure will dilate the lesion enough to get the stent in place.
2. After preparing the stent by thoroughly flushing all lumens according to the manufacturer's instructions, attach a rotating hemostatic valve and continuous heparinized saline drip to the lumen of the stent delivery catheter.
3. Advance the stent over the wire and position it across the stenosis.
4. Stent advancement may not be as easy as it sounds, and considerable tortuosity in the sigmoid may produce resistance to advancement.
5. Tips for getting the stent delivery catheter to advance beyond areas of resistance caused by tortuosity or stenosis include the following:
 - Rotating the wire as the stent is advanced.
 - Advancing the stent using rapid, jerky forward movements alternating with slight backward movements.
 - Trying to turn the patient's head away from or toward the side of the lesion.
 - Trying a stiffer wire, such as a 0.014 in. stainless steel coronary support wire or a 0.018 in. wire, if the system will accept a wire that size.
 - Trying to advance the guiding sheath over a soft catheter up into the sigmoid to bypass the first curve.
 - If one is using femoral venous access, switching to jugular venous access may be considered for greater pushability.
6. Position the stent across the stenosis. If unsure that the stent is appropriately positioned by using bony landmarks or roadmap images, it may be necessary to perform an arterial injection for a roadmap, or, if one is using an over-the-wire stent delivery system, the wire can be removed from the catheter and contrast injected through the central lumen of the stent delivery catheter to opacify the vein for a good roadmap. One must not forget to reinsert the wire before deploying the stent to ensure proper stent deployment.
7. According to the manufacturer's directions, deploy the self-expanding stent across the stenosis.
8. Remove the stent delivery system, leaving the wire in place.

9. If, and only if, there is still severe stenosis and the stent does not look like it will open the vessel, a gentle postdilation may be performed with a low-compliance balloon shorter than the stent and undersized 20% less than the size of the normal vessel diameter within the lesion.
10. Otherwise, advance the large-lumen microcatheter through the stent and into the vessel beyond it.
11. Perform venograms and pressure measurements to see the results of the stent placement and check for any residual pressure gradient across the stent.
12. If appropriately sized, one can usually expect gradual expansion of the stent, and one does not have to worry about even moderate residual stenosis.

12.8.6.4. Postprocedure Care

Once the procedure is completed, all catheters are removed and hemostasis obtained, as discussed in the general comments above. Daily antiplatelet therapy, usually consisting of clopidogrel and aspirin is to be continued for 90 days, followed by long-term aspirin. The authors obtain a follow-up MR venogram in 3–6 months, then annually, or as needed if symptoms do not resolve.

12.9. References

1. Ayanzen RH, Bird CR, Keller PJ, McCully FJ, Theobald MR, Heiserman JE. Cerebral MR venography: normal anatomy and potential diagnostic pitfalls. *Am J Neuroradiol* 2000;21(1):74–8.
2. Henkes H, Felber SR, Wentz KU, et al. Accuracy of intravascular microcatheter pressure measurements: an experimental study. *Br J Radiol* 1999;72(857):448–51.
3. Murayama Y, Massoud TF, Vinuela F. Transvenous hemodynamic assessment of experimental arteriovenous malformations. Doppler guidewire monitoring of embolotherapy in a swine model. *Stroke* 1996;27(8):1365–72.
4. Sekhar LN, Pomeranz S, Janecka IP, Hirsch B, Ramasastry S. Temporal bone neoplasms: a report on 20 surgically treated cases. *J Neurosurg* 1992;76(4):578–87.
5. Spetzler RF, Daspit CP, Pappas CT. The combined supra- and infratentorial approach for lesions of the petrous and clival regions: experience with 46 cases. *J Neurosurg* 1992;76(4):588–99.
6. Schmid-Elsaesser R, Steiger HJ, Yousry T, Seelos KC, Reulen HJ. Radical resection of meningiomas and arteriovenous fistulas involving critical dural sinus segments: experience with intraoperative sinus pressure monitoring and elective sinus reconstruction in 10 patients. *Neurosurgery* 1997;41(5):1005–16; discussion 16–8.
7. Houdart E, Saint-Maurice JP, Boissonnet H, Bonnin P. Clinical and hemodynamic responses to balloon test occlusion of the straight sinus: technical case report. *Neurosurgery* 2002;51(1):254–6; discussion 6–7.
8. Doppman JL. There is no simple answer to a rare complication of inferior petrosal sinus sampling. *Am J Neuroradiol* 1999;20(2):191–2.
9. Miller DL, Doppman JL, Peterman SB, Nieman LK, Oldfield EH, Chang R. Neurologic complications of petrosal sinus sampling. *Radiology* 1992;185(1):143–7.
10. Sturrock ND, Jeffcoate WJ. A neurological complication of inferior petrosal sinus sampling during investigation for Cushing's disease: a case report. *J Neurol Neurosurg Psychiatry* 1997;62(5):527–8.
11. Bonelli FS, Huston J, III, Meyer FB, Carpenter PC. Venous subarachnoid hemorrhage after inferior petrosal sinus sampling for adrenocorticotropic hormone. *Am J Neuroradiol* 1999;20(2):306–7.
12. Lefournier V, Gatta B, Martinie M, et al. One transient neurological complication (sixth nerve palsy) in 166 consecutive inferior petrosal sinus samplings for the etiological diagnosis of Cushing's syndrome. *J Clin Endocrinol Metab* 1999;84(9):3401–2.
13. Blevins LS, Jr, Clark RV, Owens DS. Thromboembolic complications after inferior petrosal sinus sampling in patients with Cushing's syndrome. *Endocr Pract* 1998;4(6):365–7.
14. Refetoff S, Van Cauter E, Fang VS, Laderman C, Graybeal ML, Landau RL. The effect of dexamethasone on the 24-hour profiles of adrenocorticotropin and cortisol in Cushing's syndrome. *J Clin Endocrinol Metab* 1985;60(3):527–35.
15. Van Cauter E, Refetoff S. Evidence for two subtypes of Cushing's disease based on the analysis of episodic cortisol secretion. *N Engl J Med* 1985;312(21):1343–9.
16. Oldfield EH, Doppman JL, Nieman LK, et al. Petrosal sinus sampling with and without corticotropin-releasing hormone for the differential diagnosis of Cushing's syndrome. *N Engl J Med* 1991;325(13):897–905.
17. Bonelli FS, Huston J, III, Carpenter PC, Erickson D, Young WF, Jr, Meyer FB. Adrenocorticotropic hormone-dependent Cushing's syndrome: sensitivity and specificity of inferior petrosal sinus sampling. *Am J Neuroradiol* 2000;21(4):690–6.
18. Kalsas GA, Giannulis MG, Newell-Price JD, et al. A critical analysis of the value of simultaneous inferior petrosal sinus sampling in Cushing's disease and the occult ectopic adrenocorticotropin syndrome. *J Clin Endocrinol Metab* 1999;84(2):487–92.
19. Colao A, Faggiano A, Pivonello R, Pecori G, Cavagnini F, Lombardi G. Inferior petrosal sinus sampling in the differential diagnosis of Cushing's syndrome: results of an Italian multicenter study. *Eur J Endocrinol* 2001;144(5):499–507.
20. Graham KE, Samuels MH, Nesbit GM, et al. Cavernous sinus sampling is highly accurate in distinguishing Cushing's disease from the ectopic adrenocorticotropin syndrome and in predicting intrapituitary tumor location. *J Clin Endocrinol Metab* 1999;84(5):1602–10.
21. Oldfield EH, Girton ME, Doppman JL. Absence of intercavernous venous mixing: evidence supporting lateralization of pituitary microadenomas by venous sampling. *J Clin Endocrinol Metab* 1985;61(4):644–7.
22. Manni A, Latshaw RF, Page R, Santen RJ. Simultaneous bilateral venous sampling for adrenocorticotropin in pituitary-dependent Cushing's disease: evidence for lateralization of pituitary venous drainage. *J Clin Endocrinol Metab* 1983;57(5):1070–3.

23. Doppman JL, Chang R, Oldfield EH, Chrousos G, Stratakis CA, Nieman LK. The hypoplastic inferior petrosal sinus: a potential source of false-negative results in petrosal sampling for Cushing's disease. *J Clin Endocrinol Metab* 1999;84(2):533-40.
24. Mamelak AN, Dowd CF, Tyrrell JB, McDonald JF, Wilson CB. Venous angiography is needed to interpret inferior petrosal sinus and cavernous sinus sampling data for lateralizing adrenocorticotropic-secreting adenomas. *J Clin Endocrinol Metab* 1996;81(2):475-81.
25. Kalogeras KT, Nieman LK, Friedman TC, et al. Inferior petrosal sinus sampling in healthy subjects reveals a unilateral corticotropin-releasing hormone-induced arginine vasopressin release associated with ipsilateral adrenocorticotropic secretion. *J Clin Invest* 1996;97(9):2045-50.
26. Ratliff JK, Oldfield EH. Multiple pituitary adenomas in Cushing's disease. *J Neurosurg* 2000;93(5):753-61.
27. Kim LJ, Klopfenstein JD, Cheng M, et al. Ectopic intracavernous sinus adrenocorticotropic hormone-secreting microadenoma: could this be a common cause of failed transphenoidal surgery in Cushing disease? Case report. *J Neurosurg* 2003;98(6):1312-7.
28. Miller DL, Doppman JL, Nieman LK, et al. Petrosal sinus sampling: discordant lateralization of ACTH-secreting pituitary microadenomas before and after stimulation with corticotropin-releasing hormone. *Radiology* 1990;176(2):429-31.
29. Liu C, Lo JC, Dowd CF, et al. Cavernous and inferior petrosal sinus sampling in the evaluation of ACTH-dependent Cushing's syndrome. *Clin Endocrinol (Oxf)* 2004;61(4):478-86.
30. Doppman JL, Nieman LK, Chang R, et al. Selective venous sampling from the cavernous sinuses is not a more reliable technique than sampling from the inferior petrosal sinuses in Cushing's syndrome. *J Clin Endocrinol Metab* 1995;80(8):2485-9.
31. Fujimura M, Ikeda H, Takahashi A, Ezura M, Yoshimoto T, Tomimaga T. Diagnostic value of super-selective bilateral cavernous sinus sampling with hypothalamic stimulating hormone loading in patients with ACTH-producing pituitary adenoma. *Neurol Res* 2005;27(1):11-5.
32. Teramoto A, Nemoto S, Takakura K, Sasaki Y, Machida T. Selective venous sampling directly from cavernous sinus in Cushing's syndrome. *J Clin Endocrinol Metab* 1993;76(3):637-41.
33. Lefournier V, Martinie M, Vasdev A, et al. Accuracy of bilateral inferior petrosal or cavernous sinuses sampling in predicting the lateralization of Cushing's disease pituitary microadenoma: influence of catheter position and anatomy of venous drainage. *J Clin Endocrinol Metab* 2003;88(1):196-203.
34. Ilias I, Chang R, Pacak K, et al. Jugular venous sampling: an alternative to petrosal sinus sampling for the diagnostic evaluation of adrenocorticotropic hormone-dependent Cushing's syndrome. *J Clin Endocrinol Metab* 2004;89(8):3795-800.
35. Swearingen B, Katznelson L, Miller K, et al. Diagnostic errors after inferior petrosal sinus sampling. *J Clin Endocrinol Metab* 2004;89(8):3752-63.
36. Doppman JL, Miller DL, Patronas NJ, et al. The diagnosis of acromegaly: value of inferior petrosal sinus sampling. *Am J Roentgenol* 1990;154(5):1075-7.
37. Crock PA, Gilford EJ, Henderson JK, et al. Inferior petrosal sinus sampling in acromegaly. *Aust NZ J Med* 1989;19(3):244-7.
38. Miller DL, Doppman JL, Krudy AG, et al. Localization of parathyroid adenomas in patients who have undergone surgery. Part II. Invasive procedures. *Radiology* 1987;162(1 Pt 1):138-41.
39. Chaffanjon PC, Voirin D, Vasdev A, Chabre O, Kenyon NM, Bricchon PY. Selective venous sampling in recurrent and persistent hyperparathyroidism: indication, technique, and results. *World J Surg* 2004;28(10):958-61.
40. Zarin AA, Ushikoshi S, Houkin K, Kikuchi Y, Abe H, Saitoh H. Cerebral abscess as an unusual complication of coil embolization in a dural arteriovenous fistula. Case report. *J Neurosurg* 1997;87(1):109-12.
41. Klisch J, Huppertz HJ, Spetzger U, Hetzel A, Seeger W, Schumacher M. Transvenous treatment of carotid cavernous and dural arteriovenous fistulae: results for 31 patients and review of the literature. *Neurosurgery* 2003;53(4):836-56; discussion 56-7.
42. Meyers PM, Halbach VV, Dowd CF, et al. Dural carotid cavernous fistula: definitive endovascular management and long-term follow-up. *Am J Ophthalmol* 2002;134(1):85-92.
43. Nakagawa H, Kubo S, Nakajima Y, Izumoto S, Fujita T. Shifting of dural arteriovenous malformation from the cavernous sinus to the sigmoid sinus to the transverse sinus after transvenous embolization. A case of left spontaneous carotid-cavernous sinus fistula. *Surg Neurol* 1992;37(1):30-8.
44. Yamashita K, Taki W, Nakahara I, Nishi S, Sadato A, Kikuchi H. Development of sigmoid dural arteriovenous fistulas after transvenous embolization of cavernous dural arteriovenous fistulas. *Am J Neuroradiol* 1993;14(5):1106-8.
45. Horowitz MB, Purdy PD, Valentine RJ, Morrill K. Remote vascular catastrophes after neurovascular interventional therapy for type 4 Ehlers-Danlos syndrome. *Am J Neuroradiol* 2000;21(5):974-6.
46. Chuman H, Trobe JD, Petty EM, et al. Spontaneous direct carotid-cavernous fistula in Ehlers-Danlos syndrome type IV: two case reports and a review of the literature. *J Neuroophthalmol* 2002;22(2):75-81.
47. Halbach VV, Higashida RT, Hieshima GB, Hardin CW, Pribram H. Transvenous embolization of dural fistulas involving the cavernous sinus. *Am J Neuroradiol* 1989;10(2):377-83.
48. Goto K, Hieshima GB, Higashida RT, et al. Treatment of direct carotid cavernous sinus fistulae. Various therapeutic approaches and results in 148 cases. *Acta Radiol Suppl* 1986;369:576-9.
49. Halbach VV, Higashida RT, Dowd CF, Barnwell SL, Hieshima GB. Treatment of carotid-cavernous fistulas associated with Ehlers-Danlos syndrome. *Neurosurgery* 1990;26(6):1021-7.
50. Miller NR, Monsein LH, Debrun GM, Tamargo RJ, Nauta HJ. Treatment of carotid-cavernous sinus fistulas using a superior ophthalmic vein approach. *J Neurosurg* 1995;83(5):838-42.
51. Chun GF, Tomsick TA. Transvenous embolization of a direct carotid cavernous fistula through the pterygoid plexus. *Am J Neuroradiol* 2002;23(7):1156-9.
52. Barker FG II, Ogilvy CS, Chin JK, Joseph MP, Pile-Spellman J, Crowell RM. Transethmoidal transphenoidal approach for embolization of a carotid-cavernous fistula. Case report. *J Neurosurg* 1994;81(6):921-3.
53. Benndorf G, Bender A, Lehmann R, Lanksch W. Transvenous occlusion of dural cavernous sinus fistulas through the thrombosed inferior petrosal sinus: report of four cases and review of the literature. *Surg Neurol* 2000;54(1):42-54.
54. Monsein LH, Debrun GM, Miller NR, Nauta HJ, Chazaly JR. Treatment of dural carotid-cavernous fistulas via the superior ophthalmic vein. *Am J Neuroradiol* 1991;12(3):435-9.
55. Quinones D, Duckwiler G, Gobin PY, Goldberg RA, Vinuela F. Embolization of dural cavernous fistulas via superior ophthalmic vein approach. *Am J Neuroradiol* 1997;18(5):921-8.
56. Kohyama S, Kaji T, Tokumaru AM, Kusano S, Ishihara S, Shima K. Transfemoral superior ophthalmic vein approach via the facial vein for the treatment of carotid-cavernous fistulas - two case reports. *Neurol Med Chir (Tokyo)* 2002;42(1):18-22.
57. Biondi A, Milea D, Cognard C, Ricciardi GK, Bonneville F, van Effenterre R. Cavernous sinus dural fistulae treated by transvenous approach through the facial vein: report of seven cases and review of the literature. *Am J Neuroradiol* 2003;24(6):1240-6.

58. Oishi H, Arai H, Sato K, Iizuka Y. Complications associated with transvenous embolisation of cavernous dural arteriovenous fistula. *Acta Neurochir (Wien)* 1999;141(12):1265-71.
59. Goldberg RA, Goldey SH, Duckwiler G, Vinuela F. Management of cavernous sinus-dural fistulas. Indications and techniques for primary embolization via the superior ophthalmic vein. *Arch Ophthalmol* 1996;114(6):707-14.
60. Gupta N, Kikkawa DO, Levi L, Weinreb RN. Severe vision loss and neovascular glaucoma complicating superior ophthalmic vein approach to carotid-cavernous sinus fistula. *Am J Ophthalmol* 1997;124(6):853-5.
61. Bendorff G, Bender A, Campi A, Menneking H, Lanksch WR. Treatment of a cavernous sinus dural arteriovenous fistula by deep orbital puncture of the superior ophthalmic vein. *Neuroradiology* 2001;43(6):499-502.
62. Venturi C, Bracco S, Cerase A, et al. Endovascular treatment of a cavernous sinus dural arteriovenous fistula by transvenous embolization through the superior ophthalmic vein via cannulation of a frontal vein. *Neuroradiology* 2003;45(8):574-8.
63. Kazekawa K, Iko M, Sakamoto S, et al. Dural AVFs of the cavernous sinus: transvenous embolization using a direct superficial temporal vein approach. *Radiat Med* 2003;21(3):138-41.
64. Mounayer C, Piotin M, Spelle L, Moret J. Superior petrosal sinus catheterization for transvenous embolization of a dural carotid cavernous sinus fistula. *Am J Neuroradiol* 2002;23(7):1153-5.
65. Kuwayama N, Endo S, Kitabayashi M, Nishijima M, Takaku A. Surgical transvenous embolization of a cortically draining carotid cavernous fistula via a vein of the sylvian fissure. *Am J Neuroradiol* 1998;19(7):1329-32.
66. Hara T, Hamada J, Kai Y, Ushio Y. Surgical transvenous embolization of a carotid-cavernous dural fistula with cortical drainage via a petrosal vein: two technical case reports. *Neurosurgery* 2002;50(6):1380-3; discussion 3-4.
67. Wakhloo AK, Perlow A, Linfante I, et al. Transvenous *n*-butyl-cyanoacrylate infusion for complex dural carotid cavernous fistulas: technical considerations and clinical outcome. *Am J Neuroradiol* 2005;26(8):1888-97.
68. Arat A, Cekirge S, Saatci I, Orzen B. Transvenous injection of Onyx for casting of the cavernous sinus for the treatment of a carotid-cavernous fistula. *Neuroradiology* 2004;46(12):1012-5.
69. Deguchi J, Yamada M, Ogawa R, Kuroiwa T. Transvenous embolization for a purely intraorbital arteriovenous fistula. Case report. *J Neurosurg* 2005;103(4):756-9.
70. Caragine LP, Jr., Halbach VV, Dowd CF, Higashida RT. Intraorbital arteriovenous fistulae of the ophthalmic veins treated by transvenous endovascular occlusion: technical case report. *Neurosurgery* 2006;58(1 Suppl):ONS-E170; discussion ONS-E.
71. Halbach VV, Higashida RT, Hieshima GB, Mehringer CM, Hardin CW. Transvenous embolization of dural fistulas involving the transverse and sigmoid sinuses. *Am J Neuroradiol* 1989;10(2):385-92.
72. Dawson RC, III, Joseph GJ, Owens DS, Barrow DL. Transvenous embolization as the primary therapy for arteriovenous fistulas of the lateral and sigmoid sinuses. *Am J Neuroradiol* 1998;19(3):571-6.
73. Roy D, Raymond J. The role of transvenous embolization in the treatment of intracranial dural arteriovenous fistulas. *Neurosurgery* 1997;40(6):1133-41; discussion 41-4.
74. Gobin YP, Houdart E, Rogopoulos A, Casasco A, Bailly AL, Merland JJ. Percutaneous transvenous embolization through the thrombosed sinus in transverse sinus dural fistula. *Am J Neuroradiol* 1993;14(5):1102-5.
75. Naito I, Iwai T, Shimaguchi H, et al. Percutaneous transvenous embolization through the occluded sinus for transverse-sigmoid dural arteriovenous fistulas with sinus occlusion. *Neuroradiology* 2001;43(8):672-6.
76. Houdart E, Saint-Maurice JP, Chapot R, et al. Transcranial approach for venous embolization of dural arteriovenous fistulas. *J Neurosurg* 2002;97(2):280-6.
77. Liebig T, Henkes H, Brew S, Miloslavski E, Kirsch M, Kuhne D. Reconstructive treatment of dural arteriovenous fistulas of the transverse and sigmoid sinus: transvenous angioplasty and stent deployment. *Neuroradiology* 2005;47(7):543-51.
78. Defreyne L, Vanlangenhove P, Vandekerckhove T, et al. Transvenous embolization of a dural arteriovenous fistula of the anterior cranial fossa: preliminary results. *Am J Neuroradiol* 2000;21(4):761-5.
79. Cloft HJ, Kallmes DF, Jensen JE, Dion JE. Percutaneous transvenous coil embolization of a type 4 sagittal sinus dural arteriovenous fistula: case report. *Neurosurgery* 1997;41(5):1191-3; discussion 3-4.
80. King WA, Martin NA. Intracerebral hemorrhage due to dural arteriovenous malformations and fistulae. *Neurosurg Clin N Am* 1992;3(3):577-90.
81. Deasy NP, Gholkar AR, Cox TC, Jeffrey MA. Tentorial dural arteriovenous fistulae: endovascular treatment with transvenous coil embolisation. *Neuroradiology* 1999;41(4):308-12.
82. Kallmes DF, Jensen ME, Cloft HJ, Kassell NF, Dion JE. Percutaneous transvenous coil embolization of a Djudjian type 4 tentorial dural arteriovenous malformation. *Am J Neuroradiol* 1997;18(4):673-6.
83. Troffkin NA, Graham CB, III, Berkmen T, Wakhloo AK. Combined transvenous and transarterial embolization of a tentorial-incisural dural arteriovenous malformation followed by primary stent placement in the associated stenotic straight sinus. Case report. *J Neurosurg* 2003;99(3):579-83.
84. Mickle JP, Quisling RG. The transtocular embolization of vein of Galen aneurysms. *J Neurosurg* 1986;64(5):731-5.
85. Dowd CF, Halbach VV, Barnwell SL, Higashida RT, Edwards MS, Hieshima GB. Transfemoral venous embolization of vein of Galen malformations. *Am J Neuroradiol* 1990;11(4):643-8.
86. Lasjaunias P, Garcia-Monaco R, Rodesch G, et al. Vein of Galen malformation. Endovascular management of 43 cases. *Childs Nerv Syst* 1991;7(7):360-7.
87. Lasjaunias P, Garcia-Monaco R, Rodesch G, Terbrugge K. Deep venous drainage in great cerebral vein (vein of Galen) absence and malformations. *Neuroradiology* 1991;33(3):234-8.
88. Levrier O, Gailloud PH, Souei M, Manera L, Brunel H, Raybaud C. Normal galenic drainage of the deep cerebral venous system in two cases of vein of Galen aneurysmal malformation. *Childs Nerv Syst* 2004;20(2):91-7; discussion 8-9.
89. Gailloud P, O'Riordan DP, Burger J, Lehmann CU. Confirmation of communication between deep venous drainage and the vein of Galen after treatment of a vein of Galen aneurysmal malformation in an infant presenting with severe pulmonary hypertension. *Am J Neuroradiol* 2006;27(2):317-20.
90. Ng PP, Halbach VV, Quinn R, et al. Endovascular treatment for dural arteriovenous fistulae of the superior petrosal sinus. *Neurosurgery* 2003;53(1):25-32; discussion 32-3.
91. Kato S, Fujii M, Tominaga T, Fujisawa H, Suzuki M. A case of dural arteriovenous fistula of the inferior petrosal sinus successfully treated by transarterial and transvenous embolizations. *No Shinkei Geka* 2002;30(9):981-4.
92. Ernst R, Bulas R, Tomsick T, van Loveren H, Aziz KA. Three cases of dural arteriovenous fistula of the anterior condylar vein within the hypoglossal canal. *Am J Neuroradiol* 1999;20(10):2016-20.
93. Kiyosue H, Tanoue S, Okahara M, Mori M, Mori H. Ocular symptoms associated with a dural arteriovenous fistula involving the hypoglossal canal: selective transvenous coil embolization. Case report. *J Neurosurg* 2001;94(4):630-2.
94. Tanoue S, Goto K, Oota S. Endovascular treatment for dural arteriovenous fistula of the anterior condylar vein with unusual venous drainage: report of two cases. *Am J Neuroradiol* 2005;26(8):1955-9.
95. Manabe H, Hasegawa S, Takemura A, Shafiqul IM, Ito C, Nagahata M. Contralateral inferior petrosal sinus approach for transvenous embolization of a dural arteriovenous fistula at isolated jugular bulb. Technical case report. *Minim Invasive Neurosurg* 2003;46(6):366-8.
96. Beek FJ, ten Broek FW, van Schaik JP, Mali WP. Transvenous embolisation of an arteriovenous malformation of the mandible via a femoral approach. *Pediatr Radiol* 1997;27(11):855-7.

97. Kiyosue H, Mori H, Hori Y, Okahara M, Kawano K, Mizuki H. Treatment of mandibular arteriovenous malformation by transvenous embolization: a case report. *Head Neck* 1999;21(6):574-7.
98. Kawano K, Mizuki H, Mori H, Yanagisawa S. Mandibular arteriovenous malformation treated by transvenous coil embolization: a long-term follow-up with special reference to bone regeneration. *J Oral Maxillofac Surg* 2001;59(3):326-30.
99. Touho H, Monobe T, Ohnishi H, Karasawa J. Treatment of type II perimedullary arteriovenous fistulas by intraoperative transvenous embolization: case report. *Surg Neurol* 1995;43(5):491-6.
100. Chul Suh D, Gon Choi C, Bo Sung K, Kim KK, Chul Rhim S. Spinal osseous epidural arteriovenous fistula with multiple small arterial feeders converging to a round fistular nidus as a target of venous approach. *Am J Neuroradiol* 2004;25(1):69-73.
101. Stam J. Thrombosis of the cerebral veins and sinuses. *N Engl J Med* 2005;352(17):1791-8.
102. Chang R, Friedman DP. Isolated cortical venous thrombosis presenting as subarachnoid hemorrhage: a report of three cases. *Am J Neuroradiol* 2004;25(10):1676-9.
103. Oppenheim C, Domigo V, Gaurvit JY, et al. Subarachnoid hemorrhage as the initial presentation of dural sinus thrombosis. *Am J Neuroradiol* 2005;26(3):614-7.
104. Spitzer C, Mull M, Rohde V, Kosinski CM. Non-traumatic cortical subarachnoid haemorrhage: diagnostic work-up and aetiological background. *Neuroradiology* 2005;47(7):525-31.
105. Ferro JM, Lopes MG, Rosas MJ, Fontes J. Delay in hospital admission of patients with cerebral vein and dural sinus thrombosis. *Cerebrovasc Dis* 2005;19(3):152-6.
106. Ferro JM, Canhao P, Stam J, Boussier MG, Barinagarrementeria F. Prognosis of cerebral vein and dural sinus thrombosis: results of the International Study on Cerebral Vein and Dural Sinus Thrombosis (ISCVT). *Stroke* 2004;35(3):664-70.
107. Ferro JM, Canhao P, Boussier MG, Stam J, Barinagarrementeria F. Cerebral vein and dural sinus thrombosis in elderly patients. *Stroke* 2005;36(9):1927-32.
108. Bonduel M, Sciuccati G, Hepner M, et al. Arterial ischemic stroke and cerebral venous thrombosis in children: a 12-year Argentinian registry. *Acta Haematol* 2006;115(3-4):180-5.
109. Maqueda VM, Thijs V. Risk of thromboembolism after cerebral venous thrombosis. *Eur J Neurol* 2006;13(3):302-5.
110. Martinelli I, Sacchi E, Landi G, Taioli E, Duca F, Mannucci PM. High risk of cerebral-vein thrombosis in carriers of a prothrombin-gene mutation and in users of oral contraceptives. *N Engl J Med* 1998;338(25):1793-7.
111. Arxer A, Pardina B, Blas I, Ramio L, Villalonga A. Dural sinus thrombosis in a late preeclamptic woman. *Can J Anaesth* 2004;51(10):1050-1.
112. Zapanta PE, Chi DH, Faust RA. A unique case of Bezold's abscess associated with multiple dural sinus thromboses. *Laryngoscope* 2001;111(11 Pt 1):1944-8.
113. Nakase H, Shin Y, Nakagawa I, Kimura R, Sakaki T. Clinical features of postoperative cerebral venous infarction. *Acta Neurochir (Wien)* 2005;147(6):621-6; discussion 6.
114. Emir M, Ozisik K, Cagli K, Bakuy V, Ozisik P, Sener E. Dural sinus thrombosis after cardiopulmonary bypass. *Perfusion* 2004;19(2):133-5.
115. Smith AG, Cornblath WT, Deveikis JP. Local thrombolytic therapy in deep cerebral venous thrombosis. *Neurology* 1997;48(6):1613-9.
116. Canhao P, Ferro JM, Lindgren AG, Boussier MG, Stam J, Barinagarrementeria F. Causes and predictors of death in cerebral venous thrombosis. *Stroke* 2005;36(8):1720-5.
117. Einhaupl KM, Villringer A, Meister W, et al. Heparin treatment in sinus venous thrombosis. *Lancet* 1991;338(8767):597-600.
118. Masuhr F, Mehraein S. Cerebral venous and sinus thrombosis: patients with a fatal outcome during intravenous dose-adjusted heparin treatment. *Neurocrit Care* 2004;1(3):355-61.
119. Barnwell SL, Higashida RT, Halbach VV, Dowd CF, Hieshima GB. Direct endovascular thrombolytic therapy for dural sinus thrombosis. *Neurosurgery* 1991;28(1):135-42.
120. Horowitz M, Purdy P, Unwin H, et al. Treatment of dural sinus thrombosis using selective catheterization and urokinase. *Ann Neurol* 1995;38(1):58-67.
121. Rottger C, Madlener K, Heil M, et al. Is heparin treatment the optimal management for cerebral venous thrombosis? Effect of abciximab, recombinant tissue plasminogen activator, and enoxaparin in experimentally induced superior sagittal sinus thrombosis. *Stroke* 2005;36(4):841-6.
122. Chow K, Gobin YP, Saver J, Kidwell C, Dong P, Vinuela F. Endovascular treatment of dural sinus thrombosis with rheolytic thrombectomy and intra-arterial thrombolysis. *Stroke* 2000;31(6):1420-5.
123. Liebetrau M, Mayer TE, Bruning R, Opherk C, Hamann GF. Intra-arterial thrombolysis of complete deep cerebral venous thrombosis. *Neurology* 2004;63(12):2444-5.
124. Chaloupka JC, Mangla S, Huddle DC. Use of mechanical thrombolysis via microballoon percutaneous transluminal angioplasty for the treatment of acute dural sinus thrombosis: case presentation and technical report. *Neurosurgery* 1999;45(3):650-6; discussion 6-7.
125. Philips MF, Bagley LJ, Sinson GP, et al. Endovascular thrombolysis for symptomatic cerebral venous thrombosis. *J Neurosurg* 1999;90(1):65-71.
126. Dowd CF, Malek AM, Phatouros CC, Hemphill JC, III. Application of a rheolytic thrombectomy device in the treatment of dural sinus thrombosis: a new technique. *Am J Neuroradiol* 1999;20(4):568-70.
127. Wasay M, Bakshi R, Kojan S, Bobustac G, Dubey N, Unwin DH. Nonrandomized comparison of local urokinase thrombolysis versus systemic heparin anticoagulation for superior sagittal sinus thrombosis. *Stroke* 2001;32(10):2310-7.
128. Chahlav A, Steinmetz MP, Masaryk TJ, Rasmussen PA. A transcranial approach for direct mechanical thrombectomy of dural sinus thrombosis. Report of two cases. *J Neurosurg* 2004;101(2):347-51.
129. van Nuenen BF, Munneke M, Bloem BR. Cerebral venous sinus thrombosis: prevention of recurrent thromboembolism. *Stroke* 2005;36(9):1822-3.
130. Marks MP, Dake MD, Steinberg GK, Norbush AM, Lane B. Stent placement for arterial and venous cerebrovascular disease: preliminary experience. *Radiology* 1994;191(2):441-6.
131. Higgins JN, Owler BK, Cousins C, Pickard JD. Venous sinus stenting for refractory benign intracranial hypertension. *Lancet* 2002;359(9302):228-30.
132. Owler BK, Allan R, Parker G, Besser M. Pseudotumor cerebri, CSF rhinorrhoea and the role of venous sinus stenting in treatment. *Br J Neurosurg* 2003;17(1):79-83.
133. Owler BK, Parker G, Halmagyi GM, et al. Pseudotumor cerebri syndrome: venous sinus obstruction and its treatment with stent placement. *J Neurosurg* 2003;98(5):1045-55.
134. Higgins JN, Cousins C, Owler BK, Sarkies N, Pickard JD. Idiopathic intracranial hypertension: 12 cases treated by venous sinus stenting. *J Neurol Neurosurg Psychiatry* 2003;74(12):1662-6.
135. Ogungbo B, Roy D, Gholkar A, Mendelow AD. Endovascular stenting of the transverse sinus in a patient presenting with benign intracranial hypertension. *Br J Neurosurg* 2003;17(6):565-8.
136. Metellus P, Levrier O, Fuentes S, et al. Endovascular treatment of benign intracranial hypertension by stent placement in the transverse sinus. Therapeutic and pathophysiological considerations illustrated by a case report. *Neurochirurgie* 2005;51(2):113-20.
137. Skau M, Brennum J, Gjerris F, Jensen R. What is new about idiopathic intracranial hypertension? An updated review of mechanism and treatment. *Cephalalgia* 2006;26(4):384-99.
138. Karahalios DG, Rekate HL, Khayata MH, Apostolides PJ. Elevated intracranial venous pressure as a universal mechanism in pseudotumor cerebri of varying etiologies. *Neurology* 1996;46(1):198-202.
139. Brazis PW. Pseudotumor cerebri. *Curr Neurol Neurosci Rep* 2004;4(2):111-6.

140. Murphy KJ, Gailloud P, Venbrux A, Deramond H, Hanley D, Rigamonti D. Endovascular treatment of a grade IV transverse sinus dural arteriovenous fistula by sinus recanalization, angioplasty, and stent placement: technical case report. *Neurosurgery* 2000;46(2):497-500; discussion 500-1.
141. Sanchez TG, Murao M, de Medeiros IR, et al. A new therapeutic procedure for treatment of objective venous pulsatile tinnitus. *Int Tinnitus J* 2002;8(1):54-7.
142. Zenteno M, Murillo-Bonilla L, Martinez S, et al. Endovascular treatment of a transverse-sigmoid sinus aneurysm presenting as pulsatile tinnitus. Case report. *J Neurosurg* 2004;100(1):120-2.
143. Tsumoto T, Miyamoto T, Shimizu M, et al. Restenosis of the sigmoid sinus after stenting for treatment of intracranial venous hypertension: case report. *Neuroradiology* 2003;45(12):911-5.

13. Intracranial Aneurysms and Subarachnoid Hemorrhage

An aneurysm is an abnormal dilatation of an artery. In layman's terms, an aneurysm can be thought of as a weak spot in the wall of an artery, similar to a garden hose that has been filed down on one side; water under pressure inside the hose will make the weak spot bulge out. Intracranial aneurysms can be broadly classified as saccular, fusiform, or dissecting.

13.1. Intracranial aneurysms: Pathophysiology

13.1.1. Pathology of intracranial aneurysms

An aneurysm is, by definition, an arterial structure. Most saccular aneurysms share a common morphology.¹⁻³

1. Mechanism of formation. Intracranial aneurysms appear to result from a complex series of factors including hemodynamic stress, sustained abnormal vascular remodeling, and inflammation.^{4,5}
2. Saccular aneurysms are typically found at arterial branch points, where there is a gap in the media, although a significant percentage of aneurysms are not clearly associated with a branching vessel.
3. Gross anatomy:
 - (a) Unruptured aneurysms may appear uniformly pink, like adjacent arteries, or they may have red areas, representing nearly translucent regions of the aneurysm dome, through which blood can be seen. Aneurysms may also have thick, atheromatous areas as well.
 - (b) Ruptured aneurysms. Aneurysms typically rupture at the apex of the dome; a dense fibrin cap is usually found in this region during surgery.
 - (c) Morphological features:
 - Multiple lobes. Some 9% of unruptured aneurysms and 40% of ruptured aneurysms are multilobular.⁶
 - Daughter sac. A daughter sac was found in 57% of ruptured aneurysms and 16% of unruptured aneurysms.⁷ Also sometimes referred to as "Murphy's tit."
 - (d) Site distribution (unruptured aneurysms in patients with no prior history of SAH).⁸
 - Cavernous carotid artery, 16.9%.
 - ICA, 24.8%.
 - Anterior communicating or ACA, 10.0%.
 - MCA, 22.7%.
 - Posterior communicating artery, 13.9%.
 - Vertebrobasilar or PCA, 6.6%.
 - Basilar artery apex, 5.1%.
 - (e) Single vs. multiple aneurysms:
 - Two or more aneurysms are found in 15–30% of patients.⁹⁻¹³
 - Risk factors for multiple aneurysms include female sex,¹⁰⁻¹⁴ cigarette smoking,^{10,11} hypertension,¹¹ a family history of cerebrovascular disease,¹¹ and postmenopausal state.¹¹
4. Histopathology (Fig. 13.1):
 - (a) At the edge of the aneurysm neck, there is an abrupt termination of the tunica media and internal elastic lamina.
 - (b) The aneurysm sac is mostly composed of collagenous tissue and is frequently acellular:
 - However, fibrin staining is present on the luminal side of the aneurysm wall in 50% of cases, and the aneurysm wall contains numerous

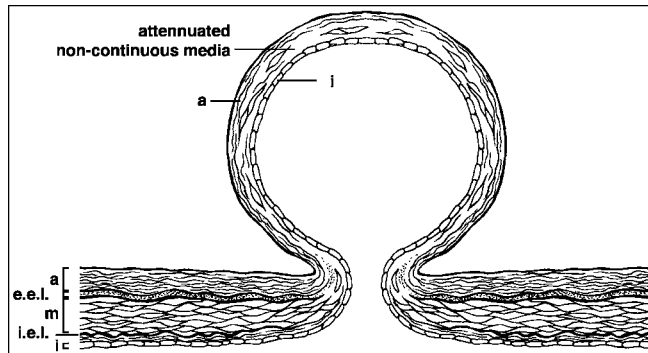


Fig. 13.1 Microscopic anatomy of an intracranial aneurysm. The internal elastic lamina is absent in the wall of the aneurysm, and the media is present but abnormal, being thin and discontinuous throughout the aneurysm dome. *a* adventitia, *m* media, *i* intima, *eel* external elastic lamina, *iel* internal elastic lamina.

polymorphonuclear leukocytes in 29% of cases; these findings may be a sign of “impending rupture” of the aneurysm.⁷

- Other “signs of impending rupture” include.¹⁵
 - Unusually thin areas in the wall.
 - Daughter sacs.
 - Patchy fibrin infiltration.
 - Intraluminal thrombus.
 - Inflammatory cells in the aneurysm wall.
 - Blood pigment containing macrophages and erythrocytes in the wall.

13.1.2. The Peculiar Infundibulum

An infundibulum is a conical dilatation at the origin of an artery (see Chap. 1). Infundibula are benign incidental findings. A small number of cases in which a P-comm infundibulum progressed to aneurysm formation and rupture have been reported. A total of 11 reports were analyzed by Marshman and colleagues in 1998.¹⁶ In this review, there was a preponderance of women (female-to-male ratio, 9:1), left-sided lesions (left-to-right ratio, 9:2), and bilateral infundibula (60%).

13.2. Unruptured intracranial aneurysms

13.2.1. Prevalence

Data on the prevalence of intracranial aneurysms in the general population comes from autopsy series and angiography series:

1. A systematic review of recent series (both autopsy and angiography studies) found that the prevalence of aneurysms for adults without SAH is approximately 2%.¹⁷
 - (a) Sex distribution. The male/female ratio for aneurysms is approximately 1:1.3.

- (b) Age distribution. The prevalence of aneurysms increases with age, peaking in the 60–79 year age group.¹⁷

13.2.2. Conditions associated with aneurysms

13.2.2.1. Familial aneurysms

1. Definition of “familial aneurysms”: When ≥ 2 first-degree relatives are affected.^{18,19}
2. Aside from autosomal dominant polycystic kidney disease (ADPKD), a familial predisposition is the strongest risk factor for the development of intracranial aneurysms.¹⁷
3. Prevalence. Estimates of the frequency of familial intracranial aneurysms range from 7 to 20%.¹⁹⁻²²
 - (a) Inheritance patterns and features:
 - In most pedigrees, the inheritance pattern is unclear, although autosomal dominant transmission is thought to be the most likely.^{23,24}
 - Familial aneurysms have a predilection for the middle cerebral artery.²⁴
 - Familial aneurysms are generally larger at the time of rupture and more likely to be multiple than sporadic aneurysms.²⁵
 - Subarachnoid hemorrhage tends to occur at a significantly younger age in patients with familial aneurysms compared to patients with sporadic aneurysms.²⁴
 - Patients with familial SAH have a greater risk of poor outcome than patients with sporadic SAH.²⁶
4. A wide array of genes and chromosomal regions have been linked to intracranial aneurysms, of both sporadic and familial nature.²⁷⁻²⁹
5. Screening in patients with familial intracranial aneurysms:
 - (a) Controversial. A theoretical model concluded that routine screening is not advantageous, even in individuals with a history of ≥ 2 affected first-degree relatives with SAH.³⁰ The American Heart Association *Recommendations for the Management of Patients with Unruptured Intracranial Aneurysms* suggests that screening in patients at risk of familial intracranial aneurysms be done on an individual basis.³⁰
 - (b) In most situations, the authors of this handbook prefer to use noninvasive imaging to screen patients with ≥ 2 first-degree relatives with aneurysms:
 - This strategy will identify an aneurysm in 8–10% of individuals.^{19,31-33}
6. The Familial Intracranial Aneurysm Study³⁴ (Table 13.1):
 - (a) Ongoing, international, multicenter study of families with a history of intracranial aneurysms.
 - (b) Families with at least two affected siblings are eligible.
 - (c) The study Web site is <http://www.fiastudy.org> and the toll free number 800-503-3427.

Table 13.1 Yield of screening for asymptomatic intracranial aneurysms

Population	Risk of having an intracranial aneurysm (%)
General population	2
First-degree relatives in families with one affected member	2–4
First-degree relatives in families ≥ 2 affected members	10

Source:³⁵

13.2.2.2. Connective tissue disorders

AUTOSOMAL DOMINANT POLYCYSTIC KIDNEY DISEASE

1. Most common life-threatening hereditary disease,³⁶ affecting 1 in 500 individuals in the United States and Europe:
 - (a) Expression is variable but penetrance reaches 100% by age 80.
 - (b) Two genes have been identified. Both are strongly expressed in vascular smooth muscle cells of normal adult arteries:
 - *PKD1* is responsible for ~85% of ADPKD cases. It encodes polycystin 1, a membrane protein that mediates cell-cell and cell-matrix interactions.³⁷
 - *PKD2*, responsible for most of the remaining cases of ADPKD, encodes polycystin 2, a membrane protein with homology to voltage-activated calcium channels, and is believed to interact with polycystin 1.³⁸
 - Polycystins are involved in the functional interaction between arterial smooth muscle cells and adjacent elastic tissue or endothelial cells. Mutations in the genes for these proteins may disrupt this interaction and weaken the vessel wall.³⁵
 - (c) ADPKD is a systemic disease:
 - Cysts develop in the kidneys, liver, pancreas, spleen, ovaries, and seminal vesicles.
 - Systemic manifestations:⁴⁰ Hypertension (in 80% of patients), end-stage renal disease (in 45% of patients by age 60), and hepatic cysts (in 60% of adults). Other commonly associated conditions are pancreatic cysts, mitral valve prolapse and colonic diverticula.
 - Neurological manifestations:
 - Hypertensive intracerebral hemorrhage.
 - Ischemic stroke:
 - (a) Hemorrhagic and ischemic stroke are the most common acute neurological events affecting patients with ADPKD.⁴¹
 - Intracranial aneurysms.
 - Cervicocephalic arterial dissections.⁴²
 - Intracranial dolichoectasia.⁴³
 - Intracranial arachnoid cysts.⁴⁴
 - Spinal meningeal diverticula.⁴⁵
 - Chronic subdural hematomas.⁴⁶
2. ADPKD and intracranial aneurysms:
 - (a) Estimates of the prevalence of intracranial aneurysms in patients with ADPKD: range from 4.0 to 40%.⁴⁷⁻⁴⁹
 - Conversely, patients with ADPKD represent only a small fraction of patients with intracranial aneurysms.¹⁹
 - (b) The incidence of SAH in patients with ADPKD is estimated at approximately 1/2,000 person-years,⁵⁰ or about five times higher than the general population.⁵¹ *However, a population-based study of the specific risk of SAH in patients with ADPKD and an unruptured aneurysm has not yet been published.*
 - (c) The risk of having an intracranial aneurysm in a patient with ADPKD is strongly related to whether the patient has a family history of intracranial aneurysms or SAH:
 - In three large prospective series, an intracranial aneurysm was found in 15.6% of patients with a family history of aneurysms vs. 5.9% of patients without a family history of aneurysms.^{47,48,52,53}
 - (d) The average age of patients with ADPKD and SAH is 41, and 10% of patients are <21 years old.⁵⁴
 - (e) Patients with ADPKD and an aneurysm are prone to developing additional aneurysms. In an average follow-up period of 15.2 years, 25% of patients with known intracranial aneurysms were found to have at least one additional aneurysm.⁵⁵
 - Conversely, patients with ADPKD and no evidence of an intracranial aneurysm on radiographic imaging are unlikely to develop

- an aneurysm. At an average follow-up of 9.8 years, only 2.6% of patients were found to have an aneurysm on imaging.⁵⁶
3. Screening for intracranial aneurysms in patients with ADPKD.⁵⁷
 - (a) Routine screening is appropriate for:
 - Patients with a family history of aneurysms or SAH or,
 - Patients with a known aneurysm or a history of aneurysms or SAH.
 - (b) Noninvasive imaging (i.e., CTA or MRA) is adequate for screening. The authors prefer annual or biannual imaging for patients with ADPKD who are at risk.
 - (c) Patients without a family or personal history of aneurysms are not routinely screened.

EHLERS–DANLOS SYNDROME (EDS) TYPE IV

1. Hereditary connective tissue disorder characterized by joint hypermobility, hyperelastic or fragile skin, easy bruising, and abnormal scarring. Ten subtypes have been described.
2. EDS Type IV, also known as *vascular EDS*, accounts for only 4% of EDS cases but is the most severe:
 - (a) Prevalence: 1 in 50,000 to 100,000 persons.⁵⁷
 - (b) Characterized by a decrease or absence of type III collagen.
 - (c) Autosomal dominant.
 - (d) Median survival is 48 years.⁵⁸
 - (e) Vascular manifestations of EDS consist of spontaneous dissection, aneurysm formation, and rupture of large and medium arteries. Arterial rupture accounts for most deaths.
 - (f) The most common neurovascular complication is spontaneous carotid-cavernous fistula, followed by ruptured intracranial aneurysms and spontaneous intracerebral hemorrhage, and carotid dissection.^{59,60}
 - All vascular procedures in patients with EDS Type IV, including angiography, endovascular procedures, and surgery, are high risk, because of the friability of vessel walls. In a series of EDS Type IV patients undergoing angiography, major complications occurred in 22% and death in 5.6%.⁶¹
 - (g) The utility of routine screening for intracranial aneurysms is controversial, because of the high complication rates associated with treatment.⁶²

α_1 -ANTITRYPSIN DEFICIENCY

1. The major function of α_1 -antitrypsin, a circulating antiprotease that is synthesized in the liver, is to protect the lungs against neutrophil elastase. α_1 -Antitrypsin deficiency is characterized by damage to elastic tissue, most commonly emphysema. Inheritance follows an autosomal codominant pattern; the gene is located on chromosome 14, and a large number of allelic variants have been identified.⁶³
2. Vascular disorders associated with α_1 -antitrypsin deficiency include arterial aneurysms, spontaneous dissections, and fibromuscular dysplasia.
3. Both the heterozygous and homozygous α_1 -antitrypsin deficiency states have been suspected to be genetic risk factors for intracranial aneurysms,⁶⁴ although other studies have found otherwise.⁶⁵⁻⁶⁷
4. Screening for asymptomatic intracranial aneurysms in individuals with α_1 -antitrypsin deficiency is generally not recommended.³⁵

MARFAN SYNDROME

1. Autosomal dominant disorder caused by mutations in the gene encoding fibrillin-1. Fibrillin-1 is a glycoprotein which is an important structural component of the extracellular matrix.
2. Vascular manifestations include aortic and mitral valve insufficiency, and aortic artery dissection and rupture.
3. Although a number of reports have associated Marfan syndrome with intracranial aneurysms, the weight of clinical evidence appears to indicate that Marfan syndrome is not associated with an increased prevalence of intracranial aneurysms.^{68,69}

NEUROFIBROMATOSIS TYPE 1

1. Autosomal dominant disorder caused by mutations in the neurofibromatosis-1 gene, which encodes neurofibronin. Neurofibronin may have a regulatory role in the development of various connective tissues.
2. Vascular manifestations include stenosis, aneurysm or fistula formation, and rupture of large and medium size arteries.³⁵
3. Firm evidence for an increased risk of intracranial aneurysms in patients with neurofibromatosis has not been shown.

PSEUDOXANTHOMA ELASTICUM

1. An heritable connective tissue disorder in which the elastic fibers of the skin, eyes, and cardiovascular system become slowly calcified and characteristic skin lesions appear, which resemble xanthomas.
2. Prevalence is approximately 1 per 100,000.
3. Stroke caused by stenotic-occlusive disease of the carotid and vertebral arteries is the most commonly reported neurovascular manifestation.⁷⁰
4. An association between pseudoxanthoma elasticum and intracranial aneurysms has been reported,⁷¹ although a study of 100 patients with the disorder found no history of "symptomatic intracranial aneurysms."⁷² This association appears to be discussed in textbooks and reviews more often than it has actually been reported.

13.2.2.3. Other conditions associated with intracranial aneurysms

ARTERIOVENOUS MALFORMATION

Up to 25% of patients with an arteriovenous malformation (AVM) have associated intracranial aneurysms.⁷³ About half of these aneurysms are present on a feeding vessel or on a major artery that participates in the arterial supply to the AVM, and most of the remaining are present within the AVM nidus. The effect of the presence of aneurysms in patients with an AVM on risk of hemorrhage is not clear, as some studies have found an increased risk of hemorrhage in this situation,⁷³⁻⁷⁵ while others have not.⁷⁶⁻⁷⁷

FIBROMUSCULAR DYSPLASIA

A systematic review of 17 studies found a prevalence of intracranial aneurysms in patients with cervical carotid and/or vertebral artery fibromuscular dysplasia of about 7%.⁷⁸

ABDOMINAL AORTIC ANEURYSMS

Intracranial aneurysms are associated with abdominal aortic aneurysms,⁷⁹ and first-degree relatives of patients with abdominal aortic aneurysms appear to be at a significantly increased risk of having an intracranial aneurysm (relative risk, 2.87-4.04).⁸⁰

SICKLE CELL ANEMIA

Sickle cell anemia is associated with intracranial aneurysms. In a review of 44 reported cases of aneurysms in sickle cell patients, 57% of patients were found to have multiple aneurysms, and 31% of the aneurysms were located in the posterior circulation.⁸¹

13.2.2.4. Modifiable risk factors for aneurysm formation and subarachnoid hemorrhage

A discussion of modifiable risk factors should be included in the management of any patient with an intracranial aneurysm. Of the following risk factors, cigarette smoking, hypertension and heavy drinking are the most significant.⁸²

CIGARETTE SMOKING

Cigarette smoking appears to strongly influence intracranial aneurysms in a very meaningful way. The mechanism is unclear; however, an imbalance in the serum elastase/ α_1 -antitrypsin ratio or increased elastase activity in smokers may contribute to aneurysm formation or SAH.⁸³

1. Aneurysm formation. Smokers have a greater incidence of multiple aneurysms.^{10,12}
2. Growth. Cigarette smoking was found to be strongly associated with growth of unruptured aneurysms.⁸⁴
3. Rupture. Case-control studies have found the relative risk of aneurysmal SAH for smokers to be twice or more that of nonsmokers.^{85,86} Other studies have confirmed that smoking is an independent risk factor for SAH.^{66,87,88}
4. Vasospasm. Smokers have an increased incidence of symptomatic cerebral vasospasm after SAH.^{89,90}

Smoking Cessation and Drugs to Help with It

Smoking is the single most important modifiable risk factor in patients with intracranial aneurysms. For patients who smoke, aneurysm management must include a discussion of the importance of smoking cessation and help, if needed. Two medications that can help patients stop smoking are varenicline and bupropion. Dosing and side effects are discussed in Chap. 17.

HYPERTENSION

Hypertension is a risk factor for SAH.^{82,86,91,92}

ALCOHOL USE

Alcohol consumption (in most studies, >2 drinks per day) has been shown to increase the risk of SAH, independently of cigarette smoking, and history of hypertension.^{66,82,93,94} Patients who drink more than their physician does should be advised to cut back on alcohol consumption.

ORAL CONTRACEPTIVES

There is evidence from systematic reviews both for⁹⁵ and against⁹⁶ oral contraceptives as a risk factor for SAH.

ATHEROSCLEROSIS

Increased serum cholesterol is a risk factor for SAH.⁹⁷

COFFEE USE

Coffee consumption >5 cups per day was found to be an independent risk factor for SAH.⁹¹

13.2.2.5. Natural history

The natural history of unruptured intracranial aneurysms is unclear and controversial. The most prominent studies concerning natural history include a study by Juvela and colleagues of a Finnish population that featured a 100% follow-up averaging 18 years,⁸⁷ a meta-analysis of publications on the topic from 1955 to 1996,¹⁷ a systematic review of the literature from Japan,⁹⁸ and the 800 pound gorilla in the field, the International Study of Unruptured Intracranial Aneurysms (ISUIA).^{8,99} Each study has unique strengths and limitations. The ISUIA is currently still going on. Two Japanese prospective studies are currently in progress, the Unruptured Cerebral Aneurysm Study in Japan¹⁰⁰ and the Small Unruptured Aneurysm Verification study.¹⁰¹

JUVELA 2000

1. Comprehensive cohort study of patients found to have unruptured intracranial aneurysms in Finland, from 1956 to 1978. The strengths of this study lay in the fact that prior to 1979, unruptured aneurysms were not surgically treated at the authors' center, which was the only neurosurgical clinic in Finland until the late 1960s. Also, the unique socioeconomic structure of Finland permitted longer and more complete follow-up than has been achieved in any other study.
2. A total of 142 patients were studied; mean follow-up was 18.1 years.
3. Annual rate of rupture according to:
 - (a) Patient history:
 - Incidental aneurysm, no history of SAH, 1.0%.
 - Incidental aneurysm with a history of SAH, 1.3%.
 - Symptomatic aneurysm, 2.6%.
 - (b) Aneurysm size:
 - 2–6 mm, 1.1%.
 - 7–9 mm, 2.3%.
 - 10–26 mm, 2.8%.
4. Mortality rate with rupture: 52%.
5. Limitations: Small total number of patients, homogeneous population, majority of patients (92%) had a history of SAH.

RINKEL 1998

1. Meta-analysis of nine studies, totaling 3,907 patient-years, found an overall risk of rupture of 1.9% per year, and an increased risk of rupture in women, older patients, symptomatic aneurysms, larger size, and posterior circulation location. Results are summarized in [Table 13.2](#).
2. Limitations: The meta-analysis included retrospective studies, and studies done prior to the CT-era.

Table 13.2 Systematic review: factors associated with rupture

Risk factor		Annual risk of rupture (%)
Overall		1.9
Sex	Male	1.3
	Female	2.6
Age	20–39	0
	40–59	3.5
	60–79	5.7
Type of aneurysm	Asymptomatic	0.8
	Asymptomatic, history of SAH	1.4
	Symptomatic	6.5
Site	ACA	1.1
	MCA	1.1
	ICA	1.2
	Posterior circulation	4.4
Size	≤10 mm	0.7
	>10 mm	4.0

From ¹⁷

MORITA 2005

1. Meta-analysis of 13 Japanese studies, totaling 3,801 patient-years, found an annual rupture rate of 2.7%. All studies were fairly recent (earliest was published in 1992).
2. The rate of rupture was increased by:
 - (a) Diameter ≥10, relative risk (RR) 6.4.
 - (b) Posterior circulation location, RR 2.3.
 - (c) Symptomatic aneurysm, RR 2.1.

3. Evidence has accumulated in other studies to support the finding that Japanese patients with unruptured intracranial aneurysms are at higher risk of rupture compared to other ethnic groups. The rate of SAH in the Japanese population is nearly nine times higher than the incidence observed in Rochester, Minnesota,^{102,103} while the prevalence of unruptured intracranial aneurysms is not significantly different,¹⁷ and the prevalence of smoking and hypertension in Japanese adults is not higher than that of the US population.¹⁰⁴⁻¹⁰⁶
4. Limitations: The meta-analysis included retrospective studies; a single ethnic group.

13.2.2.6. International Study of Unruptured Intracranial Aneurysms

The ISUIA is the largest study of the natural history of unruptured intracranial aneurysms, involving a total of 4,060 patients at 53 centers in the United States, Canada, and Europe. The study began in 1991 and is still in progress. Two reports have been published, in *The New England Journal of Medicine* in 1998 and in *Lancet* in 2003. The first paper, containing both retrospective and prospective data, generated controversy mainly because of the finding of a yearly rupture rate for small anterior circulation aneurysms of only 0.05%. The second report provided further evidence of a low rate of rupture for small anterior circulation aneurysms and also included more detailed data on treatment outcomes.

ISUIA FIRST STUDY

A total of 2,621 patients were included in the first ISUIA report.⁸ The study had a retrospective component, in which the natural history of unruptured aneurysms was assessed, and a prospective component, which focused on surgical morbidity and mortality:

1. Retrospective component. A total of 1,449 patients with 1,937 intracranial aneurysms were divided into two groups: 727 individuals with no history of SAH (Group 1) and 722 with a history of SAH from a different aneurysm (Group 2). Mean duration of follow-up was 8.3 years:
 - (a) Annual rupture rates:
 - Group 1:
 - Aneurysm diameter <10 mm: ~0.05%.
 - Aneurysm diameter ≥10 mm: ~1%.
 - Group 2:
 - Aneurysm diameter <10 mm: ~0.5%.
 - Aneurysm diameter ≥10 mm: ~1%.
 - (b) Predictors of rupture:
 - Group 1. The only independent predictors of rupture were the size and location of the aneurysm:
 - Size. Relative risk of rupture for aneurysms 10–24 mm in diameter (compared to aneurysms <10 mm) was 11.6 ($p = 0.03$) and 59.0 for aneurysms ≥25 mm in diameter ($p < 0.001$).
 - Location. Compared to other locations, the relative risk of rupture of aneurysms at the basilar apex was 13.8 ($p = 0.001$), 13.6 for aneurysms of the vertebrobasilar or posterior cerebral artery ($p = 0.007$) and 8.0 for posterior communicating artery aneurysms ($p = 0.02$).
 - Group 2. Relative risk of rupture was 5.1 for basilar apex aneurysms ($p = 0.004$) and 1.31 for “older age” patients ($p = 0.04$) (age was not defined).
2. Prospective component. Of 1,172 patients, 996 (85%) underwent surgery and the rest had endovascular treatment. Treatment-related results were reported for the surgical group only. Overall rates of morbidity and mortality:
 - (a) Group 1 ($n = 798$):
 - 30 days: 17.5%.
 - 1 year: 15.7%.
 - (b) Group 2 ($n = 197$):
 - 30 days: 13.6%.
 - 1 year: 13.1%.

- (c) The lower rates of morbidity and mortality in Group 2 were attributed to the selection of survivors of a first subarachnoid hemorrhage and craniotomy for clipping of an aneurysm.
3. Study conclusions:
- (a) The rate of rupture of anterior circulation aneurysms <10 mm in diameter is very low for patients without a history of SAH. The rate of rupture is substantially higher in patients with a history of SAH.
- (b) Surgery-related risks exceed the 7.5 year risk of rupture among patients without a history of SAH.

ISUIA SECOND STUDY

A total of 4,060 patients were included in the second ISUIA report.⁹⁹ The study was entirely prospective; 1,692 patients did not have treatment, 1,917 underwent surgery, and 451 had endovascular procedures. As in the first study, patients were divided into Group 1 (no history of SAH) and Group 2 (previous history of SAH from another lesion):

- Natural history. Mean follow-up was 4.1 years. A total of 51 patients (3%) in the untreated group had a confirmed aneurysmal SAH (mortality rate, 65%). As in the first study, patients were divided into Group 1 (no history of SAH) and Group 2 (previous history of SAH from another lesion). Patients in Group 1 had a lower rate of rupture for aneurysms <7 mm than patients in Group 2 ($p < 0.0001$); otherwise, rupture rates did not differ significantly between the groups (Table 13.3).
- Treatment. Mean follow-up was 4.0 years for patients undergoing surgery and 3.7 years for patients who had endovascular treatment. Overall morbidity and mortality rates are reported in Table 13.4. Risk factors were assessed as potential predictors of outcome:
 - Surgical group. Age was found to be a strong predictor of outcome (Fig. 13.2). Asymptomatic patients age <50 years with unruptured aneurysms of the anterior circulation ≤ 24 mm in diameter have the lowest rate of surgical morbidity and mortality, 5.6% at 1 year. Factors predictive of a poor surgical outcome:
 - Age ≥ 50 years, relative risk, RR 2.4 ($p < 0.0001$).
 - Aneurysm diameter > 12 mm, RR 2.6 ($p < 0.0001$).
 - Location in the posterior circulation, RR 1.6 ($p = 0.025$).
 - Previous ischemic cerebrovascular disease, RR 1.9 ($p = 0.01$).
 - Aneurysmal symptoms other than rupture, RR 1.59 ($p = 0.004$).

Table 13.3 ISUIA annual rupture rates according to location and size of unruptured aneurysm

	<7 mm (%)		7–12 mm (%)	13–24 mm (%)	≥ 25 mm (%)
	Group 1	Group 2			
Anterior communicating artery/MCA/ICA	0	0.3	0.52	2.9	8.0
Posterior circulation and posterior communicating artery	0.5	0.68	2.9	3.68	10
Cavernous ICA	0	0	0	0.6	1.28

Table 13.4 ISUIA outcomes after treatment

	Surgery (%)		Endovascular (%)	
	Group 1	Group 2	Group 1	Group 2
30-day morbidity and mortality	13.7	11.0	9.3	7.1
1-year morbidity and mortality	12.6	10.1	9.8	7.1

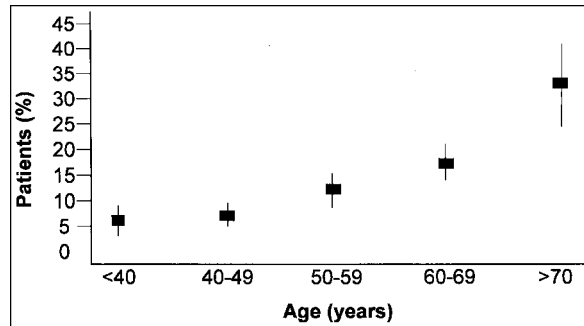


Fig. 13.2 ISUIA poor outcomes in the surgical cohort by age. Poor outcome is defined as death, a Rankin score between 3 and 5, or impaired cognitive status. Bars show 95% confidence interval. Reprinted from The Lancet, 362:103–110, Wiebers and International Study of Unruptured Intracranial Aneurysms: “Unruptured intracranial aneurysms: natural history, clinical outcome, and risks of surgical and endovascular treatment.” © 2003 Elsevier Ltd, with permission from Elsevier.

(b) Endovascular group. Morbidity and mortality seemed to be less dependent on age in patients undergoing endovascular treatment. Poor outcome was associated with:

- Aneurysm diameter >12 mm, RR 2.4 ($p < 0.03$).
- Location in the posterior circulation, RR 2.25 ($p = 0.02$).

ISUIA ANOMALIES AND STUDY LIMITATIONS

The results of the ISUIA have been controversial because the low rates of rupture do not seem to match actual practice. Consider the following calculation. The prevalence of unruptured intracranial aneurysms is about 2%. If the population of the United States is 280 million, then approximately 5.6 million people are likely to have an aneurysm. If the average annual rupture rate is ~0.1%, as the ISUIA indicates for most aneurysms, then only about 5,600 cases of aneurysmal SAH should be seen in the US each year. However, some 21,000–33,000 cases of aneurysmal SAH occur in the US each year.¹⁰⁷ Moreover, the average size of ruptured aneurysms is 6–7 mm, well within the range estimated by ISUIA to have a benign natural history. The most plausible explanation for these discrepancies is that the ISUIA results are affected by *selection* and *intervention bias*. The patients followed in the ISUIA were evaluated and counseled by cerebrovascular neurosurgeons, and a decision was made in each case to manage the patient expectantly. Patients already at lower risk of rupture may have been selected to be managed without intervention, and, once they were aware of their aneurysms, there is a distinct possibility that the patients and their physicians were successful in modifying risk factors for rupture, such as cigarette smoking and hypertension. Therefore, the results of ISUIA are applicable to some patients, but not necessarily to all patients, particularly if they are affected by confounding risk factors for hemorrhage. Management decisions for patients with unruptured aneurysms should be made on an individual basis, with careful consideration of life expectancy, risk factors for hemorrhage, and estimated risks associated with treatment (Table 13.5).

Table 13.5 Life expectancy table and projected lifetime risk of aneurysm rupture

Age interval	Average no. of years remaining ^a	Estimated lifetime risk of rupture according to annual risk of rupture ^b				
		0.05%	0.50%	1%	2%	3%
20–24	58.2	0.06	0.25	0.44	0.69	0.83
25–29	53.5	0.05	0.24	0.42	0.66	0.8

(continued)

Table 13.5 (continued)

Age interval	Average no. of years remaining ^a	Estimated lifetime risk of rupture according to annual risk of rupture ^b				
		0.05%	0.50%	1%	2%	3%
30–34	48.7	0.05	0.22	0.39	0.63	0.77
35–39	44	0.04	0.2	0.36	0.59	0.74
40–44	39.3	0.04	0.18	0.33	0.55	0.7
45–49	34.8	0.03	0.16	0.3	0.5	0.65
50–54	30.3	0.03	0.14	0.27	0.46	0.6
55–59	26.1	0.03	0.12	0.23	0.41	0.55
60–64	22	0.02	0.1	0.2	0.36	0.49
65–69	18.2	0.02	0.09	0.17	0.31	0.43
70–74	14.7	0.01	0.07	0.14	0.26	0.36
75–79	11.5	0.01	0.06	0.11	0.21	0.3
80–84	8.8	0.01	0.04	0.08	0.16	0.24
85–89	6.5	0.01	0.03	0.06	0.12	0.18
90–94	4.8	0	0.02	0.05	0.09	0.14
95–99	3.6	0	0.02	0.04	0.07	0.1

^aAverage number of years of life remaining for beginning of age interval. Life expectancy data obtained from the United States Department of Health and Human Services¹⁰⁸

^bAnnual rupture rates are approximated from the ISUIA.⁹⁹ Lifetime risk of rupture was calculated using the formula $1 - (\text{risk of no hemorrhage})^{\text{years remaining of life}}$.¹⁰⁹ Assumptions include a constant risk of rupture and no confounding factors

13.3. Aneurysm treatment

13.3.1. Conservative management

The term “conservative management” is a bit of a misnomer, since it implies no treatment at all. However, it is prudent to follow patients with aneurysms that have not been treated, and attempts should be made to modify risk factors by encouraging smoking cessation and treating hypertension. Patients with unruptured aneurysms should be monitored for new onset headaches or cranial nerve palsies, which may be warning signs of impending rupture. Periodic imaging should be done since objective evidence of aneurysm growth is associated with an increased risk of rupture.⁸⁷ The authors use annual CTA or MRA exams to follow asymptomatic patients with untreated intradural aneurysms. Growing or newly symptomatic aneurysms should then be considered for more definitive treatment.

13.3.2. Treatment: Surgical results

Microsurgery is the established “gold standard” for treatment of intracranial aneurysms. Successful surgery effectively excludes the aneurysm from the circulation, and recurrence is generally thought to be uncommon. Intraoperative or postoperative catheter angiography is necessary to check for residual aneurysm and to ensure that the parent vessels are preserved. Interpretation of surgical series is problematic, as publication bias can confound the results. For instance, in studies of surgery for unruptured aneurysms, single-center series generally report better results than multicenter or community-based studies.¹¹⁰ As the largest, randomized multicenter trials to date, ISUIA and ISAT have provided the most reliable data for the treatment of unruptured and ruptured aneurysms.

13.3.2.1. Obliteration rates, recurrence, and hemorrhage after surgery

1. The frequency of residual aneurysm after clipping is 3.8–8%.¹¹⁻¹¹⁵
2. Rupture or rerupture after clipping usually occurs when residual aneurysm is left behind after surgery:
 - (a) In a surgical series of 715 patients with an average follow-up of 6 years, the chance of rebleeding from a residual aneurysm was 3.7%.¹¹¹ The chance of rehemorrhage for all patients was 0.14%.
 - (b) Of a series of 12 cases with known residual aneurysm after surgery, two (16.7%) were found to have enlarged on follow-up angiography (mean follow-up, 4.4 years).¹¹⁶
3. Aneurysm recurrence after surgical obliteration:
 - (a) In a surgical series of 220 cases, all of whom had postoperative angiography indicating complete obliteration of the aneurysm, three patients (1.4%) had SAH attributable to a recurrent aneurysm; two other patients were found to have unruptured recurrent aneurysms on angiography.¹¹⁷ Mean follow-up was 9.9 years.
 - (b) Of 135 clipped aneurysms shown to be obliterated on postoperative angiography, two (1.5%) were found to have recurred on follow-up angiography (mean follow-up, 4.4 years).¹¹⁶
 - (c) In a cohort study involving nine centers and a total of 711 patients undergoing clipping after SAH, rerupture of the treated aneurysm did not occur during 2,666 person-years.¹¹⁵

13.3.2.2. Complication rates with surgery

1. Unruptured aneurysms:
 - (a) A systematic review of 61 studies involving 2,460 patients having elective aneurysm surgery found a permanent morbidity rate of 10.9% and a mortality rate of 2.6%.¹¹⁹
 - (b) In a state-wide analysis of patients undergoing surgery for unruptured aneurysms in California from 1990 to 1998, an adverse outcome (defined as an in-hospital death or discharge to a nursing home or rehab) occurred in 25% of cases, and death occurred in 3.5% of cases.¹²⁰
 - (c) ISUIA treatment results: The 30-day overall morbidity and mortality rate with surgery was 13.2%, and the mortality rate was 1.5%.⁹⁹ The 1-year morbidity and mortality rate was 12.2%, and the mortality rate was 2.3%.
 - (d) Risk factors for complications with surgery for unruptured aneurysms include age >50 years, aneurysm size >12 mm, posterior circulation location, and complex anatomy.^{99,121,122}
2. Ruptured aneurysms:
 - (a) Surgical complication rates for ruptured aneurysms are confounded by the multiplicity of problems that affect patients with SAH.
 - (b) Population-based studies have found a 30-day mortality rate of 13.4%, and 1-year mortality rates of 13.3–17.9%.^{123,124}
 - (c) ISAT: 1-year rate of death or dependency for surgical patients was 30.9%.

13.3.3. Treatment: Endovascular results

13.3.3.1. Angiographic results

Reports of angiographic results after endovascular treatment of intracranial aneurysms are confounded by differing definitions of angiographic findings as well as varying aneurysm locations and sizes, and whether the treated lesion was unruptured or ruptured (Table 13.6). A graphic scheme for classifying anatomic results is illustrated in Fig. 13.3.

Table 13.6 Comparison of various classification schemes for angiographic results after embolization

References					
134	Complete occlusion	Dog ear (indicating a unilateral residual neck)	Residual neck	Aneurysm filling	Treatment failure
135	Grade I (totally occluded aneurysm with no lumen or visible neck remnant)	Grade II (90–99% obliteration, “subtotal”)	Grade III (<90% obliteration “incomplete”)		
136	100%	95–99%	<95%		
137	Class I (complete obliteration)	Class II (residual neck)	Class III (residual or recurrent aneurysm)		
			Minor	Major (saccular and size large enough to permit retreatment with coils)	
130	Complete (no contrast filling of the dome, neck or body of aneurysm)	Neck remnant (residual filling of part of the neck of the aneurysm)	Incomplete (indicated by contrast within the body and dome of the aneurysm)	Attempted embolization (failure to deliver coils into aneurysm)	

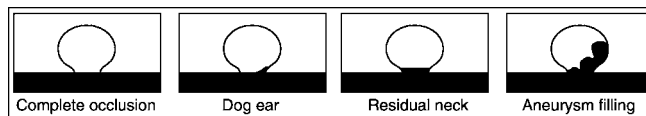


Fig. 13.3 Graphical scheme for classification of angiographic results after aneurysm embolization. Complete occlusion indicates no filling of the aneurysm; “dog ear” indicates a unilateral residual neck; “residual neck” indicates that there is some filling of the neck of aneurysm for the entire length of the aneurysm neck; “aneurysm filling” indicates significant filling of the aneurysm; and “treatment failure” (not shown) indicates no embolization of the aneurysm. Adapted with permission from.¹³⁴

IMMEDIATE ANGIOGRAPHIC RESULTS

1. “Complete” aneurysm obliteration has been reported in approximately 50–60% of cases immediately after embolization, and “near complete” occlusion has been reported in about 90% of cases.¹²⁵⁻¹³²
2. Treatment failures (i.e., no embolization at all) have been reported in approximately 5% of cases,¹²⁹⁻¹³¹ although other reports have indicated higher rates.¹³³
3. A systematic review of 48 studies found that initial occlusion rates seemed to be independent of aneurysm size, location, neck configuration, and whether the aneurysm was ruptured or unruptured.¹²⁵

LONG-TERM ANGIOGRAPHIC RESULTS

1. By convention, initial angiographic follow-up is typically done 3–6 months after treatment, then yearly after that, indefinitely.
2. *Aneurysm recurrence.* There are probably as many definitions of “aneurysm recurrence” after coiling as there are snowflakes, making comparisons between studies nearly impossible. The authors of this handbook prefer to define significant recurrence as recanalization of a volume within the aneurysm large enough to permit retreatment with either endovascular or surgical means (i.e., recanalizations classified as “major recurrences” by Raymond and colleagues).¹³⁷
 - (a) Studies including cases mostly from the 1990s found significant recurrence rates of approximately 20% of cases in the first 12–18 months after treatment:
 - In a series of 466 patients treated from 1992 to 2002, the rate of major recurrences, defined as necessitating retreatment, occurred in 20.7% of patients and were found at a mean of 16.5 months.¹³⁷ Predictors of recurrence included treatment of a ruptured aneurysm, larger aneurysm size and neck width, suboptimal initial angiographic result, and length of follow-up.
 - In a series of 818 patients treated at UCLA from 1990 to 2002, the overall rate of recanalization was 20.9%, at a mean follow-up of 11 months.¹³⁰ Recanalization was defined as >10% increase in contrast filling of the aneurysm. Factors contributing to recanalization included larger aneurysm size and wide necks. The authors also found a significant improvement in recurrence rates over time (26.1% in the first 5 years vs. 17.2% in the last 6 years), which they attributed to technical refinements.
 - (b) More recent studies have found recurrence rates (including small recurrences and recanalization) of approximately 13–15% at 1 year,^{138,139} and longer-term recurrence rates of about 20%.^{139,140}
3. Predictors of recurrence include incomplete occlusion at the initial treatment, aneurysm size >10 mm, loose packing of the aneurysm.^{137,139,141}
 - (a) Density of coil packing may correlate with occlusion durability.¹⁴¹ Typically, only some 23–26% of the endosaccular volume is replaced by coils;¹⁴² some studies have suggested that a volumetric percentage occlusion of at least 25–33% is necessary for durable occlusion.^{141,413}
 - (b) Aneurysm relationship with the parent vessel. Terminal aneurysms seem to recur at a higher rate compared to sidewall aneurysms. In a report of long-term results after coiling of 100 asymptomatic aneurysms rates of recanalization were 11% and for sidewall aneurysms and 38% for terminal aneurysms.¹⁴⁴

13.3.3.2. Clinical results with embolization

COMPLICATION RATES

Overall complication rates with coiling tend to hover around 8–10%.^{99,120,130,132} A systematic review of 48 studies totaling 1,383 patients found a rate of permanent complications with embolization of 3.7% (95% CI 2.7–4.9%).¹²⁵ An in-depth discussion of complications may be found in Chap. 5.

RUPTURE AFTER COILING

Rehemorrhage after coiling of ruptured aneurysms is uncommon, occurring in approximately 3% of cases.^{117,126,145–153} Rehemorrhages occurring within 6 months usually involve aneurysms that were incompletely occluded after the initial treatment.^{154–156} Later rehemorrhages tend to occur in aneurysms that have demonstrated some degree of recurrence,^{126,150} underscoring the need for routine radiographic surveillance of coiled aneurysms.

In ISAT, a total of 35 (3.3%) rebleeds after treatment occurred in patients after coiling within 1 year of treatment.¹⁵⁷ Of the patients in whom coils were placed in the aneurysm, 15 (1.5%) had a rehemorrhage after the initial procedure and before 30 days postprocedure.¹⁵⁸ Among these 15 patients, seven had incomplete occlusion of the aneurysm, three had complete occlusion, and five received thrombolytic therapy to treat thromboembolic complications after the initial endovascular treatment.

13.3.3.3. Selected studies comparing coiling and clipping

UNRUPTURED ANEURYSMS, RETROSPECTIVE STUDIES

1. In a cohort study of 2,357 surgical cases and 255 endovascular cases at 60 university hospitals, adverse outcomes were significantly more common in surgical cases (18.5%) compared to endovascular cases (10.6%) ($p = 0.002$).¹⁵⁹ In-hospital mortality was higher for surgical cases (2.3 vs. 0.4%; $p = 0.039$). The length of stay and hospital charges were also significantly greater for surgical cases ($p < 0.0001$ for each).
2. In a state-wide analysis of patients undergoing surgery for unruptured aneurysms in California from 1990 to 1998, an adverse outcome (defined as an in-hospital death or discharge to a nursing home or rehab) occurred in 10% of endovascular cases, compared to 25% of surgical cases ($p < 0.001$).¹²⁰ In-hospital death occurred in 0.5% of endovascular cases and 3.5% of surgical cases ($p < 0.001$). Adverse outcomes declined from 1991 to 1998 in patients treated with endovascular therapy but not in those who underwent surgery ($p < 0.005$).
3. An aggregate analysis of 1,829 endovascular patients and 10,541 surgical patients found a cumulative adverse outcome rate of 8.8% (95% CI 7.6–10.1%) for coiling and 17.8% (95% CI 17.2–18.6%) for clipping.¹⁶⁰

UNRUPTURED ANEURYSMS, PROSPECTIVE STUDIES

1. ISUIA: 1,917 patients underwent surgery and 451 patients had endovascular treatment. Overall morbidity and mortality at 1 year was 12.2% for the surgical group and 9.5% for the endovascular group. ISUIA is discussed in detail above.

RUPTURED ANEURYSMS, PROSPECTIVE STUDIES

1. A single-center randomized 109 patients with SAH to either surgery ($n = 52$) or coiling ($n = 57$).¹⁵⁴ Better angiographic results were obtained after surgery in patients with ACA aneurysms ($p = 0.005$), and after coiling in patients with posterior circulation aneurysms ($p = 0.045$). Clinical outcome was not significantly different at 3 months.
2. Long-term rerupture rates were evaluated in an “ambidirectional” cohort study of 711 surgical cases and 299 endovascular cases at nine centers.¹¹⁸ The mean length of follow-up was 4.4 years for surgical patients and 8.9 years for endovascular patients. Rerupture of the index aneurysm after 1 year occurred in one patient treated with coil embolization during 904 person-years of follow-up (annual rate 0.11%) and in no surgical patients during 2,666 person-years ($p = 0.11$). Aneurysm retreatment after 1 year was more frequent in patients treated with coiling ($p < 0.0001$), but major complications during retreatment were rare.
3. ISAT: Randomized trial of coiling vs. clipping in 2,143 patients with SAH.¹⁵⁷ The 1-year rate of death and dependency was lower in the endovascular group compared to the surgical group (23.5 vs. 30.9%; $p = 0.0001$). The ISAT is discussed in detail below.

What Should Patients Expect with Aneurysm Coiling?

The authors prefer to quote a risk of complications with coiling of approximately 10%, and a chance of aneurysm recurrence (necessitating retreatment) of about 20% over several years. The actual rates may be lower, but it is often wise to err on the conservative side when helping patients and their families formulate expectations about treatment. A tendency to err on the conservative side is also important when discussing alternatives, including surgical clipping, as well.

13.3.4. Treatment decision making: Clip or coil?

Both surgery and endovascular treatment are valid for many aneurysms. Patient-specific factors are summarized in [Table 13.7](#). Operator-specific factors include the background and comfort level of the physician in handling any particular case.

Table 13.7 Patient selection for coiling or clipping

Relative indications	Relative contraindications
<i>Endovascular treatment</i>	
<ul style="list-style-type: none"> Poor surgical candidate 	<ul style="list-style-type: none"> Elongated aortic arch or otherwise difficult vascular access
<ul style="list-style-type: none"> Favorable aneurysm anatomy 	<ul style="list-style-type: none"> Cervical or cranial vessel disease (e.g., occlusion, dissection, fibromuscular dysplasia, friable atherosclerotic plaque)
<ul style="list-style-type: none"> Favorable vascular access anatomy 	<ul style="list-style-type: none"> Giant aneurysms
<ul style="list-style-type: none"> Previous contralateral cranial surgery or hemispheric injury 	<ul style="list-style-type: none"> Aortic or femoral artery occlusion
<ul style="list-style-type: none"> Need for long-term anticoagulation (e.g., warfarin therapy for atrial fibrillation) 	<ul style="list-style-type: none"> Intraluminal thrombus
<ul style="list-style-type: none"> High risk for anesthesia complications 	<ul style="list-style-type: none"> Intolerance to iodinated contrast
<ul style="list-style-type: none"> Posterior circulation aneurysms 	<ul style="list-style-type: none"> Intolerance to heparin and/or antiplatelet agents (if stent-assisted coiling is anticipated)
<ul style="list-style-type: none"> Vascular neurosurgeon unavailable 	<ul style="list-style-type: none"> Patient unable or unwilling to have routine radiographic follow-up
<i>Surgical treatment</i>	
<ul style="list-style-type: none"> Younger patient 	<ul style="list-style-type: none"> Advanced age
<ul style="list-style-type: none"> Few medical conditions 	<ul style="list-style-type: none"> Multiple medical conditions
<ul style="list-style-type: none"> No previous cranial surgery 	<ul style="list-style-type: none"> Previous cranial surgery
<ul style="list-style-type: none"> Middle cerebral artery aneurysms 	<ul style="list-style-type: none"> Giant aneurysms
<ul style="list-style-type: none"> Symptoms attributable to aneurysm mass effect 	<ul style="list-style-type: none"> Specialized neurosurgical care unavailable
<ul style="list-style-type: none"> Surgically accessible 	<ul style="list-style-type: none"> Calcification or significant atherosclerosis of the aneurysm neck

13.3.5. Intracranial aneurysms by type or location

13.3.5.1. Unruptured intracranial aneurysms presenting with mass effect

- Solomon and colleagues found that the proportion of patients without hemorrhage presenting with mass effect from an intracranial aneurysm to be 8%,¹⁶¹ although currently, the proportion is likely to be lower because of an increase in noninvasive imaging detection of intracranial aneurysms. Cranial nerve palsies are a typical feature of unruptured aneurysms presenting with mass effect,¹⁶² oculomotor palsy related to impingement on the third cranial nerve from a P-comm aneurysm is the most frequent scenario. Oculomotor palsies are a presenting feature in some 7.2–94% of patients with small unruptured aneurysms.^{163,164} Cranial nerve palsies have traditionally thought to be due to mechanical compression of the nerve, although transmission of pulsations is likely to be a significant component as well.¹⁶⁵
 - Endovascular treatment of aneurysms with mass effect: Some degree of improvement has been reported in up to 75% of patients,^{162,166,167} although overall rates of complete symptom resolution with coiling are 32–50%.^{162,166}
 - Dampening of pulsations is likely to be the primary mechanism of improvement of symptoms with coiling. Interestingly, symptoms improved in three out of four patients who underwent coiling of aneurysms for cranial nerve dysfunction, despite a significant increase in aneurysm volume after coiling.¹⁶⁵

- (c) The shorter the duration of symptoms, the higher the likelihood of recovery, for both surgery and endovascular treatment; one series found that treatment within 5 days of symptom onset was associated with complete resolution of symptoms.
- 2. Posterior communicating artery aneurysms. In a retrospective comparison of clipping vs. coiling for patients with P-comm aneurysm-induced oculomotor palsy, six out of seven patients (86%) recovered completely, compared with two out of six patients (33%) treated with coiling.¹⁶⁸ Other series have reported complete recovery in 48–92% of patients undergoing clipping.¹⁶⁹⁻¹⁷¹
 - (a) The presence or absence of a pupillary reflex is a prototypical feature that can help distinguish a third nerve palsy due to a compressive lesion, such as a P-comm aneurysm, from an intrinsic lesion affecting the nerve, such as diabetes-associated oculomotor palsy. A diminished pupillary reaction to light results from involvement of parasympathetic fibers that are in a superficial position within the nerve, and are thus vulnerable to compression. The mnemonic, “If the pupil is involved, we’re involved! (i.e., we = neurointerventionalist or neurosurgeon)” applies:
 - Conversely, third nerve dysfunction in diabetic patients typically results from small vessel ischemia to the nerve. Since the microvascular blood supply to the nerve is oriented from outside-to-inside, the central parts of the nerve are more susceptible to ischemic injury, and the outer parasympathetic fibers are more likely to be spared. Thus, pupil sparing in third nerve palsy is *less* likely to be related to extrinsic compression by a P-comm aneurysm.
 - (b) Recovery of oculomotor function after surgery follows a predictable course. Ptosis is typically the first symptom to improve, but complete recovery can take months.
 - (c) The presence of diabetes, older age, delayed intervention, and complete oculomotor palsy are poor prognostic factors for recovery of function after coiling.¹⁷¹
- 3. Cavernous segment ICA aneurysms:
 - (a) See below.^{153,172-175}
- 4. The authors favor surgical treatment of intradural aneurysms with symptoms of mass effect for younger patients who are good surgical candidates, and reserve coiling for older patients at higher risk for surgical complications.

13.3.5.2. Cavernous ICA aneurysms

Approximately 4% of all intracranial aneurysms arise from the cavernous segment of the ICA. Many are discovered incidentally; symptomatic cavernous aneurysms can present with diplopia, pain, or a carotid-cavernous fistula. There is a strong female preponderance, with women accounting for up to 92% of patients with cavernous aneurysms.¹⁷³

1. Radiographic appearance and anatomy:
 - (a) The cavernous segment of the ICA extends from the petrous carotid to the distal dural ring. Most cavernous aneurysms are easy to identify and are clearly proximal to the distal dural ring.
 - (b) Aneurysms involving the cavernous segment can be difficult to distinguish from intradural aneurysms. A useful landmark on CTA in distinguishing cavernous aneurysms from intradural aneurysms is the optic strut, seen on coronal CTA images (Fig. 13.4).¹⁷⁶ Aneurysms that arise proximal to the optic strut are within the cavernous sinus, and aneurysms that arise distal to the optic strut are intradural.
 - (c) *Transitional* aneurysms involve both the cavernous segment and the intradural space. A focal narrowing, or waist, of the aneurysm dome on angiography is an indication of subarachnoid extension.¹⁷⁸
 - (d) The position of several cranial nerves within the cavernous sinus, including the third, fourth, and sixth cranial nerves as well as the V1 and V2 divisions of the trigeminal nerve, makes them vulnerable to compressive injury by large cavernous aneurysms, or a carotid-cavernous fistula.
2. Symptoms and physical findings:
 - (a) Unruptured cavernous aneurysms:
 - Cavernous aneurysms typically produce symptoms by interfering with cranial nerve function. Involvement of the trigeminal nerve can produce severe pain and numbness in the face. The pain may be

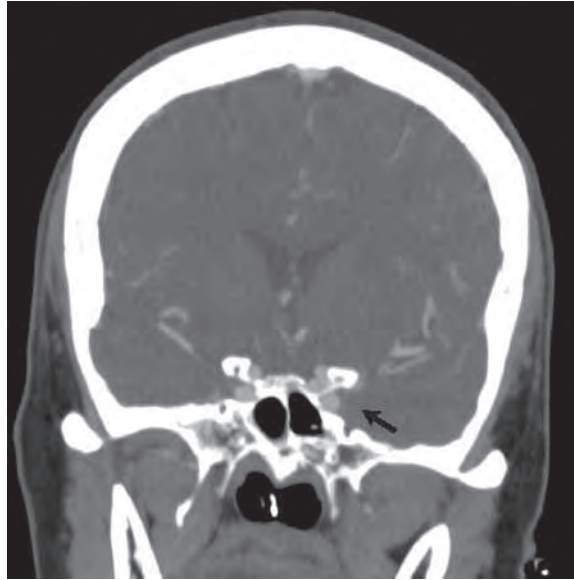

Fig. 13.4 The optic strut and carotid aneurysms. Coronal CTA MIP. The optic strut is clearly seen on the left (*arrow*). An intradural, paraclinoid "carotid cave" aneurysm arises from the medial aspect of the vessel.

constant and burning, or it may include a lancinating component evocative of trigeminal neuralgia.

- The most common symptoms at presentation are diplopia (65%) and pain (59%).¹⁷³ In patients with diplopia, all three oculomotor nerves are involved most commonly (18% of patients); an isolated sixth cranial nerve palsy is present in 17%, and an isolated third cranial nerve palsy is found in 12%.¹⁷³ Other physical findings include a reduced or absent corneal reflex, fifth cranial nerve dysesthesias, Horner's pupil, and compressive optic neuropathy.
- In contrast to third nerve dysfunction due to P-comm aneurysm, cavernous aneurysms can produce a *pupil sparing* third nerve palsy.

(b) Ruptured cavernous aneurysms:

- In a recent series of 185 patients with cavernous aneurysms, ruptured aneurysms accounted for 6.5%. In a series of symptomatic cavernous aneurysms treated with endovascular techniques, ruptured aneurysms accounted for 24.4% of cases.¹⁷⁹
- Ruptured cavernous aneurysms often produce a spontaneous carotid-cavernous fistula. In a series of ten patients with ruptured cavernous aneurysms, all had an audible pulsatile bruit. Exophthalmos, ophthalmoplegia, and diminished vision were common features. Importantly, five patients were found to have cortical venous drainage, indicating some degree of risk of intracranial hemorrhage.
- Epistaxis¹⁷⁹ and SAH¹⁸⁰⁻¹⁸² are rare sequelae of cavernous aneurysm rupture.

3. Natural history:

- (a) The risk of rupture of small cavernous segment aneurysms is extremely low.¹⁸⁰ In the ISUIA, with a mean follow-up of 4.1 years, no cavernous aneurysms <13 mm ruptured.⁹⁹ The annual rupture risk for cavernous aneurysms 13–24 mm and ≥25 mm was 0.6% and 1.28%, respectively.

- (b) Transitional and giant cavernous aneurysms carry a risk of SAH.¹⁸²
 - (c) The natural history of *symptomatic* cavernous aneurysms can be quite variable.¹⁸³ Symptoms may progress, or even spontaneously disappear.^{180,183} In an analysis of 125 untreated cavernous aneurysms manifesting with pain or diplopia, pain resolved or improved spontaneously in 56% of cases, and diplopia resolved, improved, or became unnoticed in 56% as well.¹⁷³
4. Treatment (more discussion of this topic is in Chap. 15, *Appendix: Direct Carotid-Cavernous Fistulas*):
- (a) Coil embolization or balloon test occlusion, followed by therapeutic sacrifice of the ICA is the primary treatment option. Detachable balloons were traditionally used for the carotid sacrifice, but are not currently available in the US. Companies such as Acta Vascular Systems, Santa Clara, CA, are working toward getting FDA approval of detachable balloons.
 - (b) Treatment should be reserved for cavernous aneurysms with extension into the subarachnoid space, and for selected symptomatic aneurysms:
 - In a systematic review of nine clinical series totaling 69 patients who underwent coil embolization for cavernous aneurysms causing diplopia, diplopia was improved in 96% and unchanged or increased in 3.6%.¹⁷² After coiling, 80% of aneurysms were occluded by >90%.
 - Pain may be more responsive to treatment than diplopia. In a single-center retrospective review, diplopia was resolved, improved or became unnoticed in 61% of patients undergoing endovascular treatment; this was not significantly different from the results in patients who did not have treatment (56% had the same result). In contrast, pain was resolved or improved in 96% of patients having treatment, compared to 56% of patients who did not have treatment ($p = 0.002$).
 - (c) Complications:
 - In a systematic review, none of the 68 patients treated with coil embolization had a complication.¹⁷² In a large single-center series, stroke occurred in 5% of patients and TIAs occurred in 5%, although the authors point out that all of these cases were done before 1993, implying that improved technique and devices have led to a reduction in ischemic complications.¹⁷³
 - (d) A dilemma that occurs in the management of symptomatic cavernous aneurysms is that, whereas a significant percentage of symptoms will improve without intervention, the chance of symptomatic improvement, particularly when vision or oculomotor function is affected, is best when treatment is undertaken soon after the onset of symptoms.
5. The authors favor coiling of unruptured cavernous aneurysms with extension into the subarachnoid space, and for ruptured cavernous aneurysms in patients with a bothersome bruit, cortical venous drainage, or significant diplopia or pain. Selected patients with symptomatic unruptured cavernous aneurysms are also candidates for endovascular treatment, depending on the clinical situation.

13.3.5.3. Paraclinoid ICA aneurysms

Intradural aneurysms arising from the ICA between the distal dural ring and the P-comm artery are classified as paraclinoid aneurysms, because of their proximity to the anterior clinoid process. Bilateral aneurysms are not uncommon, being present in some 23% of cases.¹⁸⁴ Numerous terms and classification systems exist for aneurysms in this region, which has created considerable confusion. Two main types of aneurysms in this region are named for the branch of the ICA they are associated with, the ophthalmic artery and the superior hypophyseal artery. Much less common aneurysms arising from this segment of the ICA are not associated with an arterial branch and include “carotid cave” and “lateral paraclinoid” aneurysms.

OPHTHALMIC ANEURYSMS

Ophthalmic aneurysms arise at the distal aspect of the origin of the ophthalmic artery and project in a superior and medial direction. They comprise 33% of paraclinoid aneurysms.¹⁸⁵

1. *Presentation.* About half of symptomatic ophthalmic aneurysms present with visual symptoms, and the remaining present with SAH.¹⁸⁶ As the aneurysm enlarges, distortion of the optic nerve can occur, which may be clinically silent despite significant involvement of the nerve. Impingement of the lateral aspect

of the optic nerve can produce a monocular superior nasal quadrantanopia (although the patient may not notice it), and in advanced cases complete ipsilateral visual loss may be present. Visual symptoms are almost always attributable to giant (≥ 2.5 cm) aneurysms. Although giant ophthalmic aneurysms have been reported to cause a *contralateral* superior temporal quadrantanopia, due to involvement of the “anterior knee of Wilbrand” (nasal retinal fibers which travel in an anterior direction for a short distance within the contralateral optic nerve after they decussate),¹⁸⁷ more recent data suggests that the “anterior knee of Wilbrand” does not actually exist.¹⁸⁸

2. *Surgical considerations.* Surgical access to ophthalmic aneurysms usually requires removal of the anterior clinoid process. Visual loss can occur from manipulation from the optic nerve or disruption of optic nerve perforating vessels during aneurysm exposure, and occurs in some 4% of cases.¹⁸⁴ A preoperative CT should be checked for the presence of calcification of the neck; significant calcification can make clipping difficult. The ophthalmic artery should be preserved whenever possible, however some patients will tolerate occlusion of this vessel without ischemic injury to the retina thanks to collateral circulation from the external carotid artery branches.
3. *Endovascular treatment.* Coiling is an attractive option for treatment of ophthalmic aneurysms because of the risk of visual loss associated with surgery. Morbidity with endovascular treatment of paraclinoid aneurysms is 2.9–8.3%.^{189,190} However, ophthalmic aneurysms seem to be prone to recurrence after coiling. Strictly speaking, ophthalmic aneurysms are sidewall aneurysms; however their location along the bend of the ICA as it arches up from the cavernous sinus may create a hemodynamic effect that is similar to that experienced by end-artery aneurysms. Relatively high recurrence rates have been reported after coiling, occurring in 26–53% of cases.^{191,192} Because of this, methodical radiographic follow-up after coiling of ophthalmic aneurysms is mandatory.

SUPERIOR HYPOPHYSEAL ARTERY ANEURYSMS

Some 47% of paraclinoid aneurysms are associated with the origin of the superior hypophyseal artery.¹⁸⁵ These aneurysms arise from the inferomedial aspect of the ICA and project inferiorly and medially. Most aneurysms of this type are incidental findings or present with SAH. Rarely, superior hypophyseal aneurysms can become large enough to compress the pituitary stalk and the optic chiasm. Surgical access to these aneurysms is technically challenging because the aneurysm is located on the opposite side of the ICA as the vessel is approached via a pterional craniotomy, and the aneurysm dome may be adherent to the parasellar dura.

OTHER PARACLINOID ANEURYSMS

Some 20% of paraclinoid aneurysms are not associated with a branch of the ICA.¹⁸⁵ Most of these arise from the ICA in either a medial or lateral direction:

1. *Medial clinoidal segment aneurysms.* Also described by some as “carotid cave” aneurysms. The term “carotid cave” refers to a space inferior to a redundant fold of dura, which extends from the medial aspect of the distal dural ring,¹⁹³ and is present in some 68–77% of cases.¹⁹⁴ Aneurysms extending into the carotid cave are usually small and project medially in the AP plane (Fig. 13.4). They are distinguished from superior hypophyseal aneurysms by their more proximal location and the absence of an associated branching artery.
2. *Lateral paraclinoid aneurysms.* These aneurysms project in a superior and lateral direction and are uncommon, accounting for only 8.2% of paraclinoid aneurysms.¹⁸⁵ They can present with SAH, even when small.

13.3.5.4. Supraclinoid ICA aneurysms

Aneurysms arising from the ICA between the P-comm artery and the carotid terminus are classified as supraclinoid aneurysms, and account for 50% of all intracranial aneurysms.¹⁹⁵

POSTERIOR COMMUNICATING ARTERY ANEURYSMS

P-comm aneurysms usually arise just distal to the origin of the posterior communicating artery, and project inferiorly and laterally. Both surgery and endovascular

treatment of P-comm aneurysms are often relatively uncomplicated, and therefore each approach is generally valid. Some 25% of the aneurysms randomized in ISAT were P-comm aneurysms.¹⁵⁸

1. *Presentation.* Unruptured P-comm aneurysms are a common cause of acute third cranial nerve palsy and are discussed above, in *Unruptured Intracranial Aneurysms Presenting with Mass Effect* section. P-comm aneurysms are also a common cause of SAH; blood on CT is usually concentrated in the lateral suprasellar and ambient cisterns.
2. *Surgical considerations.* The standard approach for P-comm aneurysms is a pterional craniotomy; resection of the anterior clinoid process can improve access to the proximal ICA. P-comm aneurysms have a tendency to rupture or rerupture during surgery at a higher rate than other aneurysms,¹⁹⁶ particularly with retraction of the temporal lobe.¹⁹⁷
3. *Endovascular treatment.* Endovascular access and coiling P-comm aneurysms is usually uncomplicated, although P-comm aneurysms seem to have a tendency to be relatively wide-necked. Sometimes these aneurysms arise at a bizarre reverse angle from the parent vessel, requiring the use of sharply curved, preshaped microcatheters to access the lesion. Stent-assisted coiling is appropriate for unruptured wide-necked P-comm aneurysms. In patients with SAH due to a wide-necked P-comm aneurysm, capping of the dome with coils can protect against rerupture in the acute phase after SAH, with more definitive stent-assisted coiling of the remnant at a later date.

ANTERIOR CHOROIDAL ARTERY ANEURYSMS

Anterior choroidal artery aneurysms account for 4% of all intracranial aneurysms. They tend to be small (average size in one series was 4 mm),¹⁹⁸ and project in an inferior and posterior direction. In most cases they arise near or adjacent to the origin of the anterior choroidal artery, although in 18% of patients the aneurysm originates entirely or in part from the anterior choroidal artery itself.¹⁹⁹ In treatment of these aneurysms, preservation of the anterior choroidal artery is critical, as the vessel is notorious for having poor collateral circulation to the proximal territory of the anterior choroidal, which, unfortunately, is just that part of this vessel that supplies the internal capsule. Ischemic stroke from occlusion of the anterior choroidal artery, described as *Anterior Choroidal Syndrome*, can cause contralateral hemiplegia, hemianesthesia, and hemianopia, although in a series of ischemic complications with surgery for anterior choroidal aneurysms, sensory and visual changes were less consistent than motor deficits.¹⁹⁹

1. *Presentation.* Most anterior choroidal artery aneurysms present with SAH or are incidental findings. Much less commonly, they can present with acute third cranial nerve palsy or cerebral ischemic symptoms from embolization of the intraluminal thrombus.
2. *Surgical considerations.* Anterior choroidal aneurysms are accessible via a pterional craniotomy. The greatest technical challenge occurs because the aneurysm usually appears on the side of the ICA opposite to the surgeon's approach, and visualization of the anterior choroidal artery origin can be problematic. In a series of 50 patients undergoing surgery for anterior choroidal aneurysms, 16% of patients had anterior choroidal territory ischemic strokes.¹⁹⁹ Most of these strokes occurred in a delayed fashion, 6–36 h after surgery.
3. *Endovascular treatment.* The small size of anterior choroidal aneurysms and the orientation of the aneurysm, at a right angle to the axis of the ICA, can make coiling these lesions tricky. Published results, however, are encouraging. In a series of 18 patients undergoing coiling of anterior choroidal aneurysms, the overall complication rate was 11%.¹⁹⁸ There was one treatment-related death due to aneurysm perforation, and another patient developed a transient contralateral hemiparesis. No rehemorrhages occurred during an average follow-up of 14 months.

CAROTID BIFURCATION ANEURYSMS

The internal carotid bifurcation is the location of some 5% of all intracranial aneurysms, and men and women appear to be affected equally.²⁰⁰ Some data suggest that these aneurysms hemorrhage at a lower age than aneurysms in other locations.²⁰⁰ These aneurysms tend to arise on the side of A1, at an average distance of 1.6 mm (between the midline of the ICA and the midline of the aneurysm neck).²⁰¹

13.3.5.5. Anterior cerebral artery aneurysms

Together, the ACA and A-comm are the most common location for intracranial aneurysms, accounting for some 39% of all ruptured aneurysms.²⁰²

ANTERIOR COMMUNICATING ARTERY ANEURYSMS

The A-comm is the single most common site of aneurysms presenting with SAH. Like P-comm aneurysms, both surgery and endovascular treatment of A-comm aneurysms are often relatively straightforward, and therefore each approach is generally valid. Some 45% of the aneurysms randomized in ISAT were A-comm aneurysms.¹⁵⁸

1. *Presentation.* On CT there is typically a clot in the interhemispheric fissure. Intraventricular hemorrhage is present in 79% of cases, and acute hydrocephalus occurs in 25% of patients.²⁰³ Hyponatremia occurs more frequently in patients with ruptured A-comm aneurysms (51%) than in patients with ruptured aneurysms in other location, presumably because of the proximity of the A-comm complex to the hypothalamus.²⁰⁴ Another common consequence of SAH due to a ruptured A-comm aneurysm is cognitive dysfunction, occasionally referred to as the “A-comm Syndrome.” Features of this syndrome include short-term memory impairment, personality changes, and confabulation, and are attributed to injury to the basal forebrain.²⁰⁵ Some data suggests that surgical patients have higher chance of memory and frontal lobe executive function deficits compared to patients treated with endovascular means.²⁰⁶
2. *Surgical considerations.* The standard surgical approach for A-comm aneurysms is a pterional craniotomy. Opening of the Sylvian fissure and partial resection of the gyrus rectus are maneuvers that can enhance access to the A-comm region. The orientation of the aneurysm strongly affects the ease of surgery; larger, inferiorly directed aneurysms can make surgical access to the contralateral A1 – necessary for proximal control – challenging.
3. *Endovascular treatment.* Several studies of endovascular treatment of A-comm aneurysms have been published.^{153,207,208} Technical factors that can limit endovascular treatment are the acute angle formed by the A1 segment relative to the ICA (which can make catheter access difficult), the relative small size of A-comm aneurysms, and the difficulty, in some cases, of adequate fluoroscopic visualization of the A-comm complex during the procedure. A recent analysis of 123 patients with A-comm aneurysms reported that successful embolization was accomplished in 70% of patients.²⁰⁸ Embolization was attempted but not successful in 9.8% of patients. At a mean follow-up of 8.6 months, some degree of recanalization was observed in 33.3% of cases. Anteriorly projecting aneurysms were more likely to be successfully coiled than either inferiorly or posteriorly/superiorly directed aneurysms, and inferiorly projecting aneurysms and wide-necked aneurysms had significantly higher rates of recanalization.
4. The authors of this handbook prefer surgery in younger patients, and endovascular treatment in older patients, and in those with complex or inferiorly directed aneurysm anatomy.

DISTAL ANTERIOR CEREBRAL ARTERY ANEURYSMS

ACA aneurysms arising distally to the A-comm artery comprise about 5% of all intracranial aneurysms.²⁰⁹ Most are located at the A2–A3 junction (usually referred to as pericallosal artery aneurysms); however aneurysms are also often located on the A2 and A3 segments. Some 41% of patients with distal ACA aneurysms have one or more additional intracranial aneurysms.²⁰⁹ Although an azygous A2 is found in <1% of the general population,²¹⁰ the anatomical variant is strongly associated with aneurysms; some 41% of azygous A2 segments have a terminal aneurysm.²¹¹ The distal ACA is also a common site for traumatic aneurysms; some 25–30% of traumatic aneurysms are located on the distal ACA.^{212,213}

1. *Presentation.* Ruptured distal ACA aneurysms appear with an intracerebral hematoma in 50% of cases^{214,215} or an interhemispheric subdural hematoma. Patients with a ruptured distal ACA aneurysm tend to present at a poorer grade compared to patients with aneurysms at other locations; some 60–63% of patients present with a Hunt and Hess grade of 3 or higher.^{215,216}
2. *Surgical considerations.* The surgical approach depends on the location of the aneurysm. Aneurysms <1cm distal to the A-comm aneurysm may be approached via a pterional craniotomy. Aneurysms in the proximity of the

genus of the corpus callosum usually require a bicoronal skin incision, frontal craniotomy, and interhemispheric approach. More distal aneurysms ("supracallosal" aneurysms) can be approached with a horseshoe skin flap and a posterior frontal craniotomy.

3. *Endovascular treatment.* Distal ACA aneurysms are typically small and located some distance along the ACA, making endovascular treatment challenging in some cases.²¹⁷ Pericallosal aneurysms, particularly those associated with an azygous A2, are the most accessible (Fig. 1.26).

13.3.5.6. Middle cerebral artery aneurysms

Middle cerebral artery aneurysms constitute about 20% of all intracranial aneurysms and are the third most common cause of aneurysmal SAH.^{218,219} Mirror MCA aneurysms occur in up to 11% of patients, and patients with MCA aneurysms also have an increased incidence of pericallosal artery aneurysms.²²⁰ Some 85% of MCA aneurysms arise at the bifurcation, 10–15% are located along the M1 segment,²¹⁸ and the remaining MCA aneurysms, appearing on the M2–4 segments, are more likely to be infectious or inflammatory in origin.²²¹ The anatomy of the MCA makes the vessel somewhat unique compared to other common aneurysm locations. The MCA trunk forms a true bifurcation, giving rise to two M2 divisions, in about 80% of cases; in 12% of cases there is a trifurcation, and in the remaining cases there are multiple branches.²²² MCA aneurysms project laterally in 45% of cases and inferiorly in 38% of cases.²²⁰

1. *Presentation.* Unruptured MCA aneurysms are less likely to be symptomatic than aneurysms at other locations.²²³ Cerebral ischemic phenomena such as TIAs and stroke are more likely to occur with MCA aneurysms than with others. Patients with seizure disorders attributable to an unruptured MCA aneurysm have been reported.^{224,225} Ruptured MCA aneurysms are commonly associated with intracerebral hematomas, which are found in nearly 40% of cases.²²⁶
2. *Surgical considerations.* There are three surgical approaches to MCA aneurysms. The medial transsylvian approach provides early access to the ICA for proximal control, and is often favored for surgery on ruptured MCA aneurysms. The lateral transsylvian approach is advantageous because it minimizes frontal and temporal lobe retraction and is useful for distal aneurysms, for aneurysms that project in an anterior direction, and for cases with a long MCA trunk.²²⁷ The superior temporal gyrus approach is the preferred approach when evacuation of an intracerebral hematoma is required.²²⁸
3. *Endovascular treatment.* Aneurysms at the M1 segment terminus are typically wide-necked and eccentric toward one division, and the aneurysm neck may incorporate one or more branches. Coil embolization can be difficult to accomplish without risk of stenosis or occlusion of at least one division. In addition, the wide-neck configuration leads to a relatively high surface area of the coil mass exposed to blood flowing past the aneurysm after coiling, raising the risk of platelet activation and thromboembolic complications. In an early report, published in 1999, coil embolization was attempted but unsuccessful in 85% of cases.²²⁹ Improved technique and better case selection has led to better results in recent publications.^{140,230} Doerfler and colleagues reported complete occlusion in 33 of 38 MCA aneurysms treated with coiling.²³⁰ Thromboembolic occlusion occurred in five patients (13%), although recanalization of the occluded vessel was obtained in four of these patients with thrombolytic treatment.²³⁰ In a series of 154 MCA aneurysms treated with coiling, thromboembolic complications occurred in 13.4% of cases, and recanalization was found on follow-up angiography in 20% (mean follow-up 15 months).¹⁴⁰ The advent of 3D angiographic imaging during endovascular treatment of complex MCA aneurysms has greatly improved the ability to safely treat these aneurysms.

13.3.5.7. Posterior circulation aneurysms

Posterior circulation aneurysms comprise about 15% of all intracranial aneurysms.

BASILAR APEX

Some 50% of all posterior circulation aneurysms are located at the basilar apex. In a systematic review of endovascular treatment of posterior circulation aneurysms, 82% were basilar apex aneurysms.²³¹

1. *Presentation.* If large enough, unruptured basilar apex aneurysms can cause a third cranial nerve palsy or brainstem compression, or, rarely, interference with the optic chiasm.²³² The pattern of blood seen on the CT after SAH can be similar to that seen with some anterior circulation ruptured aneurysms and perimesencephalic aneurysmsal SAH.
2. *Surgical considerations.* Surgery of the basilar apex is challenging because of the location, the presence of brainstem perforating vessels, and the difficulty of obtaining proximal control:
 - (a) *Approach.* An array of approaches to the basilar apex exist and selection of the surgical approach usually depends on the height of the aneurysm relative to the posterior clinoid process. The transsylvian approach is typically employed for relatively “high” basilar apex aneurysms, originating between the midlevel of the sella turcica and about 1 cm superior to the posterior clinoid. A subtemporal approach provides better access to low-lying and posteriorly projecting aneurysms. An orbitozygomatic osteotomy and division of the tentorium are maneuvers that can enhance access to the basilar apex. Intraoperative hypothermic cardiac arrest is another strategy that can reduce the chance of ischemic injury, particularly with large and giant aneurysms. A major priority of surgery of the basilar artery is preservation of the numerous brainstem perforating vessels that arise in this region.
 - (b) *Complications.* Postoperative third cranial nerve palsy is common, occurring 32–52.8% of cases;^{233,234} however complete resolution of the palsy occurs in 80% of patients within 6 months.²³⁴ Younger patients and posteriorly pointing aneurysms are risk factors for third cranial nerve palsy.
3. *Endovascular treatment.* Because of the technical difficulty with surgery, and the relative ease of catheter access, coiling has become the treatment of choice for basilar apex aneurysms in most centers. Randomized data is not available; in ISAT, only 17 (0.7%) of the cases were at the basilar apex.¹⁵⁸ In a review of six basilar apex aneurysm coiling series, the procedural morbidity was 6.6% and the procedural mortality was 1.3% (both ruptured and unruptured aneurysms were included in these figures).²³⁵ In a recent series of 316 coiled basilar apex aneurysms, a 90–100% occlusion was obtained in 86% of cases, and the overall complication rate was 19%.²³⁵ The end-artery position of basilar apex aneurysms may make them more vulnerable to recurrence after coiling. At a mean follow-up period of 19 months, coil compaction was evident in 24% of cases.²³⁵

How Many Names Can There Be?

Aneurysms at the basilar apex have been called by a variety of names, including *basilar summit*,¹⁴ *basilar top*,²³⁶ *basilar tip*,²³⁷ *basilar terminus*,²³⁸ and *basilar bifurcation*. Although the authors consider terms such as “summit” and “top” to be quaint, they prefer the term basilar apex aneurysm.

POSTERIOR CEREBRAL ARTERY

PCA aneurysms are uncommon, comprising some 1% of all intracranial aneurysms.²³⁹⁻²⁴¹ They have a predilection for the P1 and P2 segments²⁴² and they are frequently discovered at an earlier age than aneurysms in other anatomic sites.²³⁹ In addition, they are more likely to be large or giant compared to aneurysms at other locations,²⁴³ and have a relatively high incidence of coexisting vascular dysplasias.²⁴²

1. *Presentation.* Most PCA aneurysms present with SAH. Approximately 25% of patients present with hemianopia or oculomotor disturbances.^{242,244} Giant aneurysms of the P3 segment can cause memory loss due to compression of the hippocampus.²⁴²
2. *Surgical considerations.* P1 aneurysms can be approached via a pterional craniotomy.²⁴⁵ Most aneurysms of the P2 segment can be approached subtemporally. P2 aneurysms that are superior to the tentorium may be reached transcortically and via the temporal horn of the lateral ventricle and the choroidal fissure.²⁴⁶ P3 aneurysms may be reached through the occipital interhemispheric fissure.
3. *Endovascular treatment.* Endovascular strategies include coil embolization or sacrifice of the parent vessel. In a series of 20 patients with PCA aneurysms treated with endovascular techniques, 66% were treated with preservation of

the parent vessel and in the remaining 33% the parent vessel was occluded.²⁴² The overall permanent morbidity rate was 10% with no mortality. Endovascular occlusion of the PCA should be done distal to the P1 segment, to preserve important brainstem and thalamic perforators. It is often well tolerated due to well-developed collateral circulation between the distal PCA and the anterior circulation and other branches of the vertebrobasilar system. In a series of nine P2 segment aneurysms cases which were treated with occlusion of the parent vessel, no neurologic deficits occurred after treatment.²⁴⁷

SUPERIOR CEREBELLAR ARTERY ORIGIN

Most superior cerebellar artery aneurysms arise from the lateral basilar artery wall, in the crotch between the origins of the PCA and SCA. Many surgical series have combined SCA aneurysms with basilar apex aneurysms. Because of the lateral position of these aneurysms, surgery is somewhat more straightforward than surgery for basilar apex aneurysms. Moreover, the approach is similar and the risk of postoperative third cranial nerve palsy (39%) is also comparable.²³⁴ SCA aneurysms are typically small and arise from the basilar artery at a 90° angle, characteristics that can make endovascular treatment challenging. In a series of 12 SCA aneurysms treated with coiling, complete occlusion was obtained in 50%, and procedural morbidity was limited to one SCA territory infarct with good recovery.²⁴⁸

DISTAL SUPERIOR CEREBELLAR ARTERY

Distal SCA aneurysms are rare and usually present with SAH or fourth cranial nerve dysfunction.²⁴⁹⁻²⁵¹ They are also frequently associated with an AVM or are traumatic in origin.^{249,252}

Distal SCA aneurysms can be treated effectively with endovascular parent vessel sacrifice,²⁵³⁻²⁵⁵ particularly since the collateral circulation between the SCA and the AICA and PICA, and even the proximal PCA is generally well developed.

BASILAR TRUNK

Aneurysms of the basilar artery trunk are rare, comprising <1% of all intracranial aneurysms, and 8% of vertebrobasilar aneurysms.²⁵⁶ Approximately twice as many are located in the upper basilar artery as there are in the lower part of the vessel.²⁵⁷

1. *Presentation.* Basilar trunk aneurysms typically present with SAH; large and giant aneurysms may present with brainstem or cranial nerve symptoms.
2. *Surgical considerations.* Surgery in this region is impaired by the petrous bone, which interferes with direct surgical access to this region. Surgical series reports complete aneurysm occlusion rates ranging from 34 to 91%.²⁵⁸⁻²⁶⁰
3. *Endovascular treatment.* Coil embolization of basilar trunk aneurysms is preferred in most centers because of the difficulty with surgery and because catheter access to this region is relatively easy. The technical ease of endovascular treatment was illustrated by a series in which the average procedure time was only 61 min.²⁶¹ A number of endovascular series have reported generally favorable results, although basilar trunk aneurysms may tend to recur after coiling. In a report of 14 cases of coiling of basilar trunk aneurysms with an average follow-up of 20 months, recanalization occurred in 4 (28.6%).²⁶² An alternative strategy is parent vessel sacrifice. Surgical,²⁶³ or endovascular basilar trunk occlusion can be relatively safe and effective in carefully selected patients.²⁶⁴ The authors caution that management of patients after basilar artery occlusion can be challenging.

ANTERIOR INFERIOR CEREBELLAR ARTERY

Aneurysms of the anterior inferior cerebellar artery (AICA) usually arise at the origin of the vessel. In a series of 3,500 aneurysms treated with surgery, AICA aneurysms comprised 1.3%.²⁶⁵ Most surgical series combine AICA aneurysms with basilar trunk aneurysms. AICA aneurysms typically present with SAH, although brainstem compression is a feature in some 20% of cases.²⁶⁵ Like SCA aneurysms, AICA aneurysms can be associated with an AVM.²⁶⁶ Surgical strategies include the retrosigmoid, transpetrosal, far lateral, and subtemporal-transtentorial approach. Possibly because of their infrequency, relatively few reports of endovascular treatment of AICA origin aneurysms have been published so far. Of four basilar artery/AICA aneurysms treated

with coiling, complete occlusion was obtained in two and excellent or good outcomes were had by all.²⁶²

Distal AICA aneurysms are rare, and usually arise from the rostral branch of the vessel.²⁶⁵ They typically present with SAH, and hearing loss may be present due to involvement of the internal auditory artery.²⁶⁷ Endovascular occlusion of the parent vessel distal to the origin of the internal auditory artery is feasible for treatment of these aneurysms because the collateral circulation in this region is usually well developed.²⁶⁸

VERTEBROBASILAR JUNCTION

Vertebrobasilar junction aneurysms arise at the confluence of the vertebral arteries, and are very uncommon, accounting for some 3–4% of all posterior circulation aneurysms.²⁶⁷ They are frequently associated with vertebrobasilar fenestrations.²⁶⁹ Dissecting aneurysms have a tendency to appear in this location.²⁷⁰ Surgical access to this region is limited. Endovascular options include primary coiling, stenting and stent-assisted coiling, and parent vessel sacrifice. Because aneurysms at this location may be filled from both vertebral arteries the resulting hemodynamic stress may lead to a relatively high risk of recanalization after coiling. In one series, three out of five VBJ aneurysms required permanent occlusion of one or both vertebral arteries.²⁶² A potential hazard is occlusion of brainstem perforators or the anterior spinal artery; in a series of basilar artery aneurysms, two out of three ischemic complications occurred in VBJ aneurysms.²⁶²

DISTAL VERTEBRAL/PROXIMAL PICA

Aneurysms of the vertebral artery at the origin of the PICA comprise about 2% of all intracranial aneurysms, and 80% of aneurysms involving the PICA.²⁷¹ They tend to be relatively small (<12.5 mm).²⁷¹ Fusiform, nonsaccular aneurysms are more common in the distal vertebral artery than at other locations, and dissecting aneurysms are also more common, accounting for 28% of intracranial vertebral artery aneurysms in one series.²⁷²

1. *Presentation.* The most frequent presentation of PICA origin aneurysms is SAH, and intraventricular hemorrhage along with acute hydrocephalus are present in >95% of these cases.²⁷³ Some 9–12% of distal vertebral or PICA origin aneurysms present with symptoms of mass effect or ischemia.²⁷⁴
2. *Surgical considerations.* Aneurysms at the PICA–vertebral junction usually occur at least 1 cm above the foramen magnum and arise distally to the PICA origin in the angle between the two vessels. A far lateral suboccipital craniotomy usually provides adequate access. When clipping of the aneurysm with preservation of the PICA is not feasible, a PICA–PICA bypass is an option.²⁷⁵
3. *Endovascular treatment.* Recent reports of endovascular treatment of PICA aneurysms are encouraging. In a series of 31 patients treated with coiling for proximal PICA aneurysms, angiographic occlusion was achieved in 30 (97%) patients.²⁷⁶ Procedural complications occurred in three (10%) patients, including one aneurysm rupture during coiling, one minor PICA ischemic stroke, and one temporary femoral neuropathy. No recanalizations were observed at a mean angiographic follow-up of 9 months.

DISTAL PICA

Distal PICA aneurysms account for <1% of all intracranial aneurysms.^{271,277,278} They may arise from any segment of the PICA but typically occur at branching sites and at curves in the vessel, and project in the direction in which flow would have continued if the curve had not been present.²⁷¹ They are commonly associated with AVMs and other vascular abnormalities, such as dural AV fistulas.^{277,279} Unlike distal aneurysms in other vascular territories, which are often mycotic or traumatic, distal PICA aneurysms are usually sporadic and are almost never related to an infectious etiology. Men and women are affected equally.^{277,280} Most authors recommend treatment of unruptured distal PICA aneurysms of any size, as a significant percentage of ruptured distal PICA aneurysms are <5 mm in size.^{277,281}

1. *Presentation.* The majority of distal PICA aneurysms present with hemorrhage, and intraventricular hemorrhage and acute hydrocephalus are common.^{277,279}
2. *Surgical considerations.* The surgical approach depends on the location of the aneurysm; aneurysms arising from the most distal part of the PICA, the telovelotonsillar and cortical segments can be approached via a midline suboccipital

craniectomy. More proximal PICA aneurysms, of the anterior and lateral medullary segments, usually require a far lateral suboccipital approach. Sacrifice of the PICA is a valid strategy for the treatment of distal PICA aneurysms, and is generally agreed to be safe when it is done distally to the portion of the PICA that gives rise to important perforating vessels (i.e., distal to the choroidal point, or the top of the cranial loop).²⁸¹ For aneurysms of the proximal segments of the PICA that cannot be clipped with preservation of the parent vessel, trapping with a PICA–PICA bypass is an option.²⁷⁵

3. *Endovascular treatment.* Endovascular treatment can be problematic due to the difficulty of navigating a catheter into the distal PICA, and because distal PICA aneurysms tend to be relatively wide-necked. Therefore, parent vessel occlusion, when possible, is usually the most feasible endovascular approach.²⁵⁵ Very distal aneurysms may require treatment with acrylic glue, rather than coils, if soft, flow-directed catheters must be used to catheterize the distal vessel.

13.3.5.8. A brief history of endovascular treatment of intracranial aneurysms

The first successful case of the treatment of an intracranial aneurysm by “electrothrombosis” was reported in 1941.²⁸² For the treatment of an ICA aneurysm, “thirty feet of No. 34 gauge coin silver enamel wire was introduced into the aneurysm through a special needle” advanced through the orbit, and the wire was “heated to an average temperature of 80°C for a total of 40 seconds. The aneurysm no longer bled when the needle was cleared at the end of the operation.” Further attempts to treat intracranial aneurysms by electrothrombosis via the stereotactic insertion of a needle passed through a burr hole and into the aneurysm were reported by Sean Mullan and colleagues in 1965.²⁸³

Several creative approaches to aneurysm treatment were explored in the 1960s and 1970s. The “pilojection” technique involved the forcible injection of hog hairs or horse hairs into the aneurysm with a pneumatic gun.²⁸⁴ Stereotactic magnetically guided embolization of aneurysms with iron particles was also investigated.²⁸⁵

Alfred Luessenhop and A.C. Velasquez published the first report of an endovascular attempt at the treatment of an intracranial aneurysm in 1964.²⁸⁶ They described an effort to occlude a supraclinoid aneurysm with a silicone balloon. Inspired by watching helium balloons on tethers during a May Day celebration in Moscow in 1959, Fedor Serbinenko, a Russian neurosurgeon, developed silicone and latex balloon catheters, initially intended for diagnostic procedures. The balloon at the end of the catheter was used for flow-directed navigation and temporary diagnostic occlusion of major cerebral arteries. Serbinenko accomplished his first successful detachable balloon embolization for sacrifice of an ICA to treat a carotid-cavernous fistula in 1969; the technique involved filling a balloon when it was positioned at the target site with silicone polymer and detaching it by severing the catheter with the cutting edge of an arterial introduction needle.²⁸⁷ Later, technical refinements in the balloon detachment mechanism permitted placement of the detachable balloons within intracranial aneurysms.²⁸⁸

Although balloon embolization of intracranial lesions was popularized in the late 1970s and 1980s,^{289,290} the technique had several drawbacks. Placement of balloons inside aneurysms was problematic because no guidewire could be used, and the preformed spherical or oval shapes of balloons limited their usefulness in aneurysms with complex shapes. In addition, a balloon placed inside an aneurysm could have a ball-valve effect, leading to an accumulation of blood inside the aneurysm, recanalization, and rupture.²⁹¹ Because of these problems and the later introduction of detachable coils, balloon embolization of intracranial lesions has trailed off; the last manufacturer of detachable balloons in the US, Boston Scientific, Inc., stopped selling them in the US because of low demand and regulatory issues with the FDA. Detachable balloons continue to be available in other countries, and will likely eventually be reintroduced into the US, although it is doubtful that they will ever return as a potential treatment for aneurysms, except as a method for achieving large vessel parent artery occlusion.

Therapeutic arterial occlusion with endovascular “pushable” metal coils was originated for the treatment of lesions in the peripheral vasculature.²⁹² Although some operators (including the authors) have used pushable coils for the treatment of intracranial aneurysms,^{293,294} pushable coils were severely hampered by their stiffness, and by an inability to manipulate the coil inside the aneurysm and to retrieve each coil, if necessary, after it is deployed. Continued experimentation with electrothrombosis

eventually lead to the development of detachable coils. Guido Guglielmi, an Italian neurosurgeon, conceived of detachable coils serendipitously in the early 1980s. During the treatment of an experimental aneurysm with a stainless steel electrode to promote electrothrombosis, accidental detachment of the electrode tip occurred. Later, working with engineers at Target Therapeutics, Inc., he developed the Guglielmi detachable coil (GDC, Boston Scientific/Target Therapeutics, Fremont, CA). The GDC coil system permits placement of a platinum alloy coil inside the aneurysm, through a microcatheter; the coil remains attached to the pusher wire until it is in a satisfactory position. The operator then detaches the coil from the wire by applying a low-amplitude electrical current to the pusher wire, which causes electrolysis of the connection between the wire and the coil. Clinical use of GDC coils began in 1991, and in 1995 the FDA granted approval of GDC coils for the treatment of high-risk, inoperable, or ruptured intracranial aneurysms.

A number of technical refinements in the design of aneurysm coils have occurred over the last decade. An array of shapes and sizes of coils have been introduced. *Stretch resistant* coils contain a filament inside the coil to bind the distal end of the coil and resist stretching of the coil when tension is applied. Alternative detachment systems have been introduced, some of which (including TruFill DCS, Cordis Neurovascular, Miami Lakes, FL) are hydraulic rather than electrolytic.

The greatest drawback to the coiling of aneurysms has been the occurrence of recanalization in a significant percentage of treated aneurysms over time, occurring in as many as approximately 20% of coiled aneurysms in 5 years.¹³⁰ *Bioactive coils* have attracted much interest, as a means of enhancing thrombosis and eventual fibrosis within the aneurysm to reduce the likelihood of recanalization. Bioactive coils include the Matrix™ (Boston Scientific, Inc., Natick, MA) and Cerecyte™ (Micrus Endovascular, Sunnyvale, CA) systems, both of which contain polyglycolic-poly-lactic acid (PGLA), and the HydroCoil® system (Terumo Medical/MicroVention, Inc., Aliso Viejo, CA), in which the coils are treated with a gel that swells upon contact with water and occupies space within the aneurysm. Although bioactive coils currently seem to occupy a significant niche in the industry, clinical evidence of their effectiveness in reducing recanalization rates is currently lacking.

The treatment of wide-necked aneurysms can be problematic, and several techniques and devices have evolved to facilitate coiling of these lesions. Balloon remodeling, a technique popularized by Jacques Moret,²⁹⁵ involves the positioning of a temporary balloon in the parent vessel adjacent to the aneurysm neck. The balloon is inflated and permits the placement of a nest of coils within the aneurysm, which are stable once the balloon is deflated and removed. Stent-assisted coiling involves the deployment of a thin wire mesh stent in the parent vessel across the neck of the aneurysm; a microcatheter is then guided through the interstices of the stent for coil deployment. The stent acts as a scaffold to prevent the coils from prolapsing into the parent vessel. The Neuroform™ stent (Boston Scientific, Natick, MA), designed specifically for the treatment of wide-necked aneurysms, is currently in its third generation. Another stent for the treatment of aneurysms, the Enterprise™ Vascular Reconstruction Device (Cordis Neurovascular, Miami Lakes, FL) received an FDA Humanitarian Device Exemption in 2007.

The International Subarachnoid Aneurysm Trial (ISAT) (see below) was the first multicenter, randomized trial to compare surgery coiling in patients with ruptured aneurysms. The results of the trial, which demonstrated a significant advantage to coiling in 1-year outcomes, led to greater acceptance of the use of coils in all types of intracranial aneurysms.

13.4. Subarachnoid hemorrhage

This section will focus on aneurysmal SAH, which accounts for approximately 80% of all nontraumatic SAH cases.²⁹⁶ Traumatic SAH is considered separately below. The remaining ~20% of spontaneous SAH:

1. Angiographic work-up is negative in approximately in some 15–20% of patients with spontaneous SAH.²⁹⁷
2. *Perimesencephalic nonaneurysmal subarachnoid hemorrhage (PMSAH)* – a distinct entity with characteristic clinical and imaging features and an excellent prognosis:
 - (a) Overall incidence: 0.5 per 100,000 persons age ≥18,²⁹⁸ representing approximately 5% of all SAH.

- (b) Diagnosis:
- Patients typically present as HH 1 or 2.
 - Usual CT appearance: Hemorrhage is centered anterior to the pons (Fig. 13.5), although a posterior variant has been described, with the hemorrhage primarily in the in the quadrigeminal cistern.²⁹⁹
 - Radiographic work-up is negative for an aneurysm.
- (c) Mechanism is unknown, although a venous source is suspected. PMSAH is associated with a pattern of primitive venous drainage directly into dural sinuses, instead of via the vein of Galen, as is seen in most patients with SAH.³⁰⁰
- (d) Outcome: Excellent. In a series of 24 patients with this syndrome, only one had a neurological change (and it was transient), and no rebleeds occurred.³⁰¹
3. Other causes of SAH³⁰²:
- (a) Intracranial arterial dissection.
 - (b) AVM.
 - (c) Dural AVF.
 - (d) Infectious aneurysms.
 - (e) Infectious endocarditis.
 - (f) Trauma.
 - (g) Coagulation disorders.
 - (h) Cocaine abuse.
 - (i) Cervical origin of the hemorrhage (e.g., spinal AVM or fistula).
 - (j) Cavernous malformations.
 - (k) Vasculitis or other vasculopathy.
 - (l) Intracranial tumor.
 - (m) Sickle cell disease.
 - (n) Pituitary apoplexy.
 - (o) Intracranial venous sinus thrombosis.

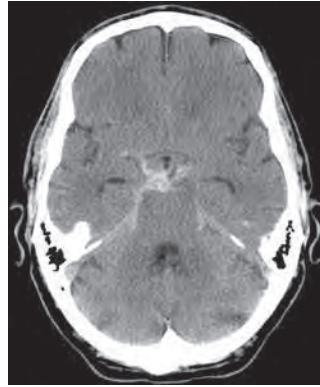

Fig. 13.5 CT appearance of perimesencephalic nonaneurysmal subarachnoid hemorrhage. In patients with perimesencephalic nonaneurysmal subarachnoid hemorrhage, the pattern of blood is frequently asymmetric and includes the ambient cisterns.

13.4.1. Aneurysmal SAH

13.4.1.1. Incidence

1. Global annual incidence of aneurysmal SAH is approximately 10/100,000.³⁰³⁻³⁰⁵
2. Some 21,000–33,000 new cases of SAH occur in the US each year.¹⁰⁷
3. Mean age at presentation: 55 years.³⁰⁶
4. Risk of SAH for women is 1.6 times that of men, and compared to Caucasians, the risk for African Americans and for Hispanics is elevated by a factor of 1.6 and 1.3, respectively.³⁰⁵ Other risk factors for SAH, such as connective tissue disorders and smoking, are discussed above.

13.4.1.2. Diagnosis

PRESENTATION

It is typically described as the “worst headache of my life.” Nausea and vomiting, meningismus, diminished level of consciousness, focal neurological findings, and the presence of risk factors for SAH should raise suspicion of aneurysmal SAH:

1. Vomiting occurs in up to 70% of patients with aneurysmal SAH.³⁰⁷

2. A history of “sentinel headache” is present in 10–43% of patients, and may be the only presenting symptom of SAH.³⁰⁸
3. Intraocular hemorrhage occurs in approximately 17% of patients with SAH.^{309,310}
 - (a) *Terson Syndrome*, i.e., hemorrhage in the vitreous humor, has been seen in 8–17%, and is associated with a significantly elevated mortality rate.^{310,311}
 - (b) Subhyaloid (i.e., preretinal) hemorrhage is seen in 11–33% of cases, and appears fundoscopically as bright red blood near the optic disc that obscures the retinal vessels.³¹²
4. Seizures with the onset of SAH occur in approximately 6% of patients.³¹³

RADIOGRAPHIC WORK-UP

1. The characteristic appearance of aneurysmal SAH on CT is hyperdense blood in the cisterns and fissures.
2. CT is falsely negative in some 2.5–7% of aneurysmal SAH cases.³¹⁴ Because blood can be cleared from CSF spaces relatively rapidly, the sensitivity of CT drops to 50% at 7 days.³¹⁵
 - (a) When the clinical suspicion for SAH is high but CT is negative, lumbar puncture (LP) is indicated, to detect blood in the CSF:
 - Optimal results are obtained if at least 6h, and preferably 12, have elapsed between the onset of the headache and the LP, to permit lysis of the red blood cells and the appearance of xanthochromia (a yellow tinge after centrifugation).³¹⁶
 - Technique: Four sequential aliquots of CSF are collected; the first and fourth tubes are sent for cell count and differential. The specimens should be examined for the presence of xanthochromia.
 - True LP evidence of SAH can be distinguished by the presence of xanthochromia (a yellow tinge after centrifugation) or by a significant drop (defined as $\geq 25\%$ in one study)³¹⁷ in the red blood cell count between the first and fourth tube.
3. CT angiography (CTA) is rapidly replacing catheter angiography as the first-line study in the work up of spontaneous SAH:
 - (a) CTA has sensitivity in the detection of intracranial aneurysms that is comparable or even superior to angiography.^{318,319}
 - (b) CTA carries less risk and expense than angiography, and has the additional advantage of demonstrating bony anatomy, which is helpful in surgical planning.
 - (c) The authors believe that the era of the late-night angiogram for patients with SAH, in anticipation of surgery or coiling the next morning, is coming to an end.
4. Catheter angiography remains the “gold standard” for imaging the intracranial vasculature and is indicated for cases in which the CTA does not explain the hemorrhage.
5. Angiogram-negative SAH:
 - (a) A brain and cervical-spine MRI should be obtained. Causes of SAH that may not be detected on a cerebral angiogram include cavernous malformations, vasculitis, and spinal vascular malformations or tumors. MR imaging revealed abnormalities in 14% of patients with angiographically negative SAH, and resulted in a significant change in management in 6% of patients.³²⁰
 - (b) A repeat angiogram may be needed. An aneurysm can be obscured on the initial angiogram because of thrombosis or vasospasm. The combined result of a second angiogram in eight reported series was 30 aneurysms in 177 patients (17%).³²¹

Table 13.8 Hunt–Hess scale

Grade	Description
1	Asymptomatic, mild headache, slight nuchal rigidity
2	Moderate-to-severe headache, nuchal rigidity, no neurological deficit other than cranial nerve palsy
3	Drowsiness/confusion and/or mild focal neurological deficit
4	Stupor, moderate-to-severe hemiparesis
5	Coma, decerebrate posturing

From reference 322.

Table 13.9 Fisher grading system for SAH

Fisher grade	Appearance of blood on CT
1	No subarachnoid blood visualized
2	Diffuse or thin sheets (vertical layers < 1 mm thick)
3	Localized clot and/or vertical layers (≥1 mm thick)
4	Diffuse or no SAH, but with intraventricular or intraparenchymal clot

From reference 323.

MORTALITY, MORBIDITY AND OUTCOMES

1. SAH accounts for 4.4% of stroke mortality but 27.3% of all stroke-related years of potential life lost before age 65.³²⁴
2. Mortality:
 - (a) The in-hospital mortality rate is 26.3%,³²⁵ and the 30-day case fatality rate is 38%.^{326,327}
 - (b) Prospective studies, which include deaths occurring prior to hospital admission, have shown consistently higher mortality rates, ranging from 56 to 86%.^{99,328,329}
3. Most deaths occur within 2 weeks of the initial hemorrhage, with 61% occurring within 48 h of the event.³³⁰
4. Patients with posterior circulation aneurysms are three times more likely to die before reaching the hospital or within the first 48 h after SAH than patients with anterior circulation aneurysms.³³¹
5. Some 10–20% of SAH survivors remain dependent.³³²
6. Overall fatality and outcomes seem to have improved in recent decades.^{332,333}

REBLEEDING AND TIMING OF TREATMENT

1. Rebleeding prior to treatment:
 - (a) The peak rate of rehemorrhage occurs in the first 24 h³³⁴ – the “spike of death” – and ranges as high as 17–19%.^{335,336,337}
 - (b) The rebleed rate appears to be approximately 20% within the first 2 weeks of the ictus,^{335,338,339} and 40% at 1 month:³³⁸
 - The rate of rebleeding is roughly 2–3% per day.
 - (c) Patients with higher Hunt and Hess grades and larger aneurysms are at higher risk of rebleeding.³⁴⁰
 - (d) Rebleeding after SAH carries a mortality rate of up to 74%.^{341,342}
 - (e) Antifibrinolytic therapy:
 - Epsilon-aminocaproic acid (Amicar®, Wyeth-Ayerst, Carolina, PR) and tranexamic acid are synthetic lysine analogues, which block lysine binding sites on plasminogen molecules, inhibiting plasmin formation and thereby inhibiting fibrinolysis.³⁴³
 - Prolonged administration of each agent has been shown to protect against recurrent hemorrhage,³⁴⁴⁻³⁴⁸ although overall outcome did not improve due to aggravated vasospasm and delayed ischemia caused by these agents.^{345,348} In addition, some studies have reported a 24–48 h lag in the effectiveness of epsilon-aminocaproic acid.^{349,350}
 - There has been a revival in interest in the use of antifibrinolytic agents, specifically to protect against rebleeding in the short term, from the time of diagnosis to treatment of the aneurysm:
 - Leipzig and colleagues circumvented the drawbacks to epsilon-aminocaproic acid by using a loading dose – to overcome the lag in effectiveness – and limited administration of the drug to a brief course, prior to early surgical intervention.³⁵¹ The overall rebleed rate of 1.3% compared favorably to historical controls.
 - A multicenter randomized trial of immediate administration of tranexamic acid, prior to early clipping or coiling of the aneurysm, showed a reduction in the rebleeding rate from

10.8 to 2.4% ($p < 0.01$) and an 80% reduction in the mortality rate from early rebleeding ($p < 0.05$).³⁵²

2. Timing of treatment:
 - (a) Several large-scale studies in the 1970s and 1980s showed that outcomes are better the earlier surgery is done for ruptured aneurysms in most patients.³⁵³⁻³⁵⁵
 - (b) The primary rationale for early treatment of ruptured aneurysms is to minimize the risk of rehemorrhage and to undertake the procedure (surgery or coiling) prior to the onset of vasospasm, when the risk of complications from treatment may be greater.
3. Long-term risk of recurrent SAH after aneurysm clipping:
 - (a) In the first 10 years after the initial SAH, the cumulative risk of recurrent SAH after clipping is 3.2%, with an incidence of 286 per 100,000 patient-years.⁸⁸ This is 22 times higher than expected in the general population.

HYDROCEPHALUS

1. Some degree of ventricular enlargement is common in SAH, occurring in about 20% of patients.³⁵⁶⁻³⁵⁹ Often the ventricles, especially the temporal horns, will “flare” in the first day or two after the ictus, then return to normal:
 - (a) 50% of patients who have clinical hydrocephalus recover spontaneously within the first 24 h.³⁵⁸
2. Hydrocephalus causing a depressed level of consciousness occurs in some 8% of patients.³⁶⁰
3. Risk factors for acute hydrocephalus after SAH:
 - (a) Intraventricular hemorrhage, diminished level of consciousness, increasing age, posterior circulation aneurysm site, and a larger volume of subarachnoid blood.³⁶¹
4. Ventriculostomy prior to protection of the ruptured aneurysm should be reserved *only* for patients with a diminished level of consciousness and ventriculomegaly.
 - (a) *Important.* During the ventriculostomy procedure, care should be taken to avoid overdrainage of CSF, to prevent an abrupt change in intracranial pressure – and transmural aneurysm pressure – that may increase the risk of rehemorrhage:
 - Placement of a ventriculostomy is associated with an increased incidence of rebleeding.^{360,362}
 - (b) The ICP after ventriculostomy should be maintained at or above 20–25 mmHg, because lower values have been associated with higher incidence of rebleeding.³⁶³
 - (c) For patients undergoing craniotomy for clipping, a ventriculostomy done at the time of surgery can produce brain relaxation and help with exposure.
5. Chronic hydrocephalus:
 - (a) Incidence is unclear. Reports vary widely, with rates of shunt-dependent post-SAH hydrocephalus ranging from 20 to 63.4%.^{359,364}
 - The indications for shunt placement typically include persistent or progressive ventriculomegaly, chronic headaches, and a lack of neurological improvement after SAH.
 - (b) In a randomized trial, gradual weaning was not found to lead to a lower rate of chronic hydrocephalus compared to rapid weaning.³⁶⁴
 - (c) The authors’ preference is to routinely obtain a head CT 1 month after SAH to check for progressive hydrocephalus.

SEIZURES

1. Seizures after SAH occur in some about 8% of patients, and 90% occur in the first 24 h after aneurysm rupture.³⁶⁵⁻³⁶⁷
2. Any patient who has a seizure after SAH should be evaluated with a CT to rule out recurrent hemorrhage.
3. Prophylactic anticonvulsant treatment was routine in many centers until recently. Seizure prevention, usually with phenytoin, was felt to be necessary to minimize the risks of rebleeding and chronic seizure disorder. Accumulating evidence suggests that routine seizure prophylaxis is not advantageous, for the following reasons:

- (a) In a multivariate model, seizures were not found to be associated with an increased risk of rebleeding.³⁴⁰
 - (b) The majority of seizures occur prior to hospitalization and are uncommon after 7 days of hospitalization.³⁶⁷
 - (c) Phenytoin exposure is associated with functional and cognitive disability after SAH.³⁶⁸
 - (d) Early seizures (within 1 week of SAH) are not a risk factor for late epilepsy.^{366,369}
 - (e) The authors of this handbook prefer to reserve anticonvulsants for patients who have had, or are suspected to have had, a seizure.
4. Treatment of seizures after SAH:
- (a) An active seizure can usually be controlled with lorazepam, 1–2 mg IV.
 - (b) Load with phenytoin, 1 g (or 17 mg kg⁻¹) IV, then maintenance dose of 100 mg PO/NG/IV TID.
 - (c) Levetiracetam (Keppra[®], UCB Pharma, Inc., Brussels, Belgium) is a recently introduced anticonvulsant with a favorable side effect profile. Although the drug has not been studied in patients with seizures after SAH, it appears to be a good alternative to phenytoin. Typical starting dose is 500 mg PO/NG BID; can be increased to a total of 1,500 mg BID if necessary to control seizures. An IV form of the drug is not available and serum levels cannot be monitored; dosing is titrated to clinical effect (seizure elimination). Primary side effect is drowsiness, and the principle drawback is that it is expensive compared to phenytoin and valproic acid.
 - (d) By convention, patients who have seizures after SAH should be maintained on an anticonvulsant for at least 6 months and then weaned off, depending on how the patient is doing.
 - (e) In most states, patients with a history of seizure after SAH must be seizure-free for 6 months before being allowed to resume driving an automobile.
5. The incidence of epilepsy after SAH (defined as ≥ 2 seizures at least 1 week after SAH) is 3–8%.^{369,371}
- (a) In ISAT, there were significantly fewer seizures in patients undergoing coiling compared to craniotomy and clipping (see below).¹⁵⁷

13.4.2. Associated medical problems

Medical problems are a major source of morbidity in patients with SAH. In a study of 457 patients with SAH, 40% of patients had at least one life-threatening medical complication, and 23% of all deaths were attributable to medical complications.³⁷² The occurrence of fevers, anemia, hyperglycemia, and acute hypoxia and hypotension related to neurogenic cardiac injury each have a significant impact on mortality and functional outcome.³⁷³ There is a growing recognition that optimal medical management of SAH patients includes tight control of serum glucose and electrolyte levels and fluid volume.

13.4.2.1. Hyperglycemia

Hyperglycemia is common in patients with SAH, occurring in some 30% of patients and is an independent predictor of a poor outcome.^{374,375,376} Hyperglycemia in this setting is presumably due to a catecholamine surge and generalized stress response.^{377,378} Ischemic injury to the insula is also associated with hyperglycemia.³⁷⁹

Hyperglycemia exacerbates cerebral ischemic injury.^{380,381} Hyperglycemia appears to worsen cerebral acidosis, leads to free radical production³⁸², and has direct cerebrovascular effects that can worsen ischemia.³⁸³ In severely ill patients in a surgical ICU, intensive insulin therapy to maintain serum glucose at or below 110 mg dL⁻¹, even in patients without diabetes, was shown to reduce morbidity and mortality.³⁸⁴ A preliminary trial of glucose and insulin infusions to maintain serum glucose within a target range of 5.0–7.0 mmol L⁻¹ (90–125 mg dL⁻¹) in SAH indicates that this strategy is safe, although larger trials to evaluate the benefit of this strategy are needed.

13.4.2.2. Serum electrolyte derangements

HYPONATREMIA

Hyponatremia occurs in as many as 30–43% of patients.^{385–387} Although hyponatremia typically appears within days of SAH, it appears >7 days following SAH in 21.4% of patients.³⁸⁸ Hyponatremia is strongly associated with cerebral vasospasm (84% of patients with hyponatremia had symptomatic vasospasm³⁸⁹), and may be a causative factor.³⁹⁰ Hyponatremia is also associated with CT evidence of raised intracranial pressure³⁹¹.

1. Risk factors for hyponatremia after SAH:
 - (a) Aneurysmal SAH (compared to angiogram-negative spontaneous SAH).³⁸⁸ Hyponatremia occurs significantly more often in patients with ruptured anterior communicating artery aneurysms (51%) compared to patients with aneurysms in other locations.²⁰⁴
 - (b) Third ventricular enlargement.³⁹²
 - (c) Diabetes, congestive heart failure, cirrhosis, and adrenal insufficiency.
2. Cerebral salt wasting (CSW) is defined as the renal loss of sodium during intracranial disease leading to hyponatremia and a decrease in extracellular fluid volume. CSW must be distinguished from the syndrome of inappropriate ADH secretion (SIADH) because the primary treatment for SIADH, water restriction, will exacerbate hypovolemia in patients with CSW and may place them at risk of cerebral ischemia.
3. CSW appears to occur *as frequently or more frequently* than SIADH in neurosurgical patients.³⁹³ A decrease in plasma volume of >10% occurs in some 50% of patients with aneurysmal SAH³⁹⁴; this finding supports the notion that volume depletion – and thus CSW, when hyponatremia appears with volume depletion – is relatively common in SAH.
4. The mechanism of CSW has not been clearly elucidated. Intracranial pathology is thought to lead to a release of one or more natriuretic factors, causing natriuresis and diuresis. Although early reports implicated atrial natriuretic factor (ANP) as the primary natriuretic factor, more recent data has linked an increase in serum levels of brain natriuretic factor (BNP) with cerebral salt wasting.³⁹⁵ Serum levels of BNP are consistently elevated in patients with SAH.^{396,397} BNP is released by the cardiac ventricles; sympathetic stimulation during SAH³⁹⁸ and during vasospasm,³⁹⁹ may cause release of BNP. BNP has also been localized to the hypothalamus,⁴⁰⁰ and may be released when that part of the brain is injured.³⁹⁶
5. Diagnosis:
 - (a) The critical feature distinguishing CSW from SIADH is volume status; patients with CSW are hypovolemic, as evidenced by a negative water balance and diminished weight, and central venous pressure. Serum osmolality, blood urea nitrogen concentration, and hematocrit may be elevated. In contrast, SIADH is invariably a normovolemic or hypervolemic state.
 - (b) Urine sodium concentration may be elevated in both CSW and SIADH and therefore is not useful in this setting. Similarly, serum ADH and ANP levels are also not helpful in distinguishing CSW from SIADH.
6. Management:
 - (a) CSW is treated with volume replacement and maintenance of a positive salt balance. IV hydration should be undertaken with 0.9% NaCl (at least 100 mL h⁻¹ or at a rate sufficient to match fluid losses). For most cases of mild and moderate cases of hyponatremia attributable to CSW, sodium repletion with NaCl tablets, 2g PO/NG TID is sufficient. For symptomatic CSW and a serum sodium level <130 mEq L⁻¹, a 3% NaCl IV infusion may be necessary.
 - (b) Overcorrection should be avoided. Rapid correction of hyponatremia is associated with central pontine myelinolysis. Elevation of the serum sodium level should not be faster than 0.7 mEq L⁻¹ h⁻¹, for a maximum total daily change not to exceed 20 mEq L⁻¹.

HYPERNATREMIA

Some degree of hypernatremia (serum sodium >150 mmol L⁻¹) has been found in 20% of patients³⁷⁵ and is an independent predictor of a poor outcome.³⁸⁷ Hypernatremia typically arises in patients with SAH as the result of mannitol administration, diabetes insipidus, or widespread brain injury. Diabetes insipidus has been reported in some 0.04% of subarachnoid patients.⁴⁰¹ Treatment of hypernatremia consists of

replacement of fluid losses with hypotonic IV fluids and desmopressin, a synthetic analogue of ADH that is usually given as 1–2 mcg IV, SQ, or intranasal doses.

HYPOKALEMIA

Some 27% of patients with SAH have hypokalemia.⁴⁰² Hypokalemia can lead to QTc prolongation and serious ventricular arrhythmias.⁴⁰³ Women are at higher risk of hypokalemia after SAH,⁴⁰⁴ and female sex and hypokalemia are independent risk factors for severe QTc prolongation in patients with SAH.⁴⁰⁵ In a literature review of 1,139 patients with SAH, there were five cases of torsade de pointes, and all of these patients were hypokalemic.⁴⁰⁶ Serum potassium levels should be checked daily and repleted as necessary to maintain the serum potassium level ≥ 3 mmol L⁻¹ (7.3 mg dL⁻¹).

HYPOMAGNESEMIA

Hypomagnesemia (<0.70 mmol L⁻¹ or 1.7 mg dL⁻¹) occurs in nearly 40% of patients with SAH.^{402,407} Hypomagnesemia at admission is associated with more blood on CT and a greater severity of illness,⁴⁰⁷ and is also associated with EKG changes in patients with SAH.⁴⁰² Although some authors have found an association between hypomagnesemia and cerebral ischemic injury in patients with SAH,⁴⁰⁷ others have not.⁴⁰⁸ Some operators administer magnesium sulfate infusion to patients after SAH, although the data to support this treatment is incomplete (see discussion of *Prevention of Ischemic Injury Due to Vasospasm* section).

13.4.2.3. Cardiac abnormalities

EKG CHANGES

EKG changes are common after SAH. Changes in the ST segment (15–51% of patients), T waves (12–92%), the appearance of U waves (4–47%), QT prolongation (11–66%), and sinus dysrhythmias are the most frequent changes.^{409,410} Although EKG abnormalities correlate with the severity of SAH,⁴¹¹ they usually disappear within a day with no change in the neurological or cardiac condition,^{403,412} and are generally not predictors of serious cardiac complications.^{409,413,414}

CARDIAC ARRHYTHMIAS

Serious cardiac arrhythmias in some 1–4% of patients with SAH,^{372,403} with malignant ventricular arrhythmias (i.e., torsade de pointes and ventricular flutter or fibrillation) in reported in 4.3%; these patients also had QTc prolongation and hypokalemia.⁴⁰³ An increased frequency of arrhythmias was found to occur on the day of, or the day after, aneurysm surgery.³⁷² Increased sympathetic tone and electrolyte alterations appear to be the primary factors; the insula and injury to this region of the brain, has also been linked to the occurrence of cardiac arrhythmias.^{415,416} Continuous EEG monitoring in the acute phase after SAH is essential.⁴¹⁷

REVERSIBLE CARDIOMYOPATHY

A syndrome of reversible cardiomyopathy, described as “stunned myocardium,” occurs in a significant percentage of patients with SAH. Left ventricular dysfunction occurs in about 10% of patients,^{414,418} and 20% of patients with SAH develop cTI >1.0 μ g L⁻¹.⁴¹⁹ Cardiac dysfunction is believed to be due to massive sympathetic nervous activation that occurs after SAH,^{419–422} coronary vasospasm has also been implicated.⁴²³

1. Risk factors:

- (a) Hunt–Hess score >2, female sex, larger body surface area and left ventricular mass, lower systolic blood pressure, and higher heart rate are independent predictors of troponin elevation.⁴¹⁹

2. Management implications:

- (a) Cardiac troponin I elevation after SAH is associated with an increased risk of cardiopulmonary complications, delayed cerebral ischemia, and death or poor functional outcome at discharge.^{424,425}
- (b) In most cases, the cardiac changes are reversible.^{426,427}

- (c) The optimal management of severely affected patients is unclear.⁴²⁸ Low cardiac output in these patients may exacerbate cerebral ischemia and inotropic agents such as dobutamine may be beneficial.^{414,426,429} In patients with profound cardiac dysfunction and cerebral vasospasm, an intra-aortic balloon pump may augment cerebral perfusion and assist cardiac function.⁴³⁰
- (d) In patients with cardiac complications and symptomatic vasospasm, aggressive hyperdynamic therapy should be avoided. In these patients, angioplasty may be more beneficial than hyperdynamic therapy in the treatment of vasospasm.⁴²⁷

13.4.2.4. Neurogenic pulmonary edema

Pulmonary complications are common in patients with SAH. The incidence of acute pulmonary edema in SAH is 20–27%,^{372,431,432} with some 6% of patients having severe pulmonary edema.³⁷² The incidence of pneumonia is 20%.³⁷⁵ The syndrome of neurogenic pulmonary edema is likely to be due to sustained elevated sympathetic tone, leading to a catecholamine-induced increase in pulmonary capillary permeability and pulmonary vasoconstriction.⁴³³ Diastolic dysfunction may also contribute to pulmonary edema.⁴³⁴ Risk factors include symptomatic vasospasm,⁴³¹ severity of illness, clinical grade of hemorrhage, red blood cell transfusions, and sepsis.⁴³² Neurogenic pulmonary edema appears most often on days 3–7 after SAH,³⁷² although it has been observed at any time from day 1 to day 14:

1. Management:
 - (a) Intubate if necessary. Mechanical ventilation parameters should be chosen to minimize positive end-expiratory pressure (PEEP), and maintain $\text{PaO}_2 > 96\%$.⁴³⁵
 - (b) *Judicious* use of diuretics, while maintaining normovolemia, may improve pulmonary function without compromising cerebral perfusion.
 - (c) Dobutamine infusion may also be a useful adjunctive measure; this drug has the advantage of not impairing cerebral perfusion.⁴³⁶

13.4.2.5. Vasospasm

Cerebral vasospasm is defined as narrowing of large or small intracranial arteries after SAH. Symptomatic vasospasm (also known as *clinical vasospasm*, or *delayed ischemic neurological deficit*) is the leading cause of death and disability in patients with SAH. The pathogenesis of vasospasm is not well understood. Arterial hemorrhage surrounding the major cerebral arteries in the subarachnoid space appears to initiate a series of changes in the arterial walls that results, several days after the hemorrhage, in narrowing of the vessel lumen. Sustained smooth muscle cell contraction appears to be the primary mechanism of vasospasm,⁴³⁷ although inflammatory, immune-mediated, and proliferative processes have also been implicated.⁴³⁸ Red blood cells are necessary for vasospasm to occur, and the 3–5 day time course of red cell lysis corresponds to the onset of clinical vasospasm. An array of vasoconstrictive mediators have also been identified which appear to have a role in vasospasm; these include oxyhemoglobin and other erythrocyte breakdown products, free radicals, eicosanoids, nitric oxide, endothelin, and various neurogenic factors.

FREQUENCY AND TIME COURSE

1. Some degree of vasospasm is seen on approximately 70% of angiograms done during the second week after SAH.^{439,440}
2. Symptomatic vasospasm occurs in some 20–25% of patients^{441,442}:
 - (a) Symptoms of vasospasm probably do not appear unless there is at least a 50% reduction in arterial caliber.⁴⁴³
 - (b) Angiographic vasospasm with >50% reduction in arterial caliber is seen in 23–30% of patients.^{444–446}
3. Onset of vasospasm rarely occurs prior to day 3 after SAH. Vasospasm is maximal at days 6–8, and is significantly reduced or gone in most patients within 2 weeks.^{447,448}
 - (a) Fewer than 4% of cases occur after day 12 after SAH.⁴⁴⁰
4. The onset of symptomatic vasospasm has been reported as long as 35 days after SAH.⁴⁴⁹

RISK FACTORS

1. The best predictor of vasospasm is the amount of blood seen on the initial head CT scan, which correlates with the frequency and severity of vasospasm.⁴⁵⁰⁻⁴⁵²
2. Other risk factors for symptomatic vasospasm include age <50 years, hyperglycemia, history of hypertension, larger aneurysm size, intraventricular hemorrhage, and cocaine use.⁴⁵³
3. The question of whether vasospasm is more likely after clipping or coiling is unresolved, as each modality has been found by various authors to be associated with a lesser incidence of vasospasm.^{454,455}

CLINICAL FEATURES AND DIAGNOSIS

1. Symptomatic vasospasm typically presents as confusion and a decline in the level of consciousness. Focal neurological deficits may appear as well.
2. The onset of symptoms may be sudden or insidious.⁴⁴⁷
3. Neurological change is the best indicator of symptomatic vasospasm, and therefore frequent neurological exams are essential in patients with SAH:
 - (a) Daily interruption of sedation was found to reduce ICU length of stay and the incidence of complications of in-patients in a medical intensive care unit.⁴⁵⁶
4. Autoregulation is impaired.⁴⁵⁷
5. Radiographic evaluation:
 - (a) Catheter angiography:
 - Gold standard for diagnosis of cerebral vasospasm.
 - Significant vasospasm is indicated by a reduction in arterial caliber by 25–50% or more.
 - (b) CTA:
 - CTA is relatively accurate for ruling in (90.7%) or ruling out (99.5%) hemodynamically significant vasospasm affecting large intracranial vessels.⁴⁵⁸ It is less accurate for evaluating distal vessels and for detecting mild or moderate vasospasm. Sources of error in CTA in this setting include over-windowing and an excessive delay in scanning after administration of the contrast dose.
 - (c) CT perfusion:
 - CT perfusion can detect reductions in regional CBF indicative of symptomatic vasospasm. CT perfusion using the deconvolution technique has significant drawbacks including the necessity of selecting a reference artery and a dependence on hemispheric asymmetry to identify ischemia, when cerebral vasospasm can be a global phenomenon. Deconvolution CT perfusion appears to be most useful in this setting when combined with CTA.⁴⁵⁹ The authors have had satisfactory results with CT perfusion using the maximum slope model.⁴⁶⁰
 - (d) Transcranial Doppler (TCD) ultrasonography:
 - Flow velocity within a vessel is directly proportional to the volume of blood flow and inversely proportional to the square of the diameter of the vessel. Therefore, TCD velocity changes can be nonspecific and can reflect either vasospasm or an *increase* in CBF.⁴⁶¹ TCD measurements are also notoriously vulnerable to operator technique.
 - The MCA is the most reliable vessel to assess,⁴⁶² and mean flow velocities $>200\text{ cm s}^{-1}$ are highly suggestive of significant vasospasm, whereas velocities $<100\text{ cm s}^{-1}$ are not.⁴⁶³
 - Most studies have defined an MCA flow velocity of $>120\text{ cm s}^{-1}$ as evidence of some degree of vasospasm.^{464,465}
 - Velocities $\geq 130\text{ cm s}^{-1}$ and $\geq 110\text{ cm s}^{-1}$ are indicative of ACA and PCA vasospasm, respectively.⁴⁶⁶
 - Velocities in the vertebral artery of $\geq 80\text{ cm s}^{-1}$ or the basilar artery of $\geq 95\text{ cm s}^{-1}$ have been found to indicate posterior circulation vasospasm.⁴⁶⁷
 - TCD seems to be more useful in *ruling in* vasospasm than ruling it out. A systematic review found the positive predictive value of MCA velocity changes in the diagnosis of vasospasm to be 97%, and the negative predictive value to be 78%.⁴⁶²
 - Lindegaard ratio: Attempts to correct for changes in CBF by calculating the ratio between the MCA velocity and the ICA

velocity.⁴⁶⁸ A ratio of <3 is normal and a ratio >6 is highly suggestive of vasospasm; intermediate values are indeterminate:

- A "modified Lindegaard ratio" for basilar artery vasospasm: the ratio between the basilar artery velocity and the extracranial vertebral artery ratio. A ratio >2 had 100% sensitivity in identification of patients with basilar artery vasospasm.⁴⁶⁹
- The authors prefer to use TCD examinations selectively. A baseline TCD examination is done on all patients on admission, to create a baseline, and then TCD values are obtained on a daily basis for surveillance in patients for whom it is difficult to rely on a change in the neurological exam to identify vasospasm, such as high-grade SAH patients, or patients on a mechanical ventilator.

PREVENTION OF ISCHEMIC INJURY DUE TO VASOSPASM

Standard management of all patients with SAH should include adequate hydration, maintenance of normonatremia, and ventricular drainage, if needed. Both hypovolemia and hyponatremia have been shown to increase the risk of cerebral ischemia in patients with SAH.³⁸⁵ Nimodipine is firmly established as a prophylactic measure in patients with SAH. Recent evidence also indicates that statin therapy may be significantly beneficial as well. Some evidence has also suggested that magnesium infusion and lumbar drainage may lower the incidence of symptomatic vasospasm. Although prophylactic hyperdynamic therapy may reduce the risk of vasospasm, it carries an increased risk of complications, and most clinicians reserve hyperdynamic therapy for the treatment of vasospasm, rather than prophylaxis:

1. Nimodipine:

- (a) Nimodipine is a voltage-gated calcium channel antagonist and reduces calcium entry into smooth muscle cells and neurons. Nicardipine is another dihydropyridine calcium channel blocker that has been studied in patients with SAH, but much less extensively than nimodipine. Nimodipine has been shown in a total of eight randomized trials to have a modest but statistically significant effect on outcome in patients (*not angiographic vasospasm*) with aneurysmal SAH.⁴⁷⁰⁻⁴⁷⁶
- (b) The largest trial was the British Aneurysm Nimodipine Trial (BRANT).⁴⁷⁶ A total of 554 patients with SAH were randomized to receive either placebo or nimodipine, 60 mg PO Q 4h for 21 days. Treatment was begun within 96h of the ictus:
 - The 3-month incidence of cerebral infarction:
 - 33% in the placebo group.
 - 22% in the nimodipine group ($p = 0.003$).
 - The 3-month rate of poor outcomes (death, vegetative state, or severe disability):
 - 33% in the placebo group.
 - 20% in the nimodipine group ($p < 0.001$).
- (c) A systematic review of three randomized trials of oral nimodipine showed a significant benefit with nimodipine, demonstrating a relative risk of death or dependence 0.70 ($p = 0.0002$).⁴⁷⁷
- (d) Both PO/NG and IV nimodipine have been evaluated, although the IV formulation is not available in North America. The most common side effect of oral nimodipine is transient hypotension; this can be mitigated by administering the drug 30 mg Q 2h instead of 60 mg Q 4h.
- (e) The mechanism of nimodipine's beneficial effect is not clear, as the oral formulation has not been found to decrease the rate of vasospasm.⁴⁷⁶ Nimodipine may function as a direct neuroprotectant or enhance cerebral microcirculation by causing arteriolar dilation.⁴⁷⁸
- (f) Although the duration of treatment in BRANT was 21 days, it seems reasonable to discontinue nimodipine earlier in good-grade patients who are beyond the standard risk period for vasospasm.^{443,479} A retrospective study of 90 patients with Hunt-Hess I-III SAH who were treated with nimodipine for 15 days or less found no evidence of a delayed neurological deficit.⁴⁷⁹ In addition, nimodipine is expensive and not available in all pharmacies. The authors prefer to stop nimodipine treatment upon discharge from the hospital for patients who are neurologically intact.

2. Statins:

- (a) Hydroxymethylglutaryl coenzyme A reductase inhibitors (statins) have surprisingly emerged as beneficial to patients with SAH. One retrospective study⁴⁸⁰ and two prospective randomized trials⁴⁸¹⁻⁴⁸⁴ have

- supported the use of statins in the prevention and management of vasospasm.
- (b) The larger of the two trials was conducted at Addenbrooke's Hospital in the United Kingdom.⁴⁸²⁻⁴⁸⁴ A total of 80 patients with SAH were randomized to receive either placebo or pravastatin, 40 mg PO QD. Treatment was begun within 72 h of ictus and continued for up to 14 days or until discharge:
- The incidence of vasospasm:⁴⁸²
 - 62.5% in the placebo group.
 - 42.5% in the pravastatin group ($p = 0.006$).
 - The incidence of vasospasm-related delayed ischemic deficits:⁴⁸²
 - 30.0% in the placebo group.
 - 5.0% in the pravastatin group ($p < 0.001$).
 - Mortality:⁴⁸²
 - 20.0% in the placebo group.
 - 5.0% in the pravastatin group ($p < 0.037$).
 - Multivariate analysis showed that pravastatin reduced unfavorable outcomes at discharge by 73% ($p = 0.041$) and by 71% at 6 months ($p = 0.063$).⁴⁸³
- (c) Pravastatin adverse effects. Although myalgia, myopathy, and hepatotoxicity are commonly associated with statin use, a large-scale prospective study found no difference in the rates of these symptoms in patients taking pravastatin 40 mg QD compared to patients taking a placebo.⁴⁸⁵ In the British pravastatin study, no adverse events attributable to pravastatin were reported; alanine aminotransferase (ALT) elevations were similar in the drug and placebo patients:
- Myalgia occurs in 2% of all patients treated with pravastatin.⁴⁸⁶ Reversible with pravastatin discontinuation.
 - Myopathy with creatine phosphokinase (CPK) elevations $>10\times$ normal occurs in $<0.1\%$ of all patients treated with pravastatin.⁴⁸⁶
 - Hepatotoxicity. ALT elevation ($>3\times$ normal) (1.4%).⁴⁸⁵
- (d) Mechanism. Numerous potential mechanisms have been invoked to explain the beneficial effect of statins in SAH, including effects independent of the cholesterol-lowering effects such as improved cerebral vasomotor reactivity and a reduction in cytokine responses to cerebral ischemia.^{487,488} Recent data suggests that cerebrovascular protection may also function through cholesterol-dependent mechanisms as well.⁴⁸⁴
3. Lumbar drainage:
- (a) Continuous lumbar drainage in patients with SAH is based on the notion that enhanced evacuation of the cisternal blood may reduce the risk of vasospasm.
- (b) A single retrospective study found a significant benefit with lumbar drainage in patients with SAH⁴⁸⁹:
- In 167 patients with SAH, 81 patients received a lumbar drain, and 86 did not. Some patients received a ventriculostomy in addition to, or instead of, a lumbar drain.
 - The drain was placed at the time of surgery and kept closed until postoperative day 1; it was then opened after a postoperative CT was checked. Drainage was undertaken at a rate of 5–10 mL h⁻¹ until the CSF was no longer visibly hemorrhagic and the risk period for vasospasm had ended.
 - Outcomes were significantly better in the lumbar drainage group:
 - Clinical vasospasm:
 - (a) Lumbar drain group 17%.
 - (b) Control group 51% ($p < 0.001$).
 - Angioplasty and/or papaverine infusion:
 - (a) Lumbar drain group 17%.
 - (b) Control group 45% ($p = 0.001$).
 - Vasospasm-related infarction:
 - (a) Lumbar drain group 7%.
 - (b) Control group 27% ($p = 0.008$).
 - Disposition (discharged to home rather than rehabilitation or an extended care facility):
 - (a) Lumbar drain group 54%.
 - (b) Control group 25% ($p = 0.002$).
 - Complications included infections in two patients with both a lumbar drain and a ventriculostomy, and transient clinical or

neurological worsening with CSF drainage was initiated (diminished level of consciousness in two, and bradycardia in one). These changes cleared rapidly after clamping the drain, and lumbar drainage was restarted successfully after 24–36 h.

4. Magnesium infusion:
 - (a) Hypomagnesemia is common among SAH patients and may be associated with cerebral ischemia and poor outcomes.⁴⁰⁷ Magnesium supplementation reverses vasospasm and reduces infarct volume in experimental SAH.^{490–492} Magnesium supplementation is well established in obstetrics and cardiology,⁴⁹³ and is inexpensive and readily available. Some clinical data suggest that magnesium supplementation may improve outcomes after SAH.
 - (b) The largest trial of magnesium in SAH to date found a trend toward a significant benefit with treatment.⁴⁹⁴ A total of 283 patients were randomized to receive magnesium sulfate ($64 \text{ mmol L}^{-1} \text{ day}^{-1}$) until day 14 after treatment of the aneurysm. Magnesium treatment reduced the risk of delayed ischemic injury by 34% (hazard ratio 0.66; 95% CI 0.38–1.14). The 3-month risk reduction for poor outcome was 23% (risk ratio 0.77; 95% CI 0.54–1.09). There were no major side effects.
 - (c) Side effects with magnesium infusion can include bradycardia and hypotension; in the authors' experience, these symptoms tend to occur most often in elderly patients, and resolve with discontinuation of the magnesium infusion. Magnesium intoxication, occurring at levels of $\geq 2.0 \text{ mmol L}^{-1}$ (4.9 mg dL^{-1}), is manifested by nausea, headache, and muscle weakness.
 - (d) Magnesium may exert beneficial effects by inhibition of the release of excitatory amino acids and blockade of the *N*-methyl-D-aspartate-glutamate receptor.^{495,496} Magnesium is also a voltage-gated calcium channel antagonist and has a cerebral vasodilatory effect.⁴⁹⁷
 - (e) The authors treat all SAH patients with magnesium. Magnesium sulfate is given IV at the dose used in the Dutch randomized trial described above⁴⁹⁴ (dissolve 40 g MgSO_4 in 1,000 mL sterile water, run IV infusion at 17 mL h^{-1}). Magnesium is started upon admission and is discontinued when the patient leaves the NICU. Magnesium is discontinued in patients with hypotensive or bradycardic side effects.
5. Prophylactic hyperdynamic therapy:
 - (a) Hyperdynamic therapy, also known as "Triple H" therapy, consists of the maintenance of hypervolemia, hypertension, and hemodilution, to improve the rheologic properties of blood, to enhance cerebral perfusion. Prophylactic hyperdynamic therapy can raise CBF in patients after SAH.⁴⁹⁸
 - (b) A systematic review of four prospective studies with a total of 488 patients found a decreased risk of symptomatic vasospasm and death with prophylactic hyperdynamic therapy, but no significant change in the incidence of delayed ischemic neurological deficits.⁴⁹⁹ However, only one of these studies was randomized.⁵⁰⁰ The paucity of information and limitations in the design of the studies lead the authors of this review article to conclude that the efficacy of prophylaxis is undecided and that recommendations for the use of prophylactic hyperdynamic therapy cannot be made.⁴⁹⁹ Similarly, two other systematic reviews of hypervolemic therapy identified only two randomized studies and found no sound evidence for the use of this technique in patients with SAH.^{501,502}
 - (c) One randomized trial found no increase in CBF with prophylactic hypervolemia;⁵⁰⁰ the authors of this study surmised that any beneficial effects of prophylactic volume expansion were likely to be due to avoidance of hypovolemia, rather than any direct benefit of additional fluid volume.
 - (d) Because of a lack of proven efficacy^{503,504} and an established increase in the risk of complications with hyperdynamic therapy (see below), the authors of this handbook prefer to use hyperdynamic therapy only in patients with evidence of symptomatic vasospasm.
6. Other preventative measures:
 - (a) Clot evacuation and lysis:
 - Surgical clot removal.
 - Thrombolysis.
 - (b) Tirilazad.
 - (c) Fasudil.
 - (d) Endothelin antagonists.

13.4.2.6. Treatment of vasospasm

Blood flow in large vessels is described by the Hagen–Poiseuille equation:

$$Q = \Delta P \pi r^4 / 8L\eta,$$

where Q is the blood flow, ΔP is the pressure gradient, r is the vessel radius, L is the length, and η is the viscosity. Theoretically, flow in cerebral vessels affected by vasospasm can be increased by increasing the pressure gradient (by induced hypertension or hypervolemia), by decreasing the viscosity (by hemodilution), or by expanding the vessel radius (by angioplasty).

HYPERDYNAMIC THERAPY

“Triple H” therapy (hypertension, hypervolemia, and hemodilution) is considered by many to be first-line therapy in the treatment of symptomatic vasospasm, and should be reserved for patients who have undergone treatment of the ruptured aneurysm.⁵⁰⁵ Hypertension and hypervolemia *do not* appear to increase the risk of hemorrhage from untreated, unruptured aneurysms in patients with SAH.⁵⁰⁶ To avoid promoting cerebral edema or hemorrhagic transformation, hyperdynamic therapy should not be used in patients with a significant brain edema or a large infarction; hyperdynamic therapy should be discontinued as soon as the ischemic deficit resolves.⁵⁰⁷

Of the three components of hyperdynamic therapy, blood pressure elevation appears to be the most beneficial,⁵⁰⁸ volume expansion seems to be useful mostly as a measure to avoid hypovolemia, which can exacerbate delayed ischemic injury.⁵⁰⁰ Specific endpoints and methods of hyperdynamic therapy vary widely; no particular quantitative endpoint (e.g., SBP vs. CPP vs. PCWP) has been shown convincingly to be superior to others. The most important endpoint is clinical improvement.

Because most published protocols have used a combination of volume expansion and induced hypertension, with hypertension added only for patients who have not responded to hypervolemia alone, hypervolemia will be considered first:

1. Hypervolemia:

- (a) A central venous pressure (CVP) catheter should be placed in all patients with aneurysmal SAH.
- (b) Target parameters range from 6 to 12 mmHg (8–16 cm water).^{509–511}
- (c) IV fluids: 0.9% normal saline at 100–140 mL h⁻¹.
 - 5% albumin (250 mL TID) can be used for additional volume expansion:
 - Infusion of 5% albumin (250 mL IV every 2 h as needed for CVP ≤8 mmHg) has been found to be effective in maintaining CVP >8 mmHg in patients with SAH.⁵¹¹
 - Dextran and hetastarch should be avoided because of potential effects on coagulation.
- (d) A systematic review found no sound evidence for or against the use of volume expansion in patients with SAH.⁵⁰¹ The authors view moderate hypervolemia as a method to ensure that the patient is well hydrated and to facilitate hypertensive therapy, if needed.

2. Hypertension:

- (a) Induced hypertension has been found to reverse deficits in patients with symptomatic vasospasm.^{505,509,510,512}
- (b) Endpoints:
 - Systolic blood pressure (SBP):
 - A radial arterial catheter is helpful for blood pressure monitoring.
 - Giannotta and colleagues reported a significant improvement in 88% of patients with symptomatic vasospasm managed in the following way: CVP was elevated to 8–10 cm water (~6–7 mmHg) with blood and plasma transfusions and albumin; for patients who did not improve and whose SBP remained <140 mmHg, dopamine or phenylephrine was used to raise SBP to 150–170 mmHg.⁵⁰⁹
 - Awad and coworkers reported a reversal of deficits in 60% of patients treated first with aggressive hypervolemic therapy

- (10–12 mmHg; ~14–16 cm water), and then with hypertension if the deficits did not improve.⁵¹⁰ Phenylephrine or dopamine was used to elevate blood pressure until the deficits cleared or to a maximum of 200 mmHg.
- Cerebral perfusion pressure (CPP):
 - Obviously requires intracranial pressure monitoring.
 - Moderate hypertension (CPP 90–120 mmHg, CVP 5–10 mmHg, Hct 25–40) led to a greater increase in brain tissue PO₂ compared to hypervolemia (CVP 10–15 mmHg) or more aggressive hypertension (CPP >120 mmHg).⁵⁰⁸
 - Pulmonary capillary wedge pressure (PCWP):
 - Requires placement of a Swan–Ganz catheter.
 - Recommended target values for PCWP range from 12–15 mmHg⁵¹³ to 16–18 mmHg.⁵¹⁴
- (c) Methods to induce hypertension:
- Volume expansion first, with isotonic saline and 5% albumin.
 - Inotropes, such as dobutamine and dopamine, increase cardiac output and are the most commonly reported hypertensive agents in hyperdynamic therapy. An increase in cardiac output, without changes in mean arterial pressure, can elevate CBF in patients with vasospasm.⁵¹⁵ Inotropes are also preferred over vasoconstrictors such as phenylephrine and levophed because of the potential for systemic ischemic complications with vasoconstrictors.
 - Dobutamine dose: 2.5–10 mcg kg⁻¹ min⁻¹, up to 40 mcg kg⁻¹ min⁻¹ as needed.
 - Dopamine dose: 5 mcg kg⁻¹ min⁻¹, up to 20–50 mcg kg⁻¹ min⁻¹ as needed.
 - Phenylephrine dose: 0.1 mcg kg⁻¹ min⁻¹, up to 4 mcg kg⁻¹ min⁻¹ as needed.
- (d) The authors prefer to use SBP as the primary quantitative endpoint for blood pressure management during treatment of symptomatic vasospasm. SBP is a simple, straightforward measurement that can be assessed in all patients, whereas CPP requires intracranial pressure monitoring and PCWP requires use of a Swan–Ganz catheter. In all patients with SAH and a treated ruptured aneurysm, SBP is allowed to rise as high as 200 mmHg; in patients with symptomatic vasospasm, volume expansion and inotropes are used to maintain SBP >160 mmHg.
3. Hemodilution:
- (a) Some degree of “hemodilution” occurs with volume expansion.
- (b) No clinical data exist to support *deliberate* hemodilution in the setting of SAH.⁴⁴³
- Controlled, isovolemic hemodilution to a hematocrit of 28% in patients with vasospasm produced an increase in global CBF but a pronounced reduction in oxygen delivery capacity.⁵¹⁶
 - A systematic review found no net benefit with hemodilution in patients with acute ischemic stroke.⁵¹⁷
- (c) The authors prefer to maintain hematocrit at about 30%:
- A hematocrit of 30% has been found to be the optimal hematocrit for reducing cerebral infarction in some animal models, and hematocrit >30% has been found to be associated with reduced perfusion and tissue survival in patients with acute ischemic stroke.⁵¹⁸
4. Complications of hyperdynamic therapy:
- (a) Documented complications with hyperdynamic therapy are numerous, with overall complication rates ranging from approximately 24–30%.^{372,519} Pulmonary edema appears to be the most frequent complication.
- (b) Intracranial complications include hemorrhagic transformation of infarcts, increased intracranial pressure, aneurysm rebleeding, and hypertensive encephalopathy.^{505,520}
- (c) Extracranial complications include pulmonary edema in 17% of patients,⁵¹⁴ myocardial infarction (2%), coagulopathy, hemothorax.⁵⁰⁵ Complications in patients with Swan–Ganz catheters were detailed by Rosenwasser and colleagues and include sepsis (13%), congestive heart failure (2%), subclavian vein thrombosis (1.3%), pneumothorax (1%) and hemothorax.⁵²¹
5. Authors’ protocol:
- (a) In patients with symptomatic vasospasm, the authors use isotonic saline and 5% albumin to maintain the CVP 8–10 cm water. Blood pressure is

maintained at SBP ≥ 160 mmHg with an inotrope if needed (dobutamine or dopamine). These quantitative endpoints are modified, if needed, depending on the clinical situation to minimize the risk of complications (e.g., the parameters are lowered if significant pulmonary or brain edema is already present). Hyperdynamic therapy is discontinued once the clinical deficit clears, or the theoretic risk period for vasospasm has been passed (i.e., > 12 days after the hemorrhage).

ANGIOPLASTY

1. Balloon angioplasty is an option for symptomatic vasospasm affecting intracranial arteries >1.5 mm in diameter,⁵²² such as the intracranial ICA, the M1, A1, and the vertebral and basilar arteries and P1 segments. Technique is discussed in Chap. 11, *Endovascular Treatment of Intracranial Stenosis and Vasospasm*.
2. The internal elastic lamina and smooth muscle cells are stretched and thinned during angioplasty.⁵²³ Dilation of the vessel segments is essentially "permanent" for the duration of the clinical vasospasm; vasospasm generally does not recur after angioplasty.
3. Results:
 - (a) Reversal of neurological deficits with angioplasty has been reported in 30–70% of patients who fail hypervolemic, hypertensive, hemodilution (Triple H) therapy.^{524–527}
 - (b) Clinical improvement appears to be strongly dependent on the timing of the procedure, with significantly better results reported with angioplasty done within 24 h,⁵²⁶ and within 2 h⁵²⁸ of the neurological change.
4. Complications:
 - (a) Overall complication rates of ~5–10% have been reported.^{524,529}
 - (b) Complications include rupture of the vessel, wire perforation, ischemic stroke, vessel dissection, femoral artery injury, retroperitoneal hemorrhage, and failure to improve symptoms.
5. Strategies:
 - (a) Some authors advocate attempting a trial of hyperdynamic therapy for vasospasm prior to performing angioplasty,⁴⁴³ whereas others prefer to do angioplasty on an emergent basis.⁵²⁸
 - (b) Angioplasty in combination with aneurysm coiling has been used successfully for patients presenting with SAH and symptomatic vasospasm.⁵³⁰ Alternatively, surgery to clip the aneurysm can be followed by immediate postoperative angioplasty.⁵³¹
 - (c) Some operators are reluctant to perform angioplasty when the affected cerebral region shows evidence of infarction on CT, because of a concern for the possibility of hemorrhagic transformation. However, in a series of 17 cases in which angioplasty was done despite a CT scan showing a new hypodensity, there were no hemorrhages or worsening of symptoms.⁵³² There was resolution of the CT hypodensities in 5 of the 17 patients and the majority of the patients improved clinically.
 - (d) Prophylactic angioplasty for vasospasm has been done in a single-center trial; however, one patient in the trial died as the result of vessel rupture during the procedure.⁵³³

INTRA-ARTERIAL PHARMACOLOGIC TREATMENT

1. Intra-arterial (IA) infusion of antispasmodic medications can supplement angioplasty, and can be used for the endovascular treatment of vasospasm of vessels distal to the circle of Willis, that are too small for balloon angioplasty. Although IA papaverine was popular in some centers in the 1990s, it has fallen out of favor in recent years because its effect is short-lived and because of side effects, such as dramatic ICP elevation and some cases of malignant ischemic infarction in territories infused. Preliminary reports of IA infusion of calcium channel blockers have been encouraging.
2. IA calcium channel blockers:
 - (a) Nicardipine:
 - In a series of 18 patients treated with IA nicardipine, all vessels that were treated demonstrated angiographic improvement, and neurologic improvement occurred in 42% of patients. Transient ICP

elevation occurred in 28% of patients and sustained ICP, requiring mannitol infusion, occurred in one patient (6%)⁵³⁴.

- Regimen: Nicardipine (Cardene IV; ESP Pharma, Inc., Edison, NJ) was diluted in 0.9% NaCl to a concentration of 0.1 mg mL⁻¹ and administered in 1 mL aliquots through a microcatheter to a maximal dose of 5 mg per vessel. Dose per vessel was based on the angiographic effect observed.

(b) Nimodipine:

- In a series of 25 patients treated with IA nimodipine, clinical improvement was observed in 76% of patients and notable vascular dilation was observed in 43% of the procedures.⁵³⁵
 - Regimen: A 25% dilution of nimodipine in saline was made. Slow infusion of the solution at a rate of 2 mL min⁻¹ was done with an electric pump. Each infusion lasted 10–30 min per vessel. The total dose per vessel was 1–3 mg and the total dose per patient was ≤5 mg.
- Note: Parenteral nimodipine is not available in the United States.

(c) Verapamil:

- In a series of 17 patients treated with IA verapamil alone, five patients (29%) experienced neurologic improvement.⁵³⁶ The average increase in vessel diameter was 44 ± 9%, and no patients had ICP elevation:
 - Regimen: On average, the total dose of verapamil per patient was 3 mg and two vessels were treated in each patient. The average dose per vessel was 2 mg and the largest single dose per vessel was 8 mg.

3. IA papaverine:

- (a) Papaverine is an alkaloid that causes vasodilation of cerebral arteries through a direct inhibitory effect on smooth muscle contraction. IA papaverine infusion reverses angiographic vasospasm.^{537,538}
- (b) The effect of papaverine is short-lived, lasting less than 3 h.⁵³⁹
- (c) Papaverine has significant adverse effects, including increased ICP,⁵⁴⁰ seizures,⁵⁴¹ paradoxical worsening of vasospasm,⁵⁴² and permanent gray matter damage.⁵⁴³
- (d) In a comparison of IA papaverine and balloon angioplasty, angioplasty was found to have a more sustained favorable effect.⁵⁴⁴

4. The authors of this handbook favor IA nicardipine or verapamil infusion in cases in which an angioplasty balloon cannot be navigated into position (e.g., the A1 segment in some patients), and for the endovascular treatment of diffuse, small vessel vasospasm (e.g., vasospasm affecting the M2 segments or beyond, despite treatment of the M1 segment). One of the authors of this handbook reserves limited IA papaverine use for rare cases in which some degree of pharmacologic dilation is required in order to navigate an angioplasty balloon into position; in these cases, a single small dose of IA papaverine (100–200 mg) is usually sufficient (the other author has not used papaverine in the last 10 years).

Table 13.10 SAH management protocol

Admission orders	Comments and references
Admit to the Neuro-ICU	A dedicated neurocritical care team was associated with reduced in-hospital mortality and length of stay in Neuro-ICU patients. ⁵⁴⁵
Diagnosis: SAH	
Condition: Critical	
Allergies:	
Vital signs: Q 1 h with neurochecks	Meticulous monitoring of the patient's neurologic status will identify changes that require prompt treatment, such as aneurysm rehemorrhage, vasospasm, or hydrocephalus ⁵⁴⁶
Activity: Bedrest	

(continued)

Table 13.10 (continued)

Admission orders	Comments and references
Nursing: SAH Precautions (low light, minimal stimulation, etc.), record CVP and UOP hourly	
NPO except meds until management plan for the aneurysm is decided	
Enteral feeding is begun as soon as feasible (diet is advanced as tolerated); a nasogastric feeding tube (Dobhoff tube) is placed and tube feeding is begun for intubated patients or those unable to eat	Nutritional needs are elevated by SAH, due to a profound stress response and increased catabolism ⁵⁴⁷
IVF: 0.9 N.S. with 20 mEq KCl L ⁻¹ at 120 mL h ⁻¹	Aggressive hydration with isotonic fluids is meant to minimize risk of hypovolemia and hyponatremia, both of which have been shown to increase the risk of cerebral ischemia after SAH ^{385,389}
5% Albumin 250 mL IV Q 6 h, hold for CVP > 12	Volume expansion with albumin is a method to prevent hypovolemia. Retrospective data suggests 5% albumin may improve outcome and reduce hospital costs in SAH patients ⁵⁴⁸
Nimodipine 60 mg PO/NG Q 4 h for 21 days	Nimodipine is associated with improved outcomes in patients with aneurysmal SAH ⁴⁷⁰⁻⁴⁷⁶
Pravastatin, 40 mg PO QD up to 14 days or until discharge	Begin pravastatin after admission labs (liver function tests and CK) are checked and are normal. Pravastatin is associated with lower rates of vasospasm and spasm-related cerebral ischemia ^{481,482}
Morphine 2–6 mg IV Q 1 h PRN (any other IV narcotic is acceptable)	
Esomeprazole 40 mg PO/IV QD (any other stress ulcer prophylactic medication is acceptable)	GI prophylaxis is recommended for all SAH patients ⁵⁴⁹
MgSO ₄ gtt (prepare 40 g in 1,000 mL sterile water; infuse at a rate of 17 mL h ⁻¹). Discontinue when the patient is transferred out of the NICU	A randomized trial of magnesium in SAH found a trend toward a significant benefit with treatment without major side effects ⁴⁹⁴
Labetalol 5–20 mg IV Q 20 min PRN SBP > 160 (BP parameters are liberalized when the aneurysm is treated, i.e., SBP up to 200 is okay)	Early rebleeding was found to correlate with SBP ≥160 mmHg, ⁵⁵⁰ and extremes of blood pressure on admission (MAP > 130 or <70 mmHg) are associated with poor outcome after SAH ⁴⁹⁵
Ondansetron 4 mg IV Q 4–6 h PRN (most other antiemetics are acceptable)	
Amicar 5 g IV load given over 1 h, then infusion at 1 g IV Q 1 h (24 g in 1 L of 0.5 N.S. at 42 mL h ⁻¹). <i>Amicar is discontinued when the aneurysm is treated</i>	Short-term antifibrinolytic treatment may reduce the risk of rebleeding without an associated increase in risk of ischemic complications or hydrocephalus. ³⁵¹ Tranexamic acid, an antifibrinolytic that is not available in the US, was shown in a randomized trial to reduce the risk of rehemorrhage ³⁵²
Avoid warfarin, clopidogrel, ticlopidine, LMWH, especially when patient has had craniotomy, ventriculostomy, or intracerebral hemorrhage	
External pneumatic compression devices on lower extremities at all times	External pneumatic calf compression reduces deep venous thrombosis in patients with SAH ³⁵¹

(continued)

Table 13.10 (continued)

Admission orders	Comments and references
Admission labs: CBC, serum electrolytes, coagulation parameters, toxicology screen, liver function tests, CK, CK-MB	
Daily labs: CBC, serum electrolytes, only (unless a question requiring a specific lab arises)	Surveillance for electrolyte disorders and infection
12 Lead EKG and chest X-ray on admission	
TCDs: obtain one baseline study on day of admission or day after admission. HH 4 and 5 patients: obtain TCDs daily	TCDs are useful for surveillance for symptomatic vasospasm, particularly in high-grade SAH patients with depressed mental status, in whom subtle neurologic changes are difficult to ascertain

Procedures

Arterial line and central line on admission.

After the aneurysm is protected, a lumbar drain is placed (in OR for clipped patients, in NICU while still intubated for coiled patients).

Ventriculostomy is placed only for symptomatic hydrocephalus.

Vasospasm Management

Any neurologic change should prompt a standard work-up, including review of electrolytes, vital signs, and a head CT if indicated. If this work-up is negative, a presumptive diagnosis of symptomatic vasospasm may be made.

All SAH patients are kept well hydrated. Full-blown hyperdynamic therapy (“H³ⁿ”) is initiated only when a diagnosis of symptomatic cerebral vasospasm is made.

13.4.2.7. The International Subarachnoid Aneurysm Trial

Randomized, prospective, multicenter trial of endovascular coiling vs. surgical clipping for selected patients with ruptured intracranial aneurysms deemed suitable for either therapy. The study began in 1994 and continued enrollment through 2002. The preliminary findings were reported in Lancet in 2002;¹⁵⁸ the final 1-year outcome data was reported in Lancet in 2005.¹⁵⁷

1. A total of 9,559 patients were screened, and 2,143 (22.4%) were randomly assigned to either surgery ($n = 1,070$) or endovascular treatment ($n = 1,073$).
2. Clinical outcomes were assessed at 2 months and 1 year. Recruitment was stopped after an interim analysis showed a significant advantage of endovascular therapy:
 - (a) Patients dead or dependent at 1 year:
 - 23.5% in the endovascular group.
 - 30.9% in the surgical group:
 - Absolute risk reduction of 7.4% ($p = 0.0001$).
 - The early survival advantage was maintained for up to 7 years and was significant ($p = 0.03$).
 - (b) Subgroup analyses showed significant benefits with endovascular therapy for patients age 50–69; all Fisher grades; aneurysm lumen size ≤ 10 mm; and ICA aneurysm location. No subgroup showed a significant benefit with surgery.
 - (c) The number of patients with confirmed rebleeding from the target aneurysm at 1 year was slightly greater in the endovascular group:
 - 45 in the endovascular group.
 - 39 in the surgical group:
 - However, 28 of the rebleeds in the surgical group occurred prior to treatment, vs. only 17 in the endovascular group. This may be partly explained by the fact that the mean interval to treatment was 1.7 days in the surgical group, and 1.1 days in the endovascular group. Not counting rebleeds occurring prior to first treatment, total 1-year rebleeds were:
 - (a) 35 in the endovascular group.
 - (b) 13 in the surgical group.
 - Late rebleeding (>1 year) was higher in the endovascular group:
 - 7 in the endovascular group.

- 2 in the surgical group.
- (d) There was a significant reduction in seizures with endovascular treatment, from hospital discharge to 1 year:
 - 27 in the endovascular group.
 - 44 in the surgical group:
 - Relative risk of seizures with endovascular treatment compared to surgery: 0.52 (95% CI 0.37–0.74).
- (e) Study limitations and controversies:
 - The study results are applicable only to aneurysms that are treatable with either surgery or coiling. Of the 9,559 patients eligible for inclusion, 69% were excluded because the aneurysm could not be treated by either procedure.
 - Most of the centers in the study were located in Europe, and therefore the results may not be applicable to patients in the US, where the degree of subspecialization and experience of neurovascular surgeons may be different.⁵⁵²
 - Although clinical outcomes at 1 year were superior in the endovascular group, the rebleeding rate after treatment was higher. Over a longer term, the effect of rebleeding may reduce the early benefit of coiling.

13.5. Intracranial aneurysms: Special situations

13.5.1. Pediatric aneurysms

Pediatric intracranial aneurysms are uncommon but have a number of features that are distinct from aneurysms found in adults.

13.5.1.1. Epidemiology and characteristic features

1. Pediatric cases account for about 1–2% of all intracranial aneurysm cases^{553,554}.
 - (a) To date, only approximately 700 cases have been reported in the literature.⁵⁵⁵
 - (b) It is estimated that academic centers typically see one case per year.⁵⁵⁶
2. About twice as many boys are affected than girls.⁵⁵⁴
3. Age at presentation is bimodal.⁵⁵³
 - (a) Birth to age 6 years, and peaking at 6 months.
 - (b) Age 8 to adolescence.
4. Aneurysms in children are more likely than adults to be at the ICA or MCA bifurcations or in the posterior circulation:
 - (a) A review of all cases reported by 2004 found the most common locations to be the ICA bifurcation (26%), A-comm (19%), MCA bifurcation (17%), and posterior circulation (17%).⁵⁵⁴
 - (b) Pediatric intracranial aneurysms are also more likely than adult aneurysms to be located in the peripheral vasculature,⁵⁵⁷ possibly reflecting the higher incidence of traumatic aneurysms in children, which are typically located in the periphery.
 - (c) A systematic review of reports of aneurysms occurring in children <1 year of age found that a prevalence of aneurysms on the MCA is nearly three times higher than on any other vessel, and did not find that boys are more frequently affected, as has been reported for other age groups.⁵⁵⁸
5. Etiology and pathophysiology:
 - (a) A number of conditions are associated with pediatric aneurysms (Table 13.11):
 - Some authors recommend routine noninvasive screening for intracranial aneurysms for children with aortic coarctation, polycystic kidney disease, and Ehlers–Danlos syndrome.⁵⁵³
 - (b) Some data suggest that idiopathic pediatric aneurysms are pathologically distinct from adult aneurysms. Some characteristic features

of adult aneurysms, such as atherosclerotic changes and an abrupt termination of the internal elastic lamina at the aneurysm neck, were not found in an autopsy series of pediatric aneurysms.⁵⁵⁹

(c) Pediatric aneurysms are more likely to be complex than adult aneurysms⁵⁶⁰; fusiform and dolichoectatic aneurysms comprised 51% of the aneurysms in one series.⁵⁵⁵

(d) Traumatic aneurysms, arising after closed or penetrating head injury, comprise 14–39% of all pediatric aneurysms.⁵⁶¹

(e) Some 20% of pediatric aneurysms are giant.⁵⁵⁴

6. Clinical features:

(a) Pediatric aneurysms are usually symptomatic at the time of presentation.

(b) SAH is the most common mode of presentation; aneurysms in children are four times as likely to present with SAH than not.⁵⁵⁴

(c) Children with SAH appear to have a lesser incidence⁵⁶⁰ and a greater tolerance⁵⁵³ for cerebral vasospasm:

- Vasospasm was found in 53% of children undergoing angiography between the 4th and 16th day after SAH.⁵⁶²

(d) Mortality after SAH is lower than in adults, ranging from 10 to 20%.⁵⁶³

Table 13.11 Conditions associated with pediatric intracranial aneurysms

Bacterial endocarditis
Brain tumors
Cardiac myxoma
Closed or penetrating head injury
Ehlers–Danlos syndrome
Fibromuscular dysplasia
G-6-PD deficiency
Human immunodeficiency virus
Irradiation
Marfan syndrome
Moyamoya disease
Polycystic kidney disease
Pseudoxanthoma elasticum
Sickle cell anemia
Syphilis
Thalassemia
Tuberous sclerosis
Type IV collagenopathy
Vascular anomalies

13.5.1.2. Management

Intracranial aneurysms in children are fundamentally different from adult aneurysms, and therefore clinical data from adult series cannot be extrapolated to the pediatric population. Interpretation of literature about the treatment of pediatric aneurysms is impaired by the infrequency of these lesions, and the fact that endovascular therapy has evolved considerably in recent years; some series report cases extending back to the infancy of neurointervention (i.e., the 1970s).⁵⁵⁵

1. Surgical series have generally reported favorable results, although direct clipping of the aneurysm has been accomplished only 30–46% of cases.^{553,555} Adjunctive surgical techniques such as trapping, large vessel occlusion, or bypass are frequently required.
2. Endovascular series have also reported good results.⁵⁶³
3. A recent single-center retrospective review found complete obliteration rates of 94% for surgical patients and 82% for endovascular patients, with no deaths and similar rates of new neurological deficits (7.7% for surgery and 6.3% for endovascular treatment).⁵⁵⁵
4. A multidisciplinary approach is important, with participation of pediatric neurosurgeons, vascular neurosurgeons, and neurointerventionalists, decision making and management.
5. *Meticulous follow-up is mandatory after both surgery and endovascular treatment:*
 - (a) De novo aneurysms occurred in up 19% of patients after treatment (mean follow-up 5.7 years).⁵⁵⁵
 - (b) Sanai and colleagues recommended angiography 6 and 24 months after endovascular treatment and 3–5 years after surgery, with additional surveillance depending on the findings of these studies.⁵⁵⁵

13.5.2. Pregnancy and intracranial aneurysms

13.5.2.1. Unruptured aneurysms and pregnancy

The risk of SAH in pregnant patients with an unruptured aneurysm is five times that of nonpregnant women in the same age group.^{564,565} The risk of rupture increases with advancing maternal age⁵⁶⁴⁻⁵⁶⁶ and as gestation progresses.⁵⁶⁴ These observations, combined with the considerable risk of SAH to the mother and the fetus, support treatment of unruptured aneurysms before patients become pregnant.

13.5.2.2. Evaluation

1. Head CT and cerebral angiography can both be performed safely during pregnancy. Recommendations for radiation exposure of the fetus include a maximum dose of 0.5 rem (roentgen-equivalent-man).⁵⁶⁷ By shielding the uterus with a lead apron, the maximum dose to the fetus during a head CT is less than 0.05 rem.⁵⁶⁸
2. Catheter angiography in pregnant patients is discussed in Chap. 2, *Diagnostic Cerebral Angiography*. The diagnostic yield of angiography in aneurysmal SAH during pregnancy is believed to be superior to that of the general population.

13.5.2.3. SAH in pregnant patients

CLINICAL FEATURES

1. The incidence of spontaneous SAH during pregnancy is 0.01–0.05% of all pregnancies.^{564,569,570}
2. The risk of hemorrhage increases with advancing gestational age, peaking at 30–34 weeks.⁵⁶⁹
3. The overall mortality rate is 35%, comparable to that of the nonpregnant population.⁵⁶⁹
4. The effect of parity on subarachnoid hemorrhage is unclear. The most recent data suggest that primigravidae are at higher risk than multiparous woman.^{569,571}
5. The clinical features of aneurysmal subarachnoid hemorrhage in pregnant patients are similar to those of nonpregnant patients.⁵⁶⁹ “The worst headache of my life” is the most common presenting complaint. A history of a sentinel headache may be present in 50% of cases.⁵⁷²
6. Hypertension is a risk factor for SAH during pregnancy, occurring in 29% of patients with antepartum aneurysmal hemorrhage and in 67% of patients with postpartum aneurysmal hemorrhage.⁵⁶⁹

DIFFERENTIAL DIAGNOSIS

1. As with SAH in the general population, trauma is the most common cause of SAH in pregnant patients.⁵⁶⁴
2. SAH must be distinguished from *preeclampsia* and *eclampsia*, which are more common than SAH in pregnant women and can appear with features similar to those of spontaneous SAH. In addition, aneurysmal SAH can precipitate preeclampsia:
 - (a) Preeclampsia is defined as the presence of hypertension in pregnant patients accompanied by proteinuria, edema, or both. Preeclampsia typically occurs after the 24th week of pregnancy and usually in primiparas. Severe preeclampsia can include a sharp increase in blood pressure, hyperreflexia, neurologic changes and visual disturbances.
 - (b) Eclampsia is defined as the occurrence of seizures in a preeclamptic patient not attributable to other causes and can cause intracranial hemorrhage. Of patients with fatal eclampsia, 40% exhibit subarachnoid hemorrhage or intraparenchymal hemorrhage on autopsy,^{573,574} although the incidence in nonfatal cases is unknown.⁵⁶⁹ Typical CT findings in

- eclampsia are multiple subcortical petechial hemorrhages or a single, large intracerebral hematoma.⁵⁶⁹
- The next most common cause of spontaneous intracranial hemorrhage during pregnancy after eclamptic disorders and aneurysmal SAH is a ruptured AVM. In a series of 154 cases of intracranial hemorrhage during pregnancy, aneurysms were the cause in 77% of patients and AVMs in 23%.⁵⁶⁹
 - Other causes of spontaneous SAH during pregnancy include disseminated intravascular coagulopathy,⁵⁷⁵ sickle cell anemia,⁵⁷⁵ anticoagulation therapy,⁵⁷⁶ cocaine abuse,⁵⁷⁷ metastatic choriocarcinoma,⁵⁷⁸ Moyamoya disease,⁵⁷⁹ and spinal vascular anomalies.⁵⁶⁴

NEUROVASCULAR MANAGEMENT

- Standard medical management of a pregnant patient with SAH includes:
 - Placement of an arterial line to permit continuous monitoring of blood pressure and treatment of hypertension and hypotension:
 - Hypotension should be avoided because the fetus is passively dependent on maternal blood pressure for adequate perfusion and is vulnerable to maternal hypotension.
 - Continuous fetal heart rate monitoring.
 - Adequate analgesia, sedation, and antiemetics should be provided.
 - Medication selection should be done in consultation with a pharmacist with consideration of the possible effects of each drug on the fetus.
- Treatment to prevent rebleeding is recommended:
 - Rehemorrhage without surgical or endovascular treatment during the pregnancy occurs in 33–50% of cases and is associated with a maternal mortality rate of 50–68%.^{569,580-582}
 - In a study of 118 pregnant patients with aneurysmal SAH, surgical treatment of the ruptured aneurysm was associated with significantly lower maternal and fetal mortality rates than conservative treatment.⁵⁶⁹
 - The maternal mortality rate in patients undergoing surgery for the ruptured aneurysm prior to delivery (11%) was significantly lower than for patients not undergoing surgery (63%). The fetal mortality rate was significantly better after surgery (5%) compared with patients not undergoing surgery (27%).⁵⁶⁹
 - The decision to treat the aneurysm should be based on neurosurgical criteria, and the method of delivery should be based on obstetric considerations:
 - Obstetrical issues should take priority over neurosurgical concerns during active labor (which can be triggered by SAH), eclampsia, or fetal distress. In these cases, delivery should be performed promptly by cesarean section, followed as soon as possible by neurosurgical treatment.^{564,583}
- Both surgery⁵⁶⁹ and endovascular techniques⁵⁸⁴⁻⁵⁸⁶ are valid options for treatment of the aneurysm during pregnancy.

OBSTETRICAL MANAGEMENT

- Method of delivery. Delivery should be undertaken in most situations according to obstetric rather than neurosurgical criteria. Both vaginal delivery and cesarean section are reasonable, and neither method seems to offer a significant advantage for patients with SAH. The risk of bleeding during vaginal delivery is not significantly different from that during cesarean section.⁵⁶⁶ Mortality rates also appear to be similar after vaginal delivery or cesarean section for pregnant patients with vascular disorders.^{569,571,587,588}
 - Obstetric methods to minimize bleeding during vaginal delivery include caudal or epidural anesthesia, shortening of the second stage of labor, and low forceps delivery.
 - Cesarean delivery can be used for fetal salvage when the mother is moribund and in the third trimester.⁵⁸⁹
- Fetal monitoring. Patients should be followed before, during, and after neurosurgical procedures with continuous fetal monitoring. If persistent fetal distress appears and is not reversed by changes in oxygenation, positioning, or blood pressure, emergent cesarean delivery should be performed:

- (a) If labor begins and delivery becomes imminent during craniotomy, the intracranial procedure should be suspended, the bone flap temporarily replaced if possible, and the child delivered vaginally or by cesarean section according to obstetric indications. The intracranial procedure should be resumed after delivery.
3. Oxytocin is used to control uterine bleeding after delivery. The safety of oxytocin in patients with SAH is not clear. However, oxytocin can cause maternal hypertension, and it does appear to have effects on cerebral vasoconstrictive effects.^{590,591} Therefore, the authors of this handbook prefer to avoid the use of oxytocin in patients with SAH when possible, particularly if the ruptured aneurysm has not yet been treated or if the patient is felt to be at significant risk of vasospasm. A neonatologist or a pediatric intensivist should be available for care of the anesthetized infant.^{566,568}

OUTCOMES

Dias and Sekhar found the overall maternal mortality rate from aneurysmal subarachnoid hemorrhage to be 35%,⁵⁶⁹ which is similar to that of the nonpregnant population. The fetal mortality rate was 17%.

13.5.3. Elderly patients with aneurysms

Elderly patients are defined by most authors as those who are ≥ 70 years of age.

13.5.3.1. Unruptured aneurysms in the elderly

1. As life expectancy increases and noninvasive imaging becomes less expensive and more widespread, unruptured aneurysms are being identified in greater numbers of older patients.
2. Surgical outcomes are related to age.⁵⁹² Although a systematic review of surgical series published between 1966 and 1996 did not find a significant relationship between age and surgical outcomes,¹¹⁹ other studies have found advanced age to be a predictor of poor outcome after surgery for unruptured aneurysms.¹²¹ ISUIA found that poor outcomes in patients having surgery for unruptured aneurysms increased in frequency with each decade of life beginning at age 50.⁹⁹ At age ≥ 70 , poor outcome, defined as death, a Rankin score between 3 and 5, or impaired cognitive status, occurred in about 30% of patients:
 - (a) In a single-center series of elderly patients being treated for unruptured aneurysms, 6-month outcomes were: excellent, 70%; good, 15%; fair, 5%; poor, 7.5%; and death, 2.5%.⁵⁹³
3. Endovascular treatment appears to be better tolerated in elderly patients than surgery. Single-center series of endovascular treatment of unruptured aneurysms in elderly patients have reported outcomes that are comparable to outcomes in younger patients.^{594,595} In a series of 22 elderly endovascular patients, 20 (91%) had excellent outcomes (modified Rankin Scale score 0 or 1).⁵⁹⁵
 - (a) Although an effect of age similar to that of surgery was not found in the endovascular group in ISUIA, the size of the endovascular cohort (451 patients) was much smaller than the surgical group (1,917 patients), and therefore the size of the group may have been too small to detect a statistically significant effect.
 - (b) An advantage of treating elderly patients with endovascular techniques is that long-term outcome may be less important than in younger patients, given a shorter overall life expectancy.⁵⁹⁴
4. Decision making in elderly patients with an unruptured aneurysm should take into account the life expectancy of the patient (see [Table 13.5](#)), a realistic estimate of the risk of rupture, and an estimate of morbidity and mortality with treatment. Good results can be obtained both with surgery and with endovascular treatment in carefully selected patients.⁵⁹³ The authors of this handbook favor endovascular treatment when possible and reserve serious consideration of treatment of unruptured aneurysms in elderly patients to those who are relatively healthy, with an aneurysm that is large, symptomatic, in the posterior circulation, or found to be enlarging on serial imaging.

13.5.3.2. Subarachnoid hemorrhage in the elderly

1. Increasing life expectancy in recent years has translated into a larger percentage of SAH patients who are elderly.⁵⁹⁶
2. Outcome is strongly related to age in patients with SAH.^{594,597,598}
 - (a) In a series consisting of both surgical and endovascularly treated SAH patients, 21% of elderly patients were independent at discharge.⁵⁹⁹
 - (b) In a study of case fatality rates over time, improvements in survival among younger patients with SAH were offset by increasing numbers of elderly patients, who have not experienced a similar improvement in outcome.⁵⁹⁶
 - (c) Interestingly, Japanese studies have consistently reported better results in elderly patients, even among patients age ≥ 80 .^{598,600,601}
3. Among the elderly, poor-grade patients (Hunt–Hess 4 or 5) do very poorly:^{598,599,602}
 - (a) In recent studies of elderly patients treated with endovascular techniques, 77% of poor-grade patients had a very poor outcome (modified Rankin Scale score, 4–5). Similarly, in another series, 62% of patients were severely disabled or dead.⁶⁰³
4. In endovascular series, a significant percentage of good-grade elderly patients with SAH have had good outcomes. In one series, 89% of the patients with low-grade SAH (Hunt and Hess Grade 1 or 2) achieved excellent outcomes (modified Rankin Scale score, 0–1).⁵⁹⁵
5. The authors favor endovascular treatment for good-grade elderly patients with SAH. Poor-grade patients are candidates for endovascular treatment provided that the patient's family understands that the chance of a good outcome is low.

13.5.4. Infectious aneurysm

The first report of an infectious intracranial aneurysm appeared in 1869 and described a 13-year-old boy with mitral valve endocarditis.⁶⁰⁴ Although *mycotic* is synonymous with *fungus*, the term *mycotic aneurysm* is a colloquialism for all infectious aneurysms and is attributed to William Osler, who used it to refer to an aortic aneurysm that arose in the setting of bacterial endocarditis.⁶⁰⁵

13.5.4.1. Epidemiology and Etiology

1. In autopsy series, infectious aneurysms comprise some 2.6–6% of all intracranial aneurysms in adults,⁶⁰⁶ although a recent report from a busy cerebrovascular center found that infectious aneurysms accounted for less than 1% of all treated aneurysms.⁶⁰⁷ Infectious aneurysms seem to be somewhat more common in children, comprising some 2–10% of reported cases of intracranial aneurysms in children.^{554,608}
2. Some 65–80% of patients with intracranial infectious aneurysms have endocarditis:^{607,609}
 - (a) Conversely, infectious aneurysms occur in 3–15% of patients with infectious endocarditis.^{610,611}
 - (b) Other predisposing medical conditions are meningitis, cavernous sinus thrombophlebitis, osteomyelitis of the skull, and sinus infections.⁶¹²
3. Some 75% of infectious aneurysms present with rupture, and 70% are found in the middle cerebral artery territory.⁶⁰⁷ Multiple lesions are found in 20% of patients.⁶¹³
4. *Streptococcal* species are the most common cause of infectious aneurysms, and *staphylococcus* species are the second most common cause. In a recent series, blood cultures identified *Streptococcus viridans* in 37.5% and *Staphylococcus aureus* in 18.7%.⁶¹¹ Other pathogens include enterococci, *Pseudomonas*, and corynebacteria. An organism is not identified in some 12–19% of cases:^{613,614}
 - (a) Most bacterially infectious aneurysms occur as the result of intravascular seeding. The infection appears to begin in the adventitia and move inward, toward the intimal surface. This pattern has led to speculation that infectious dissemination begins in the Virchow–Robin spaces of small penetrating vessels.⁶¹⁵

- (b) Infectious aneurysms are typically friable, fusiform in shape, and difficult to separate from surrounding brain parenchyma.
- 5. Intracranial fungal aneurysms are rare, and usually occur in immunocompromised patients. *Aspergillus* is the most common fungal pathogen, followed by *Phycomycetes* and *Candida albicans*. Aspergillosis of the intracranial space can occur by direct extension from the paranasal sinuses or by hematogenous spread from the lungs.⁶¹⁶

13.5.4.2. Management

An algorithm for the management of infectious aneurysms is provided in [Fig. 13.6](#)

1. Antibiotic therapy is first-line treatment for most unruptured infectious aneurysms, and for patients with hemorrhage who do not require urgent surgery.
2. Specimens for blood culture should be obtained prior to the initiation of antibiotic therapy, to permit later speciation and modification of the antibiotic regimen:
 - (a) CSF cultures are usually *not* helpful in identifying pathogens in patients with infectious aneurysms caused by hematogenous spread, as they are often negative despite an active infection.^{611,617}
3. The diagnosis can usually be made based on CT findings and the clinical situation. Catheter angiography is necessary to affirm the diagnosis, clarify anatomy, and to look for other possible lesions.
4. A prolonged course of antibiotics is usually necessary, for at least 4–6 weeks:
 - (a) Infectious aneurysms may continue to decrease in size after discontinuation of antibiotic therapy.⁶¹⁸
5. Surgery:
 - (a) Surgery should be reserved for hemorrhagic lesions that are surgically accessible, or for lesions that persist or enlarge with conservative management.
 - (b) A course of antibiotic therapy will permit fibrosis of the aneurysm wall to occur and may make surgery more feasible.⁶¹⁹
 - (c) The surgical strategy can consist of trapping and resection, trapping and bypass, clipping, or wrapping.⁶⁰⁷
6. Endovascular therapy for intracranial infectious aneurysms has been reported. Reported strategies include embolization of the aneurysm, or provocative testing followed by endovascular occlusion of the parent vessel.^{620,621} Endovascular treatment is appropriate for lesions that are poorly accessible by surgery, or for patients who are poor surgical candidates. The fragility of these aneurysms and the adjacent vessels may increase the risk of endovascular techniques.⁶²¹ A theoretical drawback to endovascular treatment is the threat of trapping, or sequestering bacteria within the lesion, making them less accessible to systemic antibiotic therapy, although this phenomenon has not been reported.
7. Radiographic follow-up. Infectious aneurysms may shrink, stabilize, or enlarge despite antibiotic therapy and even surgery, necessitating routine radiographic follow-up. Some authors have recommended serial angiography as frequently as 7 days, 14 days, 1 month, 3 months, and 1 year after the initiation of therapy.⁶¹⁴ The authors of this handbook prefer to use noninvasive imaging, such as CTA, for surveillance imaging after treatment, with at least one follow-up catheter angiogram after completion of treatment to ensure resolution of the lesion.

13.5.4.3. Outcomes

1. Historical mortality rates have approached 40%.⁶¹⁴
2. Recent series have reported an overall mortality rate of 10–18.7%,^{607,611} with good outcomes occurring in 80% of cases.⁶⁰⁷
 - (a) Infectious aneurysms of the cavernous segment of the ICA seem to carry the best prognosis, only one death and one poor outcome have been reported in a series of 18 patients.^{614,622}
3. Fungal aneurysms carry a worse prognosis, with mortality rates of 85–90%.⁶¹⁶

13.5.5. Giant aneurysms

Giant intracranial aneurysms are, by definition, ≥ 25 mm in diameter. The first report of a giant aneurysm was in 1875; the lesion was diagnosed by an audible bruit.⁶²³ Giant aneurysm morphology may be saccular or fusiform, and the lesions

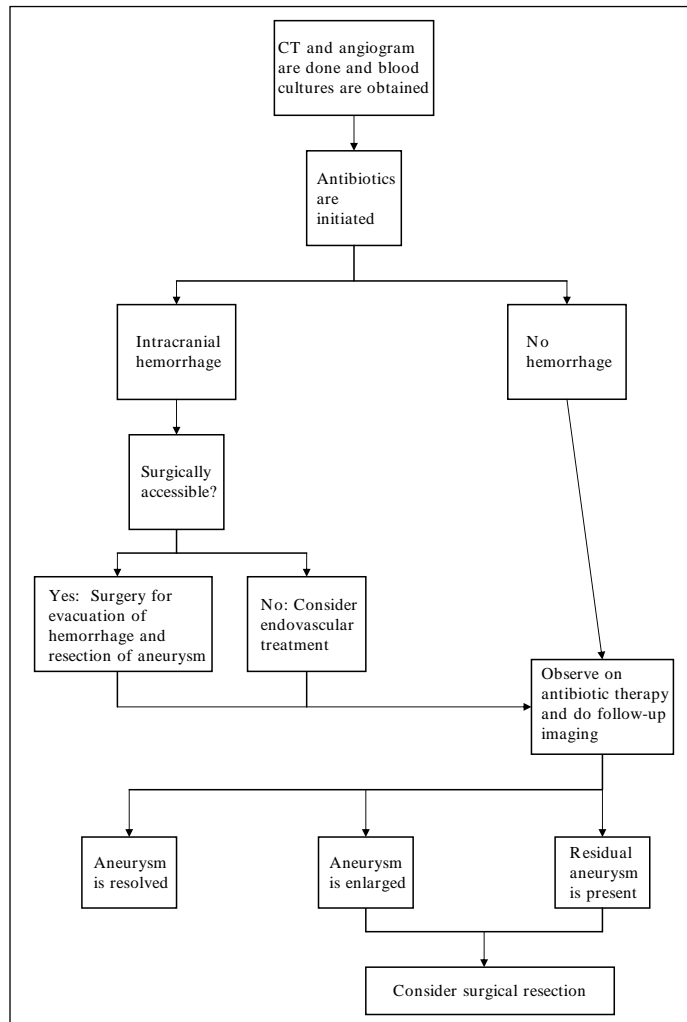


Fig. 13.6 Treatment algorithm for infectious intracranial aneurysms. Adapted from Neurosurgery, 51:1145-51, Phuong LK, Link M, Wijdicks E: "Management of intracranial infectious aneurysms: a series of 16 cases." © 2002 Lippincott Williams & Wilkins, with permission.

seem to have a propensity for the posterior circulation, occurring in the vertebro-basilar system in about a third of cases.⁶²⁴ The presence of intraluminal thrombus is common. Giant aneurysms are thought to form via several different mechanisms. In smaller aneurysms destined to become giant ones, damage to the endothelium and internal elastic lamina and stagnant flow may induce mural thrombus formation, followed by scarring and further weakening of the wall. The presence of a thrombus may exacerbate turbulent flow, cause further damage to the aneurysm wall and increase

wall shear stress. These aneurysms may also grow because of recurrent hemorrhage within the wall of the aneurysm; the highly vascular wall of a giant aneurysm may behave like a growing encapsulated chronic subdural hematoma.^{625,626} In addition, intrathrombotic capillary channels may also be an important factor in the growth of thrombosed giant aneurysms.⁶²⁷

13.5.5.1. Epidemiology

1. Giant aneurysms comprise ~5% of all intracranial aneurysms.^{628,629}
2. They typically present in the fifth to seventh decade of life.^{628,630}
3. They are slightly more common in women.⁶²⁸

13.5.5.2. Presentation

1. Approximately one third to one half of patients with giant aneurysms present with SAH.^{628,631,632}
2. Some 50–70% of patients present with mass effect or brain edema caused by intraluminal thrombosis.^{628,632,633}
 - (a) It is important to note that an acute thrombus within an aneurysm can promote vasogenic edema in surrounding brain tissue just like an intracerebral hematoma.
3. About 8% of patients present with thromboembolic symptoms from an intraluminal thrombus.⁶²⁸
4. Hypothalamic⁶³⁴ or frontal lobe dysfunction⁶³⁵ is also present in some patients.
5. Most giant aneurysms arise from the ICA, MCA, or vertebrobasilar system. Giant aneurysms of the ACA are rare:
 - (a) In a series of 18 patients with giant ACA aneurysms, dementia was present in patients with aneurysms ≥ 3.5 cm in diameter, and was caused by direct brain compression rather than hydrocephalus.⁶³⁶ Optic apparatus compression was seen with smaller aneurysms (2.7–3.2 cm) when they pointed inferiorly.

13.5.5.3. Evaluation

1. CT and CTA can identify the dimensions of the lesion, the presence of intraluminal thrombus, calcification of the aneurysm wall, surrounding brain edema, as well as pertinent skull base anatomy, should surgery be anticipated.
2. Catheter angiography is complimentary to CTA and can demonstrate precise vascular anatomy, collateral circulation, and information about blood flow dynamics.

13.5.5.4. Natural history

1. Risk of rupture:
 - (a) ISUIA: The annual risk of rupture for giant aneurysms is substantial:⁹⁹
 - Anterior communicating artery/MCA/ICA: 8.0%.
 - Posterior circulation and P-comm: 10%.
 - Cavernous ICA: 1.28%.
 - (b) Early series of patients with untreated giant aneurysms reported mortality rates of 75–100% within 2–5 years.^{637,638}
 - (c) The risk of rehemorrhage after an initial SAH may be similar to that of smaller aneurysms; in a recent series the cumulative risk of rebleeding was 18.4% within 14 days of admission.³³⁹ Of those, one third died during the hospitalization.
2. In patients with SAH due to a ruptured giant aneurysm, the mortality rate is $>50\%$.⁶³⁹

13.5.5.5. Management

1. Medical management, consisting of blood pressure management, smoking cessation, and antiplatelet therapy – if symptoms attributable to intraluminal thrombosis are present – is appropriate for patients who are at high risk of

complications with surgical or endovascular treatment. Elderly patients or those with significant comorbidities or extremely complex lesions may be better off with a conservative approach.

2. Surgery. An array of surgical strategies exist for giant aneurysms, including clipping, trapping with or without a bypass, proximal occlusion, and graduated surgical occlusion of the cervical common carotid artery (e.g., placement of a Selverstone clamp) to reduce flow to the lesion and promote thrombosis. Additional surgical techniques include hypothermic cardiac arrest and various skull base approaches.
3. Endovascular techniques:
 - (a) Parent vessel sacrifice.^{640,641} Endovascular sacrifice of the vessel is an established approach for the treatment of giant aneurysms. A balloon test occlusion is usually necessary for carotid lesions.
 - (b) Primary coiling.^{632,640,642} Occlusion of a giant aneurysm by coil embolization is an option but is typically problematic, particularly for very large aneurysms or when intraluminal thrombus is present. Giant aneurysms require a large number of coils for complete embolization, larger aneurysms are prone to recur after coiling, and, if a thrombus is present, the coil mass can sink into the clot following embolization like a Cadillac parked in the sand at the beach:
 - Most operators recommend parent vessel sacrifice over primary coiling as the first endovascular option for giant aneurysms. In two endovascular series, hemorrhage occurred after coiling in 33%⁶⁴³ and 6.4%⁶³² of patients, whereas no hemorrhages occurred after parent vessel sacrifice.
 - (c) Stent-assisted coiling.⁶⁴⁴ Some wide-necked giant saccular aneurysms and fusiform aneurysms can be treated with stent-assisted coiling.
 - (d) Covered stent.⁶⁴⁵ Covered stents (also known as “stent-grafts”) have been used for the treatment of giant and fusiform aneurysms.

13.5.6. Dissecting intracranial aneurysms

Spontaneously dissecting aneurysms are uncommon (traumatic dissecting aneurysms are considered below), but are distinctly different from more common saccular aneurysms. Dissecting aneurysms also have specific characteristics that distinguish them from lesions that may have similar radiographic features, such as fusiform and dolichoectatic aneurysms. The majority of the literature about dissecting aneurysms is from Japan, although it is not clear whether these lesions are actually more common among the Japanese population, or just more often written about.

13.5.6.1. Clinical features

1. In contrast to saccular aneurysms, dissecting aneurysms have a strong male preponderance.⁶⁴⁶
2. Also in distinction to saccular aneurysms, the vast majority of dissecting aneurysms occur in the vertebrobasilar circulation rather than the anterior circulation. In a Japanese nationwide study of 322 dissecting aneurysms, 93% were vertebrobasilar lesions and 7% were in the anterior circulation.⁶⁴⁶
 - (a) Among anterior circulation cases, ACA lesions are more common than MCA.⁶⁴⁷
3. *Presentation:*
 - (a) In contrast to most fusiform and dolichoectatic aneurysms, the evolution and presentation of a dissecting aneurysm is an acute and progressive process.⁶⁴⁸
 - (b) The most common presentation is SAH, occurring in 53% of patients in the Japanese nationwide study.⁶⁴⁶
 - (c) Cerebral ischemia or infarction is also a common mode of presentation. In a series of patients with lateral medullary infarction (Wallenberg syndrome), 18% were attributable to intracranial vertebral artery dissection.⁶⁴⁹ In anterior circulation cases, presentation with ischemic symptoms are more common than hemorrhage.^{646,647}
4. *Radiographic appearance:*
 - (a) Dissecting aneurysms often arise from an arterial trunk, such as the vertebral or basilar arteries or the ICA, in contrast to saccular aneurysms, which usually arise from arterial branch points.

- (b) Dissecting aneurysms are typically irregular structures, often including a narrow tapered parent vessel lumen associated with proximal or distal focal dilatation (“pearl and string” sign). Arterial occlusion, an intimal flap, a double lumen, extension of the aneurysm into distal branches, and retention of contrast material into the late venous phase are also angiographic features of dissecting aneurysms.^{274,650}
 - (c) The single pathognomonic sign of a dissecting aneurysm is a double lumen.⁶⁵¹
 - (d) On MRI, enhancement of the dissecting aneurysm with gadolinium is seen in 95% of cases.⁶⁵²
5. *Pathogenesis:*
- (a) Dissecting aneurysms result primarily by a sudden disruption of the internal elastic media.⁶⁵³
 - (b) Compared to the extradural arteries, normal intradural arteries have a thin media and adventitia with relatively few elastic fibers, making them more vulnerable to dissection, hemorrhage, and pseudoaneurysm formation.⁶⁵⁴ Also, intracranial arteries have diminished vasa vasorum, which may limit healing.⁶⁵⁵
 - (c) Dissecting aneurysms are dynamic lesions, with evolution of the angiographic appearance characteristically occurring over 2–3 months.
 - (d) Most spontaneous dissecting aneurysms are idiopathic, although associated risk factors include atherosclerosis, hypertension, a history of tumor resection, aneurysm clipping, or head injury, mucoid degeneration of the media, syphilis, migraines, fibromuscular dysplasia, homocystinuria, strenuous physical exertion, periarteritis nodosa, moyamoya disease, Guillain–Barré syndrome, and Marfan syndrome.^{647,656}

13.5.6.2. Management

1. Hemorrhagic dissecting aneurysms:
 - (a) The risk of rebleeding for ruptured dissecting aneurysms is significant, and may be higher than that for saccular aneurysms. In a series of 31 patients with ruptured vertebrobasilar dissecting aneurysms managed either with or without surgery, the rate of rebleeding was 71.4%, with an associated mortality rate of 46.7%.⁶⁵⁷
 - (b) Treatment of dissecting aneurysms is controversial; although most agree that either surgery or endovascular treatment to prevent rebleeding is critical. In a series of ruptured dissecting aneurysms, the mortality rate in the treated group was 20%, whereas that in the untreated group was 50%.²⁷⁰
 - Surgical techniques include proximal occlusion of the parent vessel, trapping of the lesion, and wrapping. When sacrifice of a portion of a vessel with critical branches is anticipated, surgical bypass may be necessary. Clipping of the aneurysm at the neck, as is done with saccular aneurysms, is generally not feasible.
 - Primary endovascular options include proximal occlusion and parent vessel occlusion.^{270,658} Stent placement for the treatment of dissecting aneurysms has also been reported.^{659,660}
 - Recent endovascular series have reported favorable results. A recent series of 29 patients reported overall morbidity and mortality rates of 13.8 and 17.2%, respectively.⁶⁵⁸
2. Nonhemorrhagic dissecting aneurysms:
 - (a) For symptomatic dissecting aneurysms without hemorrhage, conservative management may be the best option. In the Japanese nationwide study, the majority of nonhemorrhagic dissecting aneurysms were managed without surgery or intervention, and a good recovery (by Glasgow outcome scale) was achieved in 79% of patients.⁶⁴⁶

13.5.7. Dolichoectatic, fusiform and serpentine aneurysms

Dolichoectatic and fusiform aneurysms are uncommon, accounting for <2% of all intracranial aneurysms.^{661–663} The term *serpentine aneurysm* generally refers to giant dolichoectatic aneurysms filled largely with thrombus;⁶⁶⁴ these lesions are also very

uncommon. One school of thought holds that small fusiform aneurysms and giant serpentine aneurysms are part of a spectrum of the same pathological process, although this notion is controversial. Common to all of these aneurysms is a nonsaccular shape and the pathological involvement of a length of artery with separate inflow and outflow sites.⁶⁶⁵ The carotid and vertebrobasilar systems appear to be affected almost equally.^{662,663,665} Hypertension is strongly associated with these lesions.^{666,667}

13.5.7.1. Presentation

Symptoms may arise from compression of neural structures, cerebral ischemia, or rupture.⁶⁶⁵ Compression and ischemia are the most common causes of symptoms.^{666,668-670} Cranial nerve dysfunction appears in multiple reports, as do symptoms from brainstem compression. In a series of 132 patients with "megadolichovertebrobasilar anomaly," 31% of patients had symptoms attributable to brainstem or cerebellar compression.⁶⁷¹ Hydrocephalus can occur in patients with basilar artery dolichoectasia.^{666,672} Ischemic symptoms occurred in 25% of patients in one series,⁶⁶⁵ and can result from obstruction of perforating vessels or embolization of intraluminal thrombus. Compared to saccular aneurysms, rupture is relatively uncommon as a presenting symptom, occurring in 18–40% of patients.^{661,665,666,668}

13.5.7.2. Pathogenesis

Intracranial fusiform aneurysms can be divided into two types: acute dissecting aneurysms and chronic fusiform or dolichoectatic aneurysms.⁶⁷³ Arterial dissection is thought to be a factor in the formation of a significant percentage of fusiform intracranial aneurysms, particularly those without elongation or tortuosity of the parent vessel.^{654,674,675} An acute dissection may be the inciting event in the pathogenesis of chronic fusiform aneurysms.⁶⁶³ A series of four cases of dolichoectasia were found on MRI imaging to be dissections with aneurysmal dilation.⁶⁷⁶

Atherosclerosis, formerly thought to be an important factor in dolichoectasia, may not be a common feature of these lesions. Pathological studies of dolichoectatic aneurysms have found atherosclerosis to be absent or not a significant finding.^{673,677} However, defects in the internal elastic lamina are a consistent pathological finding in most dolichoectatic aneurysms.^{665,677-679} Chronic fusiform and dolichoectatic aneurysms may actually be progressive lesions that begin with fragmentation of the internal elastic lamina, followed by neoangiogenesis within a thickened intima, intramural thrombus formation, and repetitive intramural hemorrhage from newly formed vessels within the thrombus.⁶⁷³

13.5.7.3. Natural history

Most natural history data pertain to vertebrobasilar dolichoectasia. A cohort study of 45 patients with vertebrobasilar dolichoectasia found an increased risk of stroke in affected patients (OR = 3.6, $p = 0.018$).⁶⁸⁰ In a prospective study of 159 patients with vertebrobasilar fusiform aneurysms or dolichoectasia, the 1-, 5-, and 10-year risk of cerebral infarction due to the vertebral artery lesion was 2.7, 11.3, and 15.9%, respectively.⁶⁷⁰ The risk of recurrent ischemic symptoms was 6.7% per patient year. Median survival was 7.8 years and death was most commonly due to ischemia. In a prospective study of hemorrhage risk with a mean follow-up 4.4 years, the annual rupture rate was 0.9% overall and 2.3% in those with transitional or fusiform aneurysm subtypes.⁶⁶⁷ Evidence of aneurysm enlargement was a significant predictor of lesion rupture.

13.5.7.4. Management

Surgery or endovascular treatment is indicated for select patients with symptomatic lesions who are good candidates for a major intracranial procedure. Surgery of fusiform and dolichoectatic aneurysms can be complex. In some cases, the parent vessel can be reconstructed with a series of stacked fenestrated clips. Wrapping of fusiform aneurysms with cotton or some other material is of unclear benefit. Surgical trapping or proximal occlusions, with or without a bypass, and with or without debulking of the aneurysm are other options. Trapping is superior to proximal occlusion

when possible. Because of the rarity of these lesions, endovascular reports are limited to case reports and small series. Good results have been obtained with endovascular parent vessel occlusion^{641,681} and intravascular stenting combined with coiling.⁶⁴⁴ For cases that are managed conservatively, some authors advocate anticoagulation⁶⁶³ or antiplatelet therapy to minimize the risk of ischemic symptoms.⁶⁶⁶

13.5.8. Traumatic aneurysms and traumatic subarachnoid hemorrhage

13.5.8.1. Traumatic aneurysms

1. Traumatic aneurysms comprise <1% of all intracranial aneurysms,^{682,683} however they account for up to one third of all pediatric intracranial aneurysms.⁵⁶¹
2. Presentation:
 - (a) Traumatic aneurysms are commonly found after the appearance of delayed SAH after head injury, or unexplained neurological deterioration, epistaxis, cranial nerve palsy, or unexplained cortical bleeding.^{213,684,685}
 - (b) Traumatic aneurysms usually require a period of time to develop, ranging from 2⁶⁸⁵ to 3 weeks⁶⁸⁶ after the initial injury.
3. Diagnosis:
 - (a) A history of head injury is the main criterion for diagnosis.
 - (b) Typical angiographic features include a location in the peripheral vasculature, delayed filling and emptying of the aneurysm, an irregular contour, no visible neck, and a location separate from common arterial branch points.^{554,683,687}
4. Traumatic aneurysms can be divided into those arising from nonpenetrating head injury and those arising from penetrating head injury. Nonpenetrating head injury is a more common cause of traumatic aneurysms than penetrating injury:
 - (a) Nonpenetrating head injury:
 - Traumatic aneurysms due to nonpenetrating head injury usually result from rapid deceleration, causing sudden brain movement and vessel wall injury from stationary structures. Injury to the pericallosal artery by the edge of the falx accounts for the finding that distal ACA is the most common location for traumatic aneurysms in children.⁵⁶¹
 - The majority of traumatic aneurysms are found in the anterior circulation. A review published in 2002 found only 21 reports of posterior circulation traumatic aneurysms in the English language literature.⁶⁸⁸
 - Skull fractures are a harbinger of traumatic aneurysms, and are present in some 90% of traumatic intracranial aneurysms.⁶⁸³ Cortical traumatic aneurysms may appear adjacent to calvarial fractures,⁶⁸⁹ and traumatic aneurysms of the petrous or cavernous ICA are almost always associated with basilar skull fractures.^{685,690,691}
 - In a series of 55 patients with carotid canal fractures, ICA injury was found in six cases, two of which were traumatic aneurysms.⁶⁹²
 - (b) Penetrating head injury:
 - Traumatic aneurysms due to penetrating injury may appear as early as 2h after the injury, and appear most frequently on peripheral branches of the middle cerebral artery, and less often on the pericallosal artery.⁶⁹³ Posterior circulation aneurysms are rare, probably because penetrating trauma to that part of the head is often fatal.
 - Some 20% of these lesions are multiple.⁶⁹³
5. Management:
 - (a) Obliteration of the aneurysm or sacrifice of the parent vessel is recommended for patients with traumatic intracranial aneurysms. Conservative management is associated with a mortality rate of nearly 50%,^{561,683,694} and death is three times less likely if a traumatic aneurysm

- is identified before a hemorrhage has occurred, compared with diagnosis after rupture.²³¹
- (b) Clinical series of endovascular test occlusion followed by sacrifice of the parent vessel have reported favorable results.^{685,695}
 - (c) Both surgical and endovascular techniques can be necessary for the management of aneurysms due to penetrating trauma.⁶⁹⁶

13.5.8.2. Traumatic subarachnoid hemorrhage

Trauma is the single most common cause of SAH. Subarachnoid hemorrhage occurs in 33–60% of patients with traumatic brain injury⁶⁹⁷⁻⁶⁹⁹ and is associated with worse outcomes.^{698,700} However, it is not clear whether the finding of traumatic SAH on CT is an independent risk factor for poor outcomes, as good outcomes have been reported in >90% of patients with *mild* head injury and SAH on CT.^{701,702} Although some data from angiography, TCD measurements, and CBF studies indicate that vasospasm occurs in patients with head injury less frequently or as frequently as patients with aneurysmal SAH,^{703,704} other studies indicate that the incidence of vasospasm in head injury patients is low and does not lead to ischemic brain injury.^{705,706} Moreover, assessment of the effects of vasospasm in head injury is confounded by the array of brain injuries attributable to the trauma itself. Several trials have evaluated the efficacy of calcium channel blockers in traumatic brain injury. A systematic review of six randomized controlled trials found a benefit in unfavorable outcomes (odds ratio 0.67, 95% CI 0.46–0.98),⁷⁰⁷ although increased adverse reactions in the treated groups may offset the benefit. Published endovascular management of vasospasm after traumatic SAH is limited to a case report describing papaverine infusion in this setting.⁷⁰⁸

13.6. References

1. Abruzzo T, Shengelaia GG, Dawson RC, 3rd, Owens DS, Cawley CM, Gravanis MB. Histologic and morphologic comparison of experimental aneurysms with human intracranial aneurysms. *AJNR Am J Neuroradiol* 1998;19(7):1309-14.
2. Walker AE, Allegre GW. The pathology and pathogenesis of cerebral aneurysms. *J Neuropathol Exp Neurol* 1954;13(1):248-59.
3. Suzuki J, Ohara H. Clinicopathological study of cerebral aneurysms. Origin, rupture, repair, and growth. *J Neurosurg* 1978;48(4):505-14.
4. Krings T, Piske RL, Lasjaunias PL. Intracranial arterial aneurysm vasculopathies: targeting the outer vessel wall. *Neuroradiology* 2005;47(12):931-7.
5. Hashimoto T, Meng H, Young WL. Intracranial aneurysms: links among inflammation, hemodynamics and vascular remodeling. *Neurol Res* 2006;28(4):372-80.
6. Hademenos GJ, Massoud TF, Turjman F, Sayre JW. Anatomical and morphological factors correlating with rupture of intracranial aneurysms in patients referred for endovascular treatment. *Neuroradiology* 1998;40(11):755-60.
7. Crompton MR. Mechanism of growth and rupture in cerebral berry aneurysms. *Br Med J* 1966;5496:1138-42.
8. Unruptured intracranial aneurysms—risk of rupture and risks of surgical intervention. International Study of Unruptured Intracranial Aneurysms Investigators. *N Engl J Med* 1998;339(24):1725-33.
9. Bjorksten G, Halonen V. Incidence of intracranial vascular lesions in patients with subarachnoid hemorrhage investigated by four-vessel angiography. *J Neurosurg* 1965;23(1):29-32.
10. Qureshi AI, Suarez JJ, Parekh PD, et al. Risk factors for multiple intracranial aneurysms. *Neurosurgery* 1998;43(1):22-6; discussion 6-7.
11. Ellamushi HE, Grieve JP, Jager HR, Kitchen ND. Risk factors for the formation of multiple intracranial aneurysms. *J Neurosurg* 2001;94(5):728-32.
12. Juvela S. Risk Factors for Multiple Intracranial Aneurysms. *Stroke* 2000;31(2):392-7.
13. Kaminogo M, Yonekura M, Shibata S. Incidence and Outcome of Multiple Intracranial Aneurysms in a Defined Population. *Stroke* 2003;34(1):16-21.
14. Nehls DG, Flom RA, Carter LP, Spetzler RF. Multiple intracranial aneurysms: determining the site of rupture. *J Neurosurg* 1985;63(3):342-8.
15. Stehbens W. In: Pathology of the Cerebral Blood Vessels. St. Louis: Mosby; 1972:351-470.
16. Marshman LA, Ward PJ, Walter PH, Dossetor RS. The progression of an infundibulum to aneurysm formation and rupture: case report and literature review. *Neurosurgery* 1998;43(6):1445-8; discussion 8-9.
17. Rinkel GJE, Djibuti M, Algra A, van Gijn J. Prevalence and Risk of Rupture of Intracranial Aneurysms: A Systematic Review. *Stroke* 1998;29(1):251-6.
18. Lozano AM, Leblanc R. Familial intracranial aneurysms. *J Neurosurg* 1987;66(4):522-8.
19. Ronkainen A, Hernesniemi J, Puranen M, et al. Familial intracranial aneurysms. *Lancet* 1997;349(9049):380-4.
20. De Braekeleer M, Perusse L, Cantin L, Bouchard JM, Mathieu J. A study of inbreeding and kinship in intracranial aneurysms in the Saguenay Lac-Saint-Jean region (Quebec, Canada). *Ann Hum Genet* 1996;60 (Pt 2):99-104.
21. Norgard O, Angquist KA, Fodstad H, Forsell A, Lindberg M. Intracranial aneurysms and heredity. *Neurosurgery* 1987;20(2):236-9.
22. Schievink WI, Schaid DJ, Michels VV, Piepgras DG. Familial aneurysmal subarachnoid hemorrhage: a community-based study. *J Neurosurg* 1995;83(3):426-9.
23. Schievink WI, Schaid DJ, Rogers HM, Piepgras DG, Michels VV. On the inheritance of intracranial aneurysms. *Stroke* 1994;25(10):2028-37.
24. Bromberg JE, Rinkel GJ, Algra A, et al. Familial subarachnoid hemorrhage: distinctive features and patterns of inheritance. *Ann Neurol* 1995;38(6):929-34.
25. Ruigrok YM, Rinkel GJE, Algra A, Raaymakers TWM, van Gijn J. Characteristics of intracranial aneurysms in patients with familial subarachnoid hemorrhage. *Neurology* 2004;62(6):891-4.

26. Bromberg JE, Rinkel GJ, Algra A, Limburg M, van Gijn J. Outcome in familial subarachnoid hemorrhage. *Stroke* 1995;26(6):961-3.
27. Yamada S, Utsunomiya M, Inoue K, et al. Genome-Wide Scan for Japanese Familial Intracranial Aneurysms: Linkage to Several Chromosomal Regions. *Circulation* 2004;110(24):3727-33.
28. Ruigrok YM, Seitz U, Wolterink S, Rinkel GJE, Wijmenga C, Urban Z. Association of Polymorphisms and Haplotypes in the Elastin Gene in Dutch Patients With Sporadic Aneurysmal Subarachnoid Hemorrhage. *Stroke* 2004;35(9):2064-8.
29. Schievink WI. Genetics of intracranial aneurysms. *Neurosurgery* 1997;40(4):651-62; discussion 62-3.
30. Bederson JB, Awad IA, Wiebers DO, et al. Recommendations for the Management of Patients With Unruptured Intracranial Aneurysms: A Statement for Healthcare Professionals From the Stroke Council of the American Heart Association. *Stroke* 2000;31(11):2742-50.
31. Brown BM, Soldevilla F. MR angiography and surgery for unruptured familial intracranial aneurysms in persons with a family history of cerebral aneurysms. *AJR Am J Roentgenol* 1999;173(1):133-8.
32. Ronkainen A, Puranen MI, Hernesniemi JA, et al. Intracranial aneurysms: MR angiographic screening in 400 asymptomatic individuals with increased familial risk. *Radiology* 1995;195(1):35-40.
33. Raaymakers TW, Rinkel GJ, Ramos LM. Initial and follow-up screening for aneurysms in families with familial subarachnoid hemorrhage. *Neurology* 1998;51(4):1125-30.
34. Broderick JP, Sauerbeck LR, Foroud T, et al. The Familial Intracranial Aneurysm (FIA) study protocol. *BMC Med Genet* 2005;6:17.
35. Schievink WI. Genetics of intracranial aneurysms. In: Winn HR, ed. *Youmans Neurological Surgery*. Fifth ed. Philadelphia: Saunders; 2004:1769-79.
36. Iglesias CG, Torres VE, Offord KP, Holley KE, Beard CM, Kurland LT. Epidemiology of adult polycystic kidney disease, Olmsted County, Minnesota: 1935-1980. *Am J Kidney Dis* 1983;2(6):630-9.
37. Hughes J, Ward CJ, Peral B, et al. The polycystic kidney disease 1 (PKD1) gene encodes a novel protein with multiple cell recognition domains. *Nat Genet* 1995;10(2):151-60.
38. Mochizuki T, Wu G, Hayashi T, et al. PKD2, a gene for polycystic kidney disease that encodes an integral membrane protein. *Science* 1996;272(5266):1339-42.
39. Arnaout MA. The vasculopathy of autosomal dominant polycystic kidney disease: insights from animal models. *Kidney Int* 2000;58(6):2599-610.
40. Badani KK, Hernal AK, Menon M. Autosomal dominant polycystic kidney disease and pain - a review of the disease from aetiology, evaluation, past surgical treatment options to current practice. *J Postgrad Med* 2004;50(3):222-6.
41. Chapman AB, Johnson AM, Gabow PA. Intracranial aneurysms in patients with autosomal dominant polycystic kidney disease: how to diagnose and who to screen. *Am J Kidney Dis* 1993;22(4):526-31.
42. Bobrie G, Brunet-Bourgin F, Alamowitch S, et al. Spontaneous artery dissection: is it part of the spectrum of autosomal dominant polycystic kidney disease? *Nephrol Dial Transplant* 1998;13(8):2138-41.
43. Schievink WI, Torres VE, Wiebers DO, Huston J, 3rd. Intracranial arterial dolichoectasia in autosomal dominant polycystic kidney disease. *J Am Soc Nephrol* 1997;8(8):1298-303.
44. Schievink WI, Huston J, 3rd, Torres VE, Marsh WR. Intracranial cysts in autosomal dominant polycystic kidney disease. *J Neurosurg* 1995;83(6):1004-7.
45. Schievink WI, Torres VE. Spinal meningeal diverticula in autosomal dominant polycystic kidney disease. *Lancet* 1997;349(9060):1223-4.
46. Wijidicks EF, Torres VE, Schievink WI. Chronic subdural hematoma in autosomal dominant polycystic kidney disease. *Am J Kidney Dis* 2000;35(1):40-3.
47. Chapman AB, Rubinstein D, Hughes R, et al. Intracranial aneurysms in autosomal dominant polycystic kidney disease. *N Engl J Med* 1992;327(13):916-20.
48. Huston J, 3rd, Torres VE, Sullivan PP, Offord KP, Wiebers DO. Value of magnetic resonance angiography for the detection of intracranial aneurysms in autosomal dominant polycystic kidney disease. *J Am Soc Nephrol* 1993;3(12):1871-7.
49. Fehlings MG, Gentili F. The association between polycystic kidney disease and cerebral aneurysms. *Can J Neurol Sci* 1991;18(4):505-9.
50. Schievink WI, Torres VE, Piepgras DG, Wiebers DO. Saccular intracranial aneurysms in autosomal dominant polycystic kidney disease. *J Am Soc Nephrol* 1992;3(1):88-95.
51. Schievink WI. Intracranial aneurysms. *N Engl J Med* 1997;336(1):28-40.
52. Ruggieri PM, Poulos N, Masaryk TJ, et al. Occult intracranial aneurysms in polycystic kidney disease: screening with MR angiography. *Radiology* 1994;191(1):33-9.
53. Prison Y, Chauveau D, Torres V. Management of Cerebral Aneurysms in Autosomal Dominant Polycystic Kidney Disease. *J Am Soc Nephrol* 2002;13(1):269-76.
54. Chauveau D, Prison Y, Verellen-Dumoulin C, Macnicol A, Gonzalo A, Grunfeld JP. Intracranial aneurysms in autosomal dominant polycystic kidney disease. *Kidney Int* 1994;45(4):1140-6.
55. Belz MM, Fick-Brosnahan GM, Hughes RL, et al. Recurrence of intracranial aneurysms in autosomal-dominant polycystic kidney disease. *Kidney Int* 2003;63(5):1824-30.
56. Schrier RW, Belz MM, Johnson AM, et al. Repeat Imaging for Intracranial Aneurysms in Patients with Autosomal Dominant Polycystic Kidney Disease with Initially Negative Studies: A Prospective Ten-Year Follow-up. *J Am Soc Nephrol* 2004;15(4):1023-8.
57. Byers PH. Ehlers-Danlos syndrome type IV: a genetic disorder in many guises. *J Invest Dermatol* 1995;105(3):311-3.
58. Germain DP. Clinical and genetic features of vascular Ehlers-Danlos syndrome. *Ann Vasc Surg* 2002;16(3):391-7.
59. North KN, Whiteman DA, Pepin MG, Byers PH. Cerebrovascular complications in Ehlers-Danlos syndrome type IV. *Ann Neurol* 1995;38(6):960-4.
60. Mitsuhashi T, Miyajima M, Saitoh R, Nakao Y, Hishii M, Arai H. Spontaneous carotid-cavernous fistula in a patient with Ehlers-Danlos syndrome type IV—case report. *Neurol Med Chir (Tokyo)* 2004;44(10):548-53.
61. Freeman RK, Swegle J, Sise MJ. The surgical complications of Ehlers-Danlos syndrome. *Am Surg* 1996;62(10):869-73.
62. Schievink WI, Piepgras DG, Earnest Ft, Gordon H. Spontaneous carotid-cavernous fistulae in Ehlers-Danlos syndrome Type IV. Case report. *J Neurosurg* 1991;74(6):991-8.
63. DeMeo DL, Silverman EK. [alpha]1-Antitrypsin deficiency (middle dot) 2: Genetic aspects of [alpha]1-antitrypsin deficiency: phenotypes and genetic modifiers of emphysema risk. *Thorax* 2004;59(3):259-64.
64. Schievink WI, Katzmann JA, Piepgras DG, Schaid DJ. Alpha-1-antitrypsin phenotypes among patients with intracranial aneurysms. *J Neurosurg* 1996;84(5):781-4.
65. St Jean P, Hart B, Webster M, et al. Alpha-1-antitrypsin deficiency in aneurysmal disease. *Hum Hered* 1996;46(2):92-7.
66. Kissela BM, Sauerbeck L, Woo D, et al. Subarachnoid Hemorrhage: A Preventable Disease With a Heritable Component. *Stroke* 2002;33(5):1321-6.
67. Yoneyama T, Kasuya H, Akagawa H, et al. Absence of Alpha-1 Antitrypsin Deficiency Alleles (S and Z) in Japanese and Korean Patients With Aneurysmal Subarachnoid Hemorrhage. *Stroke* 2004;35(12):e376-8.
68. van den Berg JSP, Limburg M, Hennekam RCM. Is Marfan Syndrome Associated With Symptomatic Intracranial Aneurysms? *Stroke* 1996;27(1):10-2.
69. Conway JE, Hutchins GM, Tamargo RJ. Marfan Syndrome Is Not Associated With Intracranial Aneurysms. *Stroke* 1999;30(8):1632-6.
70. Iqbal A, Alter M, Lee SH. Pseudoxanthoma elasticum: a review of neurological complications. *Ann Neurol* 1978;4(1):18-20.

71. Munyer TP, Margulis AR. Pseudoxanthoma elasticum with internal carotid artery aneurysm. *AJR Am J Roentgenol* 1981;136(5):1023-4.
72. van den Berg JS, Hennekam RC, Cruysberg JR, et al. Prevalence of symptomatic intracranial aneurysm and ischaemic stroke in pseudoxanthoma elasticum. *Cerebrovasc Dis* 2000;10(4):315-9.
73. Stapf C, Mohr JP, Pile-Spellman J, et al. Concurrent arterial aneurysms in brain arteriovenous malformations with haemorrhagic presentation. *J Neurol Neurosurg Psychiatry* 2002;73(3):294-8.
74. Brown RD, Jr., Wiebers DO, Forbes GS. Unruptured intracranial aneurysms and arteriovenous malformations: frequency of intracranial hemorrhage and relationship of lesions. *J Neurosurg* 1990;73(6):859-63.
75. Redekop G, TerBrugge K, Montanera W, Willinsky R. Arterial aneurysms associated with cerebral arteriovenous malformations: classification, incidence, and risk of hemorrhage. *J Neurosurg* 1998;89(4):539-46.
76. Meisel HJ, Mansmann U, Alvarez H, Rodesch G, Brock M, Lasjanias P. Cerebral arteriovenous malformations and associated aneurysms: analysis of 305 cases from a series of 662 patients. *Neurosurgery* 2000;46(4):793-800; discussion 2.
77. Mansmann U, Meisel J, Brock M, Rodesch G, Alvarez H, Lasjanias P. Factors associated with intracranial hemorrhage in cases of cerebral arteriovenous malformation. *Neurosurgery* 2000;46(2):272-9; discussion 9-81.
78. Cloft HJ, Kallmes DF, Kallmes MH, Goldstein JH, Jensen ME, Dion JE. Prevalence of cerebral aneurysms in patients with fibromuscular dysplasia: a reassessment. *J Neurosurg* 1998;88(3):436-40.
79. Norgard O, Angqvist KA, Fodstad H, Forsell A, Lindberg M. Co-existence of abdominal aortic aneurysms and intracranial aneurysms. *Acta Neurochir (Wien)* 1987;87(1-2):34-9.
80. Kanai H, Umezumi M, Koide K, Hato M. Ruptured intracranial aneurysm associated with unruptured abdominal aortic aneurysm—case report. *Neurol Med Chir (Tokyo)* 2001;41(5):260-3.
81. Preul MC, Cendes F, Just N, Mohr G. Intracranial aneurysms and sickle cell anemia: multiplicity and propensity for the vertebrobasilar territory. *Neurosurgery* 1998;42(5):971-7; discussion 7-8.
82. Feigin VL, Rinkel GJE, Lawes CMM, et al. Risk Factors for Subarachnoid Hemorrhage: An Updated Systematic Review of Epidemiological Studies. *Stroke* 2005;36(12):2773-80.
83. Baker CJ, Fiore A, Connolly ES, Jr., Baker KZ, Solomon RA. Serum elastase and alpha-1-antitrypsin levels in patients with ruptured and unruptured cerebral aneurysms. *Neurosurgery* 1995;37(1):56-61; discussion 2.
84. Juvela S, Poussa K, Porras M. Factors affecting formation and growth of intracranial aneurysms: a long-term follow-up study. *Stroke* 2001;32(2):485-91.
85. Morris KM, Shaw MD, Foy PM. Smoking and subarachnoid haemorrhage: a case control study. *Br J Neurosurg* 1992;6(5):429-32.
86. Canhao P, Pinto AN, Ferro H, Ferro JM. Smoking and aneurysmal subarachnoid haemorrhage: a case-control study. *J Cardiovasc Risk* 1994;1(2):155-8.
87. Juvela S, Porras M, Poussa K. Natural history of unruptured intracranial aneurysms: probability of and risk factors for aneurysm rupture. *J Neurosurg* 2000;93(3):379-87.
88. Wermer MJH, Greebe P, Algra A, Rinkel GJE. Incidence of Recurrent Subarachnoid Hemorrhage After Clipping for Ruptured Intracranial Aneurysms. *Stroke* 2005;36(11):2394-9.
89. Lasner TM, Weil RJ, Riina HA, et al. Cigarette smoking-induced increase in the risk of symptomatic vasospasm after aneurysmal subarachnoid hemorrhage. *J Neurosurg* 1997;87(3):381-4.
90. Weir BK, Kongable GL, Kassell NF, Schultz JR, Truskowski LL, Sigrest A. Cigarette smoking as a cause of aneurysmal subarachnoid hemorrhage and risk for vasospasm: a report of the Cooperative Aneurysm Study. *J Neurosurg* 1998;89(3):405-11.
91. Isaksen J, Egge A, Waterloo K, Romner B, Ingebrigtsen T. Risk factors for aneurysmal subarachnoid haemorrhage: the Tromsø study. *J Neurol Neurosurg Psychiatry* 2002;73(2):185-7.
92. Rinkel GJ. Intracranial aneurysm screening: indications and advice for practice. *Lancet Neurol* 2005;4(2):122-8.
93. Juvela S, Hillbom M, Numminen H, Koskinen P. Cigarette smoking and alcohol consumption as risk factors for aneurysmal subarachnoid hemorrhage. *Stroke* 1993;24(5):639-46.
94. Longstreth WT, Jr., Nelson LM, Koepsell TD, van Belle G. Cigarette smoking, alcohol use, and subarachnoid hemorrhage. *Stroke* 1992;23(9):1242-9.
95. Johnston SC, Colford JM, Jr., Gress DR. Oral contraceptives and the risk of subarachnoid hemorrhage: a meta-analysis. *Neurology* 1998;51(2):411-8.
96. Teunissen LL, Rinkel GJ, Algra A, van Gijn J. Risk factors for subarachnoid hemorrhage: a systematic review. *Stroke* 1996;27(3):544-9.
97. Adamson J, Humphries SE, Ostergaard JR, Voldby B, Richards P, Powell JT. Are cerebral aneurysms atherosclerotic? *Stroke* 1994;25(5):963-6.
98. Morita A, Fujiwara S, Hashi K, Ohtsu H, Kirino T. Risk of rupture associated with intact cerebral aneurysms in the Japanese population: a systematic review of the literature from Japan. *J Neurosurg* 2005;102(4):601-6.
99. Wiebers DO, Whisnant JP, Huston J, 3rd, et al. Unruptured intracranial aneurysms: natural history, clinical outcome, and risks of surgical and endovascular treatment. *Lancet* 2003;362(9378):103-10.
100. Morita A. [On-line outcome study of unruptured cerebral aneurysm in Japan (UCAS Japan)]. *Rinsho Shinkeigaku* 2002;42(11):1188-90.
101. Yonekura M. Small unruptured aneurysm verification (SUAVE Study, Japan)—interim report. *Neurol Med Chir (Tokyo)* 2004;44(4):213-4.
102. Kiyohara Y, Ueda K, Hasuo Y, et al. Incidence and prognosis of subarachnoid hemorrhage in a Japanese rural community. *Stroke* 1989;20(9):1150-5.
103. Ingall TJ, Whisnant JP, Wiebers DO, O'Fallon WM. Has there been a decline in subarachnoid hemorrhage mortality? *Stroke* 1989;20(6):718-24.
104. Burt VL, Whelton P, Roccella EJ, et al. Prevalence of hypertension in the US adult population. Results from the Third National Health and Nutrition Examination Survey, 1988-1991. *Hypertension* 1995;25(3):305-13.
105. Patterson JM, Eberly LE, Ding Y, Hargreaves M. Associations of smoking prevalence with individual and area level social cohesion. *J Epidemiol Community Health* 2004;58(8):692-7.
106. Ministry of Health LaW. [Current Status of Nutrition in Japanese Population (Survey in 1998)]. Tokyo: Daiichi Shuppan; 2000.
107. Association AH. Heart disease and stroke statistics - 2005 update. Dallas: American Heart Association; 2005.
108. Arias E. United States Life Tables, 2002. *Natl Vital Stat Rep* 2004;53(6):1-38.
109. Kondziolka D, McLaughlin MR, Kestle JR. Simple risk predictions for arteriovenous malformation hemorrhage. *Neurosurgery* 1995;37(5):851-5.
110. Yoshimoto Y. Publication bias in neurosurgery: lessons from series of unruptured aneurysms. *Acta Neurochirurgica* 2003;145(1):45-8.
111. Feuerberg I, Lindquist C, Lindqvist M, Steiner L. Natural history of postoperative aneurysm rests. *J Neurosurg* 1987;66(1):30-4.
112. Macdonald RL, Wallace MC, Kestle JR. Role of angiography following aneurysm surgery. *J Neurosurg* 1993;79(6):826-32.
113. Thornton J, Bashir Q, Aletich VA, Debrun GM, Ausman JI, Charbel FT. What percentage of surgically clipped intracranial aneurysms have residual necks? *Neurosurgery* 2000;46(6):1294-8; discussion 8-300.
114. Sindou M, Acevedo JC, Turjman F. Aneurysmal remnants after microsurgical clipping: classification and results from a prospective angiographic study (in a consecutive series of 305 operated intracranial aneurysms). *Acta Neurochir (Wien)* 1998;140(11):1153-9.

115. Le Roux PD, Elliott JP, Eskridge JM, Cohen W, Winn HR. Risks and benefits of diagnostic angiography after aneurysm surgery: a retrospective analysis of 597 studies. *Neurosurgery* 1998;42(6):1248-54; discussion 54-5.
116. David CA, Vishteh AG, Spetzler RF, Lemole M, Lawton MT, Partovi S. Late angiographic follow-up review of surgically treated aneurysms. *J Neurosurg* 1999;91(3):396-401.
117. Tsutsumi K, Ueki K, Usui M, Kwak S, Kirino T. Risk of recurrent subarachnoid hemorrhage after complete obliteration of cerebral aneurysms. *Stroke* 1998;29(12):2511-3.
118. The CI. Rates of Delayed Rebleeding From Intracranial Aneurysms Are Low After Surgical and Endovascular Treatment. *Stroke* 2006;37(6):1437-42.
119. Raaymakers TW, Rinkel GJ, Limburg M, Algra A. Mortality and morbidity of surgery for unruptured intracranial aneurysms: a meta-analysis. *Stroke* 1998;29(8):1531-8.
120. Johnston SC, Zhao S, Dudley RA, Berman MF, Gress DR. Treatment of unruptured cerebral aneurysms in California. *Stroke* 2001;32(3):597-605.
121. Khanna RK, Malik GM, Qureshi N. Predicting outcome following surgical treatment of unruptured intracranial aneurysms: a proposed grading system. *J Neurosurg* 1996;84(1):49-54.
122. Ogilvy CS, Carter BS. Stratification of outcome for surgically treated unruptured intracranial aneurysms. *Neurosurgery* 2003;52(1):82-7; discussion 7-8.
123. Ronkainen A, Niskanen M, Rinne J, Koivisto T, Hernesniemi J, Vapalahti M. Evidence for Excess Long-Term Mortality After Treated Subarachnoid Hemorrhage. *Stroke* 2001;32(12):2850-3.
124. Britz GW, Salem L, Newell DW, Eskridge J, Flum DR. Impact of Surgical Clipping on Survival in Unruptured and Ruptured Cerebral Aneurysms: A Population-Based Study. *Stroke* 2004;35(6):1399-403.
125. Bristra EH, Rinkel GJ, van der Graaf Y, van Rooij WJ, Algra A. Treatment of intracranial aneurysms by embolization with coils: a systematic review. *Stroke* 1999;30(2):470-6.
126. Byrne JV, Sohn MJ, Molyneux AJ, Chir B. Five-year experience in using coil embolization for ruptured intracranial aneurysms: outcomes and incidence of late rebleeding. *J Neurosurg* 1999;90(4):656-63.
127. Cognard C, Weill A, Spelle L, et al. Long-term angiographic follow-up of 169 intracranial berry aneurysms occluded with detachable coils. *Radiology* 1999;212(2):348-56.
128. Raffopoulos C, Mathurin P, Boscherini D, Billa RF, Van Boven M, Hanson P. Prospective analysis of aneurysm treatment in a series of 103 consecutive patients when endovascular embolization is considered the first option. *J Neurosurg* 2000;93(2):175-82.
129. Ng P, Khangure MS, Phatouros CC, Bynevelt M, ApSimon H, McAuliffe W. Endovascular Treatment of Intracranial Aneurysms With Guglielmi Detachable Coils: Analysis of Midterm Angiographic and Clinical Outcomes. *Stroke* 2002;33(1):210-7.
130. Murayama Y, Nien YL, Duckwiler G, et al. Guglielmi detachable coil embolization of cerebral aneurysms: 11 years' experience. *J Neurosurg* 2003;98(5):959-66.
131. Gonzalez N, Murayama Y, Nien YL, et al. Treatment of unruptured aneurysms with GDCs: clinical experience with 247 aneurysms. *AJNR Am J Neuroradiol* 2004;25(4):577-83.
132. Pouratian N, Oskouian RJ, Jr., Jensen ME, Kassell NF, Dumont AS. Endovascular management of unruptured intracranial aneurysms. *J Neurol Neurosurg Psychiatry* 2006;77(5):572-8.
133. Goddard AJ, Annesley-Williams D, Gholkar A. Endovascular management of unruptured intracranial aneurysms: does outcome justify treatment? *J Neurol Neurosurg Psychiatry* 2002;72(4):485-90.
134. Roy D, Raymond J, Bouthillier A, Bojanowski MW, Mounjian R, L'Esperance G. Endovascular treatment of ophthalmic segment aneurysms with Guglielmi detachable coils. *AJNR Am J Neuroradiol* 1997;18(7):1207-15.
135. Fernandez Zubillaga A, Guglielmi G, Vinuela F, Duckwiler GR. Endovascular occlusion of intracranial aneurysms with electrically detachable coils: correlation of aneurysm neck size and treatment results. *AJNR Am J Neuroradiol* 1994;15(5):815-20.
136. Cognard C, Pierot L, Boulin A, et al. Intracranial aneurysms: endovascular treatment with mechanical detachable spirals in 60 aneurysms. *Radiology* 1997;202(3):783-92.
137. Raymond J, Guilbert F, Weill A, et al. Long-Term Angiographic Recurrences After Selective Endovascular Treatment of Aneurysms With Detachable Coils. *Stroke* 2003;34(6):1398-403.
138. Gallas S, Pasco A, Cottier J-P, et al. A Multicenter Study of 705 Ruptured Intracranial Aneurysms Treated with Guglielmi Detachable Coils. *AJNR Am J Neuroradiol* 2005;26(7):1723-31.
139. Li MH, Gao BL, Fang C, et al. Angiographic Follow-Up of Cerebral Aneurysms Treated with Guglielmi Detachable Coils: An Analysis of 162 Cases with 173 Aneurysms. *AJNR Am J Neuroradiol* 2006;27(5):1107-12.
140. Iijima A, Pliotin M, Mounayer C, Spelle L, Weill A, Moret J. Endovascular Treatment with Coils of 149 Middle Cerebral Artery Berry Aneurysms. *Radiology* 2005;237(2):611-9.
141. Tamatani S, Ito Y, Abe H, Koike T, Takeuchi S, Tanaka R. Evaluation of the Stability of Aneurysms after Embolization Using Detachable Coils: Correlation between Stability of Aneurysms and Embolized Volume of Aneurysms. *AJNR Am J Neuroradiol* 2002;23(5):762-7.
142. Szikora I, Wakhloo AK, Guterman LR, et al. Initial experience with collagen-filled Guglielmi detachable coils for endovascular treatment of experimental aneurysms. *AJNR Am J Neuroradiol* 1997;18(4):667-72.
143. Kawanabe Y, Sadato A, Taki W, Hashimoto N. Endovascular occlusion of intracranial aneurysms with Guglielmi detachable coils: correlation between coil packing density and coil compaction. *Acta Neurochir (Wien)* 2001;143(5):451-5.
144. Soeda A, Sakai N, Sakai H, Iihara K, Nagata I. Endovascular treatment of asymptomatic cerebral aneurysms: anatomic and technical factors related to ischemic events and coil stabilization. *Neurol Med Chir (Tokyo)* 2004;44(9):456-65; discussion 66.
145. Graves VB, Strother CM, Duff TA, Perl J, 2nd. Early treatment of ruptured aneurysms with Guglielmi detachable coils: effect on subsequent bleeding. *Neurosurgery* 1995;37(4):640-7; discussion 7-8.
146. Friedman JA, Nichols DA, Meyer FB, et al. Guglielmi Detachable Coil Treatment of Ruptured Sacular Cerebral Aneurysms: Retrospective Review of a 10-Year Single-Center Experience. *AJNR Am J Neuroradiol* 2003;24(3):526-33.
147. Lempert TE, Malek AM, Halbach VV, et al. Endovascular treatment of ruptured posterior circulation cerebral aneurysms. Clinical and angiographic outcomes. *Stroke* 2000;31(1):100-10.
148. Kuether TA, Nesbit GM, Barnwell SL. Clinical and angiographic outcomes, with treatment data, for patients with cerebral aneurysms treated with Guglielmi detachable coils: a single-center experience. *Neurosurgery* 1998;43(5):1016-25.
149. Nichols DA, Brown RD, Jr., Thielen KR, Meyer FB, Atkinson JL, Piepgras DG. Endovascular treatment of ruptured posterior circulation aneurysms using electrolytically detachable coils. *J Neurosurg* 1997;87(3):374-80.
150. Uda K, Goto K, Ogata N, Izumi N, Nagata S, Matsuno H. Embolization of cerebral aneurysms using Guglielmi detachable coils—problems and treatment plans in the acute stage after subarachnoid hemorrhage and long-term efficiency. *Neurol Med Chir (Tokyo)* 1998;38(3):143-52; discussion 52-4.
151. Raymond J, Roy D. Safety and efficacy of endovascular treatment of acutely ruptured aneurysms. *Neurosurgery* 1997;41(6):1235-45; discussion 45-6.
152. Eskridge JM, Song JK. Endovascular embolization of 150 basilar tip aneurysms with Guglielmi detachable coils: results of the Food and Drug Administration multicenter clinical trial. *J Neurosurg* 1998;89(1):81-6.
153. Elias T, Ogungbo B, Connolly D, Gregson B, Mendelow AD, Gholkar A. Endovascular treatment of anterior communicating artery aneurysms: results of clinical and radiological outcome in Newcastle. *Br J Neurosurg* 2003;17(3):278-86.

154. Vanninen R, Koivisto T, Saari T, Hernesniemi J, Vapalahti M. Ruptured intracranial aneurysms: acute endovascular treatment with electrolytically detachable coils—a prospective randomized study. *Radiology* 1999;211(2):325-36.
155. Cognard C, Weill A, Castaing L, Rey A, Moret J. Intracranial berry aneurysms: angiographic and clinical results after endovascular treatment. *Radiology* 1998;206(2):499-510.
156. Sluzewski M, van Rooij WJ, Rinkel GJ, Wijnalda D. Endovascular treatment of ruptured intracranial aneurysms with detachable coils: long-term clinical and serial angiographic results. *Radiology* 2003;227(3):720-4.
157. Molyneux AJ, Kerr RS, Yu LM, et al. International subarachnoid aneurysm trial (ISAT) of neurosurgical clipping versus endovascular coiling in 2143 patients with ruptured intracranial aneurysms: a randomised comparison of effects on survival, dependency, seizures, rebleeding, subgroups, and aneurysm occlusion. *Lancet* 2005;366(9488):809-17.
158. Molyneux A, Kerr R, Stratton I, et al. International Subarachnoid Aneurysm Trial (ISAT) of neurosurgical clipping versus endovascular coiling in 2143 patients with ruptured intracranial aneurysms: a randomised trial. *Lancet* 2002;360(9342):1267-74.
159. Johnston SC, Dudley RA, Gress DR, Ono L. Surgical and endovascular treatment of unruptured cerebral aneurysms at university hospitals. *Neurology* 1999;52(9):1799-805.
160. Lee T, Bayton M, Sciacca R, Mohr JP, Pile-Spellman J. Aggregate Analysis of the Literature for Unruptured Intracranial Aneurysm Treatment. *AJNR Am J Neuroradiol* 2005;26(8):1902-8.
161. Solomon RA, Fink ME, Pile-Spellman J. Surgical management of unruptured intracranial aneurysms. *J Neurosurg* 1994;80(3):440-6.
162. Malisch TW, Guglielmi G, Vinuela F, et al. Unruptured aneurysms presenting with mass effect symptoms: response to endosaccular treatment with Guglielmi detachable coils. Part I. Symptoms of cranial nerve dysfunction. *J Neurosurg* 1998;89(6):956-61.
163. Friedman JA, Piepgras DG, Pichelmann MA, Hansen KK, Brown RD, Jr., Wiebers DO. Small cerebral aneurysms presenting with symptoms other than rupture. *Neurology* 2001;57(7):1212-6.
164. Yanaka K, Matsumaru Y, Mashiko R, Hyodo A, Sugimoto K, Nose T. Small unruptured cerebral aneurysms presenting with oculomotor nerve palsy. *Neurosurgery* 2003;52(3):553-7; discussion 6-7.
165. Rodriguez-Catarino M, Frisen L, Wikholm G, Elfverson J, Quiding L, Svendsen P. Internal carotid artery aneurysms, cranial nerve dysfunction and headache: the role of deformation and pulsation. *Neuroradiology* 2003;45(4):236-40.
166. Halbach VV, Higashida RT, Dowd CF, et al. The efficacy of endosaccular aneurysm occlusion in alleviating neurological deficits produced by mass effect. *J Neurosurg* 1994;80(4):659-66.
167. Kazekawa K, Tsutsumi M, Aikawa H, et al. Internal carotid aneurysms presenting with mass effect symptoms of cranial nerve dysfunction: efficacy and imitations of endosaccular embolization with GDC. *Radiat Med* 2003;21(2):80-5.
168. Chen PR, Amin-Hanjani S, Albuquerque FC, McDougall C, Zabramski JM, Spetzler RF. Outcome of oculomotor nerve palsy from posterior communicating artery aneurysms: comparison of clipping and coiling. *Neurosurgery* 2006;58(6):1040-6; discussion 6.
169. Feely M, Kapoor S. Third nerve palsy due to posterior communicating artery aneurysm: the importance of early surgery. *J Neurol Neurosurg Psychiatry* 1987;50(8):1051-2.
170. Giombini S, Ferraresi S, Pluchino F. Reversal of oculomotor disorders after intracranial aneurysm surgery. *Acta Neurochir (Wien)* 1991;112(1-2):19-24.
171. Ahn JY, Han IB, Yoon PH, et al. Clipping vs coiling of posterior communicating artery aneurysms with third nerve palsy. *Neurology* 2006;66(1):121-3.
172. van der Schaaf IC, Brilstra EH, Buskens E, Rinkel GJE. Endovascular Treatment of Aneurysms in the Cavernous Sinus: A Systematic Review on Balloon Occlusion of the Parent Vessel and Embolization With Coils. *Stroke* 2002;33(1):313-8.
173. Stiebel-Kalish H, Kalish Y, Bar-On RH, et al. Presentation, natural history, and management of carotid cavernous aneurysms. *Neurosurgery* 2005;57(5):850-7; discussion 7.
174. Field M, Jungreis CA, Chengelis N, Kromer H, Kirby L, Yonas H. Symptomatic Cavernous Sinus Aneurysms: Management and Outcome After Carotid Occlusion and Selective Cerebral Revascularization. *AJNR Am J Neuroradiol* 2003;24(6):1200-7.
175. Bavinszki G, Killer M, Ferraz-Leite H, Gruber A, Gross CE, Richling B. Endovascular therapy of idiopathic cavernous aneurysms over 11 years. *AJNR Am J Neuroradiol* 1998;19(3):559-65.
176. Gonzalez LF, Walker MT, Zabramski JM, Partovi S, Wallace RC, Spetzler RF. Distinction between paraclinoid and cavernous sinus aneurysms with computed tomographic angiography. *Neurosurgery* 2003;52(5):1131-7; discussion 8-9.
177. al-Rodhan NR, Piepgras DG, Sundt TM, Jr. Transitional cavernous aneurysms of the internal carotid artery. *Neurosurgery* 1993;33(6):993-6; discussion 7-8.
178. White JA, Horowitz MB, Samson D. Dural waisting as a sign of subarachnoid extension of cavernous carotid aneurysms: a follow-up case report. *Surg Neurol* 1999;52(6):607-9; discussion 9-10.
179. van Rooij WJ, Sluzewski M, Beute GN. Ruptured Cavernous Sinus Aneurysms Causing Carotid Cavernous Fistula: Incidence, Clinical Presentation, Treatment, and Outcome. *AJNR Am J Neuroradiol* 2006;27(1):185-9.
180. Kupersmith MJ, Hurst R, Berenstein A, Choi IS, Jafar J, Ransohoff J. The benign course of cavernous carotid artery aneurysms. *J Neurosurg* 1992;77(5):690-3.
181. Lee AG, Mawad ME, Baskin DS. Fatal subarachnoid hemorrhage from the rupture of a totally intracavernous carotid artery aneurysm: case report. *Neurosurgery* 1996;38(3):596-8; discussion 8-9.
182. Hamada H, Endo S, Fukuda O, Ohi M, Takaku A. Giant aneurysm in the cavernous sinus causing subarachnoid hemorrhage 13 years after detection: a case report. *Surg Neurol* 1996;45(2):143-6.
183. Linskey ME, Sekhar LN, Hirsch WL, Jr., Yonas H, Horton JA. Aneurysms of the intracavernous carotid artery: natural history and indications for treatment. *Neurosurgery* 1990;26(6):933-7; discussion 7-8.
184. De Jesus O, Sekhar LN, Riedel CJ. Clinoid and paraclinoid aneurysms: surgical anatomy, operative techniques, and outcome. *Surgical Neurology* 1999;51(5):477-88.
185. Tanaka Y, Hongo K, Tada T, et al. Radiometric analysis of paraclinoid carotid artery aneurysms. *J Neurosurg* 2002;96(4):649-53.
186. Day AL. Aneurysms of the ophthalmic segment. A clinical and anatomical analysis. *J Neurosurg* 1990;72(5):677-91.
187. Berson EL, Freeman MI, Gay AJ. Visual field defects in giant suprasellar aneurysms of internal carotid. Report of three cases. *Arch Ophthalmol* 1966;76(1):52-8.
188. Lee JH, Tobias S, Kwon J-T, Sade B, Kosmorsky G, Wilbrandt's knee: does it exist? *Surgical Neurology* 2006;66(1):11-7.
189. Iihara K, Murao K, Sakai N, et al. Unruptured paraclinoid aneurysms: a management strategy. *J Neurosurg* 2003;99(2):241-7.
190. Park HK, Horowitz M, Jungreis C, et al. Endovascular treatment of paraclinoid aneurysms: experience with 73 patients. *Neurosurgery* 2003;53(1):14-23; discussion 4.
191. Hoh BL, Carter BS, Budzik RF, Putman CM, Ogilvy CS. Results after surgical and endovascular treatment of paraclinoid aneurysms by a combined neurovascular team. *Neurosurgery* 2001;48(1):78-89; discussion 90.
192. Boet R, Wong GK, Poon WS, Lam JM, Yu SC. Aneurysm recurrence after treatment of paraclinoid/ophthalmic segment aneurysms—a treatment-modality assessment. *Acta Neurochir (Wien)* 2005;147(6):611-6; discussion 6.
193. Kobayashi S, Kyoshima K, Gibo H, Hegde SA, Takemae T, Sugita K. Carotid cave aneurysms of the internal carotid artery. *J Neurosurg* 1989;70(2):216-21.
194. Kim JM, Romano A, Sanan A, van Loveren HR, Keller JT. Microsurgical anatomic features and nomenclature of the paraclinoid region. *Neurosurgery* 2000;46(3):670-80; discussion 80-2.

195. Sundt TM, Jr., Whisnant JP. Subarachnoid hemorrhage from intracranial aneurysms. Surgical management and natural history of disease. *N Engl J Med* 1978;299(3):116-22.
196. Leipzig TJ, Morgan J, Horner TG, Payner T, Redelman K, Johnson CS. Analysis of intraoperative rupture in the surgical treatment of 1694 saccular aneurysms. *Neurosurgery* 2005;56(3):455-68; discussion 68.
197. Lawton MT, Du R. Effect of the neurosurgeon's surgical experience on outcomes from intraoperative aneurysmal rupture. *Neurosurgery* 2005;57(1):9-15; discussion 9.
198. Protin M, Mounayer C, Spelle L, Williams MT, Moret J. Endovascular treatment of anterior choroidal artery aneurysms. *AJNR Am J Neuroradiol* 2004;25(2):314-8.
199. Friedman JA, Pichelmann MA, Piepgras DG, et al. Ischemic complications of surgery for anterior choroidal artery aneurysms. *J Neurosurg* 2001;94(4):565-72.
200. Miyazawa N, Nukui H, Horikoshi T, Yagishita T, Sugita M, Kanemaru K. Surgical management of aneurysms of the bifurcation of the internal carotid artery. *Clinical Neurology and Neurosurgery* 2002;104(2):103-14.
201. Sakamoto S, Ohba S, Shibukawa M, et al. Characteristics of aneurysms of the internal carotid artery bifurcation. *Acta Neurochir (Wien)* 2006;148(2):139-43; discussion 43.
202. Locksley HB. Natural history of subarachnoid hemorrhage, intracranial aneurysms and arteriovenous malformations. Based on 6368 cases in the cooperative study. *J Neurosurg* 1966;25(2):219-39.
203. Yock DH, Jr., Larson DA. Computed tomography of hemorrhage from anterior communicating artery aneurysms, with angiographic correlation. *Radiology* 1980;134(2):399-407.
204. Sayama T, Inamura T, Matsushima T, Inoha S, Inoue T, Fukui M. High incidence of hyponatremia in patients with ruptured anterior communicating artery aneurysms. *Neurol Res* 2000;22(2):151-5.
205. DeLuca J. Cognitive dysfunction after aneurysm of the anterior communicating artery. *J Clin Exp Neuropsychol* 1992;14(6):924-34.
206. Fontanella M, Perozzo P, Ursone R, Garbossa D, Bergui M. Neuropsychological assessment after microsurgical clipping or endovascular treatment for anterior communicating artery aneurysm. *Acta Neurochir (Wien)* 2003;145(10):867-72; discussion 72.
207. Moret J, Pierot L, Boulin A, Castaings L, Rey A. Endovascular treatment of anterior communicating artery aneurysms using Guglielmi detachable coils. *Neuroradiology* 1996;38(8):800-5.
208. Birknes JK, Hwang SK, Pandey AS, et al. Feasibility and limitations of endovascular coil embolization of anterior communicating artery aneurysms: morphological considerations. *Neurosurgery* 2006;59(1):43-52; discussion 43-52.
209. Steven DA, Ferguson GG. Distal Anterior Cerebral Artery Aneurysms. In: Winn HR, ed. *Youmans Neurological Surgery*. Philadelphia: Saunders; 2004:1945-57.
210. Baptista AG. Studies on the Arteries of the Brain. II. the Anterior Cerebral Artery: Some Anatomic Features and Their Clinical Implications. *Neurology* 1963;13:825-35.
211. Huber P, Braun J, Hirschmann D, Agyeman JF. Incidence of berry aneurysms of the unpaired pericallosal artery: angiographic study. *Neuroradiology* 1980;19(3):143-7.
212. Asari S, Nakamura S, Yamada O, Beck H, Sugatani H. Traumatic aneurysm of peripheral cerebral arteries. Report of two cases. *J Neurosurg* 1977;46(6):795-803.
213. Fleischer AS, Patton JM, Tindall GT. Cerebral aneurysms of traumatic origin. *Surg Neurol* 1975;4(2):233-9.
214. Inci S, Erbeni A, Ozgen T. Aneurysms of the distal anterior cerebral artery: report of 14 cases and a review of the literature. *Surg Neurol* 1998;50(2):130-9; discussion 9-40.
215. Snyckers FD, Drake CG. Aneurysms of the distal anterior cerebral artery. A report on 24 verified cases. *S Afr Med J* 1973;47(39):1787-91.
216. Hernesniemi J, Tapaninaho A, Vapalahti M, Niskanen M, Kari A, Luukkainen M. Saccular aneurysms of the distal anterior cerebral artery and its branches. *Neurosurgery* 1992;31(6):994-8; discussion 8-9.
217. Pierot L, Boulin A, Castaings L, Rey A, Moret J. Endovascular treatment of pericallosal artery aneurysms. *Neurol Res* 1996;18(1):49-53.
218. Sundt TM, Jr., Kobayashi S, Fode NC, Whisnant JP. Results and complications of surgical management of 809 intracranial aneurysms in 722 cases. Related and unrelated to grade of patient, type of aneurysm, and timing of surgery. *J Neurosurg* 1982;56(6):753-65.
219. Kassell NF, Torner JC, Haley EC, Jr., Jane JA, Adams HP, Kongable GL. The International Cooperative Study on the Timing of Aneurysm Surgery; Part 1: Overall management results. *J Neurosurg* 1990;73(1):18-36.
220. Rinne J, Hernesniemi J, Niskanen M, Vapalahti M. Analysis of 561 patients with 690 middle cerebral artery aneurysms: anatomic and clinical features as correlated to management outcome. *Neurosurgery* 1996;38(1):2-11.
221. Stoodley MA, Macdonald RI, Weir BK. Surgical treatment of middle cerebral artery aneurysms. *Neurosurg Clin N Am* 1998;9(4):823-34.
222. Friedman J, Piepgras D. Middle Cerebral Artery Aneurysms. In: Winn HR, ed. *Youmans Neurological Surgery*. Philadelphia: Saunders; 2004:1959-70.
223. Raps EC, Rogers JD, Galetta SL, et al. The clinical spectrum of unruptured intracranial aneurysms. *Arch Neurol* 1993;50(3):265-8.
224. Tanaka K, Hirayama K, Hattori H, et al. A case of cerebral aneurysm associated with complex partial seizures. *Brain Dev* 1994;16(3):233-7.
225. Miele VI, Bendok BR, Batjer HH. Unruptured aneurysm of the middle cerebral artery presenting with psychomotor seizures: case study and review of the literature. *Epilepsy Behav* 2004;5(3):420-8.
226. Tokuda Y, Inagawa T, Katoh Y, Kumano K, Ohbayashi N, Yoshioka H. Intracerebral hematoma in patients with ruptured cerebral aneurysms. *Surg Neurol* 1995;43(3):272-7.
227. Pritz MB, Chandler WF. The transylvian approach to middle cerebral artery bifurcation/trifurcation aneurysms. *Surg Neurol* 1994;41(3):217-9; discussion 9-20.
228. Ogilvy CS, Crowell RM, Heros RC. Surgical management of middle cerebral artery aneurysms: experience with transylvian and superior temporal gyrus approaches. *Surg Neurol* 1995;43(1):15-22; discussion 4.
229. Regli L, Uske A, de Tribolet N. Endovascular coil placement compared with surgical clipping for the treatment of unruptured middle cerebral artery aneurysms: a consecutive series. *J Neurosurg* 1999;90(6):1025-30.
230. Doerfler A, Wanke I, Goericke SL, et al. Endovascular Treatment of Middle Cerebral Artery Aneurysms with Electrolytically Detachable Coils. *AJNR Am J Neuroradiol* 2006;27(3):513-20.
231. Lozier AP, Connolly ES, Jr., Lavine SD, Solomon RA. Guglielmi Detachable Coil Embolization of Posterior Circulation Aneurysms: A Systematic Review of the Literature. *Stroke* 2002;33(10):2509-18.
232. Drake CG. The treatment of aneurysms of the posterior circulation. *Clin Neurosurg* 1979;26:96-144.
233. Horikoshi T, Nukui H, Yagishita T, Nishigaya K, Fukasawa I, Sasaki H. Oculomotor nerve palsy after surgery for upper basilar artery aneurysms. *Neurosurgery* 1999;44(4):705-10; discussion 10-1.
234. Al-Khayat H, Al-Khayat H, White J, Manner D, Samson D. Upper basilar artery aneurysms: oculomotor outcomes in 163 cases. *J Neurosurg* 2005;102(3):482-8.
235. Henkes H, Fischer S, Mariushi W, et al. Angiographic and clinical results in 316 coil-treated basilar artery bifurcation aneurysms. *J Neurosurg* 2005;103(6):990-9.
236. Kwon OK, Kim SH, Kwon BJ, et al. Endovascular Treatment of Wide-Necked Aneurysms By Using Two Microcatheters: Techniques and Outcomes in 25 Patients. *AJNR Am J Neuroradiol* 2005;26(4):894-900.
237. Bendorff G, Claus B, Strother CM, Chang L, Klucznik RP. Increased cell opening and prolapse of struts of a neuroform stent in curved vasculature: value of angiographic computed tomography: technical case report. *Neurosurgery* 2006;58(4 Suppl 2):ONS-E380; discussion ONS-E.
238. Josephson SA, Dillon WP, Dowd CF, Malek R, Lawton MT, Smith WS. Continuous bleeding from a basilar terminus aneurysm imaged with CT angiography and conventional angiography. *Neurocrit Care* 2004;1(1):103-6.
239. Ferrante L, Acqui M, Trillo G, Lunardi P, Fortuna A. Aneurysms of the posterior cerebral artery: do they

- present specific characteristics? *Acta Neurochir (Wien)* 1996;138(7):840-52.
240. Gerber CJ, Neil-Dwyer G. A review of the management of 15 cases of aneurysms of the posterior cerebral artery. *Br J Neurosurg* 1992;6(6):521-7.
 241. Sakata S, Fujii K, Matsushima T, et al. Aneurysm of the posterior cerebral artery: report of eleven cases—surgical approaches and procedures. *Neurosurgery* 1993;32(2):163-7; discussion 7-8.
 242. Ciceri EF, Klucznik RP, Grossman RG, Rose JE, Mawad ME. Aneurysms of the Posterior Cerebral Artery: Classification and Endovascular Treatment. *AJNR Am J Neuroradiol* 2001;22(1):27-34.
 243. Hamada J, Morioka M, Yano S, Todaka T, Kai Y, Kuratsu J. Clinical features of aneurysms of the posterior cerebral artery: a 15-year experience with 21 cases. *Neurosurgery* 2005;56(4):662-70; discussion -70.
 244. Pia HW, Fontana H. Aneurysms of the posterior cerebral artery. Locations and clinical pictures. *Acta Neurochir (Wien)* 1977;38(1-2):13-35.
 245. Honda M, Tsutsumi K, Yokoyama H, Yonekura M, Nagata I. Aneurysms of the posterior cerebral artery: retrospective review of surgical treatment. *Neurol Med Chir (Tokyo)* 2004;44(4):164-8; discussion 9.
 246. Seoane ER, Tedeschi H, de Oliveira E, Siqueira MG, Calderon GA, Rhoton AL, Jr. Management strategies for posterior cerebral artery aneurysms: a proposed new surgical classification. *Acta Neurochir (Wien)* 1997;139(4):325-31.
 247. Hallacq P, Piotin M, Moret J. Endovascular Occlusion of the Posterior Cerebral Artery for the Treatment of P2 Segment Aneurysms: Retrospective Review of a 10-Year Series. *AJNR Am J Neuroradiol* 2002;23(7):1128-36.
 248. Haw C, Willinsky R, Agid R, TerBruggen K. The endovascular management of superior cerebellar artery aneurysms. *Can J Neurol Sci* 2004;31(1):53-7.
 249. Gacs G, Vinuela F, Fox AJ, Drake CG. Peripheral aneurysms of the cerebellar arteries. Review of 16 cases. *J Neurosurg* 1983;58(1):63-8.
 250. Papo I, Caruselli G, Salvolini U. Aneurysm of the superior cerebellar artery. *Surg Neurol* 1977;7(1):15-7.
 251. Collins TE, Mehalic TF, White TK, Pezzutti RT. Trochlear nerve palsy as the sole initial sign of an aneurysm of the superior cerebellar artery. *Neurosurgery* 1992;30(2):258-61.
 252. Proust F, Callonec F, Bellow F, Laquerriere A, Hannequin D, Freger P. Tentorial edge traumatic aneurysm of the superior cerebellar artery. Case report. *J Neurosurg* 1997;87(6):950-4.
 253. Danet M, Raymond J, Roy D. Distal Superior Cerebellar Artery Aneurysm Presenting with Cerebellar Infarction: Report of Two Cases. *AJNR Am J Neuroradiol* 2001;22(4):717-20.
 254. Chaloupka JC, Putman CM, Awad IA. Endovascular therapeutic approach to peripheral aneurysms of the superior cerebellar artery. *AJNR Am J Neuroradiol* 1996;17(7):1338-42.
 255. Eckard DA, O'Boynick PL, McPherson CM, et al. Coil Occlusion of the Parent Artery for Treatment of Symptomatic Peripheral Intracranial Aneurysms. *AJNR Am J Neuroradiol* 2000;21(1):137-42.
 256. Drake CG, Peerless SJ, Hernesniemi JA. *Surgery of Vertebralbasilar Aneurysms*: London, Ontario, Experience on 1767 Patients. Vienna: Springer-Verlag; 1996.
 257. Peerless SJ, Drake CG. Posterior circulation aneurysms. In: Wilkins RH, Rengachary SS, eds. *Neurosurgery*. New York: McGraw-Hill; 1996:2341-56.
 258. Mizoi K, Yoshimoto T, Takahashi A, Ogawa A. Direct clipping of basilar trunk aneurysms using temporary balloon occlusion. *J Neurosurg* 1994;80(2):230-6.
 259. Peerless SJ, Hernesniemi JA, Gutman FB, Drake CG. Early surgery for ruptured vertebralbasilar aneurysms. *J Neurosurg* 1994;80(4):643-9.
 260. Seifert V. Direct surgery of basilar trunk and vertebralbasilar junction aneurysms via the combined transpetrosal approach. *Neurol Med Chir (Tokyo)* 1998;38 Suppl:86-92.
 261. Van Rooij WJ, Sluzewski M, Menovsky T, Wijnalda D. Coiling of saccular basilar trunk aneurysms. *Neuroradiology* 2003;45(1):19-21.
 262. Uda K, Murayama Y, Gobin YP, Duckwiler GR, Vinuela F. Endovascular treatment of basilar artery trunk aneurysms with Guglielmi detachable coils: clinical experience with 41 aneurysms in 39 patients. *J Neurosurg* 2001;95(4):624-32.
 263. Steinberg GK, Drake CG, Peerless SJ. Deliberate basilar or vertebral artery occlusion in the treatment of intracranial aneurysms. Immediate results and long-term outcome in 201 patients. *J Neurosurg* 1993;79(2):161-73.
 264. Wenderoth JD, Khangure MS, Phatourous CC, ApSimon HT. Basilar trunk occlusion during endovascular treatment of giant and fusiform aneurysms of the basilar artery. *AJNR Am J Neuroradiol* 2003;24(6):1226-9.
 265. Gonzalez LF, Alexander MJ, McDougall CG, Spetzler RF. Anteroinferior cerebellar artery aneurysms: surgical approaches and outcomes—a review of 34 cases. *Neurosurgery* 2004;55(5):1025-35.
 266. Akyuz M, Tuncer R. Multiple anterior inferior cerebellar artery aneurysms associated with an arteriovenous malformation: case report. *Surg Neurol* 2005;64 Suppl 2:S106-8.
 267. Spallone A, De Santis S, Giuffrè R. Peripheral aneurysms of the anterior inferior cerebellar artery. Case report and review of literature. *Br J Neurosurg* 1995;9(4):537-41.
 268. Suzuki K, Meguro K, Wada M, Fujita K, Nose T. Embolization of a ruptured aneurysm of the distal anterior inferior cerebellar artery: case report and review of the literature. *Surg Neurol* 1999;51(5):509-12.
 269. Yoon SM, Chun YI, Kwon Y, Kwon BD. Vertebralbasilar junction aneurysms associated with fenestration: experience of five cases treated with Guglielmi detachable coils. *Surg Neurol* 2004;61(3):248-54.
 270. Rabinov JD, Helling FR, Morris PP, Ogilvy CS, Putman CM. Endovascular Management of Vertebralbasilar Dissecting Aneurysms. *AJNR Am J Neuroradiol* 2003;24(7):1421-8.
 271. Hudgins RJ, Day AL, Quisling RG, Rhoton AL, Jr., Sypert GW, Garcia-Bengochea F. Aneurysms of the posterior inferior cerebellar artery. A clinical and anatomical analysis. *J Neurosurg* 1983;58(3):381-7.
 272. Yamaura A, Watanabe Y, Saeki N. Dissecting aneurysms of the intracranial vertebral artery. *J Neurosurg* 1990;72(2):183-8.
 273. Kallmes DF, Lanzino G, Dix JE, et al. Patterns of hemorrhage with ruptured posterior inferior cerebellar artery aneurysms: CT findings in 44 cases. *AJR Am J Roentgenol* 1997;169(4):1169-71.
 274. Yamaura A. Diagnosis and treatment of vertebral aneurysms. *J Neurosurg* 1988;69(3):345-9.
 275. Lemole GM, Jr., Henn J, Javedan S, Deshmukh V, Spetzler RF. Cerebral revascularization performed using posterior inferior cerebellar artery-posterior inferior cerebellar artery bypass. Report of four cases and literature review. *J Neurosurg* 2002;97(1):219-23.
 276. Mericle RA, Reig AS, Burry MV, Eskioglu E, Firment CS, Santra S. Endovascular surgery for proximal posterior inferior cerebellar artery aneurysms: an analysis of Glasgow Outcome Score by Hunt-Hess Grades. *Neurosurgery* 2006;58(4):619-25; discussion -25.
 277. Lewis SB, Chang DJ, Peace DA, Lafrentz PJ, Day AL. Distal posterior inferior cerebellar artery aneurysms: clinical features and management. *J Neurosurg* 2002;97(4):756-66.
 278. Horiuchi T, Tanaka Y, Hongo K, Nitta J, Kusano Y, Kobayashi S. Characteristics of distal posterior inferior cerebellar artery aneurysms. *Neurosurgery* 2003;53(3):589-95; discussion 95-6.
 279. Orakcioglu B, Schuknecht B, Otani N, Khan N, Imhof HG, Yonekawa Y. Distal posterior inferior cerebellar artery aneurysms: Clinical characteristics and surgical management. *Acta Neurochir (Wien)* 2005;147(11):1131-9.
 280. Dermbach PD, Sila CA, Little JR. Giant and multiple aneurysms of the distal posterior inferior cerebellar artery. *Neurosurgery* 1988;22(2):309-12.
 281. Heros RC. Posterior inferior cerebellar artery. *J Neurosurg* 2002;97(4):747-8; discussion 8.
 282. Werner S, Blakemore A, King B. Aneurysm of the internal carotid artery within the skull: wiring and electrothermic coagulation. *JAMA* 1941;116:578-82.

283. Mullan S, Raimondi AJ, Dobben G, Vailati G, Hekmatpanah J. Electrically induced thrombosis in intracranial aneurysms. *J Neurosurg* 1965;22(6):539-47.
284. Gallagher JP. Obliteration of intracranial aneurysms by pilojection. *JAMA* 1963;183:231-6.
285. Alksne JF, Fingerhut AG. Magnetically controlled metallic thrombosis of intracranial aneurysms. A preliminary report. *Bull Los Angeles Neurol Soc* 1965;30(3):153-5.
286. Laesslehop AJ, Velasquez AC. Observations on the Tolerance of the Intracranial Arteries to Catheterization. *J Neurosurg* 1964;21:85-91.
287. Teitelbaum GP, Larsen DW, Zelman V, Lysachev AG, Likhterman LB. A tribute to Dr. Fedor A. Serbinenko, founder of endovascular neurosurgery. *Neurosurgery* 2000;46(2):462-9; discussion 9-70.
288. Serbinenko FA. Balloon catheterization and occlusion of major cerebral vessels. *J Neurosurg* 1974;41(2):125-45.
289. Debrun G, Lacour P, Caron JP, Hurth M, Comoy J, Keravel Y. Detachable balloon and calibrated-leak balloon techniques in the treatment of cerebral vascular lesions. *J Neurosurg* 1978;49(5):635-49.
290. Hieshima GB, Grinnell VS, Mehlinger CM. A detachable balloon for therapeutic transcatheter occlusions. *Radiology* 1981;138(1):227-8.
291. Kwan ES, Heilman CB, Shucart WA, Klucznik RP. Enlargement of basilar artery aneurysms following balloon occlusion--"water-hammer effect". Report of two cases. *J Neurosurg* 1991;75(6):963-8.
292. Gianturco C, Anderson JH, Wallace S. Mechanical devices for arterial occlusion. *Am J Roentgenol Radium Ther Nucl Med* 1975;124(3):428-35.
293. Higashida RT, Halbach VV, Dowd CF, Barnwell SL, Hieshima GB. Interventional neurovascular treatment of a giant intracranial aneurysm using platinum microcoils. *Surg Neurol* 1991;35(1):64-8.
294. Hilal SK, Solomon RA. Endovascular treatment of aneurysms with coils. *J Neurosurg* 1992;76(2):337-9.
295. Moret J, Cognard C, Weill A, Castaing L, Rey A. [Reconstruction technic in the treatment of wide-neck intracranial aneurysms. Long-term angiographic and clinical results. Apropos of 56 cases]. *J Neuroradiol* 1997;24(1):30-44.
296. Adams HP Jr, Gordon DL. Nonaneurysmal subarachnoid hemorrhage. *Ann Neurol* 1991;29(5):461-2.
297. Stranjalis G, Korfiatis S, Vemmos KN, Sakas DE. Spontaneous subarachnoid hemorrhage in the era of transition from surgery to embolization. A study of the overall outcome. *Br J Neurosurg* 2005;19(5):389-94.
298. Flaherty ML, Haverbusch M, Kissela B, et al. Perimesencephalic Subarachnoid Hemorrhage: Incidence, Risk Factors, and Outcome. *J Stroke Cerebrovasc Dis* 2005;14(6):267-71.
299. Schwartz TH, Mayer SA. Quadrigeminal variant of perimesencephalic nonaneurysmal subarachnoid hemorrhage. *Neurosurgery* 2000;46(3):584-8.
300. van der Schaaf IC, Velthuis BK, Gouw A, Rinkel GJ. Venous drainage in perimesencephalic hemorrhage. *Stroke* 2004;35(7):1614-8.
301. Wijedicks EF, Schievink WI, Miller GM. Pretruncal nonaneurysmal subarachnoid hemorrhage. *Mayo Clin Proc* 1998;73(8):745-52.
302. Rinkel GJ, van Gijn J, Wijedicks EF. Subarachnoid hemorrhage without detectable aneurysm. A review of the causes. *Stroke* 1993;24(9):1403-9.
303. Linn FHH, Rinkel GJE, Algra A, van Gijn J. Incidence of Subarachnoid Hemorrhage: Role of Region, Year, and Rate of Computed Tomography: A Meta-Analysis. *Stroke* 1996;27(4):625-9.
304. Menghini VV, Brown RD, Jr., Sicks JD, O'Fallon WM, Wiebers DO. Incidence and prevalence of intracranial aneurysms and hemorrhage in Olmsted County, Minnesota, 1965 to 1995. *Neurology* 1998;51(2):405-11.
305. Labovitz DL, Halim AX, Brent B, Boden-Albala B, Hauser WA, Sacco RL. Subarachnoid Hemorrhage Incidence among Whites, Blacks and Caribbean Hispanics: The Northern Manhattan Study. *Neuroepidemiology* 2006;26(3):147-50.
306. Mayberg MR, Batjer HH, Dacey R, et al. Guidelines for the management of aneurysmal subarachnoid hemorrhage. A statement for healthcare professionals from a special writing group of the Stroke Council, American Heart Association. *Stroke* 1994;25(11):2315-28.
307. van Gijn J, Rinkel GJE. Subarachnoid haemorrhage: diagnosis, causes and management. *Brain* 2001;124(2):249-78.
308. Polmear A. Sentinel headaches in aneurysmal subarachnoid haemorrhage: what is the true incidence? A systematic review. *Cephalalgia* 2003;23(10):935-41.
309. Frizzell RT, Kuhn F, Morris R, Quinn C, Fisher WS, 3rd. Screening for ocular hemorrhages in patients with ruptured cerebral aneurysms: a prospective study of 99 patients. *Neurosurgery* 1997;41(3):529-33; discussion 33-4.
310. Pfaußler B, Beclé R, Metzler R, Mohsenipour I, Schmutzhard E. Terson's syndrome in spontaneous subarachnoid hemorrhage: a prospective study in 60 consecutive patients. *J Neurosurg* 1996;85(3):392-4.
311. McCarron MO, Alberts MJ, McCarron P. A systematic review of Terson's syndrome: frequency and prognosis after subarachnoid haemorrhage. *J Neurol Neurosurg Psychiatry* 2004;75(3):491-3.
312. Tsementzis SA, Williams A. Ophthalmological signs and prognosis in patients with a subarachnoid haemorrhage. *Neurochirurgia (Stuttg)* 1984;27(5):133-5.
313. Pinto AN, Canhao P, Ferro JM. Seizures at the onset of subarachnoid haemorrhage. *J Neurol* 1996;243(2):161-4.
314. Edlow JA, Wyer PC. Evidence-based emergency medicine/clinical question. How good is a negative cranial computed tomographic scan result in excluding subarachnoid hemorrhage? *Ann Emerg Med* 2000;36(5):507-16.
315. Bambakidis N, Selman W. Subarachnoid hemorrhage. In: Suarez JJ, ed. *Critical Care Neurology and Neurosurgery*. Totowa, N.J.: Humana Press; 2004:365-77.
316. Vermeulen M, van Gijn J. The diagnosis of subarachnoid haemorrhage. *J Neurol Neurosurg Psychiatry* 1990;53(5):365-72.
317. Heasley DC, Mohamed MA, Yousem DM. Clearing of Red Blood Cells in Lumbar Puncture Does Not Rule Out Ruptured Aneurysm in Patients with Suspected Subarachnoid Hemorrhage but Negative Head CT Findings. *AJNR Am J Neuroradiol* 2005;26(4):820-4.
318. Villablanca JP, Jahan R, Hooshi P, et al. Detection and Characterization of Very Small Cerebral Aneurysms by Using 2D and 3D Helical CT Angiography. *AJNR Am J Neuroradiol* 2002;23(7):1187-98.
319. Jayaraman MV, Mayo-Smith WW, Tung GA, et al. Detection of Intracranial Aneurysms: Multi-Detector Row CT Angiography Compared with DSA. *Radiology* 2004;230(2):510-8.
320. Rogg JM, Smeaton S, Doberstein C, Goldstein JH, Tung GA, Haas RA. Assessment of the value of MR imaging for examining patients with angiographically negative subarachnoid hemorrhage. *AJR Am J Roentgenol* 1999;172(1):201-6.
321. Suarez JJ, Tarr RW, Selman WR. Aneurysmal subarachnoid hemorrhage. *N Engl J Med* 2006;354(4):387-96.
322. Hunt WE, Hess RM. Surgical risk as related to time of intervention in the repair of intracranial aneurysms. *J Neurosurg* 1968;28(1):14-20.
323. Fisher CM, Kistler JP, Davis JM. Relation of cerebral vasospasm to subarachnoid hemorrhage visualized by computerized tomographic scanning. *Neurosurgery* 1980;6(1):1-9.
324. Johnston SC, Selvin S, Gress DR. The burden, trends, and demographics of mortality from subarachnoid hemorrhage. *Neurology* 1998;50(5):1413-8.
325. Qureshi AI, Suri MF, Nasar A, et al. Trends in hospitalization and mortality for subarachnoid hemorrhage and unruptured aneurysms in the United States. *Neurosurgery* 2005;57(1):1-8; discussion 1-8.
326. Fischer T, Johnsen SP, Pedersen L, Gaist D, Sorensen HT, Rothman KJ. Seasonal variation in hospitalization and case fatality of subarachnoid hemorrhage - a nationwide danish study on 9,367 patients. *Neuroepidemiology* 2005;24(1-2):32-7.
327. Stegmayr B, Eriksson M, Asplund K. Declining Mortality From Subarachnoid Hemorrhage: Changes in Incidence

- and Case Fatality From 1985 Through 2000. *Stroke* 2004;35(9):2059-63.
328. Juvola S, Porras M, Heiskanen O. Natural history of unruptured intracranial aneurysms: a long-term follow-up study. *J Neurosurg* 1993;79(2):174-82.
 329. Tsutsumi K, Ueki K, Morita A, Kirino T. Risk of rupture from incidental cerebral aneurysms. *J Neurosurg* 2000;93(4):550-3.
 330. Broderick JP, Brott TG, Duldner JE, Tomsick T, Leach A. Initial and recurrent bleeding are the major causes of death following subarachnoid hemorrhage. *Stroke* 1994;25(7):1342-7.
 331. Schievink WL, Wijidicks EF, Piegras DG, Chu CP, O'Fallon WM, Whisnant JP. The poor prognosis of ruptured intracranial aneurysms of the posterior circulation. *J Neurosurg* 1995;82(5):791-5.
 332. Hop JW, Rinkel GI, Algra A, van Gijn J. Case-fatality rates and functional outcome after subarachnoid hemorrhage: a systematic review. *Stroke* 1997;28(3):660-4.
 333. Ogunbo B, Gregson BA, Blackburn A, Mendelow AD. Trends over time in the management of subarachnoid haemorrhage in newcastle: review of 1609 patients. *Br J Neurosurg* 2001;15(5):388-95.
 334. Kassell NF, Torner JC. Aneurysmal rebleeding: a preliminary report from the Cooperative Aneurysm Study. *Neurosurgery* 1983;13(5):479-81.
 335. Inagawa T, Kamiya K, Ogasawara H, Yano T. Rebleeding of ruptured intracranial aneurysms in the acute stage. *Surg Neurol* 1987;28(2):93-9.
 336. Fujii Y, Takeuchi S, Sasaki O, Minakawa T, Koike T, Tanaka R. Ultra-early rebleeding in spontaneous subarachnoid hemorrhage. *J Neurosurg* 1996;84(1):35-42.
 337. Brilstra EH, Rinkel GI, Algra A, van Gijn J. Rebleeding, secondary ischemia, and timing of operation in patients with subarachnoid hemorrhage. *Neurology* 2000;55(11):1656-60.
 338. Steiger HJ, Fritsch J, Seiler RW. Current pattern of in-hospital aneurysmal rebleeds. Analysis of a series treated with individually timed surgery and intravenous nimodipine. *Acta Neurochir (Wien)* 1994;127(1-2):21-6.
 339. Khurana VG, Piegras DG, Whisnant JP. Ruptured giant intracranial aneurysms. Part I. A study of rebleeding. *J Neurosurg* 1998;88(3):425-9.
 340. Naidech AM, Janjua N, Kreiter KT, et al. Predictors and impact of aneurysm rebleeding after subarachnoid hemorrhage. *Arch Neurol* 2005;62(3):410-6.
 341. Hijdra A, Vermeulen M, van Gijn J, van Crevel H. Rupture of intracranial aneurysms: a clinicoanatomic study. *J Neurosurg* 1987;67(1):29-33.
 342. Juvola S. Rebleeding from ruptured intracranial aneurysms. *Surg Neurol* 1989;32(5):323-6.
 343. Dunn CJ, Goa KL. Tranexamic acid: a review of its use in surgery and other indications. *Drugs* 1999;57(6):1005-32.
 344. Fodstad H, Liliequist B, Schannong M, Thulin CA. Tranexamic acid in the preoperative management of ruptured intracranial aneurysms. *Surg Neurol* 1978;10(1):9-15.
 345. Kassell NF, Torner JC, Adams HP, Jr. Antifibrinolytic therapy in the acute period following aneurysmal subarachnoid hemorrhage. Preliminary observations from the Cooperative Aneurysm Study. *J Neurosurg* 1984;61(2):225-30.
 346. Mullan S, Dawley J. Antifibrinolytic therapy for intracranial aneurysms. *J Neurosurg* 1968;28(1):21-3.
 347. Vermeulen M, Lindsay KW, Murray GD, et al. Antifibrinolytic treatment in subarachnoid hemorrhage. *N Engl J Med* 1984;311(7):432-7.
 348. Vermeulen M, van Gijn J, Hijdra A, van Crevel H. Causes of acute deterioration in patients with a ruptured intracranial aneurysm. A prospective study with serial CT scanning. *J Neurosurg* 1984;60(5):935-9.
 349. Burchiel KJ, Hoffman JM, Bakay RA. Quantitative determination of plasma fibrinolytic activity in patients with ruptured intracranial aneurysms who are receiving epsilon-aminocaproic acid: relationship of possible complications of therapy to the degree of fibrinolytic inhibition. *Neurosurgery* 1984;14(1):57-63.
 350. Fodstad H, Pilbrant A, Schannong M, Stromberg S. Determination of tranexamic acid (AMCA) and fibrin/fibrinogen degradation products in cerebrospinal fluid after aneurysmal subarachnoid haemorrhage. *Acta Neurochir (Wien)* 1981;58(1-2):1-13.
 351. Leipzig TJ, Redelman K, Horner TG. Reducing the risk of rebleeding before early aneurysm surgery: a possible role for antifibrinolytic therapy. *J Neurosurg* 1997;86(2):220-5.
 352. Hillman J, Fridriksson S, Nilsson O, Yu Z, Saveland H, Jakobsson KE. Immediate administration of tranexamic acid and reduced incidence of early rebleeding after aneurysmal subarachnoid hemorrhage: a prospective randomized study. *J Neurosurg* 2002;97(4):771-8.
 353. Haley EC, Jr, Kassell NF, Torner JC. The International Cooperative Study on the Timing of Aneurysm Surgery. The North American experience. *Stroke* 1992;23(2):205-14.
 354. Ohman J, Heiskanen O. Timing of operation for ruptured supratentorial aneurysms: a prospective randomized study. *J Neurosurg* 1989;70(1):55-60.
 355. Chyatte D, Fode NC, Sundt TM, Jr. Early versus late intracranial aneurysm surgery in subarachnoid hemorrhage. *J Neurosurg* 1988;69(3):326-31.
 356. van Gijn J, Hijdra A, Wijidicks EF, Vermeulen M, van Crevel H. Acute hydrocephalus after aneurysmal subarachnoid hemorrhage. *J Neurosurg* 1985;63(3):355-62.
 357. Hasan D, Tanghe HL. Distribution of cisternal blood in patients with acute hydrocephalus after subarachnoid hemorrhage. *Ann Neurol* 1992;31(4):374-8.
 358. Suarez-Rivera O. Acute hydrocephalus after subarachnoid hemorrhage. *Surg Neurol* 1998;49(5):563-5.
 359. Dehdashti AR, Rilliet B, Rufenacht DA, de Tribolet N. Shunt-dependent hydrocephalus after rupture of intracranial aneurysms: a prospective study of the influence of treatment modality. *J Neurosurg* 2004;101(3):402-7.
 360. Hasan D, Vermeulen M, Wijidicks EF, Hijdra A, van Gijn J. Management problems in acute hydrocephalus after subarachnoid hemorrhage. *Stroke* 1989;20(6):747-53.
 361. Graff-Radford NR, Torner J, Adams HP, Jr, Kassell NF. Factors associated with hydrocephalus after subarachnoid hemorrhage. A report of the Cooperative Aneurysm Study. *Arch Neurol* 1989;46(7):744-52.
 362. Pare L, Delfino R, Leblanc R. The relationship of ventricular drainage to aneurysmal rebleeding. *J Neurosurg* 1992;76(3):422-7.
 363. Voldby B, Enevoldsen EM. Intracranial pressure changes following aneurysm rupture. Part 3: Recurrent hemorrhage. *J Neurosurg* 1982;56(6):784-9.
 364. Klopfenstein JD, Kim LJ, Feiz-Erfan I, et al. Comparison of rapid and gradual weaning from external ventricular drainage in patients with aneurysmal subarachnoid hemorrhage: a prospective randomized trial. *J Neurosurg* 2004;100(2):225-9.
 365. Hasan D, Schonck RS, Avezaat CJ, Tanghe HL, van Gijn J, van der Lugt PJ. Epileptic seizures after subarachnoid hemorrhage. *Ann Neurol* 1993;33(3):286-91.
 366. Baker CJ, Prestigiacomo CJ, Solomon RA. Short-term perioperative anticonvulsant prophylaxis for the surgical treatment of low-risk patients with intracranial aneurysms. *Neurosurgery* 1995;37(5):863-70; discussion 70-1.
 367. Rhoney DH, Tipps LB, Murry KR, Basham MC, Michael DB, Coplin WM. Anticonvulsant prophylaxis and timing of seizures after aneurysmal subarachnoid hemorrhage. *Neurology* 2000;55(2):258-65.
 368. Naidech AM, Kreiter KT, Janjua N, et al. Phenytoin Exposure Is Associated With Functional and Cognitive Disability After Subarachnoid Hemorrhage. *Stroke* 2005;36(3):583-7.
 369. Sheih I, Tamas LB, O'Laioire SA. Epilepsy after operation for aneurysms. *Neurosurgery* 1986;19(5):784-8.
 370. Claassen J, Peery S, Kreiter KT, et al. Predictors and clinical impact of epilepsy after subarachnoid hemorrhage. *Neurology* 2003;60(2):208-14.
 371. Lin CL, Dumont AS, Lieu AS, et al. Characterization of perioperative seizures and epilepsy following aneurysmal subarachnoid hemorrhage. *J Neurosurg* 2003;99(6):978-85.
 372. Solenski NJ, Haley EC, Jr, Kassell NF, et al. Medical complications of aneurysmal subarachnoid hemorrhage: a report of the multicenter, cooperative aneurysm study. Participants of the Multicenter Cooperative Aneurysm Study. *Crit Care Med* 1995;23(6):1007-17.

373. Wartenberg KE, Mayer SA. Medical complications after subarachnoid hemorrhage: new strategies for prevention and management. *Curr Opin Crit Care* 2006;12(2):78-84.
374. Dohout Mees SM, van Dijk GW, Algra A, Kempink DRJ, Rinkel GJE. Glucose levels and outcome after subarachnoid hemorrhage. *Neurology* 2003;61(8):1132-3.
375. Wartenberg KE, Schmidt JM, Claassen J, et al. Impact of medical complications on outcome after subarachnoid hemorrhage. *Crit Care Med* 2006;34(3):617-23; quiz 24.
376. Frontera JA, Fernandez A, Claassen J, et al. Hyperglycemia after SAH: predictors, associated complications, and impact on outcome. *Stroke* 2006;37(1):199-203.
377. Woo E, Ma JT, Robinson JD, Yu YL. Hyperglycemia is a stress response in acute stroke. *Stroke* 1988;19(11):1359-64.
378. Capes SE, Hunt D, Malmberg K, Pathak P, Gerstein HC. Stress Hyperglycemia and Prognosis of Stroke in Nondiabetic and Diabetic Patients: A Systematic Overview. *Stroke* 2001;32(10):2426-32.
379. Allport LE, Butcher KS, Baird TA, et al. Insular Cortical Ischemia Is Independently Associated With Acute Stress Hyperglycemia. *Stroke* 2004;35(8):1886-91.
380. Parsons MW, Barber PA, Desmond PM, et al. Acute hyperglycemia adversely affects stroke outcome: a magnetic resonance imaging and spectroscopy study. *Ann Neurol* 2002;52(1):20-8.
381. Baird TA, Parsons MW, Phan T, et al. Persistent Poststroke Hyperglycemia Is Independently Associated With Infarct Expansion and Worse Clinical Outcome. *Stroke* 2003;34(9):2208-14.
382. Ste-Marie L, Hazell AS, Bemeur C, Butterworth R, Montgomery J. Immunohistochemical detection of inducible nitric oxide synthase, nitrotyrosine and manganese superoxide dismutase following hyperglycemic focal cerebral ischemia. *Brain Res* 2001;918(1-2):10-9.
383. Kawai N, Keep RF, Betz AL, Dietrich WD. Hyperglycemia and the Vascular Effects of Cerebral Ischemia. *Stroke* 1997;28(1):149-54.
384. Van den Berghe G, Wouters P, Weekers F, et al. Intensive Insulin Therapy in Critically Ill Patients. *N Engl J Med* 2001;345(19):1359-67.
385. Hasan D, Wijidicks EF, Vermeulen M. Hyponatremia is associated with cerebral ischemia in patients with aneurysmal subarachnoid hemorrhage. *Ann Neurol* 1990;27(1):106-8.
386. Kurokawa Y, Ueda T, Ishiguro M, et al. Pathogenesis of hyponatremia following subarachnoid hemorrhage due to ruptured cerebral aneurysm. *Surg Neurol* 1996;46(5):500-7; discussion 7-8.
387. Qureshi AI, Suri MF, Sung GY, et al. Prognostic significance of hypernatremia and hyponatremia among patients with aneurysmal subarachnoid hemorrhage. *Neurosurgery* 2002;50(4):749-55; discussion 55-6.
388. Sherlock M, O'Sullivan E, Agha A, et al. The incidence and pathophysiology of hyponatraemia after subarachnoid haemorrhage. *Clin Endocrinol (Oxf)* 2006;64(3):250-4.
389. Moringa K, Hayashi S, Matsumoto Y, et al. [Hyponatremia and cerebral vasospasm in patients with aneurysmal subarachnoid hemorrhage]. *No To Shinkei* 1992;44(7):629-32.
390. Moro N, Katayama Y, Kojima J, Mori T, Kawamata T. Prophylactic Management of Excessive Natriuresis With Hydrocortisone for Efficient Hypervolemic Therapy After Subarachnoid Hemorrhage. *Stroke* 2003;34(12):2807-11.
391. Nelson RJ, Roberts J, Rubin C, Walker V, Ackery DM, Pickard JD. Association of hypovolemia after subarachnoid hemorrhage with computed tomographic scan evidence of raised intracranial pressure. *Neurosurgery* 1991;29(2):178-82.
392. Wijidicks EF, Vandongen KJ, Vangjin J, Hijdra A, Vermeulen M. Enlargement of the third ventricle and hyponatraemia in aneurysmal subarachnoid haemorrhage. *J Neurol Neurosurg Psychiatry* 1988;51(4):516-20.
393. Harrigan MR. Cerebral salt wasting syndrome. *Crit Care Clin* 2001;17(1):125-38.
394. Wijidicks EF, Vermeulen M, ten Haaf JA, Hijdra A, Bakker WH, van Gijn J. Volume depletion and natriuresis in patients with a ruptured intracranial aneurysm. *Ann Neurol* 1985;18(2):211-6.
395. McGirt MJ, Blessing R, Nimjee SM, et al. Correlation of serum brain natriuretic peptide with hyponatremia and delayed ischemic neurological deficits after subarachnoid hemorrhage. *Neurosurgery* 2004;54(6):1369-73; discussion 73-4.
396. Berendes E, Walter M, Cullen P, et al. Secretion of brain natriuretic peptide in patients with aneurysmal subarachnoid haemorrhage. *Lancet* 1997;349(9047):245-9.
397. Tomida M, Muraki M, Uemura K, Yamasaki K. Plasma Concentrations of Brain Natriuretic Peptide in Patients With Subarachnoid Hemorrhage. *Stroke* 1998;29(8):1584-7.
398. Tung PP, Olmsted E, Kopelnik A, et al. Plasma B-Type Natriuretic Peptide Levels Are Associated With Early Cardiac Dysfunction After Subarachnoid Hemorrhage. *Stroke* 2005;36(7):1567-9.
399. Sviri GE, Feinsod M, Soustiel JF. Brain Natriuretic Peptide and Cerebral Vasospasm in Subarachnoid Hemorrhage: Clinical and TCD Correlations. *Stroke* 2000;31(1):118-22.
400. Takahashi K, Totsune K, Sone M, et al. Human brain natriuretic peptide-like immunoreactivity in human brain. *Peptides* 1992;13(1):121-3.
401. Takaku A, Shindo K, Tanaka S, Mori T, Suzuki J. Fluid and electrolyte disturbances in patients with intracranial aneurysms. *Surg Neurol* 1979;11(5):349-56.
402. van den Bergh WM, Algra A, Rinkel GJE. Electrocardiographic Abnormalities and Serum Magnesium in Patients With Subarachnoid Hemorrhage. *Stroke* 2004;35(3):644-8.
403. Andreoli A, di Pasquale G, Pinelli G, Grazi P, Tognetti F, Testa C. Subarachnoid hemorrhage: frequency and severity of cardiac arrhythmias. A survey of 70 cases studied in the acute phase. *Stroke* 1987;18(3):558-64.
404. Fukui S, Otani N, Katoh H, et al. Female gender as a risk factor for hypokalemia and QT prolongation after subarachnoid hemorrhage. *Neurology* 2002;59(1):134-6.
405. Fukui S, Katoh H, Tsuzuki N, et al. Multivariate analysis of risk factors for QT prolongation following subarachnoid hemorrhage. *Crit Care* 2003;7(3):R7-R12.
406. Machado C, Baga JJ, Kawasaki R, Reinhoel J, Steinman RT, Lehmann MH. Torsade de pointes as a complication of subarachnoid hemorrhage: a critical reappraisal. *J Electrocardiol* 1997;30(1):31-7.
407. van den Bergh WM, Algra A, van der Sprenkel JW, Tulkenen CA, Rinkel GJ. Hypomagnesemia after aneurysmal subarachnoid hemorrhage. *Neurosurgery* 2003;52(2):276-81; discussion 81-2.
408. Collignon FP, Friedman JA, Piepgras DG, et al. Serum magnesium levels as related to symptomatic vasospasm and outcome following aneurysmal subarachnoid hemorrhage. *Neurocrit Care* 2004;1(4):441-8.
409. Brouwers PJ, Wijidicks EF, Hasan D, et al. Serial electrocardiographic recording in aneurysmal subarachnoid hemorrhage. *Stroke* 1989;20(9):1162-7.
410. Marion DW, Segal R, Thompson ME. Subarachnoid hemorrhage and the heart. *Neurosurgery* 1986;18(1):101-6.
411. Manninen PH, Ayra B, Gelb AW, Pelz D. Association between electrocardiographic abnormalities and intracranial blood in patients following acute subarachnoid hemorrhage. *J Neurosurg Anesthesiol* 1995;7(1):12-6.
412. Kuroiwa T, Morita H, Tanabe H, Ohta T. Significance of ST segment elevation in electrocardiograms in patients with ruptured cerebral aneurysms. *Acta Neurochir (Wien)* 1995;133(3-4):141-6.
413. Zaroff JG, Rordorf GA, Newell JB, Ogilvy CS, Levinson JR. Cardiac outcome in patients with subarachnoid hemorrhage and electrocardiographic abnormalities. *Neurosurgery* 1999;44(1):34-9; discussion 9-40.
414. Mayer SA, Lin J, Homma S, et al. Myocardial Injury and Left Ventricular Performance After Subarachnoid Hemorrhage. *Stroke* 1999;30(4):780-6.
415. Svigelj V, Grad A, Tekavcic I, Kiauta T. Cardiac arrhythmia associated with reversible damage to insula in a patient with subarachnoid hemorrhage. *Stroke* 1994;25(5):1053-5.
416. Fink JN, Selim MH, Kumar S, Veitsch B, Fong WC, Caplan LR. Insular Cortex Infarction in Acute Middle Cerebral Artery Territory Stroke: Predictor of Stroke Severity and Vascular Lesion. *Arch Neurol* 2005;62(7):1081-5.

417. Lanzino G, Kongable GL, Kassell NF. Electrocardiographic abnormalities after nontraumatic subarachnoid hemorrhage. *J Neurosurg Anesthesiol* 1994;6(3):156-62.
418. Kono T, Morita H, Kuroiwa T, Onaka H, Takatsuka H, Fujiwara A. Left ventricular wall motion abnormalities in patients with subarachnoid hemorrhage: neurogenic stunned myocardium. *J Am Coll Cardiol* 1994;24(3):636-40.
419. Tung P, Kopelnik A, Banki N, et al. Predictors of Neurocardiogenic Injury After Subarachnoid Hemorrhage. *Stroke* 2004;35(2):548-51.
420. Sato K, Masuda T, Izumi T. Subarachnoid hemorrhage and myocardial damage clinical and experimental studies. *Jpn Heart J* 1999;40(6):683-701.
421. Naredi S, Lambert G, Eden E, et al. Increased Sympathetic Nervous Activity in Patients With Nontraumatic Subarachnoid Hemorrhage. *Stroke* 2000;31(4):901-6.
422. Banki NM, Kopelnik A, Dae MW, et al. Acute Neurocardiogenic Injury After Subarachnoid Hemorrhage. *Circulation* 2005;112(21):3314-9.
423. Yuki K, Kodama Y, Onda J, Emoto K, Morimoto T, Uozumi T. Coronary vasospasm following subarachnoid hemorrhage as a cause of stunned myocardium. Case report. *J Neurosurg* 1991;75(2):308-11.
424. Naidech AM, Kreiter KT, Janjua N, et al. Cardiac Troponin Elevation, Cardiovascular Morbidity, and Outcome After Subarachnoid Hemorrhage. *Circulation* 2005;112(18):2851-6.
425. Schuiling WJ, Dennesen PJW, Tans JJJ, Kingma LM, Algra A, Rinkel GJE. Troponin I in predicting cardiac or pulmonary complications and outcome in subarachnoid haemorrhage. *J Neurol Neurosurg Psychiatry* 2005;76(11):1565-9.
426. Parr MJA, Finfer SR, Morgan MK. Lesson of the Week: Reversible cardiogenic shock complicating subarachnoid haemorrhage. *BMJ* 1996;313(7058):681-3.
427. Jain R, Deveikis J, Thompson BG. Management of Patients with Stunned Myocardium Associated with Subarachnoid Hemorrhage. *AJNR Am J Neuroradiol* 2004;25(1):126-9.
428. Naval NS, Stevens RD, Mirski MA, Bhardwaj A. Controversies in the management of aneurysmal subarachnoid hemorrhage. *Crit Care Med* 2006;34(2):511-24.
429. Levy ML, Rabb CH, Zelman V, Giannotta SL. Cardiac performance enhancement from dobutamine in patients refractory to hypervolemic therapy for cerebral vasospasm. *J Neurosurg* 1993;79(4):494-9.
430. Apostolides PJ, Greene KA, Zabramski JM, Fitzgerald JW, Spetzler RF. Intra-aortic balloon pump counterpulsation in the management of concomitant cerebral vasospasm and cardiac failure after subarachnoid hemorrhage: technical case report. *Neurosurgery* 1996;38(5):1056-9; discussion 9-60.
431. Friedman JA, Pichelmann MA, Piegras DG, et al. Pulmonary complications of aneurysmal subarachnoid hemorrhage. *Neurosurgery* 2003;52(5):1025-31; discussion 31-2.
432. Kahn JM, Caldwell EC, Deem S, Newell DW, Heckbert SR, Rubenfeld GD. Acute lung injury in patients with subarachnoid hemorrhage: incidence, risk factors, and outcome. *Crit Care Med* 2006;34(1):196-202.
433. Smith WS, Matthay MA. Evidence for a hydrostatic mechanism in human neurogenic pulmonary edema. *Chest* 1997;111(5):1326-33.
434. Kopelnik A, Fisher L, Miss JC, et al. Prevalence and implications of diastolic dysfunction after subarachnoid hemorrhage. *Neurocrit Care* 2005;3(2):132-8.
435. Macmillan CS, Grant IS, Andrews PJ. Pulmonary and cardiac sequelae of subarachnoid haemorrhage: time for active management? *Intensive Care Med* 2002;28(8):1012-23.
436. Knudsen F, Jensen HP, Petersen PL. Neurogenic pulmonary edema: treatment with dobutamine. *Neurosurgery* 1991;29(2):269-70.
437. Vorkapic P, Bevan JA, Bevan RD. Longitudinal in vivo and in vitro time-course study of chronic cerebrovasospasm in the rabbit basilar artery. *Neurosurg Rev* 1991;14(3):215-9.
438. Findley JM. Cerebral Vasospasm. In: Winn HR, ed. *Youmans Neurological Surgery*. Philadelphia: Saunders; 2004:1839-67.
439. Kassell NF, Sasaki T, Colohan AR, Nazar G. Cerebral vasospasm following aneurysmal subarachnoid hemorrhage. *Stroke* 1985;16(4):562-72.
440. Dorsch NW, King MT. A Review of Cerebral Vasospasm in Aneurysmal Subarachnoid Hemorrhage: Incidence and Effects. *Journal of Clinical Neuroscience* 1994;1:19-26.
441. Murayama Y, Malisch T, Guglielmi G, et al. Incidence of cerebral vasospasm after endovascular treatment of acutely ruptured aneurysms: report on 69 cases. *J Neurosurg* 1997;87(6):830-5.
442. Charpentier C, Audibert G, Guillemin F, et al. Multivariate Analysis of Predictors of Cerebral Vasospasm Occurrence After Aneurysmal Subarachnoid Hemorrhage. *Stroke* 1999;30(7):1402-8.
443. Macdonald RL. Management of cerebral vasospasm. In: *Neurosurgical Reviews*; 2006.
444. Findlay JM, Kassell NF, Weir BK, et al. A randomized trial of intraoperative, intracisternal tissue plasminogen activator for the prevention of vasospasm. *Neurosurgery* 1995;37(1):168-76; discussion 77-8.
445. Haley EC, Jr, Kassell NF, Apperson-Hansen C, Maile MH, Alves WM. A randomized, double-blind, vehicle-controlled trial of tirilazad mesylate in patients with aneurysmal subarachnoid hemorrhage: a cooperative study in North America. *J Neurosurg* 1997;86(3):467-74.
446. Kassell NF, Haley EC, Jr, Apperson-Hansen C, Alves WM. Randomized, double-blind, vehicle-controlled trial of tirilazad mesylate in patients with aneurysmal subarachnoid hemorrhage: a cooperative study in Europe, Australia, and New Zealand. *J Neurosurg* 1996;84(2):221-8.
447. Fisher CM, Roberson GH, Ojemann RG. Cerebral vasospasm with ruptured saccular aneurysm—the clinical manifestations. *Neurosurgery* 1977;1(3):245-8.
448. Weir B, Grace M, Hansen J, Rothberg C. Time course of vasospasm in man. *J Neurosurg* 1978;48(2):173-8.
449. Yamaguchi M, Bun T, Kuwahara T, Kitamura S. Very late-onset symptomatic cerebral vasospasm caused by a large residual aneurysmal subarachnoid hematoma—case report. *Neurol Med Chir (Tokyo)* 1999;39(9):677-80.
450. Kistler JP, Crowell RM, Davis KR, et al. The relation of cerebral vasospasm to the extent and location of subarachnoid blood visualized by CT scan: a prospective study. *Neurology* 1983;33(4):424-36.
451. Hijdra A, van Gijn J, Nagelkerke NJ, Vermeulen M, van Crevel H. Prediction of delayed cerebral ischemia, rebleeding, and outcome after aneurysmal subarachnoid hemorrhage. *Stroke* 1988;19(10):1250-6.
452. Claassen J, Bernardini GL, Kreiter K, et al. Effect of Cisternal and Ventricular Blood on Risk of Delayed Cerebral Ischemia After Subarachnoid Hemorrhage: The Fisher Scale Revisited. *Stroke* 2001;32(9):2012-20.
453. Conway JE, Tamargo RJ. Cocaine Use Is an Independent Risk Factor for Cerebral Vasospasm After Aneurysmal Subarachnoid Hemorrhage. *Stroke* 2001;32(10):2338-43.
454. Hoh BL, Topcuoglu MA, Singhal AB, et al. Effect of clipping, craniotomy, or intravascular coiling on cerebral vasospasm and patient outcome after aneurysmal subarachnoid hemorrhage. *Neurosurgery* 2004;55(4):779-86; discussion 86-9.
455. Rabinstein AA, Pichelmann MA, Friedman JA, et al. Symptomatic vasospasm and outcomes following aneurysmal subarachnoid hemorrhage: a comparison between surgical repair and endovascular coil occlusion. *J Neurosurg* 2003;98(2):319-25.
456. Schweickert WD, Gehlbach BK, Pohlman AS, Hall JB, Kress JP. Daily interruption of sedative infusions and complications of critical illness in mechanically ventilated patients. *Crit Care Med* 2004;32(6):1272-6.
457. Handa Y, Hayashi M, Takeuchi H, Kubota T, Kobayashi H, Kawano H. Time course of the impairment of cerebral autoregulation during chronic cerebral vasospasm after subarachnoid hemorrhage in primates. *J Neurosurg* 1992;76(3):493-501.
458. Yoon DY, Choi CS, Kim KH, Cho BM. Multidetector-Row CT Angiography of Cerebral Vasospasm after Aneurysmal Subarachnoid Hemorrhage: Comparison of Volume-Rendered Images and Digital Subtraction Angiography. *AJNR Am J Neuroradiol* 2006;27(2):370-7.
459. Wintermark M, Ko NU, Smith WS, Liu S, Higashida RT, Dillon WP. Vasospasm after Subarachnoid Hemorrhage:

- Utility of Perfusion CT and CT Angiography on Diagnosis and Management. *AJNR Am J Neuroradiol* 2006;27(1):26-34.
460. Harrigan MR, Leonardo J, Gibbons KJ, Guterman LR, Hopkins LN. CT perfusion cerebral blood flow imaging in neurological critical care. *Neurocrit Care* 2005;2(3):352-66.
461. Clyde BL, Resnick DK, Yonas H, Smith HA, Kaufmann AM. The relationship of blood velocity as measured by transcranial doppler ultrasonography to cerebral blood flow as determined by stable xenon computed tomographic studies after aneurysmal subarachnoid hemorrhage. *Neurosurgery* 1996;38(5):896-904; discussion -5.
462. Lysakowski C, Walder B, Costanza MC, Tramer MR. Transcranial Doppler Versus Angiography in Patients With Vasospasm due to a Ruptured Cerebral Aneurysm: A Systematic Review. *Stroke* 2001;32(10):2292-8.
463. Aaslid R, Huber P, Nornes H. Evaluation of cerebrovascular spasm with transcranial Doppler ultrasound. *J Neurosurg* 1984;60(1):37-41.
464. Burch CM, Wozniak MA, Sloan MA, et al. Detection of intracranial internal carotid artery and middle cerebral artery vasospasm following subarachnoid hemorrhage. *J Neuroimaging* 1996;6(1):8-15.
465. Kyoi K, Hashimoto H, Tokunaga H, et al. [Time course of blood velocity changes and clinical symptoms related to cerebral vasospasm and prognosis after aneurysmal surgery]. *No Shinkei Geka* 1989;17(1):21-30.
466. Wozniak MA, Sloan MA, Rothman MI, et al. Detection of vasospasm by transcranial Doppler sonography. The challenges of the anterior and posterior cerebral arteries. *J Neuroimaging* 1996;6(2):87-93.
467. Sloan MA, Burch CM, Wozniak MA, et al. Transcranial Doppler detection of vertebralbasilar vasospasm following subarachnoid hemorrhage. *Stroke* 1994;25(11):2187-97.
468. Lindegaard KF, Nornes H, Bakke SJ, Sorteberg W, Nakstad P. Cerebral vasospasm after subarachnoid haemorrhage investigated by means of transcranial Doppler ultrasound. *Acta Neurochir (Wien)* 1988;42:81-4.
469. Soustiel JF, Shik V, Shreiber R, Tavor Y, Goldsher D, Muizelaar JP. Basilar Vasospasm Diagnosis: Investigation of a Modified "Lindegaard Index" Based on Imaging Studies and Blood Velocity Measurements of the Basilar Artery * Editorial Comment: Investigation of a Modified "Lindegaard Index" Based on Imaging Studies and Blood Velocity Measurements of the Basilar Artery. *Stroke* 2002;33(1):72-8.
470. Allen GS, Ahn HS, Preziosi TJ, et al. Cerebral arterial spasm—a controlled trial of nimodipine in patients with subarachnoid hemorrhage. *N Engl J Med* 1983;308(11):619-24.
471. Barker FG, 2nd, Ogilvy CS. Efficacy of prophylactic nimodipine for delayed ischemic deficit after subarachnoid hemorrhage: a metaanalysis. *J Neurosurg* 1996;84(3):405-14.
472. Mee E, Dorrance D, Lowe D, Neil-Dwyer G. Controlled study of nimodipine in aneurysm patients treated early after subarachnoid hemorrhage. *Neurosurgery* 1988;22(3):484-91.
473. Ohman J, Heiskanen O. Effect of nimodipine on the outcome of patients after aneurysmal subarachnoid hemorrhage and surgery. *J Neurosurg* 1988;69(5):683-6.
474. Petruk KC, West M, Mohr G, et al. Nimodipine treatment in poor-grade aneurysm patients. Results of a multicenter double-blind placebo-controlled trial. *J Neurosurg* 1988;68(4):505-17.
475. Philippon J, Grob R, Dageou F, Guggiari M, Rivierez M, Viars P. Prevention of vasospasm in subarachnoid haemorrhage. A controlled study with nimodipine. *Acta Neurochir (Wien)* 1986;82(3-4):110-4.
476. Pickard JD, Murray GD, Illingworth R, et al. Effect of oral nimodipine on cerebral infarction and outcome after subarachnoid haemorrhage: British aneurysm nimodipine trial. *Bmj* 1989;298(6674):636-42.
477. Rinkel GJ, Feigin VL, Algra A, van den Bergh WM, Vermulen M, van Gijn J. Calcium antagonists for aneurysmal subarachnoid haemorrhage. *Cochrane Database Syst Rev* 2005(1):CD000277.
478. Wong MC, Haley EC, Jr. Calcium antagonists: stroke therapy coming of age. *Stroke* 1990;21(3):494-501.
479. Toyota BD. The efficacy of an abbreviated course of nimodipine in patients with good-grade aneurysmal subarachnoid hemorrhage. *J Neurosurg* 1999;90(2):203-6.
480. Para A, Kreiter KT, Williams S, et al. Effect of prior statin use on functional outcome and delayed vasospasm after acute aneurysmal subarachnoid hemorrhage: a matched controlled cohort study. *Neurosurgery* 2005;56(3):476-84; discussion -84.
481. Lynch JR, Wang H, McGirt MJ, et al. Simvastatin Reduces Vasospasm After Aneurysmal Subarachnoid Hemorrhage: Results of a Pilot Randomized Clinical Trial. *Stroke* 2005;36(9):2024-6.
482. Tseng MY, Czosnyka M, Richards H, Pickard JD, Kirkpatrick PJ. Effects of acute treatment with pravastatin on cerebral vasospasm, autoregulation, and delayed ischemic deficits after aneurysmal subarachnoid hemorrhage: a phase II randomized placebo-controlled trial. *Stroke* 2005;36(8):1627-32.
483. Tseng MY, Hutchinson PJ, Czosnyka M, Richards H, Pickard JD, Kirkpatrick PJ. Effects of acute pravastatin treatment on intensity of rescue therapy, length of inpatient stay, and 6-month outcome in patients after aneurysmal subarachnoid hemorrhage. *Stroke* 2007;38(5):1545-50.
484. Tseng MY, Hutchinson PJ, Turner CL, et al. Biological effects of acute pravastatin treatment in patients after aneurysmal subarachnoid hemorrhage: a double-blind, placebo-controlled trial. *J Neurosurg* 2007;107(6):1092-100.
485. Pfeffer MA, Keech A, Sacks FM, et al. Safety and tolerability of pravastatin in long-term clinical trials: prospective Pravastatin Pooling (PPP) Project. *Circulation* 2002;105(20):2341-6.
486. UpToDate. Pravastatin: Drug Information. In: Lexi-Comp, Inc.; 2007.
487. McGirt MJ, Pradilla G, Legnani FG, et al. Systemic administration of simvastatin after the onset of experimental subarachnoid hemorrhage attenuates cerebral vasospasm. *Neurosurgery* 2006;58(5):945-51; discussion -51.
488. Sterzer P, Meintzschel F, Rosler A, Lanfermann H, Steinmetz H, Sitzer M. Pravastatin improves cerebral vasomotor reactivity in patients with subcortical small-vessel disease. *Stroke* 2001;32(12):2817-20.
489. Klimo P, Jr., Kestle JR, MacDonald JD, Schmidt RH. Marked reduction of cerebral vasospasm with lumbar drainage of cerebrospinal fluid after subarachnoid hemorrhage. *J Neurosurg* 2004;100(2):215-24.
490. Marinov MB, Harbaugh KS, Hoopes PJ, Pikus HJ, Harbaugh RE. Neuroprotective effects of preischemia intraarterial magnesium sulfate in reversible focal cerebral ischemia. *J Neurosurg* 1996;85(1):117-24.
491. van den Bergh WM, Zuur JK, Kamerling NA, et al. Role of magnesium in the reduction of ischemic depolarization and lesion volume after experimental subarachnoid hemorrhage. *J Neurosurg* 2002;97(2):416-22.
492. Ram Z, Sadeh M, Shacked I, Sahar A, Hadani M. Magnesium sulfate reverses experimental delayed cerebral vasospasm after subarachnoid hemorrhage in rats. *Stroke* 1991;22(7):922-7.
493. Fawcett WJ, Haxby EJ, Male DA. Magnesium: physiology and pharmacology. *Br J Anaesth* 1999;83(2):302-20.
494. van den Bergh WM, on behalf of the MSG. Magnesium Sulfate in Aneurysmal Subarachnoid Hemorrhage: A Randomized Controlled Trial. *Stroke* 2005;36(5):1011-5.
495. Johnson JW, Ascher P. Voltage-dependent block by intracellular Mg²⁺ of N-methyl-D-aspartate-activated channels. *Biophys J* 1990;57(5):1085-90.
496. Rothman S. Synaptic release of excitatory amino acid neurotransmitter mediates anoxic neuronal death. *J Neurosci* 1984;4(7):1884-91.
497. Euser AG, Cipolla MJ. Resistance artery vasodilation to magnesium sulfate during pregnancy and the postpartum state. *Am J Physiol Heart Circ Physiol* 2005;288(4):H1521-5.
498. Origitano TC, Wascher TM, Reichman OH, Anderson DE. Sustained increased cerebral blood flow with prophylactic hypertensive hypervolemic hemodilution ("triple-H" therapy) after subarachnoid hemorrhage. *Neurosurgery* 1990;27(5):729-39; discussion 39-40.

499. Treggiari MM, Walder B, Suter PM, Romand JA. Systematic review of the prevention of delayed ischemic neurological deficits with hypertension, hypervolemia, and hemodilution therapy following subarachnoid hemorrhage. *J Neurosurg* 2003;98(5):978-84.
500. Lemmihan L, Mayer SA, Fink ME, et al. Effect of hypervolemic therapy on cerebral blood flow after subarachnoid hemorrhage: a randomized controlled trial. *Stroke* 2000;31(2):383-91.
501. Feigin VL, Rinkel GJ, Algra A, van Gijn J. Circulatory volume expansion for aneurysmal subarachnoid hemorrhage. *Cochrane Database Syst Rev* 2000(2):CD000483.
502. Rinkel GJ, Feigin VL, Algra A, van Gijn J. Circulatory volume expansion therapy for aneurysmal subarachnoid haemorrhage. *Cochrane Database Syst Rev* 2004(4):CD000483.
503. Egge A, Waterloo K, Sjöholm H, Solberg T, Ingebrigtsen T, Romer B. Prophylactic hyperdynamic postoperative fluid therapy after aneurysmal subarachnoid hemorrhage: a clinical, prospective, randomized, controlled study. *Neurosurgery* 2001;49(3):593-605; discussion 6.
504. Raabe A, Beck J, Berkefeld J, et al. [Recommendations for the management of patients with aneurysmal subarachnoid hemorrhage]. *Zentralbl Neurochir* 2005;66(2):79-91.
505. Kassell NF, Peerless SJ, Durward QJ, Beck DW, Drake CG, Adams HP. Treatment of ischemic deficits from vasospasm with intravascular volume expansion and induced arterial hypertension. *Neurosurgery* 1982;11(3):337-43.
506. Hoh BL, Carter BS, Ogilvy CS. Risk of hemorrhage from unsecured, unruptured aneurysms during and after hypertensive hypervolemic therapy. *Neurosurgery* 2002;50(6):1207-11; discussion 11-2.
507. Shimoda M, Oda S, Tsugane R, Sato O. Intracranial complications of hypervolemic therapy in patients with a delayed ischemic deficit attributed to vasospasm. *J Neurosurg* 1993;78(3):423-9.
508. Raabe A, Beck J, Keller M, Vatter H, Zimmermann M, Seifert V. Relative importance of hypertension compared with hypervolemia for increasing cerebral oxygenation in patients with cerebral vasospasm after subarachnoid hemorrhage. *J Neurosurg* 2005;103(6):974-81.
509. Giannotta SL, McGillicuddy JE, Kindt GW. Diagnosis and treatment of postoperative cerebral vasospasm. *Surg Neurol* 1977;8(4):286-90.
510. Awad IA, Carter LP, Spetzler RF, Medina M, Williams FC, Jr. Clinical vasospasm after subarachnoid hemorrhage: response to hypervolemic hemodilution and arterial hypertension. *Stroke* 1987;18(2):365-72.
511. Mayer SA, Solomon RA, Fink ME, et al. Effect of 5% albumin solution on sodium balance and blood volume after subarachnoid hemorrhage. *Neurosurgery* 1998;42(4):759-67; discussion 67-8.
512. Kosnik EJ, Hunt WE. Postoperative hypertension in the management of patients with intracranial arterial aneurysms. *J Neurosurg* 1976;45(2):148-54.
513. Rosenwasser RH, Delgado TE, Buchheit WA, Freed MH. Control of hypertension and prophylaxis against vasospasm in cases of subarachnoid hemorrhage: a preliminary report. *Neurosurgery* 1983;12(6):658-61.
514. Corsten L, Raja A, Guppy K, et al. Contemporary management of subarachnoid hemorrhage and vasospasm: the UIC experience. *Surg Neurol* 2001;56(3):140-8; discussion 8-50.
515. Joseph M, Ziadi S, Nates J, Dannenbaum M, Malkoff M. Increases in cardiac output can reverse flow deficits from vasospasm independent of blood pressure: a study using xenon computed tomographic measurement of cerebral blood flow. *Neurosurgery* 2003;53(5):1044-51; discussion 51-2.
516. Ekelund A, Reinstrup P, Ryding E, et al. Effects of iso- and hypervolemic hemodilution on regional cerebral blood flow and oxygen delivery for patients with vasospasm after aneurysmal subarachnoid hemorrhage. *Acta Neurochir (Wien)* 2002;144(7):703-12; discussion 12-3.
517. Asplund K, Israelsson K, Schampi I. Haemodilution for acute ischaemic stroke. *Cochrane Database Syst Rev* 2000(2):CD000103.
518. Allport LE, Parsons MW, Butcher KS, et al. Elevated hematocrit is associated with reduced reperfusion and tissue survival in acute stroke. *Neurology* 2005;65(9):1382-7.
519. Macdonald RL. Cerebral vasospasm. *Neurosurg Q* 1995;5:73-97.
520. Amin-Hanjani S, Schwartz RB, Sathi S, Stieg PE. Hypertensive encephalopathy as a complication of hyperdynamic therapy for vasospasm: report of two cases. *Neurosurgery* 1999;44(5):1113-6.
521. Rosenwasser RH, Jallo JI, Getch CC, Liebman KE. Complications of Swan-Ganz catheterization for hemodynamic monitoring in patients with subarachnoid hemorrhage. *Neurosurgery* 1995;37(5):872-5; discussion 5-6.
522. Mechanical and Pharmacologic Treatment of Vasospasm. *AJNR Am J Neuroradiol* 2001;22(9):0080:26S-7.
523. Zubkov AY, Lewis AI, Scalzo D, Bernanke DH, Harkey HL. Morphological changes after percutaneous transluminal angioplasty. *Surg Neurol* 1999;51(4):399-403.
524. Eskridge JM, Newell DW, Winn HR. Endovascular treatment of vasospasm. *Neurosurg Clin N Am* 1994;5(3):437-47.
525. Coyne TJ, Montanera WJ, Macdonald RL, Wallace MC. Percutaneous transluminal angioplasty for cerebral vasospasm after subarachnoid hemorrhage. *Can J Surg* 1994;37(5):391-6.
526. Bejjani GK, Bank WO, Olan WJ, Sekhar LN. The efficacy and safety of angioplasty for cerebral vasospasm after subarachnoid hemorrhage. *Neurosurgery* 1998;42(5):979-86; discussion 86-7.
527. Fujii Y, Takahashi A, Yoshimoto T. Effect of balloon angioplasty on high grade symptomatic vasospasm after subarachnoid hemorrhage. *Neurosurg Rev* 1995;18(1):7-13.
528. Rosenwasser RH, Armonda RA, Thomas JE, Benitez RP, Gannon PM, Harrop J. Therapeutic modalities for the management of cerebral vasospasm: timing of endovascular options. *Neurosurgery* 1999;44(5):975-9; discussion 9-80.
529. Higashida RT, Halbach VV, Cahan LD, et al. Transluminal angioplasty for treatment of intracranial arterial vasospasm. *J Neurosurg* 1989;71(5 Pt 1):648-53.
530. Murayama Y, Song JK, Uda K, et al. Combined Endovascular Treatment for Both Intracranial Aneurysm and Symptomatic Vasospasm. *AJNR Am J Neuroradiol* 2003;24(1):133-9.
531. Le Roux PD, Newell DW, Eskridge J, Mayberg MR, Winn HR. Severe symptomatic vasospasm: the role of immediate postoperative angioplasty. *J Neurosurg* 1994;80(2):224-9.
532. Jabbour P, Veznardaroglu E, Liebman K, Rosenwasser RH. Is radiographic ischemia a contraindication for angioplasty in subarachnoid hemorrhage? In: AANS Annual Meeting. San Francisco: American Association of Neurological Surgeons; 2006.
533. Muizelaar JP, Zwienerberg M, Rudisill NA, Hecht ST. The prophylactic use of transluminal balloon angioplasty in patients with Fisher Grade 3 subarachnoid hemorrhage: a pilot study. *J Neurosurg* 1999;91(1):51-8.
534. Badjatia N, Topcuoglu MA, Pryor JC, et al. Preliminary Experience with Intra-Arterial Nicardipine as a Treatment for Cerebral Vasospasm. *AJNR Am J Neuroradiol* 2004;25(5):819-26.
535. Biondi A, Ricciardi GK, Puybasset L, et al. Intra-arterial nimodipine for the treatment of symptomatic cerebral vasospasm after aneurysmal subarachnoid hemorrhage: preliminary results. *AJNR Am J Neuroradiol* 2004;25(6):1067-76.
536. Feng L, Fitzsimmons B-F, Young WL, et al. Intraarterially Administered Verapamil as Adjunct Therapy for Cerebral Vasospasm: Safety and 2-Year Experience. *AJNR Am J Neuroradiol* 2002;23(8):1284-90.
537. Kassell NF, Helm G, Simmons N, Phillips CD, Cail WS. Treatment of cerebral vasospasm with intra-arterial papaverine. *J Neurosurg* 1992;77(6):848-52.
538. Kaku Y, Yonekawa Y, Tsukahara T, Kazekawa K. Superselective intra-arterial infusion of papaverine for the treatment of cerebral vasospasm after subarachnoid hemorrhage. *J Neurosurg* 1992;77(6):842-7.
539. Vajkoczy P, Horn P, Bauhuf C, et al. Effect of Intra-Arterial Papaverine on Regional Cerebral Blood Flow in Hemodynamically Relevant Cerebral Vasospasm. *Stroke* 2001;32(2):498-505.
540. McAuliffe W, Townsend M, Eskridge JM, Newell DW, Grady MS, Winn HR. Intracranial pressure changes

- induced during papaverine infusion for treatment of vasospasm. *J Neurosurg* 1995;83(3):430-4.
541. Carhuapoma JR, Qureshi AI, Tamargo RJ, Mathis JM, Hanley DF. Intra-arterial papaverine-induced seizures: case report and review of the literature. *Surg Neurol* 2001;56(3):159-63.
 542. Barr JD, Mathis JM, Horton JA. Transient severe brain stem depression during intraarterial papaverine infusion for cerebral vasospasm. *AJNR Am J Neuroradiol* 1994;15(4):719-23.
 543. Smith SS, Dowd CF, Johnston SC, et al. Neurotoxicity of intra-arterial papaverine preserved with chlorbutanol used for the treatment of cerebral vasospasm after aneurysmal subarachnoid hemorrhage. *Stroke* 2004;35(11):2518-22.
 544. Elliott JP, Newell DW, Lam DJ, et al. Comparison of balloon angioplasty and papaverine infusion for the treatment of vasospasm following aneurysmal subarachnoid hemorrhage. *J Neurosurg* 1998;88(2):277-84.
 545. Suarez JJ, Zaidat OO, Suri MF, et al. Length of stay and mortality in neurocritically ill patients: impact of a specialized neurocritical care team. *Crit Care Med* 2004;32(11):2311-7.
 546. Finn SS, Stephensen SA, Miller CA, Drobnich L, Hunt WE. Observations on the perioperative management of aneurysmal subarachnoid hemorrhage. *J Neurosurg* 1986;65(1):48-62.
 547. Kasuya H, Kawashima A, Namiki K, Shimizu T, Takakura K. Metabolic profiles of patients with subarachnoid hemorrhage treated by early surgery. *Neurosurgery* 1998;42(6):1268-74; discussion 74-5.
 548. Suarez JJ, Shannon L, Zaidat OO, et al. Effect of human albumin administration on clinical outcome and hospital cost in patients with subarachnoid hemorrhage. *J Neurosurg* 2004;100(4):585-90.
 549. Flemming KD, Brown Jr RD, Wiebers DO. Subarachnoid Hemorrhage. *Curr Treat Options Neurol* 1999;1(2):97-112.
 550. Widjicks EFM. Aneurysmal subarachnoid hemorrhage. In: *The Clinical Practice of Critical Care Neurology*. 2nd ed. Oxford, UK: Oxford University Press; 2003:185-220.
 551. Black PM, Crowell RM, Abbott WM. External pneumatic calf compression reduces deep venous thrombosis in patients with ruptured intracranial aneurysms. *Neurosurgery* 1986;18(1):25-8.
 552. Harbaugh RE, Heros RC, Hadley MN. More on ISAT. *Lancet* 2003;361(9359):783-4; author reply 4.
 553. Khoo LT, Levy ML. Intracerebral aneurysms. In: Albright AL, Pollack IF, Adelson PD, eds. *Principles and Practice of Pediatric Neurosurgery*. New York: Thieme Medical Publishers; 1999.
 554. Huang J, McGirt MJ, Gailloud P, Tamargo RJ. Intracranial aneurysms in the pediatric population: case series and literature review. *Surg Neurol* 2005;63(5):424-32; discussion 32-3.
 555. Sanai N, Quinones-Hinojosa A, Gupta NM, et al. Pediatric intracranial aneurysms: durability of treatment following microsurgical and endovascular management. *J Neurosurg* 2006;104(2 Suppl):82-9.
 556. Laughlin S, terBrugge KG, Willinsky RA, Armstrong DC, Montanera WJ, Humphreys RP. Endovascular management of paediatric intracranial aneurysms. *Intervent Neuroradiol* 1997;3:205-14.
 557. Kanaan I, Lasjaunias P, Coates R. The spectrum of intracranial aneurysms in pediatrics. *Minim Invasive Neurosurg* 1995;38(1):1-9.
 558. Buis DR, van Ouwerkerk WJ, Takahata H, Vandertop WP. Intracranial aneurysms in children under 1 year of age: a systematic review of the literature. *Childs Nerv Syst* 2006.
 559. Batnitzky S, Muller J. Infantile and juvenile cerebral aneurysms. *Neuroradiology* 1978;16:61-4.
 560. Aryan HE, Giannotta SL, Fukushima T, Park MS, Ozgur BM, Levy ML. Aneurysms in children: Review of 15 years experience. *J Clin Neurosci* 2006;13(2):188-92.
 561. Ventureyra EC, Higgins MJ. Traumatic intracranial aneurysms in childhood and adolescence. Case reports and review of the literature. *Childs Nerv Syst* 1994;10(6):361-79.
 562. Ostergaard JR, Voldby B. Intracranial arterial aneurysms in children and adolescents. *J Neurosurg* 1983;58(6):822-7.
 563. Lasjaunias P, Wuppapapati S, Alvarez H, Rodesch G, Ozanne A. Intracranial aneurysms in children aged under 15 years: review of 59 consecutive children with 75 aneurysms. *Childs Nerv Syst* 2005;21(6):437-50.
 564. Sawin P. Spontaneous subarachnoid hemorrhage in pregnancy and the puerperium. In: Loftus C, ed. *Neurosurgical Aspects of Pregnancy*. Park Ridge, IL: American Association of Neurological Surgeons; 1996:85-99.
 565. Wiebers DO. Subarachnoid hemorrhage in pregnancy. *Semin Neurol* 1988;8(3):226-9.
 566. Robinson JL, Hall CI, Sedzimir CB. Subarachnoid hemorrhage in pregnancy. *J Neurosurg* 1972;36(1):27-33.
 567. Measurements NCoRPa, ed. *Recommendations on Limits for Exposure to Ionizing Radiation (NCRP Report No. 91)*. Bethesda, MD: National Council on Radiation Protection; 1987.
 568. Piper J. Fetal toxicity of common neurosurgical drugs. In: Loftus C, ed. *Neurosurgical Aspects of Pregnancy*. Park Ridge, IL: American Association of Neurological Surgeons; 1996:1-20.
 569. Dias MS, Sekhar LN. Intracranial hemorrhage from aneurysms and arteriovenous malformations during pregnancy and the puerperium. *Neurosurgery* 1990;27(6):855-65; discussion 65-6.
 570. Maymon R, Fejgin M. Intracranial hemorrhage during pregnancy and puerperium. *Obstet Gynecol Surv* 1990;45(3):157-9.
 571. Barrett JM, Van Hooydonk JE, Boehm FH. Pregnancy-related rupture of arterial aneurysms. *Obstet Gynecol Surv* 1982;37(9):557-66.
 572. Verweij RD, Wijdicks EF, van Gijn J. Warning headache in aneurysmal subarachnoid hemorrhage. A case-control study. *Arch Neurol* 1988;45(9):1019-20.
 573. Donnelly JF, Lock FR. Causes of death in five hundred thirty-three fatal cases of toxemia of pregnancy. *Am J Obstet Gynecol* 1954;68(1):184-90.
 574. Schwartz J. Pregnancy complicated by subarachnoid hemorrhage. *Am J Obstet Gynecol* 1951;62(3):539-47.
 575. Baro A, Freeman DW. Maternal deaths due to spontaneous subarachnoid hemorrhage. *Am J Obstet Gynecol* 1976;125(3):384-92.
 576. Hirsh J, Cade JF, Gallus AS. Anticoagulants in pregnancy: a review of indications and complications. *Am Heart J* 1972;83(3):301-5.
 577. Henderson CE, Torbey M. Rupture of intracranial aneurysm associated with cocaine use during pregnancy. *Am J Perinatol* 1988;5(2):142-3.
 578. Saleman M. Choriocarcinoma in pregnancy. In: Loftus C, ed. *Neurosurgical Aspects of Pregnancy*. Park Ridge, IL: American Association of Neurological Surgeons; 1996:147-55.
 579. Enomoto H, Goto H. Moyamoya disease presenting as intracerebral hemorrhage during pregnancy: case report and review of the literature. *Neurosurgery* 1987;20(1):33-5.
 580. Botterell EH, Cannell DE. Subarachnoid hemorrhage and pregnancy. *Am J Obstet Gynecol* 1956;72(4):844-55.
 581. Daane TA, Tandy RW. Rupture of congenital intracranial aneurysm in pregnancy. *Obstet Gynecol* 1960;15:305-14.
 582. Pool JL. Treatment of Intracranial Aneurysms During Pregnancy. *Jama* 1965;192:209-14.
 583. Lennon RL, Sundt TM, Jr., Gronert GA. Combined cesarean section and clipping of intracerebral aneurysm. *Anesthesiology* 1984;60(3):240-2.
 584. Meyers PM, Halbach VV, Malek AM, et al. Endovascular Treatment of Cerebral Artery Aneurysms during Pregnancy: Report of Three Cases. *AJNR Am J Neuroradiol* 2000;21(7):1306-11.
 585. Piotin M, de Souza Filho CB, Kothimbakam R, Moret J. Endovascular treatment of acutely ruptured intracranial aneurysms in pregnancy. *Am J Obstet Gynecol* 2001;185(5):1261-2.
 586. Kizilkilic O, Albayram S, Adaletli I, et al. Endovascular treatment of ruptured intracranial aneurysms during pregnancy: report of three cases. *Arch Gynecol Obstet* 2003;268(4):325-8.

587. Srinivasan K. Cerebral venous and arterial thrombosis in pregnancy and puerperium. A study of 135 patients. *Angiology* 1983;34(11):731-46.
588. Pedowitz P, Perell A. Aneurysms complicated by pregnancy. II. Aneurysms of the cerebral vessels. *Am J Obstet Gynecol* 1957;73(4):736-49.
589. Heikkinen JE, Rinne RI, Alahuhta SM, et al. Life support for 10 weeks with successful fetal outcome after fatal maternal brain damage. *Br Med J (Clin Res Ed)* 1985;290(6477):1237-8.
590. Stolz-Born G, Widder B, Born J. Vascular effects of oxytocin on human middle cerebral artery determined by transcranial Doppler sonography. *Regul Pept* 1996;62(1):37-9.
591. Suzuki Y, Satoh S, Kimura M, et al. Effects of vasopressin and oxytocin on canine cerebral circulation in vivo. *J Neurosurg* 1992;77(3):424-31.
592. Barker FG, 2nd, Amin-Hanjani S, Butler WE, et al. Age-dependent differences in short-term outcome after surgical or endovascular treatment of unruptured intracranial aneurysms in the United States, 1996-2000. *Neurosurgery* 2004;54(1):18-28; discussion 30.
593. Chung RY, Carter BS, Norbush A, Budzik R, Putnam C, Ogilvy CS. Management outcomes for ruptured and unruptured aneurysms in the elderly. *Neurosurgery* 2000;47(4):827-32; discussion 32-3.
594. Bradac GB, Bergui M, Fontanella M. Endovascular treatment of cerebral aneurysms in elderly patients. *Neuroradiology* 2005;47(12):938-41.
595. Cai Y, Spelle L, Wang H, et al. Endovascular treatment of intracranial aneurysms in the elderly: single-center experience in 63 consecutive patients. *Neurosurgery* 2005;57(6):1096-102; discussion 102.
596. Inagawa T. Trends in incidence and case fatality rates of aneurysmal subarachnoid hemorrhage in Izumo City, Japan, between 1980-1989 and 1990-1998. *Stroke* 2001;32(7):1499-507.
597. Lanzino G, Kassell NF, Germanson TP, et al. Age and outcome after aneurysmal subarachnoid hemorrhage: why do older patients fare worse? *J Neurosurg* 1996;85(3):410-8.
598. Sedat J, Dib M, Lonjon M, et al. Endovascular treatment of ruptured intracranial aneurysms in patients aged 65 years and older: follow-up of 52 patients after 1 year. *Stroke* 2002;33(11):2620-5.
599. Nieuwkamp DJ, Rinkel GJE, Silva R, Greebe P, Schokking DA, Ferro JM. Subarachnoid haemorrhage in patients older than 75 years: clinical course, treatment and outcome. *J Neurol Neurosurg Psychiatry* 2006;77:084350.
600. Takeuchi J. Aneurysm surgery in patients over the age of 80 years. *Br J Neurosurg* 1993;7(3):307-9.
601. Lan Q, Ikeda H, Jimbo H, Izumiya H, Matsumoto K. Considerations on surgical treatment for elderly patients with intracranial aneurysms. *Surg Neurol* 2000;53(3):231-8.
602. Fereh R, Pasqualin A, Barone G, Pinna G, Bricolo A. Surgical management of ruptured aneurysms in the eighth and ninth decades. *Acta Neurochir (Wien)* 2003;145(6):439-45; discussion 45.
603. Jain R, Deveikis J, Thompson BG. Endovascular Management of Poor-Grade Aneurysmal Subarachnoid Hemorrhage in the Geriatric Population. *AJNR Am J Neuroradiol* 2004;25(4):596-600.
604. Church W. Aneurysm of the right cerebral artery in a boy of thirteen. *Trans Pathol Soc Lond* 1869;20:109.
605. Osler W. Gulstonian lectures on malignant endocarditis. *Lancet* 1885;1:415-8, 505-8.
606. Clare CE, Barrow DL. Infectious intracranial aneurysms. *Neurosurg Clin N Am* 1992;3(3):551-66.
607. Chun JY, Smith W, Halbach VV, Higashida RT, Wilson CB, Lawton MT. Current multimodality management of infectious intracranial aneurysms. *Neurosurgery* 2001;48(6):1203-13; discussion 13-4.
608. Herman JM, Rekate HL, Spetzler RF. Pediatric intracranial aneurysms: simple and complex cases. *Pediatr Neurosurg* 1991;17(2):66-72; discussion 3.
609. Bohmfalk GL, Story JL, Wissinger JP, Brown WE, Jr. Bacterial intracranial aneurysm. *J Neurosurg* 1978;48(3):369-82.
610. Lerner PI. Neurologic complications of infective endocarditis. *Med Clin North Am* 1985;69(2):385-98.
611. Phuong LK, Link M, Wijdicks E. Management of intracranial infectious aneurysms: a series of 16 cases. *Neurosurgery* 2002;51(5):1145-51; discussion 51-2.
612. Yao KC, Bederson JB. Infectious Intracranial Aneurysms. In: Winn HR, ed. *Youmans Neurological Surgery*. Philadelphia: Saunders; 2004:2101-6.
613. Ojemann RG. Surgical management of bacterial intracranial aneurysms. In: Schmidek HH, Sweet WH, eds. *Operative Neurosurgical Techniques*. New York: Grune & Stratton; 1988:997-1001.
614. Kojima Y, Saito A, Kim I. The role of serial angiography in the management of bacterial and fungal intracranial aneurysms—report of two cases and review of the literature. *Neurol Med Chir (Tokyo)* 1989;29(3):202-16.
615. Molinari GF, Smith L, Goldstein MN, Satran R. Pathogenesis of cerebral mycotic aneurysms. *Neurology* 1973;23(4):325-32.
616. Hurst RW, Judkins A, Bolger W, Chu A, Loevner LA. Mycotic Aneurysm and Cerebral Infarction Resulting from Fungal Sinusitis: Imaging and Pathologic Correlation. *AJNR Am J Neuroradiol* 2001;22(5):858-63.
617. Pruitt AA, Rubin RH, Karchmer AW, Duncan GW. Neurologic complications of bacterial endocarditis. *Medicine (Baltimore)* 1978;57(4):329-43.
618. Morawetz RB, Karp RB. Evolution and resolution of intracranial bacterial (mycotic) aneurysms. *Neurosurgery* 1984;15(1):43-9.
619. Barrow DL, Prats AR. Infectious intracranial aneurysms: comparison of groups with and without endocarditis. *Neurosurgery* 1990;27(4):562-72; discussion 72-3.
620. Cloft HJ, Kallmes DF, Jensen ME, Lanzino G, Dion JE. Endovascular treatment of ruptured, peripheral cerebral aneurysms: parent artery occlusion with short Guglielmi detachable coils. *AJNR Am J Neuroradiol* 1999;20(2):308-10.
621. Frizzell RT, Vitek JJ, Hill DL, Fisher WS, 3rd. Treatment of a bacterial (mycotic) intracranial aneurysm using an endovascular approach. *Neurosurgery* 1993;32(5):852-4.
622. Rout D, Sharma A, Mohan PK, Rao VR. Bacterial aneurysms of the intracavernous carotid artery. *J Neurosurg* 1984;60(6):1236-42.
623. Hutchinson J. Aneurysms of the internal carotid within the skull diagnosed 11 years before the patient's death: Spontaneous cure. *Trans Clin Soc (Lond)* 1987;8:127.
624. Choi IS, David C. Giant intracranial aneurysms: development, clinical presentation and treatment. *European Journal of Radiology* 2003;46(3):178-94.
625. Schubiger O, Valavanis A, Wichmann W. Growth-mechanism of giant intracranial aneurysms; demonstration by CT and MR imaging. *Neuroradiology* 1987;29(3):266-71.
626. Koyama S, Kotani A, Sasaki J. Giant basilar artery aneurysm with intramural hemorrhage and then disastrous hemorrhage: case report. *Neurosurgery* 1996;39(1):174-7; discussion 7-8.
627. Nagahiro S, Takada A, Goto S, Kai Y, Ushio Y. Thrombosed growing giant aneurysms of the vertebral artery: growth mechanism and management. *J Neurosurg* 1995;82(5):796-801.
628. Lawton MT, Spetzler RF. Surgical strategies for giant intracranial aneurysms. *Neurosurg Clin N Am* 1998;9(4):725-42.
629. Lemole J, G.M., Henn JS, Spetzler RF, Riina HA. Giant Aneurysms. In: Winn HR, ed. *Youmans Neurological Surgery*. Philadelphia: Saunders; 2004:2079-99.
630. Pia HW, Zierski J. Giant cerebral aneurysms. *Neurosurg Rev* 1982;5(4):117-48.
631. Ausman JI, Diaz FG, Sadasivan B, Gonzales-Portillo M, Jr, Malik GM, Deopujari CE. Giant intracranial aneurysm surgery: the role of microvascular reconstruction. *Surg Neurol* 1990;34(1):8-15.
632. Gruber A, Killer M, Bavinszki G, Riehling B. Clinical and angiographic results of endosaccular coiling treatment of giant and very large intracranial aneurysms: a 7-year, single-center experience. *Neurosurgery* 1999;45(4):793-803; discussion 4.

633. Drake CG, Peerless SJ. Giant fusiform intracranial aneurysms: review of 120 patients treated surgically from 1965 to 1992. *J Neurosurg* 1997;87(2):141-62.
634. Raymond LA, Tew J. Large suprasellar aneurysms imitating pituitary tumour. *J Neurol Neurosurg Psychiatry* 1978;41(1):83-7.
635. Bokemeyer C, Frank B, Brandis A, Weirich W. Giant aneurysm causing frontal lobe syndrome. *J Neurol* 1990;237(1):47-50.
636. Lownie SP, Drake CG, Peerless SJ, Ferguson GG, Pelz DM. Clinical presentation and management of giant anterior communicating artery region aneurysms. *J Neurosurg* 2000;92(2):267-77.
637. Michael WF. Posterior fossa aneurysms simulating tumours. *J Neurol Neurosurg Psychiatry* 1974;37(2):218-23.
638. Kodama N, Suzuki J. Surgical treatment of giant aneurysms. *Neurosurg Rev* 1982;5(4):155-60.
639. Barrow DL, Alleyne C. Natural history of giant intracranial aneurysms and indications for intervention. *Clin Neurosurg* 1995;42:214-44.
640. Gobin YP, Vinuela F, Gurián JH, et al. Treatment of large and giant fusiform intracranial aneurysms with Guglielmi detachable coils. *J Neurosurg* 1996;84(1):55-62.
641. Otsuka G, Miyachi S, Handa T, et al. Endovascular trapping of giant serpentine aneurysms by using Guglielmi detachable coils: successful reduction of mass effect. Report of two cases. *J Neurosurg* 2001;94(5):836-40.
642. Ross IB, Weill A, Ptiotin M, Moret J. Endovascular treatment of distally located giant aneurysms. *Neurosurgery* 2000;47(5):1147-52; discussion 52-3.
643. Malisch TW, Guglielmi G, Vinuela F, et al. Intracranial aneurysms treated with the Guglielmi detachable coil: mid-term clinical results in a consecutive series of 100 patients. *J Neurosurg* 1997;87(2):176-83.
644. Higashida RT, Smith W, Gress D, et al. Intravascular stent and endovascular coil placement for a ruptured fusiform aneurysm of the basilar artery. Case report and review of the literature. *J Neurosurg* 1997;87(6):944-9.
645. Islak C, Kocer N, Albayram S, Kizilkilic O, Uzma O, Cokyüksel O. Bare Stent-Graft Technique: A New Method of Endoluminal Vascular Reconstruction for the Treatment of Giant and Fusiform Aneurysms. *AJNR Am J Neuroradiol* 2002;23(9):1589-95.
646. Yamaura A, Ono J, Hirai S. Clinical picture of intracranial non-traumatic dissecting aneurysm. *Neuropathology* 2000;20(1):85-90.
647. Kurino M, Yoshioka S, Ushio Y. Spontaneous dissecting aneurysms of anterior and middle cerebral artery associated with brain infarction: a case report and review of the literature. *Surg Neurol* 2002;57(6):428-36; discussion 36-8.
648. Mizutani T, Kojima H. Clinicopathological features of non-atherosclerotic cerebral arterial trunk aneurysms. *Neuropathology* 2000;20(1):91-7.
649. Okuchi K, Watabe Y, Hiramatsu K, et al. Dissecting aneurysm of the vertebral artery as a cause of Wallenberg's syndrome (in Japanese with English abstract). *No Shinkei Geka* 1990;18(8):721-7.
650. Ojemann RG, Fisher CM, Rich JC. Spontaneous dissecting aneurysm of the internal carotid artery. *Stroke* 1972;3(4):434-40.
651. Bhattacharya RN, Menon G, Nair S. Dissecting intracranial vertebral artery aneurysms. *Neurol India* 2001;49(4):391-4.
652. Nagahiro S, Hamada J, Sakamoto Y, Ushio Y. Follow-up evaluation of dissecting aneurysms of the vertebrobasilar circulation by using gadolinium-enhanced magnetic resonance imaging. *J Neurosurg* 1997;87(3):385-90.
653. Mizutani T, Kojima H, Asamoto S, Miki Y. Pathological mechanism and three-dimensional structure of cerebral dissecting aneurysms. *J Neurosurg* 2001;94(5):712-7.
654. Sasaki O, Ogawa H, Koike T, Koizumi T, Tanaka R. A clinicopathological study of dissecting aneurysms of the intracranial vertebral artery. *J Neurosurg* 1991;75(6):874-82.
655. Clower BR, Sullivan DM, Smith RR. Intracranial vessels lack vasa vasorum. *J Neurosurg* 1984;61(1):44-8.
656. Tuna M, Gocer AI, Ozel S, Bagdatoglu H, Zorludemir S, Hacıyakupoglu S. A giant dissecting aneurysm mimicking serpentine aneurysm angiographically. Case report and review of the literature. *Neurosurg Rev* 1998;21(4):284-9.
657. Mizutani T, Aruga T, Kirino T, Miki Y, Saito I, Tsuchida T. Recurrent subarachnoid hemorrhage from untreated ruptured vertebrobasilar dissecting aneurysms. *Neurosurgery* 1995;36(5):905-11; discussion 12-3.
658. Yuki I, Murayama Y, Vinuela F. Endovascular management of dissecting vertebrobasilar artery aneurysms in patients presenting with acute subarachnoid hemorrhage. *J Neurosurg* 2005;103(4):649-55.
659. Benndorf G, Herbon U, Sollmann WP, Campi A. Treatment of a Ruptured Dissecting Vertebral Artery Aneurysm with Double Stent Placement: Case Report. *AJNR Am J Neuroradiol* 2001;22(10):1844-8.
660. Chiaradio JC, Guzman L, Padilla L, Chiaradio MP. Intravascular graft stent treatment of a ruptured fusiform dissecting aneurysm of the intracranial vertebral artery: technical case report. *Neurosurgery* 2002;50(1):213-6; discussion 6-7.
661. Hayes WT, Bernhardt H, Young JM. Fusiform arteriosclerotic aneurysm of the basilar artery. Five cases including two ruptures. *Vasc Surg* 1967;1(3):171-8.
662. Housepian EM, Pool JL. A systematic analysis of intracranial aneurysms from the autopsy file of the Presbyterian Hospital, 1914 to 1956. *J Neuropathol Exp Neurol* 1958;17(3):409-23.
663. Yu YL, Moseley IF, Pullicino P, McDonald WI. The clinical picture of ectasia of the intracerebral arteries. *J Neurol Neurosurg Psychiatry* 1982;45(1):29-36.
664. Segal HD, McLaurin RL. Giant serpentine aneurysm. Report of two cases. *J Neurosurg* 1977;46(1):115-20.
665. Anson JA, Lawton MT, Spetzler RF. Characteristics and surgical treatment of dolichoectatic and fusiform aneurysms. *J Neurosurg* 1996;84(2):185-93.
666. Nishizaki T, Tamaki N, Takeda N, Shirakuni T, Kondoh T, Matsumoto S. Dolichoectatic basilar artery: a review of 23 cases. *Stroke* 1986;17(6):1277-81.
667. Flemming KD, Wiebers DO, Brown RD, Jr., et al. Prospective risk of hemorrhage in patients with vertebrobasilar nonsaccular intracranial aneurysm. *J Neurosurg* 2004;101(1):82-7.
668. Little JR, St Louis P, Weinstein M, Dohn DF. Giant fusiform aneurysm of the cerebral arteries. *Stroke* 1981;12(2):183-8.
669. Suzuki S, Takahashi T, Ohkuma H, Shimizu T, Fujita S. Management of giant serpentine aneurysms of the middle cerebral artery—review of literature and report of a case successfully treated by STA-MCA anastomosis only. *Acta Neurochir (Wien)* 1992;117(1-2):23-9.
670. Flemming KD, Wiebers DO, Brown RD, Jr., et al. The natural history of radiographically defined vertebrobasilar nonsaccular intracranial aneurysms. *Cerebrovasc Dis* 2005;20(4):270-9.
671. Resta M, Gentile MA, Di Cuozzo F, Vinjau E, Brindicci D, Carella A. Clinical-angiographic correlations in 132 patients with megadolichovertebrobasilar anomaly. *Neuroradiology* 1984;26(3):213-6.
672. Rozario RA, Levine HL, Scott RM. Obstructive hydrocephalus secondary to an ectatic basilar artery. *Surg Neurol* 1978;9(1):31-4.
673. Nakatomi H, Segawa H, Kurata A, et al. Clinicopathological Study of Intracranial Fusiform and Dolichoectatic Aneurysms: Insight on the Mechanism of Growth. *Stroke* 2000;31(4):896-900.
674. Shimoji T, Bando K, Nakajima K, Ito K. Dissecting aneurysm of the vertebral artery. Report of seven cases and angiographic findings. *J Neurosurg* 1984;61(6):1038-46.
675. Caplan LR, Baquis GD, Pessin MS, et al. Dissection of the intracranial vertebral artery. *Neurology* 1988;38(6):868-77.
676. Mizutani T, Aruga T. "Dolichoectatic" intracranial vertebrobasilar dissecting aneurysm. *Neurosurgery* 1992;31(4):765-73; discussion 73.
677. Sacks JG, Lindenburg R. Dolicho-ectatic intracranial arteries: symptomatology and pathogenesis of arterial elongation and distention. *Johns Hopkins Med J* 1969;125(2):95-106.

678. Nijensohn DE, Saez RJ, Reagan TJ. Clinical significance of basilar artery aneurysms. *Neurology* 1974;24(4):301-5.
679. Hegedus K. Ectasia of the basilar artery with special reference to possible pathogenesis. *Surg Neurol* 1985;24(4):463-9.
680. Ubogu EE, Zaidat OO. Vertebrobasilar dolichoectasia diagnosed by magnetic resonance angiography and risk of stroke and death: a cohort study. *J Neurol Neurosurg Psychiatry* 2004;75(1):22-6.
681. Mawad ME, Klucznik RP. Giant serpentine aneurysms: radiographic features and endovascular treatment. *AJNR Am J Neuroradiol* 1995;16(5):1053-60.
682. Benoit BG, Wortzman G. Traumatic cerebral aneurysms. Clinical features and natural history. *J Neurol Neurosurg Psychiatry* 1973;36(1):127-38.
683. Parkinson D, West M. Traumatic intracranial aneurysms. *J Neurosurg* 1980;52(1):11-20.
684. Giannotta SL, Gruen P. Vascular complications of head trauma. In: Barrow DL, ed. *Complications and Sequelae of Head Injury*. Park Ridge, IL: American Association of Neurological Surgeons; 1992:31-49.
685. Uzan M, Cantasdemir M, Seckin MS, et al. Traumatic intracranial carotid tree aneurysms. *Neurosurgery* 1998;43(6):1314-20; discussion 20-2.
686. Aarabi B. Management of traumatic aneurysms caused by high-velocity missile head wounds. *Neurosurg Clin N Am* 1995;6(4):775-97.
687. Steinmetz H, Heiss E, Mironov A. Traumatic giant aneurysms of the intracranial carotid artery presenting long after head injury. *Surg Neurol* 1988;30(4):305-10.
688. Nishioka T, Maeda Y, Tomogane Y, Nakano A, Arita N. Unexpected delayed rupture of the vertebral-posterior inferior cerebellar artery aneurysms following closed head injury. *Acta Neurochir (Wien)* 2002;144(8):839-45; discussion 45.
689. Buckingham MJ, Crone KR, Ball WS, Tomsick TA, Berger TS, Tew JM, Jr. Traumatic intracranial aneurysms in childhood: two cases and a review of the literature. *Neurosurgery* 1988;22(2):398-408.
690. Sadar ES, Jane JA, Lewis LW, Adelman LS. Traumatic aneurysms of the intracranial circulation. *Surg Gynecol Obstet* 1973;137(1):59-67.
691. Teal JS, Bergeron RT, Rumbaugh CL, Segall HD. Aneurysms of the petrous or cavernous portions of the internal carotid artery associated with nonpenetrating head trauma. *J Neurosurg* 1973;38(5):568-74.
692. Resnick DK, Subach BR, Marion DW. The significance of carotid canal involvement in basilar cranial fracture. *Neurosurgery* 1997;40(6):1177-81.
693. Haddad FS, Haddad GF, Taha J. Traumatic intracranial aneurysms caused by missiles: their presentation and management. *Neurosurgery* 1991;28(1):1-7.
694. Holmes B, Harbaugh RE. Traumatic intracranial aneurysms: a contemporary review. *J Trauma* 1993;35(6):855-60.
695. Luo C-B, Teng MM-H, Chang F-C, Lim J-F, Chang C-Y. Endovascular Management of the Traumatic Cerebral Aneurysms Associated with Traumatic Carotid Cavernous Fistulas. *AJNR Am J Neuroradiol* 2004;25(3):501-5.
696. Horowitz MB, Kopitnik TA, Landreneau F, et al. Multidisciplinary approach to traumatic intracranial aneurysms secondary to shotgun and handgun wounds. *Surgical Neurology* 1999;51(1):31-42.
697. Eisenberg HM, Gary HE, Jr, Aldrich EF, et al. Initial CT findings in 753 patients with severe head injury. A report from the NIH Traumatic Coma Data Bank. *J Neurosurg* 1990;73(5):688-98.
698. Kakarieka A, Braakman R, Schakel EH. Clinical significance of the finding of subarachnoid blood on CT scan after head injury. *Acta Neurochir (Wien)* 1994;129(1-2):1-5.
699. Mattioli C, Beretta L, Gerevini S, et al. Traumatic subarachnoid hemorrhage on the computerized tomography scan obtained at admission: a multicenter assessment of the accuracy of diagnosis and the potential impact on patient outcome. *J Neurosurg* 2003;98(1):37-42.
700. Servadei F, Murray GD, Teasdale GM, et al. Traumatic subarachnoid hemorrhage: demographic and clinical study of 750 patients from the European brain injury consortium survey of head injuries. *Neurosurgery* 2002;50(2):261-7; discussion 7-9.
701. Gomez PA, Lobato RD, Ortega JM, De La Cruz J. Mild head injury: differences in prognosis among patients with a Glasgow Coma Scale score of 13 to 15 and analysis of factors associated with abnormal CT findings. *Br J Neurosurg* 1996;10(5):453-60.
702. Shackford SR, Wald SL, Ross SE, et al. The clinical utility of computed tomographic scanning and neurologic examination in the management of patients with minor head injuries. *J Trauma* 1992;33(3):385-94.
703. Macpherson P, Graham DI. Correlation between angiographic findings and the ischaemia of head injury. *J Neurol Neurosurg Psychiatry* 1978;41(2):122-7.
704. Oertel M, Boscardin WJ, Obrist WD, et al. Posttraumatic vasospasm: the epidemiology, severity, and time course of an underestimated phenomenon: a prospective study performed in 299 patients. *J Neurosurg* 2005;103(5):812-24.
705. Fukuda T, Hasue M, Ito H. Does traumatic subarachnoid hemorrhage caused by diffuse brain injury cause delayed ischemic brain damage? Comparison with subarachnoid hemorrhage caused by ruptured intracranial aneurysms. *Neurosurgery* 1998;43(5):1040-9.
706. Macmillan CS, Wild JM, Wardlaw JM, Andrews PJ, Marshall I, Easton VJ. Traumatic brain injury and subarachnoid hemorrhage: in vivo occult pathology demonstrated by magnetic resonance spectroscopy may not be "ischaemic". A primary study and review of the literature. *Acta Neurochir (Wien)* 2002;144(9):853-62; discussion 62.
707. Langham J, Goldfrad C, Teasdale G, Shaw D, Rowan K. Calcium channel blockers for acute traumatic brain injury. *Cochrane Database Syst Rev* 2003(4):CD000565.
708. Cairns CJ, Finfer SR, Harrington TJ, Cook R. Papaverine angioplasty to treat cerebral vasospasm following traumatic subarachnoid haemorrhage. *Anaesth Intensive Care* 2003;31(1):87-91.

14. Arteriovenous Malformations

Arteriovenous malformations (AVMs) are congenital vascular lesions that may appear throughout the central nervous system. They consist of direct connections between arteries and veins, without an intervening capillary bed. They are believed to be about one-tenth as common as intracranial aneurysms. Spinal AVMs are discussed in Chap. 20. Vein of Galen malformations are a separate entity and are discussed in the Appendix to this chapter.

14.1. Pathophysiology

14.1.1. Pathology

1. Gross appearance
 - (a) Intracranial AVMs often resemble a ball of red and blue noodles, described by Cushing and Bailey as a *snarl* of tangled vessels.¹
 - (b) AVMs are frequently pyramidal-shaped lesions, with the base at and parallel to the cortical surface and the apex directed toward the ventricle.
 - (c) The nidus may be compact or diffuse, and range in size from several millimeters to an entire hemisphere.
 - (d) The adjacent brain parenchyma may be hemosiderin-stained from previous hemorrhage, and the over-lying meninges may be thickened and fibrotic.² Extensive gliosis, fibrosis, and calcification may be present.
2. Histopathological features
 - (a) Arteries
 - AVM arteries are abnormally dilated, with marked thinning in some regions and degeneration or absence of the media and elastic lamina.³
 - Degenerative changes are present, presumably due to wall shear stress caused by high flow.² These include irregular thickening of the vessel wall in some regions, endothelial proliferation, medial hypertrophy, and multilaminated, thickened basal laminae.⁴
 - (b) Nidus
 - Nidal vessels may contain a hypertrophic media, blurring the distinction between arteries and veins.
 - Aneurysms and islands of sclerotic tissue may be present within the nidus.
 - (c) Veins
 - “Arterialized” veins may exhibit thickening of the vein wall due to cellular proliferation.²
 - Although thickened AVM veins may grossly resemble arteries, they lack an organized elastic lamina and therefore are not truly arterial structures.
 - (d) Functional brain tissue is usually not present within an AVM, although in diffuse lesions, AVM vessels may be separated by normal tissue.

14.1.2. Etiology

1. AVMs are assumed to appear during fetal development between the fourth and eighth weeks of life.
 - (a) However, some evidence suggests that AVMs may develop later in life, as AVMs are rarely detected in utero⁵ or found in infants.⁶ One hypothesis maintains that AVMs first appear in utero but then continue to grow after birth.⁵
2. The precise etiology of AVMs is unclear. Some theories:

- (a) AVMs represent persistent direct connections between arteries and veins within the primitive vascular plexus.
- (b) AVMs are dynamic and result from a derangement in vessel growth, i.e., a "proliferative capillaropathy."⁷
- (c) AVMs result from a dysfunction of the remodeling process at the junction between capillaries and veins.⁸
- (d) AVMs may represent fistualized cerebral venous angiomas.⁹

14.1.2.1. Physiology

1. Hemodynamic characteristics
 - (a) AVMs are typically high-flow, low-resistance systems.¹⁰
 - (b) *Steal phenomenon*. In some cases, high-flow diversion of blood flow through an unruptured AVM is believed to produce symptoms by reducing perfusion in adjacent normal brain tissue.¹¹ Steal, as a mechanism of symptoms, is thought to be very rare or nonexistent.
 - Regional CBF surrounding the lesion may be reduced.¹²
 - Adaptive changes in autoregulation in peri-lesional brain tissue may occur.¹³
 - *Evidence against steal phenomenon*: In a prospective study of 152 patients with unruptured AVMs, only 2 (1.3%) had focal neurological symptoms possibly attributable to steal phenomenon.¹⁴ TCD examinations showed no relation between feeding artery pressure or flow velocities and neurological deficits; the authors took these findings as evidence against steal as a pathophysiological mechanism in most patients.
 - (c) Increased pressure in feeding arteries and in draining veins (i.e., outflow restriction) is associated with hemorrhage.^{12,15}
2. Functional displacement. Development of an AVM within the brain appears to lead to reorganization and displacement of functional tissue.^{16,17}

14.2. Clinical features

14.2.1. Epidemiology

1. Prevalence
 - (a) Estimates of the prevalence of brain AVMs in the general population range from 0.005 to 0.6%.¹⁸⁻²¹
2. Incidence of AVM-related hemorrhage
 - (a) New York Islands Arteriovenous Malformation Study.^{22,23} Incidence of first-ever AVM hemorrhage: 0.51 per 100,000 person-years.
3. Slightly more common in men (55% of all cases).^{22,24}
4. Mean age at diagnosis: 31.2 years.²⁴

14.2.2. Anatomic features

1. Location
 - (a) Equally distributed between the left and right sides.²⁵⁻²⁷
 - (b) About 65% of lesions involve the cerebral hemispheres²⁸; 15% involve deep midline structures, and 20% are in the posterior fossa.²⁹
 - (c) Eloquent tissue (sensorimotor, language, or visual cortex; hypothalamus or thalamus; internal capsule; brainstem; cerebellar peduncles, or cerebellum) is involved in up to 71% of the cases.³⁰
2. Feeding vessels
 - (a) Feeding arteries have been divided into three types³¹:

- Terminal: Arteries which may supply normal tissue proximally but terminate within the AVM.
 - Pseudo-terminal: Feeders that supply normal brain distal to their supply to the AVM.
 - Indirect (aka *en passage*): feeders that typically arise at right angles from larger normal arteries.
3. Multiplicity
 - (a) Up to 9% of patients have multiple AVMs.³²
 - (b) Most patients with multiple AVMs frequently have an associated vascular syndrome, such as hereditary hemorrhagic telangiectasia (see below).³³

14.2.3. Conditions associated with AVMs

14.2.3.1. Familial intracranial AVMs

Most intracranial AVMs are sporadic. “Familial” AVMs are rare; only 53 cases in 25 families have been reported.³⁴ A systematic review of reported cases found³⁴:

1. Mean age at diagnosis: 27 years, which was younger than in patients with sporadic AVMs.
2. Patients with familial AVMs did not differ from the reference populations with respect to sex and mode of presentation.
3. In families with familial AVMs in successive generations, the age of the child at diagnosis was younger than the age of the parent at diagnosis which suggests clinical anticipation.

14.2.3.2. Hereditary hemorrhagic telangiectasia

Hereditary hemorrhagic telangiectasia (aka Rendu-Osler-Weber syndrome) is a group of autosomal dominant disorders of vascular structure, affecting the brain as well as the nose, skin, lungs, and gastrointestinal tract. Similar cases were independently reported by Rendu,³⁵ Osler,³⁶ and Weber³⁷ around the beginning of the last century.

1. Diagnosis is based on four primary clinical features³⁸:
 - (a) Spontaneous recurrent nosebleeds
 - (b) Muco-cutaneous telangiectasia
 - (c) Visceral involvement
 - (d) An affected first-degree relative
 - *Definite*: three criteria are present
 - *Suspected*: two criteria are present
 - *Unlikely*: one criterion is present
2. Epidemiology
 - (a) Prevalence is 1 in 5,000–8,000.^{39–41}
 - (b) Men and women are affected equally.⁴²
 - (c) Wide distribution across ethnic groups but Caucasians appear to be affected primarily.⁴²
3. Clinical features
 - (a) Central nervous system
 - Cerebrovascular abnormalities associated with Rendu-Osler-Weber syndrome include AVMs, telangiectasias, cavernous malformations, and aneurysms.^{43,44}
 - An MRI screening study found a prevalence of cerebrovascular lesions of 23%.⁴⁵
 - AVMs are the most common vascular lesions. Intracranial or spinal AVMs are present in some 10–15% of patients.^{42,46–48}
 - The presence of pulmonary AVMs is a risk factor for having brain AVMs.⁴⁷
 - Brain AVMs are mostly low-grade (Spetzler–Martin Grade I or II) and are frequently multiple.^{33,47}
 - The incidence of hemorrhage in patients with an AVM and Rendu-Osler-Weber syndrome is comparable to (or less than) the incidence in the non-Rendu-Osler-Weber population, although hemorrhage is six times more common among women.^{47,48}
 - Cerebral ischemic events and brain abscesses may be attributable to right-to-left shunting due to pulmonary AVMs.³⁹

- *Screening* for brain AVMs in patients with Rendu-Osler-Weber syndrome is recommended by some authors.^{46,48,50}
 - CTA is not optimal for screening due to false negative results.⁴⁷
- (b) Epistaxis
 - Spontaneous epistaxis from telangiectasias of the nasal mucosa is the most common clinical manifestation; in 80% of cases epistaxis is the first clinical symptom of the disease.⁵¹
 - More than 50% of patients have recurrent epistaxis before the age of 20.⁵²
 - Epistaxis occurs in a biphasic 24-h pattern, with a primary peak in the morning and a smaller second peak in the evening.⁵³
- (c) Skin
 - Cutaneous and mucocutaneous telangiectasias are present in 50–80% of cases.⁴²
- (d) Lungs
 - Pulmonary AVMs are present in 14–33% of patients.^{46,54,55}
 - Embolization to the brain is a risk of endovascular treatment of pulmonary AVMs.⁵⁶
- (e) GI tract
 - Recurrent gastrointestinal hemorrhage occurs in a minority of cases.⁴²
- 4. Pathophysiology
 - (a) The initial morphologic change of hereditary hemorrhagic telangiectasia consists of focal dilatations of postcapillary venules accompanied by a diminishing capillary network.^{42,57} As the venules enlarge over time, they become tortuous and connected to enlarging arterioles, eventually forming direct arteriovenous fistulae.
- 5. Genetics
 - (a) Autosomal dominant.
 - (b) Affected patients are heterozygous; homozygous forms are lethal.⁵⁸
 - (c) Two genes have been identified.
 - Endoglin (*ENG*), on chromosome 9q.^{59,60}
 - Activin-receptor-like kinase (*ALK1*), on chromosome 12q.⁶¹

14.2.3.3. Wyburn-Mason syndrome

Wyburn-Mason syndrome (aka unilateral retinocephalic vascular malformation or Bonnet-Dechaume-Blanc syndrome) is a rare condition characterized by the presence of AVMs in the brain and retina. Roger Wyburn-Mason published the first English language analysis of this syndrome in London in 1943.⁶² Theron and colleagues published an analysis of 25 cases.⁶³

1. Wyburn-Mason syndrome is congenital, nonhereditary, and without sex or race predilection.
2. The initial diagnosis of the syndrome is usually made when a retinal AVM is detected.
3. The associated intracranial vascular lesion is unilateral, related to the optic pathway, and frequently involves the optic nerve, chiasm, optic tract, and basal ganglia.⁶³ In some cases the AVM may extend to the occipital lobe.

14.2.3.4. Sturge-Weber syndrome

Sturge-Weber syndrome (aka encephalotrigeminal angiomatosis) is a neurocutaneous disorder. Patients typically present with angiomas involving the leptomeninges, retina, and the dermatomes (port wine stains) of the face. The leptomeningeal venous angioma consists of numerous small tortuous, thin-walled vessels lying in the pia and adjacent hemisphere, typically in the posterior parietal and anterior occipital lobes. Associated intracranial AVMs have been reported.^{64,65}

14.2.4. Natural history

Natural history data comes from numerous retrospective studies and several prospective studies. Estimates of the annual rate of hemorrhage from an AVM range

from <2 to 17.8%.^{27,66-71,70} The risk of hemorrhage from an AVM depends strongly on whether there has been a previous hemorrhage.

1. *With a previous hemorrhage*
 - (a) The most commonly reported incidence of rebleeding in the first year after hemorrhage is approximately 7%.^{27,67,71-74}
 - Other studies: 3.9%,⁶⁹ 17.9%,⁷³ 17.8%.⁷⁰
 - Risk decreases to baseline after 3-5 years.^{67,73}
2. *Without a previous hemorrhage*
 - (a) Most studies: 2-4% per year.^{27,66,69,75,76}
3. *Spontaneous regression*
 - (a) Rare. In a review of 700 cases, a total of six cases (0.9%) of angiographically documented lesions disappeared on follow-up angiograms.⁷⁷ Three of these cases occurred in patients that had undergone partial resection of the lesion.

14.2.4.1. Lifetime risk of hemorrhage

Assuming a constant annual risk of hemorrhage of 2-4%, the lifetime risk of hemorrhage can be estimated by the following formula⁷⁸:

$$\text{Lifetime risk} = 1 - (\text{Risk of no hemorrhage})^{\text{Years remaining of life}}$$

Alternative method. Assuming a 3% annual risk, lifetime risk can be approximated as follows⁷⁹:

$$\text{Lifetime risk (\%)} = 105 - \text{The patient's age in years (Table 14.1).}$$

Table 14.1 Life expectancy table and projected lifetime risk of AVM hemorrhage

Age interval	Average no. of years remaining ^a	Estimated lifetime risk of rupture according to annual risk of rupture ^b		
		2%	3%	4%
5-9	72.9	0.77	0.89	0.95
10-14	67.9	0.75	0.87	0.94
15-19	63.0	0.72	0.85	0.92
20-24	58.2	0.69	0.83	0.91
25-29	53.5	0.66	0.8	0.89
30-34	48.7	0.63	0.77	0.86
35-39	44	0.59	0.74	0.83
40-44	39.3	0.55	0.7	0.8
45-49	34.8	0.5	0.65	0.76
50-54	30.3	0.46	0.6	0.71
55-59	26.1	0.41	0.55	0.66
60-64	22	0.36	0.49	0.59
65-69	18.2	0.31	0.43	0.52
70-74	14.7	0.26	0.36	0.45
75-79	11.5	0.21	0.3	0.37
80-84	8.8	0.16	0.24	0.3
85-89	6.5	0.12	0.18	0.23
90-94	4.8	0.09	0.14	0.18
95-99	3.6	0.07	0.1	0.14

^aAverage number of years of life remaining for beginning of age interval. Life expectancy data obtained from the United States Department of Health and Human Services⁸⁰

^bAnnual rupture rates are based on studies of patients without a previous hemorrhage.^{27,66,69,75} Lifetime risk of rupture was calculated using the formula $1 - (\text{Risk of no hemorrhage})^{\text{Years remaining of life}}$.⁷⁸ Assumptions include a constant risk of rupture and no confounding factors

14.2.4.2. Risk factors for hemorrhage

Risk of hemorrhage is not uniform across the population of patients with AVM,⁸¹ and appears to vary widely according to a number of patient characteristics. *However, data about risk factors for hemorrhage must be interpreted with caution. For nearly every factor that has been associated with AVM hemorrhage, there is at least one other study that has not found a significant association.*⁸²

1. Prior hemorrhage is a strong predictor of hemorrhage.^{71,83,84}
2. AVM size – controversial
 - (a) Increased bleeding risk has been associated with small AVM.^{15,27,85–89}
 - (b) In contrast, other studies have found a lower risk of hemorrhage for smaller AVMs^{75,90} or a higher risk for large AVMs.⁹¹
 - (c) Yet other studies have not found a relationship between size and hemorrhage risk.^{66,73,75}
3. Deep venous drainage.^{84,88}
4. Presence of only a single draining vein.⁸⁹
5. Impaired venous drainage (i.e., venous stenosis or venous reflux).^{15,92}
6. Infratentorial location.²⁹
7. Deep brain location.^{84,93}
8. Periventricular location.^{94,95}
9. Presence of intracranial aneurysms.^{75,95,96}
10. Presence of MCA perforator feeding vessels.⁹⁶
11. Presence of non-intracranial aneurysms.⁶⁸
12. Increasing age.^{26,27,66,81,84}
13. Female sex and of reproductive age.⁹⁰
14. Hypertension.⁸⁸
15. Hispanic ethnicity.⁹⁷
16. A polymorphism in the inflammatory cytokine IL6 (i.e., patients homozygous for the interleukin (IL)-6-174 G allele).⁹⁸

14.2.4.3. Outcome after hemorrhage

The overall morbidity of AVM hemorrhage is lower than it is for intracranial hemorrhage due to other causes,⁸³ possibly because AVMs are thought to be congenital lesions, and the adjacent brain is adapted to the presence of the lesion.⁹⁹

1. Mortality with hemorrhage
 - (a) 5–30%^{26,27,66,69,70,72–75,100,101}
2. Morbidity with hemorrhage
 - (a) 20–30%^{26,27,66,69,70,72–75,100,101}

14.2.5. Presentation

1. Hemorrhage
 - (a) Most common symptom at presentation, occurring in some 53% of patients at initial diagnosis.²⁴
2. Seizures
 - (a) After hemorrhage, seizures are the second most common presenting symptom of intracranial AVMs, occurring in 20–25% of cases.^{75,100,102}
 - (b) The annual incidence of epilepsy in patients with AVMs is 1–4%.^{27,66}
 - (c) Lesion location in the temporal and parietal lobes is more associated with seizure disorders than in other locations.^{66,103}
 - (d) Seizures associated with parietal lobe AVMs are typically focal, whereas seizures due to frontal lobe AVMs are frequently generalized.¹⁰⁰
3. Headaches
 - (a) Headache complaints are more common among patients with AVMs than the general population,¹⁰⁴ suggesting that unruptured AVMs may cause headaches.
 - (b) Various reports have described an association between AVMs and migraine and other headache syndromes.^{104–106}
4. Developmental learning disorders
 - (a) Patients with AVMs are more likely to have developmental learning disorders than patients with other intracranial disorder, even many

years prior to the diagnosis of the AVM.¹⁰⁷ This may be due to subtle injury to the brain by the AVM, displacement of functional tissue by the AVM, or steal phenomenon.

14.2.6. Imaging

1. CT/CTA
 - (a) CT is still the best imaging technique to check for an acute hemorrhage.
 - (b) A noncontrast CT of an unruptured AVM may appear normal; sensitivity can be increased by using IV contrast or doing a CTA.

CT findings with AVMs:

 - Heightened vascularity.
 - Serpentine, enlarged veins.
 - In some cases, perilesional atrophy and/or hydrocephalus.
 - (c) CTA: AVMs are typically best seen on MIP images.
2. MRI
 - (a) More sensitive than CT in identifying subtle lesions.
 - (b) Permits precise anatomic localization of lesions.
 - (c) Detection of associated aneurysms is limited, particularly intranidal aneurysms and aneurysms <5 mm in size.^{108,109}
3. Angiography
 - (a) Catheter angiography provides information about AVMs that is superior to complimentary compared to other imaging techniques. Advantages include:
 - Greater sensitivity.
 - Able to clarify anatomy of feeding vessels and draining veins (e.g., distinguishes between ACA and MCA contributions to a cerebral convexity lesion).
 - Best imaging technique to identify intranidal aneurysms.
 - Able to determine arteriovenous transit times.
 - (b) Angiography remains the gold standard for the evaluation of AVMs, and the authors of this handbook believe that it should be considered for every patient with an intracranial AVM, or an intracerebral hemorrhage that may be due to an AVM.
 - *Yield of angiography* in patients with spontaneous ICH (i.e., the chance of finding an underlying vascular abnormality¹¹⁰):
 - Patients age ≤45 years: 50%
 - Patients age >45 years: 18%
 - Patients without a history of hypertension: 44%
 - Patients with a history of hypertension: 9%
 - (c) *Complications*: A systematic review found that the risk of complications of angiography in patients with AVMs (0.3–0.8%) is significantly lower than for patients being evaluated for TIA or stroke (3.0–3.7%).¹¹¹

14.3. Management

Management options for patients with an AVM are

1. Expectant management
2. Surgery
3. Radiosurgery
4. Embolization
5. A combination of embolization, radiosurgery, and/or surgery

Obviously, AVMs and patients with them vary greatly, and so the management strategy for any given patient must be highly individualized. Mainstream thinking presently favors surgery or radiosurgery for most patients¹¹²; embolization is usually most useful as a preparatory step prior to surgery or radiosurgery. Conservative management is gaining favor for large or difficult-to-treat lesions, and for patients at high risk of complications.¹¹³

14.3.1. Expectant Management

Non-surgical and non-interventional management of some patients with AVMs is appropriate. Some authors, considering the natural history of asymptomatic AVMs and the relative low morbidity associated with hemorrhage of some lesions, argue against the routine treatment of asymptomatic lesions.¹¹⁴ An ongoing multicenter study, A Randomized Trial of Unruptured Brain Arteriovenous Malformations (ARUBA), is comparing treatment of unruptured lesions with conservative management (<http://www.arubastudy.org>). Large AVMs may also warrant conservative management, considering the difficulty and morbidity of treatment.

14.3.2. Surgery

Surgical resection of brain AVMs is the “gold standard” for the treatment of small, accessible lesions.^{112,115,116} Decision making in most cases begins with stratification according to the Spetzler–Martin grading system (Table 14.2), which is currently the most commonly used system. A decision analysis model suggested that surgical resection of small, asymptomatic AVMs, assuming a risk of major neurological morbidity and mortality <6.8%, offers the greatest overall quality of life over time compared to observation or radiosurgery.¹¹⁷

14.3.2.1. Surgical Outcomes

1. Obliteration rates.
 - (a) Spetzler–Martin grades I–III: 94–100%.^{118–124}
Grades I–III lesions account for ~60 to 80% of AVMs.^{118,125}
 - (b) Spetzler–Martin grades IV–V: There is a paucity of data on angiographic obliteration rates after surgery for high grade AVMs, partly because multimodality treatment strategies are frequently used. Separate discussions of *Large AVMs* and *Multimodality Treatment* appear below.
 - (c) For a discussion of surgery compared to radiosurgery, see below.
2. Complications. A systematic review of 25 reports, including 2,425 patients, found an overall rate of post-operative mortality of 3.3% and permanent morbidity of 8.6%.¹²⁴
 - (a) Spetzler–Martin grades I–III:
 - Permanent morbidity 0–5%.^{119,121–123,126}
 - Mortality 0–3.9%.^{119,123,126,127}
 - (b) Spetzler–Martin grades IV–V:
 - Morbidity 12.2–21.9%.^{118,120}
 - Mortality 11.1–38.4%.^{118,127}

Table 14.2 Spetzler–Martin scale³⁰

Lesion characteristic		Number of points
Size	Small (<3 cm)	1
	Medium (3–6 cm)	2
	Large (>6 cm)	3
Location	Non-eloquent site	0
	Eloquent site (sensorimotor, language, or visual cortex; hypothalamus or thalamus; internal capsule; brainstem; cerebellar peduncles, or cerebellum)	1
Pattern of venous drainage	Superficial only	0
	Any deep	1

This grading system was developed to predict surgical risk, not prognosis. Size indicates maximum diameter

3. Effects on patients with seizures
 - (a) After surgery, 43.6–81% of patients with a history of seizures are seizure-free.^{118,128,129}

14.3.2.2. Surgery: Practical Issues

1. *Timing of surgery.* AVMs do not carry the same high rehemorrhage risk that ruptured aneurysms do; therefore, timing of surgery depends on several factors other than rehemorrhage risk. Most authors recommend that surgery be done on an elective basis,^{112,130,131} days to weeks after the ictus, to allow the patient to recover from the initial event and to allow the clot to liquefy. Others advocate earlier surgery in most cases.¹³²
 - (a) *Early surgery* is indicated when
 - The clot has significant mass effect and the patient will benefit from evacuation of the hematoma.
 - The lesion is surgically accessible.
 - (b) *Late surgery* (several weeks or more after the hemorrhage) is indicated when:
 - The clot burden is relatively low.
 - The patient is relatively poor surgical candidate soon after the initial hemorrhage.
 - Imaging studies do not show the AVM clearly, and a delayed, detailed angiogram may show the lesion more clearly.
2. *Surgery combined with embolization or radiosurgery.* See the sections below on *Radiosurgery and Embolization*.
3. *Intraoperative and postoperative angiography:* Either intraoperative or postoperative angiography is *always* indicated, to ensure complete obliteration of the lesion.
 - (a) *Intraoperative angiography*
 - Advantages: Allows for detection, and removal, of residual AVM during the operation.
 - Disadvantages: Adds time to the operation; angiography in the OR is usually lower-quality than biplane angiography in a dedicated neuro-angio suite.
 - Results: A review of published reports of intraoperative angiography found that the results of the intraoperative angiogram altered the management of the case in an average of 15% of the time (range: 5.6–57%).¹³³
 - When the intraoperative angiogram was compared to a post-op angiogram, a false negative result was found in 4.4% cases, and a false positive result occurred in 1.7% of cases.¹³³
 - The reported technical failure rate was 2.5% and the complication rate was 3.1%.¹³³
 - (b) *Post-op angiography*
 - Results: In a series of 324 patients undergoing post-op angiography craniotomy for AVM resection, 1.8% were found to have residual lesions.¹³⁴
4. *Surgical complications*
 - (a) *Seizures*
 - New-onset seizures occur in 6.5–22% of patients after AVM treatment.¹³⁵
 - Some authors recommend routine antiseizure prophylaxis for patients undergoing AVM surgery.^{116,136}
 - (b) *Cerebral edema*
 - Perioperative cerebral edema occurs in $\leq 3\%$ of cases^{118,137–140} and may first occur in the operating room or up to 11 days after surgery.¹³⁷ Cerebral edema may occur after AVM surgery or embolization.¹⁴¹
 - Post-treatment cerebral edema is believed to be attributable in most cases to (1) *normal perfusion pressure breakthrough* or (2) *occlusive hyperemia*.
 - *Normal perfusion pressure breakthrough*.¹⁴² This theory maintains that the tissue around an AVM is subject to chronic steal because of diversion of flow into the AVM, resulting in sustained dilation and loss of autoregulation. Presumably, in some cases the vessels in this tissue are unable to autoregulate when normal perfusion is reestablished after resection of the AVM, resulting in edema and hemorrhage.

- *Occlusive hyperemia*.^{137,141} According to this theory, brain edema after AVM resection is due to obstruction of venous outflow, with associated vascular engorgement, and to sluggish flow in former arterial feeders with subsequent hypoperfusion and ischemia.

Management

- Standard measures to control cerebral edema in this setting include¹⁴³:
 - Head CT to exclude hemorrhage (*obviously*).
 - The head and neck should be maintained in a neutral position to minimize jugular vein compression and obstruction of CSF outflow.
 - IV mannitol.
 - Ventriculostomy.
 - Intubation and mechanical ventilation if the patient's neurological status is diminished; judicious hyperventilation may be helpful, as cerebrovascular reactivity to CO₂ remains intact after AVM resection.^{144,145}
 - Decompressive craniectomy (or removal of the bone flap).
 - High-dose barbiturate anesthesia.
- (c) *Rehemorrhage*
 - Overall incidence of early rehemorrhage after surgery (≤ 1 week) is 2%.¹⁴⁶ Risk factors for rehemorrhage include higher grade AVMs and the presence of lenticulostriate feeders.¹⁴⁶
 - Often attributable to residual AVM.
 - Aggressive post-operative blood pressure control can minimize risk of rehemorrhage.
- (d) *Vasospasm*
 - Symptomatic vasospasm, attributable to extensive dissection and exposure of major intracranial arteries, occurs in <1% of cases.¹⁴⁷
- (e) *Intracranial thrombosis*
 - Retrograde thrombosis of an arterial feeder, with recanalization of the vessel with IA urokinase, has been reported.¹⁴⁸
 - Delayed venous thrombosis and infarction after AVM resection has also been reported.¹⁴⁹

14.3.3. Radiosurgery

Radiosurgery involves the administration of multiple beams of radiation; each beam is delivered from a different direction, and all beams converge on the target, or isocenter. The radiation dose in the isocenter is high but the radiation dose received by non-targeted structures is relatively low. Advantages of radiosurgery are that it is minimally invasive, relatively low-risk, and useful for treatment of surgically inaccessible lesions. Disadvantages include a latency period (usually 2–3 years) until AVM obliteration occurs, and that it is most effective for smaller lesions.

14.3.3.1. Radiosurgery techniques

- Gamma knife.
 - Most widely used platform for AVM radiosurgery.
 - Two hundred and one gamma ray beams from cobalt-60 sources pass through holes (collimators) in a helmet and converge on the isocenter. Dosing is controlled by determining the size of the collimators and the exposure time.¹⁵⁰
- Linear accelerator (LINAC).
 - LINACs use microwaves to accelerate electrons that then collide with a target to generate high energy photons. The LINAC is mounted on a gantry that rotates through an arc and concentrates radiation energy on the isocenter. Dosing is controlled by using multiple intersecting arcs and beam weight adjustment. Current LINAC devices include Novalis[®] (BrainLAB, Helmstetten, Germany), X-Knife[™] (Radionics, Burlington, MA), Trilogy[™] (Varian Medical Systems, Palo Alto, CA), and CyberKnife[®] (Accuray, Sunnyvale, CA).

3. Particle beam.
 - (a) Charged particles are delivered rather than photons. The theoretical advantage of particle beam treatment over photon beam radiosurgery is that the energy deposition is more concentrated (and tissue exposure outside of the target is lessened) due to the Bragg peak effect. Another theoretical advantage is that the relative biological effectiveness is higher compared to other techniques. Both protons and helium nuclei have been used to treat AVMs.^{151,152} Disadvantage is that particle beam radiosurgery requires a relatively expensive cyclotron or synchrotron.

14.3.3.2. Mechanism of AVM obliteration in radiosurgery

The earliest and primary effect of radiosurgery is damage to AVM endothelial cells. Progressive occlusion of the vessel lumen occurs during a sequence of events that is similar to wound healing.¹⁵³ Endothelial damage induces the proliferation of smooth muscle cells and myofibroblasts and an accumulation of extracellular collagen, causing stenosis and occlusion of the nidus.^{153,154} A chronic inflammatory response also contributes to the formation of granulation tissue in the region of the AVM.

14.3.3.3. Radiosurgery outcomes

4. Obliteration rates. Rates of angiographic cure depend primarily on lesion size. Most of the following results are at 2–5 year follow-up.
 - (a) Lesion diameter ≤ 3 cm: 75–95%^{128,151,155–160}
 - (b) Lesion diameter ≥ 3 cm: $\leq 70\%$ ^{157,159}
5. Effect on hemorrhage risk
 - (a) Risk of hemorrhage persists during the latency period between radiosurgery and AVM obliteration, but may be reduced compared to the risk of hemorrhage prior to radiosurgery.¹⁶¹ One study found the annual risk of hemorrhage during the 2-year latency period to be 4.8%¹⁶²; a more recent study of 1,593 cases found an annual risk of hemorrhage during the 2-year latency period to be 1.8%.¹⁶³
 - (b) The presence of an unsecured proximal aneurysm is associated with an increased risk of hemorrhage during the latency period.¹⁶²
 - (c) Even with complete angiographic obliteration, the risk of hemorrhage may not be zero; Shin and colleagues estimated the risk of rebleeding after complete nidus obliteration to be 0.3% per year.¹⁶⁴
6. Effect on patients with seizures
 - (a) Radiosurgery can be effective in patients with seizures attributable to an AVM. Seizure-free rates after radiosurgery are 51–80%.^{165–168}
7. Complications. Pooled data from 1,255 patients¹⁶⁹:
 - (a) Overall rate of neurological complications (transient or permanent neurologic deficits): 8%
 - (b) Permanent neurologic deficits: 4.8%
 - (c) Complications:
 - Radiation injury to brain parenchyma (6.4%)
 - Cranial nerve injury (1%)
 - New or worsened seizures (0.8%)
 - Death (0.2%)

14.3.3.4. Radiosurgery: Practical issues

1. Dosing
 - (a) The applied radiation dose is inversely proportional to the irradiated volume. To determine the dose of radiation, a dose/volume curve is used.
 - (b) Dose–response studies have found meaningful responses up to 25 Gy.¹⁷⁰ Above this point, there is minimal incremental increase in obliteration rates but a significant increase in complications.
 - (c) The volume of tissue that receives 12 Gy (the 12 Gy volume) correlates with complications of radiation treatment.^{171–173} Lower success rates for treatment of large AVMs with radiosurgery are believed to be due to lower doses used for those cases in an effort to minimize the 12 Gy volume.¹⁷⁴

2. Complication management
 - (a) Transient brain edema is a source of headaches and neurologic deficits in some patients after radiosurgery. Some operators use low-dose oral dexamethasone therapy for 2 weeks after treatment.¹⁵⁷ Delayed symptoms attributable to brain edema frequently respond to a short course (2–3 days) of IV dexamethasone.
3. Follow-up imaging
 - (a) Follow-up catheter angiography is necessary in all patients 2–3 years after radiosurgery for an AVM, because of the significant (5–25%) chance of residual and because complete lesion obliteration is necessary to minimize hemorrhage risk.¹⁷⁵
4. Repeat radiosurgery
 - (a) When complete obliteration of the lesion is not obtained within 3 years after treatment, repeat radiosurgery is an option. Repeat radiosurgery is associated with a 62–70% probability of obliteration.^{176,177}

14.3.4. Surgery compared to radiosurgery

Several reports have compared surgery to radiosurgery, with the expected results. Surgery is associated with a higher cure rate with a lower rehemorrhage risk, while radiosurgery is less morbid.

1. Pikus and colleagues compared a surgical series to published radiosurgery reports and found advantages in surgery in terms of angiographic cure rates and rehemorrhage risk, although surgery had a significantly higher rate of neurological complications.¹²¹
2. Nataf and coworkers compared two series of patients with lesions that were considered equally suitable for treatment by surgery or radiosurgery.¹⁷⁸ Although the rate of cure was similar for both groups of patients, neurological morbidity was higher after surgery and recurrent bleeding was more frequent after radiosurgery.

14.3.5. Embolization

14.3.5.1. A briefer history of embolization of intracranial AVMs

The first report of embolization of a brain AVM appeared in 1960.¹⁷⁹ A patient with a large left Sylvian fissure AVM underwent surgical exposure of the cervical carotid artery, and four spheres of methyl methacrylate, measuring between 2.5 and 4.2 mm in diameter, were embolized into the lesion. Angiography showed near total occlusion of the lesion and good filling of normal vessels. Limited progress was made with AVM embolization during the 1960s, largely because of the absence of useful catheters and embolic agents. Flow-directed particulate embolization,¹⁸⁰ balloon embolization,¹⁸¹ and delivery of embolic material through a punctured microballoon (the “calibrated leak balloon” technique)^{182,183} were reported in the 1970s.

Advancements in catheter design in the 1980s permitted selective cannulation of the AVM pedicles. An array of embolic agents was used in this decade, including silk threads, alcohol, and polyvinyl alcohol (PVA). Isobutyl-2-cyanoacrylate was used during this time, but reports of toxicity and carcinogenicity in animal studies^{184,185} lead to the withdrawal of this material from the market and the introduction of *N*-butyl-2-cyanoacrylate (NBCA).¹⁸⁶

During the 1990s, NBCA and polyvinyl alcohol emerged as the most popular embolization materials for AVMs. While the principal advantage of NBCA is its resistance to recanalization, compared to PVA (which is prone to recanalization¹⁸⁷), the adhesive properties of NBCA require great care during injection to minimize the risk of catheter retention. A randomized trial comparing NBCA to PVA for preoperative embolization of AVMS found no difference and also that the two agents were equivalent in terms of percentage of nidus reduction and number of feeding pedicles embolized.¹⁸⁸ Interestingly, although the overall rates of procedural complications were similar in both groups, patients treated with PVA had a significantly higher rate of post-resection hemorrhage compared to patients treated with NBCA (17.8% vs. 4.8%).

Ethylene vinyl alcohol copolymer in dimethyl sulfoxide solution (Onyx, Micro Therapeutics, Inc., Irvine, CA) was introduced in 1990. Although Onyx was originally conceived of as an embolic agent for intracranial aneurysms, somewhat disappointing results in a North American randomized trial of the material for aneurysms¹⁸⁹ were followed by encouraging initial results with the use of the agent for the treatment of AVMs.¹⁹⁰ Onyx received FDA approval for pre-surgical embolization of AVMs in 2005.

14.3.5.2. Embolization results

AVM embolization techniques and strategies are discussed in detail in Chap. 7, *Intracranial Embolization*.

1. Cure rates
 - (a) Complete AVM obliteration has been reported in some 5–10% of cases.^{191–196}
 - (b) The relatively low cure rate with embolization alone is probably due to the fact that only a minority of AVMs have a single pedicle, or several pedicles, that can be safely catheterized.
2. Palliation
 - (a) Embolization to improve symptoms attributable to “steal phenomenon” has been reported.^{197,198}
3. Embolization combined with surgery or radiosurgery (or both). Numerous reports of presurgical^{30,118,191,192,199–204} and pre-radiosurgical^{187,194,205–207} embolization have been published.
 - (a) Pre-surgery embolization.
 - The goals of pre-surgery embolization are to reduce the volume of the nidus and to occlude deep and difficult-to-reach feeders when possible.
 - Embolization has been reported to shorten operative time and blood loss.^{30,118,191,192,199–204,208}
 - In a series comparing AVM surgery patients with presurgical embolization to those without it, complication rates and the proportion of patients with good or excellent outcomes were similar in both groups, despite the fact that the embolization group had higher grade lesions.¹⁹⁹
 - Vinuela and colleagues suggested that occlusion of >75% of the AVM nidus facilitates surgical resection, while elimination of <50% does little to facilitate surgery.²⁰⁹
 - (b) Pre-radiosurgery embolization
 - The aim of pre-radiosurgery embolization is to reduce the volume of the nidus.
 - Improved rates of AVM obliteration have been found when the volume is reduced with embolization to <10 cm³.^{187,194} Volume – diameter relationships are listed in Table 14.3.
 - When radiosurgery does not result in AVM obliteration, repeat embolization may be effective.²¹⁰
4. Complications. A systematic review of 25 reports, including 2,425 patients, found an overall rate of permanent morbidity associated with pre-surgical embolization of 4–8.9%.¹²⁴
 - (a) Overall permanent morbidity: 2–14%.^{188,195,196,200,208,211,212}
 - (b) Mortality: 1.0–3.7%.^{188,195,196,200,208,211,212}

Table 14.3 Estimation of AVM volume based on diameter^a

Diameter (cm)	Volume (cm ³)
1	0.51
2	4.19
3	14.14
4	33.51
5	65.45
6	113.09

^aAssumes that the lesion is a sphere; volume = (4/3)πr³

14.3.6. Specific considerations

14.3.6.1. Associated aneurysms

Most reports indicate that intracranial aneurysms are found in some 15–25% of patients with AVMs.^{213,214} One study of superselective angiography reported an incidence of associated aneurysms of 58%.⁹⁵

1. Classification and incidence of AVM-associated aneurysms
 - (a) *Feeding artery aneurysms*
 - Attributable to wall-shear stress caused by high flow through AVM feeding arteries.
 - Incidence: 11.2–17%.^{213,214}
 - Approximately twice as common as intranidal aneurysms.^{213,214}
 - (b) *Intranidal aneurysms*
 - True intranidal aneurysms
 - True aneurysms in the AVM nidus can be distinguished from venous varices by their early appearance during the arterial phase on angiography.²¹⁵
 - Incidence: 5.5–8%.^{213,214}
 - Intranidal *pseudoaneurysms*
 - Uncommon lesions that can only be firmly diagnosed by histopathology. An intranidal pseudoaneurysm may be identified as a new finding on a follow-up angiogram.²¹⁶ Found in 8% of angiograms of patients with an AVM.²¹⁶ Differentiation between true- and pseudo-intranidal aneurysms is academic and has no therapeutic implications.²¹⁷
 - (c) *Incidental aneurysms*
 - Aneurysms not related to the AVM seem to occur in AVM patients at about the same rate as aneurysms in the general population (0.8%).²¹³
2. Risk of hemorrhage
 - (a) Patients with an AVM and an associated aneurysm (feeding artery or intranidal) are at increased risk of hemorrhage compared to patients with an AVM only.²¹⁴
 - Annual risk of hemorrhage: 7%.⁶⁸
 - (b) Feeding artery aneurysm
 - Presence of a feeding artery aneurysm is an independent risk factor for hemorrhage in AVM patients, although only 6% of the attributable risk is due to the aneurysm (i.e., only 6% of hemorrhages could be prevented by eliminating the feeding artery aneurysm).²¹⁴
 - (c) Intranidal aneurysm
 - Annual risk of hemorrhage 9.8%.²¹³
3. Management
 - (a) No consensus exists for the management of associated aneurysms. Some authors advocate treatment of the aneurysm first,^{218–220} whereas others recommend treatment of the AVM first,²¹³ or treatment of both lesions simultaneously.^{221–223}
 - (b) Effect of AVM treatment on feeding vessel aneurysms:
 - Some feeding vessel aneurysms may regress with treatment of the AVM. In a report of 23 AVMs with feeding vessel aneurysms, 18 were unchanged after treatment, four were smaller, and 1 disappeared completely.²¹³
 - Feeding vessel aneurysm rupture has been reported immediately after AVM resection²¹⁹ or within 3 weeks after AVM treatment.²¹⁸
 - The presence of an unsecured proximal aneurysm is a risk factor for post-radiosurgery hemorrhage.¹⁶²
 - (c) The authors of this handbook recommend the following strategy:
 - For patients who present with hemorrhage, treat the lesion that caused the hemorrhage first (*obviously*).
 - For patients who present without hemorrhage, treat the feeding vessel aneurysm first, if feasible.

14.3.6.2. Large and giant AVMs

Large AVMs are variously defined as Spetzler–Martin IV–V lesions, or lesions with a diameter >3 cm or volume >10–15 cm³. Giant AVMs are lesions with a diameter >6 cm. These AVMs are problematic because they are difficult to treat and the natural history is murky.

1. Natural history
 - (a) Natural history studies have reported widely divergent hemorrhage rates for patients with Grade IV and V AVMs.

- One retrospective study found an annual hemorrhage risk of 1.5%,²²⁴ while another found an annual pretreatment hemorrhage rate of 10.4% for all patients (13.9% for patients presenting with hemorrhage and 7.3% for patients without hemorrhage at presentation).²²⁵
 - A prospective study of 301 patients with AVMs found that lesion diameter >3cm was an independent risk factor for hemorrhage (odds ratio 2.5, $P < 0.0001$).⁹¹
- (b) Although some evidence has suggested that larger AVMs may be at a lower risk of hemorrhage than smaller lesions,^{15,27,66,85–89} estimates of higher risk for larger AVMs^{91,225} seem plausible, given that larger lesions are more likely to contain other anatomic features, aside from size, that are established risk factors for hemorrhage, such as deep location or deep venous drainage.²²⁵
2. Surgery
 - (a) Morbidity and mortality with surgery of Grade IV–V lesions runs as high as 21.9 and 38.4%, respectively.^{118,127}
 3. Radiosurgery
 - (a) Complete obliteration rates for large AVMs with single-treatment radiosurgery are very low.^{226–228}
 - Obliteration rates for AVMs $\geq 15\text{ cm}^3$ are 25%.^{227,228}
 - (b) A study of staged volume radiosurgery for AVMs $>15\text{ cm}^3$ reported obliteration in 50% of cases.²²⁹ In these cases, two or three separate anatomic compartments were irradiated at a 3- to 8-month intervals. Fourteen percent of patients had a hemorrhage after radiosurgery, 14% developed peri-AVM imaging changes requiring steroid treatment, and neurological worsening occurred in 4%.
 4. Effects of partial treatment
 - (a) Most authors agree that maximal protection against hemorrhage risk is obtained only with complete obliteration of the lesion.
 - (b) Han and colleagues found an increased annual risk of hemorrhage with partial treatment, compared to no treatment (10.4% vs. 1.5%).²²⁴
 - (c) Conversely, Meisel and coworkers found a decreased risk of hemorrhage with partial embolization.²¹¹
 5. Multimodality strategies
 - (a) A combination of embolization, radiosurgery, and surgery may be effective in some cases.
 - (b) In a series of 53 patients with giant (>6 cm) AVMs undergoing multimodality treatment, 36% were completely cured of the AVM.²³⁰ The patients were treated with surgery (51%), embolization (98%), and/or radiosurgery (89%). Long-term treatment-related morbidity was 15%. At a mean follow-up of 37 months, clinical results were excellent in 51%, good in 28%, poor in 6%, and 15% were dead.
 6. Management recommendations
 - (a) No consensus exists for the management of large AVMs. Some prominent authors have recently recommended conservative management in most patients,^{224,231} while others have advocated treatment, particularly of patients who present with hemorrhage.²²⁵
 - (b) “Palliative” treatment does not appear to reduce the risk of hemorrhage (and may actually increase it); therefore, any treatment of large AVMs should be directed toward eventual obliteration of the lesion.

14.3.6.3. AVMs in children

Pediatric patients with intracranial AVMs differ from adults in important ways: AVM recurrence after treatment is more frequent in children and prognosis after hemorrhage is better.

1. Prevalence of AVMs among children
 - (a) About 10–20% of newly diagnosed brain AVMs are in children.^{232,233}
 - (b) Overall prevalence in children is 0.014–0.028%.²³⁴
2. Risk of hemorrhage
 - (a) Although anecdotal reports have suggested that children are at higher risk of hemorrhage from AVMs than adults, a recent study found the annual risk of hemorrhage for children (age <20) and adults to be similar, 2.0 and 2.2%, respectively.⁷⁶

3. Presentation
 - (a) Up to 75% of children with AVMs present with hemorrhage, and 15% present with seizures.²³²
4. Hemorrhage
 - (a) Any child with a spontaneous intracranial hemorrhage should be presumed to have an underlying AVM until proven otherwise.²³⁵
 - (b) Children may be more likely than adults to present with hemorrhage
 - Hemorrhage is the presenting symptom in 63% of children and seizures are the presenting symptom in 13.4%.²³⁶
 - (c) Outcomes after hemorrhage
 - Seventeen percent have fair or poor outcomes.²³⁶
 - Among pediatric AVM patients who present in a coma, mortality is 40%, however, >50% have a good functional outcome.²³⁷
5. Management
 - (a) Surgery
 - Obliteration rates: 90–95%.^{236,238}
 - Complications:
 - Perioperative morbidity: 19%.²³⁶
 - Perioperative mortality: ≤5%.^{236,239}
 - (b) Radiosurgery
 - Obliteration rates: 68–95%.^{160,240}
 - Permanent neurological complications: <3%.^{160,240}
6. AVM recurrence after treatment
 - (a) Unlike adults, AVMs in children have a tendency to recur after treatment in a small percentage of patients.^{236,241,242}
 - In a series of 808 patients who had undergone complete surgical resection of an AVM, five patients (0.6%) were found to have recurrent AVMs after negative postoperative angiography, and they were all in the pediatric age group.²⁴¹
 - A recent series reported a recurrence rate of 5.6%.²³⁶
 - (b) Follow-up surveillance imaging
 - Because of the possibility of recurrence, most authors recommend continued follow-up imaging in children, even after complete obliteration.²³⁵

14.3.6.4. Pregnancy and AVMs

1. AVM hemorrhage during pregnancy.
 - (a) Relatively common cause of ICH in pregnant woman. An AVM is the cause of hemorrhage in 21–48% of ICH cases during pregnancy and the puerperium.^{243–246}
 - (b) Mean gestational age at time of hemorrhage is 30 weeks.²⁴⁴
 - (c) Hypertension is present in 17% of pregnant patients with an AVM hemorrhage.²⁴⁴
 - (d) Outcomes are worse in pregnant women compared to nonpregnant AVM patients.²⁴⁷
 - Some 57% of pregnant patients are stuporous or comatose at presentation.²⁴⁴
 - Maternal mortality rates range from 0 to 28%.^{244,246,248,249}
 - Fetal mortality rate is 14%.²⁴⁴
 - (e) Rehemorrhage is more frequent in pregnant patients; 25–30% of pregnant patients rebleed during the same pregnancy.^{243,246,249,250}
 - (f) *Neurosurgical Management*
 - Given the relatively high rate of rebleeding and high morbidity associated with hemorrhage, treatment of the AVM to prevent further hemorrhage is usually prudent.
 - Most authors recommend surgery, when feasible, and that the decision to operate should be based on neurosurgical criteria.^{244,245,250} Embolization may be an option for selected, small lesions that can be safely and completely obliterated with a single procedure. Radiosurgery and, in most cases, embolization are not able to quickly reduce the risk of rehemorrhage and are not appropriate for pregnant patients.
 - Conservative management may be appropriate for cases in which surgery would be risky or difficult. Dias and Sekhar did not find

a significant advantage for surgery compared with nonsurgical management in terms of maternal or fetal mortality rates.²⁴⁴

(g) *Obstetrical Management*

- The choice of delivery method should be based on obstetric rather than neurosurgical criteria, as there does not seem to be a significant advantage for either cesarean or vaginal delivery.²⁴⁴
 - (h) Reasonable efforts should be taken to minimize radiation dose to the fetus during both diagnostic imaging and any interventional procedure.
2. Unruptured AVMs in pregnant patients and in women anticipating becoming pregnant.
- (a) Although pregnancy does not appear to confer an increased risk of hemorrhage in women with an AVM,²⁴⁷ outcomes after hemorrhage during pregnancy are significantly worse than in nonpregnant patients.²⁴⁴
 - The risk of first hemorrhage for pregnant women with an unruptured AVM is 3.5%,²⁴⁷ which is comparable to the annual risk of bleeding among all patients with an AVM.
 - (b) Pregnancy should be deferred until AVM treatment is completed.
 - (c) In pregnant patients with an unruptured AVM, assiduous blood pressure control may minimize risk of hemorrhage, given that hypertension is associated with hemorrhage in this setting.²⁴⁴

14.4. Appendix: Vein of Galen malformations

Vein of Galen malformations are congenital abnormalities that are distinct from other intracranial vascular malformations. They have a spectrum of severity and may present at birth, during infancy, or during later childhood. They are rare, and are believed to comprise $\leq 1\%$ of intracranial vascular malformations.¹³⁸ Management of these lesions is presently handled primarily by pediatric neurosurgeons and neurointerventionalists.

14.4.1. Angiographic classification

Lasjaunias and colleagues divided congenital vein of Galen lesions into three types²⁵¹:

1. Choroidal. Network of feeders, resembling a nidus, supplied primarily by the choroidal arteries.
2. Mural. One or more arterial feeders connected to a dilated vein of Galen.
3. Secondary. Enlargement of the vein of Galen due to an adjacent vascular malformation, fistula, or venous outlet obstruction.

Yasargil introduced the following classification scheme²⁵²:

1. Type I. Relatively few feeders, arising principally from the pericallosal and posterior cerebral arteries.
2. Type II. Feeders arise mainly from the thalamoperforators and posterior cerebral arteries.
3. Type III (aka true, or choroidal type). *Most common type*. Mixed pattern of feeders, arising from the pericallosal arteries, thalamoperforators, and posterior cerebral arteries.
4. Type IV (aka secondary type). Aneurysmal dilatation (i.e., varix) of the vein of Galen resulting from shunting from adjacent parenchymal AVM or dural AV fistula, or outlet obstruction in the straight sinus.

14.4.2. Development, anatomy and pathophysiology

14.4.2.1. Embryology

The embryonic precursor to the normal vein of Galen is the median prosencephalic vein, which has arteriovenous fistulous connections within the primitive vascular bed. The fistulous connections normally involute between the fifth and seventh

weeks of development,²⁵³ and by 3 months of development, the posterior part of the median prosencephalic vein joins the internal cerebral veins and the basal veins to form the vein of Galen. Persistence of the median prosencephalic vein and its primitive arteriovenous connections leads to a true vein of Galen malformation. The sump effect of the high flow, low resistance venous drainage leads to the recruitment and enlargement of feeding arteries.

14.4.2.2. Anatomy

Vein of Galen malformations are midline structures, extending from the inter-ventricular foramen to the choroidal fissure, and laterally to the atria.²⁵¹

1. Arterial supply is usually bilateral and symmetrical.²⁵⁴
 - (a) Choroidal arteries. In most cases all of the choroidal arteries contribute feeders.
 - (b) Subependymal arterial network arising from the posterior circle of Willis.
 - (c) Thalamoperforators – rare.
2. Venous drainage is into a dilated median vein of the prosencephalon, which drains into a falcine sinus and then into the superior sagittal sinus or the posterior venous sinuses.
 - (a) The straight sinus is absent in most patients.²⁵⁵
 - (b) Venous outlet obstruction may be present.
 - (c) There is no connection to the deep cerebral venous system.
 - Because of this, deep brain structures use alternative drainage pathways, which typically includes thalamic and subtemporal or lateral mesencephalic veins, which have an epsilon shape on a lateral angiogram.

14.4.3. Clinical features

The clinical manifestations of patients with vein of Galen malformations can be divided into cardiac and neurological problems. Patients may be divided into three age groups²⁵⁶: (1) neonates, (2) infants, and (3) older children and adults. Neonates typically appear with cardiac failure; infants usually present with hydrocephalus and head enlargement²⁵⁷; older patients frequently present with hydrocephalus, headaches, and developmental delay.

1. High output cardiac failure.
 - (a) The intracranial AV shunt can be hemodynamically significant, resulting in dilatation of the right chambers of the heart,²⁵⁸ pulmonary hypertension, and left heart failure.
 - (b) A loud, machine-like bruit may be present over the head and chest.²⁵⁶
 - (c) May be diagnosed by prenatal ultrasound; 22% of children with a prenatal diagnosis have irreversible brain damage at birth and die.²⁵⁴
 - (d) The severity of cardiac symptoms vary widely, from asymptomatic cardiomegaly to cardiogenic shock.
 - In some cases, a brief (3-day) period of relative stability occurs after birth, followed by acute decompensation.²⁵⁴
 - Some patients require emergent embolization of the intracranial lesion, whereas others may be medically stabilized for a while, and undergo embolization later in life.
2. Neurological manifestations.
 - (a) Neurological symptoms are attributable to:
 - Intracranial venous hypertension, resulting from AV shunting and venous outflow obstruction.
 - Heart failure, which may cause pre- and post-natal brain damage. MRI may show white matter lesions or diffuse brain destruction (i.e., *melting brain syndrome*).²⁵⁹
 - Hydrocephalus.
 - The intracranial venous system normally possesses a pressure gradient that facilitates absorption of CSF. Intracranial venous hypertension interferes with this process.

14.4.4. Natural history and overall prognosis

Although many publications about vein of Galen malformations include a discussion of the "natural history" of these lesions, a firm understanding of the prognosis of untreated patients is nearly impossible to obtain. The rarity of these lesions, the wide spectrum of severity at presentation, and the variety of treatment approaches currently in use (treatment vs. no treatment, arterial vs. venous embolization, ventricular shunting vs. no shunting) make it difficult to generalize about outcome. Clinical results reported below are from Lasjaunias and colleagues at Hopital de Bicêtre in France.

1. Overall, about 50% of neonates with vein of Galen malformations can be salvaged.²⁵⁶
2. Spontaneous thrombosis of a vein of Galen malformation is rare, and has been reported to occur in some 2.5% of patients (with half of them neurologically normal).²⁵⁴

14.4.5. Management and outcomes

Most authors agree that patients at the two ends of the spectrum of severity, those with profound symptoms and multisystem failure, and those with completely asymptomatic lesions may be followed expectantly.²⁵⁶

14.4.5.1. Neonates

Lasjaunias and colleagues have developed scoring system to help with decision-making (Table 14.4).²⁶⁰

1. Score <8 is associated with a poor systemic or neurological outcome and may be an indication to withhold therapy.
2. Score 8–12 is associated with normal neurological status by medically-refractory heart failure, and emergent embolization should be considered.
3. Score >12 indicates that the patient may be stable enough to delay embolization until the child is at least 5 months of age.

Table 14.4 Bicêtre neonatal evaluation score²⁶⁰

Points	Cardiac function	Cerebral function	Respiratory function	Hepatic function	Renal function
5	Normal	Normal	Normal	–	–
4	Overload, no medical treatment	Subclinical, isolated EEG abnormalities	Tachypnea, finishes bottle	–	–
3	Failure; stable with medical treatment	Nonconvulsive intermittent neurological signs	Tachypnea, does not finish bottle	No hepatomegaly, normal hepatic function	Normal
2	Failure; not stable with medical treatment	Isolated convulsion	Assisted ventilation, normal saturation FIO ₂ <25%	Hepatomegaly, normal hepatic function	Transient anuria
1	Ventilation necessary	Seizures	Assisted ventilation, normal saturation FIO ₂ >25%	Moderate or transient hepatic insufficiency	Unstable diuresis with treatment
0	Resistant to medical therapy	Permanent neurological signs	Assisted ventilation, desaturation	Abnormal coagulation, elevated enzymes	Anuria

EEG electroencephalogram; FIO₂ fraction of inspired oxygen. Maximum score = 21. Reproduced from Vascular Diseases in Neonates, Infants and Children: Interventional Neuroradiology Management, 49, Lasjaunias P: "Neonatal evaluation score (Bicêtre)." © 1997 Springer Science and Business Media with permission.

14.4.5.2. Treatment in neonates

1. Evaluation of neonates with vein of Galen malformations should include the following²⁵⁵:
 - (a) Weight and head circumference
 - (b) Renal and liver function tests
 - (c) Cranial and cardiac ultrasound exams
 - (d) Brain MRI, to provide information about lesion anatomy and the status of myelination.
 - Catheter angiography is *not indicated* unless embolization is planned.
2. The optimal age for embolization is ≥ 5 months.²⁵⁴ Treatment should be delayed until then when possible.
3. The interventional strategy consists of arterial embolization to reduce the shunt.
 - (a) Venous embolization in neonates is associated with higher morbidity^{261–264} and should be used only when an arterial route is not available.²⁵⁴
 - (b) Glue (e.g., NBCA) is the preferred agent for embolization because it is more resistant to recanalization than particles or coils.
4. Reduction of 30% of shunt volume is sufficient to improve cardiac function and permit weaning of the ventilator.²⁵⁴
 - (a) An angiographic cure of the lesion is not necessary to control symptoms and allow the brain to develop normally.

14.4.5.3. Outcomes in neonates

Of 23 neonates treated, death occurred despite or because of embolization in 52%; of the survivors, 36.4% were neurologically normal and 63.6% had moderate or severe retardation.²⁵⁵

14.4.5.4. Infants

1. Hydrocephalus in vein of Galen malformation patients is due to intracranial venous hypertension, and frequently responds to treatment of the lesion.
2. CSF shunting should be reserved until after endovascular treatment has been undertaken.^{254,257}
 - (a) Less than 50% of patients with hydrocephalus go on to require a shunt.²⁵⁶
 - (b) CSF shunting can be problematic in these patients. Shunting may contribute to venocongestive brain edema,²⁶⁵ and carries a risk of subdural hematoma development.
 - (c) Endoscopic third ventriculostomy is an acceptable alternative to ventricular shunting in selected patients.²⁵⁴

14.4.5.5. Outcomes in infants

Of 153 infants treated, death occurred despite or because of embolization in 7.2%; of the survivors, 78.9% were neurologically normal and 21.1% had moderate or severe retardation.²⁵⁵

14.4.5.6. Children and adults

Developmental delay is part of the natural history of untreated symptomatic vein of Galen malformations,²⁵⁵ because of sustained, long-term intracranial venous hypertension and hydrocephalus.

1. Elevated intracranial venous pressures are well-documented in patients with vein of Galen malformations.²⁶⁶
2. Some authors argue strenuously that embolization should be done to normalize venous pressure, and treat hydrocephalus, prior to CSF shunt placement.²⁵⁵
3. Adults: Very rare.^{267–270}

14.4.5.7. Outcomes in children

Of 40 children treated, no deaths occurred, 67.5% were neurologically normal and 32.5% had moderate or severe retardation.²⁵⁵

14.4.5.8. Complications of embolization procedures

At Hopital de Bicêtre, total of 196 patients, 1981–2002²⁵⁵:

1. Transient neurological disability: 1.6%
2. Permanent neurological disability: 2.1%
3. Nondisabling nonneurological complications: 6.7%
4. Hemorrhage: 5.6%

14.5. References

1. Cushing H, Bailey P. Tumors Arising from the Blood Vessels of the Brain: Angiomatous Malformations and Hemangioblastomas. Springfield, IL: Charles C. Thomas; 1928:9–102.
2. Challa VR, Moody DM, Brown WR. Vascular malformations of the central nervous system. *J Neuropathol Exp Neurol* 1995;54(5):609–21.
3. Mandybur TI, Nazek M. Cerebral arteriovenous malformations. A detailed morphological and immunohistochemical study using actin. *Arch Pathol Lab Med* 1990;114(9):970–3.
4. Zabramski JM, Henn JS, Coons S. Pathology of cerebral vascular malformations. *Neurosurg Clin N Am* 1999;10(3):395–410.
5. Mullan S, Mojtahedi S, Johnson DL, Macdonald RL. Embryological basis of some aspects of cerebral vascular fistulas and malformations. *J Neurosurg* 1996;85(1):1–8.
6. Suh DC, Alvarez H, Bhattacharya JJ, Rodesch G, Lasjaunias PL. Intracranial haemorrhage within the first two years of life. *Acta Neurochir (Wien)* 2001;143(10):997–1004.
7. Yakšedilargil MG. AVM of the brain, history, embryology, pathological considerations, hemodynamics, diagnostic studies, microsurgical anatomy. Stuttgart: George Thieme Verlag; 1988.
8. Lasjaunias P. A revised concept of the congenital nature of cerebral arteriovenous malformations. *Intervent Neuroradiol* 1997;3:275–81.
9. Mullan S, Mojtahedi S, Johnson DL, Macdonald RL. Cerebral venous malformation-arteriovenous malformation transition forms. *J Neurosurg* 1996;85(1):9–13.
10. Iwama T, Hayashida K, Takahashi JC, Nagata I, Hashimoto N. Cerebral hemodynamics and metabolism in patients with cerebral arteriovenous malformations: an evaluation using positron emission tomography scanning. *J Neurosurg* 2002;97(6):1314–21.
11. Kader A, Young WL. The effects of intracranial arteriovenous malformations on cerebral hemodynamics. *Neurosurg Clin N Am* 1996;7(4):767–81.
12. Todaka T, Hamada J, Kai Y, Morioka M, Ushio Y. Analysis of mean transit time of contrast medium in ruptured and unruptured arteriovenous malformations: a digital subtraction angiographic study. *Stroke* 2003;34(10):2410–4.
13. Young WL, Pile-Spellman J, Prohovnik I, Kader A, Stein BM. Evidence for adaptive autoregulatory displacement in hypotensive cortical territories adjacent to arteriovenous malformations. Columbia University AVM Study Project. *Neurosurgery* 1994;34(4):601–10; discussion 10–11.
14. Mast H, Mohr JP, Osipov A, et al. 'Steal' is an unestablished mechanism for the clinical presentation of cerebral arteriovenous malformations. *Stroke* 1995;26(7):1215–20.
15. Duong DH, Young WL, Vang MC, et al. Feeding artery pressure and venous drainage pattern are primary determinants of hemorrhage from cerebral arteriovenous malformations. *Stroke* 1998;29(6):1167–76.
16. Burchiel KJ, Clarke H, Ojemann GA, Dacey RG, Winn HR. Use of stimulation mapping and corticography in the excision of arteriovenous malformations in sensorimotor and language-related neocortex. *Neurosurgery* 1989;24(3):322–7.
17. Alkadhi H, Kollias SS, Crelier GR, Golay X, Hepp-Reymond MC, Valavanis A. Plasticity of the human motor cortex in patients with arteriovenous malformations: a functional MR imaging study. *Am J Neuroradiol* 2000;21(8):1423–33.
18. McCormick WF. The pathology of vascular ("arteriovenous") malformations. *J Neurosurg* 1966;24(4):807–16.
19. Courville CB. Intracranial tumors. Notes upon a series of three thousand verified cases with some current observations pertaining to their mortality. *Bull Los Angeles Neurol Soc* 1967;32(3):Suppl 2:1–80.
20. Jellinger K. Vascular malformations of the central nervous system: a morphological overview. *Neurosurg Rev* 1986;9(3):177–216.
21. Sarwar M, McCormick WF. Intracerebral venous angioma. Case report and review. *Arch Neurol* 1978;35(5):323–5.
22. Stapf C, Mast H, Sciacca RR, et al. The New York Islands AVM Study: design, study progress, and initial results. *Stroke* 2003;34(5):e29–33.
23. Stapf C, Labovitz DL, Sciacca RR, Mast H, Mohr JP, Sacco RL. Incidence of adult brain arteriovenous malformation hemorrhage in a prospective population-based stroke survey. *Cerebrovasc Dis* 2002;13(1):43–6.
24. Hofmeister C, Stapf C, Hartmann A, et al. Demographic, morphological, and clinical characteristics of 1289 patients with brain arteriovenous malformation. *Stroke* 2000;31(6):1307–10.
25. Brown RD, Jr., Wiebers DO, Torner JC, O'Fallon WM. Incidence and prevalence of intracranial vascular malformations in Olmsted County, Minnesota, 1965 to 1992. *Neurology* 1996;46(4):949–52.
26. ApSimon HT, Reef H, Phadke RV, Popovic EA. A population-based study of brain arteriovenous malformation: long-term treatment outcomes. *Stroke* 2002;33(12):2794–800.
27. Graf CJ, Perret GE, Torner JC. Bleeding from cerebral arteriovenous malformations as part of their natural history. *J Neurosurg* 1983;58(3):331–7.
28. McCormick WF, Rosenfield DB. Massive brain hemorrhage: a review of 144 cases and an examination of their causes. *Stroke* 1973;4(6):946–54.
29. Khaw AV, Mohr JP, Sciacca RR, et al. Association of infratentorial brain arteriovenous malformations with hemorrhage at initial presentation. *Stroke* 2004;35(3):660–3.
30. Spetzler RF, Martin NA. A proposed grading system for arteriovenous malformations. *J Neurosurg* 1986;65(4):476–83.
31. Valavanis A. The role of angiography in the evaluation of cerebral vascular malformations. *Neuroimaging Clin N Am* 1996;6(3):679–704.

32. Willinsky RA, Lasjaunias P, Terbrugge K, Burrows P. Multiple cerebral arteriovenous malformations (AVMs). Review of our experience from 203 patients with cerebral vascular lesions. *Neuroradiology* 1990;32(3):207-10.
33. Putman CM, Chaloupka JC, Fulbright RK, Awad IA, White RI Jr, Fayad PB. Exceptional multiplicity of cerebral arteriovenous malformations associated with hereditary hemorrhagic telangiectasia (Osler-Weber-Rendu syndrome). *Am J Neuroradiol* 1996;17(9):1733-42.
34. van Beijnum J, van der Worp HB, Schippers HM, et al. Familial occurrence of brain arteriovenous malformations: a systematic review. *J Neurol Neurosurg Psychiatry* 2007;78(11):1213-7.
35. Rendu HJM. Épistaxis répétées chez un sujet porteur de petits angiomes cutanés et muqueux. *Bull Soc Med Hop* 1896;13:731-3.
36. Osler W. On family form of recurring epistaxis, associated with multiple telangiectasias of skin and mucous membranes. *Bull Johns Hopkins Hosp* 1901;12:333-7.
37. Weber EP. Multiple hereditary developmental angiomas (telangiectasia) of the skin and mucous membranes associated with recurring hemorrhages. *Lancet* 1907;2:160-2.
38. Shovlin CL, Guttmacher AE, Buscarini E, et al. Diagnostic criteria for hereditary hemorrhagic telangiectasia (Rendu-Osler-Weber syndrome). *Am J Med Genet* 2000;91(1):66-7.
39. Bideau A, Planchu H, Brunet G, Robert J. Epidemiological investigation of Rendu-Osler disease in France: its geographical distribution and prevalence. *Population* 1989;44(1):3-22.
40. Kjeldsen AD, Vase P, Green A. Hereditary haemorrhagic telangiectasia: a population-based study of prevalence and mortality in Danish patients. *J Intern Med* 1999;245(1):31-9.
41. Dakeishi M, Shioya T, Wada Y, et al. Genetic epidemiology of hereditary hemorrhagic telangiectasia in a local community in the northern part of Japan. *Hum Mutat* 2002;19(2):140-8.
42. Sadick H, Sadick M, Gotte K, et al. Hereditary hemorrhagic telangiectasia: an update on clinical manifestations and diagnostic measures. *Wien Klin Wochenschr* 2006;118(3-4):72-80.
43. Roman G, Fisher M, Perl DP, Poser CM. Neurological manifestations of hereditary hemorrhagic telangiectasia (Rendu-Osler-Weber disease): report of 2 cases and review of the literature. *Ann Neurol* 1978;4(2):130-44.
44. Waller JD, Greenberg JH, Lewis CW. Hereditary hemorrhagic telangiectasia with cerebrovascular malformations. *Arch Dermatol* 1976;112(1):49-52.
45. Fulbright RK, Chaloupka JC, Putman CM, et al. MR of hereditary hemorrhagic telangiectasia: prevalence and spectrum of cerebrovascular malformations. *Am J Neuroradiol* 1998;19(3):477-84.
46. Haitjema T, Disch F, Overtoom TT, Westermann CJ, Lammers JW. Screening family members of patients with hereditary hemorrhagic telangiectasia. *Am J Med* 1995;99(5):519-24.
47. Willemsse RB, Mager JJ, Westermann CJ, Overtoom TT, Mauser H, Wolbers JG. Bleeding risk of cerebrovascular malformations in hereditary hemorrhagic telangiectasia. *J Neurosurg* 2000;92(5):779-84.
48. Easey AJ, Wallace GM, Hughes JM, Jackson JE, Taylor WJ, Shovlin CL. Should asymptomatic patients with hereditary haemorrhagic telangiectasia (HHT) be screened for cerebral vascular malformations? Data from 22,061 years of HHT patient life. *J Neurol Neurosurg Psychiatry* 2003;74(6):743-8.
49. Burke CM, Safai C, Nelson DP, Raffin TA. Pulmonary arteriovenous malformations: a critical update. *Am Rev Respir Dis* 1986;134(2):334-9.
50. Jessurun GA, Kamphuis DJ, van der Zande FH, Nossent JC. Cerebral arteriovenous malformations in The Netherlands Antilles. High prevalence of hereditary hemorrhagic telangiectasia-related single and multiple cerebral arteriovenous malformations. *Clin Neurol Neurosurg* 1993;95(3):193-8.
51. Romer W, Burk M, Schneider W. [Hereditary hemorrhagic telangiectasia (Osler's disease)]. *Dtsch Med Wochenschr* 1992;117(17):669-75.
52. Haitjema T, Balder W, Disch FJ, Westermann CJ. Epistaxis in hereditary haemorrhagic telangiectasia. *Rhinology* 1996;34(3):176-8.
53. Sadick H, Fleischer I, Goessler U, Hormann K, Sadick M. Twenty-four-hour and annual variation in onset of epistaxis in Osler disease. *Chronobiol Int* 2007;24(2):357-64.
54. White RI Jr, Lynch-Nyhan A, Terry P, et al. Pulmonary arteriovenous malformations: techniques and long-term outcome of embolotherapy. *Radiology* 1988;169(3):663-9.
55. Vase P, Holm M, Arendrup H. Pulmonary arteriovenous fistulas in hereditary hemorrhagic telangiectasia. *Acta Med Scand* 1985;218(1):105-9.
56. Mager HJ, Overtoom TT, Mauser HW, Westermann CJ. Early cerebral infarction after embolotherapy of a pulmonary arteriovenous malformation. *J Vasc Interv Radiol* 2001;12(1):122-3.
57. Guttmacher AE, Marchuk DA, White RI, Jr. Hereditary hemorrhagic telangiectasia. *N Engl J Med* 1995;333(14):918-24.
58. Snyder LH, Doan CA. Clinical and experimental studies in human inheritance. Is the homozygous form of multiple telangiectasia lethal? *J Lab Clin Med* 1944;29:1211-367.
59. Shovlin CL, Hughes JM, Tuddenham EG, et al. A gene for hereditary haemorrhagic telangiectasia maps to chromosome 9q3. *Nat Genet* 1994;6(2):205-9.
60. McDonald MT, Papenberg KA, Ghosh S, et al. A disease locus for hereditary haemorrhagic telangiectasia maps to chromosome 9q33-34. *Nat Genet* 1994;6(2):197-204.
61. Johnson DW, Berg JN, Gallione CJ, et al. A second locus for hereditary hemorrhagic telangiectasia maps to chromosome 12. *Genome Res* 1995;5(1):21-8.
62. Wyburn-Mason R. Arteriovenous aneurysm of mid-brain and retina, facial naevi and mental changes. *Brain* 1943;66:163-203.
63. Théron J, Newton TH, Hoyt WF. Unilateral retinocephalic vascular malformations. *Neuroradiology* 1974;7(4):185-96.
64. Mizutani T, Tanaka H, Aruga T. Multiple arteriovenous malformations located in the cerebellum, posterior fossa, spinal cord, dura, and scalp with associated port-wine stain and supratentorial venous anomaly. *Neurosurgery* 1992;31(1):137-40; discussion 40-1.
65. Laufer L, Cohen A. Sturge-Weber syndrome associated with a large left hemispheric arteriovenous malformation. *Pediatr Radiol* 1994;24(4):272-3.
66. Crawford PM, West CR, Chadwick DW, Shaw MD. Arteriovenous malformations of the brain: natural history in unoperated patients. *J Neurol Neurosurg Psychiatry* 1986;49(1):1-10.
67. Itoyama Y, Uemura S, Ushio Y, et al. Natural course of unoperated intracranial arteriovenous malformations: study of 50 cases. *J Neurosurg* 1989;71(6):805-9.
68. Brown RD, Jr, Wiebers DO, Forbes GS. Unruptured intracranial aneurysms and arteriovenous malformations: frequency of intracranial hemorrhage and relationship of lesions. *J Neurosurg* 1990;73(6):859-63.
69. Ondra SL, Troupp H, George ED, Schwab K. The natural history of symptomatic arteriovenous malformations of the brain: a 24-year follow-up assessment. *J Neurosurg* 1990;73(3):387-91.
70. Mast H, Young WL, Koennecke HC, et al. Risk of spontaneous haemorrhage after diagnosis of cerebral arteriovenous malformation. *Lancet* 1997;350(9084):1065-8.
71. Halim AX, Johnston SC, Singh V, et al. Longitudinal risk of intracranial hemorrhage in patients with arteriovenous malformation of the brain within a defined population. *Stroke* 2004;35(7):1697-702.
72. Forster DM, Steiner L, Hakanson S. Arteriovenous malformations of the brain. A long-term clinical study. *J Neurosurg* 1972;37(5):562-70.
73. Fufts D, Kelly DL, Jr. Natural history of arteriovenous malformations of the brain: a clinical study. *Neurosurgery* 1984;15(5):658-62.
74. Choi JH, Mast H, Sciacca RR, et al. Clinical outcome after first and recurrent hemorrhage in patients with untreated brain arteriovenous malformation. *Stroke* 2006;37(5):1243-7.

75. Brown RD, Jr, Wiebers DO, Forbes G, et al. The natural history of unruptured intracranial arteriovenous malformations. *J Neurosurg* 1988;68(3):352-7.
76. Fullerton HJ, Achrol AS, Johnston SC, et al. Long-term hemorrhage risk in children versus adults with brain arteriovenous malformations. *Stroke* 2005;36(10):2099-104.
77. Abdulrauf SI, Malik GM, Awad IA. Spontaneous angiographic obliteration of cerebral arteriovenous malformations. *Neurosurgery* 1999;44(2):280-7; discussion 7-8.
78. Kondziolka D, McLaughlin MR, Kestle JR. Simple risk predictions for arteriovenous malformation hemorrhage. *Neurosurgery* 1995;37(5):851-5.
79. Brown RD, Jr. Simple risk predictions for arteriovenous malformation hemorrhage. *Neurosurgery* 2000;46(4):1024.
80. Arias E. United States Life Tables, 2002. *Natl Vital Stat Rep* 2004;53(6):1-38.
81. Stapf C, Khaw AV, Sciacca RR, et al. Effect of age on clinical and morphological characteristics in patients with brain arteriovenous malformation. *Stroke* 2003;34(11):2664-9.
82. Choi JH, Mohr JP. Brain arteriovenous malformations in adults. *Lancet Neurol* 2005;4(5):299-308.
83. Hartmann A, Mast H, Mohr JP, et al. Morbidity of intracranial hemorrhage in patients with cerebral arteriovenous malformation. *Stroke* 1998;29(5):931-4.
84. Stapf C, Mast H, Sciacca RR, et al. Predictors of hemorrhage in patients with untreated brain arteriovenous malformation. *Neurology* 2006;66(9):1350-5.
85. Waltimo O. The change in size of intracranial arteriovenous malformations. *J Neurol Sci* 1973;19(1):21-7.
86. Guidetti B, Delitala A. Intracranial arteriovenous malformations. Conservative and surgical treatment. *J Neurosurg* 1980;53(2):149-52.
87. Spetzler RF, Hargraves RW, McCormick PW, Zabramski JM, Flom RA, Zimmerman RS. Relationship of perfusion pressure and size to risk of hemorrhage from arteriovenous malformations. *J Neurosurg* 1992;76(6):918-23.
88. Langer DJ, Lasner TM, Hurst RW, Flamm ES, Zager EL, King JT, Jr. Hypertension, small size, and deep venous drainage are associated with risk of hemorrhagic presentation of cerebral arteriovenous malformations. *Neurosurgery* 1998;42(3):481-6; discussion 7-9.
89. Albert P, Salgado H, Polaina M, Trujillo F, Ponce de Leon A, Durand F. A study on the venous drainage of 150 cerebral arteriovenous malformations as related to haemorrhagic risks and size of the lesion. *Acta Neurochir (Wien)* 1990;103(1-2):30-4.
90. Karlsson B, Lindquist C, Johansson A, Steiner L. Annual risk for the first hemorrhage from untreated cerebral arteriovenous malformations. *Minim Invasive Neurosurg* 1997;40(2):40-6.
91. Stefani MA, Porter PJ, terBrugge KG, Montanera W, Willinsky RA, Wallace MC. Large and deep brain arteriovenous malformations are associated with risk of future hemorrhage. *Stroke* 2002;33(5):1220-4.
92. Nataf F, Meder JF, Roux FX, et al. Angioarchitecture associated with haemorrhage in cerebral arteriovenous malformations: a prognostic statistical model. *Neuroradiology* 1997;39(1):52-8.
93. Fleetwood IG, Marcellus ML, Levy RP, Marks MP, Steinberg GK. Deep arteriovenous malformations of the basal ganglia and thalamus: natural history. *J Neurosurg* 2003;98(4):747-50.
94. Drummond JC, Patel PM. Cerebral physiology and the effects of anesthetics and techniques. In: Miller RD, ed. *Anesthesia*. 5th ed. Philadelphia, PA: Churchill Livingstone; 2000.
95. Turjman F, Massoud TF, Vinueza F, Sayre JW, Guglielmi G, Duckwiler G. Correlation of the angioarchitectural features of cerebral arteriovenous malformations with clinical presentation of hemorrhage. *Neurosurgery* 1995;37(5):856-60; discussion 60-2.
96. Miyasaka Y, Yada K, Ohwada T, Kitahara T, Kurata A, Irikura K. An analysis of the venous drainage system as a factor in hemorrhage from arteriovenous malformations. *J Neurosurg* 1992;76(2):239-43.
97. Kim H, Sidney S, McCulloch CE, et al. Racial/ethnic differences in longitudinal risk of intracranial hemorrhage in brain arteriovenous malformation patients. *Stroke* 2007;38(9):2430-7.
98. Pawlikowska L, Tran MN, Achrol AS, et al. Polymorphisms in genes involved in inflammatory and angiogenic pathways and the risk of hemorrhagic presentation of brain arteriovenous malformations. *Stroke* 2004;35(10):2294-300.
99. Stapf C, Mohr JP, Pile-Spellman J, Solomon RA, Sacco RL, Connolly ES, Jr. Epidemiology and natural history of arteriovenous malformations. *Neurosurg Focus* 2001;11(5):e1.
100. Wilkins RH. Natural history of intracranial vascular malformations: a review. *Neurosurgery* 1985;16(3):421-30.
101. Perret G, Nishioka H. Report on the cooperative study of intracranial aneurysms and subarachnoid hemorrhage. Section VI. Arteriovenous malformations. An analysis of 545 cases of cranio-cerebral arteriovenous malformations and fistulae reported to the cooperative study. *J Neurosurg* 1966;25(4):467-90.
102. Yeh HS, Kashiwagi S, Tew JM, Jr, Berger TS. Surgical management of epilepsy associated with cerebral arteriovenous malformations. *J Neurosurg* 1990;72(2):216-23.
103. Parkinson D, Bachers G. Arteriovenous malformations. Summary of 100 consecutive supratentorial cases. *J Neurosurg* 1980;53(3):285-99.
104. Monteiro JM, Rosas MJ, Correia AP, Vaz AR. Migraine and intracranial vascular malformations. *Headache* 1993;33(10):563-5.
105. Haas DC. Migraine and intracranial vascular malformations. *Headache* 1994;34(5):287.
106. Obermann M, Gizewski ER, Limmroth V, Diener HC, Katsarava Z. Symptomatic migraine and pontine vascular malformation: evidence for a key role of the brainstem in the pathophysiology of chronic migraine. *Cephalalgia* 2006;26(6):763-6.
107. Lazar RM, Connaire K, Marshall RS, et al. Developmental deficits in adult patients with arteriovenous malformations. *Arch Neurol* 1999;56(1):103-6.
108. Korogi Y, Takahashi M, Mabuchi N, et al. Intracranial aneurysms: diagnostic accuracy of three-dimensional, Fourier transform, time-of-flight MR angiography. *Radiology* 1994;193(1):181-6.
109. Huston J, III, Rufenacht DA, Ehman RL, Wiebers DO. Intracranial aneurysms and vascular malformations: comparison of time-of-flight and phase-contrast MR angiography. *Radiology* 1991;181(3):721-30.
110. Zhu XL, Chan MS, Poon WS. Spontaneous intracranial hemorrhage: which patients need diagnostic cerebral angiography? A prospective study of 206 cases and review of the literature. *Stroke* 1997;28(7):1406-9.
111. Cloft HJ, Joseph GJ, Dion JE. Risk of cerebral angiography in patients with subarachnoid hemorrhage, cerebral aneurysm, and arteriovenous malformation: a meta-analysis. *Stroke* 1999;30(2):317-20.
112. Ogilvy CS, Stieg PE, Awad I, et al. AHA Scientific Statement: Recommendations for the management of intracranial arteriovenous malformations: a statement for healthcare professionals from a special writing group of the Stroke Council, American Stroke Association. *Stroke* 2001;32(6):1458-71.
113. Cockroft KM. Unruptured cerebral arteriovenous malformations: to treat or not to treat. *Stroke* 2006;37(5):1148-9.
114. Stapf C, Mohr JP, Choi JH, Hartmann A, Mast H. Invasive treatment of unruptured brain arteriovenous malformations is experimental therapy. *Curr Opin Neurol* 2006;19(1):63-8.
115. Fleetwood IG, Steinberg GK. Arteriovenous malformations. *Lancet* 2002;359(9309):863-73.
116. Baskaya MK, Jea A, Heros RC, Javahary R, Sultan A. Cerebral arteriovenous malformations. *Clin Neurosurg* 2006;53:114-44.
117. McInerney J, Gould DA, Birkmeyer JD, Harbaugh RE. Decision analysis for small, asymptomatic intracranial arteriovenous malformations. *Neurosurg Focus* 2001;11(5):e7.
118. Heros RC, Korosue K, Diebold PM. Surgical excision of cerebral arteriovenous malformations: late results. *Neurosurgery* 1990;26(4):570-7; discussion 7-8.
119. Sisti MB, Kader A, Stein BM. Microsurgery for 67 intracranial arteriovenous malformations less than 3 cm in diameter. *J Neurosurg* 1993;79(5):653-60.

120. Hamilton MG, Spetzler RF. The prospective application of a grading system for arteriovenous malformations. *Neurosurgery* 1994;34(1):2-6; discussion-7.
121. Pikus HJ, Beach ML, Harbaugh RE. Microsurgical treatment of arteriovenous malformations: analysis and comparison with stereotactic radiosurgery. *J Neurosurg* 1998;88(4):641-6.
122. Pik JH, Morgan MK. Microsurgery for small arteriovenous malformations of the brain: results in 110 consecutive patients. *Neurosurgery* 2000;47(3):571-5; discussion 5-7.
123. Lawton MT, Spetzler-Martin Grade III arteriovenous malformations: surgical results and a modification of the grading scale. *Neurosurgery* 2003;52(4):740-8; discussion 8-9.
124. Castel JP, Kantor G. [Postoperative morbidity and mortality after microsurgical exclusion of cerebral arteriovenous malformations. Current data and analysis of recent literature]. *Neurochirurgie* 2001;47(2-3 Pt 2):369-83.
125. Schaller C, Schramm J, Haun D. Significance of factors contributing to surgical complications and to late outcome after elective surgery of cerebral arteriovenous malformations. *J Neurol Neurosurg Psychiatry* 1998;65(4):547-54.
126. Morgan MK, Rochford AM, Tsatsarlis A, Little N, Faulder KC. Surgical risks associated with the management of Grade I and II brain arteriovenous malformations. *Neurosurgery* 2004;54(4):832-7; discussion 7-9.
127. Russell SM, Woo HH, Joseffer SS, Jafar JJ. Role of frameless stereotaxy in the surgical treatment of cerebral arteriovenous malformations: technique and outcomes in a controlled study of 44 consecutive patients. *Neurosurgery* 2002;51(5):1108-16; discussion 16-8.
128. Steiner L, Lindquist C, Adler JR, Torner JC, Alves W, Steiner M. Clinical outcome of radiosurgery for cerebral arteriovenous malformations. *J Neurosurg* 1992;77(1):1-8.
129. Hoh BL, Chapman PH, Loeffler JS, Carter BS, Ogilvy CS. Results of multimodality treatment for 141 patients with brain arteriovenous malformations and seizures: factors associated with seizure incidence and seizure outcomes. *Neurosurgery* 2002;51(2):303-9; discussion 9-11.
130. Martin NA, Wilson CB. Preoperative and postoperative care: management of intracranial hemorrhage. In: Wilson CB, Stein BM, eds. *Intracranial Arteriovenous Malformations*. Baltimore: Williams & Wilkins; 1984:121-9.
131. Solomon RA, Stein BM. Management of deep supratentorial and brain stem arteriovenous malformations. In: Barrow DL, ed. *Intracranial Vascular Malformations*. Park Ridge, IL: American Association of Neurological Surgeons; 1990:125-41.
132. Jafar JJ, Rezaei AR. Acute surgical management of intracranial arteriovenous malformations. *Neurosurgery* 1994;34(1):8-12; discussion-3.
133. Lefkowitz MA, Vinuela F, Martin N. Critical care management. In: Stieg PE, Batjer HH, Samson D, eds. *Intracranial Arteriovenous Malformations*. New York: Informa; 2007:329-42.
134. Hoh BL, Carter BS, Ogilvy CS. Incidence of residual intracranial AVMs after surgical resection and efficacy of immediate surgical re-exploration. *Acta Neurochir (Wien)* 2004;146(1):1-7; discussion.
135. Morcos JJ, Heros RC. Supratentorial arteriovenous malformations. In: Carter LP, Spetzler RF, Hamilton MG, eds. *Neurovascular Surgery*. New York: McGraw-Hill; 1995:979-1004.
136. Harrigan MR, Thompson BG. Critical care management. In: Stieg PE, Batjer HH, Samson D, eds. *Intracranial Arteriovenous Malformations*. New York: Informa; 2007:383-92.
137. al-Rodhan NR, Sundt TM, Jr., Piepgras DG, Nichols DA, Rufenacht D, Stevens LN. Occlusive hyperemia: a theory for the hemodynamic complications following resection of intracerebral arteriovenous malformations. *J Neurosurg* 1993;78(2):167-75.
138. Drake CG. Cerebral arteriovenous malformations: considerations for and experience with surgical treatment in 166 cases. *Clin Neurosurg* 1979;26:145-208.
139. Kader A, Young WL. Arteriovenous malformations: considerations for perioperative critical care monitoring. In: Batjer H, ed. *Cerebrovascular Disease*. Philadelphia, PA: Lippincott-Raven; 1997.
140. Morgan MK, Johnston IH, Hallinan JM, Weber NC. Complications of surgery for arteriovenous malformations of the brain. *J Neurosurg* 1993;78(2):176-82.
141. Wilson CB, Hieshima G. Occlusive hyperemia: a new way to think about an old problem. *J Neurosurg* 1993;78(2):165-6.
142. Spetzler RF, Wilson CB, Weinstein P, Mehdorn M, Townsend J, Telles D. Normal perfusion pressure breakthrough theory. *Clin Neurosurg* 1978;25:651-72.
143. Day AL, Friedman WA, Sybert GW, Mickle JP. Successful treatment of the normal perfusion pressure breakthrough syndrome. *Neurosurgery* 1982;11(5):625-30.
144. Batjer HH, Devous MD, Sr. The use of acetazolamide-enhanced regional cerebral blood flow measurement to predict risk to arteriovenous malformation patients. *Neurosurgery* 1992;31(2):213-7; discussion 7-8.
145. Young WL, Prohovnik I, Ornstein E, et al. The effect of arteriovenous malformation resection on cerebrovascular reactivity to carbon dioxide. *Neurosurgery* 1990;27(2):257-66; discussion 66-7.
146. Morgan MK, Winder M, Little NS, Finfer S, Ritson E. Delayed hemorrhage following resection of an arteriovenous malformation in the brain. *J Neurosurg* 2003;99(6):967-71.
147. Yasargil MG. *Microsurgery B, III. AVM of the Brain*. Stuttgart: George Thieme Verlag; 1988.
148. Sipes EP, Kirsch JR, Nauta HJ, Debrun G, Ulatowski JA, Bell WR. Intra-arterial urokinase for treatment of retrograde thrombosis following resection of an arteriovenous malformation. Case report. *J Neurosurg* 1992;76(6):1004-7.
149. Miyasaka Y, Yada K, Ohwada T, et al. Hemorrhagic venous infarction after excision of an arteriovenous malformation. Case report. *Neurosurgery* 1991;29(2):265-8.
150. Yamamoto M. Gamma knife radiosurgery: technology, applications, and future directions. *Neurosurg Clin N Am* 1999;10(2):181-202.
151. Steinberg GK, Fabrikant JI, Marks MP, et al. Stereotactic helium ion Bragg peak radiosurgery for intracranial arteriovenous malformations. Detailed clinical and neuroradiologic outcome. *Stereotact Funct Neurosurg* 1991;57(1-2):36-49.
152. Kjellberg RN. Stereotactic Bragg peak proton beam radiosurgery for cerebral arteriovenous malformations. *Ann Clin Res* 1986;18 Suppl 47:17-9.
153. Schneider BF, Eberhard DA, Steiner LE. Histopathology of arteriovenous malformations after gamma knife radiosurgery. *J Neurosurg* 1997;87(3):352-7.
154. Szeifert GT, Kemeny AA, Timperley WR, Forster DM. The potential role of myofibroblasts in the obliteration of arteriovenous malformations after radiosurgery. *Neurosurgery* 1997;40(1):61-5; discussion 5-6.
155. Lunsford LD, Kondziolka D, Flickinger JC, et al. Stereotactic radiosurgery for arteriovenous malformations of the brain. *J Neurosurg* 1991;75(4):512-24.
156. Colombo F, Pozza F, Chierigo G, Casentini L, De Luca G, Francescon P. Linear accelerator radiosurgery of cerebral arteriovenous malformations: an update. *Neurosurgery* 1994;34(1):14-20; discussion-1.
157. Friedman WA, Bova FJ, Mendenhall WM. Linear accelerator radiosurgery for arteriovenous malformations: the relationship of size to outcome. *J Neurosurg* 1995;82(2):180-9.
158. Yamamoto Y, Coffey RJ, Nichols DA, Shaw EG. Interim report on the radiosurgical treatment of cerebral arteriovenous malformations. The influence of size, dose, time, and technical factors on obliteration rate. *J Neurosurg* 1995;83(5):832-7.
159. Schlienger M, Atlan D, Lefkopoulou D, et al. Linac radiosurgery for cerebral arteriovenous malformations: results in 169 patients. *Int J Radiat Oncol Biol Phys* 2000;46(5):1135-42.
160. Shin M, Kawamoto S, Kurita H, et al. Retrospective analysis of a 10-year experience of stereotactic radio surgery for

- arteriovenous malformations in children and adolescents. *J Neurosurg* 2002;97(4):779-84.
161. Maruyama K, Kawahara N, Shin M, et al. The risk of hemorrhage after radiosurgery for cerebral arteriovenous malformations. *N Engl J Med* 2005;352(2):146-53.
 162. Pollock BE, Flickinger JC, Lunsford LD, Bissonette DJ, Kondziolka D. Hemorrhage risk after stereotactic radiosurgery of cerebral arteriovenous malformations. *Neurosurgery* 1996;38(4):652-9; discussion 9-61.
 163. Karlsson B, Lax I, Söderman M. Risk for hemorrhage during the 2-year latency period following gamma knife radiosurgery for arteriovenous malformations. *Int J Radiat Oncol Biol Phys* 2001;49(4):1045-51.
 164. Shin M, Kawahara N, Maruyama K, Tago M, Ueki K, Kirino T. Risk of hemorrhage from an arteriovenous malformation confirmed to have been obliterated on angiography after stereotactic radiosurgery. *J Neurosurg* 2005;102(5):842-6.
 165. Kurita H, Kawamoto S, Suzuki I, et al. Control of epilepsy associated with cerebral arteriovenous malformations after radiosurgery. *J Neurol Neurosurg Psychiatry* 1998;65(5):648-55.
 166. Eisenschank S, Gilmore RL, Friedman WA, Henchey RA. The effect of LINAC stereotactic radiosurgery on epilepsy associated with arteriovenous malformations. *Stereotact Funct Neurosurg* 1998;71(2):51-61.
 167. Schauble B, Cascino GD, Pollock BE, et al. Seizure outcomes after stereotactic radiosurgery for cerebral arteriovenous malformations. *Neurology* 2004;63(4):683-7.
 168. Lim YJ, Lee CY, Koh JS, Kim TS, Kim GK, Rhee BA. Seizure control of gamma knife radiosurgery for non-hemorrhagic arteriovenous malformations. *Acta Neurochir Suppl* 2006;99:97-101.
 169. Flickinger JC, Kondziolka D, Lunsford LD, et al. A multi-institutional analysis of complication outcomes after arteriovenous malformation radiosurgery. *Int J Radiat Oncol Biol Phys* 1999;44(1):67-74.
 170. Flickinger JC, Kondziolka D, Maitz AH, Lunsford LD. An analysis of the dose-response for arteriovenous malformation radiosurgery and other factors affecting obliteration. *Radiother Oncol* 2002;63(3):347-54.
 171. Friedman WA, Bova FJ, Bollampally S, Bradshaw P. Analysis of factors predictive of success or complications in arteriovenous malformation radiosurgery. *Neurosurgery* 2003;52(2):296-307; discussion 8.
 172. Flickinger JC, Kondziolka D, Pollock BE, Maitz AH, Lunsford LD. Complications from arteriovenous malformation radiosurgery: multivariate analysis and risk modeling. *Int J Radiat Oncol Biol Phys* 1997;38(3):485-90.
 173. Korytko T, Radivoyevitch T, Colussi V, et al. 12 Gy gamma knife radiosurgical volume is a predictor for radiation necrosis in non-AVM intracranial tumors. *Int J Radiat Oncol Biol Phys* 2006;64(2):419-24.
 174. Pannullo SC, Abbott J, Allbright R. Radiosurgical Principles. In: Stieg PE, Batjer HH, Samson D, eds. *Intracranial Arteriovenous Malformations*. New York: Informa; 2007:177-88.
 175. Guo WY, Karlsson B, Ericson K, Lindqvist M. Even the smallest remnant of an AVM constitutes a risk of further bleeding. Case report. *Acta Neurochir (Wien)* 1993;121(3-4):212-5.
 176. Karlsson B, Kihlstrom L, Lindquist C, Steiner L. Gamma knife surgery for previously irradiated arteriovenous malformations. *Neurosurgery* 1998;42(1):1-5; discussion 6.
 177. Liscak R, Vladyka V, Simonova G, et al. Arteriovenous malformations after Leksell gamma knife radiosurgery: rate of obliteration and complications. *Neurosurgery* 2007;60(6):1005-14; discussion 15-6.
 178. Nataf F, Schlienger M, Bayram M, Ghosoub M, George B, Roux FX. Microsurgery or radiosurgery for cerebral arteriovenous malformations? A study of two paired series. *Neurosurgery* 2007;61(1):39-49; discussion 50.
 179. Luessenhop AJ, Spence WT. Artificial embolization of cerebral arteries. Report of use in a case of arteriovenous malformation. *JAMA* 1960;172:1153-5.
 180. Djindjian R, Houdart R, Rey A. [Place of embolization in the investigation and therapy of cerebral and spinal malformations and vascular tumors. (Apropos of 50 cases)]. *Ann Med Interne (Paris)* 1973;124(5):365-75.
 181. Serbinenko FA. Balloon catheterization and occlusion of major cerebral vessels. *J Neurosurg* 1974;41(2):125-45.
 182. Kerber C. Balloon catheter with a calibrated leak. A new system for superselective angiography and occlusive catheter therapy. *Radiology* 1976;120(3):547-50.
 183. Pevsner PH. Micro-balloon catheter for superselective angiography and therapeutic occlusion. *Am J Roentgenol* 1977;128(2):225-30.
 184. Ciapetti G, Stea S, Cenni E, et al. Toxicity of cyanoacrylates in vitro using extract dilution assay on cell cultures. *Biomaterials* 1994;15(2):92-6.
 185. Vinters HV, Galil KA, Lundie MJ, Kaufmann JC. The histotoxicity of cyanoacrylates. A selective review. *Neuroradiology* 1985;27(4):279-91.
 186. Brothers MF, Kaufmann JC, Fox AJ, Deveikis JP. n-Butyl 2-cyanoacrylate-substitute for IBCA in interventional neuroradiology: histopathologic and polymerization time studies. *Am J Neuroradiol* 1989;10(4):777-86.
 187. Mathis JA, Barr JD, Horton JA, et al. The efficacy of particulate embolization combined with stereotactic radiosurgery for treatment of large arteriovenous malformations of the brain. *Am J Neuroradiol* 1995;16(2):299-306.
 188. The n-BCA Trial Investigators. N-butyl cyanoacrylate embolization of cerebral arteriovenous malformations: results of a prospective, randomized, multi-center trial. *Am J Neuroradiol* 2002;23(5):748-55.
 189. FDA. Statistical Review for PMA P030004, Onyx LES Liquid Embolic System, Micro Therapeutics, Inc., 2003. (Accessed October 3, 2007, at <http://www.fda.gov/ohrms/dockets/ac/03/briefing/3975b1-03-statistical.pdf>)
 190. Jahan R, Murayama Y, Gobin YP, Duckwiler GR, Vinters HV, Vinuela F. Embolization of arteriovenous malformations with Onyx: clinicopathological experience in 23 patients. *Neurosurgery* 2001;48(5):984-95; discussion 95-7.
 191. Deruty R, Pellissou-Guyotat I, Mottolese C, Bascoulergue Y, Amat D. The combined management of cerebral arteriovenous malformations. Experience with 100 cases and review of the literature. *Acta Neurochir (Wien)* 1993;123(3-4):101-12.
 192. Fournier D, TerBrugge KG, Willinsky R, Lasjaunias P, Montanera W. Endovascular treatment of intracerebral arteriovenous malformations: experience in 49 cases. *J Neurosurg* 1991;75(2):228-33.
 193. Wikholm G, Lundqvist C, Svendsen P. Embolization of cerebral arteriovenous malformations: Part I - Technique, morphology, and complications. *Neurosurgery* 1996;39(3):448-57; discussion 57-9.
 194. Gobin YP, Laurent A, Merienne L, et al. Treatment of brain arteriovenous malformations by embolization and radiosurgery. *J Neurosurg* 1996;85(1):19-28.
 195. Valavanis A, Yasargil MG. The endovascular treatment of brain arteriovenous malformations. *Adv Tech Stand Neurosurg* 1998;24:131-214.
 196. Frizzel RT, Fisher WS, III. Cure, morbidity, and mortality associated with embolization of brain arteriovenous malformations: a review of 1246 patients in 32 series over a 35-year period. *Neurosurgery* 1995;37(6):1031-9; discussion 9-40.
 197. Sugita M, Takahashi A, Ogawa A, Yoshimoto T. Improvement of cerebral blood flow and clinical symptoms associated with embolization of a large arteriovenous malformation: case report. *Neurosurgery* 1993;33(4):748-51; discussion 52.
 198. Fox AJ, Girvin JP, Vinuela F, Drake CG. Rolandic arteriovenous malformations: improvement in limb function by IBC embolization. *Am J Neuroradiol* 1985;6(4):575-82.
 199. Jafar JJ, Davis AJ, Berenstein A, Choi IS, Kupersmith MJ. The effect of embolization with N-butyl cyanoacrylate prior to surgical resection of cerebral arteriovenous malformations. *J Neurosurg* 1993;78(1):60-9.
 200. Debrun GM, Aletich V, Ausman JI, Charbel F, Dujovny M. Embolization of the nidus of brain arteriovenous malformations with n-butyl cyanoacrylate. *Neurosurgery* 1997;40(1):112-20; discussion 20-1.
 201. DeMeritt JS, Pile-Spellman J, Mast H, et al. Outcome analysis of preoperative embolization with N-butyl cyanoacrylate in cerebral arteriovenous malformations. *Am J Neuroradiol* 1995;16(9):1801-7.

202. Grzyska U, Westphal M, Zanella F, Freckmann N, Herrmann HD, Zeumer H. A joint protocol for the neurosurgical and neuroradiologic treatment of cerebral arteriovenous malformations: indications, technique, and results in 76 cases. *Surg Neurol* 1993;40(6):476-84.
203. Pasqualin A, Scienza R, Cioffi F, et al. Treatment of cerebral arteriovenous malformations with a combination of preoperative embolization and surgery. *Neurosurgery* 1991;29(3):358-68.
204. Pelz DM, Fox AJ, Vinuela F, Drake CC, Ferguson GG. Preoperative embolization of brain AVMs with isobutyl-2 cyanoacrylate. *Am J Neuroradiol* 1988;9(4):757-64.
205. Deruty R, Pelissou-Guyotat I, Amat D, et al. Multidisciplinary treatment of cerebral arteriovenous malformations. *Neurol Res* 1995;17(3):169-77.
206. Hurst RW, Berenstein A, Kupersmith MJ, Madrid M, Flamm ES. Deep central arteriovenous malformations of the brain: the role of endovascular treatment. *J Neurosurg* 1995;82(2):190-5.
207. Lundqvist C, Wikholm G, Svendsen P. Embolization of cerebral arteriovenous malformations: Part II - Aspects of complications and late outcome. *Neurosurgery* 1996;39(3):460-7; discussion 7-9.
208. Taylor CL, Dutton K, Rappard G, et al. Complications of preoperative embolization of cerebral arteriovenous malformations. *J Neurosurg* 2004;100(5):810-2.
209. Vinuela F, Dion JE, Duckwiler G, et al. Combined endovascular embolization and surgery in the management of cerebral arteriovenous malformations: experience with 101 cases. *J Neurosurg* 1991;75(6):856-64.
210. Marks MP, Lane B, Steinberg GK, et al. Endovascular treatment of cerebral arteriovenous malformations following radiosurgery. *Am J Neuroradiol* 1993;14:297-303.
211. Meisel HJ, Mansmann U, Alvarez H, Rodesch G, Brock M, Lasjaunias P. Effect of partial targeted N-butyl-cyanoacrylate embolization in brain AVM. *Acta Neurochir (Wien)* 2002;144(9):879-87; discussion 88.
212. Hartmann A, Pile-Spellman J, Stapf C, et al. Risk of endovascular treatment of brain arteriovenous malformations. *Stroke* 2002;33(7):1816-20.
213. Redekop G, TerBrugge K, Montanera W, Willinsky R. Arterial aneurysms associated with cerebral arteriovenous malformations: classification, incidence, and risk of hemorrhage. *J Neurosurg* 1998;89(4):539-46.
214. Stapf C, Mohr JP, Pile-Spellman J, et al. Concurrent arterial aneurysms in brain arteriovenous malformations with haemorrhagic presentation. *J Neurol Neurosurg Psychiatry* 2002;73(3):294-8.
215. Marks MP, Lane B, Steinberg GK, Snipes GJ. Intracranial aneurysms in cerebral arteriovenous malformations: evaluation and endovascular treatment. *Radiology* 1992;183(2):355-60.
216. Garcia-Monaco R, Rodesch G, Alvarez H, Iizuka Y, Hui F, Lasjaunias P. Pseudoaneurysms within ruptured intracranial arteriovenous malformations: diagnosis and early endovascular management. *Am J Neuroradiol* 1993;14(2):315-21.
217. Murray RA, Russell EJ. Radiographic diagnosis. In: Stieg PE, Batjer HH, Samson D, eds. *Intracranial Arteriovenous Malformations*. New York: Informa; 2007:95-113.
218. Thompson RC, Steinberg GK, Levy RP, Marks MP. The management of patients with arteriovenous malformations and associated intracranial aneurysms. *Neurosurgery* 1998;43(2):202-11; discussion 11-2.
219. Batjer H, Suss RA, Samson D. Intracranial arteriovenous malformations associated with aneurysms. *Neurosurgery* 1986;18(1):29-35.
220. Piotin M, Ross JB, Weill A, Kothimbakam R, Moret J. Intracranial arterial aneurysms associated with arteriovenous malformations: endovascular treatment. *Radiology* 2001;220(2):506-13.
221. Suzuki J, Onuma T. Intracranial aneurysms associated with arteriovenous malformations. *J Neurosurg* 1979;50(6):742-6.
222. Kondziolka D, Nixon BJ, Lasjaunias P, Tucker WS, TerBrugge K, Spiegel SM. Cerebral arteriovenous malformations with associated arterial aneurysms: hemodynamic and therapeutic considerations. *Can J Neurol Sci* 1988;15(2):130-4.
223. Deruty R, Mottolese C, Soustiel JF, Pelissou-Guyotat I. Association of cerebral arteriovenous malformation and cerebral aneurysm. Diagnosis and management. *Acta Neurochir (Wien)* 1990;107(3-4):133-9.
224. Han PP, Ponce FA, Spetzler RF. Intention-to-treat analysis of Spetzler-Martin grades IV and V arteriovenous malformations: natural history and treatment paradigm. *J Neurosurg* 2003;98(1):3-7.
225. Jayaraman MV, Marcellus ML, Do HM, et al. Hemorrhage rate in patients with Spetzler-Martin grades IV and V arteriovenous malformations: is treatment justified? *Stroke* 2007;38(2):325-9.
226. Kjellberg RN, Hanamura T, Davis KR, Lyons SL, Adams RD. Bragg-peak proton-beam therapy for arteriovenous malformations of the brain. *N Engl J Med* 1983;309(5):269-74.
227. Miyawaki L, Dowd C, Wara W, et al. Five year results of LINAC radiosurgery for arteriovenous malformations: outcome for large AVMS. *Int J Radiat Oncol Biol Phys* 1999;44(5):1089-106.
228. Pan DH, Guo WY, Chung WY, Shiau CY, Chang YC, Wang LW. Gamma knife radiosurgery as a single treatment modality for large cerebral arteriovenous malformations. *J Neurosurg* 2000;93 Suppl 3:113-9.
229. Sirin S, Kondziolka D, Niranjan A, Flickinger JC, Maitz AH, Lunsford LD. Prospective staged volume radiosurgery for large arteriovenous malformations: indications and outcomes in otherwise untreatable patients. *Neurosurgery* 2006;58(1):17-27; discussion 17-27.
230. Chang SD, Marcellus ML, Marks MP, Levy RP, Do HM, Steinberg GK. Multimodality treatment of giant intracranial arteriovenous malformations. *Neurosurgery* 2003;53(1):1-11; discussion 3.
231. Heros RC. Spetzler-Martin grades IV and V arteriovenous malformations. *J Neurosurg* 2003;98(1):1-2; discussion.
232. Celli P, Ferrante L, Palma L, Cavedon G. Cerebral arteriovenous malformations in children. Clinical features and outcome of treatment in children and in adults. *Surg Neurol* 1984;22(1):43-9.
233. Millar C, Bissonnette B, Humphreys RP. Cerebral arteriovenous malformations in children. *Can J Anaesth* 1994;41(4):321-31.
234. Garza-Mercado R, Cavazos E, Tamez-Montes D. Cerebral arteriovenous malformations in children and adolescents. *Surg Neurol* 1987;27(2):131-40.
235. Greenfield JP, Souweidane MM. Diagnosis and management of pediatric arteriovenous malformations. In: Stieg PE, Batjer HH, Samson D, eds. *Intracranial Arteriovenous Malformations*. New York: Informa; 2007:359-69.
236. Bristol RE, Albuquerque FC, Spetzler RF, Rekatte HL, McDougall CG, Zabramski JM. Surgical management of arteriovenous malformations in children. *J Neurosurg* 2006;105(2 Suppl):88-93.
237. Meyer PG, Orliaguet GA, Zerub M, et al. Emergency management of deeply comatose children with acute rupture of cerebral arteriovenous malformations. *Can J Anaesth* 2000;47(8):758-66.
238. Hoh BL, Ogilvy CS, Butler WE, Loeffler JS, Putnam CM, Chapman PH. Multimodality treatment of nongalenic arteriovenous malformations in pediatric patients. *Neurosurgery* 2000;47(2):346-57; discussion 57-8.
239. Fong D, Chan ST. Arteriovenous malformation in children. *Childs Nerv Syst* 1988;4(4):199-203.
240. Cohen-Gadol AA, Pollock BE. Radiosurgery for arteriovenous malformations in children. *J Neurosurg* 2006;104(6 Suppl):388-91.
241. Kader A, Goodrich JT, Sonstein WJ, Stein BM, Carmel PW, Michelsen WJ. Recurrent cerebral arteriovenous malformations after negative postoperative angiograms. *J Neurosurg* 1996;85(1):14-8.
242. Ali MJ, Bendok BR, Rosenblatt S, Rose JE, Getch CC, Batjer HH. Recurrence of pediatric cerebral arteriovenous malformations after angiographically documented resection. *Pediatr Neurosurg* 2003;39(1):32-8.
243. Sawin P. Spontaneous subarachnoid hemorrhage in pregnancy and the puerperium. In: Lofcus C, ed. *Neurosurgical Aspects of Pregnancy*. Park Ridge, IL: American Association of Neurological Surgeons; 1996:85-99.

244. Dias MS, Sekhar LN. Intracranial hemorrhage from aneurysms and arteriovenous malformations during pregnancy and the puerperium. *Neurosurgery* 1990;27(6):855-65; discussion 65-6.
245. Amias AG. Cerebral vascular disease in pregnancy. I. Haemorrhage. *J Obstet Gynaecol Br Commonw* 1970;77(2):100-20.
246. Robinson JL, Hall CS, Sedzimir CB. Arteriovenous malformations, aneurysms, and pregnancy. *J Neurosurg* 1974;41(1):63-70.
247. Horton JC, Chambers WA, Lyons SL, Adams RD, Kjellberg RN. Pregnancy and the risk of hemorrhage from cerebral arteriovenous malformations. *Neurosurgery* 1990;27(6):867-71; discussion 71-2.
248. Schwartz J. Pregnancy complicated by subarachnoid hemorrhage. *Am J Obstet Gynecol* 1951;62(3):539-47.
249. Majewski T, Liebert W, Nowak S, Smol S. [Conservative treatment of cerebral arteriovenous malformations. Follow-up study of 31 cases]. *Neurol Neurochir Pol* 1998;32(3):573-9.
250. Sadasivan B, Malik GM, Lee C, Ausman JJ. Vascular malformations and pregnancy. *Surg Neurol* 1990;33(5):305-13.
251. Lasjaunias P, Terbrugge K, Piske R, Lopez Ibor L, Manelfe C. [Dilatation of the vein of Galen. Anatomical forms and endovascular treatment apropos of 14 cases explored and/or treated between 1983 and 1986]. *Neurochirurgie* 1987;33(4):315-33.
252. Yasargil MG. AVM of the brain, clinical considerations, general and specific operative techniques, surgical results, nonoperated cases, cavernous and venous angiomas, neuroanesthesia. In: *Microneurosurgery*. Stuttgart: Georg Thieme; 1988:317-96.
253. Raybaud CA, Strother CM, Hald JK. Aneurysms of the vein of Galen: embryonic considerations and anatomical features relating to the pathogenesis of the malformation. *Neuroradiology* 1989;31(2):109-28.
254. Alvarez H, Garcia Monaco R, Rodesch G, Sachet M, Krings T, Lasjaunias P. Vein of Galen aneurysmal malformations. *Neuroimaging Clin N Am* 2007;17(2):189-206.
255. Lasjaunias PL, Chng SM, Sachet M, Alvarez H, Rodesch G, Garcia-Monaco R. The management of vein of Galen aneurysmal malformations. *Neurosurgery* 2006;59(5 Suppl 3):S184-94; discussion S3-13.
256. Mickle JP, Mericle RA, Burry MV, Sohn Williams L. Vein of Galen malformations. In: Winn HR, ed. *Youmans Neurological Surgery*. Philadelphia: Saunders; 2004:3433-46.
257. Zerah M, Garcia-Monaco R, Rodesch G, et al. Hydrodynamics in vein of Galen malformations. *Childs Nerv Syst* 1992;8(3):111-7; discussion 7.
258. Chevret L, Durand P, Alvarez H, et al. Severe cardiac failure in newborns with VGAM. Prognosis significance of hemodynamic parameters in neonates presenting with severe heart failure owing to vein of Galen arteriovenous malformation. *Intens Care Med* 2002;28(8):1126-30.
259. Lasjaunias P, Rodesch G, Terbrugge K, Taylor W. Arterial and venous angioarchitecture in cerebral AVMs in adults. *Rivista di Neuroradiologica* 1994;7(Suppl 4):35-9.
260. Lasjaunias P. Neonatal evaluation score (Bicêtre). In: *Vascular Diseases in Neonates, Infants and Children: Interventional Neuroradiology Management*. Berlin: Springer; 1997:49.
261. Mickle JP, Quisling RG. The transthoracic embolization of vein of Galen aneurysms. *J Neurosurg* 1986;64(5):731-5.
262. Dowd CF, Halbach VV, Barnwell SL, Higashida RT, Edwards MS, Hieshima GB. Transfemoral venous embolization of vein of Galen malformations. *Am J Neuroradiol* 1990;11(4):643-8.
263. Charafeddine L, Numaguchi Y, Sinkin RA. Disseminated coagulopathy associated with transthoracic embolization of vein of Galen aneurysm in a neonate. *J Perinatol* 1999;19(1):61-3.
264. Lylyk P, Vinuela F, Dion JE, et al. Therapeutic alternatives for vein of Galen vascular malformations. *J Neurosurg* 1993;78(3):438-45.
265. Andeweg J. Intracranial venous pressures, hydrocephalus and effects of cerebrospinal fluid shunts. *Childs Nerv Syst* 1989;5(5):318-23.
266. Quisling RG, Mickle JP. Venous pressure measurements in vein of Galen aneurysms. *Am J Neuroradiol* 1989;10(2):411-7.
267. Abe T, Matsumoto K, Kiyota K, Tanaka H. Vein of Galen aneurysmal malformation in an adult: a case report. *Surg Neurol* 1996;45(1):39-43.
268. Mylonas C, Booth AE. Vein of Galen aneurysm presenting in middle age. *Br J Neurosurg* 1992;6(5):491-4.
269. Hassan T, Timofeev EV, Ezura M, et al. Hemodynamic analysis of an adult vein of Galen aneurysm malformation by use of 3D image-based computational fluid dynamics. *Am J Neuroradiol* 2003;24(6):1075-82.
270. Marques RM, Lobao CA, Sasaki VS, Aguiar LR. Vein of Galen aneurysm in an adult: case report. *Arq Neuropsiquiatr* 2006;64(3B):862-4.

15. Dural Arteriovenous Fistulas

Intracranial dural AV fistulas (dAVF, aka dural AV fistulas, dural arteriovenous fistulous malformation¹) are acquired lesions that usually involve one of the intracranial venous sinuses. They comprise $\leq 10\%$ of all intracranial vascular malformations.² Typically, numerous branches of the ECA, ICA, and/or vertebral artery form direct connections to a venous sinus and/or intracranial veins. Any intracranial venous sinus may be involved. Clinical features, natural history and management options depend upon the location and anatomy of the lesion. Lesions causing arterialization of intradural veins (aka retrograde leptomeningeal cortical venous flow) are classically associated with intracranial hemorrhage. Spinal dural AV fistulas are discussed in Chap. 20, *Spinal Vascular Lesions*.

15.1. Pathophysiology

15.1.1. Anatomy and classification

All intracranial dAVFs consist of one or more meningeal feeding arteries that drain directly into a venous sinus or intracranial vein. Two classification systems are in common usage and both have been validated as predictive of risk of hemorrhage.³ Borden and colleagues¹:

1. Type I. Dural AVFs that drain directly into a dural venous sinus or meningeal vein.
2. Type II. Dural AVFs that drain into a dural venous sinus with retrograde drainage into subarachnoid veins.
3. Type III. Dural AVFs that drain directly into subarachnoid veins.
4. Further classification into subtypes *a* and *b* indicate single or multiple fistulas, respectively.

Cognard and coworkers⁴:

1. Type I. Drainage is into a sinus, with normal antegrade flow.
2. Type II. Dural AVFs with reflux.
 - (a) IIa Reflux into the sinus.
 - (b) IIb Reflux into cortical veins.
 - (c) IIa + b Reflux into both.
3. Type III. Direct cortical venous drainage without venous ectasia.
4. Type IV. Direct cortical venous drainage with venous ectasia larger than 5 mm in diameter and three times larger than the diameter of the draining vein.
5. Type V. Drainage occurs into spinal perimedullary veins.

15.1.2. Etiology

Several lines of evidence have led to a three-stage hypothesis for the formation of dAVFs (Fig. 15.1).⁵⁻⁷

1. Stage 1. Venous sinus thrombosis is the initial event,⁸ possibly combined with other anatomic features that limit venous outflow, such as venous sinus stenosis.
2. Stage 2. Nascent microscopic fistulas within the wall of the venous sinus, connecting vaso vasorum to tiny venous tributaries, enlarge. This process may be the result of a build-up of back pressure in the venous system, inflammatory changes in response to the thrombosis, and/or via an increase in angiogenic factor expression.^{7,9-13}
3. Stage 3. Recanalization of the thrombosed venous sinus occurs. If only partial recanalization appears, or if there is some other venous sinus outflow obstruction (like venous sinus stenosis), arterial flow is diverted into the subarachnoid venous system (i.e., retrograde leptomeningeal flow occurs).

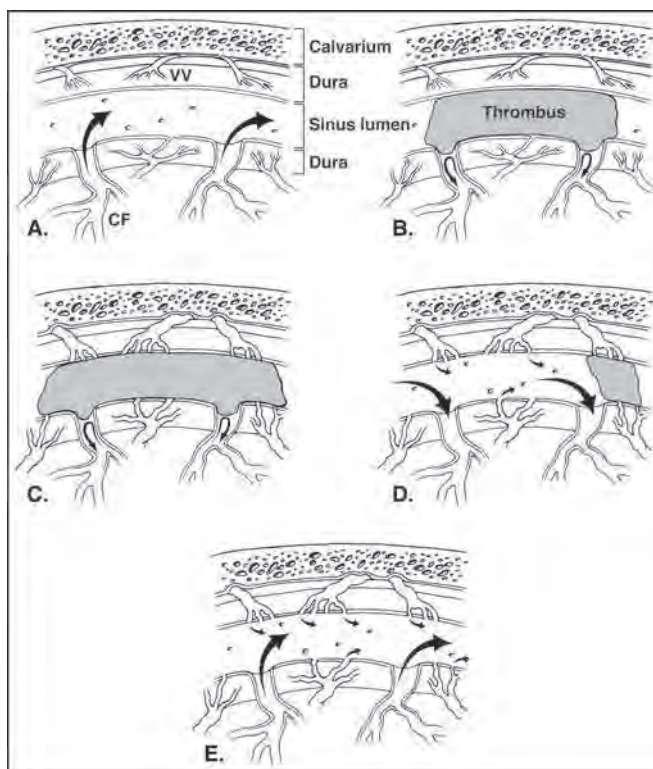


Fig. 15.1 Stages in the formation of dural arteriovenous fistulas. (a) Normal anatomy of the dural venous sinus. (b) Stage 1. Thrombosis of the venous sinus occurs, leading to diversion of flow in the entering venous tributaries. (c) Stage 2. Thrombosis of the venous sinus provides an impetus to the enlargement and expansion of nascent connections between vaso vasorum and fistulas between vaso vasorum and nearby arteries within the wall of the venous sinus. Over time, as dural arteries enlarge, grooves in the adjacent bone develop. (d) Stage 3-Partial recanalization. Incomplete recanalization of the thrombosed sinus occurs, (or some other venous outflow-limiting factor exists, such as venous sinus stenosis), leading to diversion of arterial flow into subarachnoid veins. (e) Stage 3-Complete recanalization. Normal venous outflow resumes, and AV fistulas may or may not continue to be patent.

15.1.2.1. Evidence in favor of the three stage hypothesis

1. Microscopic fistulas between meningeal arteries and veins are normal and present throughout the dura.¹⁴⁻¹⁷
 - Also, the dura has an elaborate network of arterial anastomoses¹⁵ which explains why fistulas apparently supplied only by ECA branches can promptly recruit blood supply from ICA branches after embolization.¹⁸
2. Development of abnormal communications between dural arteries and veins appears to be an essential factor in the development of dAVFs.¹⁹
3. Dural AV fistulas are usually located either in the wall of dural venous sinuses²⁰ or within a centimeter or so of a dural venous sinus.¹⁷

4. Venous sinus thrombosis is strongly associated with intracranial dAVFs.^{5,8,11,21}
 - Experimental models have also reproduced venous thrombosis- or venous hypertension-associated dAVFs.^{10,22,23}
5. Venous sinus thrombosis can redirect arterial blood into subarachnoid veins.²⁴
6. Progressive thrombosis can transform Type I malformations into Type II malformations.

15.2. Clinical features

1. Most patients with dAVFs are adults; dAVFs in children are rare but have been reported.²⁵
2. Benign dAVFs are most common among women,^{26,27} whereas dAVFs with cortical venous drainage appear to be most common among men.^{28,29}
3. Multiple intracranial dAVFs are present in 6.7% of patients.³⁰
4. *Presentation.* Symptoms and physical findings are highly variable, and depend on the location and anatomy of the lesion (see below for discussion of dAVFs by location).
 - (a) Overall, pulsatile tinnitus is the most common symptom and is present in about 60% of patients.³¹ See section on Pulsatile Tinnitus below.
 - (b) A bruit is present in about 50% of patients.³¹
 - (c) Hydrocephalus may be present and is attributable to venous hypertension in the superior sagittal sinus, interfering with CSF absorption.²⁴
5. Significant symptoms from dAVFs are generally divided into those attributable to hemorrhage or “non-hemorrhagic neurological defects,”^{32,33} which are usually due to intracranial venous hypertension.
6. *Hemorrhage.*
 - (a) In a prospective study of intracranial hemorrhage due to an intracranial vascular malformation (brain AVM, cavernoma, or dAVF), a dAVF was the underlying cause in 6.4% of cases.³⁴
 - (b) Risk factors for hemorrhage^{5,24,35,36}:
 - Leptomeningeal venous drainage
 - Variceal or aneurysmal venous dilatations
 - Galenic drainage
 - Stenosis or occlusion of associated venous sinuses
 - Location in the anterior fossa, middle fossa, or tentorial incisura
 - (c) Case fatality rate with hemorrhage: 20%^{31,32}
7. *Intracranial venous hypertension* The intracranial venous system is valveless and so elevated pressure within arterialized venous sinuses and/or intracranial veins may be transmitted throughout the intracranial venous system. Diffuse white matter changes on MRI due to venous congestion may be seen.^{37,38} Neurological symptoms attributable to elevated intracranial venous pressure include:
 - (a) Progressive dementia (aka venous hypertensive encephalopathy, venous congestive encephalopathy, or progressive cognitive impairment)^{24,39–42}
 - (b) Pseudotumor cerebri⁴³
 - (c) Parkinsonism⁴⁴

15.2.1.1. Pulsatile tinnitus: What does it mean?

Some 4% of all patients with tinnitus have pulsatile tinnitus (aka pulse-synchronous tinnitus).⁴⁵ Pulsatile tinnitus is usually caused by vibrations from turbulent blood flow. Dural AV fistulas are the single most common cause of pulsatile tinnitus, followed by C–C fistulas and atherosclerotic carotid stenosis.⁴⁶ In a series of 24 patients with Borden Type I dAVFs of the transverse-sigmoid region, pulsatile tinnitus was the presenting symptom in all patients.²⁷ A vascular disorder is present in 42% of patients with pulsatile tinnitus; a non-vascular disorder is the cause of pulsatile tinnitus in 14% of patients.⁴⁶

1. Vascular causes
 - (a) dAVF
 - (b) ICA stenosis or occlusion
 - (c) Carotid dissection
 - (d) Fibromuscular dysplasia
 - (e) Persistent stapedia artery

- (f) Aberrant or lateralized ICA
 - (g) Intracranial venous hypertension
 - (h) High-riding internal jugular vein⁴⁷
 - (i) Venous sinus stenosis⁴⁸
 - (j) Turbulent flow through a dominant internal jugular vein
 - (k) Vertebral artery-venous fistula
2. Non-vascular causes of pulsatile tinnitus
 - (a) Middle ear disorders (otitis media, glomus tympanicum, cholesteatoma)
 - (b) Labyrinth disorders (otospongiosis)
 - (c) High cardiac output disorders (anemia, thyrotoxicosis, valvular heart disease)
 - (d) Skull base tumors
 3. Work-up for pulsatile tinnitus
 - (a) Pulsatile tinnitus is either *objective* (a bruit on the skull or mastoid process can be heard by the examiner) or *subjective* (only the patient can perceive it). Objective tinnitus should raise a high suspicion of an underlying vascular abnormality and a catheter angiogram is frequently indicated.
 - (b) Imaging
 - CT is insensitive in the assessment of pulsatile tinnitus
 - MRI is more sensitive than CT
 - In patients with subjective pulsatile tinnitus, MRI/MRA defined anatomical abnormalities that may contribute to pulsatile tinnitus in 63% of patients.⁴⁹
 - (c) In the absence of objective pulsatile tinnitus, MRI/MRA is an appropriate initial diagnostic step.⁴⁹

15.2.1.2. Imaging

ANGIOGRAPHY

Catheter angiography is the best technique for the diagnosis of an intracranial dAVF.^{50,51}

1. Technique
 - (a) A complete 6-vessel cerebral angiogram is usually necessary, as some lesions may have feeding arteries from both sides, as well as from the ICA or vertebral arteries as well as the ECAs.
 - (b) Each angiogram should be carried well into the venous phase, to assess intracranial vein and venous sinus anatomy.
2. Pertinent findings
 - (a) The single most important goal of angiography in patients with a dAVF is to investigate for retrograde leptomeningeal venous drainage.
 - Good visualization of the venous phase is essential.
 - Tortuous, engorged veins seen during the venous phase is termed *pseudophlebatic pattern* and is a sign of venous congestion.⁵² A pseudophlebatic pattern was seen in 81% with retrograde leptomeningeal venous drainage and in only 8% of dAVF patients with drainage into a venous sinus only.⁵²
 - Subtle findings seen during the venous phase include drainage via pial or medullary collateral veins, focal regions of delayed circulation and venous rerouting to the orbit or to transosseous veins.⁵²
 - (b) The arterial feeders must be characterized.
 - Occasionally, a dAVF may have only a single (or two or three) endovascularly accessible arterial pedicles and thus be a prospect for curative arterial embolization.
 - (c) Venous outflow obstruction should be checked for (e.g., venous sinus stenosis or thrombosis).

MRI

MRI may not show some dAVFs and should not be used instead of catheter angiography to exclude the presence of a dAVF. *Remember: a normal MRI does not exclude the presence of a dAVF.*

1. MRI findings in patients with dAVFs:
 - (a) Preliminary experience with MRA assessment of dAVFs has been reported.⁵³

- (b) A surplus of pial vessels suggests the presence of a dAVF with cortical venous drainage.³⁷
 - (c) Enhanced MRI is superior to non-enhanced MRI in assessing retrograde venous drainage in intracranial dAVFs.
2. In some cases however, MRI may provide complementary information in patients with a dAVF that is not available with catheter angiography:
 - (a) MRI evidence of white matter edema (diffuse T2 hyperintensity in the white matter) is evidence of venous congestion.³⁷
 - (b) Evaluation for hydrocephalus.
 - (c) Quantitative assessment of cerebral blood volume by dynamic susceptibility contrast MRI can provide quantitative information about retrograde cortical venous drainage.⁵⁴

CTA

Like MRI, CTA may not show some dAVFs,⁵⁵ and should not be used instead of catheter angiography.

1. CTA can identify some dAVFs, particularly those with enlarged intracranial veins.⁵⁶

15.2.2. Natural history

The overall annual risk of hemorrhage in patients with intracranial dAVFs is 1.8%, with a case fatality rate of 20% with hemorrhage.³¹ However, the natural history of dAVFs depends strongly on the pattern of venous drainage. Most Borden Type I lesions (aka Cognard Type I or IIa) are considered to be “benign” whereas higher grade lesions are “aggressive.”

15.2.2.1. Borden type I dAVFs: Most are benign

1. In a series of 112 patients with Borden Type I lesions followed for median time of 27.9 months, observation and/or palliative therapy resulted in a benign and tolerable level of disease in 98.2% of cases.²⁶
 - (a) Palliation consisted of embolization to reduce symptoms without obliteration of the lesion.
 - (b) In 2% of cases conversion to a higher grade lesion occurred, with progressive thrombosis of venous outlets.
2. A previous study reported on a group of 54 patients with Borden Type I lesions.⁵⁷ During a mean follow-up period of 33 months, 53 (98%) patients had good outcomes (i.e., symptoms were resolved, improved, or unchanged). One death was reported; this patient had a complex torcular dAVF and his death was attributed to venous hypertension and elevated intracranial pressure.
3. Cognard and colleagues reported on a group of seven patients with Type I lesions, followed for a mean time of 7 years, all of whom developed a worsening in both the venous drainage pattern and clinical symptoms.⁵⁸ The authors did not indicate the number of patients with Type I lesions in the entire group, so an incidence of worsening cannot be calculated from this paper.

15.2.2.2. Borden type II and III dAVFs: Aggressive

Patients with high grade dAVFs are at significant risk of hemorrhage or neurological problems because of intracranial venous hypertension.

1. Risk of hemorrhage or non-hemorrhagic neurological deficit.
 - (a) van Dijk and colleagues reported on 20 patients with Borden Type II or III lesions who were either partially treated or not treated at all and followed for a mean period of 4.3 years.³³
 - The annual rate of hemorrhage was 8.1% and the annual rate of a non-hemorrhagic neurological deficit was 6.9%, yielding an annual event rate of 15%.
 - (b) Davies and coworkers reported on 14 patients with Borden Type II or III lesions who were followed for a mean period of 25 months without or prior treatment.³²

- The annual rate of hemorrhage was 19.2% and the annual rate of a non-hemorrhagic neurological deficit was 10.9%. The overall annual mortality rate was 19.3%.
2. Risk of rehemorrhage.
 - (a) In a series of patients with dAVFs with cortical venous drainage presenting with hemorrhage, rebleeding occurred in 35% within 2 weeks of the initial hemorrhage.⁵⁹

15.3. Management

Management options for patients with a dAVF are

1. Conservative management
2. Endovascular techniques
3. Surgery
4. Radiosurgery
5. A combination of endovascular treatment, radiosurgery, and/or surgery

15.3.1. Conservative management

Conservative management (i.e., no endovascular or surgical procedure, with or without surveillance imaging) is reasonable in certain situations. Asymptomatic or minimally symptomatic Borden Type I lesions without evidence of cortical venous drainage may be managed expectantly. It is well established that spontaneous regression of dAVFs occurs in some cases. This is particularly true of cavernous sinus dAVFs,^{60,61} in which spontaneous regression has been reported in up to 73% of cases.⁶²⁻⁶⁴ Intermittent manual compression is also effective for some patients with cavernous sinus or transverse-sigmoid lesions.^{65,66}

15.3.2. Endovascular treatment

Generally the most effective treatment of dAVFs is occlusion of the draining vein.⁷ In most cases, obliteration of the lesion can only be accomplished by treatment of the venous side of the lesion. Transvenous techniques appear to carry the highest success rates among endovascular techniques. Even successful arterial embolization usually occurs only when the microcatheter is positioned well within or adjacent to the nidus, so that embolic material can be pushed through the nidus into the venous side. If only feeding arteries are occluded and not the draining vein, collateral vessels usually develop and the fistula will recur. Conversely, it is equally important to ensure that normal venous drainage is preserved after embolization to avoid exacerbated venous hypertension and risk of hemorrhage.

Embolization of the arterial feeders alone is usually only palliative. Embolization of feeders proximal to the nidus will nearly invariably be followed by recruitment of a new arterial supply and possibly the redirection of the venous outflow with an increased risk of hemorrhage.

15.3.3. Surgery

Surgery for intracranial dAVFs has evolved considerably over the last three decades, from simple ligation of feeding vessels (which produced success rates of only 0–8%)⁶⁷ to blood-soaked fistula resection and packing of the venous sinus,⁶⁸ or to more elegant interruption of the draining vein, when the anatomy is favorable.⁶⁹ Although endovascular techniques are presently first-line treatments for many dAVFs, surgery remains standard for anterior fossa dAVFs.⁶⁷ A variety of hybrid surgical/endovascular procedures have evolved as well, including surgical exposure of the superior ophthalmic vein for embolization of the cavernous sinus^{70,71} and craniectomy with direct puncture of a venous sinus.⁷²

15.3.4. Radiosurgery

Preliminary reports of radiosurgery for intracranial dAVFs are encouraging.^{73,74} In many cases embolization is combined with radiosurgery.⁷⁵ Overall rates of lesion obliteration are 58–77%.^{74,76,77}

15.4. Dural AVFs by location

In North American and European series, the transverse-sigmoid sinus region is the most common location for dAVFs^{31,32}; in a Korean report, the cavernous sinus was the most common location, accounting for 64% of cases (Fig. 15.2).⁷⁸

Most common locations for dAVFs are⁷⁹

1. Transverse-sigmoid sinus 35%
2. Cavernous sinus 35%
3. Tentorium/Superior petrosal sinus 5%
4. Superior sagittal sinus 5%
5. Anterior fossa 5%

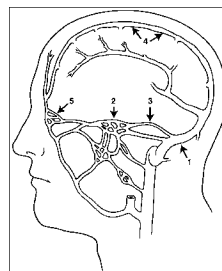


Fig. 15.2 Most common locations of dural arteriovenous fistulas.

15.4.1. Transverse-sigmoid sinus dAVFs

The transverse-sigmoid sinus (aka lateral sinus) is the most common location for intracranial dAVFs, comprising 38% of all intracranial dAVFs.⁷⁹

15.4.1.1. Clinical features

1. Women are affected more than men and the lesion is present most often on the left.^{5,80}
2. Borden Type I dAVFs of the transverse-sigmoid sinus (analysis of 24 cases)²⁷:
 - (a) Seventy-nine percent women; median age at onset of symptoms: 54 years.
 - (b) Unilateral pulsatile tinnitus was the presenting symptom (and a bruit could be heard) in all patients.
 - (c) MRI was normal in all patients.
3. May be associated with meningiomas.^{81,82}
4. Anatomy
 - (a) Feeders – may be bilateral
 - ECA branches are most common: occipital, posterior auricular, ascending pharyngeal, middle meningeal, accessory meningeal and superficial temporal arteries.
 - ICA branches: meningohypophyseal trunk, inferolateral trunk.
 - Vertebral artery branches: posterior meningeal artery, cerebellar falcine and muscular branches.
 - (b) Venous drainage
 - The transverse or sigmoid sinus is stenotic or occluded in a significant percentage of cases.⁵
 - Retrograde venous flow, when present, may be into occipital and parietal cortical veins.
5. Presentation
 - (a) Hemorrhage or intracranial venous hypertension
 - Patients with transverse-sigmoid dAVFs present with hemorrhage or other serious symptoms in only 11% of cases.⁵⁰
 - (b) Symptoms without hemorrhage may include⁸⁰

- Pulsatile tinnitus (most common symptom)
- Headache
- Visual disturbance
- Mastoid pain/otalgia
- Dizziness
- Hydrocephalus
- Trigeminal neuralgia⁸³

15.4.1.2. Management

Relative to dAVFs in other locations, these lesions are often benign and frequently require treatment only to alleviate symptoms such as pulsatile tinnitus. Lesions with aggressive characteristics, such as retrograde venous flow and/or venous hypertension, should be treated.

Selection of the treatment strategy involves weighing several different factors. Paramount among these is the venous anatomy; other considerations include the clinical gravity of the situation, the arterial anatomy and the patient's ability to undergo endovascular and/or surgical procedures. A systematic review in 1997 found that combined therapy (endovascular plus surgical treatment) was significantly more effective than either therapy alone ($P < 0.01$).⁶⁷

1. Manual compression

- (a) Technique: The patient is instructed to compress the pulsatile occipital artery with either hand for 30 min TID.
- (b) Results: In 25% of cases complete thrombosis may occur within 4–6 weeks.⁶⁶ Occipital artery compression may also provide transient relief from dAVF-associated headaches.⁶⁶

2. Surgery

- (a) Early surgical technique consisted of complete excision coupled with packing of the sigmoid sinus, a procedure associated with significant blood loss.⁶⁸ More recently, good results have been obtained with surgical disconnection of the draining vein or veins.^{29,84}

3. Embolization

(a) Venous embolization

- Venous embolization, or venous embolization combined with arterial embolization, results in significantly higher cure rates compared to arterial embolization alone. Successful venous embolization depends upon identifying patients with favorable anatomy for this approach; occlusion of a sinus that freely communicates with normal venous structures can cause a venous infarction and hemorrhage.
- Suitable venous anatomy:
 - The affected sinus is compromised and no longer contributes to the drainage of normal tissue.^{1,85,86}
 - *Parallel venous channel*. Caragine and colleagues reported on ten patients with dAVF consisting of arterial feeders converging on a “parallel venous channel,” that was separate from, but in communication with the transverse or sigmoid sinus.⁸⁷ Embolization of the venous channel and cure of the fistula, with preservation of the venous sinuses, was achieved in all patients.
- Venous approaches
 - Femoral venous access is the most commonly reported route; alternatives include direct puncture of the internal jugular vein and craniectomy with direct puncture of a venous sinus.⁷²

(b) Arterial embolization

- Arterial embolization is rarely curative and should be reserved for palliation or as an adjunct to venous embolization⁸⁸ or surgery.

(c) Embolization results

- Most published series of transverse-sigmoid dAVF embolizations employed a combination venous/arterial strategy in some patients and venous embolization only in others.
- Angiographic cure rates: 55–87.5%.^{85,86,89,90}
- Symptom improvement or resolution: 90–96%.^{85,86,89}
- Transient complications: 10–15%.^{85,89}
- Permanent complications: 0–5%.^{85,86,89}

4. Venous sinus angioplasty and stenting
 - (a) Treatment of a transverse sinus dAVF by sinus recanalization, angioplasty and stent placement has been reported.⁹¹
5. Radiosurgery
 - (b) Two reports dedicated specifically to radiosurgery transverse-sigmoid dAVFs of a total of 45 patients^{75,77}:
 - Angiographic cure rates: 55–87.5%
 - Symptom improvement or resolution: 74–96%
 - No neurologic complications were reported

15.4.2. Cavernous sinus dAVFs

Carotid-cavernous fistulas (CC fistulas) may be direct or indirect. *Direct* CC fistulas (aka high flow CCFs) consist of a defect in the wall of the ICA, causing a shunt between the ICA and the cavernous sinus (e.g., traumatic CCF or ruptured cavernous segment aneurysm). *Indirect* CC fistulas (aka low flow CC fistulas) are equivalent to dAVFs of the cavernous sinus; they comprise about 35% of all dAVFs.⁷⁹ Barrow and colleagues established the following classification scheme⁶³:

1. Type A. Direct shunt between ICA and cavernous sinus (e.g., traumatic CCF or ruptured cavernous segment aneurysm). Direct CC fistulas are discussed separately in the Appendix.
2. Type B. Indirect fistula between branches of the ICA and the cavernous sinus.
3. Type C. Indirect fistula between branches of the ECA and the cavernous sinus.
4. Type D. Indirect fistula between branches of both the ICA and ECA and the cavernous sinus.
 - (a) Type D1: Unilateral⁹²
 - (b) Type D2: Bilateral

15.4.2.1. Indirect CC fistulas: Clinical features

1. Most patients are women in the sixth or seventh decade of life.
 - (a) Men comprise 27% of cases.⁹²
2. Barrow Type D is most common.⁹³
3. Slight propensity for the left.⁹⁴
4. Anatomy
 - (a) Feeders
 - May be bilateral.
 - ECA: Branches of the internal maxillary, middle meningeal, accessory meningeal, ascending pharyngeal.
 - ICA: Cavernous segment branches.
 - (b) Venous drainage
 - Highly variable.
 - Impaired venous drainage is typical and enlargement of the superior ophthalmic vein is a frequent finding.
 - Cortical venous drainage is present in 31–34% of cases⁹⁴
 - (c) *Inferior petrosal sinus dAVF*
 - A variant of cavernous dAVFs; accounts for some 3% of intracranial dAVFs.⁹⁵
 - Presentation is similar to cavernous dAVFs.⁹⁶
5. Presentation
 - (a) Termed “Red-eyed shunt syndrome” by some authors.⁶²
 - (b) Most common findings⁹⁴:
 - Chemosis (94%)
 - Exophthalmos (87%)
 - Cranial nerve palsy (54%)
 - Increased intraocular pressure (60%)
 - Diplopia (51%)
 - Impaired vision (28%)
 - Pulsatile tinnitus⁹⁷
 - (c) A bruit is present in >50% of patients⁹⁸
 - (d) So-called “white-eye” CC fistulas occur when posterior venous drainage predominates and a painful ocular motor nerves palsy develops without congestive orbital features.⁹⁹

6. Imaging

- (a) CT: Typical findings include proptosis and superior ophthalmic vein enlargement.
- (b) MRA: May show an enlarged superior ophthalmic vein.
- (c) A catheter angiogram remains the gold standard for a complete evaluation of an indirect CC fistula.¹⁰⁰ Angiography is most important for assessing the presence of retrograde cortical venous flow, as well as delineating feeders and the precise pattern of venous drainage; all of these critical anatomic features of any given CC fistula are poorly seen with noninvasive imaging.

15.4.3. Indirect CC fistulas: Management

Spontaneous resolution of an indirect fistula is not uncommon, with reported rates of spontaneous remission ranging from 5.6%⁶¹ to 73%.⁶²⁻⁶⁴ Some authors, like the senior author of this handbook, prefer to attempt conservative management of most patients with indirect CC fistulas, whereas the junior author offers intervention to most patients with bothersome symptoms. Barrow and colleagues proposed the following indications for treatment⁶³: (1) Visual deterioration; (2) Obtrusive diplopia; (3) Intolerable bruit or headache; and (4) "Malignant" proptosis with untreatable corneal exposure. The presence of retrograde cortical venous drainage is also a good indication for treatment.

Selection of technique: Venous occlusion is the most reliable method to treat indirect CC fistulas. A systematic review in 1997 found overall success rates of 78% for transvenous approaches and 62% for transarterial approaches.⁶⁷

1. Manual compression

- (a) Technique⁶⁸: The patient is instructed to use the opposite hand to locate the pulse of the carotid artery in the mid-neck region just lateral to the trachea. Gradually increasing pressure is applied until the palpable pulse is stopped. The opposite hand is used in case hemispheric ischemia develops. Compression is maintained for 10–15 s at a time, 2–3 times an hour.
 - Contraindications: Cervical carotid artery disease (atherosclerosis, dissection), sick sinus syndrome, poor patient compliance.
- (b) Results: In 30% of cases closure occurred within a mean of 41 days (range, several minutes to 6 months).⁶⁵

2. Embolization

- (a) Venous: Most effective technique. Several different routes to the cavernous sinus may be used; the most commonly used are the inferior petrosal sinus and the superior ophthalmic vein.
 - Femoral vein/Inferior petrosal sinus^{94,101-103}
 - Successful embolization of the cavernous sinus via the femoral vein and inferior petrosal sinus reported in 64% of cases.¹⁰⁴
 - A thrombosed inferior petrosal sinus can be traversed in some cases.^{101,105,106}
 - A 0.035" guidewire may be used to gently probe through and open a recently occluded inferior petrosal sinus.⁹⁴
 - Superior ophthalmic vein^{70,71}
 - Surgical exposure is obtained through the upper eyelid.
 - (a) Percutaneous puncture of the superior ophthalmic vein has been reported.¹⁰⁷
 - Success rate (92–100%^{70,71}) is higher compared to transfemoral venous routes.
 - Alternative techniques for access:
 - Direct puncture of the internal jugular vein.¹⁰⁸
 - Transfemoral facial vein approach.¹⁰⁸
 - Superior petrosal sinus.¹⁰⁸
 - Sylvian vein.¹¹⁰
 - Pterygoid plexus.¹¹¹
 - Frontal vein.¹¹²
 - Coil placement should begin in the posterior part of the superior ophthalmic vein and extend into the cavernous sinus, when approaching from a posterior route.⁹⁴
- (b) Arterial: Embolization of arterial feeders is rarely curative and should be used only for palliation in select cases.

- (c) Embolic material. Detachable coils are the most commonly used material; recent reports have described good results with NBCA either alone or in combination with coils.^{113,114} Onyx embolization has also been reported.¹¹⁵
 - (d) Endovascular results. Overall results in two large recent series are very favorable:
 - Complete cure: 90–94.5% of cases.^{94,102}
 - Fistula closure will usually result in normalization of intraocular pressure.¹¹⁶ Improvement in vision may take longer and is less certain, as several different mechanisms may contribute to vision loss (e.g., optic neuropathy, keritis and corneal ulceration, vitreous hemorrhage, retinal ischemia, or retinal detachment).
 - Procedure-related permanent morbidity: 0–2.3%^{94,102}
3. Radiosurgery
- (a) Several reports have been published on the use of radiosurgery for the treatment of cavernous CC fistulas.^{73,76,117,118} Although the results are generally favorable, with obliteration rates >80%, the wide variety of techniques used (dosing, use of embolization, lesion anatomy) make it difficult to make firm conclusions about the usefulness of radiosurgery in this setting.

15.4.4. Tentorial dAVFs

Tentorial dAVFs (aka superior petrosal dAVFs)^{95,119} comprise about 5% of all intracranial dAVFs.⁷⁹ Although in most cases, the lesion is located on the petrous ridge and involves the superior petrosal sinus, most publications refer to them as “tentorial” dAVFs.^{69,120–122} These lesions are thought to be prone to hemorrhage and are difficult to treat by surgery and by embolization. All, or nearly all, tentorial dAVFs are Borden Type II or III lesions.^{32,120} Picard and colleagues classified tentorial dAVFs¹²³:

1. Tentorial marginal type, located along the free edge of the tentorium.
2. Tentorial lateral type, located adjacent to the lateral venous sinuses.
3. Tentorial medial type, located adjacent to the straight sinus and torcula.

15.4.4.1. Clinical features

1. Anatomy
 - (a) Feeders. Majority are bilateral.¹²⁴
 - Typically, multiple fine feeders arise from (in order of frequency)¹²²:
 - Middle meningeal artery
 - Meningohypophyseal trunk
 - Posterior cerebral artery
 - Occipital artery
 - Posterior meningeal artery
 - Superior cerebellar artery
 - (b) Venous drainage
 - Drainage is retrograde in all cases¹²²
 - Cerebral and/or cerebellar veins
 - Basal vein of Rosenthal
 - Pontine and paramesencephalic veins
 - Cervical paramedullary spinal veins
2. Presentation
 - (a) Some 80–90% of patients present with hemorrhage or a history of hemorrhage.¹²⁵
 - (b) Symptoms from unruptured lesions may include pulsatile tinnitus,¹²⁶ hemifacial spasm,¹²⁷ myelopathy visual problems,¹²⁸ trigeminal neuralgia,¹²⁹ or hemisensory disturbance.¹³⁰
3. Imaging¹²²
 - (a) CT: Hemorrhage centered in the ambient cistern or posterior fossa
 - (b) MRI: High signal on T2-weighted images indicating edema in the thalamus, midbrain, and cerebellum

15.4.4.2. Management

Tentorial dAVFs are aggressive lesions and should be obliterated when feasible. Incomplete treatment should be avoided, as recruitment of new feeders and redirection of venous outflow may occur.¹³¹ No single treatment strategy is ideal; selection of surgery and/or embolization depends on the clinical situation (vascular anatomy, patient age and health status, etc.). Because of the aggressive nature of these lesions, late (1–2 years post-treatment) follow-up catheter angiography should be done, even in cases in which an angiographic cure is obtained.

1. Surgery

- (a) Surgery is most effective for patients who are good candidates for a craniotomy and who have a lesion with a single, surgically accessible draining vein.
- (b) Technique: Surgical technique for tentorial dAVFs has evolved considerably in recent years.^{69,120,121} In most cases, resection of the nidus is not necessary; obliteration of the lesion can be accomplished by coagulation and division of the arterialized draining vein or veins, when the anatomy is suitable.^{69,121} Interruption of the draining vein may be effective when no other pathway for venous drainage exists.⁶⁹ Lewis and coworkers, however, emphasized the importance of surgical interruption of the arterial supply, rather than the draining veins.¹²⁴ The route of cranial access (e.g., suboccipital versus subtemporal craniotomy) depends on where the arterialized veins are located. Pre-operative arterial embolization may facilitate surgery.^{120,122}
- (c) Surgical results: Several small recent series have reported angiographic cures with no mortality.^{69,120,122}

2. Embolization

(a) Venous embolization

- In most cases, tortuous retrograde leptomeningeal drainage is not connected to a venous sinus, making transvenous embolization difficult or impossible. Some patients, however, have anatomy that is favorable for a transfemoral venous approach.
- Venous embolization should be done only when a venous drainage pouch that is separate from veins draining normal brain tissue can be identified and accessed with a microcatheter.¹²⁰ When embolization is limited to the venous outlet immediately adjacent to the nidus, with preservation of functional drainage, venous embolization with platinum coils can provide adequate treatment.¹³²

(b) Arterial embolization

- Arterial embolization can lead to an angiographic cure only when the microcatheter tip is placed close enough to the nidus to permit placement of embolic material across the nidus to the venous side.^{119,120} NBCA has been the agent of choice,¹²⁰ because of its resistance to recanalization. Onyx may be a good alternative.¹³³
- van Rooj and coworkers recommend temporary balloon-occlusion of the ICA when a microcatheter is placed in the tentorial artery, to stabilize the microcatheter, obtain flow-arrest during the injection of embolic agent and to prevent reflux into the ICA.¹²⁶
- Brief, reversible asystole due to a trigeminocardiac reflex during arterial embolization has been reported.¹³³

3. Radiosurgery

- (a) Some authors argue strenuously against the use of radiosurgery for treatment of tentorial dAVFs, given the latency period of radiosurgery, <100% obliteration rate, and risk of injury to adjacent structures such as the brainstem and cranial nerves.^{120,124} On the other hand, successful obliteration has been reported,^{73–75,134,135} and in two dAVF radiosurgery series, tentorial dAVFs were the most common kind of lesion treated.^{74,76}

15.4.5. Superior sagittal sinus dAVFs

Comprise 5% of intracranial dAVFs.³⁵

15.4.5.1. Clinical features

1. Men and women are equally affected.¹³⁶
2. Anatomy. These lesions are typically located in the midportion of the sagittal sinus and feeding arteries are bilateral in the majority of cases.
 - (a) Feeders (listed in descending order of frequency)¹³⁶:
 - Middle meningeal artery
 - Occipital artery
 - Superficial temporal artery
 - Vertebral artery
 - Posterior auricular artery
 - Anterior falx artery
 - (b) Venous drainage
 - Two patterns: directly into the sagittal sinus (majority of cases) or into cortical veins.¹³⁷
 - Sagittal sinus may or may not be occluded.
3. Presentation
 - (a) Over a third of patients present with hemorrhage.¹³⁶
 - Subarachnoid hemorrhage, intraparenchymal hemorrhage, or subdural hemorrhage may be present.
 - (b) Symptoms without hemorrhage may include those attributable to venous hypertension (e.g., mental status changes, headache).
 - (c) May be misdiagnosed as acute sagittal sinus thrombosis.

15.4.5.2. Management

Lesion obliteration is indicated in patients with hemorrhage or symptoms attributable to the fistula. Sagittal sinus dAVFs associated with a downstream venous sinus occlusion are believed to be at highest risk of hemorrhage or venous hypertension.

1. Surgery
 - (a) Surgery is usually fairly straightforward and effective in achieving complete obliteration of the lesion. Surgical techniques include skeletonization of the superior sagittal sinus (i.e., disconnection of arterialized veins) and surgical exposure followed by direct puncture for embolization of the sinus.¹³⁸
 - (b) Surgical occlusion of the superior sagittal sinus should be avoided or only done if the affected portion is within the anterior third of the superior sagittal sinus, to minimize risk of venous infarction.¹³⁹
2. Embolization
 - (a) Venous embolization
 - Successful transcranial venous embolization of sagittal sinus dAVFs has been reported.⁷²
 - (b) Arterial embolization
 - The “angiographically remote” location of these lesions can make them difficult to reach from a transfemoral approach. And the multiplicity (and bilaterality) of feeders in many cases further impair endovascular attempts at a cure.
 - Direct cervical carotid puncture (with the patient adequately sedated or under general anesthesia) may facilitate arterial access to the nidus.
 - Case reports and small series report an angiographic cure in about 50% of cases.¹⁴⁰
 - Arterial embolization has been successfully combined with surgery and radiosurgery.¹⁴¹
3. Radiosurgery
 - (a) Successful radiosurgery of superior sagittal sinus dAVFs has been reported.^{74,76,142}

15.4.6. Anterior fossa dAVFs

Anterior fossa dAVFs (aka ethmoidal dAVFs, cribriform dAVFs) comprise about 5% of all intracranial dAVFs.⁷⁹ These lesions are unique for two reasons:

1. They always have retrograde leptomeningeal venous drainage.
 - (a) Because of this, they are at high risk of hemorrhage.

2. They are frequently supplied by a fine tuft of feeders arising from anterior ethmoidal branches of the ophthalmic arteries.
 - (a) Because of this, they are difficult to treat with embolization because it is difficult to embolize the feeders without also embolizing the distal ophthalmic artery and retina.

15.4.6.1. Clinical features

1. Men are more commonly affected than women.^{143–145}
2. Anatomy. Typically, numerous arteries converge on the dura of the anterior cranial fossa floor and falx and merge into a single dilated draining vein.
 - (a) Feeders
 - Supply is via the anterior ethmoidal branches of the ophthalmic artery in 84% of cases.¹⁴³
 - Bilateral in 50% of cases.¹⁴⁴
 - Other feeders may arise from the internal maxillary artery, middle meningeal artery¹⁴⁶ and superficial temporal artery.
 - Rarely, additional feeders from the anterior cerebral artery may be present.^{146,147}
 - (b) Venous drainage
 - Drainage is into intradural frontal veins in all cases.¹⁴⁴
3. Presentation
 - (a) Most patients present with hemorrhage.^{143,144}
 - A review of reported cases found a history of hemorrhage in 62% of all cases of anterior fossa dAVFs, compared to about 15% for all intracranial dAVFs.¹⁴³
 - (b) Symptoms without hemorrhage may include
 - Visual loss, presumably from diversion of flow from the ophthalmic artery.¹⁴⁸
 - Proptosis and chemosis.¹⁴⁹
 - Diminished olfactory sensation and taste.¹⁴⁴
 - Intracranial venous hypertension and dementia.¹⁴⁹

15.4.6.2. Management

The natural history of anterior fossa dAVFs is not known. However, the fact that >80% of patients present with hemorrhage or have a history of hemorrhage, combined with the invariable retrograde venous drainage pattern seen with these lesions, lead most authors to agree that they are aggressive lesions that should be obliterated when feasible.^{144,145,149}

1. Surgery
 - (a) Surgery is first-line treatment for most patients, given the high hemorrhage risk of these lesions and the difficulties associated with embolization.^{144,150}
 - (b) Technique: A pterional or low-frontal craniotomy provides access to the floor of the frontal fossa. The key maneuver is interruption of the fistulous connection between the arteries perforating the dura around the cribriform plate and the draining vein or veins.¹⁴⁴ Coagulation and division of the connecting vein is usually all that is necessary for obliteration of the lesion; excision of the dura, or entry into the orbit for excision of the nidus are not necessary.^{144,151}
 - (c) Surgical results: A systematic review found a rate of obliteration with surgery of 95%.⁶⁷ Lawton and colleagues reported on 15 patients undergoing surgery; occlusion of the fistula was obtained in all patients.¹⁴⁴ No surgical complications were reported and a good outcome was described in all patients except one, who presented initially in a coma.
2. Embolization
 - (a) Venous embolization
 - Successful transvenous embolization by direct puncture of the internal jugular vein has been reported.¹⁵²
 - (b) Arterial embolization.
 - The proximity of the central retinal artery to the anterior ethmoidal branches makes arterial embolization of anterior fossa dAVFs problematic. Nevertheless, successful arterial embolization of these lesions has been reported by several authors.^{145,149} Embolization may be a reasonable option for symptomatic palliation and for patients who are poor surgical candidates.

- The microcatheter tip should be positioned distal to the origin of the central retinal artery, for obvious reasons.
 - Provocative testing with amytal and lidocaine prior to embolization is critical.
 - Use of embolic particles >400µm in size (the average diameter of the central retinal artery¹⁵³) may minimize risk of retinal ischemia.
3. Radiosurgery
- (a) Successful radiosurgery of anterior fossa dAVFs has been reported.⁷⁴

15.5. Appendix: Direct carotid-cavernous fistulas

15.5.1.1. Direct CC fistulas: Clinical features

1. Causes
 - (a) Trauma (most common cause)
 - (b) Ruptured cavernous segment ICA aneurysm (cause of ≤20% of direct CC fistulas^{154–156})
 - (c) Ehlers-Danlos Type IV¹⁵⁷ (see separate discussion below)
 - (d) Fibromuscular dysplasia¹⁵⁸
 - (e) Pseudoxanthoma elasticum
 - (f) Iatrogenesis:
 - Endoscopic sinus surgery.
 - Transsphenoidal pituitary surgery.
 - Trigeminal balloon microcompression gangliolysis.¹⁵⁹
 - Perforation of the meningohipophyseal trunk during embolization of a meningioma.¹⁶⁰
 - (g) Fungal arteritis associated with:
 - Osteogenesis imperfecta.¹⁶¹
2. Anatomy
 - (a) ICA defect:
 - Most direct fistulas are a single hole measuring 2–6mm in diameter.¹⁶²
 - Most common location the defect in traumatic cases is the horizontal cavernous segment.¹⁶²
 - May consist of more than one defect in the ICA (e.g., “double-hole” fistula) or a complete transection of the ICA.
 - (b) Bilateral traumatic CC fistulas are present in 1–2% of cases^{155,163}
 - (c) Venous drainage:
 - Cavernous sinus.
 - Retrograde intracranial venous flow is present in 9% of patients.¹⁶⁴
3. Presentation
 - (a) Classic description: Pulsating exophthalmos.^{165,166}
 - (b) Most frequent presentation: Exophthalmia with pulsating conjunctival hyperemia and vascular murmur.¹⁵⁴
 - (c) Severity of symptoms depends on the cause of fistula and the severity of the ICA lesion. Common findings include injection and chemosis, proptosis, elevated intraocular pressure, ophthalmoplegia and a periorbital bruit.
 - The sixth cranial nerve is most commonly affected.¹¹⁶
 - A third cranial nerve palsy, when present, may or may not be pupil-sparing (in contrast to third cranial nerve palsies due to a posterior communicating artery aneurysm, which nearly invariably has pupillary involvement).
 - Rarely, seventh cranial nerve dysfunction is present.¹⁶⁷
 - (d) A bruit is present in 80% of cases.¹⁵⁵
 - (e) Cerebral ischemia of the ipsilateral hemisphere can occur if the ICA flow is diverted into the cavernous sinus (i.e., a *functional* ICA occlusion is present, even if the vessel is physically patent) and collateral circulation is insufficient. A direct CC fistula may also act as a sump and divert flow from major intracranial arteries such as the p-comm.¹⁶⁴
4. Imaging
 - (a) CT

- In traumatic cases, a fine-cut head CT should be obtained to assess for skull fractures.
 - Skull fractures are present in 7–17% of traumatic CC fistula cases.
- CTA may show occlusion of the ICA or engorgement of the cavernous sinus.
- (b) MRA: Elliptical centric time-resolved imaging of contrast kinetics (EC-TRICKS) has provided good imaging of a direct CC fistula.¹⁶⁸
- (c) Angiography
 - A catheter angiogram remains the gold standard for a complete evaluation of a direct CC fistula.¹⁰⁰
 - Contralateral carotid and vertebral injections should be done to assess collateral circulation.
 - The anatomy of high-flow fistulas are difficult to discern, particularly if all of the contrast is diverted into the cavernous sinus. Helpful angiographic techniques:
 - Mehringer–Hieshima maneuver¹⁶⁹: Low-rate injection (2–3 mL/s) into the ipsilateral ICA while manual compression is applied to the ipsilateral CCA. Flow through the fistula is reduced to make it easier to see.
 - Huber maneuver¹⁷⁰: Selective injection of the dominant vertebral artery while manual compression is applied to the ipsilateral CCA. The fistula will opacify by retrograde flow.

15.5.1.2. Direct CC fistulas: Management

Spontaneous closure of direct CC fistulas occurs, but it is rare.¹⁵⁶ Some small asymptomatic direct fistulas can be left untreated, but most do require intervention. Further discussion of the management of cavernous segment ICA aneurysms is in Chap. 13.

1. Manual compression
 - (a) Technique: The patient is instructed to use the opposite hand to locate the pulse of the carotid artery in the mid-neck region just lateral to the trachea. Gradually increasing pressure is applied until the palpable pulse is stopped. The opposite hand is used in case hemispheric ischemia develops. Compression is maintained for 10–15 s at a time, 2–3 times an hour.
 - Contraindications: Cervical carotid artery disease (atherosclerosis, dissection), sick sinus syndrome, poor patient compliance.
 - (b) Results: 17% of patients with a direct CC fistula had complete closure of the fistula with no recurrence either clinically or at angiography done 1 year later.⁶⁵
2. Cavernous sinus embolization
 - (a) Transarterial
 - Detachable balloons
 - Cavernous sinus embolization with detachable balloons is associated with a fistula occlusion rate of ~90% with preservation of the ICA in 60–88% of cases.^{63,162,163,171} Detachable balloons are not currently available in the United States, but they are still in use in other countries.^{172,173}
 - Coils^{174,175}
 - Coil embolization is most useful for the treatment of direct CC fistulas due to a ruptured cavernous segment aneurysm.¹⁷³ Transarterial embolization of traumatic CC fistulas can be problematic, particularly when the defect in the wall of the ICA is large. An initial closure of the fistula may be obtained, but the coils may migrate within the cavernous sinus over time, leading to a recurrence of the fistula. The authors of this handbook have witnessed this scenario repeatedly.
 - Coils or balloons + liquid embolics
 - Transarterial embolization of the cavernous sinus with coils, combined with glue (NBCA) or Onyx, can be effective in select cases.¹⁷²
 - Access to the cavernous sinus can even be reached through the vertebral artery.¹⁷⁶
 - (b) Transvenous
 - Transvenous embolization with coils alone seems to be more effective than transarterial embolization with coils alone, likely because

- better microcatheter positioning is possible and tighter packing of the cavernous sinus can be achieved.^{174,175}
 - Superior ophthalmic vein approach.⁷⁰
3. Stenting
 - (a) Stent-assisted embolization¹⁷⁷
 - (b) Covered stent repair of the ICA^{178–180}
 4. Carotid sacrifice
 - (a) Parent vessel occlusion is a valid option, but should be preceded by balloon test occlusion

15.5.1.3. Ehlers-Danlos type IV

Ehlers-Danlos Type IV (aka vascular type) is rare autosomal dominant collagen-vascular disorder. Type IV accounts for 4% of all Ehlers-Danlos cases and is the most severe form of the disease.

1. Diagnosis
 - (a) Four clinical criteria¹⁸¹:
 - Easy bruising
 - Thin skin with visible veins
 - Characteristic facial features
 - Rupture of arteries, uterus, or intestines
 - (b) Confirmation of diagnosis:
 - Cultured fibroblasts synthesize abnormal type III procollagen molecules or identification of a mutation in the gene for type III procollagen.¹⁸²
2. Pathophysiology
 - (a) Type III collagen is decreased or absent.
 - (b) The vessels in affected patients have reduced total collagen content and have thin walls with irregular elastic fibrils and reduced cross-sectional area.
3. Epidemiology
 - (a) Very rare. Prevalence is unknown.
4. Clinical features
 - (a) Hypermobility of large joints and hyperextensibility of the skin, features of the more common forms of Ehlers-Danlos syndrome are unusual in Type IV.
 - (b) Median life expectancy is 48 years.¹⁸²
 - Complications are rare in childhood; 25% of patients have a first complication by the age of 20 years and more than 80% have at least one complication by the age of 40.¹⁸²
 - Most deaths result from arterial dissection or rupture.¹⁸²
 - (c) *Cerebrovascular manifestations*
 - About 10% of patients have an arterial problem affecting the central nervous system.¹⁸²
 - Direct CC fistulas
 - Most common cerebrovascular complication.
 - Patients are predominantly female.¹⁸³
 - May be bilateral.¹⁸⁴
 - Endovascular treatment of direct CC fistulas in patients with Ehlers Danlos IV is very hazardous because of the fragility of the vessels.^{157,184,185}
 - A review of published reports of diagnostic cerebral angiography in patients with Ehlers-Danlos IV, the overall morbidity was 36% and mortality was 12%.¹⁸⁶ In another report, two of four patients died due to remote vascular injuries around the time of their neurointerventional procedures.¹⁸⁵

15.6. References

1. Borden JA, Wu JK, Shucart WA. A proposed classification for spinal and cranial dural arteriovenous fistulous malformations and implications for treatment. *J Neurosurg* 1995;82(2):166–79.
2. Al-Shahi R, Bhattacharya JJ, Currie DG, et al. Prospective, population-based detection of intracranial vascular malformations in adults: The Scottish Intracranial Vascular Malformation Study (SIVMS). *Stroke* 2003;34(5):1163–9.
3. Davies MA, TerBrugge K, Willinsky R, Coyne T, Saleh J, Wallace MC. The validity of classification for the clinical presentation of intracranial dural arteriovenous fistulas. *J Neurosurg* 1996;85(5):830–7.

4. Cognard C, Gobin YP, Pierot L, et al. Cerebral dural arteriovenous fistulas: clinical and angiographic correlation with a revised classification of venous drainage. *Radiology* 1995;194(3):671-80.
5. Houser OW, Campbell JK, Campbell RJ, Sundt TM, Jr. Arteriovenous malformation affecting the transverse dural venous sinus - an acquired lesion. *Mayo Clin Proc* 1979;54(10):651-61.
6. Piton J, Guilleux MH, Guibert-Tranier F, Caille JM. Fistulae of the lateral sinus. *J Neuroradiol* 1984;11(3):143-59.
7. Mullan S. Reflections upon the nature and management of intracranial and intraspinal vascular malformations and fistulae. *J Neurosurg* 1994;80(4):606-16.
8. Chaudhary MY, Sachdev VP, Cho SH, Weitzner I, Jr., Puljic S, Huang YP. Dural arteriovenous malformation of the major venous sinuses: an acquired lesion. *Am J Neuroradiol* 1982;3(1):13-9.
9. Terada T, Tsura M, Komai N, et al. The role of angiogenic factor bFGF in the development of dural AVFs. *Acta Neurochir (Wien)* 1996;138(7):877-83.
10. Lawton MT, Jacobowitz R, Spetzler RF. Redefined role of angiogenesis in the pathogenesis of dural arteriovenous malformations. *J Neurosurg* 1997;87(2):267-74.
11. Uranishi R, Nakase H, Sakaki T. Expression of angiogenic growth factors in dural arteriovenous fistula. *J Neurosurg* 1999;91(5):781-6.
12. Tirakotai W, Bian LG, Bertalanffy H, Siegfried B, Sure U. Immunohistochemical study in dural arteriovenous fistula and possible role of ephrin-B2 for development of dural arteriovenous fistula. *Chin Med J (Engl)* 2004;117(12):1815-20.
13. Klisch J, Kubalek R, Scheufler KM, Zirngiebel U, Dreys J, Schumacher M. Plasma vascular endothelial growth factor and serum soluble angiopoietin receptor sTIE-2 in patients with dural arteriovenous fistulas: a pilot study. *Neuroradiology* 2005;47(1):10-7.
14. Arkhipovich AA. [The functional significance of the arteriovenous anastomoses of the cerebral dura mater]. *Vopr Neurokhir* 1974;0(2):37-42.
15. Rowbotham GF, Little E. The circulations and reservoir of the dura mater. *Neuroradiology* 1973;6(4):175-9.
16. Kerber CW, Newton TH. The macro and microvasculature of the dura mater. *Neuroradiology* 1973;6(4):175-9.
17. Ishikawa T, Sato S, Sasaki T, et al. Histologic study of arteriovenous shunts in the normal dura mater adjacent to the transverse sinus. *Surg Neurol* 2007;68(3):272-6.
18. Djindjian R, Cophignon J, Rey A, Theron J, Merland JJ, Houdart R. Superselective arteriographic embolization by the femoral route in neuroradiology. Study of 50 cases. II. Embolization in vertebrobasilar pathology. *Neuroradiology* 1973;6(3):132-42.
19. Hamada Y, Goto K, Inoue T, et al. Histopathological aspects of dural arteriovenous fistulas in the transverse-sigmoid sinus region in nine patients. *Neurosurgery* 1997;40(3):452-6; discussion 6-8.
20. Nishijima M, Takaku A, Endo S, et al. Etiological evaluation of dural arteriovenous malformations of the lateral and sigmoid sinuses based on histopathological examinations. *J Neurosurg* 1992;76(4):600-6.
21. Handa J, Yoneda S, Handa H. Venous sinus occlusion with a dural arteriovenous malformation of the posterior fossa. *Surg Neurol* 1975;4(5):433-7.
22. Herman JM, Spetzler RF, Bederson JB, Kurbat JM, Zabramski JM. Genesis of a dural arteriovenous malformation in a rat model. *J Neurosurg* 1995;83(3):539-45.
23. Terada T, Higashida RT, Halbach VV, et al. Development of acquired arteriovenous fistulas in rats due to venous hypertension. *J Neurosurg* 1994;80(5):884-9.
24. Lasjaunias P, Chiu M, ter Brugge K, Tolia A, Hurth M, Bernstein M. Neurological manifestations of intracranial dural arteriovenous malformations. *J Neurosurg* 1986;64(5):724-30.
25. Kincaid PK, Duckwiler GR, Gobin YP, Vinuela F. Dural arteriovenous fistula in children: endovascular treatment and outcomes in seven cases. *Am J Neuroradiol* 2001;22(6):1217-25.
26. Satomi J, van Dijk JM, Terbrugge KG, Willinsky RA, Wallace MC. Benign cranial dural arteriovenous fistulas: outcome of conservative management based on the natural history of the lesion. *J Neurosurg* 2002;97(4):767-70.
27. Raupp S, van Rooij WJ, Sluzewski M, Tijssen CC. Type I cerebral dural arteriovenous fistulas of the lateral sinus: clinical features in 24 patients. *Eur J Neurol* 2004;11(7):489-91.
28. van Rooij WJ, Sluzewski M, Beute GN. Dural arteriovenous fistulas with cortical venous drainage: incidence, clinical presentation, and treatment. *Am J Neuroradiol* 2007;28(4):651-5.
29. van Dijk JM, Terbrugge KG, Willinsky RA, Wallace MC. Selective disconnection of cortical venous reflux as treatment for cranial dural arteriovenous fistulas. *J Neurosurg* 2004;101(1):31-5.
30. Barnwell SL, Halbach VV, Dowd CF, Higashida RT, Hieshima GB, Wilson CB. Multiple dural arteriovenous fistulas of the cranium and spine. *Am J Neuroradiol* 1991;12(3):441-5.
31. Brown RD, Jr., Wiebers DO, Nichols DA. Intracranial dural arteriovenous fistulae: angiographic predictors of intracranial hemorrhage and clinical outcome in nonsurgical patients. *J Neurosurg* 1994;81(4):531-8.
32. Davies MA, ter Brugge K, Willinsky R, Wallace MC. The natural history and management of intracranial dural arteriovenous fistulae. Part 2: Aggressive lesions. *Interv Neuroradiol* 1997;3:303-11.
33. van Dijk JMC, ter Brugge KG, Willinsky RA, Wallace MC. Clinical course of cranial dural arteriovenous fistulas with long-term persistent cortical venous reflux. *Stroke* 2002;33(5):1233-6.
34. Cordonnier C, Al-Shahi Salman R, Bhattacharya JJ, et al. Differences between intracranial vascular malformation types in the characteristics of their presenting haemorrhages: prospective, population-based study. *J Neurol Neurosurg Psychiatry* 2008;79:47-51.
35. Awad IA, Little JR, Akarawi WP, Ahl J. Intracranial dural arteriovenous malformations: factors predisposing to an aggressive neurological course. *J Neurosurg* 1990;72(6):839-50.
36. Malik GM, Pearce JE, Ausman JJ, Mehta B. Dural arteriovenous malformations and intracranial hemorrhage. *Neurosurgery* 1984;15(3):332-9.
37. Willinsky R, Terbrugge K, Montanera W, Mikulis D, Wallace MC. Venous congestion: an MR finding in dural arteriovenous malformations with cortical venous drainage. *Am J Neuroradiol* 1994;15(8):1501-7.
38. Yamakami I, Kobayashi E, Yamaura A. Diffuse white matter changes caused by dural arteriovenous fistula. *J Clin Neurosci* 2001;8(5):471-5.
39. Hirono N, Yamadori A, Komiya M. Dural arteriovenous fistula: a cause of hypoperfusion-induced intellectual impairment. *Eur Neurol* 1993;33(1):5-8.
40. Cognard C, Casasco A, Toevi M, Houdart E, Chiras J, Merland J-J. Dural arteriovenous fistulas as a cause of intracranial hypertension due to impairment of cranial venous outflow. *J Neurol Neurosurg Psychiatry* 1998;65(3):308-16.
41. Hurst RW, Bagley LJ, Galetta S, et al. Dementia resulting from dural arteriovenous fistulas: the pathologic findings of venous hypertensive encephalopathy. *Am J Neuroradiol* 1998;19(7):1267-73.
42. Hasumi T, Fukushima T, Haisa T, Yonemitsu T, Waragai M. Focal dural arteriovenous fistula (DAVF) presenting with progressive cognitive impairment including amnesia and alexia. *Intern Med* 2007;46(16):1317-20.
43. Silberstein P, Kottos P, Worner C, et al. Dural arteriovenous fistulae causing pseudotumour cerebri syndrome in an elderly man. *J Clin Neurosci* 2003;10(2):242-3.
44. Lee PH, Lee JS, Shin DH, Kim BM, Huh K. Parkinsonism as an initial manifestation of dural arteriovenous fistula. *Eur J Neurol* 2005;12(5):403-6.
45. Stouffer JL, Tyler RS. Characterization of tinnitus by tinnitus patients. *J Speech Hear Disord* 1990;55(3):439-53.
46. Waldvogel D, Mattle HP, Sturzenegger M, Schroth G. Pulsatile tinnitus - a review of 84 patients. *J Neurol* 1998;245(3):137-42.
47. Adler JR, Ropper AH. Self-audible venous bruits and high jugular bulb. *Arch Neurol* 1986;43(3):257-9.

48. Russell EJ, De Michaelis BJ, Wiet R, Meyer J. Objective pulse-synchronous "essential" tinnitus due to narrowing of the transverse dural venous sinus. *Int Tinnitus J* 1995;1(2):127-37.
49. Shin EJ, Lalwani AK, Dowd CF. Role of angiography in the evaluation of patients with pulsatile tinnitus. *Laryngoscope* 2000;110(11):1916-20.
50. Cawley CM, Barrow DL, Dion JE. Treatment of lateral-sigmoid and sagittal sinus dural arteriovenous malformations. In: Winn HR, ed. *Youmans Neurological Surgery*. Philadelphia: Saunders; 2004:2283-91.
51. van Rooij WJ, Shuzewski M, Beute GN. Intracranial dural fistulas with exclusive perimedullary drainage: the need for complete cerebral angiography for diagnosis and treatment planning. *Am J Neuroradiol* 2007;28(2):348-51.
52. Willinsky R, Goyal M, terBrugge K, Montanera W. Tortuous, engorged pial veins in intracranial dural arteriovenous fistulas: correlations with presentation, location, and MR findings in 122 patients. *Am J Neuroradiol* 1999;20(6):1031-6.
53. Coley SC, Romanowski CA, Hodgson TJ, Griffiths PD. Dural arteriovenous fistulae: noninvasive diagnosis with dynamic MR digital subtraction angiography. *Am J Neuroradiol* 2002;23(3):404-7.
54. Noguchi K, Kubo M, Kuwayama N, et al. Intracranial dural arteriovenous fistulas with retrograde cortical venous drainage: assessment with cerebral blood volume by dynamic susceptibility contrast magnetic resonance imaging. *Am J Neuroradiol* 2006;27(6):1252-6.
55. Hashimoto Y, Kin S, Haraguchi K, Niwa J. Pitfalls in the preoperative evaluation of subarachnoid hemorrhage without digital subtraction angiography: report on 2 cases. *Surg Neurol* 2007;68(3):344-8.
56. Coskun O, Hamon M, Catroux G, Gosme L, Courtheoux P, Theron J. Carotid-cavernous fistulas: diagnosis with Ssral CT angiography. *Am J Neuroradiol* 2000;21(4):712-6.
57. Davies MA, Saleh J, ter Brugge K, Willinsky R, Wallace MC. The natural history and management of intracranial dural arteriovenous fistulae. Part 1: Benign lesions. *Interv Neuroradiol* 1997;3:295-302.
58. Cognard C, Houdart E, Casasco A, Gabrillargues J, Chiras J, Merland JJ. Long-term changes in intracranial dural arteriovenous fistulae leading to worsening in the type of venous drainage. *Neuroradiology* 1997;39(1):59-66.
59. Duffau H, Lopes M, Janosevic V, et al. Early rebleeding from intracranial dural arteriovenous fistulas: report of 20 cases and review of the literature. *J Neurosurg* 1999;90(1):78-84.
60. Ohtulola PS, Eliam M, Molot M, Talalla A. Spontaneous regression of a dural arteriovenous malformation. *Neurosurgery* 1983;12(6):687-90.
61. Hamby WB. Signs and symptoms of carotid-cavernous fistula. In: *Carotid Cavernous Fistula*. Springfield: Charles C. Thomas; 1966.
62. Phelps CD, Thompson HS, Ossoinig KC. The diagnosis and prognosis of atypical carotid-cavernous fistula (red-eyed shunt syndrome). *Am J Ophthalmol* 1982;93(4):423-36.
63. Barrow DL, Spector RH, Braun IF, Landman JA, Tindall SC, Tindall GT. Classification and treatment of spontaneous carotid-cavernous sinus fistulas. *J Neurosurg* 1985;62(2):248-56.
64. Sasaki H, Nukui H, Kaneko M, et al. Long-term observations in cases with spontaneous carotid-cavernous fistulas. *Acta Neurochir (Wien)* 1988;90(3-4):117-20.
65. Higashida RT, Hieshima GB, Halbach VV, Benton JR, Goto K. Closure of carotid cavernous sinus fistulae by external compression of the carotid artery and jugular vein. *Acta Radiol Suppl* 1986;369:580-3.
66. Halbach VV, Higashida RT, Hieshima GB, Goto K, Norman D, Newton TH. Dural fistulas involving the transverse and sigmoid sinuses: results of treatment in 28 patients. *Radiology* 1987;163(2):443-7.
67. Lucas CP, Zabramski JM, Spetzler RF, Jacobowitz R. Treatment for intracranial dural arteriovenous malformations: a meta-analysis from the English language literature. *Neurosurgery* 1997;40(6):1119-30; discussion 30-2.
68. Sundt TM, Jr., Piepgras DG. The surgical approach to arteriovenous malformations of the lateral and sigmoid dural sinuses. *J Neurosurg* 1983;59(1):32-9.
69. Thompson BG, Doppman JL, Oldfield EH. Treatment of cranial dural arteriovenous fistulae by interruption of leptomeningeal venous drainage. *J Neurosurg* 1994;80(4):617-23.
70. Miller NR, Monsein LH, Debrun GM, Tamargo RJ, Nauta HJ. Treatment of carotid-cavernous sinus fistulas using a superior ophthalmic vein approach. *J Neurosurg* 1995;83(5):838-42.
71. Quinones D, Duckwiler G, Gobin PY, Goldberg RA, Vinuela F. Embolization of dural cavernous fistulas via superior ophthalmic vein approach. *Am J Neuroradiol* 1997;18(5):921-8.
72. Houdart E, Saint-Maurice JP, Chapot R, et al. Transcranial approach for venous embolization of dural arteriovenous fistulas. *J Neurosurg* 2002;97(2):280-6.
73. Koebele CJ, Singhal D, Sheehan J, et al. Radiosurgery for dural arteriovenous fistulas. *Surg Neurol* 2005;64(5):392-8; discussion 8-9.
74. Soderman M, Edner G, Ericson K, et al. Gamma knife surgery for dural arteriovenous shunts: 25 years of experience. *J Neurosurg* 2006;104(6):867-75.
75. Friedman JA, Pollock BE, Nichols DA, Gorman DA, Foote RL, Stafford SL. Results of combined stereotactic radiosurgery and transarterial embolization for dural arteriovenous fistulas of the transverse and sigmoid sinuses. *J Neurosurg* 2001;94(6):886-91.
76. O'Leary S, Hodgson TJ, Coley SC, Kemeny AA, Radatz MW. Intracranial dural arteriovenous malformations: results of stereotactic radiosurgery in 17 patients. *Clin Oncol (R Coll Radiol)* 2002;14(2):97-102.
77. Pan DH, Chung WY, Guo WY, et al. Stereotactic radiosurgery for the treatment of dural arteriovenous fistulas involving the transverse-sigmoid sinus. *J Neurosurg* 2002;96(5):823-9.
78. Kim MS, Han DH, Kwon OK, Oh C-W, Han MH. Clinical characteristics of dural arteriovenous fistula. *J Clin Neurosci* 2002;9(2):147-55.
79. McDougall CG, Halbach VV, Higashida RT, et al. Treatment of dural arteriovenous fistulas. *Neurosurg Q* 1997;7:110-34.
80. Lalwani AK, Dowd CF, Halbach VV. Grading venous restrictive disease in patients with dural arteriovenous fistulas of the transverse/sigmoid sinus. *J Neurosurg* 1993;79(1):11-5.
81. Ahn JY, Lee BH, Cho YJ, Joo JY, Lee KS. Dural arteriovenous fistula associated with meningioma: spontaneous disappearance after tumor removal. *Neurol Med Chir (Tokyo)* 2003;43(6):308-11.
82. Horinaka N, Nonaka Y, Nakayama T, Mori K, Wada R, Maeda M. Dural arteriovenous fistula of the transverse sinus with concomitant ipsilateral meningioma. *Acta Neurochir (Wien)* 2003;145(6):501-4; discussion 4.
83. de Paula Lucas C, Zabramski JM. Dural arteriovenous fistula of the transverse-sigmoid sinus causing trigeminal neuralgia. *Acta Neurochir (Wien)* 2007;149(12):1249-53.
84. Collice M, D'Aliberti G, Talamonti G, et al. Surgical interruption of leptomeningeal drainage as treatment for intracranial dural arteriovenous fistulas without dural sinus drainage. *J Neurosurg* 1996;84(5):810-7.
85. Urtaşun F, Biondi A, Casaco A, et al. Cerebral dural arteriovenous fistulas: percutaneous transvenous embolization. *Radiology* 1996;199(1):209-17.
86. Roy D, Raymond J. The role of transvenous embolization in the treatment of intracranial dural arteriovenous fistulas. *Neurosurgery* 1997;40(6):1133-41; discussion 41-4.
87. Caragine LP, Halbach VV, Dowd CF, Ng PP, Higashida RT. Parallel venous channel as the recipient pouch in transverse/sigmoid sinus dural fistulae. *Neurosurgery* 2003;53(6):1261-6; discussion 6-7.
88. Dawson RC, III, Joseph GJ, Owens DS, Barrow DL. Transvenous embolization as the primary therapy for arteriovenous fistulas of the lateral and sigmoid sinuses. *Am J Neuroradiol* 1998;19(3):571-6.
89. Halbach VV, Higashida RT, Hieshima GB, Christopher FD. Endovascular therapy of dural fistulas. In: Vinuela F, Halbach VV, Dion JE, eds. *Interventional Neuroradiology: Endovascular Therapy of the Central Nervous System*. New York: Raven; 1992:29-50.
90. Olteanu-Nerbe V, Uhl E, Steiger HJ, Yousry T, Reulen HJ. Dural arteriovenous fistulas including the transverse

- and sigmoid sinuses: results of treatment in 30 cases. *Acta Neurochir (Wien)* 1997;139(4):307-18.
91. Murphy KJ, Gailloud P, Venbrux A, Deramond H, Hanley D, Rigamonti D. Endovascular treatment of a grade IV transverse sinus dural arteriovenous fistula by sinus recanalization, angioplasty, and stent placement: technical case report. *Neurosurgery* 2000;46(2):497-500; discussion 1.
 92. Tomsick TA. Etiology, prevalence, and natural history. In: Tomsick TA, ed. *Carotid Cavernous Fistula*. Cincinnati: Digital Educational Publishing; 1997:59-73.
 93. Ernst RJ, Tomsick TA. Classification and angiography of carotid cavernous fistulas. In: Tomsick TA, ed. *Carotid Cavernous Fistula*. Cincinnati: Digital Educational Publishing; 1997:13-21.
 94. Kirsch M, Henkes H, Liebig T, et al. Endovascular management of dural carotid-cavernous sinus fistulas in 141 patients. *Neuroradiology* 2006;48(7):486-90.
 95. Malek AM, Halbach VV, Higashida RT, Phatouros CC, Meyers PM, Dowd CF. Treatment of dural arterio-malformations and fistulas. In: Rosenwasser RH, ed. *Neuroendovascular Surgery*. Philadelphia: Saunders; 2000:147-66.
 96. Barnwell SL, Halbach VV, Dowd CF, Higashida RT, Hieshima GB. Dural arteriovenous fistulas involving the inferior petrosal sinus: angiographic findings in six patients. *Am J Neuroradiol* 1990;11(3):511-6.
 97. Mohyuddin A. Indirect carotid cavernous fistula presenting as pulsatile tinnitus. *J Laryngol Otol* 2000;114(10):788-9.
 98. Halbach VV, Higashida RT, Hieshima GB, Reicher M, Norman D, Newton TH. Dural fistulas involving the cavernous sinus: results of treatment in 30 patients. *Radiology* 1987;163(2):437-42.
 99. Acierno MD, Trobe JD, Cornblath WT, Gebarski SS. Painful oculomotor palsy caused by posterior-draining dural carotid cavernous fistulas. *Arch Ophthalmol* 1995;113(8):1045-9.
 100. Phatouros CC, Meyers PM, Dowd CF, Halbach VV, Malek AM, Higashida RT. Carotid artery cavernous fistulas. In: Rosenwasser RH, ed. *Neuroendovascular Surgery*. Philadelphia: W.B. Saunders; 2000:67-84.
 101. Yamashita K, Taki W, Nishi S, et al. Transvenous embolization of dural carotid-cavernous fistulae: technical considerations. *Neuroradiology* 1993;35(6):475-9.
 102. Meyers PM, Halbach VV, Dowd CF, et al. Dural carotid cavernous fistula: definitive endovascular management and long-term follow-up. *Am J Ophthalmol* 2002;134(1):85-92.
 103. Kinugasa K, Tokunaga K, Kamata I, et al. Selection and combination of techniques for treating spontaneous carotid-cavernous sinus fistulas. *Neurol Med Chir (Tokyo)* 1994;34(9):597-606.
 104. Kim DJ, Kim DI, Suh SH, et al. Results of transvenous embolization of cavernous dural arteriovenous fistula: a single-center experience with emphasis on complications and management. *Am J Neuroradiol* 2006;27(10):2078-82.
 105. Halbach VV, Higashida RT, Hieshima GB, Hardin CW, Pribram H. Transvenous embolization of dural fistulas involving the cavernous sinus. *Am J Neuroradiol* 1989;10(2):377-83.
 106. Benndorf G, Bender A, Lehmann R, Lanksch W. Transvenous occlusion of dural cavernous sinus fistulas through the thrombosed inferior petrosal sinus: report of four cases and review of the literature. *Surg Neurol* 2000;54(1):42-54.
 107. Benndorf G, Bender A, Campi A, Menneking H, Lanksch WR. Treatment of a cavernous sinus dural arteriovenous fistula by deep orbital puncture of the superior ophthalmic vein. *Neuroradiology* 2001;43(6):499-502.
 108. Agid R, Willinsky RA, Haw C, Souza MP, Vane JJ, ter-Brugge KG. Targeted compartmental embolization of cavernous sinus dural arteriovenous fistulae using transfemoral medial and lateral facial vein approaches. *Neuroradiology* 2004;46(2):156-60.
 109. Mounayer C, Pötin M, Spelle L, Moret J. Superior petrosal sinus catheterization for transvenous embolization of a dural carotid cavernous sinus fistula. *Am J Neuroradiol* 2002;23(7):1153-5.
 110. Kuwayama N, Endo S, Kitabayashi M, Nishijima M, Takaku A. Surgical transvenous embolization of a cortically draining carotid cavernous fistula via a vein of the sylvian fissure. *Am J Neuroradiol* 1998;19(7):1329-32.
 111. Jahan R, Gobin YP, Glenn B, Duckwiler GR, Vinuela F. Transvenous embolization of a dural arteriovenous fistula of the cavernous sinus through the contralateral pterygoid plexus. *Neuroradiology* 1998;40(3):189-93.
 112. Venturi C, Bracco S, Cerase A, et al. Endovascular treatment of a cavernous sinus dural arteriovenous fistula by transvenous embolization through the superior ophthalmic vein via cannulation of a frontal vein. *Neuroradiology* 2003;45(8):574-8.
 113. Wakhloo AK, Perlow A, Linfante I, et al. Transvenous n-butyl-cyanoacrylate infusion for complex dural carotid cavernous fistulas: technical considerations and clinical outcome. *Am J Neuroradiol* 2005;26(8):1888-97.
 114. Shaibani A, Rohany M, Parkinson R, et al. Primary treatment of an indirect carotid cavernous fistula by injection of N-butyl cyanoacrylate in the dural wall of the cavernous sinus. *Surg Neurol* 2007;67(4):403-8; discussion 8.
 115. Suzuki S, Lee DW, Jahan R, Duckwiler GR, Vinuela F. Transvenous treatment of spontaneous dural carotid-cavernous fistulas using a combination of detachable coils and onyx. *Am J Neuroradiol* 2006;27(6):1346-9.
 116. Kupersmith MJ, Berenstein A, Flamm E, Ransohoff J. Neuroophthalmologic abnormalities and intravascular therapy of traumatic carotid cavernous fistulas. *Ophthalmology* 1986;93(7):906-12.
 117. Guo WY, Pan DH, Wu HM, et al. Radiosurgery as a treatment alternative for dural arteriovenous fistulas of the cavernous sinus. *Am J Neuroradiol* 1998;19(6):1081-7.
 118. Pollock BE, Nichols DA, Garrity JA, Gorman DA, Stafford SL. Stereotactic radiosurgery and particulate embolization for cavernous sinus dural arteriovenous fistulae. *Neurosurgery* 1999;45(3):459-66; discussion 66-7.
 119. Ng PP, Halbach VV, Quinn R, et al. Endovascular treatment for dural arteriovenous fistulae of the superior petrosal sinus. *Neurosurgery* 2003;53(1):25-32; discussion 3.
 120. Tomak PR, Cloft HJ, Kaga A, Cawley CM, Dion J, Barrow DL. Evolution of the management of tentorial dural arteriovenous malformations. *Neurosurgery* 2003;52(4):750-60; discussion 60-2.
 121. Grisoli F, Vincentelli F, Fuchs S, et al. Surgical treatment of tentorial arteriovenous malformations draining into the subarachnoid space. Report of four cases. *J Neurosurg* 1984;60(5):1059-66.
 122. Zhou L-F, Chen L, Song D-L, Gu Y-X, Leng B. Tentorial dural arteriovenous fistulas. *Surg Neurol* 2007;67(5):472-81.
 123. Picard L, Bracard S, Istak C, et al. Dural fistulae of the tentorium cerebelli. Radioanatomical, clinical and therapeutic considerations. *J Neuroradiol* 1990;17(3):161-81.
 124. Lewis AI, Rosenblatt SS, Tew JM, Jr. Surgical management of deep-seated dural arteriovenous malformations. *J Neurosurg* 1997;87(2):198-206.
 125. King WA, Martin NA. Intracerebral hemorrhage due to dural arteriovenous malformations and fistulae. *Neurosurg Clin N Am* 1992;3(3):577-90.
 126. van Rooij W, Sluzewski M, Beute GN. Tentorial artery embolization in tentorial dural arteriovenous fistulas. *Neuroradiology* 2006;48(10):737-43.
 127. Deshmukh VR, Maughan PH, Spetzler RF. Resolution of hemifacial spasm after surgical obliteration of a tentorial arteriovenous fistula: case report. *Neurosurgery* 2006;58(1):E202; discussion E.
 128. Benndorf G, Schmidt S, Sollmann WP, Kroppenstedt SN. Tentorial dural arteriovenous fistula presenting with various visual symptoms related to anterior and posterior visual pathway dysfunction: case report. *Neurosurgery* 2003;53(1):222-6; discussion 6-7.
 129. Matsushige T, Nakaoka M, Ohta K, Yahara K, Okamoto H, Kurisu K. Tentorial dural arteriovenous malformation manifesting as trigeminal neuralgia treated by stereotactic radiosurgery: a case report. *Surg Neurol* 2006;66(5):519-23; discussion 23.
 130. Iwamoto Y, Nakahara I, Higashi T, et al. Tentorial dural arteriovenous fistula presenting symptoms due to mass

- effect on the dilated draining vein: case report. *Surg Neurol* 2006;65(5):511-5.
131. Detwiler PW, Lucas CP, Zabramski JM, McDougall CG. Cranial dural arteriovenous malformations. *BNI Q* 2000;16(1):24-32.
 132. Kallmes DF, Jensen ME, Cloft HJ, Kassell NF, Dion JE. Percutaneous transvenous coil embolization of a Djindjian type 4 tentorial dural arteriovenous malformation. *Am J Neuroradiol* 1997;18(4):673-6.
 133. Lv X, Li Y, Lv M, Liu A, Zhang J, Wu Z. Trigemino-cardiac reflex in embolization of intracranial dural arteriovenous fistula. *Am J Neuroradiol* 2007;28(9):1769-70.
 134. Lewis AI, Tomsick TA, Tew JM, Jr. Management of tentorial dural arteriovenous malformations: transarterial embolization combined with stereotactic radiation or surgery. *J Neurosurg* 1994;81(6):851-9.
 135. Shin M, Kurita H, Tago M, Kirino T. Stereotactic radiosurgery for tentorial dural arteriovenous fistulae draining into the vein of Galen: report of two cases. *Neurosurgery* 2000;46(3):730-3; discussion 3-4.
 136. Kurl S, Saari T, Vanninen R, Hemesniemi J. Dural arteriovenous fistulas of superior sagittal sinus: case report and review of literature. *Surg Neurol* 1996;45(3):250-4.
 137. Barnwell SL, Halbach VV, Dowd CF, Higashida RT, Hieshima GB, Wilson CB. A variant of arteriovenous fistulas within the wall of dural sinuses. Results of combined surgical and endovascular therapy. *J Neurosurg* 1991;74(2):199-204.
 138. Pierot L, Visot A, Boulin A, Dupuy M. Combined neurosurgical and neuroradiological treatment of a complex superior sagittal sinus dural fistula: technical note. *Neurosurgery* 1998;42(1):194-7.
 139. Jaeger R. Observations on resection of the superior longitudinal sinus at and posterior to the Rolandic venous inflow. *J Neurosurg* 1951;8(1):103-9.
 140. Halbach VV, Higashida RT, Hieshima GB, Rosenblum M, Cahan L. Treatment of dural arteriovenous malformations involving the superior sagittal sinus. *Am J Neuroradiol* 1988;9(2):337-43.
 141. Bertalanffy A, Dietrich W, Kitz K, Bavinzki G. Treatment of dural arteriovenous fistulae (dAVFs) at the superior sagittal sinus (SSS) using embolisation combined with micro- or radiosurgery. *Minim Invasive Neurosurg* 2001;44(4):205-10.
 142. Maruyama K, Shin M, Kurita H, Tago M, Kirino T. Stereotactic radiosurgery for dural arteriovenous fistula involving the superior sagittal sinus. Case report. *J Neurosurg* 2002;97(5 Suppl):481-3.
 143. Gliemroth J, Nowak G, Arnold H. Dural arteriovenous malformation in the anterior cranial fossa. *Clin Neurol Neurosurg* 1999;101(1):37-43.
 144. Lawton MT, Chun J, Wilson CB, Halbach VV. Ethmoidal dural arteriovenous fistulae: an assessment of surgical and endovascular management. *Neurosurgery* 1999;45(4):805-10; discussion 10-1.
 145. Lefkowitz M, Giannotta SL, Hieshima G, et al. Embolization of neurosurgical lesions involving the ophthalmic artery. *Neurosurgery* 1998;43(6):1298-303.
 146. Newton TH, Cronqvist S. Involvement of dural arteries in intracranial arteriovenous malformations. *Radiology* 1969;93(5):1071-8.
 147. Martin NA, King WA, Wilson CB, Nutik S, Carter LP, Spetzler RF. Management of dural arteriovenous malformations of the anterior cranial fossa. *J Neurosurg* 1990;72(5):692-7.
 148. Tiyyavorabun S, Vonofakos D, Lorenz R. Intracerebral arteriovenous malformation fed by both ethmoidal arteries. *Surg Neurol* 1986;26(4):375-82.
 149. Abrahams JM, Bagley LJ, Flamm ES, Hurst RW, Sinson GP. Alternative management considerations for ethmoidal dural arteriovenous fistulas. *Surg Neurol* 2002;58(6):410-6.
 150. Halbach VV, Higashida RT, Hieshima GB, Wilson CB, Barnwell SL, Dowd CF. Dural arteriovenous fistulas supplied by ethmoidal arteries. *Neurosurgery* 1990;26(5):816-23.
 151. Im S-H, Oh CW, Han DH. Surgical management of an unruptured dural arteriovenous fistula of the anterior cranial fossa: natural history for 7 years. *Surg Neurol* 2004;62(1):72-5.
 152. Defreyne L, Vanlangenhove P, Vandekerckhove T, et al. Transvenous embolization of a dural arteriovenous fistula of the anterior cranial fossa: preliminary results. *Am J Neuroradiol* 2000;21(4):761-5.
 153. Tsutsumi S, Rhoton AL, Jr. Microsurgical anatomy of the central retinal artery. *Neurosurgery* 2006;59(4):870-8; discussion 8-9.
 154. Desal H, Leaute F, Auffray-Calvier E, et al. [Direct carotid-cavernous fistula. Clinical, radiologic and therapeutic studies. Apropos of 49 cases]. *J Neuroradiol* 1997;24(2):141-54.
 155. Lewis AI, Tomsick TA, Tew JM, Jr. Management of 100 consecutive direct carotid-cavernous fistulas: results of treatment with detachable balloons. *Neurosurgery* 1995;36(2):239-44; discussion 44-5.
 156. Debrun GM, Vinuela F, Fox AJ, Davis KR, Ahn HS. Indications for treatment and classification of 132 carotid-cavernous fistulas. *Neurosurgery* 1988;22(2):285-9.
 157. Desal HA, Toulgoat F, Raoul S, et al. Ehlers-Danlos syndrome type IV and recurrent carotid-cavernous fistula: review of the literature, endovascular approach, technique and difficulties. *Neuroradiology* 2005;47(4):300-4.
 158. Numaguchi Y, Higashida RT, Abernathy JM, Pisarello JC. Balloon embolization in a carotid-cavernous fistula in fibromuscular dysplasia. *Am J Neuroradiol* 1987;8(2):380-2.
 159. Kuether TA, O'Neill OR, Nesbit GM, Barnwell SL. Direct carotid cavernous fistula after trigeminal balloon microcompression gangliolysis: case report. *Neurosurgery* 1996;39(4):853-5; discussion 5-6.
 160. Barr JD, Mathis JM, Horton JA. Iatrogenic carotid-cavernous fistula occurring after embolization of a cavernous sinus meningioma. *Am J Neuroradiol* 1995;16(3):483-5.
 161. de Campos JM, Ferro MO, Burzaco JA, Boixados JR. Spontaneous carotid-cavernous fistula in osteogenesis imperfecta. *J Neurosurg* 1982;56(4):590-3.
 162. Debrun G, Lacour P, Vinuela F, Fox A, Drake CG, Caron JP. Treatment of 54 traumatic carotid-cavernous fistulas. *J Neurosurg* 1981;55(5):678-92.
 163. Higashida RT, Halbach VV, Tsai FY, et al. Interventional neurovascular treatment of traumatic carotid and vertebral artery lesions: results in 234 cases. *Am J Roentgenol* 1989;153(3):577-82.
 164. Halbach VV, Hieshima GB, Higashida RT, Reicher M. Carotid cavernous fistulae: indications for urgent treatment. *Am J Roentgenol* 1987;149(3):587-93.
 165. Dandy WE, Follis RH. On the pathology of carotid-cavernous aneurysms (pulsating exophthalmos). *Am J Ophthalmol* 1941;24:365-85.
 166. Sugar HS, Meyer SJ. Pulsating exophthalmos. *Arch Ophthalmol* 1940;64:1288-321.
 167. Kapur A, Sanghavi NG, Parikh NK, Amin SK. Spontaneous carotid-cavernous fistula with ophthalmoplegia and facial palsy. *Postgrad Med J* 1982;58(686):773-5.
 168. Vattoth S, Cherian J, Pandey T. Magnetic resonance angiographic demonstration of carotid-cavernous fistula using elliptical centric time resolved imaging of contrast kinetics (EC-TRICKS). *Magn Reson Imaging* 2007;25(8):1227-31.
 169. Mehinger CM, Hieshima GB, Grinnell VS, Tsai F, Pribram HF. Improved localization of carotid cavernous fistula during angiography. *Am J Neuroradiol* 1982;3(1):82-4.
 170. Huber P. A technical contribution of the exact angiographic localization of carotid cavernous fistulas. *Neuroradiology* 1976;10(5):239-41.
 171. Goto K, Hieshima GB, Higashida RT, et al. Treatment of direct carotid cavernous sinus fistulae. Various therapeutic approaches and results in 148 cases. *Acta Radiol Suppl* 1986;369:576-9.
 172. Luo CB, Teng MMH, Chang FC, Chang CY. Transarterial balloon-assisted n-butyl-2-cyanoacrylate embolization of direct carotid cavernous fistulas. *Am J Neuroradiol* 2006;27(7):1535-40.
 173. van Rooij WJ, Sluzewski M, Beute GN. Ruptured cavernous sinus aneurysms causing carotid cavernous fistula: incidence, clinical presentation, treatment, and outcome. *Am J Neuroradiol* 2006;27(1):185-9.

174. Nesbit GM, Barnwell SL. The use of electrolytically detachable coils in treating high-flow arteriovenous fistulas. *Am J Neuroradiol* 1998;19(8):1565-9.
175. Jansen O, Dorfler A, Forsting M, et al. Endovascular therapy of arteriovenous fistulae with electrolytically detachable coils. *Neuroradiology* 1999;41(12):951-7.
176. Debrun GM, Ausman JI, Charbel FT, Aletich VA. Access to the cavernous sinus through the vertebral artery: technical case report. *Neurosurgery* 1995;37(1):144-6; discussion 6-7.
177. Moron FE, Klucznik RP, Mawad ME, Strother CM. Endovascular treatment of high-flow carotid cavernous fistulas by stent-assisted coil placement. *Am J Neuroradiol* 2005;26(6):1399-404.
178. Kocer N, Kizilkilic O, Albayram S, Adaletli I, Kantarci F, Islak C. Treatment of iatrogenic internal carotid artery laceration and carotid cavernous fistula with endovascular stent-graft placement. *Am J Neuroradiol* 2002;23(3):442-6.
179. Archondakis E, Pero G, Valvassori L, Boccardi E, Scialfa G. Angiographic follow-up of traumatic carotid cavernous fistulas treated with endovascular stent graft placement. *Am J Neuroradiol* 2007;28(2):342-7.
180. Gomez F, Escobar W, Gomez AM, Gomez JF, Anaya CA. Treatment of carotid cavernous fistulas using covered stents: midterm results in seven patients. *Am J Neuroradiol* 2007;28(9):1762-8.
181. Beighton P, De Paepe A, Steinmann B, Tsipouras P, Wenstrup RJ. Ehlers-Danlos syndromes: revised nosology, Villefranche, 1997. Ehlers-Danlos National Foundation (USA) and Ehlers-Danlos Support Group (UK). *Am J Med Genet* 1998;77(1):31-7.
182. Pepin M, Schwarze U, Superti-Furga A, Byers PH. Clinical and genetic features of Ehlers-Danlos syndrome type IV, the vascular type. *N Engl J Med* 2000;342(10):673-80.
183. Mitsuhashi T, Miyajima M, Saitoh R, Nakao Y, Hishii M, Arai H. Spontaneous carotid-cavernous fistula in a patient with Ehlers-Danlos syndrome type IV - case report. *Neurol Med Chir (Tokyo)* 2004;44(10):548-53.
184. Halbach VV, Higashida RT, Dowd CF, Barnwell SL, Hieshima GB. Treatment of carotid-cavernous fistulas associated with Ehlers-Danlos syndrome. *Neurosurgery* 1990;26(6):1021-7.
185. Horowitz MB, Purdy PD, Valentine RJ, Morrill K. Remote vascular catastrophes after neurovascular interventional therapy for type 4 Ehlers-Danlos Syndrome. *Am J Neuroradiol* 2000;21(5):974-6.
186. Schievink WL, Piepgras DG, Earnest Ft, Gordon H. Spontaneous carotid-cavernous fistulae in Ehlers-Danlos syndrome Type IV. Case report. *J Neurosurg* 1991;74(6):991-8.

16. Cavernous Malformations and Venous Angiomas

16.1. Cavernous malformations

Cavernous malformations (aka cerebral cavernous malformations, cavernous angiomas, cavernomas, cavernous hemangiomas, cryptic vascular malformations or angiographically occult vascular malformations) are distinctive cerebrovascular abnormalities. They may appear throughout and around the central nervous system, including the brain, spinal cord, cranial nerves, ventricles and orbit.^{1,2} Overall, cavernous malformations are thought to account for some 10% of all cerebrovascular malformations. Cavernous malformations occur in two forms: *sporadic* and *familial*. In the sporadic form, the patient usually has only one lesion and there is no family history of the disorder. The familial form is characterized by multiple lesions and a family history of seizures.

16.1.1. Angioma Alliance

The Angioma Alliance is a non-profit organization that has established a DNA/Tissue Bank and Patient Registry for the use of researchers investigating cerebral and spinal cavernous malformations: <http://www.angiomaalliance.org>. Email: Biobank@AngiomaAlliance.org.

16.1.2. Epidemiology and risk factors

1. Prevalence
 - (a) The prevalence of cavernomas in the general population appears to be about 0.5%
 - Large autopsy series: frequency of cavernomas was 0.5%³
 - Frequency of cavernomas on brain MRI: 0.4–0.5%^{4,5}
 2. Multiple in 50% of cases⁶
 3. Sex prevalence is equal^{5,7,8}
 4. Risk factors
 - (a) Family history (see below)
 - (b) Cranial irradiation
 - Radiation treatment is an established risk factor for the de novo formation of cavernous malformations
 - A review of published reports of radiation-associated cavernomas found⁹:
 - Most cases are in children (mean age, 11.7 years) although adult cases have been reported.
 - Majority of lesions occurred in males.
 - Mean radiation dose: 60.45 Gy.
 - Mean latency period before detection of the cavernoma: 8.9 years.
 - Most common presenting symptom was seizures.
 - Most common reason for radiation treatment, in order of frequency:
 - (a) Medulloblastoma
 - (b) Glioma
 - (c) Acute lymphoblastic lymphoma

16.1.3. Pathophysiology

Cavernous malformations are well circumscribed, lobulated lesions, varying from <1 mm to 9 cm in diameter.¹⁰

1. Cavernous malformations consist of dilated, thin-walled vascular structures (caverns) with an endothelial lining and a variable layer of fibrous adventitia. Elastic fibers have been reported¹¹ but are usually absent. Extensive hemosiderin deposits, indicating previous hemorrhage and thrombosis may be present.¹² Calcification is present in 11–40% of cases.^{11,13}
2. Gross appearance resembles a mulberry.
3. Ultrastructural analysis has demonstrated defects in the tight junctions between endothelial cells that form the blood–brain barrier, which may account for leakage of blood elements into the surrounding brain.^{14,15}
4. Cavernoma growth appears to occur by a process of cavern proliferation in the setting of repeated lesional hemorrhages and brittle vascular morphology devoid of mature vessel wall elements.^{16–18}
5. *Association with venous angiomas* (see below for a discussion of venous angiomas)
 - (a) Percentage of patients with a cavernoma who also have an associated venous angioma on MRI: approximately 25%.^{19,20}
 - MRI may underestimate the prevalence of associated venous angiomas. In a surgical series of 86 patients undergoing resection of brainstem cavernomas, an associated venous angioma was found in all cases.²¹
 - Some authors believe that all cavernomas are associated with a venous angioma, whether or not the venous angioma is visible on imaging or not.²²
 - (b) Percentage of patients with a venous angioma on MRI who also have an associated cavernous malformation: 18%.²³
 - (c) Direct connections between venous angiomas and cavernous malformations have been found.^{24,25}
 - Abnormal hemodynamics within venous angiomas may lead to the formation of cavernous malformations.^{26–29}
 - Local venous hypertension within a venous angioma may lead to a reactive process called *hemorrhagic angiogenic proliferation*, contributing to the formation of a cavernous malformation.²⁶
 - The occurrence of de novo cavernous malformations after radiation therapy further supports this hypothesis, as vessel changes after radiation therapy occur mostly on the venous side and simulate the histological findings of venous angiomas.²⁹

16.1.4. Familial form

1. Definition of familial cavernous malformation: one or several lesions in at least two members of a family.^{30,31}
 - (a) The presence of three or more lesions is “almost pathognomonic” for the familial form.³²
2. Familial cases comprise 6–50% of all cavernous malformation cases.^{3,6,33,34}
3. Hispanic patients of Mexican descent appear to have the highest incidence of familial cavernomas, although familial forms have been identified in almost every other ethnic group.
4. Familial form patients are most likely to have multiple lesions and the number of lesions increases with age.^{31,35}
 - (a) Multiple lesions are found in 50–84% of familial form patients.^{30,33,36}
 - (b) The number of lesions per patient depends on the MRI technique (gradient echo imaging has the greatest sensitivity, see below).
 - Mean number of lesions detected by gradient echo was 20.2 in symptomatic patients and 16.3 in asymptomatic subjects.³¹
5. Familial form lesions are *not* usually associated with a venous angioma.
6. Some 40% of patients with the familial form remain asymptomatic despite the presence of multiple lesions.³⁰

16.1.4.1. Genetics

1. Three genes for cerebral cavernous malformations (CCM) have been identified:
 - (a) *CCM1* on chromosome 7q.^{37–39}
 - The *CCM1* gene is also known as *KRIT1*, which is thought to be involved in arterial development.⁴⁰
 - Mutation of the *CCM1* gene is responsible for nearly all inherited cavernomas among the Hispanic population of the United States.^{41,42}
 - (b) *CCM2* on chromosome 7p.⁴³
 - (c) *CCM3* on chromosome 3q.⁴³
2. No differences in clinical presentation have been found for the three different loci.⁴⁰

16.1.5. Imaging

1. MRI
 - (a) MRI is the radiographic technique of choice for the identification and follow-up, being more accurate than both CT and angiography in the detection of cavernous malformations.³³
 - (b) Characteristic MRI findings:
 - Both T2 and T1-weighted images typically show discrete areas of mixed signal intensity surrounded by a black rim of diminished signal intensity (looks like *popcorn*). Or, when the lesion is small, a discrete “black dot.”
 - *Gradient echo* sequences demonstrate cavernous malformations with greater sensitivity than T1 or T2 images.^{44–47}
 - Gradient echo shows hemosiderin staining the best.
 - An associated venous angioma is present on MRI in about 25% of sporadic cases,^{19,20} but is not usually seen in familial cases.
 - Zabramski and colleagues described four categories of lesions in patients with the familial form based on MRI findings³⁰:
 - *Type I*. Subacute hemorrhage surrounded by a rim of hemosiderin-stained macrophages and gliotic brain.
 - (a) T1: Hyperintense core.
 - (b) T2: Hyper- or hypointense core with surrounding hypointense rim.
 - *Type II*. Loculated areas of hemorrhage and thrombosis of varying age, surrounded by gliotic, hemosiderin-stained brain. Most common finding in patients with cavernomas.⁴
 - (a) T1: Reticulated mixed signal core.
 - (b) T2: Reticulated mixed signal core with surrounding hypointense rim.
 - *Type III*. Chronic, resolved hemorrhage with hemosiderin within and around the lesion. Therefore, findings on T2-weighted SE sequences are hypointense, with greater magnification on T2-weighted GE sequences, whereas T1-weighted SE sequences exhibit hypointense to isointense signals.
 - (a) T1: Iso- or hypointense.
 - (b) T2: Hypointense with a hypointense rim.
 - (c) Gradient echo: Hypointense.
 - *Type IV*. Very small lesions or “telangiectasias.”
 - (a) T1: Poorly seen or not visualized at all.
 - (b) T2: Poorly seen or not visualized at all.
 - (c) Gradient echo: Punctate hypointense lesions.
 - (c) If the diagnosis is uncertain, the presence of an associated venous angioma can help confirm that the lesion is a cavernous malformation.
 - (d) Other lesions may have an appearance on MRI that is similar to cavernomas¹⁰: AVMs, calcified neoplasms (e.g., oligodendrogliomas), infectious, inflammatory and granulomatous lesions, hemorrhagic tumors and tumors containing melanin or fat.

2. CT
 - (a) Focal area of increased density, with or without enhancement.
 - (b) Calcifications are present in 40% of cases.⁴⁸
3. Angiography
 - (a) Cavernomas are usually “angio-occult,” although venous pooling may be seen in rare cases.³³

16.1.6. Presentation and clinical features

1. Age at presentation
 - (a) Most patients present in the third and fifth decades of life.^{4,13,30,49}
 - (b) Mean age at presentation in one series was 37.6 years.⁴
 - (c) Some 25% of patients are <18 years of age.^{5,50}
 - Age at presentation for pediatric patients has a bimodal pattern with peaks at 3 and 11 years of age.⁵¹
2. The most common presenting symptom of cavernous malformations is seizures, occurring in up to 55% of patients.^{4,5,11,33,34,52}
3. Focal neurological deficits are present in 12–45% of patients at presentation.^{4,5,33,52,53}
4. Headache may be the only “manifestation” of the lesion in some 25% of patients diagnosed with a cavernoma.⁵² A history of chronic headaches is present in 3–52% of patients.^{4,5,30,31,52}
5. The clinical manifestations of cavernomas are similar in both the sporadic and familial forms.⁴⁶
6. Pregnancy and cavernomas.
 - (a) An increase in cavernoma size occurs during pregnancy.^{7,54,55}
 - (b) Anecdotal evidence suggests that pregnancy is associated with the de novo appearance of new lesions,^{5,56,57} and may increase the risk of hemorrhage from cavernomas.^{5,44,54,56,58,59}
 - (c) Hormonal stimulation has been hypothesized to have a role in cavernoma growth and hemorrhage.^{5,21,53,56,58}
 - (d) Resection of asymptomatic lesions may be a reasonable option in patients anticipating pregnancy.

16.1.7. Natural history

1. Cavernomas are dynamic lesions and may demonstrate spontaneous enlargement, regression and de novo formation.⁶⁰
 - (a) In a prospective MRI volumetric study of patients with cavernous malformations, over a 24-month period, 43% of lesions increased in volume, 35% decreased in volume and 22% remained stable.⁶⁰
 - (b) Another prospective study found that the average lesion size decreased by 9.1 mm over mean follow-up period of 16.2 months.⁶¹
2. Annual symptomatic hemorrhage risk may depend on whether the patient has a previous history of symptomatic hemorrhage;
 - (a) Annual risk of hemorrhage *without* a prior symptomatic hemorrhage: ~ 0.5%.^{4,5,58,62}
 - (b) Annual risk of hemorrhage *with* a prior symptomatic hemorrhage: ~ 4.5%.^{44,62}
 - A retrospective Japanese series found an annual hemorrhage rate for patients with a prior hemorrhage of 22.9%.⁵⁸
 - (c) However, another prospective natural history study for an annual hemorrhage rate of 3.1%, with no difference between patients with or without a previous symptomatic hemorrhage
3. Symptomatic hemorrhage
 - (a) Risk factors for symptomatic hemorrhage:
 - Previous hemorrhage.⁶²
 - Female sex.^{5,34,58}
 - An associated venous angioma.^{19,20}
 - (b) Lesion location does not appear to affect the risk of symptomatic hemorrhage.⁶²

16.1.8. Management

16.1.8.1. Asymptomatic cavernous malformations

Asymptomatic lesions are frequently discovered as incidental findings on imaging or in association with another symptomatic lesion. Patients with asymptomatic lesions, or a vague complaint such as headaches, can be reassured that the expected natural history is likely to be relatively benign and do not necessarily require treatment.² Surveillance imaging is an option. Alternatively, resection of a surgically accessible asymptomatic lesion may be reasonable if the patient is a good surgical candidate, is relatively young, female, anticipating pregnancy, or has a family history of symptomatic cavernous malformations.^{10,63}

16.1.8.2. Seizures associated with a cavernous malformation

1. Cerebral cavernous malformations are known to be more epileptogenic than other cerebrovascular lesions, presumably because of the deposition of ferric ions resulting from repeated microhemorrhages within and around the lesions.⁶⁴
 - (a) Lesion locations at highest risk for seizures are the cerebral cortex and temporal, frontal and perilimbic sites.⁶⁵
 - (b) Cavernomas are nearly twice as likely to be associated with seizures compared to other lesions, such as AVMs and tumors, in similar locations.¹⁰
2. The annual risk of developing seizures is 0.4–1.51%.^{4,58}
3. The need for treatment with anticonvulsant medications is obvious in patients presenting with a first seizure. Although some authors recommend medical therapy as the first-line treatment for patients with seizures attributable to a cavernoma,⁶⁵ resection of a cavernoma for treatment of epilepsy can be advantageous for the following reasons:
 - (a) Long-term anticonvulsant therapy carries a cost in terms of side effects, medication expense and possible effects on neuronal plasticity.
 - (b) There is a hypothesis that resection of an epileptic lesion before repeated seizures occur and “kindling” develops, may better prevent future seizures.
 - (c) Surgery is usually indicated for patients with medically refractory seizures.
4. A complete seizure work-up, including EEG monitoring, is necessary in all patients anticipating resection of a cavernoma for treatment of a seizure disorder.
 - (a) A cavernoma seen on imaging is *not* a cause of seizures in some 6% of patients with a cavernoma and epilepsy.⁶⁶
5. Surgical results: About 60–80% of patients are seizure-free after lesion resection, with or without anticonvulsant medications.^{67,68}
 - (a) Seizure outcome after resection of cavernous malformations is better when surrounding hemosiderin-stained brain also is removed.⁶⁹
 - (b) Predictors for good seizure outcome are age >30 years at the time of surgery, mesiotemporal lesion localization, cavernoma size <1.5 cm and the absence of secondarily generalized seizures.⁶⁸
 - (c) Seizure control may be better if resection of epileptogenic cortex is combined with resection of the underlying lesion. A systematic review comparing lesionectomy with the combined procedure found that at 2-year follow-up, patients having the combined surgery were significantly less likely to have persistent seizures.⁷⁰

16.1.8.3. Symptomatic hemorrhagic cavernous malformations

1. *Definition of symptomatic hemorrhagic cavernous malformation:* Clinical history of *apoplectic hemorrhage* or neurologic symptoms attributable to a cerebral mass lesion, with evidence of *extralesional hemorrhage* on imaging.^{10,63}
2. Similar to the situation in patients with multiple intracranial aneurysms and subarachnoid hemorrhage, among patients with multiple cavernomas, the largest lesion is usually symptomatic.^{3,30}

3. Surgery should be considered for patients with symptomatic lesions in a surgically accessible location who are acceptable candidates for cranial surgery. Patients who present with a hemorrhagic lesion are at increased risk of subsequent rehemorrhage.⁶²
4. Surgical considerations.
 - (a) Frameless stereotactic guidance and intraoperative cortical mapping, if eloquent cortex is involved, can be helpful.
 - (b) Intraoperative ultrasound can also help localize a cavernoma.
 - (c) Any associated venous angioma should be spared.^{21,25,28,71}

16.1.8.4. Brainstem cavernous malformations

1. About 20% of intracranial cavernomas are located in the brainstem,³⁴ and are most commonly found in the pons, followed in frequency by the midbrain and the medulla.^{5,66,72}
2. Selection of surgical candidates. Surgery should be considered for patients that meet at least one of the following criteria²¹: (1) lesion anatomy is favorable for resection; (2) repeated hemorrhages have occurred; and/or (3) significant mass effect is produced by the hemorrhage.
 - (a) *Favorable anatomy.* Surgical resection is appropriate only for cases in which the cavernoma, or the cavernoma-associated hemorrhage, has reached the surface of the brainstem. Disruption of even 1 mm of normal brainstem tissue can cause significant morbidity.
 - T1-weighted imaging provides the most accurate indication of the relationship between the cavernoma and the surface of the brainstem. T2-weighted imaging may provide an incorrect measure of the proximity of the lesion to the pial surface due to the ferromagnetic properties of the hemosiderin ring.^{73,74}
 - 3D-constructive interference in steady-state (CISS) MRI is useful in demonstrating the thickness of the parenchymal layer over brainstem cavernomas and in clarifying spatial relationships of the lesion to nuclei, tracts, cranial nerves and vessels.⁷⁵
 - Conservative management is recommended for cavernomas or hematomas that do not reach the pial surface.^{21,73}
 - (b) *Repeated versus single hemorrhage.* Traditionally, surgery on brainstem cavernomas has been recommended for patients having had at least two symptomatic hemorrhages. Some recent reports, however, have advocated surgery after only one hemorrhage, if the anatomy is favorable.^{73,76,77} Another recent report did not find a relationship between timing of surgery or number of previous hemorrhages and long-term results.⁷⁸
3. Surgical considerations.
 - (a) *Timing of surgery.*
 - Surgery ≥ 3 –5 days after the hemorrhage helps to insure that the clot will be liquefied.²²
 - Some authors recommend relatively early surgery (e.g., <1 month) after hemorrhage, attributing better outcomes with early surgery to the advantages of operating within a clot cavity and without reactive gliosis.^{73,76,77}
 - (b) Frameless stereotactic guidance and intraoperative monitoring can be helpful.
 - (c) The optimal surgical approach can be planned in MRI images using the “two-point method.”⁷⁹ One point is placed in the center of the lesion and the second is placed where the lesion most closely reaches the pial surface. A surgical trajectory is then mapped along a straight line connecting the two points.
 - (d) Although exophytic lesions are readily apparent during surgery, intrinsic lesions can be identified by hemosiderin staining or a bulge on the surface of the brainstem.
 - (e) Great care must be taken to preserve any associated venous angioma that may be encountered.²¹
 - (f) Postoperative care.
 - The patient may be left intubated for 24 h after surgery and extubated only after adequate cough and gag reflexes are identified.²²

- Tracheostomy and feeding-tube placement may be necessary and may be removed as the patient recovers lower cranial nerve function.
 - An early postoperative MRI (<48 h) can assess for residual lesion. Imaging-incomplete resection is associated with recurrent hemorrhage.⁸⁶
4. Outcomes
- (a) A series of 86 surgically treated patients with brainstem cavernomas found²¹:
- Complications. The rate of temporary and/or permanent morbidity was 35%; permanent or severe deficits occurred in 12%. Mortality was 8%. A total of 33% had one or more new cranial nerve deficits.
 - Long-term outcome. At a mean follow-up of 35 months, 87% of patients reported that they were better or the same as before surgery. The average GOS score was 4.53.

16.1.8.5. Radiosurgery for cavernous malformations

Inspired by the success of radiosurgery in the treatment of brain AVMs, radiosurgery has been used for the treatment of cavernomas at several centers. A number of single-center series have been published.⁸¹⁻⁹⁶ Some reports have shown disappointing results with radiosurgery for cavernomas, particularly when compared to the natural history (with respect to hemorrhage)^{76,93} or surgery (for patients with seizures).⁸¹ Furthermore, some evidence indicates that complications after radiosurgery of some lesions, particularly brainstem cavernomas, are more significant compared to AVMs.^{93,97,98} One author who had advocated radiosurgery for brainstem cavernomas in the past later reversed his position, based on long-term complication rates.⁹⁹ In addition, a pathological analysis of cavernomas after radiosurgery did not find histological evidence of vessel occlusion.¹⁰⁰ Radiosurgery for cavernomas remains controversial, and requires further investigation before it becomes an established technique.

16.2. Venous angiomas

Venous angiomas (aka venous malformations, venous anomalies, developmental venous anomalies, medullary venous malformations or caput medusae) are a normal variant of intraparenchymal medullary veins, being larger and more visible on imaging than most medullary veins (Fig. 16.1). They are usually found in white matter and are associated with cavernous malformations.¹⁰¹ They are characterized histologically by a complex of sometimes thickened and hyalinized veins with interspersed normal neural parenchyma.¹⁰²

The most important thing to know about venous angiomas is that they are usually incidental findings on imaging and with rare exception are completely benign. When associated with a cavernous malformation, they may be erroneously identified as the source of symptoms.²⁸ They may also be confused with AVMs and other aggressive lesions by the uninitiated. The

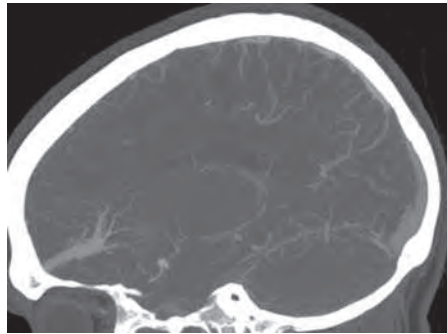


Fig. 16.1 Frontal lobe venous angioma in a sagittal CT angiogram reconstruction. It has the typical stellate network of veins converging on a single large collecting vein.

authors of this handbook wish they had a dollar for every patient referred to them with an incidental venous angioma found on imaging and misidentified as an AVM.

1. Prevalence
 - (a) Venous angiomas are found in some 2.6% of autopsies.^{53,103}
 - (b) A review of 7,266 brain MRIs found a frequency of venous angiomas of 0.7%.²³
2. Etiology
 - (a) Venous angiomas are thought to be congenital and result from a failure of normal embryogenesis.¹⁰⁴
3. Imaging
 - (a) Typical appearance on MRI and CTA: radial pattern, the so-called *caput medusa*, which converges on an enlarged central trunk.¹⁰⁵
 - (b) Seen only during the venous phase on angiography.
 - (c) About two thirds are in a supratentorial location and one third are in the cerebellum and brainstem.²³
4. Natural history and presentation
 - (a) A prospective study with 298 patient-years of observation found a symptomatic hemorrhage rate of 0.34% per year.¹⁰⁶
 - (b) Often found in close proximity to a cavernous malformation.
 - Of all patients found to have a venous angioma on MRI, 18% had an associated cavernous malformation.²³
 - In every case in which there was a hemorrhage associated with the venous angioma, a cavernoma was present.²³
 - (c) Rarely, spontaneous thrombosis of a very large venous angioma may cause venous infarction or hemorrhage.
5. Management
 - (a) Most venous angiomas are incidental findings and do not require treatment or follow-up imaging.
 - (b) During surgery for evacuation of a hemorrhage or resection of a cavernous malformation, it is critical to preserve the associated venous angioma, particularly in the brainstem.
 - (c) Removal of a venous angioma may cause a venous infarction.

16.3. References

1. Herter T, Bennefeld H, Brandt M. Orbital cavernous hemangiomas. *Neurosurg Rev* 1988;11(2):143–7.
2. Raychaudhuri R, Batjer HH, Awad IA. Intracranial cavernous angioma: a practical review of clinical and biological aspects. *Surg Neurol* 2005;63(4):319–28; discussion 28.
3. Otten P, Pizzolato GP, Rilliet B, Berney J. [131 cases of cavernous angioma (cavernomas) of the CNS, discovered by retrospective analysis of 24,535 autopsies]. *Neurochirurgie* 1989;35(2):82–3, 128–31.
4. Del Curling O, Jr., Kelly DL, Jr., Elster AD, Craven TE. An analysis of the natural history of cavernous angiomas. *J Neurosurg* 1991;75(5):702–8.
5. Robinson JR, Awad IA, Little JR. Natural history of the cavernous angioma. *J Neurosurg* 1991;75(5):709–14.
6. Rigamonti D, Drayer BP, Johnson PC, Hadley MN, Zabramski J, Spetzler RF. The MRI appearance of cavernous malformations (angiomas). *J Neurosurg* 1987;67(4):518–24.
7. Yamasaki T, Handa H, Yamashita J, et al. Intracranial and orbital cavernous angiomas. A review of 30 cases. *J Neurosurg* 1986;64(2):197–208.
8. Herter T, Brandt M, Szuwart U. Cavernous hemangiomas in children. *Childs Nerv Syst* 1988;4(3):123–7.
9. Nimjee SM, Powers CJ, Bulsara KR. Review of the literature on de novo formation of cavernous malformations of the central nervous system after radiation therapy. *Neurosurg Focus* 2006;21(1):e4.
10. Maraire JN, Awad IA. Intracranial cavernous malformations: lesion behavior and management strategies. *Neurosurgery* 1995;37(4):591–605.
11. Simard JM, Garcia-Bengochea F, Ballinger WE, Jr., Mickle JP, Quisling RG. Cavernous angioma: a review of 126 collected and 12 new clinical cases. *Neurosurgery* 1986;18(2):162–72.
12. Zabramski JM, Henn JS, Coons S. Pathology of cerebral vascular malformations. *Neurosurg Clin N Am* 1999;10(3):395–410.
13. Voigt K, Yasargil MG. Cerebral cavernous haemangiomas or cavernomas. Incidence, pathology, localization, diagnosis, clinical features and treatment. Review of the literature and report of an unusual case. *Neurochirurgia (Stuttg)* 1976;19(2):59–68.
14. Wong JH, Awad IA, Kim JH. Ultrastructural pathological features of cerebrovascular malformations: a preliminary report. *Neurosurgery* 2000;46(6):1454–9.
15. Clatterbuck RE, Eberhart CG, Crain BJ, Rigamonti D. Ultrastructural and immunocytochemical evidence that an incompetent blood-brain barrier is related to the pathophysiology of cavernous malformations. *J Neurol Neurosurg Psychiatry* 2001;71(2):188–92.
16. Gault J, Sarin H, Awadallah NA, Shenkar R, Awad IA. Pathobiology of human cerebrovascular malformations: basic mechanisms and clinical relevance. *Neurosurgery* 2004;55(1):1–16; discussion 7.
17. Robinson JR, Jr., Awad IA, Masaryk TJ, Estes ML. Pathological heterogeneity of angiographically occult vascular malformations of the brain. *Neurosurgery* 1993;33(4):547–54; discussion 54–5.
18. Rothbart D, Awad IA, Lee J, Kim J, Harbaugh R, Criscuolo GR. Expression of angiogenic factors and structural proteins in central nervous system vascular malformations. *Neurosurgery* 1996;38(5):915–24; discussion 24–5.
19. Abdulrauf SI, Kaynar MY, Awad IA. A comparison of the clinical profile of cavernous malformations with and without associated venous malformations. *Neurosurgery* 1999;44(1):41–6; discussion 6–7.

20. Wurm G, Schnizer M, Fellner FA. Cerebral cavernous malformations associated with venous anomalies: surgical considerations. *Neurosurgery* 2005;57(1 Suppl):42-58; discussion 42-58.
21. Porter RW, Detwiler PW, Spetzler RF, et al. Cavernous malformations of the brainstem: experience with 100 patients. *J Neurosurg* 1999;90(1):50-8.
22. Porter RW, Detwiler PW, Spetzler RF. Infratentorial Cavernous Malformations. In: Winn HR, ed. *Youmans Neurological Surgery*. Philadelphia: Saunders; 2004:2321-39.
23. Topper R, Jurgens E, Reul J, Thron A. Clinical significance of intracranial developmental venous anomalies. *J Neurol Neurosurg Psychiatry* 1999;67(2):234-8.
24. Little JR, Awad IA, Jones SC, Ebrahim ZY. Vascular pressures and cortical blood flow in cavernous angioma of the brain. *J Neurosurg* 1990;73(4):555-9.
25. Sasaki O, Tanaka R, Koike T, Koide A, Koizumi T, Ogawa H. Excision of cavernous angioma with preservation of coexisting venous angioma. Case report. *J Neurosurg* 1991;75(3):461-4.
26. Awad IA, Robinson JR, Jr, Mohanty S, Estes ML. Mixed vascular malformations of the brain: clinical and pathogenetic considerations. *Neurosurgery* 1993;33(2):179-88; discussion 88.
27. Cricillo SF, Dillon WP, Fink ME, Edwards MS. Progression of multiple cryptic vascular malformations associated with anomalous venous drainage. Case report. *J Neurosurg* 1994;81(3):477-81.
28. Rigamonti D, Spetzler RF, Medina M, Rigamonti K, Geckle DS, Pappas C. Cerebral venous malformations. *J Neurosurg* 1990;73(4):560-4.
29. Perrini F, Lanzino G. The association of venous developmental anomalies and cavernous malformations: pathophysiological, diagnostic, and surgical considerations. *Neurosurg Focus* 2006;21(1):e5.
30. Zabramski JM, Wascher TM, Spetzler RF, et al. The natural history of familial cavernous malformations: results of an ongoing study. *J Neurosurg* 1994;80(3):422-32.
31. Brunereau L, Labauge P, Tournier-Lasserre E, Laberge S, Levy C, Houtteville J-P. Familial form of intracranial cavernous angioma: MR imaging findings in 51 families. *Radiology* 2000;214(1):209-16.
32. Johnson EW, Marchuk DA, Zabramski JM. The Genetics of Cerebral Cavernous Malformations. In: Winn HR, ed. *Youmans Neurological Surgery*. Philadelphia: Saunders; 2004:2299-304.
33. Rigamonti D, Hadley MN, Drayer BP, et al. Cerebral cavernous malformations. Incidence and familial occurrence. *N Engl J Med* 1988;319(6):343-7.
34. Moriarty JL, Wetzel M, Clatterback RE, et al. The natural history of cavernous malformations: a prospective study of 68 patients. *Neurosurgery* 1999;44(6):1166-71; discussion 72-3.
35. Kattapong VI, Hart BL, Davis LE. Familial cerebral cavernous angiomas: clinical and radiologic studies. *Neurology* 1995;45(3 Pt 1):492-7.
36. Dobyns WB, Michels VV, Groover RV, et al. Familial cavernous malformations of the central nervous system and retina. *Ann Neurol* 1987;21(6):578-83.
37. Marchuk DA, Gallione CJ, Morrison LA, et al. A locus for cerebral cavernous malformations maps to chromosome 7q in two families. *Genomics* 1995;28(2):311-4.
38. Gunel M, Awad IA, Anson J, Lifton RP. Mapping a gene causing cerebral cavernous malformation to 7q11.2-q21. *Proc Natl Acad Sci U S A* 1995;92(14):6620-4.
39. Dubovsky J, Zabramski JM, Kurth J, et al. A gene responsible for cavernous malformations of the brain maps to chromosome 7q. *Hum Mol Genet* 1995;4(3):453-8.
40. Plummer NW, Zawistowski JS, Marchuk DA. Genetics of cerebral cavernous malformations. *Curr Neurol Neurosci Rep* 2005;5(5):391-6.
41. Johnson EW, Iyer LM, Rich SS, et al. Refined localization of the cerebral cavernous malformation gene (CCM1) to a 4-cM interval of chromosome 7q contained in a well-defined YAC contig. *Genome Res* 1995;5(4):368-80.
42. Gunel M, Awad IA, Finberg K, et al. A founder mutation as a cause of cerebral cavernous malformation in Hispanic Americans. *N Engl J Med* 1996;334(15):946-51.
43. Craig HD, Gunel M, Cepeda O, et al. Multilocus linkage identifies two new loci for a mendelian form of stroke, cerebral cavernous malformation, at 7p15-13 and 3q25.2-27. *Hum Mol Genet* 1998;7(12):1851-8.
44. Porter PJ, Willinsky RA, Harper W, Wallace MC. Cerebral cavernous malformations: natural history and prognosis after clinical deterioration with or without hemorrhage. *J Neurosurg* 1997;87(2):190-7.
45. Labauge P, Laberge S, Brunereau L, Levy C, Tournier-Lasserre E. Hereditary cerebral cavernous angiomas: clinical and genetic features in 57 French families. *Societe Francaise de Neurochirurgie. Lancet* 1998;352(9144):1892-7.
46. Brunereau L, Leveque C, Bertrand P, et al. Familial form of cerebral cavernous malformations: evaluation of gradient-spin-echo (GRASE) imaging in lesion detection and characterization at 1.5 T. *Neuroradiology* 2001;43(11):973-9.
47. Lehnardt F-G, von Smekal U, Ruckriem B, et al. Value of gradient-echo magnetic resonance imaging in the diagnosis of familial cerebral cavernous malformation. *Arch Neurol* 2005;62(4):653-8.
48. Houtteville JP. Brain cavernoma: a dynamic lesion. *Surg Neurol* 1997;48(6):610-4.
49. Vaquero J, Leunda G, Martinez R, Bravo G. Cavernomas of the brain. *Neurosurgery* 1983;12(2):208-10.
50. Scott RM, Barnes P, Kupsky W, Adelman LS. Cavernous angiomas of the central nervous system in children. *J Neurosurg* 1992;76(1):38-46.
51. Edwards M, Baumgartner J, Wilson C. Cavernous and Other Cryptic Vascular Malformations in the Pediatric Age Group. In: Awad IA, Barrow DL, eds. *Cavernous Malformations*. Park Ridge, IL: AANS; 1993:163-83.
52. Giombini S, Morello G. Cavernous angiomas of the brain. Account of fourteen personal cases and review of the literature. *Acta Neurochir (Wien)* 1978;40(1-2):61-82.
53. McCormick WF, Hardman JM, Boulter TR. Vascular malformations ("angiomas") of the brain, with special reference to those occurring in the posterior fossa. *J Neurosurg* 1968;28(3):241-51.
54. Katayama Y, Tsubokawa T, Maeda T, Yamamoto T. Surgical management of cavernous malformations of the third ventricle. *J Neurosurg* 1994;80(1):64-72.
55. Zauberman H, Feinsod M. Orbital hemangioma growth during pregnancy. *Acta Ophthalmol (Copenh)* 1970;48(5):929-33.
56. Pozzati E, Acciarri N, Tognetti F, Marliani F, Giangaspero F. Growth, subsequent bleeding, and de novo appearance of cerebral cavernous angiomas. *Neurosurgery* 1996;38(4):662-9; discussion 9-70.
57. Awada A, Watson T, Obeid T. Cavernous angioma presenting as pregnancy-related seizures. *Epilepsia* 1997;38(7):844-6.
58. Aiba T, Tanaka R, Koike T, Kameyama S, Takeda N, Komata T. Natural history of intracranial cavernous malformations. *J Neurosurg* 1995;83(1):56-9.
59. Flemming KD, Goodman BP, Meyer FB. Successful brainstem cavernous malformation resection after repeated hemorrhages during pregnancy. *Surg Neurol* 2003;60(6):545-7; discussion 7-8.
60. Clatterback RE, Moriarty JL, Elmaci I, Lee RR, Breiter SN, Rigamonti D. Dynamic nature of cavernous malformations: a prospective magnetic resonance imaging study with volumetric analysis. *J Neurosurg* 2000;93(6):981-6.
61. Kim D-S, Park Y-G, Choi J-U, Chung S-S, Lee K-C. An analysis of the natural history of cavernous malformations. *Surg Neurol* 1997;48(1):9-17.
62. Kondziolka D, Lunsford LD, Kestle JR. The natural history of cerebral cavernous malformations. *J Neurosurg* 1995;83(5):820-4.
63. Vives KP, Gunel M, Awad IA. Surgical Management of Supratentorial Cavernous Malformations. In: Winn HR, ed. *Youmans Neurological Surgery*. Philadelphia: Saunders; 2004:2305-19.
64. Willmore LJ, Triggs WJ, Gray JD. The role of iron-induced hippocampal peroxidation in acute epileptogenesis. *Brain Res* 1986;382(2):422-6.
65. Awad I, Jabbar P. Cerebral cavernous malformations and epilepsy. *Neurosurg Focus* 2006;21(1):e7.
66. Requena I, Arias M, Lopez-Ibor L, et al. Cavernomas of the central nervous system: clinical and neuroimaging

- manifestations in 47 patients. *J Neurol Neurosurg Psychiatry* 1991;54(7):590-4.
67. Noto S, Fujii M, Akimura T, et al. Management of patients with cavernous angiomas presenting epileptic seizures. *Surg Neurol* 2005;64(6):495-8.
 68. Baumann CR, Acciarri N, Bertalanffy H, et al. Seizure outcome after resection of supratentorial cavernous malformations: a study of 168 patients. *Epilepsia* 2007;48(3):559-63.
 69. Baumann CR, Schuknecht B, Lo Russo G, et al. Seizure outcome after resection of cavernous malformations is better when surrounding hemosiderin-stained brain also is removed. *Epilepsia* 2006;47(3):563-6.
 70. Weber JP, Silbergeld DL, Winn HR. Surgical resection of epileptogenic cortex associated with structural lesions. *Neurosurg Clin N Am* 1993;4(2):327-36.
 71. Rigamonti D, Spetzler RF. The association of venous and cavernous malformations. Report of four cases and discussion of the pathophysiological, diagnostic, and therapeutic implications. *Acta Neurochir (Wien)* 1988;92(1-4):100-5.
 72. Lobato RD, Perez C, Rivas JJ, Cordobes F. Clinical, radiological, and pathological spectrum of angiographically occult intracranial vascular malformations. Analysis of 21 cases and review of the literature. *J Neurosurg* 1988;68(4):518-31.
 73. Bruneau M, Bijlenga P, Reverdin A, et al. Early surgery for brainstem cavernomas. *Acta Neurochir (Wien)* 2006;148(4):405-14.
 74. Ferroli P, Sinisi M, Franzini A, Giombini S, Solero CL, Broggi G. Brainstem cavernomas: long-term results of microsurgical resection in 52 patients. *Neurosurgery* 2005;56(6):1203-12; discussion 12-4.
 75. Zausinger S, Yousry I, Brueckmann H, Schmid-Elsaesser R, Tonn JC. Cavernous malformations of the brainstem: three-dimensional-constructive interference in steady-state magnetic resonance imaging for improvement of surgical approach and clinical results. *Neurosurgery* 2006;58(2):322-30; discussion 30.
 76. Mathiesen T, Edner G, Kihlstrom L. Deep and brainstem cavernomas: a consecutive 8-year series. *J Neurosurg* 2003;99(1):31-7.
 77. Wang C-C, Liu A, Zhang J-T, Sun B, Zhao Y-L. Surgical management of brain-stem cavernous malformations: report of 137 cases. *Surg Neurol* 2003;59(6):444-54.
 78. Samii M, Eghbal R, Carvalho GA, Matthies C. Surgical management of brainstem cavernomas. *J Neurosurg* 2001;95(5):825-32.
 79. Brown AP, Thompson BG, Spetzler RF. The two-point method: evaluating brain stem lesions. *BNI Q* 1996;12:20-4.
 80. Kikuta K, Nozaki K, Takahashi JA, Miyamoto S, Kikuchi H, Hashimoto N. Postoperative evaluation of microsurgical resection for cavernous malformations of the brainstem. *J Neurosurg* 2004;101(4):607-12.
 81. Shih YH, Pan DH. Management of supratentorial cavernous malformations: craniotomy versus gammaknife radiosurgery. *Clin Neurol Neurosurg* 2005;107(2):108-12.
 82. Yoon PH, Kim DI, Jeon P, Ryu YH, Hwang GI, Park SJ. Cerebral cavernous malformations: serial magnetic resonance imaging findings in patients with and without gamma knife surgery. *Neurol Med Chir (Tokyo)* 1998;38 Suppl:255-61.
 83. Kida Y, Kobayashi T, Mori Y. Radiosurgery of angiographically occult vascular malformations. *Neurosurg Clin N Am* 1999;10(2):291-303.
 84. Seo Y, Fukuoka S, Takanashi M, et al. Gamma knife surgery for angiographically occult vascular malformations. *Stereotact Funct Neurosurg* 1995;64 Suppl 1:98-109.
 85. Kida Y, Kobayashi T, Tanaka T. Treatment of symptomatic AOVMS with radiosurgery. *Acta Neurochir Suppl* 1995;63:68-72.
 86. Alexander E, III, Loeffler JS. Radiosurgery for intracranial vascular malformations: techniques, results, and complications. *Clin Neurosurg* 1992;39:273-91.
 87. Huang Y-C, Tseng C-K, Chang C-N, Wei K-C, Liao C-C, Hsu P-W. LINAC radiosurgery for intracranial cavernous malformation: 10-year experience. *Clin Neurol Neurosurg* 2006;108(8):750-6.
 88. Liscak R, Vladyka V, Simonova G, Vymazal J, Novotny J, Jr. Gamma knife surgery of brain cavernous hemangiomas. *J Neurosurg* 2005;102 Suppl:207-13.
 89. Kim MS, Pyo SY, Jeong YG, Lee SI, Jung YT, Sim JH. Gamma knife surgery for intracranial cavernous hemangioma. *J Neurosurg* 2005;102 Suppl:102-6.
 90. Liu KD, Chung WY, Wu HM, et al. Gamma knife surgery for cavernous hemangiomas: an analysis of 125 patients. *J Neurosurg* 2005;102 Suppl:81-6.
 91. Hasegawa T, McInerney J, Kondziolka D, Lee JY, Flickinger JC, Lunsford LD. Long-term results after stereotactic radiosurgery for patients with cavernous malformations. *Neurosurgery* 2002;50(6):1190-7; discussion 7-8.
 92. Zhang N, Pan L, Wang BJ, Wang EM, Dai JZ, Cai PW. Gamma knife radiosurgery for cavernous hemangiomas. *J Neurosurg* 2000;93 Suppl 3:74-7.
 93. Pollock BE, Garces YI, Stafford SL, Foote RL, Schomberg PJ, Link MJ. Stereotactic radiosurgery for cavernous malformations. *J Neurosurg* 2000;93(6):987-91.
 94. Regis J, Bartolomei F, Kida Y, et al. Radiosurgery for epilepsy associated with cavernous malformation: retrospective study in 49 patients. *Neurosurgery* 2000;47(5):1091-7.
 95. Mitchell P, Hodgson TJ, Seaman S, Kemeny AA, Forster DM. Stereotactic radiosurgery and the risk of haemorrhage from cavernous malformations. *Br J Neurosurg* 2000;14(2):96-100.
 96. Kondziolka D, Lunsford LD, Flickinger JC, Kestle JR. Reduction of hemorrhage risk after stereotactic radiosurgery for cavernous malformations. *J Neurosurg* 1995;83(5):825-31.
 97. Chang SD, Levy RP, Adler JR, Jr, Martin DP, Krakovitz PR, Steinberg GK. Stereotactic radiosurgery of angiographically occult vascular malformations: 14-year experience. *Neurosurgery* 1998;43(2):213-20; discussion 20-1.
 98. Amin-Hanjani S, Ogilvy CS, Candia GJ, Lyons S, Chapman PH. Stereotactic radiosurgery for cavernous malformations: Kjellberg's experience with proton beam therapy in 98 cases at the Harvard Cyclotron. *Neurosurgery* 1998;42(6):1229-36; discussion 36-8.
 99. Coffey RJ. Brainstem cavernomas. *J Neurosurg* 2003;99(6):1116-7; author reply 7.
 100. Gewirtz RJ, Steinberg GK, Crowley R, Levy RP. Pathological changes in surgically resected angiographically occult vascular malformations after radiation. *Neurosurgery* 1998;42(4):738-42; discussion 42-3.
 101. Roberson GH, Kase CS, Wolpow ER. Telangiectases and cavernous angiomas of the brainstem: "cryptic" vascular malformations. Report of a case. *Neuroradiology* 1974;8(2):83-9.
 102. McCormick WF. The pathology of vascular ("arteriovenous") malformations. *J Neurosurg* 1966;24(4):807-16.
 103. Sarwar M, McCormick WF. Intracerebral venous angioma. Case report and review. *Arch Neurol* 1978;35(5):323-5.
 104. Awad IA, Spetzler RF, Hodak JA, Awad CA, Carey R. Incidental subcortical lesions identified on magnetic resonance imaging in the elderly. I. Correlation with age and cerebrovascular risk factors. *Stroke* 1986;17(6):1084-9.
 105. Rigamonti D, Spetzler RF, Drayer BP, et al. Appearance of venous malformations on magnetic resonance imaging. *J Neurosurg* 1988;69(4):535-9.
 106. McLaughlin MR, Kondziolka D, Flickinger JC, Lunsford S, Lunsford LD. The prospective natural history of cerebral venous malformations. *Neurosurgery* 1998;43(2):195-200.

17. Acute Ischemic Stroke

Agnieszka Anna Ardelt

This chapter will discuss acute ischemic stroke: mechanisms, risk factors, clinical presentation, diagnostic evaluation, and treatment other than thrombolysis, which is discussed in Chap. 9.

17.1. Acute ischemic stroke: Burden of disease

In the United States, approximately 700,000 people suffer a stroke annually, and the vast majority of strokes are ischemic in nature. Over 150,000 people with stroke die each year; only cardiac disease and cancer result in more deaths than stroke. Stroke leaves survivors with disabilities which have both personal and societal implications: 20–30% will need assistance with activities of daily living or walking, and the majority will be unable to return to work.¹

17.2. Acute ischemic stroke: Terminology and differential diagnosis of acute onset focal neurologic dysfunction

17.2.1. Terminology

1. Stroke.
 - (a) Focal (or, less frequently, global) neurologic dysfunction of *any* cause.
 - (b) Most frequent colloquial use signifies cerebral ischemia and/or hemorrhage.
 - (c) Most common use in *clinical studies* signifies cerebral ischemia, cerebral hemorrhage, and/or subarachnoid hemorrhage.
 - (d) Sometimes used colloquially to mean cerebral *infarct*.
2. Acute stroke.
 - (a) *Apoplectic* onset of focal (or, less frequently, global) neurologic dysfunction of *any* cause.
 - (b) Sometimes used synonymously with “acute ischemic stroke,” implying that the underlying cause of acute focal neurologic dysfunction is ischemic.
3. Acute ischemic stroke.
 - (a) Acute, *apoplectic* onset of focal neurologic dysfunction of *ischemic cause*, i.e., acute cerebral ischemia due to arterial blockage or narrowing and cessation or diminution of blood flow to an area of brain.
4. Cerebral infarct.
 - (a) A localized area of dead tissue, as a consequence of having been deprived of its blood supply.
 - (b) The term is usually used in reference to a pathologic specimen or radiologic imaging, where particular features suggest tissue death due to ischemia.
5. Vasculopathy.
 - (a) Generic term for disease of blood vessels, regardless of etiology.
 - If the etiology is inflammatory, the term *vasculitis* is used.
 - (b) Classification by blood vessel size (diameter).
 - Large vessel vasculopathy.

- Also referred to as *arteriopathy* if the arteries or arterioles are predominantly affected.
- If the etiology is inflammatory, the term *arteritis* may be used.
- Small vessel vasculopathy.
 - Also referred to as *angiopathy* or *microangiopathy*.
 - When referring to cerebral vasculature, terms including *penetrating vessel disease*, *lacunar disease*, *small vessel disease*, or *white matter disease* are also used.
 - If the etiology is inflammatory, the term *angitis* is used.

17.2.2. Differential diagnosis of acute onset focal neurologic dysfunction

Most patients presenting with acute stroke symptoms will be found to have cerebral ischemia or hemorrhage; however, in one study, of 350 presentations with stroke symptoms, 31% were attributable to *stroke mimics*.²

1. Acute cerebral ischemia.
 - (a) Most common etiology of focal neurologic dysfunction, especially in patients with ischemic stroke risk factors.
 - (b) Approximately 60–70% of all causes of acute focal neurologic dysfunction.
 - (c) Whether cerebral *ischemia* will result in *infarction* depends on the severity and duration of ischemia; the longer and more severe, the more likely an infarct will ensue.
2. Intracranial hemorrhage
 - (a) Approximately 10–15% of all causes of acute focal neurologic dysfunction.
 - (b) Usually readily ruled out with noncontrast head CT.
 - Isodense subdural hemorrhages may be difficult, but critical, to diagnose; administering IV tPA could have fatal consequences (Fig. 17.1).
3. Stroke mimics.
 - (a) It is important to efficiently rule out mimics when evaluating patients with acute focal neurologic deficit who present within the thrombolysis time window; noncontrast head CT and the pattern of deficit on neurologic examination are helpful in ruling in a vascular cause (see Acute Ischemic Stroke: Clinical Presentation and Patient Evaluation sections).
 - (b) Frequency of stroke mimics.

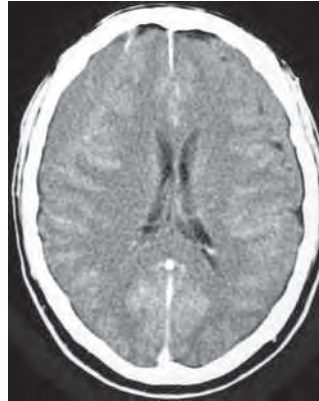


Fig. 17.1 Isodense chronic subdural hematoma. There is a chronic SDH in the *right frontal* region and a smaller one in the *left frontal* area. They blend in with the adjacent brain and are somewhat hard to see. The clinical presentation of a patient with a chronic SDH may mimic an acute ischemic stroke.

Frequency of stroke mimics in acute presentations ²	
Conditions mimicking acute stroke	Frequency (%)
Sepsis or metabolic derangement	23.8
Seizure or Todd's paralysis ^a	21.1
Syncope and presyncope	9.2
Cerebral mass lesion	9.2

(continued)

Vestibular dysfunction	6.4
Confusional state	6.4
Mononeuropathy	5.5
Functional (medically unexplained)	5.5
Dementia	3.7
Migraine	2.8
Spinal cord pathology	2.8
Other	3.6

*Transient postictal paralysis, usually resolving within 48 h

(c) Selected conditions mimicking acute strokes.

- Sepsis and metabolic derangement.
 - *Sepsis*. Unlikely to present with lateralizing signs unless in the setting of *anamnesic* symptoms (recurrent symptoms related to a chronic brain injury) or concomitant intracranial or extracranial artery stenosis resulting in focal hypoperfusion in the setting of hypotension.
 - *Blood glucose abnormalities*. Hypoglycemia (or, rarely, hyperglycemia) can present with global neurologic dysfunction including altered mental status and/or coma, as well as focal neurologic signs and symptoms including hemiplegia (*hypoglycemic hemiplegia*) and/or aphasia³; symptoms resolve quickly with the administration of dextrose; failure to make this diagnosis may lead to permanent neurologic injury.
- Seizure and/or postictal paralysis.
 - Less likely to account for focal symptoms if still present more than 6 h from symptom onset.²
 - Seizures may occur *as a result* of acute cerebral ischemia or hemorrhage: In one study, 8.6% of patients with ischemic stroke experienced first-ever seizures, and 40% of poststroke seizures occurred within 24 h of ictus⁴; in another study, 7.7% of patients presenting with acute focal neurologic dysfunction had seizure activity at the time of onset and, of those, 55% were found to have cerebral ischemia.
 - Emergent CT perfusion and angiography,⁵ MR perfusion and angiography,⁶ carotid and transcranial Doppler ultrasound, or conventional angiography may be used to rule in acute cerebrovascular cause and clarify the diagnosis in patients with acute focal neurologic deficit and seizures at onset.
 - The so-called *limb-shaking transient ischemic attacks* may be especially difficult to clinically differentiate from seizures (see “Acute Ischemic Stroke: Clinical Presentation” section).
- Syncope and presyncope.
 - Unlikely to present with true lateralizing signs, unless there is concomitant intracranial or extracranial artery stenosis resulting in focal hypoperfusion in the setting of hypotension.
 - Common reason for referrals to vascular neurologists, despite the fact that cerebrovascular disease is a rare etiology of true *syncope*, defined as transient, self-limited loss of consciousness⁷.
 - In the rare cases where the cause of syncope is cerebrovascular, vertebrobasilar insufficiency or subclavian steal is usually involved.
- Intracranial space occupying lesion (tumor, abscess, arteriovenous malformation, etc.).
 - May be asymptomatic until reaches a large size, or results in hemorrhage, edema, or seizure.
 - Usually readily identified with noncontrast head CT.
- Migraine.
 - The relationship of migraines and cerebral ischemia is complex: migraines (*complicated migraines*) may mimic

acute ischemic stroke; migraines are a risk factor for cerebral ischemia (see “Migraine in Acute Ischemic Stroke: Conventional Risk Factors, Predisposing Conditions, and Risk Factor Modification” section); and headache can occur in the setting of cerebral ischemia: 32% of patients with cerebral ischemia complained of headache.⁸

- Psychiatric disease (aka functional, medically unexplained, presentation).
 - Diagnosis of exclusion.
 - Pattern of deficit may be suspicious for non organic etiology, i.e., exam does not readily suggest a cerebral vascular distribution.
 - The etiology may be conversion disorder or malingering.
- Spinal cord pathology.
 - Pattern of weakness and sensory deficit may suggest spinal cord localization.
- Cerebral sinus or venous thrombosis.
 - Risk factors include infection, dehydration, oral contraceptive use, coagulopathy, or pregnancy/puerperium.
 - Usually readily identified with noncontrast head CT.
 - Focal neurologic dysfunction is usually due to cerebral edema, hemorrhage, or seizure.
- Anamnestic syndrome.
 - Recurrence of focal neurologic deficit similar to that seen with prior cerebral injury, in the setting of current systemic derangement, i.e., infection or metabolic derangement, usually in an elderly patient. Not to be confused with *amnesia*, which is loss of memory.
 - Diagnosis of exclusion in patients with previous brain injury.

17.3. Acute ischemic stroke: Mechanisms

Three basic mechanisms can result in cessation or diminution of flow to regions of brain: embolism from a proximal source with occlusion of the downstream artery; local occlusion, usually due to in situ thrombosis, of a proximal or distal artery; or global hypoperfusion. The majority of ischemic strokes are split between embolic (with 25% cardioembolic) and local occlusion, with global hypoperfusion accounting for the minority. In large vessel disease, all three mechanisms may be involved, e.g., a carotid artery severely stenotic (because of a large atherosclerotic plaque) may cause distal ischemia from plaque emboli and/or worsening stenosis with distal hypoperfusion due to acute plaque rupture and thrombosis, which may be exacerbated by low cardiac output or relative systemic hypotension. Sometimes one mechanism may predominate at different times in the evolution of cerebrovascular pathology. Detailed discussion of risk factors and conditions associated with ischemic stroke follows in the subsequent section; some examples of specific conditions discussed in the subsequent section are listed within each mechanistic category later.

1. Embolism.

(a) Artery-to-artery embolism.

- Extracranial and intracranial large vessel vasculopathy of any cause.
 - Atherosclerotic (most common).
 - Nonatherosclerotic.
 - (a) Dissection or fibromuscular dysplasia.
 - (b) Dolichoectasia.
 - (c) Vasculitis/arteritis.
 - (d) Moya-moya disease/syndrome.
 - (e) Vasospasm/vasoconstriction.
- Aortic arch abnormality of any cause.
 - Atherosclerotic atheroma.
 - Dissection/aneurysm.
 - Connective tissue disease or infection.

- (b) Cardioembolism.
 - Arrhythmia
 - Atrial fibrillation (most common)
 - Valvulopathy
 - Rheumatic heart disease
 - Prosthetic heart valves
 - Endocarditis
 - (a) Infectious
 - (b) Nonbacterial thrombotic
 - Mitral valve prolapse
 - Cardiomyopathy, dilated
 - Acute MI and ventricular thrombus.
 - Paradoxical embolism
 - Patent foramen ovale
 - Pulmonary AVM
 - Intracardiac lesions
 - Tumors, e.g., atrial myxoma
- 2. Local occlusion
 - (a) Small vessel vasculopathy of any cause.
 - Related to multiple risk factors: hypertension, hyperlipidemia, diabetes mellitus, cigarette smoking, etc. (most common)
 - Cerebral autosomal dominant arteriopathy with subcortical infarcts and leukoencephalopathy (CADASIL)
 - Cerebral angitis
 - Cerebral amyloid angiopathy
 - (b) Abnormalities of coagulation.
 - Malignancy
 - Hormonal
 - Pregnancy and puerperium
 - Oral contraceptives
 - Hormone replacement
 - Genetic coagulopathies
 - Antiphospholipid antibody syndrome
 - (c) Abnormalities of platelet function.
 - Heparin-induced thrombocytopenia
 - Thrombotic thrombocytopenic purpura
 - (d) Hyperviscosity.
 - Sickle cell disease
 - Hyperfibrinogenemia
 - Polycythemia vera
- 3. Hypoperfusion
 - (a) Systemic hypotension of any cause.
 - (b) Heart failure/low cardiac output.
 - (c) Cardiac arrhythmia or arrest.

17.4. Acute ischemic stroke: Conventional risk factors, predisposing conditions, and risk factor modification

The approach to the patient with cerebral ischemia starts with the understanding of the *patient milieu*: the constellation of ischemic stroke risk factors, some modifiable and some not, which, alone and in combination, confer specific ischemic stroke risk. The main pathophysiologic theme underlying the conventional risk factors is endothelial injury leading to (1) *atherosclerosis* (discussed in Chap. 18) which manifests as large artery disease (extracranial and intracranial), (2) cerebral *microangiopathy* which manifests as lacunar infarcts and perivascular white matter disease, and (3) coronary artery disease which leads to abnormalities of cardiac function and rhythm. These disease processes predispose to cerebral ischemia due to embolism, local occlusion, and/or hypoperfusion.

Conventional ischemic stroke risk factors
Age
Gender
Ethnicity/heredity/genetics
Hypertension
Diabetes mellitus
Hyperlipidemia
Cigarette smoking
Cardiac disease ^a
Atrial fibrillation
Cervical carotid stenosis
Intracranial stenosis

^aIncludes cardiomyopathy, myocardial infarction with intraventricular thrombus, intracardiac lesions (tumors), valvular diseases, etc

In up to 40% of patients, despite etiologic investigation, the specific cause of ischemic stroke is not identified. It is likely that, with time and further research, additional risk factors and predisposing conditions for ischemic stroke will be recognized, accounting for some of these so-called *cryptogenic* strokes. Conventional risk factors, constellations of risk factors, as well as other conditions, either currently emerging as ischemic stroke risk factors or known, albeit uncommon, risk factors are discussed later in alphabetical order.

17.4.1. Acute myocardial infarction (MI) with left ventricular (LV) thrombus

1. Ischemic stroke risk in MI with LV thrombus
 - (a) Up to 12% in patients with MI and LV thrombus, but can be as high as 20% if thrombus is apical⁹.
2. Management of stroke risk in MI with LV thrombus
 - (a) Primary prevention of ischemic stroke.
 - Warfarin sodium with INR goal of 2.0–3.0 for 3 months to 1 year may be considered¹⁰
 - (b) Secondary prevention of ischemic stroke⁹.
 - Warfarin sodium with INR goal of 2.0–3.0 for 3 months to 1 year
 - Concomitant low-dose aspirin should be used in the setting of coronary artery disease.

17.4.2. Age

Age is the strongest risk factor for ischemic stroke. Incidence of cerebral ischemia increases with age irrespective of ethnicity and gender: incidence doubles with each decade after age 55.¹¹

17.4.3. Alcohol consumption

There is a protective effect of consumption of small amounts of alcohol, and a deleterious effect of consumption of >5 drinks per day, on ischemic stroke risk in primary¹⁰ and secondary stroke prevention.⁹

1. Potential mechanisms of deleterious effect of alcohol:
 - (a) Hypertension, coagulopathy, and cardiac arrhythmias.

2. Potential mechanisms of beneficial effect of alcohol:
 - (a) Increase in HDL/LDL ratio and decreased platelet aggregation.

2006 AHA Recommendation¹⁰
Patients with ischemic stroke or TIA who consume alcohol should eliminate alcohol consumption or decrease it to no more than 1–2 drinks per day.

17.4.4. Aortic arch atheroma

Aortic arch atheromas are found most frequently using transesophageal echocardiography in elderly patients with atherosclerotic disease at other sites.

1. Ischemic stroke risk with aortic arch atheroma
 - (a) Plaques ≥ 4 -mm thick. Up to 11% recurrence at 1 year in some elderly patients with cryptogenic stroke, despite antiplatelet therapy.¹²
2. Mechanism of ischemic stroke with aortic arch atheroma: thromboembolism
3. Management of ischemic stroke risk with aortic arch atheroma
 - (a) Best therapy is unknown
 - Antiplatelet therapy, antihypertensive drugs, smoking cessation aids, as well as HMG CoA reductase inhibitors (statins) are routinely prescribed.¹³
 - (b) Systemic anticoagulation or dual antiplatelet therapy, most commonly with aspirin and clopidogrel, has been advocated for specific patients (e.g., plaque with a mobile component or free-floating thrombus).^{14, 15}
 - Randomized therapeutic trials comparing antiplatelet drugs to warfarin are lacking
 - Benefit of dual antiplatelet therapy is offset by risk of hemorrhage (MATCH study).¹⁶
 - (c) Routine aortic atherectomy, aortic filters, or stenting are not currently recommended.¹³

17.4.5. Arrhythmia

The most common and best-studied arrhythmia predisposing to ischemic stroke through a thromboembolic mechanism is atrial fibrillation (see “Atrial Fibrillation” section). Other abnormalities of cardiac rhythm including sick sinus syndrome or tachycardiabradycardia syndrome may be associated with increased risk ischemic stroke.¹⁷ Ischemic stroke prevention in paroxysmal atrial fibrillation and atrial flutter should be approached in the same manner as persistent atrial fibrillation.^{18, 19}

17.4.6. Atherosclerosis, arterial

Atherosclerotic disease can affect both extracranial and intracranial vasculature and is fully discussed in Chaps. 18 and 19, respectively.

17.4.7. Atrial fibrillation (AF)

AF is the most common arrhythmia. Thromboembolism may occur as a result of clot formation primarily within the left atrium and left atrial appendage.

1. Predisposing factors for AF²⁰
 - (a) Heart disease: cardiac ischemia, valvular heart disease, myocardial dysfunction
 - (b) Medical conditions: thyrotoxicosis, pulmonary embolism, sleep apnea, obesity, neurologic emergencies
 - (c) Idiopathic, aka lone AF
 - (d) Familial
 - (e) Perioperative
 - (f) Associated with caffeine or alcohol use

2. Prevalence of AF
 - (a) Increases with age²¹
 - Age ≥65. Five percent of the population
 - Age ≥80. Ten percent of the population
 - (b) Causes 15% of ischemic strokes in the US
 - If age ≥80. Twenty-four percent of ischemic strokes
3. Ischemic stroke risk in AF
 - (a) Nonrheumatic AF, *not treated* with antithrombotic therapy²²
 - Approximate average risk. 5% per year (primary prevention), 12% per year (secondary prevention)²³
 - Stratification based on patient characteristics: CHADS₂ Score

CHADS ₂ Score for Ischemic Stroke Risk Stratification in Atrial Fibrillation ²²		
	Prognostic factor in atrial fibrillation	CHADS ₂ Score, points
C	Recent congestive heart failure	1
H	Hypertension	1
A	Age ≥75	1
D	Diabetes mellitus	1
S₂	Previous stroke or transient ischemic attack	2

CHADS ₂ score	Ischemic stroke in atrial fibrillation without antithrombotic therapy (rate per 100 person-years)
0	1.9
1	2.8
2	4.0
3	5.9
4	8.5
5	12.5
6	18.2

4. Management of AF
 - (a) Prevention of thromboembolism in persistent or paroxysmal AF
 - Risk reduction and complication rates with antithrombotic therapy^{19, 23, 24}

Risk reduction and complication rates with antithrombotic therapy in atrial fibrillation		
Rate (ARR and RRR compared to placebo)	Aspirin (25–1,300 mg per day)	Warfarin sodium (INR 2–3)
Ischemic stroke (RRR per year)	23%	65%
Primary prevention of ischemic stroke (ARR per year)	1.5%	2.7% (NNT for 1 year to prevent 1 stroke: 37)
Secondary prevention of ischemic stroke (ARR per year)	2.5%	8.4% (NNT for 1 year to prevent 1 stroke: 12)
Complications (intracranial and extracranial hemorrhages) (rate per 100 person-years)	3.5	7.9

- Selection of antithrombotic therapy in patients with AF using the CHADS₂ score²⁰
 - CHADS₂ = 0: aspirin (81–325 mg)

- CHADS₂ = 1: aspirin or warfarin sodium
- CHADS₂ ≥2: warfarin sodium with goal INR 2–3
- (b) Rate control in AF²
 - Goals
 - Symptomatic relief from tachycardia
 - Prevention of tachycardia-related cardiomyopathy
- (c) Other options for selected patients with AF
 - Rhythm control
 - Cardioversion
 - Anticoagulation is required periprocedure
 - Catheter ablation/pacemaker implantation

17.4.8. Birth control pills

See “Oral Contraceptives” section.

17.4.9. Cerebral amyloid angiopathy (CAA)

CAA is characterized by deposition of amyloid β -protein in the walls of cortical and leptomeningeal blood vessels.²⁵ CAA is associated with dementia and intracerebral hemorrhage, but may manifest with cerebral ischemia due to microvascular disease. In some patients, pathologic specimens feature amyloid deposits in association with a vascular inflammatory reaction (vasculitis) on brain biopsy, for which immunosuppressive therapy may eventually be an option.²⁶ There is no specific treatment for CAA or specific primary or secondary ischemic stroke prevention strategy.²⁵

17.4.10. Cerebral autosomal dominant arteriopathy with subcortical infarcts and leukoencephalopathy (CADASIL)

CADASIL is a dominantly inherited disorder caused by mutation of the Notch3 gene, resulting in damage to the endothelium of small cerebral arteries and arterioles, i.e., a small vessel vasculopathy.²⁷ Central nervous system manifestations include ischemic stroke, migraine, dementia, psychiatric disorders, and seizures. Other organs affected include skin, muscle, heart, liver, GI tract, and peripheral nerves. The diagnosis can be made with genetic testing.²⁷

1. Ischemic stroke and transient ischemic attack (TIA) in CADASIL
 - (a) May occur in up to 85% of affected people, with frequent recurrence.
 - (b) Small vessel (lacunar) syndromes predominate, usually beginning in the fourth or fifth decade. (Fig. 17.2)
 - (c) There is no specific treatment or primary or secondary ischemic stroke preventative strategy, and while the effect of conventional preventative therapies on stroke recurrence in CADASIL is unknown, control of conventional stroke risk factors is logical; double antiplatelet therapy or systemic anticoagulation is avoided due to intracerebral hemorrhage risk.

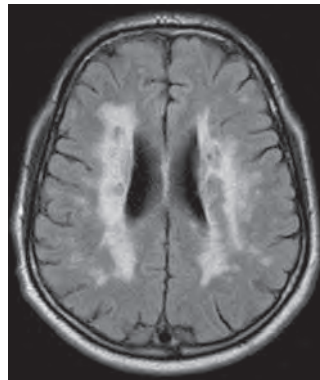


Fig. 17.2 MRI of the brain in a patient with CADASIL. Multiple subcortical infarcts are evident.

17.4.11. Cardiomyopathy (CM)

CM predisposes to thromboembolism by virtue of relative stasis of blood and clot formation within the cardiac apex. Thromboembolism may occur regardless of etiology of ventricular dysfunction:

1. Relationship of stroke risk to reduction in ejection fraction (EF)^{28, 29}
 - (a) Postmyocardial infarction ventricular dysfunction
 - Cumulative risk of stroke (96% of strokes were ischemic)

Ischemic stroke risk as a function of ejection fraction ²⁸	
Ejection fraction (%)	Stroke rate over 5 years after myocardial infarction (%)
≤28	8.9
29–35	7.8
>35	4.1

2. Management of ischemic stroke risk in CM
 - (a) Antithrombotic therapy
 - Lack of randomized controlled studies
 - Warfarin with goal of INR 2–3 *may be considered* for patients with severe LV dysfunction for primary prevention¹⁰
 - *Either* warfarin sodium with goal INR 2–3 *or* anti platelet agents are reasonable for secondary prevention⁹

17.4.12. Cigarette smoking

See “Tobacco, Smoked” section.

17.4.13. Coagulopathy

Venous thrombosis can lead to ischemic stroke if there is concomitant abnormal right-to-left communication, such as a patent foramen ovale (PFO). Typical conditions increasing the risk of venous thrombosis in the general population are pregnancy, oral contraceptives, nephrotic syndrome, postoperative state, immobility, and malignancy.³⁰ If the ischemic stroke is cryptogenic and the patient is <50 years old, the patient is typically screened for genetic coagulopathy. Although a fraction of the population may indeed harbor genetic disorders of the coagulation pathways which predispose to venous thrombosis, i.e., primary hypercoagulability, caution needs to be exercised in making this diagnosis in the acute phase of ischemic stroke: acute thrombosis may cause transient hypercoagulability (secondary hypercoagulability), and laboratory tests for coagulation factor levels may be affected. Thus, all tests with the exception of genetic tests (e.g., Factor V Leyden and prothrombin gene mutations) should be performed at least two months after the acute stroke phase.^{31, 32} Additionally, a positive family history and/or personal history suggestive of a clotting disorder antedating the stroke should be sought to increase the pretest probability of primary hypercoagulability.

In summary, rare patients who present with cryptogenic ischemic stroke may have primary hypercoagulability (up to 4% of patients <50 years old with ischemic stroke; approximately 1% of all patients with ischemic stroke).³² If a patient with primary hypercoagulability and ischemic stroke shows no evidence of venous thrombosis and a right-to-left shunt (i.e., paradoxical embolism as stroke mechanism), a relationship of the coagulation disorder to arterial thrombosis may be invoked, although this should not preclude screening for conventional ischemic stroke risk factors.

This section focuses on selected genetic coagulopathies. Additional selected hematologic conditions which are associated with a thrombophilic state are discussed in the “Hyperviscosity,” “Heparin-Induced Thrombocytopenia,” “Malignancy,” and “Sickle Cell Disease” sections.

Prevalence of primary hypercoagulability among patients with ischemic stroke			
Condition	Prevalence range (%)	Pretest probability (%)	
		>50 Years Old	All ages
Hereditary protein C, protein S, and antithrombin III deficiency	0–21	Unknown	Unknown
Hereditary fibrinolytic deficiency (e.g., plasminogen)	0–2.7	Unknown	Unknown
Activated protein C resistance (aka Factor V Leyden mutation)	0–38	11	7
Prothrombin gene mutations	1–12.5	5.7	4.5
Antiphospholipid antibodies			
(a) anticardiolipin antibody		21	17
(b) lupus anticoagulant		8	3

1. Prevalence of coagulopathy in ischemic stroke patients³¹.
2. Clinical factors increasing the pretest probability of coagulopathy in ischemic stroke patients.
 - (a) All disorders: age ≤50, family history of thrombosis, personal history of venous or arterial thrombosis.
 - (b) Hereditary protein C, protein S, and antithrombin III deficiency, or fibrinolytic deficiency.
 - Thrombus in atypical location (e.g., upper extremity).
 - Thrombosis during pregnancy/puerperium.
 - Warfarin-induced skin necrosis (protein C or S deficiency).
 - Resistance to heparin (antithrombin III deficiency).
 - (c) Activated protein C resistance or prothrombin gene mutation.
 - Cerebral sinus thrombosis.
 - Thrombosis during pregnancy/puerperium.
 - (d) Antiphospholipid antibodies.
 - Systemic lupus erythematosus.
 - Miscarriage.
 - Livedo reticularis (reticulated pattern of purplish discoloration on the skin due to changes in vascular diameter).
 - Idiopathic thrombocytopenia.
 - Nonbacterial thrombotic endocarditis.
3. Management of patients with ischemic stroke and coagulopathy⁹.
 - (a) All patients should receive a full cerebrovascular evaluation of conventional ischemic stroke risk factors.
 - (b) Established hereditary protein C, protein S, antithrombin III or fibrinolytic deficiency; activated protein C resistance; or prothrombin gene mutation and cryptogenic ischemic stroke.
 - If deep venous thrombosis is present. Anticoagulation with warfarin sodium to INR 2–3, short or long term, depending on additional patient-specific factors.
 - If deep venous thrombosis is absent. Antiplatelet therapy *or* anticoagulation with warfarin sodium to goal INR 2–3.
 - If there are recurrent thrombotic events on antiplatelet therapy. Anticoagulation with warfarin sodium to goal INR 2–3.
 - (c) Established antiphospholipid antibodies and cryptogenic ischemic stroke.
 - If antiphospholipid antibodies are present, but there are no features of antiphospholipid antibody syndrome (see [Table 17.1](#)): antiplatelet therapy.
 - If antiphospholipid syndrome is present: anticoagulation with warfarin sodium to INR 2–3.
 - Diagnostic criteria (Sapporo Criteria) for antiphospholipid antibody syndrome³³.

Table 17.1 Diagnosis of antiphospholipid antibody syndrome (aka Hughes Syndrome)³³

<i>Clinical criteria (one or more required)</i>	
•	Vascular thrombosis: arterial OR venous OR small vessel thrombosis in any organ
•	Pregnancy complications: unexplained fetal death after 10 weeks of gestation OR premature birth due to pre-eclampsia, eclampsia, or placental insufficiency OR three unexplained consecutive spontaneous abortions before 10 weeks of gestation
<i>Laboratory criteria (one or more required)</i>	
•	Anticardiolipin IgG or IgM antibodies detected on two or more occasions separated by at least 6 weeks
•	Lupus anticoagulant detected on two or more occasions separated by at least 6 weeks

17.4.14. C-Reactive protein

High blood levels of C-reactive protein (CRP) and other inflammatory molecules correlate with increased atherosclerosis and risk of coronary disease and ischemic stroke, although the relationship is less clear for ischemic stroke than for coronary disease.³⁴ It is uncertain whether CRP is causative or a marker of disease severity. The interpretation and the application of CRP levels in clinical situations are currently being investigated. Monitoring of CRP levels may eventually prove useful in stratifying patients at greatest risk of coronary and cerebrovascular events, as well as in gauging response to preventative therapies.

17.4.15. Diabetes mellitus (DM)

DM affects 8% of American adults and is a predictor of recurrent ischemic stroke.⁹ Chronically poor glycemic control results in injury to the microvasculature in many organs including the brain, peripheral nerve, retina, and kidney. The microangiopathy in turn causes ischemic damage. In the brain, manifestations of diabetic microangiopathy include progressive subcortical white matter injury and lacunar ischemic strokes. Appropriate glycemic control decreases microvascular injury, and is recommended for primary and secondary prevention of ischemic stroke.^{9, 10}

1. Diagnosis.

Diagnosis of diabetes mellitus	
	Fasting plasma glucose (mg dL ⁻¹)
Normal fasting glucose	<100
Impaired fasting glucose	100–126
Diabetes	>126

2. Management of DM.

- (a) Oral hypoglycemic drugs, long- and short-acting insulin, and diabetic diet should be used to achieve glycemic control.
- (b) Glycemic control should be monitored with HbA_{1c} levels: HbA_{1c} > 7% suggests poor control.
- (c) Concomitant conditions increasing stroke risk, especially hypertension and hyperlipidemia should be aggressively treated in patients with DM.
- (d) Lifestyle changes including weight reduction, decreasing alcohol intake, and smoking cessation should be prescribed for patients with DM.

3. Insulin resistance.

- (a) Relatively common worldwide, affecting perhaps >1 billion people.
- (b) Currently being investigated as a risk factor for vascular disease³⁵.

17.4.16. Dissection, arterial

Discussed in Chap. 18.

17.4.17. Dolichoectasia, arterial

Discussed in Chap. 13.

17.4.18. Drug abuse

Drug abuse can lead to ischemic stroke through a variety of mechanisms. For example, cocaine use can predispose to acute risk in the form of cerebral vasospasm or chronic risk in the form of hypertensive cerebral vasculopathy (see also “Cocaine and Stroke”, in the “Vasculitis” section). Cerebral vasculitis has been associated with amphetamine use. Intravenous drug use of any sort can lead to bacterial endocarditis and embolic stroke risk. Patients who abuse drugs should be counseled as to the risks and referred to appropriate drug rehabilitation services.

17.4.19. Endocarditis

Endocarditis accounts for less than 1% of thromboembolic ischemic strokes, and is classified as either bacterial (BE)³⁶ (aka infective) or nonbacterial thrombotic (NBTE) (aka marantic).³⁷ Conditions predisposing to BE include valvular abnormalities, catheter-related blood stream infections, intravenous drug use, and immune suppression. BE can occur on native or prosthetic valves, and in the majority of cases either streptococci or staphylococci are involved. NBTE is most often associated with malignancy, disseminated intravascular coagulation, systemic lupus erythematosus with antiphospholipid syndrome, and primary hypercoagulabilities in the setting of previously normal valves. In these conditions, valvular vegetations are sterile and typically consist of fibrin and platelets. The term *Libman-Sacks endocarditis* usually refers to sterile endocardial lesions in patients with systemic lupus erythematosus and the antiphospholipid syndrome (see “Coagulopathy” section).

1. Diagnosis of endocarditis.

(a) BE (see [Table 17.2](#)).

- Clinical exam findings of systemic embolization.
 - Osler nodes: tender nodules on finger and toe pads, present in 10–25% of patients with BE, but not specific to BE.

Table 17.2 Modified Duke criteria for diagnosis of bacterial endocarditis³⁶

<i>Major criteria</i>
<ul style="list-style-type: none">• Microorganisms isolated from two separate blood cultures, persistent bacteremia, or a single culture with <i>Coxiella Burnetii</i>• Evidence of endocardial lesion (new valvular regurgitation or positive echocardiogram)
<i>Major criteria</i>
<ul style="list-style-type: none">• Predisposition (IV drug use, previous BE, prosthetic heart valve, mitral valve prolapse, etc.)• Fever• Evidence of embolization• Immunologic phenomena (Osler nodes, Janeway lesions, etc.)• Microbiologic findings not meeting major criteria
<i>Definite bacterial endocarditis</i>
2 major criteria OR 1 major and 3 minor criteria OR 5 minor criteria
<i>Possible bacterial endocarditis</i>
1 major and 1 minor criteria OR 3 minor criteria

- Janeway lesions: nodular hemorrhages on palms and soles, most likely associated with BE when seen on physical exam.
 - Petechiae and palpable purpura.
 - Splinter hemorrhages: subungual, dark red streaks; may also be seen with trauma.
 - Roth spots: oval retinal hemorrhages with pale centers.
 - New cardiac murmur.
 - Positive blood cultures.
 - See “Culture-negative endocarditis”.
 - Evidence of vegetations on echocardiography.
 - Transesophageal is more sensitive, but transthoracic may reveal large lesions.
 - Culture-negative endocarditis.
 - Blood cultures may be sterile in up to 5% of cases of BE diagnosed using strict criteria outlined earlier.
 - Causes of sterile cultures: prior use of antibiotics, right heart endocarditis, slow-growing organisms, fungi, intracellular pathogens, NBTE³⁶.
- (b) NBTE.
- Transesophageal or transthoracic echocardiography showing vegetations.
 - Sterile blood cultures.
 - Evidence of systemic embolization.
 - Underlying primary condition such as cancer or the anti phospholipid syndrome.
- Cardiac murmurs infrequent (unlike in BE).
2. Ischemic stroke risk in endocarditis.
- (a) BE.
- Up to 20% of patients have ischemic stroke and up to 65% may have embolization elsewhere.
 - Large vegetations on anterior leaflet of mitral valve are most likely to embolize.
 - Cerebral embolization of vegetations containing bacteria can result in cerebral ischemia, abscess, mycotic aneurysm and arteritis, and hemorrhage (5% of cases).
- (b) NBTE.
- Systemic (including brain) emboli are present on autopsy in almost half of patients with NBTE³⁸.
3. Other complications of endocarditis.
- (a) BE³⁶.
- Congestive heart failure: up to 50%.
 - Glomerulonephritis.
 - Annular abscess or cardiac conduction system involvement.
 - Mycotic aneurysm or cerebral abscess.
4. Management of endocarditis.
- (a) BE.
- Obtain blood cultures.
 - Start empiric intravenous antibiotics geared at most likely organisms.
 - Tailor antibiotics based on culture sensitivities.
 - If valves are prosthetic, continue systemic anticoagulation, unless there is evidence of hemorrhage or the infarct is large, i.e., at risk for hemorrhagic transformation.
 - There is *no* role for systemic anticoagulation in case of native valves, and initiation may increase risk of hemorrhagic conversion of cerebral infarcts.
 - Surgical management is reserved for cases of valvular insufficiency, heart failure, continued embolization, or persistent bacteremia despite appropriate antibiotic therapy, highly resistant virulent organisms, immediate relapse after completion of therapy, or large vegetations on the mitral valve.
- (b) NBTE³⁷.
- Evaluate patient for malignancy, primary hypercoagulability, and the antiphospholipid syndrome and treat primary condition accordingly.

- Unless contraindicated (i.e., in the setting of hemorrhage or moderate-to-large acute cerebral infarcts), systemic anticoagulation should be used.
 - In patients with malignancy, heparins may be more effective than warfarin or other vitamin K antagonists.
 - In patients with primary hypercoagulability or antiphospholipid syndrome, warfarin should be used (see “Coagulopathy” section).
- In cases of large vegetations or destructive valvular lesion, surgical therapy is an option⁸⁹.

17.4.20. Ethnicity

The effect of ethnicity on ischemic stroke in the United States has been investigated in large population-based studies such as the Greater Kentucky/Cincinnati Study and the Northern Manhattan Study.^{11, 40} Americans of African and Hispanic descent exhibit higher ischemic stroke rates than Caucasians, irrespective of age and gender.

17.4.21. Fabry disease

Fabry Disease is an X-linked lysosomal storage disease and a relatively rare etiology of ischemic stroke. The disease is caused by deficiency of α -galactosidase A, which manifests with systemic accumulation of glycosphingolipids. Fabry Disease should be kept in mind when investigating patients with cryptogenic ischemic stroke: the importance of making this rare diagnosis lies in the availability of disease-modifying therapy.⁴¹

1. Incidence of Fabry Disease.
 - (a) 1:55,000 male births.
 - (b) Seventy percent of women may be symptomatic: typically milder symptoms and occurring later in life than in men.
2. Disease manifestations of Fabry Disease.
 - (a) Intermittent paresthesias, especially involving the hands and feet.
 - (b) Chronic abdominal complaints, primarily pain.
 - (c) Angiokeratomata.
 - (d) Renal insufficiency and proteinuria.
 - (e) Hypertrophic cardiomyopathy, arrhythmias.
 - (f) Cerebral ischemia, predominantly vertebrobasilar.
3. Diagnostic testing for Fabry Disease.
 - (a) Males.
 - Pedigree analysis.
 - Plasma or leukocyte α -galactosidase A.
 - (b) Females.
 - Mutation analysis.
4. Treatment of Fabry Disease.
 - (a) Enzyme replacement therapy.
 - Agents.
 - Agalsidase alpha is used worldwide, but not approved in the US.
 - Agalsidase beta is approved in the US.
 - Treatment effects.
 - Stabilization of cardiac, renal disease.
 - Reversal of cerebrovascular nitric oxide dysfunction.

17.4.22. Family history of ischemic stroke

Maternal or paternal history of ischemic stroke is an ischemic stroke risk factor. Ultimately, this is due to the combination of genetic (see later) and environmental (including cultural) influences.

17.4.23. Fibromuscular dysplasia

Discussed in Chap. 18.

17.4.24. Gender

Pre-menopausal Caucasian females have a lower incidence of ischemic stroke than males. This difference is lost with menopause and is affected by ethnicity, e.g., women of African American descent have a higher frequency of cerebral ischemia than age-matched Caucasian females or males.¹¹

17.4.25. Genetics

In most patients, a predisposition to ischemic stroke is multifactorial, i.e., a complex interplay of genes relating to intrinsic risk factors like hypertension and diabetes with extrinsic aspects including diet, cigarette smoking, alcohol intake, and physical activity. In general, genetic predispositions to ischemic stroke can be classified as single gene or polygenic disorders.²⁷ In the majority of stroke patients, risk is likely polygenic. The unraveling of the genetic complexity has only begun: in several diseases with defined genetic causes, ischemic stroke is a common manifestation. Only single gene disorders are considered:

1. Single gene disorders.
 - (a) Ischemic stroke as a recognized manifestation.
 - Cerebral autosomal dominant arteriopathy with subcortical infarcts and leukoencephalopathy (CADASIL).
 - Cerebral autosomal recessive arteriopathy with subcortical infarcts and leukoencephalopathy (CARASIL).
 - Rare; features similar to CADASIL.
 - Fabry Disease (see “Fabry Disease” section).
 - Moya-moya Disease (see Chap. 18).
 - Sickle Cell Disease (see “Sickle Cell Disease” section).
 - (b) Ischemic stroke observed occasionally.
 - Ehler-Danlos Type 4.
 - Mutation in collagen type 3 gene.
 - Predisposition to arterial dissection and aneurysm formation (see Chapter 15).
 - Marfan Syndrome.
 - Mutation in fibrillin gene.
 - Associated with aortic dissection and valvular heart disease.
 - Neurofibromatosis Type 1.
 - Associated with hypertension and moya-moya syndrome (see Chap. 18).
 - Familial Hemiplegic Migraine.
 - Mutation in neuronal voltage-gated calcium channel subunit gene.
 - Homocystinuria.
 - Autosomal recessive, cystathione beta-synthase deficiency.
 - Associated with carotid artery disease or dissection.
 - Management is dietary, with pyridoxine supplementation and antiplatelet therapy.
2. Genes currently under investigation⁴²
 - (a) Phosphodiesterase 4D gene (PDE 4D).
 - Polymorphisms may be associated with increased ischemic stroke risk in certain populations.
 - Increased association with large artery ischemic stroke, but not carotid intima media thickness (see “Intima Media” section).
 - (b) 5-Lipoxygenase-activating protein (ALOX5AP).
 - Polymorphisms may be associated with increased ischemic stroke risk in certain populations.
 - Associated with atherosclerosis and intima media thickness.
 - (c) New genes with possible links to ischemic stroke are constantly being added to the list.

17.4.26. Hemoglobinopathy

See “Sickle Cell Disease” section.

17.4.27. Heparin-induced thrombocytopenia (HIT)

There are two forms of HIT: HIT Type I may be nonimmune, occurs within 1–3 days of starting heparin, and is usually self-limited (i.e., platelet counts recover while heparin is continued) and without consequence to the patient; while HIT Type II is a serious, potentially life-threatening immune-mediated disease manifested by thrombocytopenia and platelet activation, and resulting in thrombosis in 20–50% of patients.⁴³ The immune reaction in HIT Type II is caused by administration of heparins, either unfractionated or low molecular weight, and the resulting antibodies are directed against platelet factor 4 and heparin. The mere presence of antibodies is not sufficient to make the diagnosis of HIT Type II, as in some patients the existence of antibodies has no clinical consequences (see Table 17.3). When used without specifying type, the term HIT usually refers to HIT Type II, and this is how the term will be used in the remainder of this section, unless otherwise specified.

1. Incidence: See Table 17.3.⁴⁴
2. Diagnosis of HIT.
 - (a) Heparin exposure: Thrombocytopenia develops 5–10 days after initiation of heparin therapy, although in patients with recent heparin exposure, thrombocytopenia may occur within 1 day of re-exposure.
 - (b) Otherwise unexplained $\geq 50\%$ drop in platelet count (or to $< 150 \times 10^9 \text{ L}^{-1}$).
 - (c) Laboratory diagnosis.
 - Two types of assays: antigen and functional assays.
 - Because neither assay has high sensitivity and specificity, both assays should be used in making the diagnosis.
 - (e) Normalization of platelet count when heparin is discontinued.
3. Thrombosis in HIT.
 - (a) Occurs in 20–50% of patients; risk is more than 30 times that of control populations; incidence increases with recent surgery or other causes of increased inflammatory response.
 - (b) Venous and arterial thromboses.
 - Most common: pulmonary embolism.
 - Myocardial infarction, ischemic stroke, extremity infarctions can occur.
 - Venous thromboses are more common in medical and orthopedic patients; arterial thromboses in cardiac surgical or vascular surgical patients.

Table 17.3 Incidence of antiheparin antibodies and heparin-induced thrombocytopenia

Patient population/risk	Incidence of heparin antibodies (%)	Incidence of HIT (%)
<i>High Risk</i> Unfractionated heparin in the setting of orthopedic surgery	14	3–5
<i>Intermediate Risk</i> Unfractionated heparin in the setting of cardiac surgery	25–50	1–2
<i>Intermediate Risk</i> Unfractionated heparin in general medical or neurologic patients	8–20	0.8–3
<i>Intermediate Risk</i> Low molecular weight heparin in medical, neurologic, surgical patients	2–8	0–0.9

4. Other, less common, manifestations of HIT.
 - (a) Venous limb gangrene, skin necrosis, disseminated intravascular coagulation, and anaphylaxis.
5. Management of HIT⁴⁴.
 - (a) Goals of therapy in HIT.
 - Decrease risk of thrombosis by reducing platelet activation and thrombin generation⁴⁴.
 - (b) Protocol in suspected HIT.
 - Because it is sometimes difficult to initially differentiate the benign self-limited HIT Type I from HIT Type II, all patients with exposure to heparin and thrombocytopenia should be suspected of having HIT Type II until ruled out with laboratory testing.
 - All forms of heparin, including unfractionated or low molecular weight injections and heparin central and peripheral line flushes, should be stopped.
 - Laboratory tests for HIT, PTT, INR, and liver function should be obtained.
 - An alternative anticoagulant should be started.
 - Either a direct thrombin inhibitor (e.g., argatroban or lepirudin, or bivalirudin if undergoing percutaneous coronary procedures) or a heparinoid should be used.
 - Warfarin should not be started before full anticoagulation with the alternative agent *and* platelet count recovery due to the possibility of warfarin-induced skin necrosis.
 - (c) Protocol in confirmed HIT.
 - All forms of heparin should be stopped: unfractionated or low molecular weight injections and heparin central and peripheral line flushes.
 - Thrombocytopenia *without* thrombosis.
 - Alternative anticoagulant should be continued until platelet counts recover to patient's baseline or stable plateau.
 - Anticoagulation with an alternative agent or warfarin for a further 4 weeks should be considered, as the risk of thrombosis remains high.
 - Thrombocytopenia *with* thrombosis.
 - Alternative anticoagulant should be continued until platelet counts recover to $>150 \times 10^9 \text{ L}^{-1}$.
 - Once platelet count recovers, alternative anticoagulant should be continued during the transition to oral anticoagulation with warfarin until the INR is stably within the goal range.
 - Oral anticoagulation should be continued for 3–6 months.
 - Future exposure to heparin should be avoided.

17.4.28. Hormone replacement therapy (HRT)

Estrogens are thought to be beneficial in a variety of conditions, from dementia to sepsis. The incidence of ischemic stroke is lower in premenopausal women compared to age-matched men, and estrogens were found to be neuroprotective in experimental models of ischemic stroke.^{45–48} Early clinical studies (mostly observational and case controlled) suffered from many shortcomings including variable replacement regimens and resulted in conflicting data on HRT in humans. Although recent randomized, controlled clinical trials of HRT did not show benefit and one revealed higher cardio- and cerebrovascular event rates (see [Table 17.4](#)), further studies are needed to fully understand the cerebrovascular impact of HRT.

1. Ischemic stroke risk with HRT: See [Table 17.4](#).⁴⁹
2. Factors increasing ischemic stroke risk with HRT: conventional ischemic stroke risk factors.
3. Prescribing HRT in 2007.
 - (a) HRT is not recommended for routine use in prevention of chronic conditions⁵³.
 - (b) HRT may be considered for use in specific patients for relief of vasomotor symptoms and vaginal atrophy⁵⁴.

Table 17.4 Ischemic stroke risk with hormone replacement therapy⁴⁹

Clinical study	Relative risk of ischemic stroke
Heart and Estrogen/Progestin Study (HERS) ⁵⁰	1.18 (NS)
Women Estrogen Stroke Trial (WEST) ⁵¹	1.00
Women's Health Initiative (WHI) ⁵² (estrogen/progestin arm)	1.44 ^a

^aAbsolute risk of ischemic stroke in the treatment cohort is low: 8/10,000 women per year of HRT

17.4.29. Hyperhomocysteinemia

Plasma homocysteine levels >10 μ M correlate with increased risk of ischemic stroke and coronary ischemia, but studies to date have shown no reduction in ischemic events with vitamin treatment.⁵⁵ Although the hypothesis that lowering homocysteine reduces ischemic stroke risk requires further study,^{56, 57} due to low risk and cost of standard vitamin formulations, it seems reasonable to encourage vitamin use in patients with ischemic stroke and hyperhomocysteinemia.⁹

17.4.30. Hypertension

Hypertension is one of the major risk factors for ischemic stroke. Multiple clinical investigations and meta-analyses have shown that controlling hypertension leads to reduction in stroke risk.^{9, 10}

1. Prevalence of hypertension: estimated >50 million Americans.
2. Classification of blood pressure (BP) ranges⁵⁸.

Diagnosis of hypertension			
	Systolic BP (mmHg)		Diastolic BP (mmHg)
Normal BP	<120	and	<80
Prehypertension	120–139	or	80–90
Hypertension, stage 1	140–159	or	90–99
Hypertension, stage 2	\geq 160	or	\geq 100

3. Stroke (ischemic and hemorrhagic) risk with hypertension.
 - (a) Increases with increasing systolic and diastolic BP.
 - (b) Antihypertensive treatment is effective in primary and secondary ischemic stroke prevention⁵⁹.
 - Stroke (including cerebral hemorrhage), nonfatal stroke, combined vascular events: 20–25% reduction.
 - (c) Class effects⁵⁹.
 - β -blockers: no effect on stroke risk.
 - Diuretics: 32% reduction in stroke risk.
 - ACE inhibitors: 26% reduction in all vascular events.
 - Diuretics and ACE inhibitors: 40–45% reduction in stroke, MI, all vascular events.
3. Management of hypertension.
 - (a) Antihypertensive medications should be used for primary prevention of ischemic stroke⁵⁸.
 - General goal BP in patients without concomitant diabetes or renal disease: <140/90 mmHg.
 - Goal in patients with concomitant diabetes or renal disease: <130/80 mmHg.

- There is probably continued benefit with further decrease to 120/80 mmHg.
- (b) Antihypertensive medications should be used for secondary prevention in patients with cerebral infarcts or transient ischemic attack⁹.
 - Timing.
 - In the hyperacute period after ischemic stroke, BP is naturally increased.
 - Lowering BP in the hyperacute period correlates with increased morbidity and mortality.
 - Gentle initiation within the first week after ischemic stroke is probably safe in most patients, although the decision to start therapy and the class of drugs must be individualized (see “Acute Ischemic Stroke: Treatment” section).
 - Deferral of therapy initiation, or prolongation of the time period over which goal BP are reached, may be appropriate in patients with a BP-dependent neurologic examination or intracranial or extracranial arterial stenosis.
 - Goal BP⁹.
 - Insufficient data to make absolute, one-size -fits-all recommendation.
 - Goals and therapy must be individualized.
 - Initial reduction of 10/5 mmHg is desired.
 - Preferred agents⁵⁸.
 - Unless contraindicated, thiazide diuretics in combination with ACE inhibitors are good initial agents in patients with TIA or ischemic stroke.
 - Lifestyle changes⁵⁸.
 - Facilitate BP control.
 - (a) Weight loss.
 - (b) Diet: low sodium, high potassium and calcium.
 - (c) Aerobic exercise regimen.
 - (d) Limitation of alcohol intake.

17.4.31. Hypercoagulability

See “Coagulopathy” section.

17.4.32. Hyperviscosity syndromes

Hyperviscosity is a rare cause of cerebral ischemia. Hematologic conditions in which increased blood viscosity (but also thrombophilia) may play a role in the pathogenesis of cerebral ischemia include essential thrombocythemia, polycythemia vera, myeloma, leukemia, thrombotic thrombocytopenic purpura, and Waldenström’s macroglobulinemia.⁶⁰ Sickle cell disease and other hemoglobinopathies affect blood viscosity during crises, but additional mechanisms are also responsible for ischemic stroke risk (see “Sickle Cell Disease” section). Many conditions including ischemic stroke are associated with elevated fibrinogen levels. A recent Cochrane review concluded that there are insufficient data on the use of fibrinogen depleting agents in ischemic stroke, and further studies are required.⁶¹

17.4.33. Infections

Infections with specific organisms have been implicated in the pathogenesis of atherosclerosis, although data are sparse on treatment of infections as a means of stroke prevention.⁶² Minocycline, an antibiotic, may eventually be proven effective in the treatment of acute ischemic stroke, although its putative mechanism of action may not be related to its antimicrobial activity.⁶³

17.4.34. Inflammation

Inflammation plays a role in atherosclerosis, as well as in the pathophysiology of acute and subacute ischemic stroke. Similar to infections discussed, not enough data are currently available to make recommendations on specific screening and anti-inflammatory treatment regimens in stroke prevention (see also “C-Reactive Protein” section).

17.4.35. Intima media thickness (IMT)

Measurement of carotid IMT on ultrasonography is currently under investigation as a marker of atherosclerosis, surrogate vascular endpoint, and predictor of ischemic stroke risk.⁶⁴

17.4.36. Lipid disorders

3-hydroxy-3-methylglutaryl coenzyme A (HMGCoA) reductase inhibitors (statins) have been shown to decrease stroke risk in patients with cardiac disease, in a manner related to the degree of LDL cholesterol lowering.⁹ Furthermore, withdrawal of statins in the acute phase of ischemic stroke results in increased mortality and neurologic disability.⁶⁵ The recent Stroke Prevention by Aggressive Reduction in Cholesterol Levels (SPARCL) trial was designed to determine whether atorvastatin at a dose of 80 mg daily prevented strokes in patients with previous stroke (ischemic or hemorrhagic) or TIA and LDL levels 100–190 mg dL⁻¹ without coronary heart disease.⁶⁶

1. SPARCL study.
 - (a) Results, at a median 4.9 years of follow up.

SPARCL study results ⁶⁶			
Selected outcomes	Atorvastatin, 80 mg	Placebo	P value
Nonfatal or fatal stroke ^a	11.2%	13.1%	0.03
Stroke or TIA	15.9%	20.1%	<0.001
Major coronary event	3.4%	5.1%	0.003
Death	9.1%	8.9%	NS
Rhabdomyolysis	0.08%	0.13%	NS
Transaminase elevation >3× normal	2.2%	0.5%	<0.001

^aIschemic and hemorrhagic: 67.4 and 65.9% of strokes were ischemic in the atorvastatin and placebo groups, respectively; there may be a relationship between statin use and increased risk of cerebral hemorrhage, but further studies are required⁶⁷

2. Management of hyperlipidemia in patients with ischemic stroke⁹.
 - (a) Patients with stroke or transient ischemic attack who are at very high risk for *cardiovascular* disease (those with established cardiovascular disease and multiple risk factors or poorly controlled risk factors or metabolic syndrome [see later] or acute coronary events): goal LDL cholesterol <70 mg dL⁻¹.
 - (b) Other patients with ischemic stroke or transient ischemic attack.
 - Patients with coronary disease and hyperlipidemia: statin agents, lifestyle modifications to achieve goal LDL cholesterol <100 mg dL⁻¹.
 - Patients with LDL cholesterol 100–190 mg dL⁻¹ and no known coronary disease: atorvastatin 80 mg daily (SPARCL).
 - Patients with HDL cholesterol ≤40 mg dL⁻¹: consider niacin or gemfibrozil.
3. Mechanisms of statin benefit beyond lipid lowering⁶⁸.

Mechanisms of statin action in the ischemic brain
Augmentation of collateral flow ⁶⁹
Improvement of endothelial reactivity
Anti-inflammatory and antioxidant activity
Stabilization of atherosclerotic plaques
Stimulation of neural progenitor cells (neurorepair)

4. Additional ischemic stroke risk factors related to lipid metabolism.⁹
 - (a) Lipoprotein a: elevation is associated with increased risk of ischemic stroke.
 - (b) Apolipoprotein a1 (component of HDL): cardioprotective; low levels may increase risk of developing carotid atherosclerosis.
 - (c) Apolipoprotein b (component of LDL): high levels may be associated with carotid atherosclerosis.
 - (d) HDL: low HDL cholesterol is associated with an increased risk of vascular ischemic events.

17.4.37. Metabolic syndrome

Metabolic Syndrome refers to the clustering of vascular risk factors in certain individuals and includes *hypertriglyceridemia*, *low HDL*, *hypertension*, *abdominal obesity*, and *insulin resistance*. Individuals with metabolic syndrome have an increased risk of ischemic stroke.⁷⁰

17.4.38. Malignancy

Patients with systemic cancer harbor conventional, as well as cancer-specific, risk factors for cerebrovascular disease. The cancer-specific risk factor for stroke is most often hypercoagulability.⁷¹

1. Prevalence of ischemic stroke in cancer patients: 0.12% of all admissions to Memorial Sloan–Kettering Cancer Center.
2. Traditional risk factors in patients with cancer.
 - (a) Hypertension: 53%.
 - (b) Tobacco use: 32%.
 - (c) Diabetes mellitus: 19%.
 - (d) No identified risk factors other than cancer: 15%.
3. Ischemic stroke mechanisms in patients with cancer.
 - (a) Embolic (54%).
 - Atrial fibrillation.
 - Ventricular thrombus.
 - Bacterial endocarditis.
 - Nonbacterial thrombotic endocarditis.
 - (b) Nonembolic (46%).
 - Small vessel disease: 12%.
 - Large vessel disease: 10%.
4. Management of stroke risk in patients with cancer.
 - (a) Secondary prevention of stroke: antiplatelet agents, anticoagulation in selected patients, antihypertensive drugs, cholesterol-lowering medications, smoking cessation.
5. Prognosis after ischemic stroke in patients with cancer.
 - (a) Median overall survival: 4.5 months.
 - (b) Factors affecting survival.
 - Stroke severity.
 - Mechanism: worst for embolic infarcts.
 - Primary cancer: worst for lung cancer.
 - Presence of metastatic disease.

17.4.39. Migraine

The relationship between ischemic stroke and migraine is complex: migraines may be triggered by cerebral infarction; migraines may cause cerebral infarction (*migrainous infarct*); migraine disorders and conventional ischemic stroke risk factors may coexist in a patient; and patients may have diseases which predispose both to migraines and ischemic stroke (see “CADASIL” and “MELAS” sections).

1. Prevalence of migrainous infarcts⁷².
 - (a) 0.5–1.5% of ischemic strokes overall.
 - (b) 10–15% of ischemic stroke in patients <45 years old.
2. Criteria for diagnosis of migrainous infarct.
 - (a) Diagnostic criteria⁷³.
 - Patient must have previously met diagnostic criteria for migraine with aura.
 - One or more symptoms of focal neurologic dysfunction (aura) developing gradually over more than 4 min, lasting less than 60 min with headache occurring before, after, or simultaneously with aura.
 - Current attack similar to typical attacks, but focal neurologic symptoms not reversible and imaging confirms ischemic infarction.
 - Diagnostic evaluation rules out other etiologies of cerebral infarction.
3. Ischemic stroke risk with migraines⁷⁴.
4. Mechanisms of cerebral ischemia in patients with migraines.

Ischemic stroke risk with migraine ⁷⁴	
Migraine classification	RR (CI)
Migraine, general	2.16 (1.89–2.48)
Migraine with aura	2.27 (1.61–3.19)
Migraine without aura	1.83 (1.06–3.15)
Female migraineurs <45 years old	2.76 (2.17–3.52)
Migraine with oral contraceptive use	8.72 (5.05–15.05)

- (a) Increased risk of ischemic stroke⁷².
 - Migrainous infarct: probably too infrequent to account for the entirety of increased risk.
 - Vasoconstrictive drugs used for migraine treatment.
 - Conflicting data on triptans and ergots.
 - Association with other stroke risk factors.
 - Patent foramen ovale: Invoked as a cause of migraines *and* ischemic strokes largely by virtue of association; this hypothesis is currently being investigated (see also “Patent Foramen Ovale” section).
 - Cervical vascular dissection: Migraine is more common in these patients, RR 3.6 (1.5–8.6) with a single, and 6.7 (1.9–24.1) with multiple, dissections; the mechanistic connection between migraine and dissection is unclear.
- (b) Migrainous infarct: The mechanism is unknown, but two have been postulated.
 - Neuronal spreading depression during aura is associated with decreased cerebral blood flow sometimes to levels right at, or slightly below, the ischemic threshold.
 - Transient cerebral arterial spasm during migraine may result in cerebral hypoperfusion.
5. Management of ischemic stroke patients with migraines⁷².
 - (a) Conventional ischemic stroke risk factors should be fully investigated in migraineurs before diagnosing a migrainous infarct.
 - (b) Risk factors in migraineurs with ischemic stroke should be modified.
 - Smoking cessation.
 - Control of hypertension.
 - Discontinuation of oral contraceptives.
 - Avoidance of triptans and ergots.

17.4.40. Mitochondrial diseases, including MELAS

The mitochondrial disorders are a heterogeneous group of hereditary diseases affecting mitochondrial function. Involvement of the peripheral and central nervous systems is common; onset may be at any time during life. *Stroke-like episodes* have been observed in mitochondrial encephalomyopathy, lactic acidosis, stroke-like episodes (MELAS); myoclonic epilepsy and ragged red fibers (MERFF); and Kearns-Sayre Syndrome (KSS). Frequently, episodes occur in close temporal association with migraine. Stroke-like episodes are thought to occur due to energy metabolism exhaustion, rather than a vascular cause, resulting in focal neurological deficits. MRI findings are suggestive of a predominant component of vasogenic, rather than cytotoxic, edema. Lesions are not in typical vascular territories.

1. Prevalence of mitochondrial disease (estimated prevalence near Madrid, Spain): 5.7 per 100,000 in people >14 years old⁷⁵.
2. Approach to diagnosis of mitochondrial diseases⁷⁶.
 - (a) Rule out other more common disorders.
 - (b) Evaluation in suspected mitochondrial disorders.
 - History: Determine degree of CNS, PNS, and organ involvement, family history.
 - Blood testing: Lactate, pyruvate, hypothalamic-pituitary axis hormones.
 - CSF: Lactate, pyruvate.
 - Imaging: CT (atrophy, basal ganglia calcifications, white matter hypodensities, largely nonspecific); MRI (most common findings discussed earlier); MR spectroscopy (increased lactate peaks).
 - EEG: No pathognomonic patterns, but seizures have been observed in 40–50% of mitochondrial disorders vi. EMG/NCS: normal, myopathic, or combined features may be seen; neuropathy (usually axonal sensory-motor) can be seen in up to 25% of patients.
 - Muscle/nerve biopsy: May yield pathognomonic features.
 - Brain biopsy: Immunohistochemical evaluation may suggest reduced levels of respiratory chain components; electron microscopy may reveal structurally abnormal mitochondria.
 - DNA testing: Various specific mutations in mitochondrial or nuclear DNA have been identified and can be used to make the diagnosis.
3. Management of mitochondrial disease⁷⁶.
 - (a) No specific treatments, aside from some symptomatic therapies based on case reports, are currently available.
 - (b) Avoidance of drugs which inhibit the respiratory chain, e.g., valproate, barbiturates, tetracyclines, and phenothiazines, seems prudent.
4. Prognosis in mitochondrial diseases⁷⁶.
 - (a) Subclinical disorder may appear during times of mitochondrial stress, e.g., infection.
 - (b) Course is usually progressive once disease becomes clinically apparent, with eventual multiorgan involvement and death.
 - (c) Death in patients with mitochondrial disease with CNS manifestations is usually in the third decade⁷⁵.

17.4.41. Moya-Moya disease and syndrome

Discussed in Chap. 18; see also “Sickle Cell Disease” section.

17.4.42. Nutrition

Diets high in sodium may exacerbate hypertension; diets high in carbohydrates may worsen blood glucose control in patients with diabetes; and overeating may lead to obesity (see later). Thus, nutritional counseling should be offered to ischemic stroke patients, especially those harboring multiple ischemic stroke risk factors.

17.4.43. Obesity

Obesity is associated with well-established risk factors for ischemic stroke including hypertension and diabetes. While there are no studies showing that weight reduction is beneficial in reducing stroke risk per se, weight reduction lowers blood pressure and blood glucose.⁹

AHA 2006 Recommendation¹⁰

In patients with ischemic stroke or TIA, weight reduction to a goal of 18.5–24.9 kg m⁻² Body Mass Index is recommended.

17.4.44. Obstructive sleep apnea (OSA)

OSA has been increasingly recognized as a condition which coexists with, and may actually cause or exacerbate, other medical disorders, including hypertension, pulmonary hypertension, diabetes mellitus, and gastroesophageal reflux disease.⁷⁷ OSA is characterized by repetitive episodes of upper airway obstruction during sleep, during which arterial oxygen levels may decrease and carbon dioxide levels may increase. Awakening during these episodes is associated with resumption of respiration and transient elevations in blood pressure.

OSA and risk of stroke are strongly associated, and OSA prevalence is high in patients with acute ischemic stroke.⁷⁸ OSA may increase stroke risk indirectly by exacerbating systemic hypertension or directly through effects on the cerebral vasculature. It is hypothesized that hypercapnea and hypoxia during apneic episodes may over time affect cerebral vasoreactivity and cause endothelial dysfunction and platelet activation. Whether use of continuous positive airway pressure (CPAP) affects stroke risk, recovery or mortality after stroke is currently under investigation. CPAP should be used cautiously in acute stroke patients, especially in those who are at risk of aspiration.

17.4.45. Oral contraceptives (OCP)

OCP are associated with increased stroke risk.^{49, 79} The level of risk at any one time in any one patient may be influenced by: formulation (estrogen or progestin or combination; specific dose and type of estrogen or progestin); duration of use; current vs. remote use; and associated conditions (see later).

1. Stroke risk probably results from OCP-related hypercoagulable state, hypertension, and/or alteration of lipid metabolism.
2. Mechanisms of cerebral ischemia with OCP.
 - (a) Venous thrombosis and embolism.
 - Paradoxical embolism.
 - Cerebral sinus or venous thrombosis.
 - (b) Arterial thrombosis.

Related to hypertension and/or alteration of lipid metabolism.
3. Level of ischemic stroke risk with OCP use⁷⁹.
 - (a) Definitions.
 - High-dose estrogen: $\geq 50 \mu\text{g}$.
 - Low-dose estrogen: $< 50 \mu\text{g}$.
 - (b) Role of progestin OCP.
 - Conflicting stroke risk data for estrogen- and progestin-containing OCP.
 - Possibly lower risk with progestin-only OCP compared to estrogen-only or combined OCP.
 - (c) Ischemic stroke rates in women of child-bearing age.
 - Compiled from meta-analyses.

Ischemic stroke risk with oral contraceptive use ⁷⁹	
	Incidence of ischemic stroke
Women of child-bearing age <i>without</i> OCP use	4.4/100,000
Women of child-bearing age using OCP	8.5/100,000 NNH = 1 ischemic stroke/24,000 women treated with OCP

4. Conditions elevating stroke risk in OCP users include hypertension, cigarette smoking, migraines, and age >35 years old.
5. Prescribing guidelines for OCP.
 - (a) Several professional organizations including World Health Organization and the AHA have released OCP-prescribing guidelines.
 - (b) The American College of Obstetrics and Gynecology's (ACOG) Practice Bulletin (2006) presents a comprehensive, measured approach to prescribing OCP on a case-by-case basis to women with coexisting medical conditions which elevate stroke risk.⁸⁰

17.4.46. Patent foramen ovale (PFO)

The relationship between cardiac septal abnormalities and cerebral ischemia is controversial. Of septal abnormalities found in adults, PFO is the most common,¹² and a higher incidence of PFO in young patients with cryptogenic ischemic stroke generated the hypothesis that PFO is causal in ischemic stroke. Recently, PFO was also found to be more prevalent in older (≥ 55 years old) patients with cryptogenic ischemic stroke.⁸¹ Unfortunately, many physicians have accepted this hypothesis as a proven fact (guilt by association) and have advocated PFO closure as a means of stroke prevention. PFO closure in patients with recurrent ischemic stroke despite medical therapy is currently under investigation.

1. Prevalence of PFO⁸¹.
 - (a) Normal population: 20–25%.
 - (b) 43.9% in patients <55 years old with cryptogenic ischemic stroke vs. 14.3% in those with stroke from a known conventional cause.
 - (c) 28.3% in patients ≥ 55 years old with cryptogenic ischemic stroke vs. 11.9% in those with stroke from a known conventional cause.
2. Potential mechanisms of ischemic stroke with PFO.
 - (a) Deep venous thrombosis and paradoxical embolism.
 - Rarely proven to be the case in clinical practice.
 - (b) Local thrombosis nearby or within the PFO with subsequent embolism.
 - Possibly increased by presence of atrial septal aneurysm (ASAN) (see Table 17.5).
 - (c) Arrhythmia (most likely AF) and subsequent embolism.
 - Possibly increased by presence of ASAN.
3. Ischemic stroke recurrence with PFO.
 - (a) Prospective registry of patients <55 years old with cryptogenic ischemic stroke, treated primarily with antiplatelet therapy.⁸²
4. Management of PFO⁹.
 - (a) Antiplatelet therapy for secondary ischemic stroke prevention.

Table 17.5 Ischemic stroke recurrence with patent foramen ovale⁸²

	Patients with recurrent ischemic stroke or TIA (%)			
	1 year	2 years	3 years	4 years
No PFO	3.0	4.7	5.2	6.2
PFO	3.7	4.6	5.6	5.6
PFO + ASAN	5.9	8.0	10.3	19.2

- (b) Warfarin sodium for patients with concomitant indications for anti coagulation, e.g., documented hypercoagulable state and/or deep venous thrombosis.
- (c) PFO closure may be considered if ischemic strokes recur despite maximal medical therapy; otherwise PFO closure should be offered only as part of a clinical trial.

17.4.47. Physical inactivity

Risk of ischemic stroke is reduced with moderate physical activity, probably due to beneficial effects on blood pressure, weight, and glucose metabolism.

AHA 2006 Recommendation¹⁰

In ischemic stroke patients, at least 30 min daily, if tolerated, of physical exercise appropriate for each individual patient is recommended.

17.4.48. Sickle cell disease (SCD)

SCD affects approximately 70,000 Americans. There are four common genotypes of SCD, with hemoglobin S homozygosity (HbSS) being most frequent in the US.⁸³ SCD predisposes to both ischemic (primarily in children) and hemorrhagic (primarily in adults) stroke. Up to 22% of children experience *silent infarctions*: MRI lesions consistent with infarct which appear without concomitant clinical symptoms and signs.⁸⁴

1. Incidence of ischemic stroke in SCD⁸⁵.
 - (a) If transcranial Doppler (TCD) velocity in distal ICA or proximal MCA $\geq 200 \text{ cm s}^{-1}$ in untreated patient: 10–13% per year.
 - (b) Overall, 7–11% of children with HbSS will have a stroke.
2. Mechanisms of ischemic stroke in SCD.
 - (a) Increased blood viscosity and adherence to the endothelium of sickled cells resulting in occlusion of capillaries.
 - (b) Chronic activation of coagulation pathways, including platelet activation.
 - (c) Depletion of nitric oxide with subsequent endothelial dysfunction.
 - (d) Progressive obliterative and proliferative vasculopathy.
 - May result in moya-moya syndrome (see Chap 18) characterized by distal internal cerebral artery and proximal middle cerebral artery stenosis/occlusion with ischemic stroke due to thromboembolism or hemodynamic insufficiency.
 - Secondary angiogenesis, usually within the basal ganglia near the ICA trifurcation, may predispose to hemorrhage in adulthood.
3. Primary prevention of ischemic stroke in SCD.
 - (a) Transfusion.
 - Distal ICA/proximal MCA TCD velocity $\geq 200 \text{ cm s}^{-1}$ predicts ischemic stroke risk.
 - Benefit: 92% reduction in stroke risk and normalization of TCD velocities⁸⁶.
 - Goal: Reduce proportion of hemoglobin S to <30% and normalize TCD velocities.
 - Risk: May lead to hemosiderosis, venous access difficulty, and other complications.
 - (b) Hydroxyurea.
 - Increases proportion of fetal hemoglobin (HbF).
 - HbF does not incorporate into HbS polymer (less sickling).
 - Increasing HbF decreases proportion of HbS, which is protective.
 - Other beneficial effects: Decrease in white blood cell count and blood rheology; enhanced vascular reactivity.
 - Decreases TCD velocities.
 - Decreases stroke risk⁸⁷.

- Hydroxyurea/phlebotomy: 5.7 strokes per 100 patient-years.
 - Hydroxyurea with transfusion during hydroxyurea titration: 3.6 strokes per 100 patient-years.
4. Secondary prevention of ischemic stroke in SCD.
- (a) Transfusion⁸⁸.
- Goal: reduce hemoglobin S to <30% of total and increase total hemoglobin to >10 g dL⁻¹.
 - Erythrocytapheresis (exchange transfusion) is the treatment of choice acutely.
 - Manual exchange transfusions and simple transfusions may be utilized chronically.
- (b) Hydroxyurea.
- (c) Hematopoietic stem cell transplantation.
- Currently under investigation⁸⁸.
5. Ischemic stroke recurrence in SCD.
- (a) As high as 23% of patients treated with transfusion.
- Fifty-seven percent of patients undergoing simple transfusion.
 - Twenty-one percent of patients undergoing exchange transfusion.

17.4.49. Tobacco, smoked

Smoking tobacco-containing cigarettes increases ischemic stroke risk independent of other risk factors.⁹ This risk decreases to baseline five years after smoking cessation.

Drugs to help stop smoking: Bupropion and varenicline

Bupropion SR (Zyban[®], GlaxoSmithKline, Research Triangle Park, N.C.) has been shown to effectively improve smoking cessation rates^{89,90} by its effect on nicotine craving. Standard dose is 150-mg tablets, 1 tablet once a day for 3 days, then 1 tablet twice a day for 7–12 weeks. Higher doses should not be used for smoking cessation. The patient should follow the instructions in the package insert, and quit smoking after being on Zyban for 1 week, to allow a steady-state blood level to be achieved. Common side effects are dry mouth and insomnia, which are usually self-limited. The most common major adverse effect is seizures, particularly in patients with a history of seizures or other conditions which may lower the seizure threshold.

Varenicline (Chantix[™] in the US and Champix[®] in Europe, Mexico, and Canada; Pfizer, New York, NY) is a partial agonist of the $\alpha 4\beta 2$ subtype of the nicotinic acetylcholine receptor, which has been shown to improve smoking cessation rates.^{91, 92} Since its introduction in 2006, varenicline has become more popular than bupropion because of its better side effect profile and greater effectiveness (see Table 17.6). It is, however, more expensive.

Standard varenicline dose is 0.5-mg tablets, 1 tablet once a day for 3 days, then 1 tablet twice a day for 4 days, then 2 tablets twice a day for 12 weeks. If smoking cessation has not been achieved it may be continued for another 12 weeks. Side effects are uncommon but may include nausea, headache, flatulence, and insomnia.^{90, 93}

Table 17.6 Varenicline effect in smoking cessation⁹¹

Abstinence from smoking at 12 months	OR (CI)
Varenicline vs. placebo	3.22 (2.43–4.27)
Varenicline vs. bupropion	1.66 (1.28–2.16)

AHA 2006 Recommendation¹⁰

All smokers with ischemic stroke should be counseled on smoking cessation, and smoking-cessation aids including nicotine delivery devices, such as gum and patches, and pharmacologic agents should be recommended.

17.4.50. Valvulopathies

Abnormalities of cardiac valves may lead to ischemic stroke. Mitral valve prolapse (MVP) is the most common valvulopathy in adults and is thought to be a cause of cerebral embolism in *rare* patients with cryptogenic stroke. MVP may also predispose to bacterial endocarditis. Mitral annular calcification (MAC) may be linked with cardiac conduction abnormalities and is thought to be a risk factor for cardioembolism. Prosthetic mechanical valves are extremely thrombogenic and require life-long anticoagulation with warfarin sodium. Rheumatic mitral valve disease and other valvulopathies may be associated with atrial fibrillation, dramatically increasing the risk of cardioembolism.

1. Ischemic stroke risk with valvulopathies⁹
 - (a) Rheumatic mitral valve disease, recurrent embolism: 30–65%, most within 6 months of initial event.
 - (b) Mechanical prosthetic heart valves: Four percent per year without anticoagulation; 1% per year with anticoagulation⁹⁴.
 - (c) Bioprosthetic valves: One percent per year, risk highest within 3 months of valve replacement surgery⁹⁴.
 - (d) MVP, MAC, aortic valve disease: risk is not well defined.
2. Management of ischemic stroke risk in patients with valvulopathies.
 - (a) Rheumatic heart disease.
 - Primary prevention⁹⁵
 - With atrial fibrillation: Life-long warfarin therapy, goal INR 2–3.
 - With mitral or tricuspid stenosis and sinus rhythm with enlarged atrium or atrium with clot: Long-term warfarin therapy, goal INR 2–3.
 - Referral for valve repair.
 - Secondary prevention⁹
 - Long-term warfarin therapy, goal INR 2–3.
 - Addition of ASA, 81 mg per day, to warfarin in cases of recurrent embolism despite proper warfarin anticoagulation.
 - (b) Prosthetic heart valves⁹
 - Modern mechanical valves.
 - Life-long anticoagulation with warfarin, goal INR 2.5–3.5.
 - Addition of ASA, 75–100 mg per day, in to warfarin in cases of thromboembolism despite proper warfarin anticoagulation.
 - A higher INR goal (3–4.5) may be considered for caged ball or disk valves⁹⁴.
 - Bioprosthetic valves.
 - Primary prevention: If mitral bioprosthetic valve, oral anticoagulation to goal INR 2–3 for 3 months after surgery, then ASA 325 mg per day if in sinus rhythm; same approach may be considered for aortic bioprosthetic valves.⁹⁴
 - Secondary prevention: Long-term warfarin therapy, goal INR 2–3.
 - (c) MAC, MVP, aortic valve disease: Consider antiplatelet therapy in the setting of TIA or ischemic stroke⁹.

17.4.51. Vasculitis

The vasculitides are inflammatory vasculopathies. CNS vasculitis may be associated with a systemic vasculitis; it can be primary, i.e., isolated to the CNS; or it can be related to a connective tissue disease or another systemic disease process.^{96,97} Vasculitides can be classified according to many schemes, including size of predominantly involved blood vessels (small, medium, or large) or type of pathologic process (necrotizing, immune complex-mediated, granulomatous, etc.).

Classification of selected primary systemic vasculitides ⁹⁸		
Vessel size	Pathophysiology	Examples
Large (aorta, large arteries)	Granulomatous vasculitis	Giant cell arteritis Takayasu arteritis

(continued)

Medium (arteries, arterioles)	Necrotizing arteritis	Polyarteritis nodosa
Small (arterioles, capillaries, venules, veins)	Vascular immune complexes	Lupus vasculitis
		Rheumatoid vasculitis
	Rare vascular immune complexes	Wegener's granulomatosis
		Churg–Strauss syndrome

CNS involvement with vasculitis generally presents with a prolonged and progressive functional decline, encephalopathy, seizures, and cerebral ischemic and hemorrhagic lesions.^{96, 97} Although “vasculitis” is often invoked when interpreting cerebral angiograms showing features characteristic of inflammatory vasculopathy, it is important to keep in mind that the diagnosis of CNS vasculitis cannot be made solely on the basis of angiography. Vasculitis is a pathologic diagnosis; and in the absence of a tissue diagnosis, appropriate clinical history, physical exam findings, CSF, and other laboratory values, along with appropriate imaging,⁹⁹ are required to make the diagnosis.

1. Systemic vasculitis.

(a) Giant cell arteritis (aka temporal arteritis, Horton's disease, Hutchinson-Horton disease).

- Characteristics.
 - Most common primary vasculitis in adults >50 years old.
 - Perivascular inflammation leads to intimal hyperplasia, usually without thrombosis.
 - Largely extracranial involvement, but 20–50% can present with vision loss or ischemic stroke¹⁰⁰.
 - Headache is most common symptom; occurs in 65–75% of patients¹⁰¹.
 - Scalp tenderness and jaw claudication may occur and are highly suggestive of the diagnosis.
- Associated findings.
 - Elevated erythrocyte sedimentation rate (ESR); normal ESR may not be meaningful if clinical suspicion is strong¹⁰².
- Diagnostic criteria (3 of 5 required)¹⁰¹.
 - Age of onset ≥50.
 - New onset or new type of headache.
 - Temporal artery tenderness or attenuated pulsation.
 - Westergren ESR >50 mm h⁻¹.
 - Positive temporal artery biopsy⁹⁸.
- Management.
 - Immune suppression with corticosteroids.
 - Antithrombotic therapy may be considered in patients with ischemic stroke¹⁰⁰.

(b) Takayasu arteritis (aka pulseless disease).

- Characteristics.
 - Involves aorta and branches, but intracranial involvement may occur.
 - Media and adventitia thickening leads to stenosis and occlusion.
 - Neurologic symptoms are usually transient (TIA), although cerebral infarcts can also occur¹⁰³.
- Associated findings.
 - Exacerbation of the disease may be associated with elevations in ESR.
- Diagnostic criteria (3 of 6 required)¹⁰⁴.
 - Age <40 years at onset.
 - Extremity claudication.
 - Decreased brachial artery pulse.
 - >10-mmHg blood pressure difference between arms.
 - Bruit over subclavian artery.
 - Abnormal arteriogram.
- Management.
 - Immune suppression with corticosteroids.
 - Cyclophosphamide, azathioprine, methotrexate, or others may be necessary.

- (c) Polyarteritis nodosa (PAN).
- Characteristics.
 - Most common of the necrotizing vasculitides.
 - Features destruction of the vessel wall and aneurysm formation.
 - Organs involved include brain, nerves, skeletal muscle, heart, and kidney.
 - Microangiopathic brain involvement is more common than medium cerebral vessel vasculitis¹⁰⁵.
 - Associated findings.
 - Hepatitis may be present.
 - Peripheral nerve involvement is usually a *mononeuropathy multiplex* (scattered, asymmetric involvement of nerves at multiple sites).
 - Diagnostic criteria (3 of 10 required)¹⁰⁶.
 - Weight loss ≥ 4 kg.
 - Livedo reticularis.
 - Testicular tenderness.
 - Myalgias, weakness, leg tenderness.
 - Mono- or polyneuropathy.
 - Diastolic blood pressure >90 mmHg.
 - Elevation of blood urea nitrogen or creatinine.
 - Hepatitis B surface antibody or antigen positive.
 - Arteriogram with visceral artery aneurysms or occlusion.
 - Biopsy showing granulocytes, or granulocytes and monocytes in the artery wall.
 - Management.
 - Immune suppression with corticosteroids.
 - Cyclophosphamide, azathioprine, methotrexate, or others may be necessary.
- (d) Wegener's granulomatosis (aka necrotizing granulomatosis with polyangiitis).
- Characteristics.
 - Necrotizing vasculitis.
 - Granulomatous infiltration of the respiratory tract and necrotizing glomerulonephritis.
 - Associated findings.
 - Presence of circulating antineutrophil-cytoplasmic antibodies (cANCA).
 - Generalized disease: in addition to lung and kidney involvement, manifests with arthritis, palpable purpura, neuropathy, and *rarely* cerebral infarction (infarcts may be due to nonbacterial thrombotic endocarditis or cerebral vasculitis).¹⁰⁷
 - Diagnostic criteria (2 of 4 required).¹⁰⁸
 - Oral ulcers or purulent or bloody nasal discharge.
 - Chest X-ray showing nodules, infiltrates, or cavities.
 - Microhematuria or red cell casts in urine.
 - Biopsy with granulomatous inflammation within or around artery or arteriole.
 - Management.
 - Immune suppression with corticosteroids.
 - Cyclophosphamide, azathioprine, methotrexate, or others may be necessary.
- (e) Churg–Strauss vasculitis (aka allergic granulomatous angiitis).
- Characteristics.
 - Necrotizing vasculitis.
 - Respiratory system involvement.
 - Rare cerebral infarction due to eosinophilic cerebral vasculitis.¹⁰⁹
 - Associated findings.
 - Eosinophilia, pulmonary infiltrates, nasal polyps, skin rash, and GI disturbances.
 - Diagnostic criteria (4 of 6 required)^{110, 111}.
 - Asthma.
 - Peripheral eosinophilia $>10\%$ of total white blood count.
 - Peripheral neuropathy due to vasculitis.
 - Transient pulmonary infiltrates.

- Paranasal sinus abnormalities.
 - Biopsy showing eosinophils around blood vessels.
 - Management.
 - Immune suppression with corticosteroids.
 - Cyclophosphamide, azathioprine, methotrexate, or others may be necessary.
2. Primary CNS vasculitis (aka CNS angiitis, CNS granulomatous angiitis, primary angiitis of the CNS, isolated angiitis of the CNS)^{96, 112, 113}.
- (a) Characteristics.
- Involvement of cortical and leptomeningeal vessels, usually small arteries.
 - Segmental granulomatous angiitis.
 - T-cell mediated process.
- (b) Clinical features¹¹².
- Slight male predominance (4M:3F), onset usually in middle age.
 - Presentation typically subacute, evolving over weeks to months with headache, cognitive decline, encephalopathy, seizures, focal neurologic deficits.
- (c) Diagnostic criteria¹¹².
- Definite.
 - Brain biopsy showing perivascular granulomatous infiltrates.
 - Possible.
 - Arteriogram with vascular beading.
 - Neurologic decline for at least three months.
 - Increased CSF protein and leukocyte count
 - a. Exclusion of other diseases.
 - Brain biopsy: Although cortical and leptomeningeal biopsy may sometimes be negative (due to missing inflammatory foci with the biopsy needle), it is important to perform it, *especially if the patient is declining and cyclophosphamide therapy is being contemplated*, as biopsy may provide an alternate diagnosis such as intravascular lymphoma.
- (d) Management.
- Immune suppression with corticosteroids; in some cases cyclophosphamide may be necessary.
3. Secondary CNS vasculitis^{96, 97}.
- (a) Vasculitis associated with CNS infections.
- Characteristics.
 - Inflammatory exudates around arteries result in fibrosis and constriction or direct vascular infection/invasion results in luminal stenosis.
 - Selected infections associated with CNS vasculitis.
 - *Meningovascular syphilis* (aka Heubner's arteritis) involving small and medium-sized vessels.
 - *Basilar meningitis* with *M. tuberculosis* or fungi involving the basilar artery and pontine perforators.
 - Bacterial meningitis with involvement of pial vessels.
 - Varicella zoster vasculitis.

Varicella Zoster Vasculitis

Reactivation of latent varicella zoster virus (VZV) usually occurs in patients >60 years old and may or may not cause the characteristic dermatomally distributed rash. In immunocompetent hosts, VZV reactivation in the trigeminal ganglia may sometimes be followed several weeks later by ischemic stroke. Pathologically, cerebral ischemia is due to a granulomatous-necrotizing vasculitis of cerebral arteries: usually the internal carotid artery, middle cerebral artery, or anterior cerebral artery. In immunocompromised hosts, VZV reactivation may result in a small vessel vasculitis and concomitant encephalitis and/or myelitis.¹¹⁴

- Diagnosis of CNS vasculitis associated with infections.
 - Evaluation of CSF, including white cell count, red cell count, protein glucose, gram stain and culture, specific viral polymerase chain reaction (PCR) tests, acid-fast stain, India

- ink fungal stain, cryptococcal antigen, VDRL as well as bacterial, fungal, and tuberculosis culture.
- Brain magnetic resonance imaging: cerebral infarction or, less frequently, hemorrhage.
- Cerebral angiography.
- Brain biopsy.
- Management of CNS vasculitis associated with infections.
 - Treatment of underlying infection using appropriate antibiotics at CNS doses.
 - Concomitant corticosteroids.
 - (a) Dexamethasone started *prior to* first dose of antibiotic in community-acquired bacterial meningitis improves outcome.¹¹⁵
 - (b) Steroids used together with antiviral therapy have been used in VZV vasculitis and may be helpful in other similar conditions¹¹⁴.
- (b) CNS vasculitis associated with connective tissue diseases.
 - Characteristics.
 - Inflammatory exudates around arteries result in fibrosis and constriction result in luminal stenosis.
 - Selected connective tissue disorders associated with CNS vasculitis.
 - Systemic lupus erythematosus (SLE): Autoimmune inflammatory disease which involves multiple organs.

Systemic Lupus Erythematosus (SLE)

Although cerebral vasculitis is frequently invoked as a cause of cerebral infarction in SLE, it is relatively rare. A seminal study of pathologic specimens from SLE patients showed that true vasculitis with intramural inflammation was present only in 3 of 24 cases.¹¹⁶ Other, more common, causes of cerebral ischemia in SLE: noninflammatory cerebral vasculopathy; antiphospholipid antibody syndrome (see Coagulopathy section); cerebral microangiopathy due to hypertension; and cardioembolism due to Libman-Sacks endocarditis (see Endocarditis section).^{117, 118}

- Rheumatoid arthritis (RA): A multisystem disorder which can affect the brain by causing a lymphocytic pachymeningitis and arteritis.
- Sjogren's Syndrome: Characterized by keratoconjunctivitis, xerostomia, and a PAN-like vasculitis which may involve multiple organs including the brain; associated with the presence in the blood of Ro ([SS]-A) and La ([SS]-B) antibodies, the detection of which can aid with diagnosis.
- Diagnosis of connective tissue diseases.
 - Clinical and historical evidence of a connective tissue disease.
 - Laboratory evaluation appropriate for suspected condition, including serum rheumatoid factor (RA); SS-A, SS-B antibodies (Sjogren's); antinuclear antibody, anti-DNA antibodies (SLE), and others.
- Management of connective tissue diseases.
 - Disease specific, usually involving immunosuppression.
- (c) CNS vasculitis associated with drug use¹¹⁹.
 - Characteristics.
 - Necrotizing arteritis, similar to PAN.
 - Specific selected agents.
 - Amphetamines: Use may be related to cerebral hemorrhage or ischemia in the setting of angiographically suggested and histologically proven vasculitis.
 - Cocaine.

Cocaine and Stroke

Cocaine administration by any route predisposes to ischemic and hemorrhagic strokes. Acute hypertension is thought to be related to hemorrhage especially in the setting of chronic hypertensive vasculopathy or in patients harboring intracra-

(continued)

nial aneurysms. Chronic hypertensive vasculopathy, microangiopathy, and acute vasospasm are thought to relate to ischemic stroke risk. Intravenous use can also predispose to endocarditis. Unlike in cases of amphetamine-related cerebral vasculitis, true cerebral vasculitis in chronic cocaine use has not been frequently demonstrated.¹¹⁹

- Heroin and other opioids: Vasculopathy leading to cerebral ischemia has been observed, although histological proof of an inflammatory etiology is lacking¹²⁰; endocarditis is another common etiology of cerebral ischemia with heroin use.
- Diagnosis.
 - History, physical exam (needle tracks), urine drug screen.
- Stroke prevention.
 - Abstinence from drug use.
- (d) CNS vasculitis associated with other selected systemic diseases.^{96, 97}
 - Behcet's disease: Characterized by oral and genital ulcers, and iritis; the associated vasculitis may involve the brain; treatment is of the underlying disease.¹²¹
 - Paraneoplastic cerebritis: Perivascular inflammation has sometimes been associated with cerebritis; treatment is of the underlying malignancy.
 - Lymphoma: An associated CNS vasculitis similar to primary CNS vasculitis has been observed; treatment is of the underlying malignancy.

17.4.52. Vasoconstriction (aka vasospasm)

The generic term vasoconstriction or vasospasm implies functional contraction of vascular smooth muscle cells. The term implies reversibility, but the length of time during which the vessel is in spasm may be variable, from seconds to days. In neurology, the term *vasospasm* usually refers to the entity observed in patients 7–14 days after aneurysmal subarachnoid hemorrhage. Postsubarachnoid hemorrhage vasospasm is characterized by initial functional arterial contraction resulting in luminal narrowing, followed by progression to actual structural changes within the arteries: intimal proliferation with progressive luminal narrowing and, subsequently, necrosis of the tunica media. In a subset of patients, these vascular changes lead to cerebral ischemia: 5–10% of hospitalized patients with aneurysmal subarachnoid hemorrhage will die from cerebral vasospasm. Subarachnoid hemorrhage and vasospasm are discussed in Chap. 13. Other conditions associated with cerebral vasoconstriction are discussed later.

1. Call–Fleming syndrome (aka reversible cerebral constriction, benign cerebral angiopathy, postpartum cerebral angiopathy).^{122, 123}
 - (a) Characteristics.
 - The majority of patients are female; prevalence is low.
 - Presentation is with *thunderclap* headache mimicking subarachnoid hemorrhage; seizures, nausea, vomiting may accompany the headache.
 - Acutely, CT is usually normal and lumbar puncture shows no abnormality; cerebral angiography reveals diffuse arterial luminal narrowing, sometimes mimicking angiographic findings of vasculitis.
 - (b) Associated conditions, possibly precipitating factors.
 - Sympathomimetic and serotonergic drugs.
 - Migraine.
 - Pregnancy/puerperium (aka postpartum cerebral angiopathy).
 - (c) Diagnosis.

Differentiating Call–Fleming syndrome and CNS Angiitis clinically	
Call–Fleming syndrome	Primary CNS Angiitis
Female predominance	Slight male predominance
Acute presentation	Subacute presentation

Thunderclap headache	Chronic headaches
Normal sensorium	Altered sensorium
Normal CSF	Abnormal CSF
MRI may be normal ^a	MRI most likely abnormal
Abnormal cerebral angiogram	Cerebral angiogram may be normal
Reversible in 4–12 weeks	Requires prolonged immunosuppressive therapy

^aIn 13 patients, abnormalities included white matter changes (3 patients); infarct (4 patients); sub-arachnoid hemorrhage (1 patient); and intracranial hemorrhage (2 patients)¹²³

(d) Treatment: No controlled trial data available.

- In a review of 16 patients, the following therapies were used with very good outcomes¹²³.
 - No specific therapy.
 - Calcium channel blockers (usually verapamil).
 - Course of corticosteroids (<6 months).
 - Cytotoxic drugs (minority of patients).
- Currently, a short course of steroids with or without calcium channel blockers is usually prescribed based on anecdotal experience.¹²⁴
- If focal neurologic deficits develop: Hypervolemic therapy, hemodynamic augmentation, or balloon angioplasty may be options in select patients.

(d) Prognosis.

- In the majority of patients, the course is benign, with resolution of symptoms and angiographic findings over weeks¹²³.
 - Ischemic and hemorrhagic strokes may occur; however, they usually do not result in major disability.
2. Other entities invoked as causes of transient cerebral vascular spasm include: drugs of abuse, direct vascular stimulation during neurosurgical or neuroendovascular procedures, hypertensive emergency, and migraines.

17.5. Acute ischemic stroke: Clinical presentation

Cerebral ischemia (and, thus, neurologic signs and symptoms) may be reversible if the lesion causing decreased cerebral blood flow is treated expeditiously, before brain tissue infarcts. The clinical presentation of acute cerebral ischemia is variable from patient to patient with respect to the evolution of symptoms over time (temporal classification) as well as specific constellations of symptoms (syndromic classification).

In a recent, prospectively collected database of >2,000 patients with ischemic stroke, 51% of lesions were located in the middle cerebral artery territory, 13% in typical small vessel territories, 11% in the brainstem, 9% in more than one territory, 7% in the posterior cerebral artery territory, 5% in the anterior cerebral artery territory, and 4% in the cerebellum.¹²⁵

17.5.1. Temporal classification

Some aspects of the temporal classification of cerebral ischemia are now obsolete; however, understanding the temporal pattern of symptom evolution is helpful in hypothesizing about the mechanism of cerebral ischemia and, most importantly, preventing impending or ongoing ischemia, secondary cerebral injury, and systemic complications of cerebral ischemia. If a patient experiences a focal neurologic deficit followed by complete remission of symptoms, and the deficit is thought to be ischemic in nature, i.e., TIA the patient should be *emergently* evaluated, rather than dismissed because he/she experienced *just a TIA*. This kind of patient may have a high stroke risk (see Acute Ischemic Stroke: Patient Evaluation – Selection of TIA Patients for Emergent

Cerebrovascular Evaluation section). This patient is potentially salvageable once the etiology of TIA is identified and the underlying lesion treated.

With the emergence of MRI techniques with high sensitivity for cerebral ischemia, the clinical diagnoses of TIA and acute ischemic stroke can be readily correlated with imaging. It turns out that many TIA patients have evidence of infarction on DWI imaging in the setting of completely resolved neurologic deficit.¹²⁶ Fundamentally, this finding supports the contention that *remitting* and *persisting* deficits in patients, if ischemic in nature, should be treated seriously and equivalently. To reflect this, a clinical term which combines TIA and acute ischemic stroke has been suggested: *acute ischemic cerebrovascular syndrome*.¹²⁷

1. Transient ischemic attack (TIA).

(a) Acute onset of focal neurologic dysfunction of vascular (ischemic) origin usually lasting for several minutes and completely remitting.

- Original definition from 1975 was: “cerebral dysfunction of ischemic nature lasting no longer than 24 h with a tendency to recur.”¹²⁸ but subsequently it became apparent that the majority of TIAs last well under 1 h¹²⁶.
- Symptoms occur either because of embolization, local thrombosis, or hypoperfusion and remit because of spontaneous clot lysis and/or increased systemic blood pressure resulting in better cerebral perfusion through collaterals or severely stenotic artery.
- Differential diagnosis of transient neurologic dysfunction: Cerebral ischemia, migraine, seizure, postictal paralysis, conversion disorder.
- Prognosis in TIAs is discussed in the “Selection of TIA Patients for Emergent Cerebrovascular Evaluation” section.
- Transient global amnesia (TGA) has sometimes been classified as a TIA, although its etiology remains a controversial topic.

Transient Global Amnesia (TGA)

TGA is characterized by sudden onset of anterograde amnesia in association with repetitive questioning such as “where am I?” and “what are we doing?” usually in middle-age individuals. There are no additional neurologic deficits, and the syndrome spontaneously remits, typically in a matter of minutes to hours. In the majority of patients, TGA never recurs. TGA patients do not have an increased incidence of vascular risk factors, and precipitating events such as sexual intercourse, pain, hot shower, or physical activity have been sometimes documented.¹²⁹

Various hypotheses have been proposed to explain the etiology of TGA, including transient ischemia, spreading depression, seizures, and venous congestion. The venous congestion mechanism has gained in popularity recently, although it is most likely that TGA has different causes in different subsets of patients.^{129–132}

2. Crescendo TIA.

(a) Repeated episodes of stereotyped transient focal neurologic dysfunction of ischemic origin, usually recurring over hours, days, or sometimes weeks.

(b) Possible mechanism of symptoms and remissions.

- Repeated embolizations from an unstable proximal (large vessel) plaque with spontaneous clot lysis.
- Repeated bouts of hemodynamic insufficiency in the setting of severely stenotic proximal vessel.
- Repeated local thrombosis and spontaneous lysis in a small, penetrating vessel (see “Lacunar Syndromes” section).

3. Reversible ischemic neurologic deficit (RIND).

(a) Transient focal neurologic dysfunction of ischemic origin lasting more than 24 h but resolving completely by 3 weeks.

- This term is no longer used in current clinical practice.

4. Stroke in evolution.

(a) Progression (worsening) of focal neurologic deficits over hours or days, in the acute period, without return to premonitory baseline or early recovery.

- Occurs in approximately 30% patients¹³³; see “Acute Ischemic Stroke: Treatment – Prevention and Management of Neurologic Complications” section.

5. Completed stroke.
 - (a) Maximal, fixed focal neurologic deficit without remission in the acute period; the deficit may decrease with time and rehabilitation due to synaptic reorganization and other mechanisms of neurorepair.

17.5.2. Syndromic classification: Large vessels

Constellations of neurologic signs and symptoms suggest anatomic and vascular localization of a CNS lesion. Vascular supply to the brain is generally stereotyped (see Chap. 1) and, therefore, vascular compromise begets specific patterns of neurologic dysfunction. Specific signs accompanying focal neurologic dysfunction (e.g., carotid bruit or Horner syndrome) may corroborate hypothesized location of a vascular lesion (Fig. 17.3).

Cerebral large vessel syndromes are related mostly to atherosclerotic thromboembolic disease (discussed in Chaps. 18 and 19). Involvement of the most distal branches of the major circulations discussed later may give rise to watershed infarctions, while involvement of the deep, penetrating branches may give rise to small

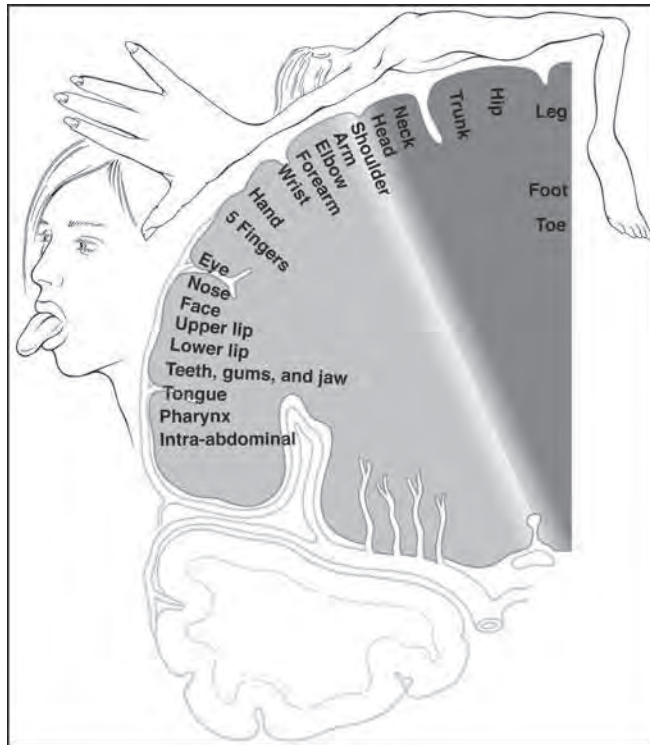


Fig. 17.3 The Homunculus. *Dark gray area* corresponds to the ACA territory; *light gray area* is the MCA territory. Since the lower extremity is functionally represented in cortical tissue perfused by the ACA, infarction of the ACA is likely to result in leg weakness. Similarly, the face and the arm are represented in cortical tissue supplied by the MCA and will be preferentially affected by infarction of the distal MCA.

vessel (lacunar) syndromes. The discussion of large vessel and small vessel vascular syndromes is based on **Localization in Clinical Neurology**, by PW Brazis, JC Masdeau, and J Biller.¹³⁴

1. Internal carotid artery (ICA).

(a) General.

- If Circle of Willis is complete, it gives rise to.
 - Anterior cerebral artery (ACA).
 - Middle cerebral artery (MCA).
 - Anterior choroidal artery (AChA).
- Supplies the majority of the cerebral hemispheres.
- Occlusion in extracranial (cervical) or intracranial portion is possible.
- Proximal cervical or intracranial occlusion may be asymptomatic, depending on collateral circulation and rapidity of occlusion.
- Clinical manifestation of occlusion may be a TIA (may be recurrent), stepwise deficits, progressive deficits, or sudden, fixed deficits.

(b) Clinical ICA syndromes.

- Transient monocular blindness (aka amaurosis fugax).

Transient monocular blindness

Acute onset of painless monocular visual loss usually described as a *shade* or *curtain* being drawn or *circumferential* constriction, typically resolving in seconds to minutes. The etiology is probably an embolism to the ophthalmic artery from a carotid artery plaque, although hemodynamic insufficiency from a high-grade carotid stenosis is also possible.

- Limb-shaking TIA (aka limb-shaking syndrome).

Limb-Shaking TIA

Episodes of rhythmic or arrhythmic involuntary movements of the hand, arm, leg, or any combination thereof. The movements have been described as jerking, twitching, tremulous, trembling, and uncoordinated. There is no *Jacksonian march* (stereotyped spread of dysfunction from the face to the arm and then to the leg or in the opposite direction), and the face is usually not involved. The movements can last for a few minutes and may occur upon arising from a sitting or lying position. The etiology is thought to be cerebral hypoperfusion of the ACA-MCA watershed region due to a hemodynamically significant proximal carotid artery plaque.¹³⁵

- Variable presentation featuring.
 - MCA syndromes (see later).
 - ACA-MCA Watershed Syndrome (see later).
 - Complete ICA Syndrome combining complete MCA and ACA syndromes.

(c) Findings associated with ICA ischemic syndromes.

- Seizures.
 - More likely with involvement of cortical gray matter (e.g., distal or complete MCA syndromes)¹³⁶.
 - Seizure rate with ischemic stroke is approximately 5% across all vascular territories.
- Carotid bruit^{137, 138}.

- Prevalence: 6.4% in men and women >60 years old with systolic hypertension, without previous stroke.
- General marker of atherosclerosis.
- Sixty-nine percent of carotid bruits correlate with internal carotid stenosis.

Horner syndrome
Miosis (small pupil)
Ptosis (eyelid droop)
Forehead anhidrosis ^a (lack of sweating)

^aAnhidrosis may be absent if the lesion is distal to the carotid bifurcation because interruption of the common or external carotid artery sympathetic fibers is necessary to produce anhidrosis

- Presence of bruit may reflect external carotid turbulence.
- Absence of bruit is nondiagnostic, e.g., no bruit is evident with complete occlusion.
- Horner Syndrome.
 - Related to a structural lesion of the internal carotid which disrupts the sympathetic fibers traveling alongside it.
 - Dissection or fibromuscular dysplasia of the internal carotid artery may present with Horner Syndrome.

2. Anterior choroidal artery (AChA).

(a) General.

- Originates from ICA.
- Supplies posterior limb of the internal capsule, thalamic radiations, optic tract and radiations, and lateral geniculate body.
- Clinical manifestation of occlusion may be a TIA (may be recurrent), stepwise deficits, progressive deficits, or sudden, fixed deficits (Fig. 17.4).

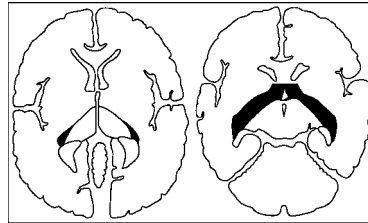


Fig. 17.4 Anterior choroidal artery territory.

(b) Clinical AChA syndromes.

Anterior choroidal artery occlusion	
Involved structure	Neurologic finding
Pyramidal tract fibers in the posterior limb of the internal capsule	Contralateral hemiparesis
Superior thalamic radiations in the posterior limb of the internal capsule	Contralateral hemisensory loss
Optic tract, lateral geniculate body, and/or optic radiations	Homonymous hemianopsia or various other visual field deficits

- Unilateral AChA occlusion.
 - Common syndromes: pure motor syndrome, pure sensory syndrome, or ataxic hemiparesis.
 - Rare syndromes: hemineglect or apraxia (if nondominant lesion) or language disturbance (if dominant lesion).
- Bilateral AChA occlusion.
 - Pseudobulbar affect.
 - Mutism, lethargy, neglect.
 - Facial diplegia, bilateral arm and leg weakness/sensory loss.

3. Anterior cerebral artery (ACA).

(a) General.

- Arises from the ipsilateral ICA.
- Sometimes both ACAs arise from one carotid artery or the A1 segment on one side may be hypoplastic.
- Supplies anterior corpus callosum and parasagittal cortex (Fig. 17.5).

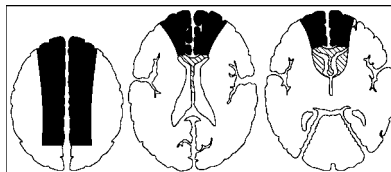


Fig. 17.5 Anterior Cerebral Artery Territory. Hatched area corresponds to deep ACA perforators; solid black areas indicate the remaining ACA territory.

- Gives rise to the artery of Heubner (aka medial lenticulostriate artery) which supplies anterior limb of the internal capsule.
 - Presentation varies with site of occlusion (proximal vs. distal) and the robustness of Willisian collateral circulation.
 - Clinical manifestation of occlusion may be a TIA (may be recurrent), stepwise deficits, progressive deficits, or sudden, fixed deficits.
- (b) Clinical ACA syndromes.

Anterior cerebral artery occlusion		
Involved ACA branch	Involved structure	Neurologic finding
Hemispheric	Parasagittal motor cortex	Contralateral lower extremity weakness, with possible involvement of the shoulder
Callosal	Anterior corpus callosum	Left arm apraxia ^a (anterior disconnection syndrome); may have contralateral lower extremity sensory loss
Artery of Heubner	Anterior limb of the internal capsule	Contralateral weakness of face and arm without sensory loss

^aIncapacity to produce purposeful voluntary movement in the absence of sensory or motor deficit

- Additional findings with ACA occlusion.
 - If dominant hemisphere, transcortical motor aphasia (see later).
 - Dysarthria, hypophonia.
 - Abulia (impairment of performance of voluntary actions and/or inability to make decisions), memory impairment, urinary incontinence (especially if bilateral involvement).
 - Transient mild hemiparesis, dysarthria, behavioral deficit (caudate nucleus infarct).
4. Middle Cerebral Artery (MCA) (Fig. 17.6).
- (a) General.
- The largest branch of the ICA.
 - Supplies majority of cerebral hemispheres and basal ganglia.
 - Most common site of intracranial vascular occlusion: Involved in >50% of all ischemic strokes.
 - Presentation varies with location of occlusion (stem or proximal MCA vs. superior division vs. inferior division vs. lenticulostriate perforating arteries) and the extent of collateral circulation.
 - Clinical manifestation of occlusion may be a TIA (may be recurrent), stepwise deficits, progressive deficits, or sudden, fixed deficits.
- (b) Clinical MCA syndromes.
- Complete MCA Syndrome.
 - Contralateral hemiplegia.
 - Contralateral hemianesthesia.
 - Contralateral homonymous hemianopia.
 - Contralateral visual or sensory neglect.
 - Gaze deviation and gaze paresis.
 - (a) "Patient looks at the lesion".
 - Apraxia.
 - If dominant hemisphere.
 - (a) Aphasia¹³⁹.

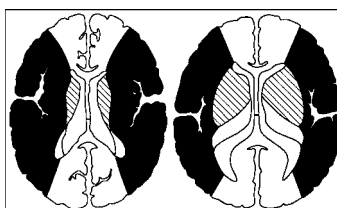


Fig. 17.6 Middle cerebral artery territory. *Hatched area* corresponds to deep MCA perforators (thalamostriates); *solid black areas* indicate the remaining MCA territory.

Aphasia classification									
Aphasia type	Clinical features						Lesion location		
	Naming	Repetition	Comprehension	Fluency	Reading	Writing			
Expressive (Broca)	Poor	Poor	Intact	Poor	Poor	Poor			Frontoparietal operculum
Receptive (Wernicke)	Poor	Poor	Poor	Intact (Nonsensical)	Poor	Poor			Inferoposterior perisylvian
Global Conduction	Poor	Poor	Poor	Poor	Poor	Poor			Large perisylvian
Transcortical sensory	Usually intact	Poor	Intact	Intact	Intact	May be spared			Posterior perisylvian
Transcortical motor	Usually intact	Intact	Poor	Intact (Nonsensical)	Poor	Poor			Parietal, temporal, or thalamus
			Intact	Poor	May be spared	May be spared			Frontal, striatum

Gerstmann syndrome
Apraxia (inability to write)
Finger agnosia (inability to recognize/name fingers)
Acalculia (inability to calculate)
Right-left confusion

- (b) Gerstmann Syndrome: lesions in the angular and supramarginal gyri.
- 8. If nondominant hemisphere.
 - (a) Anosognosia (ignorance of the presence of disability).
 - (b) Dressing apraxia.
 - (c) Impaired spatial skills.
 - (d) Impaired prosody (intonation).
 - (e) Acute confusional state.
- Deep MCA Syndrome: Infarction of territory supplied by lateral lenticulostriate perforating arteries affecting the head of the caudate, anterior limb of the internal capsule, and putamen.
 - Contralateral hemiparesis (primarily upper extremity).
 - Aphasia, apraxia, neglect, inattention.
- Superficial MCA Syndromes: Infarction of cortical and subcortical regions supplied by distal branches of the MCA with sparing of lenticulostriate perforators; may involve the superficial anterior (superior) territory or superficial posterior (inferior) territory.

Superficial middle cerebral artery syndromes	
Superior (anterior)	Inferior (posterior)
Contralateral face and arm weakness and sensory loss	Contralateral homonymous hemianopia
Gaze deviation and gaze paresis: patient "looks at the lesion"	Contralateral visual or sensory neglect
Broca's Aphasia (dominant hemisphere)	Gerstmann Syndrome (dominant hemisphere)
	Wernicke's Aphasia (dominant hemisphere)

- Additional findings in superficial MCA syndromes, especially in nondominant hemisphere: anosognosia, dressing apraxia, impaired spatial skills, impaired prosody, acute confusional state.
5. Posterior Cerebral Artery (PCA) (Fig. 17.7).
- (a) General.
- Paired PCAs arise from basilar artery bifurcation.
 - Supplies the midbrain, thalamus, and occipital and temporal cortex.
 - Clinical manifestation of occlusion may be a TIA (may be recurrent), stepwise deficits, progressive deficits, or sudden, fixed deficits.
 - Artery of Percheron.
 - Arises from the P1 segment of the PCA.
 - Occlusion results in bilateral thalamic ischemia and coma.
- (b) Clinical PCA syndromes.

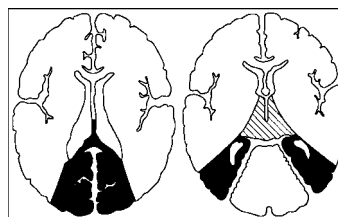


Fig. 17.7 Posterior cerebral artery territory. Hatched area corresponds to deep PCA perforators; solid black areas indicate the remaining PCA territory.

- Hemispheric PCA branches.
 - Contralateral homonymous hemianopia, sparing the macula.
- Bilateral involvement of hemispheric PCA branches.
 - Balint Syndrome: bilateral parieto-occipital lesions (including watershed infarcts).

Balint syndrome
Visual simultanagnosia (inability to recognize the meaning of the whole even though the meaning of the individual parts is understood)
Optic ataxia (impaired visually guided reaching and depth perception)
Gaze apraxia (inability to shift gaze on command)
Decreased visual attention

- Cortical blindness with preserved pupillary reflexes.
- Anton Syndrome (aka denial of blindness): bilateral medial occipital lesions.

Anton Syndrome
cortical blindness
lack of awareness of blindness
confabulation about what is "seen"

- Bilateral homonymous hemianopia.
- Visual hallucinations.
- Visual agnosia.
- Color agnosia.
- Prosopagnosia (inability to recognize faces).
- Delirium.
- Confusion.
- Amnesia.
- Callosal PCA branches, dominant hemisphere.
 - Alexia without agraphia (aka pure word blindness): lesion in inferior splenium of the corpus callosum and medial occipital lobe).
 - Color anomia.
 - Object anomia.
 - Contralateral homonymous hemianopia.
- Thalamic branches of the PCA.
 - Pure hemisensory syndrome.
 - Sensorimotor syndrome.
 - Dejerine–Roussy Thalamic Syndrome.

Dejerine–Roussy thalamic syndrome
Contralateral vasomotor disturbance
Contralateral dysesthesia (thalamic pain)
Contralateral sensory loss
Transient contralateral hemiparesis
Involuntary choreoathetoid or ballistic movements

- Abulia, apathy, disorientation, aphasia if dominant side, alien hand, and neglect if non dominant (anterior thalamus).
- Somnolence, memory loss (paramedian thalamus).
- PCA occlusion can sometimes simulate MCA occlusion; in one series 17.8% of PCA infarcts mimicked MCA infarcts^{140–142}.

Posterior cerebral artery occlusion simulating middle cerebral artery occlusion	
Clinical manifestation	Lesion location
Contralateral hemiparesis (face, arm > leg)	Cerebral peduncle or posterior limb of the internal capsule
Contralateral hemisensory loss	Ventral Posterior Thalamic Nucleus
Contralateral hemineglect	Centromedian/parafascicular thalamic nuclei
Homonymous hemianopia	Striate cortex or geniculate body
Gaze palsy	Midbrain
Aphasia (if dominant side)	Ventral lateral or pulvinar thalamic nuclei

- Midbrain branches of the PCA: note that the midbrain is also supplied by branches from the BA, SCA, posterior communicating artery, and anterior and posterior choroidal arteries).
 - Weber Syndrome.

Weber syndrome	
Lesion location	Neurologic findings
Fascicle of CN III	Ipsilateral pupil-involving CN III palsy
Cerebral peduncle	Contralateral hemiplegia (face-arm-leg)

- Midbrain Syndrome of Foville: Weber Syndrome plus conjugate gaze palsy to the opposite side.
- Benedikt Syndrome.

Benedikt syndrome	
Lesion location	Neurologic Findings
Red nucleus	Contralateral involuntary movements (tremor, athetosis or chorea)
Fascicle of CN III	Ipsilateral pupil-involving CN III palsy

- Nothnagel syndrome.

Nothnagel syndrome	
Lesion location	Neurologic Findings
Superior cerebellar peduncle	Contralateral cerebellar ataxia
Fascicle of CN III	Ipsilateral pupil-involving CN III palsy

- Claude syndrome: A combination of Benedikt and Nothnagel Syndromes featuring contralateral asynergia, ataxia, dysmetria, tremor (superior cerebellar peduncle and red nucleus), and ipsilateral pupil-involving CN III palsy (fascicle of CN III).
- Parinaud syndrome (aka dorsal midbrain syndrome, pretectal syndrome, Sylvian aqueduct syndrome, Koerber-Salus-Elsching Syndrome): Most often seen with hydrocephalus or pineal region tumors, but can rarely be observed with infarcts.

Parinaud syndrome
Vertical gaze paralysis
Abnormalities of convergence
Paralysis of accommodation
Convergence–retraction nystagmus
Light-near pupillary dissociation
Lid retraction (aka Collier's sign)
Skew deviation

- Internuclear ophthalmoplegia: May be unilateral or bilateral
- Wall-eyed bilateral internuclear ophthalmoplegia.
- Peduncular hallucinosis: Visual hallucinations, usually very vivid and colorful, involving formed human figures.
- Top of the Basilar Syndrome: Results in variable degree of infarction of the midbrain, thalamus, pons, and temporal and occipital lobes usually secondary to embolus traveling through the basilar, and lodging and/or fragmenting at the PCA origin.

Top of the basilar syndrome
Disturbance of consciousness
Disturbance of memory
Pathologic laughter
Abnormal eye movements including gaze palsies, skew deviation
Pupillary abnormalities
Visual disturbances including Balint & Anton Syndromes
Peduncular hallucinosis
Hemi- or quadriparesis and sensory loss

6. Basilar Artery (BA) (Fig. 17.8).

(a) General.

- Arises from the joining of the two vertebral arteries.
- Supplies the pons and cerebellum, and bifurcates into the PCAs which supply the midbrain, thalamus, and occipital and temporal cortex.
- Clinical manifestation of occlusion may be a TIA (may be recurrent), stepwise deficits, progressive deficits, or sudden, fixed deficits.
- While majority of ischemic lesions in the brainstem are due to intrinsic perforator (lacunar) disease, BA thrombosis or cardioembolism is one of the most devastating diseases: occlusion of multiple pontine perforating arteries can result in the Locked-in Syndrome in which the patient is awake but unable to move or communicate aside from blinking and vertical eye movements; occlusion of the top of the basilar can result in the Top of the Basilar Syndrome with coma secondary to bilateral thalamic involvement.

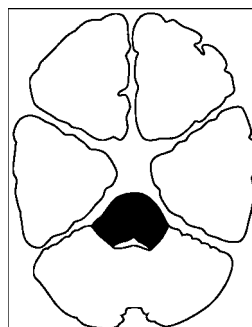


Fig. 17.8 Basilar artery territory.

(b) Clinical BA syndromes.

- Top of the Basilar Syndrome.
- Penetrating pontine branches.
 - Ventral pontine syndromes: pure motor hemiparesis, dysarthria-clumsy hand, ataxic hemiparesis (see Lacunar Syndromes section).
 - Paramedian pontine syndromes: variable dysarthria, ataxia, hemiparesis, pseudobulbar palsy (if bilateral involvement).
 - Locked-in syndrome (bilateral ventral pontine infarcts).

Locked-in syndrome
Quadriplegia
Aphonia
Paralysis of horizontal eye movements
No disturbance of consciousness
Communication may be possible through vertical eye movements and eye blinking

(c) Other classical pontine syndromes, sometimes observed with infarction.

- Ventral pons.
 - Raymond Syndrome: ipsilateral lateral rectus palsy (CN VI fascicles) and contralateral hemiplegia sparing the face (pyramidal tract).
 - Dorsal pons.
 - Foville syndrome: contralateral hemiplegia (corticospinal tract), ipsilateral peripheral facial palsy (nucleus and/or fascicle of CN VII), and gaze palsy to the lesioned side, i.e., “patient looks away from the lesion” (CN VI and/or paramedian pontine reticular formation [PPRF]).
 - Raymond–Cestan syndrome: ipsilateral ataxia (cerebellum), contralateral sensory loss (spinothalamic tract and medial lemniscus), and sometimes contralateral hemiparesis (corticospinal tract) or paralysis of conjugate gaze toward lesion (PPRF).
 - Lateral pons.
 - Marie-Foix Syndrome: ipsilateral cerebellar ataxia (cerebellar connections), contralateral hemiparesis (corticospinal tract), contralateral hemisensory loss (spinothalamic tract).
7. Superior cerebellar artery (SCA) (Fig. 17.9).

(a) General.

- Paired SCAs arise from the distal segment of the basilar artery.
- Supplies the dorsal surface of the cerebellar hemisphere and vermis, dentate nucleus, middle and superior cerebellar peduncles, and lateral pons.
- Clinical manifestation of occlusion may be a TIA (may be recurrent), stepwise deficits, progressive deficits, or sudden, fixed deficits.
- Accounts for 35% of all cerebellar infarcts.

(b) Clinical SCA syndromes.

- Dorsal cerebellar infarction.

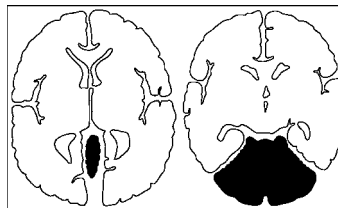


Fig. 17.9 Superior cerebellar artery territory.

Superior cerebellar artery syndromes	
Lesion location	Neurologic findings
Vestibular nuclei	Vertigo, nausea, vomiting
Medial longitudinal fasciculus and cerebellar connections	Nystagmus
Descending oculosympathetic fibers	Ipsilateral Horner Syndrome
Superior cerebellar peduncle and cerebellum	Ipsilateral ataxia and/or intention tremor
Lateral lemniscus	Ipsilateral deafness
Lateral spinothalamic tract	Contralateral trunk and extremity hemisensory loss
Pontine tectum	Contralateral CN IV palsy

8. Anterior inferior cerebellar artery (AICA) (Fig. 17.10).

- (a) General.
- Paired AICAs arise approximately 1cm above the basilar artery origin.
 - Supplies anterior surface of cerebellar hemisphere, flocculus, lateral pontomedullary tegmentum.
 - Clinical manifestation of occlusion may be a TIA (may be recurrent), stepwise deficits, progressive deficits, or sudden, fixed deficits.
 - Accounts for 5% of all cerebellar infarcts.
- (b) Clinical AICA syndromes.
- Ventral cerebellar infarction.

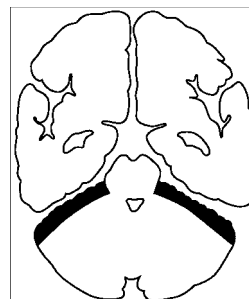


Fig. 17.10 Anterior inferior cerebellar artery territory.

Anterior inferior cerebellar artery syndromes	
Lesion location	Neurologic findings
Trigeminal spinal nucleus and tract	Ipsilateral facial sensory loss
Vestibular nuclei	Vertigo, nausea, vomiting, nystagmus
Lateral pontomedullary tegmentum	Ipsilateral deafness and facial paralysis
Lateral spinothalamic tract	Contralateral trunk and extremity hemisensory loss
Descending oculosympathetic fibers	Ipsilateral Horner syndrome
Middle cerebellar peduncle and cerebellum	Ipsilateral ataxia

9. Posterior Inferior Cerebellar Artery (PICA) (Fig. 17.11).

- (a) General.
- Arises from intracranial portion of the vertebral artery.
 - Supplies lateral medulla, inferior vermis, inferior cerebellar hemisphere.
 - Clinical manifestation of occlusion may be a TIA (may be recurrent), stepwise deficits, progressive deficits, or sudden, fixed deficits.

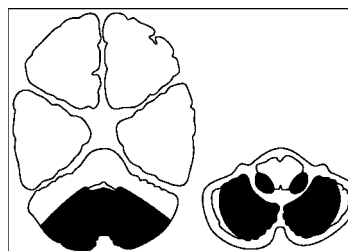


Fig. 17.11 Posterior inferior cerebellar artery territory.

- Accounts for 40% of all cerebellar infarcts.
- (b) Clinical PICA syndromes.
- Lateral medullary and inferior cerebellar infarction.

Posterior inferior cerebellar artery syndrome (Lateral Medullary [Wallenberg] Syndrome)	
Vestibular nuclei	Vertigo, nausea, vomiting
Inferior cerebellar peduncle and cerebellum	Ipsilateral ataxia
Nucleus ambiguus	Dysphagia, dysarthria
Descending oculosympathetic fibers	Ipsilateral Horner Syndrome
Trigeminal spinal nucleus and tract	Ipsilateral facial sensory loss
Spinothalamic tract	Contralateral trunk and extremity hemisensory loss
Dorsal middle medulla	Hiccups
Pons	Diplopia

10. Vertebral Artery (VA).

- (a) General.
- Clinical manifestation of occlusion may be a TIA (may be recurrent), stepwise deficits, progressive deficits, or sudden, fixed deficit.
- (b) Clinical VA syndromes.
- Medial Medullary Syndrome (aka Dejerine's Anterior Bulbar Syndrome); note that the medulla is also supplied by the anterior and posterior spinal arteries, PICA, and BA.

Medial medullary syndrome	
Lesion location	Neurologic findings
CN XII	Ipsilateral tongue paresis
Pyramid	Contralateral hemiparesis
Medial lemniscus	Contralateral loss of position, vibration sense
Nucleus intercalates	Upbeat nystagmus

11. Watershed territories (border zones).

- (a) General.
- Definition of watershed: territory supplied by the distal- most branches of the major cerebral circulations.
 - Mechanism of infarction: hemodynamic, although embolism to the watershed areas, as well as local thrombosis in the setting of decreased flow, is possible.
 - Bilateral or unilateral syndromes are possible: asymmetry results from pre-existing unilateral vasculopathy with stenosis, making the downstream territory more susceptible to hypotension.
- (b) Clinical syndromes.
- ACA-MCA-PCA watersheds.
 - Bilateral parieto-occipital infarcts with visual field deficits (lower altitudinal), difficulty in visually judging distance, cortical blindness, and/or optic ataxia.
 - ACA-MCA watersheds.
 - Bilateral brachial sensory and motor deficit, sparing lower extremities and shoulders, eventually confined to the hands and forearms, i.e., a variation of the "person in a barrel" syndrome.
 - MCA-PCA watershed.
 - Bilateral parieto-temporal infarcts with difficulties in reading and calculations, cortical blindness, or memory impairment.

17.5.3. Syndromic classification: Small vessels

Cerebral small vessel vasculopathy is also referred to as *cerebral microangiopathy*, *penetrating (or deep) artery disease*, *small vessel disease*, *subcortical white matter disease*, or *lacunar disease*. Long-standing multiple risk factor-related damage to the endothelium of small cerebral arteries results in lipohyalinosis (degeneration of the tunica media and adventitia and subsequent fibrosis). Eventually local thrombosis and occlusion of the vessel may occur, giving rise to an infarct in the territory of the affected small vessel. Another mechanism of local thrombosis is atherosclerotic plaque at arterial branch points, i.e., origins of the penetrating vessels. Patients at risk for lacunar ischemic disease are also at risk for intracerebral hemorrhage in the same anatomic locations, which can present with similar neurologic signs.

1. Lacune.
 - (a) Small 0.5–15 mm diameter ischemic cerebral infarct.
 - (b) Territory of small-diameter-penetrating artery to deep brain structures.
 - (c) Typical locations, in descending order of frequency.

Locations of lesions causing lacunar syndromes (lacunes)
Putamen
Basis pontis
Thalamus
Posterior limb of internal capsule
Caudate nucleus
Anterior limb of the internal capsule
Subcortical white matter (corona radiata)
Cerebellar white matter
Corpus callosum

2. Lacunar syndromes.

Lacunar syndromes
Pure motor hemiparesis
Pure sensory syndrome
Ataxic hemiparesis
Dysarthria-clumsy hand syndrome

- (a) Pure motor hemiparesis or hemiplegia.
 - Unilateral face-arm-leg weakness +/- dysarthria.
 - Absence of cortical signs.
 - Typical lesion locations: internal capsule, corona radiata, basis pontis.
- (b) Pure sensory syndrome.
 - Unilateral face-arm-leg numbness +/- paresthesias.
 - Absence of cortical or motor signs.
 - Typical lesion locations.
 - Thalamus (ventroposterolateral nucleus) .
 - Corona radiata .
 - Pontine tegmentum (medial lemniscus).
 - A small cortical lesion may also cause this syndrome.
- (c) Dysarthria-clumsy hand syndrome.
 - Lower extremity weakness, incoordination of the upper and lower extremity, usually no facial weakness.
 - Absence of cortical signs.
 - Typical lesion locations.
 - Internal capsule.
 - Basis pontis.

- A superficial anterior cerebral artery lesion can also cause this syndrome.
- (d) Ataxic hemiparesis.
 - Unilateral facial weakness, tongue deviation, dysarthria, dysphagia, fine motor hand weakness, Babinski sign.
 - Absence of cortical signs.
 - Typical lesion locations.
 - Basis pontis.
 - Internal capsule.

17.5.4. Clinical stroke classification schema

Several clinical classification schemas have been developed, primarily for clinical research and quality of care applications. The TOAST Diagnostic Classification is based on the suspected mechanism of cerebral ischemia and separates patients with ischemic stroke into five groups: large artery atherosclerosis, cardioembolism, small vessel occlusion (lacunar disease), other determined etiology, and undetermined etiology.¹⁴³ The Oxfordshire Community Stroke Project Classification assigns the suspected arterial territory based on the clinical syndrome: TAC (total anterior circulation stroke), LAC (lacunar stroke), PAC (partial anterior circulation stroke), and POC (posterior circulation stroke).¹⁴⁴

17.6. Acute ischemic stroke: Patient evaluation

The 2007 AHA Guidelines for the Early Management of Adults with Ischemic Stroke is a Comprehensive, evidence-based document outlining principles and practical goals for the acute treatment of ischemic stroke patients.¹⁴⁵ Much of the following discussion, unless otherwise indicated, is based on that reference.

17.6.1. Prehospital assessment of patients with acute cerebral ischemia (Stroke or TIA)

The care of the acute stroke patients begins with:

1. Rapid identification of the emergent nature of the complaint by prehospital emergency dispatchers.
2. Appropriate assessment, identification of stroke as a possible cause of the patient's complaint and exam findings, stabilization and management by Emergency Medical Systems providers.
3. Rapid transport to the nearest Emergency Department of an institution that provides acute stroke care.
4. Notification of the receiving institution of the impending arrival of an acute stroke patient in order to rapidly mobilize resources.

In order to facilitate care of acute stroke patients, the Brain Attack Coalition recommended that institutions which have the infrastructure to provide care to uncomplicated stroke patients including thrombolysis with intravenous tPA be designated as Primary Stroke Centers (PSC), and institutions which have the infrastructure for handling complicated cases requiring endovascular procedures, surgical procedures, or intensive care be designated as Comprehensive Stroke Centers (CSC). Admission to PSC and CSC is thought to improve outcomes in patients with stroke.

17.6.2. Selection of TIA patients for emergent cerebrovascular evaluation

Evaluation of TIA patients, even in the setting of fully resolved deficit, should be expedited and geared toward rapidly identifying etiology and modifiable, treatable risk factors in order to prevent symptom recurrence.

1. Prognosis during 90 days after emergency department diagnosis of TIA¹⁴⁶.
 - (a) Stroke: 10.5%.
 - 5.3% re-presented within the first 2 days after TIA.
2. Risk factors associated with stroke recurrence after TIA symptoms¹⁴⁶.
 - (a) Age >60.
 - (b) Diabetes mellitus.
 - (c) Symptom duration >10 min.
 - (d) Weakness.
 - (e) Speech impairment.
3. ABCD² score for determination of stroke risk within 2 days of TIA¹⁴⁷.
 - (a) Two scores (ABCD and California) had been independently derived to aid in selecting TIA patients with high stroke risk (these patients require emergent cerebrovascular evaluation and treatment, usually necessitating hospital admission).
 - ABCD score predicts risk at 7 days after TIA symptoms.
 - California score predicts risk at 90 days after TIA symptoms.
 - (b) ABCD², a new, unified score based on the aforementioned aspects, was derived.
 - ABCD² score (Age; Blood pressure; Clinical features; Duration; Diabetes).

ABCD ² score		
	Clinical feature	Weight (points)
A	Age ≥60	1
B	First assessment blood pressure after TIA systolic ≥140 or diastolic ≥90 mmHg	1
C	<i>Clinical features of TIA</i>	
	Unilateral weakness	2
	Isolated speech impairment	1
D	<i>Duration of TIA</i>	
	≥60 min	2
	10–59 min	1
E	Diabetes	1

Stroke risk based on the ABCD ² score			
ABCD ² score	Stroke risk, 2 days (%)	Stroke risk, 7 days (%)	Stroke risk, 90 days (%)
0–3 (Low risk)	1.0	1.2	3.1
4–5 (Moderate risk)	4.1	5.9	9.8
6–7 (High risk)	8.1	11.7	17.8

17.6.3. Emergency department evaluation of acute ischemic stroke patients

Patients with acute stroke symptoms should be evaluated *immediately* by individuals trained in the assessment and management of acute stroke patients. The goal is to complete the evaluation, identify candidates for intravenous tPA, and start treatment within 60 min, i.e., door-to-needle time ≤60 min.¹⁴⁵

1. Assess and stabilize the ABCs, obtain vital signs including oxygen saturation.
2. Assess neurologic deficit, perform brief general examination to identify any acute co-morbid conditions.
3. Determine time of symptom onset and whether patient is a candidate for intravenous thrombolysis (see Chap. 9).

4. If not a candidate for intravenous thrombolysis, determine if the patient is a candidate for endovascular rescue therapies (see Chap. 9).
5. Rule out ischemic stroke mimics: Obtain noncontrast head CT, bedside blood glucose, basic laboratory tests (see later); in a few patients in whom the etiology of symptoms is not clear or specific nonischemic conditions are suspected after the initial assessment, perfusion brain imaging, cerebrovascular assessment with ultrasound or angiography, lumbar puncture, or electroencephalogram may be necessary.

17.6.4. General evaluation of patients with cerebral ischemia

1. Initial investigation.
 - (a) Laboratory testing to rule out metabolic stroke mimics and identify some ischemic stroke risk factors – this is usually done in the Emergency Department¹⁴⁵.

Basic laboratory testing in patients with suspected cerebral ischemia	
Laboratory test	Purpose
<i>All patients</i>	
Chemistry profile	Identifies metabolic derangements
Complete blood count	Suggests infection; identifies polycythemia; suggests thrombotic thrombocytopenic purpura or heparin-induced thrombocytopenia
Partial thromboplastin and prothrombin time	Suggests coagulopathy
Cardiac enzymes	Identifies recent or ongoing myocardial injury
<i>Selected patients</i>	
Urine and serum toxicology	Identifies intoxications with drugs or alcohol
Arterial blood gas	Identifies hypercarbia or hypoxia
Hepatic function panel and serum ammonia	Identifies hepatic encephalopathy
Pregnancy test	Identifies pregnancy in women of child-bearing age

2. Etiologic investigation.
 - (a) Identification of conventional risk factors (usually began in the Emergency Department and continued after hospital admission).

Conventional risk factor evaluation in patients with cerebral ischemia	
Risk factor	Diagnostic approach
Hypertension	Elicit history; physical exam and EKG signs; repeat BP measurements
Diabetes mellitus	Fasting glucose; HbA _{1c}
Hyperlipidemia	Fasting lipid profile
Atrial fibrillation	12-lead EKG; continuous telemetry monitoring; Holter monitor
Myocardial infarction	History; 12-lead EKG; serial cardiac enzyme testing
Smoking (tobacco)	Elicit history; physical exam signs; chest x-ray findings

- (b) Evaluation of the extracranial and intracranial vasculature, specifically to identify cervical carotid disease.

Evaluation of extracranial and intracranial vasculature in patients with cerebral ischemia	
Diagnostic test	Pro & Con
CT angiography (CTA)	PRO: rapid; usually readily available 24–7; noninvasive; 90% accuracy compared to conventional angiography for internal carotid disease CON: iodinated contrast (see Chap. 2)
Magnetic resonance angiography (MRA)	PRO: no iodinated contrast; noninvasive; may be used without contrast enhancement CON: lengthy; may not be available 24–7; if performed with contrast, may carry risk of gadolinium-related systemic sclerosis in a minority of patients (see Chap. 2); turbulence may cause signal drop-out; degree of stenosis may be overestimated
Carotid duplex ultrasound	PRO: rapid; noninvasive CON: operator dependent; compared to conventional angiography, sensitivity and specificity approximately 70%
Transcranial Doppler ultrasound	PRO: dynamic assessment; can determine direction of collateral flow; rapid; potential for therapeutics; ability to continuously monitor for an extended period in real time; when combined with “bubble” study may detect clinically relevant right-to-left shunts CON: operator dependent; may not be able to obtain temporal windows (10–15% of patients); sensitivity lower than conventional angiography ¹⁴⁸
Conventional angiography	PRO: gold standard; superior resolution; provides collateral vessel assessment CON: iodinated contrast; may not be available 24–7; invasive, carries risk of infarct and other complications (1–2%)

The author of this chapter (AA) prefers contrast-enhanced MRA and ultrasound for the evaluation of the intracranial and extracranial vasculature in patients with acute ischemic stroke. The other authors of this handbook (JD and MH) favor CTA. Both imaging strategies have been shown to provide useful information in a timely manner, and all three authors of this handbook advise the reader to use whichever imaging technology is the most expeditious, reliable, and interpretable in their hands.

- (c) Identification of cardiac source of embolism in selected patients.
- Whether echocardiography should be performed in all ischemic stroke patients or reserved only for those with cryptogenic stroke has been the subject of extensive discussion in the literature.^{149–151}

Echocardiography in patients with cerebral ischemia	
Test	Pro & Con
Transthoracic echocardiography	PRO: noninvasive; good ability to image mitral valve and apical region; with “bubble” test, able to detect right-to-left shunts CON: poor visualization of aortic arch and atria
Transesophageal echocardiography	PRO: superior ability to assess the aortic arch, valvular vegetations, patent foramen ovale; cost effective CON: invasive; requires sedation (may increase aspiration risk in patients with large infarcts or brainstem infarcts)

It is the authors' practice to investigate cardiac sources of embolism with TTE with "bubble" test in the majority of patients with cerebral ischemia. The authors use TEE instead of TTE in young patients and patients with cryptogenic, but suspected to be embolic, cerebral ischemia. Right-to-left shunts can also be identified using transcranial Doppler ultrasound^{152, 153}

- (d) Identification of less common risk factors in patients with cryptogenic stroke.
- Detailed information on less common risk factors and use of specialized diagnostic tests can be found in the "Acute Ischemic Stroke: Conventional Risk Factors, Predisposing Conditions, and Risk Factor Modification" section.

Additional investigations in selected patients with cerebral ischemia		
Test	Purpose	Comments
Erythrocyte sedimentation rate (ESR)	General marker of inflammation	May suggest entities such as giant cell arteritis, other vasculitides, endocarditis, or systemic infection
Antinuclear antibody (ANA)	Marker of connective tissue disease	May suggest systemic lupus erythematosus, Sjogren's syndrome, rheumatoid arthritis, scleroderma, etc.
Rapid plasma reagin (RPR)	Screening test for syphilis	May suggest meningovascular syphilis
Homocysteine	Marker of vascular disease	Although treating elevated homocysteine has not been shown to be protective in stroke prevention, treatment with vitamins is of low risk and cost
Specialized coagulopathy tests	Diagnosis of coagulopathies	See "Coagulopathy" section
Lumbar puncture	Evaluation of infectious, inflammatory, or neoplastic entities	Useful in the diagnostic approach to vasculitis, neoplastic conditions such as lymphoma, and inflammatory conditions such as sarcoid; and for evaluation of subarachnoid hemorrhage
Lower extremity ultrasound	Evaluate for lower extremity thrombus	Useful if a right-to-left shunt is identified and hypercoagulability is suspected

17.6.5. Stroke in the young evaluation

Although cardioembolism is the most common cause of ischemic stroke in patients <50 years old, they may still harbor conventional risk factors, and the evaluation should rule these out. Echocardiography (preferably TEE) should be used to investigate the heart, and the cervical and intracranial vasculature should be evaluated for vasculopathy including dissection, *moya-moya*, and fibromuscular dysplasia. The threshold to evaluate the vasculature with the gold standard, conventional angiography, is generally lower in these patients, especially if no conventional risk factors are identified. In patients with suggestive personal or family history, screening for hypercoagulability should be performed.

17.7. Acute ischemic stroke: Treatment

The goal of acute treatment of cerebral ischemia is *rapid reperfusion* in patients who present within the therapeutic window. The overall treatment paradigm for patients with ischemic stroke consists of:

1. Rapid assessment by a Stroke Team.
2. Acute thrombolysis in selected patients (see Chap. 9).
3. Augmentation of cerebral blood flow and oxygen delivery.
4. Prevention of thrombus extension or re-embolization (i.e., early ischemic stroke recurrence).
5. Neuroprotection.
6. Prevention and management of neurologic complications.
7. Prevention and management of general medical complications.
8. Secondary stroke prevention.
9. Rehabilitation.

The 2007 AHA Guidelines for the Early Management of Adults with Ischemic Stroke is a comprehensive, evidence-based document outlining principles and practical goals for the acute treatment of ischemic stroke patients.¹⁴⁵ Much of the following discussion, unless otherwise indicated, is based on it.

17.7.1. Thrombolysis

1. Recommendations and comments.
 - a. Intravenous thrombolysis with tPA within 3 h of symptom onset in patients meeting specific criteria (see Chap. 9).
 - b. Intravenous administration of other thrombolytics is considered investigational and should not be offered outside of clinical studies.
 - c. Intra-arterial thrombolysis is an option for patients with major ischemic stroke presenting within 6 h of symptom onset, who are not intravenous tPA candidates (see Chap. 9).
 - d. Additional endovascular approaches (angioplasty, stenting, mechanical embolectomy) are being utilized in selected patients in the acute setting, but require further investigation.
 - e. Approaches to augmentation of intravenous thrombolysis including ultrasonography are currently being investigated in clinical trials.¹⁵⁴

17.7.2. Augmentation of cerebral blood flow and oxygen delivery

Cerebral perfusion is impaired in acute cerebral ischemia not only due to cessation or decrease in blood flow due to thrombus or embolus, but also due to endothelial dysfunction, increased blood viscosity, increased red blood cell aggregation, decreased red cell deformability, platelet activation, and elevated fibrinogen levels. Cerebral perfusion may be augmented using the following measures.

1. Hemodilution and volume expansion
 - (a) Benefits.
 - Improved cerebral blood flow and oxygen delivery.
 - Improved collateral flow to the penumbra.
 - (b) Risks.
 - Cardiac and pulmonary adverse events.
 - (c) Bottom line for the majority of patients.
 - Not shown to reduce mortality or improve outcome in acute ischemic stroke.
 - Weight-based maintenance intravenous fluids should be used.
 - Overzealous fluid administration should be avoided.
 - Dehydrated or hypotensive patients may require a greater degree of volume resuscitation.
2. Flat head-of-bed positioning.
 - (a) Benefits.
 - Improved collateral flow to the *penumbra* (region of brain in which flow is reduced and metabolic demands are not met but cell death has not yet ensued, i.e., a potentially salvageable area if blood flow is rapidly restored).¹⁵⁵
 - (b) Risks.
 - Respiratory decompensation or aspiration.
 - (c) Bottom line for the majority of patients.
 - Use acutely unless patient cannot tolerate it due to respiratory dysfunction or high risk of aspiration.

- Progressively elevate the head on day 2 if the neurologic deficit is stable.
3. Blood pressure (BP) management
- (a) Acute BP management.
- Transient elevation of BP is extremely common in acute ischemic stroke.
 - Severe *hypertension* or *hypotension* correlates with worse outcome after ischemic stroke.
 - BP management in acute ischemic stroke is controversial.
 - Ideal blood pressure range in the immediate aftermath of acute ischemic stroke is not known.
 - Current guidelines allow liberal *permissive hypertension* in the acute stroke period.
 - Lower BP if $\geq 220/120$ mmHg and no IV tPA is to be administered.
 - Lower BP if $\geq 180/105$ and patient received intravenous tPA (BP must have been lowered to $\leq 185/110$ before treatment with IV tPA).
 - Lower BP if there is end-organ damage, e.g., myocardial infarction, aortic dissection, pulmonary edema, etc..
 - Recommended agents: labetalol boluses and/or infusion; nicardipine infusion; sodium nitroprusside infusion if BP elevation is severe or does not respond to the other agents.
 - If BP lowering correlates with worsening of neurologic deficit, therapy should be stopped and BP allowed to rise again.
 - Author's note.
 - Consider lowering BP in patients in whom a large vessel obstruction has been relieved, in order to prevent hyperemia and hemorrhagic conversion of ischemic infarct.
- (b) Acute *induced* hypertension.
- Benefits (similar to permissive hypertension).
 - Improved cerebral perfusion to the penumbra.
 - Improved neurologic deficit and outcome.
 - Risks (similar to permissive hypertension).
 - End-organ damage, e.g., myocardial infarction.
 - Worsening of cerebral edema.
 - Hemorrhagic conversion of ischemic infarct.
 - Bottom line for the majority of patients.
 - Requires further study.
 - A possible treatment option in special cases in highly selected patients.
- (c) Chronic BP management.
- General principles.
 - BP reduction to normal levels reduces risk of recurrent ischemic stroke (discussed under Hypertension in the Acute Ischemic Stroke: Conventional Risk Factors, Predisposing Conditions, and Risk Factor Modification section).
 - It is not known how aggressively and when after ictus BP lowering can be safely started.
 - Low-dose antihypertensive medications one day after ictus were safe in *mild-to-moderate* ischemic stroke.
 - Author's notes.
 - “One-size-fits-all” approach is probably not appropriate: some patients with hemodynamically significant large vessel lesions which cannot be remedied may require a higher blood pressure in order to perfuse the brain; these patients may still benefit from blood pressure lowering chronically, but in a more gradual fashion.
 - A possible approach to BP lowering: if neurologic deficit is stable and there is no large vessel stenosis, a low-dose ACE inhibitor (unless contraindicated) is started on day 2, and a diuretic is added one or two days later if the neurologic exam remains stable; both drugs are then titrated to achieve normal BP over the next several weeks; patients with hemodynamically significant large vessel stenosis are approached on a case-by-case basis.
4. HMG CoA reductase inhibitors (statins).
- (a) Improve collateral flow⁶⁹ and are currently being investigated as therapy in acute ischemic stroke.

17.7.3. Prevention of thrombus extension or re-embolization (i.e., Early ischemic stroke recurrence) (or: Why heparin and other blood thinners should be used sparingly)

It makes intuitive sense that medications typically utilized chronically to prevent recurrent stroke (secondary stroke prevention), i.e., systemic anticoagulants and antiplatelet drugs, may prevent thrombus extension and/or re-embolization in the acute period of ischemic stroke. However, at this time, available evidence does not support emergent anticoagulation, loading with antiplatelet agents, double antiplatelet therapy, or the use of intravenous antiplatelet agents in the setting of acute ischemic stroke.¹⁴⁵ Anticoagulation and antiplatelet agents are also not proven as adjuncts to intravenous or intra-arterial thrombolysis, and should not be administered within 24 h of thrombolysis.¹⁴⁵ Some experts suggest use of emergent systemic anticoagulation in specific patients, such as those with *minor* infarcts (smaller likelihood of hemorrhagic conversion) and potentially *large territory at risk* in the setting of severe carotid stenosis, atrial fibrillation, free-floating intracardiac or aortic arch thrombus, or basilar thrombosis.¹⁵⁶ Current guidelines, however, reflect the lack of data supporting this practice,¹⁴⁵ and more research is needed on the efficacy and safety of emergent aggressive antiplatelet therapy and acute systemic anticoagulation in selected patients.

17.7.4. Neuroprotection

Many compounds have been observed in preclinical studies in animals (primarily rodents) to be neuroprotective in acute ischemic stroke. Disappointingly, most of these compounds have failed in human clinical trials.¹⁵⁷ The reasons for such dismal results are multifactorial, from species differences (rodents vs. humans), to trial design and animal model technical flaws. New strategies for preclinical and clinical testing are needed, and one agent that is currently promising and awaits a larger clinical trial is minocycline.⁶³

1. Blood glucose management.

(a) General¹⁵⁸.

- Ischemic stroke patients may be hyperglycemic in the acute period due to underlying diabetes or effects on the hypothalamic-pituitary-adrenal axis, i.e., the *stress response*.
- Hyperglycemia in the acute period after ischemic stroke correlates with worse neurologic outcomes (even in patients treated with thrombolysis) and increased morbidity and mortality.
- Mechanisms of hyperglycemia-related brain injury: pro-inflammatory effects; anaerobic metabolism with tissue acidosis and free radical formation; blood brain barrier disruption and increased tissue edema.
- Hyperglycemia, rather than being causative, may be a marker of larger infarcts and higher disease severity.

(b) Intensive insulin therapy.

- Benefit: results in lower mortality and morbidity in ICU patients.
 - Surgical patients, ≥ 5 days in the ICU: mortality decreases from 20.2 to 10.6%¹⁵⁹.
 - Medical patients, ≥ 3 days in the ICU: mortality decreases from 52.5 to 43.0%¹⁶⁰.
- Mechanisms of benefit: blood glucose lowering and effects independent of blood glucose lowering including vasodilatory, anti-inflammatory, and antioxidant actions.
- Risk: hypoglycemia-related brain injury.

(c) Insulin therapy in acute stroke patients.

- GIST-UK trial¹⁶¹.
 - Insulin infusion for 24 h in acute stroke patients.
 - Failed to prove that lowering blood glucose in hyperglycemic, nondiabetic patients results in improved outcome.

- Several cautions to conclusions: smaller than planned sample size; mild average blood glucose elevations; BP decrement more pronounced in the study arm; non standardized blood glucose control after the first 24 h
 - Bottom line: more randomized, controlled trials of intensive insulin therapy in acute ischemic stroke are needed¹⁵⁸.
 - (d) Current guidelines for blood glucose control in acute ischemic stroke.
 - Based on preclinical and observational human data, it is reasonable to propose that patients with ischemic stroke will benefit from tight glucose control in the acute period.
 - Blood glucose >140 mg dL⁻¹ in patients with acute ischemic stroke should be treated, but hypoglycemia should be avoided.
 - Author's notes.
 - Blood glucose control in acute ischemic stroke patients should *at least* mirror the guidelines for other hospitalized patients: For ICU <110 mg dL⁻¹; for general ward 90–130 mg dL⁻¹ or <110 mg dL⁻¹ preprandial, depending on the organization determining the guidelines; of note, these guidelines for general medical patients are not without controversy¹⁶².
 - Patients with renal failure, low body mass, cachexia, and those who are NPO should be rigorously monitored for hypoglycemia: Bedside blood glucose measurements should be performed frequently (every 4–6 h for patients on the ward and every 1 h for patients on insulin infusion in the ICU), and hypoglycemia should be promptly treated.
 - (e) Practical considerations in insulin therapy.
 - Most effective blood glucose control.
 - Insulin infusion (requires ICU admission).
 - Alternative method in patients with mild hyperglycemia.
 - Early use of scheduled long-acting insulin in addition to sliding scale insulin.
 - Sole reliance on sliding scale insulin is not advised¹⁶³.
2. Temperature management.
- (a) General.
- Systemic hyperthermia correlates with worse neurologic outcome.¹⁶⁴
 - Mechanisms of damage: increased metabolic demand, free radical generation, disruption of the blood brain barrier, and potentiation of excitotoxicity.
 - Although no studies in human patients with acute ischemic brain injury show improved outcomes with treatment of fever, several show worse outcomes with persistent hyperthermia¹⁶⁵.
 - It makes intuitive sense to seek the etiology of fever, treat quickly, and maintain normothermia.
- (b) Etiology of fever in ischemic stroke patients.

Differential diagnosis of fever in stroke patients
Infection
Urinary tract (especially with indwelling catheter)
Pneumonia (ventilator-associated or aspiration; sometimes may be inflammatory rather than infectious, i.e., <i>pneumonitis</i>)
Sinusitis (especially if nasogastric tube is present)
Blood stream (central venous catheter or endocarditis-related)
Ventriculitis/meningitis (especially if intraventricular catheter present; may be aseptic, i.e., chemical, in some cases)
Osteomyelitis (in the setting of decubitus ulcers)
Colitis (e.g., <i>Clostridium difficile</i> , especially if history of antibiotic administration)
Cholecystitis, hepatitis, pancreatitis, or peritonitis, etc. (may be inflammatory rather than infectious, especially early in the course)
Abscess
Surgical site infection
Cellulitis

Venous thromboembolism
Deep venous thrombosis
Pulmonary embolism
Drug fever
Transfusion reaction
Gout
Central fever
Diagnosis of exclusion

- (c) Induced mild (34°C) hypothermia.
- Protective in hypoxic-ischemic brain injury in the setting of cardiac arrest.
 - Study 1: Favorable outcome: 75/136 (55%) vs. 54/139 (39%), NNT=6¹⁶⁶.
 - Study 2: Favorable outcome: 21/43 (49%) vs. 9/34 (26%), NNT=4¹⁶⁷.
 - Can be used as adjunctive therapy to control elevated intracranial pressure¹⁶⁸.
 - Outcome studies in traumatic brain injury and ischemic stroke are ongoing.
 - Risks: cardiac arrhythmia, coagulopathy.
 - Guidelines.
 - There are insufficient data to recommend generalized use of induced hypothermia in acute ischemic stroke patients at this time.¹⁴⁵

17.7.5. Prevention and management of neurologic complications

1. Neurologic monitoring.
 - (a) Treatment with intravenous or intra-arterial thrombolysis usually necessitates observation in a higher acuity setting; some patients with acute cerebral ischemia who are not candidates for acute thrombolysis may require admission to the ICU for other reasons.

Selection of patients with cerebral ischemia for ICU admission ¹⁶⁹
Endotracheal intubation – mechanical ventilation
Hemodynamic instability – vasopressor therapy – invasive monitoring
Intensive blood pressure lowering ^a
Marginal ^b neurologic exam – frequent neurologic monitoring
Fluctuating neurologic exam – frequent neurologic monitoring
Acute posterior circulation ischemia
Large infarct at risk for malignant edema
After intravenous thrombolysis
After intra-arterial thrombolysis
Increased nursing requirements

^aIn general, blood pressure is not aggressively lowered in the acute period after ischemic stroke, but exceptions include patients with severe blood pressure elevations, end-organ damage, or status post IV or IA thrombolysis (especially with recanalization)

^bMarginally responsive patients (GCS 8–9) who may require endotracheal intubation for airway protection or patients with severe dysarthria or dysphagia at high risk of aspiration

- (b) Approximately 30% of ischemic stroke patients worsen clinically during the initial hours to days after ischemic stroke, and the etiology of worsening may require specific intervention¹³³.
- Early deterioration (≤ 72 h post ictus): 80.3% from cerebral causes, 19.7% from systemic causes¹⁷⁰.
 - Late deterioration (> 72 h): 100% from systemic causes¹⁷⁰.

Worsening neurologic examination after ischemic stroke	
Etiology	Possible interventions
New or ongoing ischemia	Hemodynamic augmentation; thrombectomy (e.g., mechanical retrieval); augmentation of medical therapy
Cerebral edema	Endotracheal intubation; osmolar therapy; hemicraniectomy or suboccipital craniotomy
Hemorrhagic conversion	Reversal of coagulopathy (if present); osmolar or surgical therapy if with mass effect
Seizure/status epilepticus	Antiepileptic drug therapy
Concurrent systemic illness	
Urinary tract infection	Antibiotic therapy
Congestive heart failure	Inotropic therapy
Pneumonia	Antibiotic therapy
Myocardial infarction	Medical and/or interventional therapy
Metabolic abnormality	Correction of abnormality

2. Management of cerebral edema and increased intracranial pressure (ICP).
- (a) Incidence of cerebral edema.
- Eight percent of acute ischemic stroke patients, usually peaking 3–4 days from ictus.
- (b) Characteristics.
- Cytotoxic edema, not responsive to corticosteroids.
 - *Malignant* cerebral edema.
 - May occur as early as one day from onset.
 - Usually with complete MCA or ICA infarction, especially if NIH-SS > 20 ; $> 2/3$ MCA territory involved or concomitant ACA or PCA infarct; or DWI lesion > 145 mL.
 - May result in brain herniation and death.
 - In cerebellar infarcts, edema may result in hydrocephalus and brain stem compression.
- (c) Medical management.
- Depends on the rapidity of clinical deterioration and the overall goals of care.
 - Mild cerebral edema without much tissue displacement on head CT or MRI.
 - Serum sodium should be 140–145 mEq L⁻¹.
 - Arterial $p\text{CO}_2$ should be within the normal range, i.e., 35–45 mmHg.
 - Body temperature should be normal.
 - Compression of cerebral venous outflow (jugular veins) should be avoided.
 - Head of bed should be elevated at 30° to facilitate venous outflow.
 - Severe cerebral edema¹⁶⁸.
 - Hyperventilation to $p\text{CO}_2$ goal of 28–35 mmHg is reasonable for the short term while osmolar therapy is being instituted; once other therapies are at goal, $p\text{CO}_2$ should be gently normalized (ideally with concurrent ICP monitoring).
 - Osmolar therapy with hypertonic saline (3% sodium chloride-acetate mix) with goal serum sodium of 145–155 mEq L⁻¹; requires central venous access and frequent, usually every 4–6 h, serum sodium monitoring; continuous or bolus therapy can be used.

- Boluses of mannitol are an alternative therapy.
- Caution should be exercised in patients requiring hemodialysis: conventional hemodialysis may increase ICP; continuous approaches are preferred¹⁷¹.
- Surgical management (see later).
- Metabolic suppression with *barbiturates*, *thiopental*, *propofol* or *mild hypothermia* (temperature goal of 34°C) are options if the patient is not a candidate for surgery.
- Cerebral herniation¹⁶⁸.

Brain code protocol: treatment of elevated ICP/cerebral herniation	
CSF drainage (if intraventricular catheter, aka external ventricular drain, is present and patent)	Open and/or lower intraventricular catheter to facilitate drainage
Hyperventilation	Open airway
	Hyperventilate: 10–15 rapid bagged breaths; when on ventilator, initial pCO ₂ goal 28–35, for no longer than 2–3 h; prolonged hypocapnea results in tachyphylaxis (adaptation); severe degree of hypocapnea may result in decreased cerebral perfusion through cerebral vasoconstriction
	Intubate the trachea (if not already intubated)
Osmolar therapy	Osmolar therapy: mannitol 1 g kg ⁻¹ IV over 15–30 min or 23.4% NaCl ^a IV over 15–30 min
Metabolic suppression	Propofol or thiopental IV injection ^b
Diagnosis	STAT head CT
Surgical management	Neurosurgical evaluation

^aAvailable only in specialized Neurointensive Care environments; should be given only through a central venous catheter by a physician familiar with its use; may result in hypotension if given too rapidly
^bShould only be used in ICU setting by a physician familiar with these agents; if given too rapidly or at too high a dose, serious hemodynamic adverse effects can occur (bradycardia and/or hypotension)

- Can be effectively reversed provided it is recognized early, managed rapidly, and definitively treated.
- (d) Surgical management.
 - Medical therapy may only be a temporizing measure, and surgical therapy may be necessary to offer definitive treatment and save the patient's life and neurologic function.
 - Posterior circulation infarction with severe cerebral edema.
 - Insertion of an intraventricular catheter may relieve acute symptomatic hydrocephalus but will *not* decompress the brain stem.
 - Posterior fossa decompression via suboccipital craniotomy may save the patient's life and minimize injury to the brain stem.
 - Anterior circulation infarction with severe cerebral edema.

Outcomes at 12 months in malignant middle cerebral artery infarctions ¹⁷²		
Modified Rankin scale grade (mRS; see later)	Hemicraniectomy (% of Patients)	Medical treatment (% of Patients)
2	14	2
3	29	19
4	31	2
5	4	5
6	22	71

- A pooled analysis of three randomized studies of hemicraniectomy for malignant middle cerebral artery infraction within 48 h of ictus was recently performed.¹⁷²
- Summary of results:
 - (a) Significantly fewer deaths with surgery: NNT 2 for survival.
 - (b) Significantly fewer survivors with mRS ≥ 3 at 12 months with surgery: NNT 4 for the prevention of mRS > 3 .
 - (c) Surgery beneficial in patients *with* and *without* aphasia.

Modified Rankin scale (mRS)	
Grade	Description
0	No deficit
1	No significant disability despite symptoms: able to carry out usual activities
2	Slight disability: unable to carry out all previous activities, but looks after own affairs without assistance
3	Moderate disability: requires help with activities of daily living but able to walk without assistance
4	Moderately severe disability: unable to walk without assistance and unable to attend to bodily needs without assistance
5	Severe disability: bedridden, incontinent, requiring constant nursing care and attention
6	Dead

- Currently, the timing of surgery and patient selection should be individualized, but if decompression is to be performed, it should be done prior to occurrence of irreversible secondary injury^{145, 172}.
3. Management of postischemic stroke seizures.
- (a) Incidence.
- Two types of poststroke seizures are recognized: *early* (occurring within 14 days of stroke) and *late* (occurring after 14 days).
 - In one study, 5% of patients presenting with stroke (73% with ischemic stroke) had seizures: 36% were early seizures (25% within the first 24 h); 87% of patients had cortical involvement; 50% had at least one seizure recurrence; recurrence was related to late-onset seizure and occipital location of lesion¹⁷³.
 - Late-onset seizures are more likely to result in epilepsy¹⁷³.
- (b) Management.
- Prospective data are needed to firmly establish functional effects of poststroke seizures, although worsening neurologic status with repeated seizures has been observed^{136, 173}.
 - It is unclear whether a single postischemic stroke seizure requires treatment with antiepileptic drugs (AED), but if patients are treated, control can be achieved with monotherapy in most cases; it is generally agreed that patients with recurrent seizures require treatment with AED¹³⁶.
 - More data are needed regarding appropriate AED for the treatment of poststroke seizures; some agents are neuroprotective in animal studies, but some may impair poststroke recovery and cognition¹³⁶.
 - While no specific AED for use in poststroke epilepsy can be recommended at this time, the most appropriate drug should be used in each individual patient based on the patient milieu, i.e., concurrent medical problems, degree of neurologic disability, and concurrent medications.

17.7.6. Prevention and management of general medical complications

Patients with acute ischemic stroke, especially the elderly, are at risk for many general medical complications which increase mortality and morbidity and slow neurologic recovery. Some of these complications can be reduced in frequency by early mobilization; however, in some patients who are dependent on collateral flow during the acute phase, upright posture may worsen neurologic status. These patients should be mobilized less rapidly, but should be turned frequently while in bed (to minimize the chance of decubitus ulcers) and treated with prophylaxis against deep venous thrombosis.

1. Infections (especially pneumonia and urinary tract infection).
 - (a) Prevention and management.
 - Pneumonia: Early mobilization, pulmonary toilet, early swallow-function assessment; high degree of vigilance for making the diagnosis in the setting of fever; appropriate use of antibiotics.
 - Urinary tract infection: Whenever possible, indwelling urinary catheters should be avoided; high degree of vigilance for making the diagnosis in the setting of fever; appropriate use of antibiotics.
 2. Deep venous thrombosis (DVT) and pulmonary thromboembolism (PTE).
 - (a) Prevalence.
 - Without prophylaxis, DVT can develop in up to 73% of patients with hemiplegia; PTE in up to 20%¹⁷⁴.
 - With medical prophylaxis, DVT developed in 10–18% of patients with ischemic stroke who were unable to walk due to lower extremity motor weakness; PTE developed in up to 1%¹⁷⁵.
 - (b) Prevention and management.
 - Mechanical.
 - Use of graduated compression stockings and intermittent pneumatic compression devices decreases the risk of DVT/PTE in a variety of patients, including spinal cord injured and neurosurgical perioperative patients.¹⁷⁶
 - Medical.
 - Either low molecular weight or unfractionated heparin is generally used.
 - In ischemic stroke patients, enoxaparin may be more effective at DVT prevention than unfractionated heparin (dosed twice daily) at no increased risk of major intracranial hemorrhage but increased risk of major extracranial hemorrhage; with enoxaparin, NNT (to prevent one venous thromboembolism) = 13, NNH (to cause one major extracranial hemorrhage) = 173.¹⁷⁵
 - Combination.
 - Addition of sequential compression devices to subcutaneous heparin prevents more DVT and PTE in stroke patients than heparin alone¹⁷⁷.
 3. Decubitus ulcers (aka pressure sores)¹⁷⁸.
 - (a) Prevention and management.
 - Early mobilization in patients who can tolerate upright posture.
 - Frequent turning/repositioning in bed-bound patients.
 - Specialized support surfaces which attenuate pressure on the patient's skin, e.g., special mattresses, mattress overlays, or dynamic support surfaces.
 - Optimization of nutritional status.
 - Treatment of incontinence.
 - Skin care with moisturizer.
 4. Falls.
 - (a) Prevention and management.
 - Nursing measures to avoid falls.
 - Appropriate use of physical restraints.
 - Prevention and treatment of acute confusional states, maintenance of normal day–night cycle.
 5. Dehydration.
 - (a) Prevention and management.
 - Hydration and nutrition.

1. All patients with dysarthria should receive a swallowing evaluation.
 2. Patients in whom swallowing is abnormal may be temporarily fed through a nasogastric tube; some patients may require placement of a percutaneous endoscopic gastrostomy if swallowing function is unlikely to return rapidly¹⁴⁵.
6. Constipation and fecal impaction.
 - (a) Prevention and management.
 - Pharmacologic bowel management regimen.
 7. Gastric ulceration (aka stress ulcers).
 - (a) Prevention and management.
 - Gastrointestinal prophylaxis with proton pump inhibitors or histamine H₂ receptor blockers is typically utilized in ischemic stroke patients, especially if they are endotracheally intubated and ventilated¹⁷⁹.
 8. Neuropsychiatric disorders.
 - (a) Prevention and management.
 - Depression: Occurs in up to 20% patients with stroke and should be managed with antidepressants appropriate for each individual patient¹⁸⁰.
 - Delirium: Avoidance of CNS-acting medications like benzodiazepines or narcotics; maintenance of normal day-night cycle; high degree of vigilance for making the diagnosis; management with antipsychotic agents if necessary¹⁸¹.

17.7.7. Secondary ischemic stroke prevention

As discussed in this chapter, all patients with acute ischemic stroke are evaluated to determine stroke etiology and risk factors for future events. In general, all patients are screened for modifiable conventional risk factors: hypertension, diabetes mellitus, hyperlipidemia, tobacco smoking, cardiac disease, atrial fibrillation, and extracranial and/or intracranial vasculopathy. A summary of general secondary stroke prevention strategies appears later, while risk factor modification is covered in detail in the “Acute Ischemic Stroke: Conventional Risk Factors, Predisposing Conditions, And Risk Factor Modification” section. Extracranial and intracranial atherosclerotic vasculopathy are

Summary of selected secondary ischemic stroke prevention strategies ⁹	
Strategy	Comments
<i>Antiplatelet therapy</i>	<ul style="list-style-type: none"> • Indicated for atherosclerotic, lacunar, or cryptogenic stroke or TIA (see also Chap. 18)
	<ul style="list-style-type: none"> • 28% and 16% relative odds reduction in nonfatal and fatal ischemic stroke, respectively
	<ul style="list-style-type: none"> • <i>Current choice of agents:</i> aspirin; clopidogrel; ticlopidine; dipyridamole/aspirin
	<ul style="list-style-type: none"> • The appropriate dose of aspirin for stroke prevention has not been specifically defined, but 325 mg is frequently used in clinical practice
	<ul style="list-style-type: none"> • <i>Agents showing promise:</i> cilostazol and glycoprotein IIb/IIIa antagonists¹⁸²
	<ul style="list-style-type: none"> • Choice of agents should be individualized, e.g., aspirin is less expensive, but clopidogrel or dipyridamole/aspirin may provide slightly more risk reduction and different side effect profile
	<ul style="list-style-type: none"> • Combination therapy with aspirin and clopidogrel may be appropriate in patients with acute coronary syndromes, and cardiac or cerebrovascular stents
	<ul style="list-style-type: none"> • There is no evidence that increasing the dose of aspirin or changing to another antiplatelet agent is helpful in patients who have an ischemic event while on antiplatelet therapy, although these interventions are frequently used in clinical practice

(continued)

	<ul style="list-style-type: none"> • <i>Aspirin resistance</i> is sometimes invoked to explain recurrence of cardio- and cerebrovascular events while on therapy; but inadequate dose may play a role¹⁸³
<i>Systemic anticoagulation</i>	<ul style="list-style-type: none"> • Appropriate for many patients with cardioembolic stroke risk factors, such as atrial fibrillation
	<ul style="list-style-type: none"> • Timing of therapy initiation should be individualized, e.g., anticoagulation may be delayed for 1–2 weeks in the setting of a large infarct (to decrease the chance of hemorrhagic conversion), but may be started earlier in the setting of TIA or small infarct
	<ul style="list-style-type: none"> • Not generally recommended for noncardioembolic risk factors, although may be used sometimes in conditions like arterial dissection or patent foramen ovale, especially with symptom recurrence while on antiplatelet therapy
<i>HMG CoA reductase inhibitors (statins)</i>	<ul style="list-style-type: none"> • Statin beneficial actions are likely due to actions in addition to cholesterol lowering
	<ul style="list-style-type: none"> • Statin therapy should not be acutely withdrawn in patients presenting with acute ischemic stroke
	<ul style="list-style-type: none"> • Statin therapy after ischemic stroke prevents cardiovascular events and recurrent strokes
	<ul style="list-style-type: none"> • Patients should be warned of side effects and symptoms, and transaminases, creatine kinase, and lipid panel should be checked prior to and 1–3 months after therapy initiation
	<ul style="list-style-type: none"> • The appropriate duration of therapy is unknown, but benefits were found after 5 years of therapy
<i>Blood pressure reduction</i>	<ul style="list-style-type: none"> • Hypertension should be treated after the acute phase of stroke
	<ul style="list-style-type: none"> • Choice of agents should be individualized, but ACE inhibitors and diuretics like hydrochlorothiazide may have particular benefits
<i>Blood glucose management in diabetes</i>	<ul style="list-style-type: none"> • Blood glucose should be tightly controlled using agents appropriate for individual patients
	<ul style="list-style-type: none"> • Efficacy of treatment should be evaluated with periodic HbA_{1c} evaluation
<i>Smoking cessation</i>	<ul style="list-style-type: none"> • Smoking cessation should not be optional in patients with ischemic stroke
	<ul style="list-style-type: none"> • All possible smoking cessation aids should be recommended; nicotine receptor partial agonists like varenicline appear particularly effective

covered in Chaps. 18 and 19, respectively. Patients in whom conventional risk factors are not identified (i.e., ones with cryptogenic stroke) are usually evaluated further for rare causes of ischemic stroke. More emphasis on rare causes is placed in patients who are <50 years old (see “Stroke in the Young Evaluation” section).

A crucial aspect of secondary stroke prevention is education of the patient *and* the patient’s family, friends, and caregivers. Education on control of diabetes, hypertension, hyperlipidemia, diet, weight management, and smoking cessation should start in the hospital, because starting patient and caregiver education early is likely to increase medical compliance.

17.7.8. Rehabilitation and neurorepair

Although more data are needed, it is generally agreed that in order for traditional physical rehabilitation to be effective, it needs to be started early (i.e., during the acute phase in the hospital), be intensive and specific, and last well into the chronic phase.¹⁸⁴ Ongoing investigations in stroke rehabilitation include constraint-induced movement therapy¹⁸⁵, mechanical aids^{186, 187}; electrical stimulation¹⁸⁸; and pharmacologic interventions.¹⁸⁹ Preclinical studies are focusing on stem cell transplantation, as well as pharmacologic enhancement of natural plasticity and stem cell-based neurorepair.^{190, 191}

17.8. Acute ischemic stroke: Outcome

Recovery after ischemic stroke is a dynamic process, but patients generally reach 50% of their maximum recovery within 2 weeks of injury, and 80% of all patients reach their best possible recovery within 4–5 weeks.¹⁸⁴ Factors such as age, medical comorbidities, degree of neurologic (motor and cognitive) disability, as measured by a variety of scales including the Barthel Index (see <http://www.strokecenter.org/trials/scales/barthel.html>) and the NIH-SS (see Chap. 9), and social factors, affect individual patients' ability to return to work.¹⁹²

17.9. Internet ischemic stroke resources

American Academy of Neurology: <http://www.aan.com>

American Heart Organization: <http://www.americanheart.org>

American Stroke Association: <http://www.strokeassociation.org>

Internet Stroke Center at Washington University: <http://www.strokecenter.org>

National Stroke Association: <http://www.stroke.org>

17.10. References

1. AHA Heart Disease and Stroke Statistics-2004 Update. Dallas, TX: American Heart Association; 2003, pp. 1–52
2. Hand PJ, Kwan J, Lindley RI, Dennis MS, Wardlaw JM. Distinguishing between stroke and mimic at the bedside: The brain attack study. *Stroke* 2006;37(3):769–75
3. Foster JW, Hart RG. Hypoglycemic hemiplegia: Two cases and a clinical review. *Stroke* 1987;18(5):944–6
4. Bladin CF, Alexandrov AV, Bellavance A, et al. Seizures after stroke: A prospective multicenter study. *Arch Neurol* 2000;57(11):1617–22
5. Sylaja PN, Dzialowski I, Krol A, Roy J, Federico P, Demchuk AM. Role of CT angiography in thrombolysis decision-making for patients with presumed seizure at stroke onset. *Stroke* 2006;37(3):915–7
6. Selim M, Kumar S, Fink J, Schlaug G, Caplan LR, Linfante I. Seizure at stroke onset: Should it be an absolute contraindication to thrombolysis? *Cerebrovasc Dis* 2002;14(1):54–7
7. Benditt DG, van Dijk JG, Sutton R, et al. Syncope. *Curr Probl Cardiol* 2004;29(4):152–229
8. Arboix A, Massons J, Oliveres M, Arribas MP, Titus F. Headache in acute cerebrovascular disease: A prospective clinical study in 240 patients. *Cephalalgia* 1994;14(1):37–40
9. Sacco RL, Adams R, Albers G, et al. Guidelines for prevention of stroke in patients with ischemic stroke or transient ischemic attack: A statement for healthcare professionals from the American Heart Association/American Stroke Association Council on Stroke: Co-sponsored by the Council on Cardiovascular Radiology and Intervention: The American Academy of Neurology affirms the value of this guideline. *Stroke* 2006;37(2):577–617
10. Goldstein LB, Adams R, Albers MJ, et al. Primary prevention of ischemic stroke: A guideline from the American Heart Association/American Stroke Association Stroke Council: Cosponsored by the Atherosclerotic Peripheral Vascular Disease Interdisciplinary Working Group; Cardiovascular Nursing Council; Clinical Cardiology Council; Nutrition, Physical Activity, and Metabolism Council; and the Quality of Care and Outcomes Research Interdisciplinary Working Group: The American Academy of Neurology affirms the value of this guideline. *Stroke* 2006;37(6):1583–633
11. Kissela B, Schneider A, Kleindorfer D, et al. Stroke in a biracial population: The excess burden of stroke among blacks. *Stroke* 2004;35(2):426–31
12. Amarenco P. Cryptogenic stroke, aortic arch atheroma, patent foramen ovale, and the risk of stroke. *Cerebrovasc Dis* 2005;20(Suppl 2):68–74
13. Molise TA, Tunick PA, Kronzon I. Complications of aortic atherosclerosis: Atheroemboli and thromboemboli. *Curr Treat Options Cardiovasc Med* 2007;9(2):137–47
14. Dressler FA, Craig WR, Castello R, Labovitz AJ. Mobile aortic atheroma and systemic emboli: Efficacy of anticoagulation and influence of plaque morphology on recurrent stroke. *J Am Coll Cardiol* 1998;31(1):134–8
15. Ferrari E, Vidal R, Chevallier T, Baudouy M. Atherosclerosis of the thoracic aorta and aortic debris as a marker of poor prognosis: Benefit of oral anticoagulants. *J Am Coll Cardiol* 1999;33(5):1317–22
16. Lutsep HL. MATCH results: Implications for the internist. *Am J Med* 2006;119(6):526 e1–7
17. Orenca AJ, Hammill SC, Whisnant JP. Sinus node dysfunction and ischemic stroke. *Heart Dis Stroke* 1994; 3(2):91–4
18. Scholten MF, Thornton AS, Mekeel JM, Koudstaal PJ, Jordaens LJ. Anticoagulation in atrial fibrillation and flutter. *Europace* 2005;7(5):492–9
19. Hart RG, Pearce LA, Rothbart RM, McAnulty JH, Asinger RW, Halperin JL. Stroke with intermittent atrial fibrillation: Incidence and predictors during aspirin therapy. *Stroke Prevention in Atrial Fibrillation Investigators*. *J Am Coll Cardiol* 2000;35(1):183–7
20. Medi C, Hankey GJ, Freedman SB. Atrial fibrillation. *Med J Aust* 2007;186(4):197–202
21. Fang MC, Chen J, Rich MW. Atrial fibrillation in the elderly. *Am J Med* 2007;120(6):481–7
22. Gage BF, Waterman AD, Shannon W, Boechler M, Rich MW, Radford MJ. Validation of clinical classification schemes for predicting stroke: Results from the National Registry of Atrial Fibrillation. *J Am Med Assoc* 2001;285(22):2864–70
23. Hart RG, Benavente O, McBride R, Pearce LA. Antithrombotic therapy to prevent stroke in patients with atrial fibrillation: A meta-analysis. *Ann Intern Med* 1999;131(7):492–501

24. Petty GW, Brown RD, Jr., Whisnant JP, Sicks JD, O'Fallon WM, Wiebers DO. Frequency of major complications of aspirin, warfarin, and intravenous heparin for secondary stroke prevention. A population-based study. *Ann Intern Med* 1999;130(1):14-22
25. Rensink AA, de Waal RM, Kremer B, Verbeek MM. Pathogenesis of cerebral amyloid angiopathy. *Brain Res Brain Res Rev* 2003;43(2):207-23
26. Kinnecom C, Lev MH, Wendell L, et al. Course of cerebral amyloid angiopathy-related inflammation. *Neurology* 2007;68(17):1411-6
27. Razvi SS, Bone I. Single gene disorders causing ischaemic stroke. *J Neurol* 2006;253(6):685-700
28. Loh E, Sutton MS, Wun CC, et al. Ventricular dysfunction and the risk of stroke after myocardial infarction. *N Engl J Med* 1997;336(4):251-7
29. Pfeffer MA, Braunwald E, Moye LA, et al. Effect of captopril on mortality and morbidity in patients with left ventricular dysfunction after myocardial infarction. Results of the survival and ventricular enlargement trial. The SAVE Investigators. *N Engl J Med* 1992;327(10):669-77
30. Thomas DP, Roberts HR. Hypercoagulability in venous and arterial thrombosis. *Ann Intern Med* 1997;126(8):638-44
31. Bushnell CD, Goldstein LB. Diagnostic testing for coagulopathies in patients with ischemic stroke. *Stroke* 2000;31(12):3067-78
32. Hart RG, Kanter MC. Hematologic disorders and ischemic stroke. A selective review. *Stroke* 1990;21(8):1111-21
33. Ortel TL. Thrombosis and the antiphospholipid syndrome. *Hematology Am Soc Hematol Educ Program* 2005:462-8
34. Elkind MS. Inflammation, atherosclerosis, and stroke. *Neurologist* 2006;12(3):140-8
35. Bonora E, Kiechl S, Willeit J, et al. Insulin resistance as estimated by homeostasis model assessment predicts incident symptomatic cardiovascular disease in caucasian subjects from the general population: The Bruneck study. *Diabetes Care* 2007;30(2):318-24
36. Bashore TM, Cabell C, Fowler V, Jr. Update on infective endocarditis. *Curr Probl Cardiol* 2006;31(4):274-352
37. el-Shami K, Griffiths E, Streiff M. Nonbacterial thrombotic endocarditis in cancer patients: Pathogenesis, diagnosis, and treatment. *Oncologist* 2007;12(5):518-23
38. Lopez JA, Ross RS, Fishbein MC, Siegel RJ. Nonbacterial thrombotic endocarditis: A review. *Am Heart J* 1987;113(3):773-84
39. Rabinstein AA, Giovannelli C, Romano JG, Koch S, Forteza AM, Ricci M. Surgical treatment of nonbacterial thrombotic endocarditis presenting with stroke. *J Neurol* 2005;252(3):352-5
40. White H, Boden-Albala B, Wang C, et al. Ischemic stroke subtype incidence among whites, blacks, and Hispanics: The Northern Manhattan Study. *Circulation* 2005;111(10):1327-31
41. Clarke JT. Narrative review: Fabry disease. *Ann Intern Med* 2007;146(6):425-33
42. Markus HS, Alberts MJ. Update on genetics of stroke and cerebrovascular disease 2005. *Stroke* 2006;37(2):288-90
43. Daneschvar HL, Daw H. Heparin-induced thrombocytopenia (an overview). *Int J Clin Pract* 2007;61(1):130-7
44. Arepally GM, Ortel TL. Clinical practice. Heparin-induced thrombocytopenia. *N Engl J Med* 2006;355(8):809-17
45. Suzuki S, Brown CM, Wise PM. Mechanisms of neuroprotection by estrogen. *Endocrine* 2006;29(2):209-15
46. Yang SH, Liu R, Perez EJ, Wang X, Simpkins JW. Estrogens as protectants of the neurovascular unit against ischemic stroke. *Curr Drug Targets CNS Neurol Disord* 2005;4(2):169-77
47. Merchenthaler I, Dellovade TL, Shughrue PJ. Neuroprotection by estrogen in animal models of global and focal ischemia. *Ann NY Acad Sci* 2003;1007:89-100
48. Hum PD, Macrae IM. Estrogen as a neuroprotectant in stroke. *J Cereb Blood Flow Metab* 2000;20(4):631-52
49. Bushnell CD. Oestrogen and stroke in women: Assessment of risk. *Lancet Neurol* 2005;4(11):743-51
50. Simon JA, Hsia J, Cauley JA, et al. Postmenopausal hormone therapy and risk of stroke: The Heart and Estrogen/Progestin Replacement Study (HERS). *Circulation* 2001;103(5):638-42
51. Viscoli CM, Brass LM, Kernan WN, Sarrel PM, Suijsa S, Horwitz RJ. A clinical trial of estrogen-replacement therapy after ischemic stroke. *N Engl J Med* 2001;345(17):1243-9
52. Rossouw JE, Anderson GL, Prentice RL, et al. Risks and benefits of estrogen plus progestin in healthy postmenopausal women: Principal results From the Women's Health Initiative randomized controlled trial. *J Am Med Assoc* 2002;288(3):321-33
53. Hormone therapy for the prevention of chronic conditions in postmenopausal women: Recommendations from the U.S. Preventive Services Task Force. *Ann Intern Med* 2005;142(10):855-60
54. Executive summary. Hormone therapy. *Obstet Gynecol* 2004;104(4 Suppl):1S-4S
55. Toole JF, Malinow MR, Chambless LE, et al. Lowering homocysteine in patients with ischemic stroke to prevent recurrent stroke, myocardial infarction, and death: The Vitamin Intervention for Stroke Prevention (VISP) randomized controlled trial. *J Am Med Assoc* 2004;291(5):565-75
56. Wang X, Qin X, Demirtas H, et al. Efficacy of folic acid supplementation in stroke prevention: A meta-analysis. *Lancet* 2007;369(9576):1876-82
57. Spence JD. Homocysteine-lowering therapy: A role in stroke prevention? *Lancet Neurol* 2007;6(9):830-8
58. Chobanian AV, Bakris GL, Black HR, et al. Seventh report of the Joint National Committee on Prevention, Detection, Evaluation, and Treatment of High Blood Pressure. *Hypertension* 2003;42(6):1206-52
59. Rashid P, Leonardi-Bee J, Bath P. Blood pressure reduction and secondary prevention of stroke and other vascular events: A systematic review. *Stroke* 2003;34(11):2741-8
60. Arboix A, Besses C. Cerebrovascular disease as the initial clinical presentation of haematological disorders. *Eur Neurol* 1997;37(4):207-11
61. Liu M, Counsell C, Zhao XL, Wardlaw J. Fibrinogen depleting agents for acute ischaemic stroke. *Cochrane Database Syst Rev* 2003(3):CD000091
62. Elkind MS, Cole JW. Do common infections cause stroke? *Semin Neurol* 2006;26(1):88-99
63. Lampl Y, Boaz M, Gilad R, et al. Minocycline treatment in acute stroke: An open-label, evaluator-blinded study. *Neurology* 2007;69(14):1404-10
64. Touboul PJ, Hennerici MG, Meairs S, et al. Mannheim carotid intima-media thickness consensus (2004-2006). An update on behalf of the Advisory Board of the Third and Fourth Watching the Risk Symposium, 13th and 15th European Stroke Conferences, Mannheim, Germany, 2004, and Brussels, Belgium, 2006. *Cerebrovasc Dis* 2007;23(1):75-80
65. Blanco M, Nombela F, Castellanos M, et al. Statin treatment withdrawal in ischemic stroke: A controlled randomized study. *Neurology* 2007;69(9):904-10
66. Amarenco P, Bogousslavsky J, Callahan A, 3rd, et al. High-dose atorvastatin after stroke or transient ischemic attack. *N Engl J Med* 2006;355(6):549-59
67. Goldstein LB. Low LDL cholesterol, statins, and brain hemorrhage: Should we worry? *Neurology* 2007;68(10):719-20
68. Cimino M, Gelosa P, Gianella A, Nobili E, Tremoli E, Sironi L. Statins: Multiple mechanisms of action in the ischemic brain. *Neuroscientist* 2007;13(3):208-13
69. Oviagele B, Saver JL, Starkman S, et al. Statin enhancement of collateralization in acute stroke. *Neurology* 2007;68(24):2129-31
70. Bang OY. Intracranial atherosclerotic stroke: Specific focus on the metabolic syndrome and inflammation. *Curr Atheroscler Rep* 2006;8(4):330-6
71. Cestari DM, Weine DM, Panageas KS, Segal AZ, DeAngelis LM. Stroke in patients with cancer: Incidence and etiology. *Neurology* 2004;62(11):2025-30
72. Bousser MG, Welch KM. Relation between migraine and stroke. *Lancet Neurol* 2005;4(9):533-42
73. Classification and diagnostic criteria for headache disorders, cranial neuralgias and facial pain. Headache Classification Committee of the International Headache Society. *Cephalalgia* 1988;8(Suppl 7):1-96

74. Erminan M, Takkouche B, Isorna FC, Samii A. Risk of ischaemic stroke in people with migraine: Systematic review and meta-analysis of observational studies. *Br Med J* 2005;330(7482):63
75. Arpa J, Cruz-Martinez A, Campos Y, et al. Prevalence and progression of mitochondrial diseases: A study of 50 patients. *Muscle Nerve* 2003;28(6):690-5
76. Finsterer J. Central nervous system manifestations of mitochondrial disorders. *Acta Neurol Scand* 2006;114(4):217-38
77. Collop N. The effect of obstructive sleep apnea on chronic medical disorders. *Cleve Clin J Med* 2007;74(1):72-8
78. Yaggi H, Mohsenin V. Obstructive sleep apnoea and stroke. *Lancet Neurol* 2004;3(6):333-42
79. Helms A, Ajayi O, Kittner S. Investigating the link between oral contraceptives and stroke. *Pract Neurol* 2007;6(4):34-40
80. ACOG practice bulletin. No. 73: Use of hormonal contraception in women with coexisting medical conditions. *Obstet Gynecol* 2006;107(6):1453-72
81. Handke M, Harloff A, Olschewski M, Hetzel A, Geibel A. Patent foramen ovale and cryptogenic stroke in older patients. *N Engl J Med* 2007;357(22):2262-8
82. Mas JL, Arquizan C, Lamy C, et al. Recurrent cerebrovascular events associated with patent foramen ovale, atrial septal aneurysm, or both. *N Engl J Med* 2001;345(24):1740-6
83. Redding-Lallinger R, Knoll C. Sickle cell disease – pathophysiology and treatment. *Curr Prob Pediatr Adolesc Health Care* 2002;36:346-76
84. Wang WC. The pathophysiology, prevention, and treatment of stroke in sickle cell disease. *Curr Opin Hematol* 2007;14(3):191-7
85. Adams RJ. Big strokes in small persons. *Arch Neurol* 2007;64(11):1567-74
86. Adams RJ, Brambilla DJ, Granger S, et al. Stroke and conversion to high risk in children screened with transcranial Doppler ultrasound during the STOP study. *Blood* 2004;103(10):3689-94
87. Ware RE, Zimmerman SA, Sylvestre PB, et al. Prevention of secondary stroke and resolution of transfusional iron overload in children with sickle cell anemia using hydroxyurea and phlebotomy. *J Pediatr* 2004;145(3):346-52
88. Krishnamurti L. Hematopoietic cell transplantation for sickle cell disease: State of the art. *Expert Opin Biol Ther* 2007;7(2):161-72
89. Holmes S, Zwar N, Jimenez-Ruiz CA, et al. Bupropion as an aid to smoking cessation: A review of real-life effectiveness. *Int J Clin Pract* 2004;58(3):285-91
90. Haggstram FM, Chatkin JM, Sussenbach-Vaz E, Cesari DH, Fam CF, Fritscher CC. A controlled trial of nortriptyline, sustained-release bupropion and placebo for smoking cessation: Preliminary results. *Palm Pharmacol Ther* 2006
91. Cahill K, Stead LF, Lancaster T. Nicotine receptor partial agonists for smoking cessation. *Cochrane Database Syst Rev* 2007(1):CD006103
92. Williams KE, Reeves KR, Billing CB, Jr., Pennington AM, Gong J. A double-blind study evaluating the long-term safety of varenicline for smoking cessation. *Curr Med Res Opin* 2007;23(4):793-801
93. Administration USFaD. FDA Approves Novel Medication for Smoking Cessation; 2006 May 11, 2006. Report No. <http://www.fda.gov/bbs/topics/NEWS/2006/NEW01370.html>
94. Mercadante N. Management of patients with prosthetic heart valves: Potential impact of valve site, clinical characteristics, and comorbidity. *J Thromb Thrombolys* 2000;10(1):29-34
95. Hardman SM, Cowie MR. Fortnightly review: Anticoagulation in heart disease. *Br Med J* 1999;318(7178):238-44
96. Kelley RE. CNS vasculitis. *Front Biosci* 2004;9:946-55
97. Younger DS. Vasculitis of the nervous system. *Curr Opin Neurol* 2004;17(3):317-36
98. Jennette JC, Falk RJ. Nosology of primary vasculitis. *Curr Opin Rheumatol* 2007;19(1):10-6
99. Kuker W. Cerebral vasculitis: Imaging signs revisited. *Neuroradiology* 2007;49(6):471-9
100. Lee MS, Smith SD, Gator A, Hoffman GS. Antiplatelet and anticoagulant therapy in patients with giant cell arteritis. *Arthritis Rheum* 2006;54(10):3306-9
101. Melson MR, Weyand CM, Newman NJ, Biousse V. The diagnosis of giant cell arteritis. *Rev Neurol Dis* 2007;4(3):128-42
102. Salvarani C, Hunder GG. Giant cell arteritis with low erythrocyte sedimentation rate: Frequency of occurrence in a population-based study. *Arthritis Rheum* 2001;45(2):140-5
103. Ringleb PA, Strittmatter EI, Loewer M, et al. Cerebrovascular manifestations of Takayasu arteritis in Europe. *Rheumatology (Oxford)* 2005;44(8):1012-5
104. Arend WP, Michel BA, Bloch DA, et al. The American College of Rheumatology 1990 criteria for the classification of Takayasu arteritis. *Arthritis Rheum* 1990;33(8):1129-34
105. Reichart MD, Bogousslavsky J, Janzer RC. Early lacunar strokes complicating polyarteritis nodosa: Thrombotic microangiopathy. *Neurology* 2000;54(4):883-9
106. Lightfoot RW, Jr., Michel BA, Bloch DA, et al. The American College of Rheumatology 1990 criteria for the classification of polyarteritis nodosa. *Arthritis Rheum* 1990;33(8):1088-93
107. Lamprecht P, Gross WL. Wegener's granulomatosis. *Herz* 2004;29(1):47-56
108. Leavitt RY, Fauci AS, Bloch DA, et al. The American College of Rheumatology 1990 criteria for the classification of Wegener's granulomatosis. *Arthritis Rheum* 1990;33(8):1101-7
109. Kang DW, Kim DE, Yoon BW, Seo JW, Roh JK. Delayed diagnosis: Recurrent cerebral infarction associated with Churg-Strauss syndrome. *Cerebrovasc Dis* 2001;12(3):280-1
110. Keogh KA, Specks U. Churg-Strauss syndrome: Clinical presentation, antineutrophil cytoplasmic antibodies, and leukotriene receptor antagonists. *Am J Med* 2003;115(4):284-90
111. Masi AT, Hunder GG, Lie JT, et al. The American College of Rheumatology 1990 criteria for the classification of Churg-Strauss syndrome (allergic granulomatosis and angiitis). *Arthritis Rheum* 1990;33(8):1094-100
112. Calabrese LH, Mallek JA. Primary angitis of the central nervous system. Report of 8 new cases, review of the literature, and proposal for diagnostic criteria. *Medicine (Baltimore)* 1988;67(1):20-39
113. Moore PM. Vasculitis of the central nervous system. *Semin Neurol* 1994;14(4):307-12
114. Gilden DH, Kleinschmidt-DeMasters BK, LaGuardia JJ, Mahalingam R, Cohrs RJ. Neurologic complications of the reactivation of varicella-zoster virus. *N Engl J Med* 2000;342(9):635-45
115. de Gans J, van de Beek D. Dexamethasone in adults with bacterial meningitis. *N Engl J Med* 2002;347(20):1549-56
116. Johnson RT, Richardson EP. The neurological manifestations of systemic lupus erythematosus. *Medicine (Baltimore)* 1968;47(4):337-69
117. Devinsky O, Petito CK, Alonso DR. Clinical and neuropathological findings in systemic lupus erythematosus: The role of vasculitis, heart emboli, and thrombotic thrombocytopenic purpura. *Ann Neurol* 1988;23(4):380-4
118. Kitagawa Y, Gotoh F, Koto A, Okayasu H. Stroke in systemic lupus erythematosus. *Stroke* 1990;21(11):1533-9
119. Brust JC. Vasculitis owing to substance abuse. *Neurol Clin* 1997;15(4):945-57
120. Niehaus L, Meyer BU. Bilateral borderzone brain infarctions in association with heroin abuse. *J Neurol Sci* 1998;160(2):180-2
121. Serdaroglu P. Behcet's disease and the nervous system. *J Neurol* 1998;245(4):197-205
122. Call GK, Fleming MC, Sealfon S, Levine H, Kistler JP, Fisher CM. Reversible cerebral segmental vasoconstriction. *Stroke* 1988;19(9):1159-70
123. Haji-Ali RA, Furlan A, Abou-Chebel A, Calabrese LH. Benign angiopathy of the central nervous system: Cohort of 16 patients with clinical course and long-term followup. *Arthritis Rheum* 2002;47(6):662-9
124. Calabrese LH. Clinical management issues in vasculitis. Angiographically defined angitis of the central nervous system: Diagnostic and therapeutic dilemmas. *Clin Exp Rheumatol* 2003;21(6 Suppl 32):S127-30

125. Ng YS, Stein J, Ning M, Black-Schaffer RM. Comparison of clinical characteristics and functional outcomes of ischemic stroke in different vascular territories. *Stroke* 2007;38(8):2309-14
126. Caplan LR. Transient ischemic attack with abnormal diffusion-weighted imaging results: What's in a name? *Arch Neurol* 2007;64(8):1080-2
127. Kidwell CS, Warach S. Acute ischemic cerebrovascular syndrome: Diagnostic criteria. *Stroke* 2003;34(12):2995-8
128. A classification and outline of cerebrovascular diseases. *Neurology* 1958;8(5):395-434
129. Quinette P, Guillery-Girard B, Dayan J, et al. What does transient global amnesia really mean? Review of the literature and thorough study of 142 cases. *Brain* 2006;129(Pt 7):1640-58
130. Bettermann K. Transient global amnesia: The continuing quest for a source. *Arch Neurol* 2006;63(9):1336-8
131. Roach ES. Transient global amnesia: Look at mechanisms not causes. *Arch Neurol* 2006;63(9):1338-9
132. Menendez Gonzalez M, Rivera MM. Transient global amnesia: Increasing evidence of a venous etiology. *Arch Neurol* 2006;63(9):1334-6
133. Ali LK, Saver JL. The ischemic stroke patient who worsens: New assessment and management approaches. *Rev Neurol Dis* 2007;4(2):85-91
134. Brazis PW, Masdeau JC, Biller J. Localization in clinical neurology. Philadelphia, PA: Lippincott; 2007
135. Ali S, Khan MA, Khealani B. Limb-shaking Transient Ischemic Attacks: Case report and review of literature. *BMC Neurol* 2006;6:5
136. Camilo O, Goldstein LB. Seizures and epilepsy after ischemic stroke. *Stroke* 2004;35(7):1769-75
137. Murie JA, Sheldon CD, Quin RO. Carotid artery bruit: Association with internal carotid stenosis and intraluminal turbulence. *Br J Surg* 1984;71(1):50-2
138. Shorr RI, Johnson KC, Wan JY, et al. The prognostic significance of asymptomatic carotid bruits in the elderly. *J Gen Intern Med* 1998;13(2):86-90
139. Hillis AE. Aphasia: Progress in the last quarter of a century. *Neurology* 2007;69(2):200-13
140. Chambers BR, Brooder RJ, Donnan GA. Proximal posterior cerebral artery occlusion simulating middle cerebral artery occlusion. *Neurology* 1991;41(3):385-90
141. Maulaz AB, Bezerra DC, Bogousslavsky J. Posterior cerebral artery infarction from middle cerebral artery infarction. *Arch Neurol* 2005;62(6):938-41
142. Hommel M, Besson G, Pollak P, Kahane P, Le Bas JF, Perret J. Hemiplegia in posterior cerebral artery occlusion. *Neurology* 1990;40(10):1496-9
143. Adams HP, Jr., Bendixen BH, Kappelle LJ, et al. Classification of subtype of acute ischemic stroke. Definitions for use in a multicenter clinical trial. TOAST Trial of Org 10172 in Acute Stroke Treatment. *Stroke* 1993;24(1):35-41
144. Bamford J, Sandercock P, Dennis M, Burn J, Warlow C. Classification and natural history of clinically identifiable subtypes of cerebral infarction. *Lancet* 1991;337(8756):1521-6
145. Adams HP, Jr., del Zoppo G, Alberts MJ, et al. Guidelines for the early management of adults with ischemic stroke: A guideline from the American Heart Association/American Stroke Association Stroke Council, Clinical Cardiology Council, Cardiovascular Radiology and Intervention Council, and the Atherosclerotic Peripheral Vascular Disease and Quality of Care Outcomes in Research Interdisciplinary Working Groups: The American Academy of Neurology affirms the value of this guideline as an educational tool for neurologists. *Stroke* 2007;38(5):1655-711
146. Johnston SC, Gress DR, Browner WS, Sidney S. Short-term prognosis after emergency department diagnosis of TIA. *J Am Med Assoc* 2000;284(22):2901-6
147. Johnston SC, Rothwell PM, Nguyen-Huynh MN, et al. Validation and refinement of scores to predict very early stroke risk after transient ischaemic attack. *Lancet* 2007;369(9558):283-92
148. Feldmann E, Wilterdink JL, Kosinski A, et al. The Stroke Outcomes and Neuroimaging of Intracranial Atherosclerosis (SONIA) trial. *Neurology* 2007;68(24):2099-106
149. Pearson AC, Labovitz AJ, Tatineni S, Gomez CR. Superiority of transesophageal echocardiography in detecting cardiac source of embolism in patients with cerebral ischemia of uncertain etiology. *J Am Coll Cardiol* 1991;17(1):66-72
150. Rauh R, Fischereder M, Spengel FA. Transesophageal echocardiography in patients with focal cerebral ischemia of unknown cause. *Stroke* 1996;27(4):691-4
151. McNamara RL, Lima JA, Whelton PK, Powe NR. Echocardiographic identification of cardiovascular sources of emboli to guide clinical management of stroke: A cost-effectiveness analysis. *Ann Intern Med* 1997;127(9):775-87
152. Angeli S, Del Sette M, Beelke M, Anzola GP, Zanette E. Transcranial Doppler in the diagnosis of cardiac patent foramen ovale. *Neuro Sci* 2001;22(5):353-6
153. Del Sette M, Dini L, Rizzi D, Sugo A, Albano B, Gandolfo C. Diagnosis of right-to-left shunt with transcranial Doppler and vertebralbasilar recording. *Stroke* 2007;38(8):2254-6
154. Alexandrov AV, Molina CA, Grotta JC, et al. Ultrasound-enhanced systemic thrombolysis for acute ischemic stroke. *N Engl J Med* 2004;351(21):2170-8
155. Schwarz S, Georgiadis D, Aschoff A, Schwab S. Effects of body position on intracranial pressure and cerebral perfusion in patients with large hemispheric stroke. *Stroke* 2002;33(2):497-501
156. Caplan LR. Resolved: Heparin may be useful in selected patients with brain ischemia. *Stroke* 2003;34(1):230-1
157. Faden AI, Stoica B. Neuroprotection: Challenges and opportunities. *Arch Neurol* 2007;64(6):794-800
158. Garg R, Chaudhuri A, Munschauer F, Dandona P. Hyperglycemia, insulin, and acute ischemic stroke: A mechanistic justification for a trial of insulin infusion therapy. *Stroke* 2006;37(1):267-73
159. van den Berghe G, Wouters P, Weekers F, et al. Intensive insulin therapy in the critically ill patients. *N Engl J Med* 2001;345(19):1359-67
160. Van den Berghe G, Wilmer A, Hermans G, et al. Intensive insulin therapy in the medical ICU. *N Engl J Med* 2006;354(5):449-61
161. Gray CS, Hildreth AJ, Sandercock PA, et al. Glucose-potassium-insulin infusions in the management of post-stroke hyperglycaemia: The UK Glucose Insulin in Stroke Trial (GIST-UK). *Lancet Neurol* 2007;6(5):397-406
162. Inzucchi SE. Clinical practice. Management of hyperglycemia in the hospital setting. *N Engl J Med* 2006;355(18):1903-11
163. Umpierrez GE, Palacio A, Smiley D. Sliding scale insulin use: Myth or insanity? *Am J Med* 2007;120(7):563-7
164. Zaremba J. Hyperthermia in ischemic stroke. *Med Sci Monit* 2004;10(6):RA148-53
165. Fernandez A, Schmidt JM, Claassen J, et al. Fever after subarachnoid hemorrhage: Risk factors and impact on outcome. *Neurology* 2007;68(13):1013-9
166. Hypothermia after Cardiac Arrest Study Group. Mild therapeutic hypothermia to improve the neurologic outcome after cardiac arrest. *N Engl J Med* 2002;346(8):549-56
167. Bernard SA, Gray TW, Buist MD, et al. Treatment of comatose survivors of out-of-hospital cardiac arrest with induced hypothermia. *N Engl J Med* 2002;346(8):557-63
168. Bhardwaj A, Mirski M, Ulatowski J. *Handbook of Neurocritical Care*. Totowa, NJ: Humana Press; 2004
169. Nguyen T, Koroshetz WJ. Intensive care management of ischemic stroke. *Curr Neurol Neurosci Rep* 2003;3(1):32-9
170. Karepov VG, Gur AY, Bova I, Aronovich BD, Bornstein NM. Stroke-in-evolution: Infarct-inherent mechanisms versus systemic causes. *Cerebrovasc Dis* 2006;21(1-2):42-6
171. Davenport A. The management of renal failure in patients at risk of cerebral edema/hypoxia. *New Horiz* 1995;3(4):717-24
172. Vahedi K, Hofmeijer J, Juettler E, et al. Early decompressive surgery in malignant infarction of the middle cerebral artery: A pooled analysis of three randomised controlled trials. *Lancet Neurol* 2007;6(3):215-22
173. Berges S, Moulin T, Berger E, et al. Seizures and epilepsy following strokes: Recurrence factors. *Eur Neurol* 2000;43(1):3-8

174. McCarthy ST, Turner J. Low-dose subcutaneous heparin in the prevention of deep-vein thrombosis and pulmonary emboli following acute stroke. *Age Ageing* 1986;15(2):84-8
175. Sherman DG, Albers GW, Bladin C, et al. The efficacy and safety of enoxaparin versus unfractionated heparin for the prevention of venous thromboembolism after acute ischaemic stroke (PREVAIL Study): An open-label randomised comparison. *Lancet* 2007;369(9570):1347-55
176. Epstein NE. A review of the risks and benefits of differing prophylaxis regimens for the treatment of deep venous thrombosis and pulmonary embolism in neurosurgery. *Surg Neurol* 2005;64(4):295-301; discussion 2
177. Kamran SI, Downey D, Ruff RL. Pneumatic sequential compression reduces the risk of deep vein thrombosis in stroke patients. *Neurology* 1998;50(6):1683-8
178. Reddy M, Gill SS, Rochon PA. Preventing pressure ulcers: A systematic review. *J Am Med Assoc* 2006;296(8):974-84
179. Martin B. Prevention of gastrointestinal complications in the critically ill patient. *AACN Adv Crit Care* 2007;18(2):158-66
180. Chemerinski E, Levine SR. Neuropsychiatric disorders following vascular brain injury. *Mt Sinai J Med* 2006;73(7):1006-14
181. Ferro JM, Caeiro L, Verdelho A. Delirium in acute stroke. *Curr Opin Neurol* 2002;15(1):51-5
182. Caplan LR, Fisher M. The endothelium, platelets, and brain ischemia. *Rev Neurol Dis* 2007;4(3):113-21
183. Chen WH, Cheng X, Lee PY, et al. Aspirin resistance and adverse clinical events in patients with coronary artery disease. *Am J Med* 2007;120(7):631-5
184. Kreisel SH, Hennerici MG, Bazner H. Pathophysiology of stroke rehabilitation: The natural course of clinical recovery, use-dependent plasticity and rehabilitative outcome. *Cerebrovasc Dis* 2007;23(4):243-55
185. Mark VW, Taub E, Morris DM. Neuroplasticity and constraint-induced movement therapy. *Eura Medicophys* 2006;42(3):269-84
186. O'Malley MK, Ro T, Levin HS. Assessing and inducing neuroplasticity with transcranial magnetic stimulation and robotics for motor function. *Arch Phys Med Rehabil* 2006;87(12 Suppl 2):S59-66
187. Hogan N, Krebs HI, Rohrer B, et al. Motions or muscles? Some behavioral factors underlying robotic assistance of motor recovery. *J Rehabil Res Dev* 2006;43(5):605-18
188. Sheffler LR, Chae J. Neuromuscular electrical stimulation in neurorehabilitation. *Muscle Nerve* 2007;35(5):562-90
189. Phillips JP, Devier DJ, Feeney DM. Rehabilitation pharmacology: Bridging laboratory work to clinical application. *J Head Trauma Rehabil* 2003;18(4):342-56
190. Dobkin BH. Behavioral, temporal, and spatial targets for cellular transplants as adjuncts to rehabilitation for stroke. *Stroke* 2007;38(2 Suppl):832-9
191. Chen J, Chopp M. Neurorestorative treatment of stroke: Cell and pharmacological approaches. *NeuroRx* 2006;3(4):466-73
192. Wozniak MA, Kittner SJ. Return to work after ischemic stroke: A methodological review. *Neuroepidemiology* 2002;21(4):159-66

18. Extracranial Cerebrovascular Occlusive Disease

This chapter will discuss extracranial atherosclerotic disease and arterial dissection.

18.1. Atherosclerotic extracranial arterial disease

Large vessel atherosclerotic disease, most commonly extracranial carotid stenosis, accounts for some 15–20% of cerebral ischemic events.^{1,2}

18.1.1. Atherosclerosis

Atherosclerosis is thought to represent an inflammatory response to injury³ in a hyperlipidemic environment.⁴ The fatty streak is believed to precede the development of an atherosclerotic plaque, and is present in infancy.⁵ The distinguishing histological feature is the presence of foam cells, lipid-filled macrophages and myointimal smooth muscle cells adjacent to the endothelial layer.⁴ The process involves several stages:

1. Atherosclerosis begins with endothelial damage or dysfunction caused by a variety of factors.
 - (a) Elevated or modified low-density lipoprotein⁶
 - (b) Free radicals caused by
 - i. Cigarette smoking
 - ii. Hypertension
 - iii. Diabetes mellitus
 - (c) Genetic alterations
 - (d) Elevated plasma homocysteine levels⁷
 - (e) Infection (associated with atherosclerosis, but not yet shown to *cause* it)
 - i. *Chlamydia pneumoniae*⁸
 - ii. Herpes virus⁹
2. Smooth muscle cells migrate into the lesion and proliferate.¹⁰
3. The artery wall thickens, and the vessel undergoes gradual compensatory dilation (*remodeling*).
4. Macrophages and lymphocytes are activated and immigrate from the blood, which multiply within the lesion.
 - (a) Activation of mononuclear cells leads to the release of hydrolytic enzymes and cytokines, which can induce further injury and cause focal necrosis.
5. Fibrous tissue accumulates.
 - (a) Smooth muscle cells synthesize collagen.
 - (b) Fibrous cap forms over a core of lipid and necrotic tissue.
6. Capacity for compensatory dilation is exceeded and the lesion extends into the lumen of the vessel.
 - (a) Stenosis results
7. The plaque becomes unstable.
 - (a) The fibrous cap is degraded by metalloproteinases.
 - (b) Rupture of the plaque can occur, followed by thrombosis.

18.1.1.1. Plaque location

1. Atherosclerotic plaques develop where wall shear stress is reduced, not elevated.¹¹
 - (a) Metabolic and functional changes influencing an intact endothelium are necessary for plaque formation, rather than endothelial denudation.¹²

- (b) Low flow velocity and oscillation also contribute.¹³
 - (c) These hemodynamic factors result in delayed clearance of putative blood-borne atherogenic factors.
 - 2. Carotid bifurcation is prone to plaque formation.
 - (a) Large area of flow separation and low wall shear stress due to:
 - i. Large cross-sectional area of the carotid sinus (twice that of the ICA).
 - ii. Branching angle.
 - (b) Plaque is largest along the lateral wall of the carotid sinus.
 - i. Changing geometric configuration with plaque growth causes hemodynamic changes that favor plaque formation on the side and inner walls.
- Atherosclerosis can cause cerebral ischemic symptoms via two mechanisms¹⁴:
1. Hemodynamic compromise due to stenosis.
 - (a) Blood flow in a vessel the size of the ICA remains fairly constant until the internal diameter is reduced by approximately 70%.¹⁵
 2. Embolization from an ulcerative plaque.

18.1.1.2. Carotid artery bifurcation atherosclerotic disease

PREVALENCE

1. Prevalence of carotid atherosclerosis in the general population: 25%.¹⁶
 - (a) Intimal-medial thickening:
 - i. Men 9.4%, women 11.7%.
 - (b) Plaque:
 - i. Men 13.3%, women 13.4%.
 - (c) Stenotic plaque:
 - i. Men 2.7%, women 1.5%.
2. Prevalence of carotid stenosis ($\geq 40\%$) in the general population: 2–11%.^{17–21}

RISK FACTORS FOR CAROTID STENOSIS

1. Advanced age^{18,19,21–23}
2. Cigarette smoking^{18,19,23,24}
3. Sex:
 - (a) Male^{18,22,23}
 - (b) Female²⁵
4. Hypertension^{19,20,26–28}
5. Diabetes²⁹
6. Coronary artery disease³⁰
7. Mitral annulus calcification³¹
8. Peripheral arterial disease³²
9. Chronic renal failure³³
10. Total cholesterol^{18,23,27}
11. (Inversely) Ratio of high-density lipoprotein cholesterol to total cholesterol¹⁸
12. Elevated C-reactive protein³⁴
13. “Psychological strain”³⁵

18.1.2. Carotid endarterectomy

Carotid endarterectomy (CEA) has an uncommon distinction among surgical procedures in that it has been shown in randomized clinical trials to significantly reduce the risk of stroke in selected patients. It remains the standard of care for most patients. In 2002, some 134,000 CEAs were done in the U.S.³⁶

18.1.2.1. Symptomatic carotid stenosis

There have been three major recent randomized trials of CEA for symptomatic stenosis.

NORTH AMERICAN SYMPTOMATIC ENDARTERECTOMY TRIAL (NASCET)

- 2,885 patients with transient ischemic attack (TIA) or minor stroke within the previous 120 days who had a 30–99% ipsilateral ICA stenosis were randomized to receive either medical therapy (risk factor modification and aspirin 1,300 mg daily) or medical therapy and CEA.³⁷
- Stenosis was measured on angiography by comparing the residual lumen diameter in the most stenotic portion of the ICA to the lumen diameter of the ICA distal to the stenosis (this method has been used for all randomized trials of CEA except for the ECST).
- The arm of the trial for patients with $\geq 70\%$ stenosis was terminated before the end of the study because an interim analysis showed a considerable advantage of surgery.
 - For patients with $\geq 70\%$ stenosis, ipsilateral stroke rate at 2 years was
 - 26% in the medical group
 - 9% in the surgical group ($p < 0.001$)³⁸
 - Absolute risk reduction of 17%
 - The benefit persisted for at least 8 years³⁹
 - The risk reduction correlated with the degree of stenosis
- For moderate stenosis (50–69%), the 5-year ipsilateral stroke rate was:
 - 22.2% in the medical group
 - 15.7% in the surgical group ($p = 0.045$)³⁹
 - Absolute risk reduction of 6.5%

EUROPEAN CAROTID SURGERY TRIAL (ECST)

- 3,024 patients with TIA, retinal infarction, or nondisabling stroke within the previous 6 months were randomized to receive either medical therapy (use of aspirin was permitted but not required) or medical therapy and CEA.⁴⁰
- Stenosis in the ECST was determined on angiography by comparing the residual stenosis at the most stenotic portion of the vessel to the probable original lumen diameter at that site (Fig. 18.1). This method differed from the method used for NASCET; consequently, higher degrees of stenosis were reported in the ECST relative to NASCET angiographic measurements.
- The 3-year risk of major stroke or death in patients with $\geq 80\%$ (approximately $\geq 60\%$ by the NASCET method):
 - 26.5% in the medical group
 - 14.9% in the surgical group
 - Absolute risk reduction for surgery of 11.6%.
 - This risk reduction persisted for at least 10 years after surgery.

VETERANS AFFAIRS COOPERATIVE STUDY ON SYMPTOMATIC

STENOSIS (VACS)

- 197 men with symptomatic stenosis were randomized to receive medical therapy, including aspirin (325 mg daily), or medical therapy and CEA.
- Prematurely terminated when NASCET and ECST data were released.
- The risk of stroke at an average follow-up of 11.9 months in patients with $>50\%$ stenosis:
 - 19.4% in the medical group
 - 11.7% in the surgical group ($p = 0.011$)
 - Absolute risk reduction for surgery of 11.7%.⁴⁴
- Benefit of surgery was greater in patients with $>70\%$ stenosis:
 - Absolute risk reduction of 17.7% ($p = 0.004$).

ANALYSIS OF POOLED DATA

A meticulous analysis examined the results of the NASCET, ECST, and VACS by remeasuring the degree of stenosis in ECST using the method employed by the two other trials.⁴⁵ Data for 6,092 patients, with 35,000 patient-years of follow-up, were pooled. Results were stratified according to degree of stenosis:

- $<30\%$: CEA increased the risk of ipsilateral stroke.
 - Absolute risk increase: 2.2% ($p = 0.05$)
- 30–49%: No effect.
 - Absolute risk reduction: 3.2% ($p = 0.06$)
- 50–69%: Marginal benefit of CEA
 - Absolute risk reduction: 4.6% ($p = 0.04$)

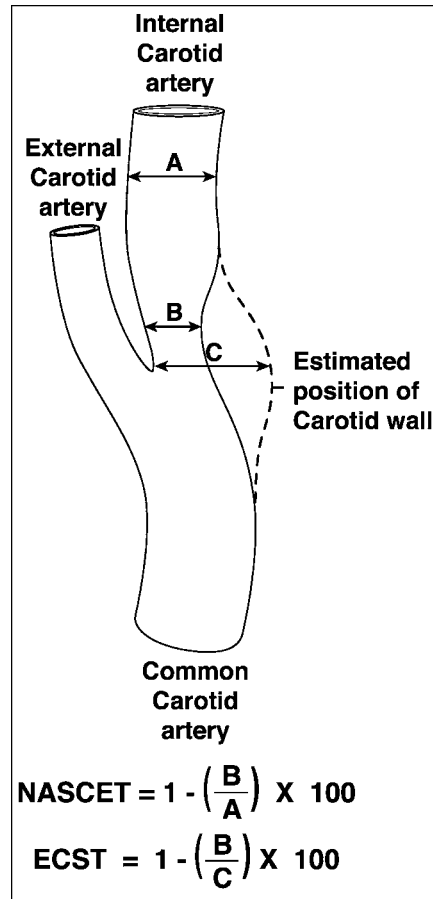


Fig. 18.1 Comparison of NASCET and ECST measurements of carotid stenosis.⁴¹ For example, 85% stenosis by the ECST method is approximately 70% stenosis by NASCET criteria. Adapted from THE LANCET, 351:1372–1373: Donnan GA et al.: "Surgery for prevention of stroke." © Elsevier 1998 with permission from Elsevier.

4. $\geq 70\%$ without near occlusion: Highly beneficial
 - (a) Absolute risk reduction: 16.0% ($p < 0.001$)
5. Near occlusion:
 - (a) Trend toward benefit at 2 years.
 - i. Absolute risk reduction: 5.6% ($p = 0.19$)
 - (b) No benefit at 5 years
 - i. Absolute risk *increase*: 1.7% ($p = 0.9$)

CLINICAL TRIAL DATA CAVEATS

1. Outcome after CEA strongly depends on risk for perioperative complications. In the NASCET, the 30-day rate of disabling stroke and death after CEA in patients with 70–99% stenosis was 2.1%. In the ECST, the 30-day rate of nonfatal major

- stroke or death was 7.0%. Complication rates significantly higher than 6% in patients with >70% stenosis can eliminate the benefit of the operation.⁴⁶
2. “Best medical therapy” has evolved since these trials were done, to include combination antiplatelet regimens and lipid-lowering agents.
 3. All three trials based measurement of stenosis on catheter angiography; most patient selection for CEA currently is done based on noninvasive imaging, such as duplex ultrasonography, which is less accurate.
 4. Not included in the trials were patients with remote symptoms or clinically silent cerebral infarctions identified on imaging.
 5. Some 20% of patients with symptomatic 70–99% carotid stenosis subsequently have a stroke related to other causes.⁴⁷

SUBGROUP ANALYSES

1. Ulcerated plaque.
 - (a) Natural history. In NASCET, patients in the medical arm with an ulcerated plaque had rates of ipsilateral stroke that increased dramatically with degree of stenosis. The risk of stroke at 24 months by degree of stenosis:⁴⁸
 - i. 75%; No ulcer: 21.2%; ulcer: 26.3%
 - ii. 85%; No ulcer: 21.3%; ulcer: 43.9%
 - iii. 95%; No ulcer: 21.3%; ulcer: 73.2%
 - (b) Surgical risk. In NASCET, the perioperative stroke and death rate was 1.5 times higher in the presence of an ulcerated plaque.⁴⁹
2. Hemispheric vs. retinal symptoms. Medically treated patients with hemispheric symptoms are at higher risk of stroke compared to patients with retinal ischemic events only.
 - (a) In NASCET, the relative risk of ipsilateral stroke in patients with 70–99% stenosis and hemispheric symptoms compared to patients with retinal symptoms only was 3.23 (95% CI, 1.47–7.12).⁵⁰
 - i. Benefit of surgery included patients whose only symptom was amaurosis fugax, as well as those with hemispheric symptoms.⁵⁰
3. Near occlusion. Defined as a “string sign” on angiography with a very high-grade stenosis with reduced caliber of the ICA distal to the stenosis⁵¹, near occlusion is associated with a lower risk of stroke in medically treated patients.
 - (a) In NASCET, patients in the medical arm with near occlusion had a 1-year stroke risk of 11.1%, which is lower than the 1-year stroke risk for patients with 90–94% stenosis, and approximately equal to the risk for patients with 70–89% stenosis.⁵²
 - i. Near occlusion also confers no additional risk of perioperative complications with CEA, compared to other patients with >70% stenosis.
4. Contralateral occlusion. Patients in NASCET with contralateral occlusion were at elevated risk of stroke with both medical therapy and CEA.⁵³
 - (a) The risk of ipsilateral stroke in medically treated patients with 50–99% stenosis and a contralateral occlusion was more than twice as that of patients without a contralateral occlusion.
 - (b) Perioperative risk of stroke or death for patients with 70–99% stenosis:
 - i. 14.3% for patients with a contralateral occlusion.
 - ii. 4.0% for patients without a contralateral occlusion.
5. Intraluminal thrombus. Angiographic evidence of intraluminal thrombus confers significant risk in both medically and surgically treated patients. In NASCET, 1.8% of patients had intraluminal thrombus. The 30-day rate of any stroke or death for surgical patients was similar to medically treated patients:⁵⁴
 - (a) Medical treatment group
 - i. With intraluminal thrombus: 10.7%
 - ii. Without intraluminal thrombus: 2.2%
 - (b) Surgical group
 - i. With intraluminal thrombus: 12.0%
 - ii. Without intraluminal thrombus: Not reported by Villareal and colleagues. However, for comparison, the 30-day risk of stroke and death rate for all surgical patients in NASCET was 6.5%.⁵⁵
6. Elderly patients. The risk of stroke increases with age.⁵⁶ Although the risk of CEA also increases significantly with age (a 36% increase in perioperative risk of stroke or death for patients >75 years⁵⁷), in NASCET, the net benefit of CEA in patients with 50–99% stenosis increased with age.⁵⁶

- (a) Age < 65, absolute risk reduction (ARR) 10%
 - (b) Age 65–74, ARR 15%
 - (c) Age ≥75, ARR 29%
7. Ipsilateral intracranial aneurysms. Forty-eight patients in NASCET had an unruptured intracranial aneurysm ipsilateral to the symptomatic carotid artery.⁵⁸
- (a) Of 25 patients in the surgery group, one patient had a fatal subarachnoid hemorrhage six days after CEA.
 - (b) There were no hemorrhages among the 23 patients in the medical group.

AMERICAN HEART ASSOCIATION RECOMMENDATION

CEA in symptomatic patients be undertaken by surgeons whose surgical morbidity and mortality rate is <6%.⁵⁹

18.1.2.2. Asymptomatic carotid stenosis

There have been five randomized trials of CEA for asymptomatic carotid stenosis.

ASYMPTOMATIC CAROTID ATHEROSCLEROSIS STUDY (ACAS)

1. 1,662 patients with ≥60% stenosis, defined by either angiography or carotid duplex ultrasonography, were randomized to CEA or medical treatment.⁶⁰ All patients received aspirin, 325 mg daily.
2. The study was stopped prematurely when a significant benefit for surgery was found.
3. Aggregate risk over 5 years for ipsilateral stroke and any perioperative stroke or death:
 - (a) 11.0% in the medical group
 - (b) 5.1% in the surgical group
 - i. Aggregate risk reduction of 53% (95% CI, 22–72%).
 - ii. Benefit was statistically significant for men but not women.
4. The rate of perioperative stroke and death in the CEA group, 2.3%, was similar to the annual rate of ipsilateral stroke in the medical group (2.2%).
5. No apparent increase in the benefit of CEA with increasing degree of stenosis.
6. Post hoc analysis of patients with contralateral occlusion⁶¹
 - (a) Medically treated patients with a contralateral occlusion were less likely to have a stroke than those patients without a contralateral occlusion. 5-year risk of perioperative and ipsilateral stroke:
 - i. Stroke rate without contralateral occlusion: 11.7%
 - ii. Stroke rate with contralateral occlusion: 3.5% ($p = 0.011$)
 - (b) CEA may not benefit patients with contralateral carotid occlusion, and may be harmful. Effect on absolute risk of 5-year risk of perioperative and ipsilateral stroke:
 - i. Without contralateral occlusion: 6.7% reduction
 - ii. With contralateral occlusion: 2.0 increase ($P = 0.047$).

VETERANS ADMINISTRATION COOPERATIVE ASYMPTOMATIC TRIAL

1. 444 men with ≥50% stenosis were randomized to receive medical therapy (recommended: aspirin, 1,300 mg daily) or medical therapy with CEA.⁶²
2. After a 4-year follow-up period, the combined incidence of ipsilateral neurologic events:
 - (a) 20.6% in the medical group
 - (b) 8.0% in the surgical group ($P < 0.001$)
3. The high overall mortality rate of 33%, primarily owing to coronary atherosclerosis, suggests that the study population differed from those in other trials and makes interpretation of these results difficult.⁶³

CAROTID ARTERY STENOSIS WITH ASYMPTOMATIC NARROWING: OPERATION VERSUS ASPIRIN (CASANOVA)

1. 410 patients with 50–90% stenosis were randomized to receive CEA and medical therapy or medical therapy only and followed for a mean interval of 42 months.⁶⁴ All patients received aspirin, 330 mg, and dipyridamole, 75 mg, three times daily.

2. No significant difference was found in stroke rates in the medical (11.3%) and surgical (10%) groups.
 - (a) The small size of the study and the fact that a significant number of crossovers occurred between the groups obscures the importance of the findings.

MAYO ASYMPTOMATIC CAROTID ENDARTERECTOMY TRIAL

1. A total of 158 patients received either medical therapy with aspirin or CEA *without* aspirin.⁶⁵ No major strokes or deaths occurred in either group.
2. Rate of myocardial infarction
 - (a) 9% in the medical group
 - (b) 26% in the surgical group ($p = 0.002$)
3. Study was terminated early owing to the significantly higher number of myocardial infarctions and transient cerebral ischemic events that occurred in the surgical group, presumably because this group did not receive aspirin.
4. Results underscore the importance of treating patients with cerebrovascular atherosclerosis with antiplatelet agents.

ASYMPTOMATIC CAROTID SURGERY TRIAL (ACST)

1. Largest study completed to date.
2. 3,120 patients with 60–99% stenosis on ultrasound were randomized to receive either *immediate* CEA or indefinite *deferral* of CEA (only 4% per year got CEA in this group).⁶⁶ Five-year risk of all strokes
 - (a) 11.8% in the deferred group
 - (b) 6.4% in the immediate group ($P < 0.0001$)
3. Risk of stroke or death within 30 days of CEA: 3.1%.
4. First study to show a protective effect of CEA in women. Five-year risk of non-perioperative stroke:
 - (a) 7.48% in the deferred group
 - (b) 3.40% in the immediate group ($p = 0.02$)
5. No apparent increase in benefit with increasing degree of stenosis.

AMERICAN HEART ASSOCIATION RECOMMENDATION

CEA in asymptomatic patients be undertaken by surgeons whose surgical morbidity and mortality rate is <3%.⁵⁹

18.1.3. Radiographic evaluation

1. CEA is only effective when patients are selected appropriately.
2. In the major trials for symptomatic carotid stenosis, patient eligibility was based on angiographic criteria. Thus, radiographic evaluation of carotid stenosis must match the accuracy of catheter angiography.
 - (a) In addition, CEA in asymptomatic patients carries a slender risk–benefit ratio, making accurate patient selection essential.
3. Carotid duplex ultrasonography is a useful screening method for detection of 70–99% stenosis.⁶⁷
 - (a) Sensitivity 94%
 - (b) Specificity 89%
4. Limitations of duplex ultrasonography:
 - (a) A significant proportion of CEAs are performed in general practice settings lacking designated, accredited vascular laboratories.^{68,69}
 - (b) Even accredited, high-volume vascular laboratories may report false positive results for carotid stenosis ranging from 20 to 41%.⁷⁰
 - (c) Duplex scanning cannot image the distal ICA, intracranial vasculature, identify tandem lesions, or accurately distinguish preocclusive disease from total occlusion.^{71,72}
 - (d) Duplex scanning does not indicate whether the lesion is relatively high in the cervical region, which is information that is important in planning for a CEA.
5. These limitations *necessitate* additional confirmatory studies in the evaluation of patients with carotid stenosis.

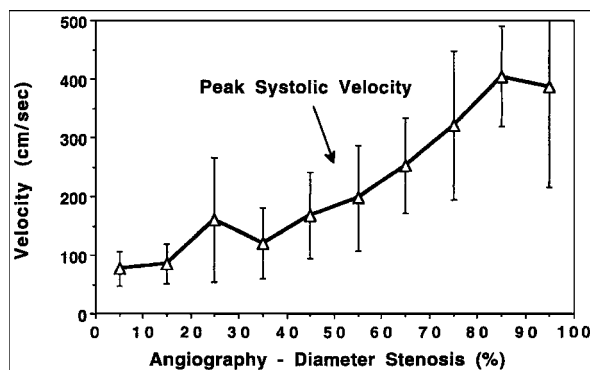


Fig. 18.2 Carotid Doppler velocities and degree of stenosis. Relationship between the mean peak systolic velocity (PSV) and the percentage of stenosis and the percentage of stenosis measured arteriographically. The PSV increases with the increasing severity of stenosis. Error bars show 1 SD about the mean. Reproduced from Radiology, 214: 247-52, Grant EG, Duerinckx AJ, El Saden SM, et al. "Ability to Use Duplex US to Quantify Internal Carotid Arterial Stenoses: Fact or Fiction?" © 2000 Radiology Society of North America, with permission.

- (a) Computed tomography angiography⁷³ and magnetic resonance angiography^{74,75} can be used to confirm the results of carotid duplex imaging with a high degree of accuracy.
- (b) The authors' preference is to obtain ultrasound studies and a CTA (second choice: MRA) in the evaluation of all patients with carotid stenosis.

INTERPRETATION OF CAROTID ULTRASOUND RESULTS

The term *carotid duplex* refers to a combination of Doppler measurements of velocity and B-mode imaging of the vessel. Carotid stenosis usually begins to cause a change in blood flow velocity when the degree of stenosis exceeds 50% (by NASCET criteria, corresponding to a 70% reduction in cross-sectional area). Flow velocity increases as the severity of stenosis increases (Fig. 18.2). Three validated criteria for measuring stenosis >50% include:⁷⁶

1. Maximum peak systolic velocity (PSV) or Doppler frequency shift
2. B-mode measurements (gray-scale and/or color Doppler) of diameter reduction
3. ICA/CCA PSV ratio

A consensus paper published by the Society of Radiologists in Ultrasound established ultrasound criteria for the diagnosis of ICA stenosis (Table 18.1).⁷⁷

1. Primary criteria:
 - (a) Parameters (ICA PSV and the presence of plaque on gray-scale and/or color Doppler ultrasound images) that should be used to diagnose and grade ICA stenosis.
2. Additional criteria:
 - (a) Additional parameters (ICA/CCA PSV ratio and ICA peak diastolic velocity) that can be used when the ICA PSV may not indicate the actual degree of stenosis due to technical or clinical factors (e.g., tandem lesions, discrepancy between the visual assessment of the plaque and the ICA PSV, elevated CCA velocity, hyperdynamic cardiac state, or low cardiac output).

Table 18.1 Consensus panel Gray-Scale and Doppler ultrasound criteria for diagnosis of ICA stenosis

Degree of stenosis (%)	Primary parameters		Additional parameters	
	ICA PSV (cm/sec)	Plaque estimate (%) ^a	ICA/CCA PSV ratio	ICA EDV (cm/sec)
Normal	<125	None	<2.0	<40
<50	<125	<50	<2.0	<40
50–69	125–230	≥50	2.0–4.0	40–100
≥70 but less than near occlusion	>230	≥50	>4.0	>100
Near occlusion	High, low, or undetectable	Visible	Variable	Variable
Total occlusion	Undetectable	Visible, no detectable lumen	Not applicable	Not applicable

^a Plaque estimate (diameter reduction) with gray-scale and color Doppler ultrasound. Reproduced from Radiology, 229:340–6, Grant EG, Benson CB, Moneta GL et al.: "Gray-scale and Doppler US diagnosis – Society of Radiologists in Ultrasound Consensus Conference." © 2003 Radiology Society of North America, with permission

18.1.4. Recurrent stenosis after CEA

1. Two forms:
 - (a) Early restenosis (<2 years after CEA) is characterized by myointimal cell proliferation. Diffuse thickening of the intima and media results in fibrous hypertrophic scarring throughout the CEA site. Stenosis of this type usually has a smooth, firm, nonulcerated appearance.
 - (b) Late restenosis (>2 years after CEA) is the result of a reaccumulation of atherosclerotic plaque and is typically friable and ulcerated in appearance.
2. Risk of restenosis after CEA:
 - (a) Meta-analysis of 29 reports⁷⁹, the risk of recurrent stenosis after CEA:
 - i. 10% in the first year
 - ii. 3% in the second year
 - iii. 3% in the second year
 - iv. Long-term risk is about 1% per year
 - (b) Risk factors for restenosis:⁸⁰
 - i. Diabetes
 - ii. Female sex
3. Risk of stroke with recurrent stenosis is unclear.
 - (a) Relative risk of stroke in patients with recurrent stenosis compared with that in patients without recurrent stenosis ranged from 0.1 to 10.⁷⁹
 - (b) Myointimal hyperplasia leads to a smooth, nonulcerated stenosis without the same potential for ulceration and thromboembolism as atherosclerotic stenosis.
4. Redo-CEA carries a higher risk of complications than primary CEA.
 - (a) 30-day perioperative neurological event rate:
 - i. 4.8% in reoperation patients
 - ii. 0.8% in primary CEA ($p = 0.015$)⁸¹
 - (b) Cranial nerve injury:
 - i. 17% in reoperation patients
 - ii. 5.3% in primary CEA ($p < 0.001$)
 - Although most of these injuries were transient.
5. The authors' preference is to reserve treatment of recurrent stenosis strictly for patients who are symptomatic.

18.1.4.1. Medical management

Medical management of carotid artery disease centers on cholesterol reduction, modification of risk factors, and antiplatelet therapy.

Table 18.2 Serum LDL goals according to risk factors⁸⁵

Risk factor(s)	Serum LDL goal
Coronary heart disease (CHD)	<100 mg/dL
Multiple (≤ 2) risk factors ^a	<130 mg/dL
Zero or one risk factor	<160 mg/dL

^a Risk factors include cigarette smoking; hypertension (BP $\geq 140/90$ mmHg or on antihypertensive medication); low HDL cholesterol (<40 mg/dL); family history of premature CHD (CHD in male first degree relative < 55 years; CHD in female first degree relative < 65 years); age (men ≥ 45 years; women ≥ 55 years)

CHOLESTEROL REDUCTION

1. Elevated serum low-density lipoprotein (LDL) cholesterol out of proportion to high-density lipoprotein (HDL) cholesterol is the greatest risk factor for propagation of atherosclerosis.
2. 3-Hydroxy-3-methyl glutaryl coenzyme A (HMG-CoA) reductase inhibitors (statins) have been shown to slow the progression of carotid atherosclerosis^{82,83} and reduce the risk of stroke in patients with coronary artery disease.⁸⁴
3. Guidelines for the medical management of hypercholesterolemia have been set forth by the National Institutes of Health (Table 18.2).⁸⁵
4. Patients placed on statins should be informed about and monitored for signs of myopathy, which can affect a small percentage of patients.⁸⁶
5. Lovastatin (Mevacor[®], Merck & Co., Inc., Whitehouse Station, NJ).⁸⁷
 - (a) Usual recommended starting dose is 20 mg once a day with the evening meal. Recommended dosing range is 10–80 mg/day in single or two divided doses; the maximum recommended dose is 80 mg/day.
 - (b) Patients should be advised to report unexplained muscle pain, tenderness, or weakness.

HYPERTENSION

1. Most prevalent risk factor for stroke.⁸⁸
2. Treatment reduces risk of stroke.
 - (a) An analysis of randomized trials found that a 5–6-mmHg reduction in diastolic blood pressure can reduce the risk of stroke by 42% ($p < 0.0001$).⁸⁹
3. Over-correction of hypertension should be avoided to avert cerebrovascular hemodynamic failure, particularly in patients with hemodynamically significant carotid stenosis or with long-standing untreated hypertension.

CIGARETTE SMOKING

1. In a meta-analysis of 32 studies, the summary relative risk of stroke for smokers is 1.5 (95% CI, 1.4–1.6).⁹⁰
2. A discussion of Zyban[®]^{91,92} and other medications to help with smoking cessation is in Chapter 17.

ANTIPLATELET THERAPY

1. Rationale: Symptomatic carotid thromboembolic disease occurs in a high-flow environment, and generally appears with acute plaque rupture and thrombosis.³³
 - (a) A characteristic *white clot* – a platelet-rich thrombus – forms
 - (b) Platelets participate in plaque rupture and thrombosis⁹⁴
 - (c) Lipids released by a ruptured plaque activate platelets⁹⁵
2. Aspirin
 - (a) Inhibits platelet aggregation by inhibiting cyclo-oxygenase, which produces thromboxane.
 - (b) Mayo Asymptomatic Carotid Endarterectomy Study⁶⁵
 - i. Terminated early because a significantly higher number of MIs and transient cerebral ischemic events occurred in the surgical group, presumably due to the absence of aspirin use in the surgical group.

- ii. Underscores the importance of aspirin use in patients with asymptomatic carotid stenosis.
- (c) Appropriate dose of aspirin remains controversial.
 - i. Low-dose aspirin (30–283 mg daily) has been shown to reduce the risk of stroke in asymptomatic patients with coronary artery disease⁹⁶ and in patients with TIA.^{97,98}
 - ii. The ASA and Carotid Endarterectomy Trial randomized patients undergoing CEA to receive low doses (81 or 325 mg daily) or high doses (650 or 1,300 mg daily).⁹⁹
 - The combined rate of stroke, myocardial infarction, and death was lower in the low-dose groups than in the high-dose groups at 3 months (6.2 vs. 8.4%, $p = 0.03$).
 - iii. Conversely, high-dose aspirin (650–1,300 mg daily) may have protective effects that are unrelated to cyclo-oxygenase inhibition.¹⁰⁰
 - A comparison of studies using doses ≥ 950 mg daily with those using doses < 950 mg daily found a greater reduction in stroke risk in the higher dose studies.¹⁰⁰
 - Drawback: gastrototoxicity.
- 3. Clopidogrel
 - (a) Inhibits platelet aggregation induced by adenosine diphosphate by inhibiting the platelet adenosine diphosphate receptor.
 - (b) Clopidogrel vs. Aspirin in Patients at Risk of Ischemic Events (CAPRIE) randomized 19,185 patients with vascular disease to receive clopidogrel (75 mg daily) or aspirin (325 mg daily).¹⁰¹ Annual risk of ischemic stroke, MI, or vascular death was lower in the clopidogrel group:
 - i. Clopidogrel group 5.32%
 - ii. Aspirin group 5.83% ($p = 0.043$)
 - (c) Management of Atherothrombosis with Clopidogrel in High-Risk Patients with Recent Transient Ischemic Attack or Ischemic Stroke (MATCH)¹⁰² randomized 7,599 patients with a recent stroke or TIA to receive either clopidogrel (75 mg daily) or clopidogrel (75 mg daily) plus low-dose aspirin (75 mg daily). During an 18 month follow-up period, there was:
 - i. No significant difference in the rate of ischemic events (stroke or MI).
 - ii. Significant increase in life-threatening hemorrhage in the combination therapy group (2.6% vs. 1.3%) (absolute risk increase 1.3% [95% CI, 0.6–1.9]).
- 4. Dipyridamole
 - (a) Inhibits platelet aggregation by inhibiting phosphodiesterase and increasing levels of cyclic adenosine monophosphate.
 - (b) The European Stroke Prevention Study-2 (ESPS-2) randomized 6,602 patients with prior stroke or TIA to receive treatment with extended-release dipyridamole (400 mg daily), low-dose aspirin (50 mg daily), the two agents in combination, or placebo.¹⁰³ Two-year stroke risk reduction compared to placebo was found to be greatest for the combination regimen:
 - i. Risk reduction 37% with combination therapy ($p < 0.001$)
 - ii. A post hoc analysis of patients in ESPS-2 at high risk for stroke also found combination therapy to be more effective than low-dose aspirin alone at preventing stroke.¹⁰⁴
 - (c) Available as Aggrenox[®] (aspirin 25 mg/extended release dipyridamole 200 mg) capsules.
 - (d) Headaches occur in 38.7% of patients treated with aspirin/dipyridamole combination.¹⁰⁵
 - i. Usually self-limited and decrease in frequency over time.
- 5. Ticlopidine
 - (a) Prevents platelet aggregation by blocking the 5'-diphosphate binding site of the IIa/IIIb receptor, the final common pathway of platelet aggregation.
 - (b) The Ticlopidine Aspirin Stroke Study (TASS) randomized 3,069 patients with minor stroke or TIA to receive aspirin 650 mg BID or ticlopidine 250 mg BID.¹⁰⁶ The ticlopidine group had a greater reduction in 3-year risk of stroke:
 - i. The ticlopidine group had a 21% relative risk reduction for stroke compared with aspirin ($p = 0.024$).
 - (c) Ticlopidine is associated with an approximately 1–2% incidence of severe neutropenia and >60 cases of ticlopidine-associated thrombotic thrombocytopenia purpura (TTP) have been reported.¹⁰⁷

- (d) Neutrophil counts are required at 2-week intervals for the first three months of ticlopine therapy; the drug must be held if the neutrophil count drops below 1,200/mm³.
 - (e) The authors' preference is to use ticlopidine as a second-line agent (in combination with aspirin) in patients undergoing angioplasty and stenting who cannot tolerate clopidogrel.
6. Anticoagulants
- (a) There is no controlled trial data to support the use of warfarin or heparin in patients with either symptomatic or asymptomatic extracranial carotid atherosclerotic disease.
 - i. Exception: A course of anticoagulation may be an option when an intraluminal thrombus is present.
7. Antiplatelet Therapy Recommendations:
- (a) Evidence-based guidelines for the prevention of cerebral ischemic events published by The Seventh ACCP Conference on Antithrombotic and Thrombolytic Therapy:¹⁰⁸
 - i. In patients who have had a noncardiogenic stroke or TIA, the following are all acceptable (Grade IA evidence):
 - Aspirin 50–325 mg daily, *or*
 - Combination of aspirin 25 mg and extended-release dipyridole 200 mg BID, *or*
 - Clopidogrel 75 mg daily
 - (b) The authors' preference is to use aspirin, 325 mg daily for most patients with atherosclerotic carotid disease.

18.1.5. Carotid angioplasty and stenting

18.1.5.1. A brief history of carotid angioplasty and stenting

Endovascular treatment of extracranial carotid stenosis has been made possible by developments in endovascular technology for other applications in recent decades. Angioplasty with or without stenting has been established as an alternative to surgical revascularization in patients with coronary artery disease and peripheral vascular disease. Angioplasty for carotid stenosis was first reported in the early 1980s.^{109,110} In contrast to CEA, in which the atherosclerotic plaque is removed, angioplasty causes fracture of the plaque and stretching of the media.¹¹¹ With angioplasty alone, however, plaque debris may be released into the intracranial circulation; and the resulting irregularity within the plaque can become thrombogenic sites before remodeling and endothelialization can occur.^{112,113} High rates of neurological complications attributable to embolization of plaque fragments were described in the initial reports of carotid angioplasty.^{114,115}

The development of intravascular stenting was driven by a need for improvement in coronary balloon angioplasty, in which acute occlusion and restenosis after angioplasty are problematic. Following the first report of carotid stenting in 1995¹¹⁶, stenting was seen as necessary along with carotid angioplasty to stabilize the plaque and reduce embolization of debris. Angioplasty with stenting has become the endovascular treatment of choice for carotid stenosis.¹¹⁷ However, stenting did not eliminate the problem of embolization. An early trial of CAS vs. CEA was stopped prematurely because of a high rate of stroke in the CAS group.¹¹⁸ Of seven patients randomized to CAS, five had a stroke. Embolic protection techniques have evolved to prevent embolization during CAS. The first report of an embolic protection technique described a triple coaxial catheter with a latex balloon mounted at the distal end.¹¹⁹ In recent years, ICA filters and flow-reversal techniques have also been introduced. Presently, filter devices are the most common embolic protection devices. Appropriate sizing of angioplasty balloons has minimized the risk of asystole during CAS, and eliminated the need for routine cardiac pacing. The addition of antiplatelet agents such as clopidogrel and GP IIb/IIIa inhibitors has also served to prevent and treat thromboembolic complications during CAS.^{120,121}

The use of CAS has expanded globally in recent years, driven by a combination of influences, including improvements in technique and devices, the medical device industry, the availability of physicians with endovascular expertise (e.g., interventional cardiologists), and a growing popular interest in less invasive treatment.

By the year 2000, some 5,210 carotid stent procedures, involving 4,757 patients, had been reported worldwide, with a technical success rate of 98.4% and a combined periprocedural stroke and death rate of 5.07%.¹²² By comparison, an update of the same survey in 2003 reported 12,392 procedures with a technical success rate of 98.9% and a combined stroke and death rate of 4.75%.¹²³

Despite refinements in CAS, CEA remains the “gold standard” for the treatment of carotid stenosis in selected patients. In most trials and registries to date, CAS has been evaluated as an alternative for patients who would be at high risk for complications with CEA. In 1998, a consensus statement by the American Heart Association recommended that the use of CAS be limited to randomized trials.¹²⁴ A number of multicenter trials and registries are underway, and several are completed, to evaluate the efficacy of CAS with adjunctive distal protection, primarily in high-risk patients (Table 18.3). The Carotid Revascularization Endarterectomy vs. Stent Trial (CREST) is an NIH-sponsored multicenter randomized trial of CEA vs. CAS in nonhigh-risk patients. CREST originally enrolled only patients with symptomatic stenosis $\geq 50\%$ by angiography (or $>70\%$ by ultrasound); however, in June 2005, the study protocol was amended to permit enrollment of asymptomatic patients. Patient enrollment in CREST was recently completed and the first results are expected to be reported in 2010. Major European trials include SPACE, (Stent-Protected Percutaneous Angioplasty of the Carotid vs. Endarterectomy)¹³² and EVA-3S (Endarterectomy vs. Angioplasty in Patients with Symptomatic Severe Carotid Stenosis).¹³³

18.1.5.2. Rationale for carotid angioplasty and stenting

The rationale for developing CAS centers on three lines of evidence: (1) the results of the CEA clinical trials have important limitations, (2) patients at high risk for surgery may benefit from a less-invasive procedure, and (3) anatomic and other neurovascular considerations in certain patients make CAS more feasible than surgery.

1. *Limitations of CEA clinical trial results*
 - (a) Rigid selection criteria excluded many patients.
 - i. e.g., NASCET, exclusion criteria included
 - Age older than 79 years
 - Previous ipsilateral endarterectomy
 - Intracranial stenosis more severe than the surgically accessible lesion
 - Lung, liver, or renal failure, etc.³⁷
 - (b) Trial surgical results did not reflect actual clinical practice.
 - i. In a study of Medicare patients undergoing CEA during 1992 and 1993 in trial hospitals (participating in NASCET and ACAS) and in nontrial hospitals, the perioperative mortality rate was significantly greater in the nontrial hospitals.¹³⁴
 2. High-risk surgical candidates
 - (a) Patients with a previous history of MI, angina, or hypertension are approximately 1.5 times more likely to have medical complications with CEA than are patients without these medical problems.¹³⁵
 - (b) Patients with coronary artery disease are at elevated risk of perioperative stroke and death with CEA, with an incidence as high as 25%¹³⁶ or 40%.¹³⁷
 - (c) Congestive heart failure is also an independent risk factor for stroke or death in conjunction with CEA.^{136,138}
 - (d) Elderly patients are at elevated risk with CEA.
 - i. Postoperative stroke or death rate for patients with asymptomatic carotid stenosis who are 75 years or older is 7.5%, compared to 1.8% in patients younger than 75 years.¹³⁸
 3. Neurovascular considerations
 - (a) Anatomic features that make CEA difficult:
 - i. High carotid bifurcation (at or above C2).
 - ii. Short or thick neck.
 - iii. Cervical stenosis that limits neck rotation.
 - (b) Tandem lesions:
 - i. Identified in up to one third of patients with symptomatic carotid stenosis.¹³⁹
 - ii. In a review of 1,160 CEAs in symptomatic patients, including 65 patients with ipsilateral carotid siphon stenosis, there was a trend toward a higher rate of adverse outcomes in patients with tandem lesions (13.9% vs. 7.9%, $P = 0.10$).¹⁴⁰

Table 18.3 Carotid angioplasty and stent trials*

Study	Sponsor	Design	Patient population	Stent	Embolic protection device	No. of patients	Results
ARCHEr 1 and 2	Guidant	Single-arm registry	High risk	OTW Acculink	OTW Accunet	436	Final 1-year data (all death, stroke, MI within 30 days + all ipsilateral stroke from 31 days to 1 year): ARCHEr 1: 8.3%, ARCHEr 2: 10.2%, weighted historical control: 14.5% ¹²⁵
ARCHEr 3	Guidant	Single-arm registry	High risk	RX Acculink	RX Acculink	145	30-day death, stroke, MI rate: 8.3% ¹²⁵
BEACH	Boston Scientific	Single-arm registry	High risk	Monorail Wallstent	FilterWire EX and EZ	480	30-day stroke, death, MI rate: 5.4% 1-year stroke, death, MI rate: 9.1% ¹²⁶
CABERNET	EndoTex	Single-arm registry	High risk	NexStent	FilterWire EX and EZ	454	30-day stroke, death MI rate: 3.8% ¹²⁷
CAPTURE	Guidant	Single-arm registry	Patient's physician used an ACCULINK and/ or ACCUNET (no specific patient population or degree of stenosis indicated)	RX Acculink	RX Acculink	N/A	N/A
CaRESS	MIH	Nonrandomized double-arm registry; physician chooses treatment – 2:1 CEA: CAS	Symptomatic and asymptomatic	Physician's choice	GuardWire Plus	397	No significant differences between CAS and CEA 30-day stroke and death rate: 2.1% (vs. 3.6% in CEA); Stroke, death, or MI at 30 days + ipsilateral stroke or death from neurologic causes within 31 days to 1 year: 10.9% (vs. 14.3% in CEA) ¹²⁸

CASES	Cordis	Single-arm registry	High risk	Precise	AngioGuard-XP	1,500 anticipated	N/A
CREATE	ev3	Single-arm registry	High risk	Protégé	Spider	420 anticipated	N/A
CREST	NIH and Guidant	Randomized trial	Symptomatic and asymptomatic	Acculink	AccUNET	2,500 anticipated	N/A
MAVERiC I and II	Medtronic	Single-arm registry	High risk	Exponent	Guardwire	498	MAVERiC I 30-day Stroke, death, or MI: 5.1% One year stroke, death, or MI: 5.1% MAVERiC II 30-day Stroke, death, or MI: 5.3% 30-day MACE: 5.9%
MAVERiC Int'l	Medtronic	Outside US single-arm registry	High risk	Exponent	Interceptor	51	30-day all stroke and deaths: 5.7% ¹²⁹
MO/MA	Invatec	Single-arm registry	75% of final population was high risk	Any	MO/MA	157	30-day stroke, death and MI: 8%
PASCAL	Medtronic	Single-arm registry	Symptomatic and asymptomatic	Exponent	Any CE Mark-approved device ^a	115	Stroke, death, or MI at 30 days + ipsilateral stroke or death from neurologic causes within 31 days to 1 year: 12.2% (vs. 20.1% in the CEA group) ¹³⁰
SAPPHIRE	Cordis	Randomized trial, CAS vs. CEA	High risk (age >80 alone qualifies)	Precise	Angioguard	334	30-day stroke, death MI rate: 7.2% ¹³¹
SECURITY	Abbott Vascular Devices	Single-arm registry	High risk	X.act	EmboShield	305	N/A
VIVA	Bard Peripheral Vascular	Single-arm registry	High risk	Vivexx	EmboShield	550 anticipated	N/A

* Abbreviations: OTW Over the wire, RX Rapid exchange, ARCHER Acculink for Revascularization of Carotids in High-Risk Patients, BEACH Boston Scientific EPI: A Carotid Stent for High-Risk Surgical Patients, CAS carotid artery angioplasty and stenting, CABERNET Carotid Artery Revascularization using Boston Scientific EPI FilterWire and EndoTex Stent, CAPTURE Carotid ACCULINK/ACCUNET Post Approval Trial to Uncover Rare Events, CarRESS Carotid Revascularization with Endarterectomy or Stenting Systems, CEA carotid endarterectomy, CREATE Carotid Revascularization with ev3 Arterial Technology Evolution, CREST Carotid Revascularization Endarterectomy vs. Stent Trial, MAVERiC Evaluation of the Medtronic AVE Self-expanding Carotid Stent System with Distal Protection in the Treatment of Carotid Stenosis, NIH National Institutes of Health, PASCAL Performance And Safety of the Medtronic AVE Self-Expandable Stent in Treatment of Carotid Artery Lesions, SAPPHIRE Stenting and Angioplasty with Protection in Patients at High-Risk for Endarterectomy, SECURITY Registry Study to Evaluate the Neuroshield Bare Wire Cerebral Protection System and X-Act Stent in Patients at High Risk for Carotid Endarterectomy, VIVA Vivexx Carotid Revascularization Trial, N/A Not available

^a Attestation of Conformity issued by the European Union of Agrément, which is a requirement for products sold in the European Market

- (c) Contralateral occlusion
 - i. Some 14% of patients with significant carotid stenosis have contralateral carotid artery occlusion.¹⁴¹
 - ii. NASCET:⁵³
 - Risk of ipsilateral stroke in medically treated patients with 70–99% stenosis of the symptomatic carotid artery and occlusion of the contralateral carotid artery was 69.4% at 2 years.
 - Perioperative risk of stroke or death was 14.3%.
- (d) Radiation-induced stenosis
 - i. CEA in this situation is encumbered by relatively long lesions, scarring around the vessels, and poorly defined dissection planes,^{142,143} and elevated risk of perioperative complications.¹⁴⁴
- (e) Restenosis after CEA
 - i. Surgery for recurrent carotid stenosis carries significantly greater risk of morbidity than surgery for primary stenosis.^{145,146}
 - ii. The rate of cranial nerve injuries is as high as 17%.⁸¹

18.1.5.3. Major CAS single-arm trials and registries

A wide variety of CAS trials have been completed or are in progress around the world. Several important studies are summarized in [Table 18.3](#). Most published data on CAS to date is from single-arm registries involving patients at high risk of complications with CEA; the 30-day stroke, death, and MI rates in these studies range from 3.8% to 8.3%.^{126,127}

18.1.5.4. Major randomized trials: CAS versus CEA

Several randomized trials have been completed ([Table 18.4](#)).

THE LEICESTER TRIAL: “THE STOPPED TRIAL”

1. 23 patients with symptomatic carotid stenosis (>70%) were randomized to receive either CEA or CAS.¹¹⁸
2. Only 17 patients received treatment before the trial was suspended because of a high rate of complications in the angioplasty group.
 - (a) CAS: 5/7 patients had a stroke
 - (b) CEA: 0/10 patients, no strokes ($p = 0.0034$).
3. Factors contributing to the high rate of complications in the CAS group:¹⁴⁹
 - (a) Pre-dilation was not routine
 - (b) Interventionalist experience was limited (while the surgeons had considerable expertise)
 - (c) Only one antiplatelet agent was used
 - (d) Study was done prior to the widespread use of embolic protection

Table 18.4 Randomized trials in progress: CAS versus CEA*

Study	Patient population	Country	No. of patients anticipated
CREST	Symptomatic and asymptomatic	US	2,500
EVA-3S	Symptomatic and asymptomatic	France	1,000
ICSS (AKA CAVATAS-2)	Symptomatic	United Kingdom	1,500
SPACE ¹⁴⁸	Symptomatic	Germany, Austria, Switzerland	1,200

* Abbreviations: CREST Carotid Revascularization Endarterectomy vs. Stent Trial, EVA-3S Endarterectomy vs. Angioplasty in Patients With Symptomatic Severe Carotid Stenosis, ICSS International Carotid Stenting Study, CAVATAS Carotid and Vertebral Transluminal Angioplasty Study, SPACE (Stent-Protected Percutaneous Angioplasty of the Carotid vs. Endarterectomy)

CAROTID AND VERTEBRAL TRANSLUMINAL ANGIOPLASTY STUDY (CAVATAS)¹⁵⁰

1. 504 patients with symptomatic or asymptomatic carotid stenosis were randomized to receive either carotid angioplasty (without or with stenting) or CEA.
2. Inclusion criteria were not restrictive (i.e., the patient population was not high risk).
3. *Only 26% of patients in the angioplasty group also received a stent; 74% received angioplasty alone.*
4. 30-day results
 - (a) Disabling stroke or death:
 - i. Carotid angioplasty 6.4%
 - ii. CEA 5.9% (difference not significant)
 - (b) Cranial neuropathy:
 - i. Carotid angioplasty 0%
 - ii. CEA 8.7% ($p < 0.0001$)
 - (c) Major groin or neck hematoma:
 - i. Carotid angioplasty 1.2%
 - ii. CEA 6.7% ($p < 0.0015$)
5. Long-term results
 - (a) No significant difference in the rate of ipsilateral stroke was found with survival analysis up to 3 years after randomization (adjusted hazard ratio = 1.04, 95% CI, 0.63–1.70, $p = 0.9$).
6. Restenosis at one year ($\geq 70\%$):¹⁵¹
 - (a) Carotid angioplasty 18.5%
 - (b) CEA 5.2% ($p = 0.0001$)

STENTING AND ANGIOPLASTY WITH PROTECTION IN PATIENTS AT HIGH RISK FOR ENDARTERECTOMY (SAPPHIRE)

1. 334 patients at high risk for surgery (Table 18.5) with symptomatic stenosis ($\geq 50\%$) or asymptomatic stenosis ($\geq 80\%$) were randomized to CEA or CAS. The study was designed to test the hypothesis that CAS is not inferior to CEA. The study was discontinued because of low enrollment. Adverse event rates were lower in the CAS group.¹³⁰
 - (a) Primary endpoint (stroke, death, or MI at 30 days plus ipsilateral stroke or death from neurologic causes within 31 days to 1 year)
 - (b) The study was designed to test the hypothesis that CAS is not inferior to CEA. Trend toward a lower incidence of death, stroke, or MI at 1 year:
 - i. 4.8% in the CAS group.
 - ii. 9.8% in the CEA group ($p = 0.09$).

Table 18.5 SAPPHERE criteria for high risk^a

1.	Clinically significant cardiac disease (congestive heart failure, abnormal stress test, or need for open-heart surgery)
2.	Severe pulmonary disease
3.	Contralateral carotid occlusion
4.	Contralateral laryngeal-nerve palsy
5.	Previous radical neck surgery or radiation therapy to the neck
6.	Recurrent stenosis after endarterectomy
7.	Age >80 years

^a At least one factor required

CAROTID REVASCLARIZATION ENDARTERECTOMY VERSUS STENT TRIAL (CREST)

1. NIH-sponsored multicenter trial. Patients with symptomatic stenosis ($>50\%$) or asymptomatic stenosis ($\geq 60\%$) are randomized to CAS or CEA. Enrollment was completed in 2009.

2. Two studies:
 - (a) Lead-in study. Nonrandomized credentialing arm; interventionalists not yet credentialed to enroll patients in the randomized study may enroll up to 20 patients in the lead-in study to demonstrate experience and safety in CAS.
 - (b) Randomized study. Fully credentialed investigators may enroll patients to be randomized to either CAS or CEA.
 - i. The randomized phase of CREST originally included only symptomatic patients; asymptomatic patients were allowed to enroll in the randomized phase beginning in June 2005 because of slow recruitment.
3. Enrollment totalled 2,522 randomized patients.
4. Lead-in phase data about age as a risk factor for complications with CAS¹⁵²
 - (a) 749 lead-in patients (30.7% symptomatic, 69.3% asymptomatic). The proportion of patients suffering periprocedural stroke and death increased with age ($p = 0.0006$)
 - i. >60 years 1.7%
 - ii. 60–69 years 1.3%
 - iii. 70–79 years 5.3%
 - iv. ≥80 years 12.1%
 - (b) These findings lead the CREST trial organizers to prohibit the enrollment of patients aged ≥80 in the lead-in study.
 - i. Octogenarians are still allowed to enroll in the randomized phase.

STENT-PROTECTED PERCUTANEOUS ANGIOPLASTY OF THE CAROTID VS. ENDARTERECTOMY (SPACE)¹³²

1. 1,183 patients in Germany, Austria, and Switzerland with symptomatic stenosis (≥50%) were randomized to CAS or CEA. The study was designed to test the hypothesis that CAS is not inferior to CEA. The study was stopped prematurely (1,900 patients were planned) because of problems with funding and enrollment.¹⁵³
2. Primary endpoint (ipsilateral ischemic stroke or death from the time of randomization to 30 days after procedure):
 - (a) 6.84% in the CAS group
 - (b) 6.34% in the CEA group (one-sided p value for noninferiority was 0.09)
3. Longer-term results are anticipated.
4. *SPACE failed to prove noninferiority of carotid-artery stenting compared with carotid endarterectomy for the periprocedural complication rate.*
5. Controversies about SPACE:
 - (a) Use of embolic protection devices was not required in this trial, and only 27% of the cases in the CAS group were done with embolic protection devices. However, the 30-day rate of ipsilateral stroke or death in SPACE was 7.3% in CAS cases with embolic protection, compared to 6.7% in those without it.¹⁵⁴
 - (b) The noninferiority test used by SPACE is different from the analysis used by previous carotid surgery trials, in which the null hypothesis assumed no difference between the two interventions. This may contribute to uncertainty and a perception of ambiguity about the results.¹⁵⁴

ENDARTERECTOMY VERSUS ANGIOPLASTY IN PATIENTS WITH SYMPTOMATIC SEVERE CAROTID STENOSIS (EVA-3 S)¹³³

1. A total of 527 patients in France with symptomatic stenosis (≥60%) were randomized to CAS or CEA. Enrollment was stopped prematurely (enrollment of 872 patients was originally planned) for “reasons of safety and futility.”
2. Primary endpoint (any stroke or death within 30 days after treatment):
 - (a) 9.6% in the CAS group
 - (b) 3.9% in the CEA group ($p = 0.004$)
3. Any stroke or death at six months:
 - (a) 11.7% in the CAS group
 - (b) 6.1% in the CEA group ($p = 0.02$)
4. Controversies about EVA-3 S:
 - (a) Relatively modest requirements for interventionalists to participate in the study.¹⁵³

- (b) Wide variety of devices used for CAS (any of five different stents and seven different embolic protection devices were permitted).

18.1.5.5. Recurrent stenosis after CAS

1. Global registry¹²³
 - (a) Restenosis rates of carotid stenting were 2.7%, 2.6%, and 2.4% at 1, 2, and 3 years, respectively.
2. Single-center series, carotid duplex:
 - (a) Restenosis (> or =70%), median follow-up 12 months: 3.0%¹⁵⁵
 - (b) Restenosis (> or =80%), median follow-up 16.4 months: 5%¹⁵⁶
3. Four-center series, carotid duplex. Analysis of 2,172 cases found rates of restenosis (>50%) to be 1%, 2%, and 3.4% after 1, 3, and 5 years, respectively.¹⁵⁷
4. CAS changes the physiology of atherosclerotic disease. Most strokes attributable to carotid stenosis are embolic; CAS stabilizes the plaque. Therefore, restenosis after CAS may not have the same natural history as native carotid stenosis.

18.1.5.6. Effect of embolic protection on periprocedural complication rates in CAS

Release of embolic material during CAS without embolic protection is common, as demonstrated by transcranial Doppler¹⁵⁸ and postprocedure MRI.¹⁵⁹ A variety of embolic protection devices have been introduced for use during CAS (see Chap. 10). No randomized trial has compared CAS with and without embolic protection. A number of series, however, have shown a significant reduction in complication rates with the use of embolic protection devices.

1. The global registry found a periprocedural and death rate of 5.29% in cases without protection, compared to a 2.23% rate with protection.¹²³
2. A systematic review of published studies including 2,537 CAS procedures found that the 30-day stroke and death rate in both symptomatic and asymptomatic patients was 1.8% in patients treated with cerebral protection devices compared with 5.5% in patients treated without cerebral protection devices ($p < 0.001$).¹⁶⁰
 - (a) This effect was due to a reduction in both major and minor strokes; the death rates were almost identical.
3. In the French EVA-3S Trial, in which patients were randomized to CEA or CAS with or without embolic protection, the Safety Committee recommended stopping CAS without protection, because the 30-day stroke rate was 3.9 times higher than that of CAS with protection (4/15 vs. 5/58).¹⁶¹

18.1.5.7. Timing of CEA or CAS after a stroke

The optimal timing of surgical or endovascular treatment of carotid stenosis after a cerebral ischemic event is controversial. Surgery within 7 days of a stroke has been found to be a risk factor for complications with CEA.¹⁶² The authors' preference is wait treatment 1–2 weeks after a completed stroke, and to proceed sooner for patients with TIAs only or crescendo TIAs.

18.1.5.8. Patient selection: CAS or CEA?

Appropriate patient selection is important to minimize risk of complications. Factors that elevate risk of complications with CEA are discussed above (in *Rationale for Carotid Angioplasty and Stenting*). A number of neurovascular factors have been shown to increase the risk of complications with CAS:

1. Tortuous anatomy
2. Long lesion
3. Tandem lesions
4. Ulcerated lesion
5. Intraluminal thrombus

Factors that can guide patient selection are summarized in [Table 18.6](#).

Table 18.6 Patient selection for angioplasty and stenting or carotid endarterectomy carotid angioplasty and stenting

Carotid Angioplasty and Stenting	
Relative indications	Relative contraindications
• Poor surgical candidate	• Elongated aortic arch or otherwise difficult vascular access
• Accessible vascular anatomy	• High grade carotid stenosis
• Focal stenosis	• Long region of stenosis
• Tandem stenoses	• Aortic or femoral artery occlusion
• Previous neck surgery	• Intolerance to antiplatelet agents
• Radiation-induced stenosis	• Intolerance to iodinated contrast
• High risk for anesthesia complications	• Intraluminal thrombus
Carotid Endarterectomy	
Relative indications	Relative contraindications
• Younger patient	• Advanced age
• Few medical conditions	• Multiple medical conditions
• No previous neck surgery or radiation	• Previous neck surgery or radiation
• Thin, supple neck	• Short, thick neck
• Patent, nonstenotic contralateral carotid artery	• Contralateral carotid occlusion
• Low carotid bifurcation	• High carotid bifurcation

18.1.6. Atherosclerotic carotid occlusion

18.1.6.1. Asymptomatic carotid occlusion

1. Prevalence
 - (a) Prevalence of silent ICA occlusion in the general population age >60 is <1%.¹⁶³
2. Prognosis – *excellent*.
 - (a) Very low risk of ischemic stroke.^{164,165}
 - (b) “The benign course of never-symptomatic carotid occlusion”¹⁶⁶
 - i. Risk of stroke in 30 patients with never-symptomatic carotid occlusion during an average follow-up of 32 months: 3.3%. No strokes occurred in the carotid territory ipsilateral to the occluded artery in these patients.

18.1.6.2. Symptomatic carotid occlusion

1. Incidence
 - (a) Annual incidence is 6 per 100,000 persons.¹⁶⁷
2. Prognosis^{168,169}
 - (a) Overall annual risk of stroke: 5–7%
 - (b) Annual risk of stroke ipsilateral to the occluded artery: 2–6%
3. Prognosis depends strongly on *hemodynamic status*.
 - (a) Cerebral blood flow in the presence of carotid occlusion is maintained by collateral circulation (e.g., blood flow from the contralateral carotid system via the anterior communicating artery or pial-collaterals on the cortical surface). Collateral circulation in some patients with carotid occlusion has little reserve (i.e., blood flow in the affected brain region is at or

near maximum, and cannot be increased if necessary by autoregulatory dilation of cerebral arterioles). These patients are at elevated risk of stroke. Quantitative assessment of cerebral hemodynamic status in these patients has been best demonstrated by ^{15}O PET measurement of oxygen extraction fraction (OEF) and xenon-CT cerebral blood flow measurement with acetazolamide challenge.

4. ^{15}O PET
 - (a) This nuclear medicine technique permits quantitative measurement of CBF, CBV, and OEF.
 - (b) Stage 0. Cerebral perfusion pressure (CPP) is normal. OEF shows little regional variation. Moderate reductions in CPP have little effect on cerebral blood flow (CBF) because of autoregulatory compensation.
 - (c) Stage I. Chronic, sustained reduction of CPP (e.g., due to ICA occlusion) causes cerebral arterioles to be maximally dilated to maintain adequate CBF. Cerebrovascular reserve is exhausted. PET demonstrates increased cerebral blood volume (CBV) relative to CBF (increased CBV/CBF ratio).
 - (d) Stage II. Further reduction of CPP leads to a *decrease* in CBF and an *increase* in OEF, to maintain cerebral oxygen metabolism and brain function.
 - i. Prospective study of 81 patients with previous stroke or TIA in the territory of an occluded carotid artery.¹⁶⁹ Rate of stroke in average follow-up of 31.5 months:
 - 12 of 39 (30.8%) patients with Stage II hemodynamic failure
 - 3 of 42 (7.1%) patients without ($p = 0.004$).
5. Xenon-CT
 - (a) Nonradioactive xenon inhalation technique permits quantitative measurement of CBF. Acetazolamide, a carbonic anhydrase inhibitor, causes dilation in cerebral arterioles and an increase in CBF. In regions of the brain with Stage I or Stage II hemodynamic failure, cerebral arterioles are unable to dilate any further in response to acetazolamide, and regional CBF either remains the same after administration of acetazolamide, or decreases as blood flow is diverted from low-flow to high-flow regions.
 - i. Prospective study of 68 patients with symptomatic carotid stenosis or occlusion who underwent xenon-CT studies before and after administration of acetazolamide.¹⁷⁰ Patients were classified according to response and followed for a mean of 24 months.
 - Group 2: CBF reduction >5% in at least one vascular territory and baseline flow of 45 cc/100 gm/min or less.
 - 36% rate of stroke (all ipsilateral to side with lowest reserve) ($p = 0.0007$).
 - Group 1: all other patients.
 - 4.4% rate of stroke (both strokes occurred contralateral to the side with lowest reserve).

18.1.6.3. Surgical options for cerebral revascularization in patients with carotid occlusion

1. Direct anastomotic bypass procedures:
 - (a) Low flow
 - i. E.g., STA–MCA bypass
 - ii. The first EC–IC bypass was performed by Yasargil, in Zurich, Switzerland, in 1967.¹⁷¹
 - (b) High flow
 - i. E.g., saphenous vein or radial artery graft
 - ii. Can establish up to 3.7 times increase in flow compared to a low-flow bypass¹⁷²
 - iii. Excimer laser method is a new technique for high-flow bypass¹⁷³
2. Indirect nonanastomotic bypass procedures:
 - (a) Used primarily in younger patients (e.g., Moyamoya Syndrome).
 - (b) Examples:
 - i. Temporal muscle grafting (encephalomyosynangiosis); transposition of the STA (encephaloduroarteriosynangiosis).

18.1.6.4. Extracranial–Intracranial (EC/IC) Bypass Trial

1. 1,377 patients with recent hemisphere stroke, retinal infarction, or TIA and atherosclerotic occlusion or narrowing of the ipsilateral ICA or MCA were randomized to receive either medical care (714 patients, aspirin 325 mg QID) or medical care with STA–MCA bypass (663 patients).¹⁷⁴ Average follow-up was 55.8 months.
 - (a) ICA occlusion was the most common angiographic lesion. The percentages of patients with each type of angiographic finding (medical group/surgery group):
 - i. MCA stenosis: 13.0%/14.4%
 - ii. MCA occlusion: 11.1%/12.1%
 - iii. ICA stenosis (above C2): 16.7%/15.4%
 - iv. ICA occlusion: 59.9%/58.1%
 2. 30-day surgical results:
 - (a) Mortality 0.6%
 - (b) Major stroke rate 2.5%
 3. Postoperative patency rate 96%.
 4. Results:
 - (a) Overall stroke rate (i.e., total number of patients having a fatal or non-fatal stroke over a mean follow-up period of 55.8 months):
 - i. Medical group: 28.7%
 - ii. Surgical group: 30.9%
 - (b) Subgroups:
 - i. All patients with ICA occlusion:
 - Medical group: 29.1%
 - Surgical group: 31.4%
 - ii. ICA occlusion with symptoms between time of angiogram and randomization:
 - Medical group: 34.7%
 - Surgical group: 45.7%
 - iii. ICA stenosis ($\geq 70\%$):
 - Medical group: 36.1%
 - Surgical group: 37.7%
 - iv. MCA stenosis ($\geq 70\%$):
 - Medical group: 23.7%
 - Surgical group: 44.0%
 - v. Bilateral ICA occlusion:
 - Medical group: 39.5%
 - Surgical group: 45.2%
 - vi. MCA occlusion:
 - Medical group: 22.8%
 - Surgical group: 20.0%
 5. No subgroup was found to benefit from bypass.
 - (a) Two groups did significantly worse with surgery:
 - i. MCA stenosis ($\geq 70\%$) ($n = 109$)
 - ii. Ischemic symptoms and occluded ICA ($n = 287$)
 6. *This study thus failed to confirm the hypothesis that extracranial-intracranial anastomosis is effective in preventing cerebral ischemia in patients with atherosclerotic arterial disease in the carotid and middle cerebral arteries.*
 7. Study results have been highly controversial.^{175–178}
 - (a) Primary limitations and criticisms:
 - i. Study did not base patient selection on hemodynamic assessment.
 - Imaging technology since the EC/IC bypass trial was done has progressed significantly, enabling identification of patients who have symptomatic cerebrovascular hemodynamic failure, and would thus, presumably, benefit the most from bypass surgery.
 - ii. Patients with MCA stenosis were included; bypass in this setting can reduce flow through the stenotic vessel, leading to occlusion.^{179–181}
 - iii. A large number of patients (2,572) received STA–MCA bypass outside of the trial while the trial was being conducted.
 - iv. Multiple sources of bias were present (e.g., observational bias).

18.1.6.5. Carotid Occlusion Surgery Study (COSS)

1. Trial in progress to evaluate STA–MCA bypass in patients with symptomatic ICA occlusion and ipsilateral increase OEF measured by PET (<http://www.cosstrial.org/coss/home.asp>).
2. A total of 372 patients will be randomized to surgical or nonsurgical treatment.

18.1.7. Extracranial vertebral artery atherosclerotic disease

Some 20% of cerebral ischemic events involve the posterior circulation. In the New England Medical Center Posterior Circulation Registry (NEMC-PCR), the extracranial vertebral artery was the most common site of vascular occlusive lesions in patients with vertebrobasilar insufficiency (VBI).¹⁸² In an angiographic series of 4,728 patients with ischemic stroke, some degree of extracranial stenosis was seen in 18% of cases on the right and 22.3% on the left.¹⁸³

Atherosclerosis is the most common cause of extracranial vertebral artery stenosis; less common causes are arterial dissection, extrinsic compression due to trauma, osteophytes, or fibrous bands, or vasculitis (most commonly giant-cell arteritis).¹⁸⁴ Risk factors for atherosclerotic extracranial vertebral artery disease are identical to those found in patients with atherosclerotic carotid artery disease.¹⁸² However, atherosclerotic plaque at the vertebral artery origin is considered to be “smoother” and less prone to ulceration than in the carotid system.¹⁸⁵ White patients seem to be preferentially affected by atherosclerosis of the extracranial vertebral artery.¹⁸⁶

Two patterns of symptoms due to extracranial vertebral artery stenosis have been observed:^{182,187}

1. Brief and multiple TIAs, consisting of dizziness, loss of balance, and visual disturbances, and sometimes precipitated by changes in position.
2. Sudden-onset stroke, usually involving the PICA-supplied region of the cerebellum or the distal intracranial posterior circulation territory.

The most common mechanism of stroke in these patients is intra-arterial embolism, rather than hemodynamic failure.¹⁸⁷

18.1.8. Diagnosis

The diagnosis of VBI attributable to extracranial vertebral artery occlusive disease depends on a combination of symptoms and radiographic findings:

1. Symptoms of VBI (must include at least two of the following symptoms):¹⁸⁸
 - (a) Motor or sensory symptoms
 - (b) Dysarthria
 - (c) Imbalance
 - (d) Dizziness or vertigo
 - (e) Tinnitus
 - (f) Alternating paresthesias
 - (g) Homonymous hemianopia
 - (h) Diplopia
 - (i) Other cranial nerve palsies
 - (j) Dysphagia
 - i. Fewer than 1% of patients with VBI in the NEMC-PCR had only a single presenting symptom or sign.¹⁸²
 - ii. “Drop attacks” (sudden loss of postural tone without warning) are rarely attributable to VBI. No patient in the NEMC-PCR had a drop attack as the only symptom.^{182,189}
2. $\geq 50\%$ stenosis of the vertebral artery by CTA, angiography, or MRA.
 - (a) The authors favor CTA for imaging; CTA has been found to be as accurate as angiography in imaging of vertebral artery stenosis¹⁹⁰, and CTA has the additional advantage of also imaging extravascular structures.
3. Additional findings can support the diagnosis of symptomatic VBI:
 - (a) MRI evidence of ischemic injury to the posterior circulation (may not be found in patients with minor stroke or TIAs only).
 - (b) Hypoplasia or stenosis affecting the contralateral vertebral artery.

18.1.9. Prognosis

The prognosis of symptomatic extracranial vertebral artery stenosis is not well understood. Although a number of reports have suggested a more benign natural history than for symptomatic carotid stenosis, a more recent systematic review found that the risk of stroke or death in patients with VBI appears to be at least as high as it is in patients with symptomatic carotid bifurcation disease, and possibly higher.¹⁹¹

MEDICAL THERAPY

Combination antiplatelet regimens (e.g., aspirin and clopidogrel) are emerging as the mainstay of medical therapy for patients with VBI. A combination of aspirin and dipyridamole was shown to significantly reduce the rate of stroke in patients with VBI compared to placebo.¹⁹² Patients with atherosclerosis and hyperlipidemia should also be treated with a lipid-lowering agent.¹⁹³ The authors' preference is to avoid warfarin therapy for patients with atherosclerotic stenosis, for lack of convincing evidence of efficacy and safety.

ANGIOPLASTY AND STENTING

Although surgery for vertebral artery stenosis has been reported¹⁹⁴, endovascular techniques have become the most common approach in patients who remain symptomatic despite medical therapy. No large series or randomized trial data are available.

1. Immediate results
 - (a) High rates of technical success (residual stenosis < 50%):
 - i. 97%¹⁹⁵
 - ii. 100%.¹⁹⁶
 - (b) Relatively low rates of procedure-related complications:
 - i. 8.8% (all TIAs without permanent neurologic change)¹⁹⁷
 - ii. 3% (one TIA)¹⁹⁷
 - iii. 0%.¹⁹⁶
2. Long-term results
 - (a) Relatively high rates of restenosis:
 - i. 100% of patients with angioplasty alone.¹⁹⁸
 - ii. Angiographic follow-up (mean 16.2 months) in 30 patients:¹⁹⁵
 - 13 (43%) had restenosis (>50%).
 - No correlation between restenosis and return of symptoms.
 - iii. High rates of recurrent stenosis are presumably due to vessel wall recoil.
3. Stenting of Symptomatic Atherosclerotic Lesions in the Vertebral or Intracranial Arteries (SSYLVIA).¹⁹⁹
 - (a) Nonrandomized trial using the NEUROLINK System (Guidant Corp.) balloon-mounted stent. 18 patients underwent treatment for extracranial vertebral artery stenosis (6 ostia, 12 proximal to the PICA).
 - (b) Technical success (residual stenosis < 50%) achieved in 17 (94%) patients.
 - (c) No periprocedural neurological events.
 - (d) 6-month follow-up angiogram was done in 14 (78%) patients.
 - i. 6 (43%) of these 14 showed evidence of in-stent restenosis (>50%).
 - 4 of 6 (67%) of patients with ostial lesions had restenosis.
 - ii. 2 (11%) of 18 had a stroke corresponding to the vascular distribution of the treated vertebral artery; both were treated for ostial lesions and both had restenosis on angiography.

18.2. Extracranial arterial dissection

18.2.1. Carotid dissection

18.2.1.1. Spontaneous internal carotid artery dissection

1. Common cause of stroke in young adults (20%).²⁰⁰
 - (a) Mean age of patients with stroke due to spontaneous carotid dissection: 44.5.²⁰¹

- (b) 70% of cases are between the ages of 35 and 70.²⁰²
 - (c) No significant gender effect.²⁰²
 - (d) Underlying vasculopathy in 15–20%²⁰³
 - i. e.g., fibromuscular dysplasia (see below), Marfan's syndrome, Ehlers-Danlos syndrome
 - (e) Recent infection is a risk factor:²⁰⁴
 - i. e.g., upper respiratory tract, gastrointestinal tract infection
 - (f) History of minor trauma may be evident.
 - i. 41% have a history of "trivial" trauma²⁰⁵
 - ii. 24% of cases were associated with chiropractic maneuvers in one series²⁰⁶
2. Usually arise from an intimal tear.
 - (a) Blood enters the wall of the artery to form an intramural hematoma
 - i. Intramural hematoma is usually located in the tunica media, but may be eccentric, toward the intima or adventitia.²⁰⁷
 - Toward intima results in stenosis
 - Toward adventitia can result in an aneurysmal dilatation.
 - The term *pseudoaneurysm* in this setting is misleading, because the aneurysmal wall consists of blood vessel elements.
 3. Dissection typically begins 2–3 cm distal to the origin.
 - (a) Distal extent is usually limited by the skull base.
 4. Cerebral ischemia can result from:
 - (a) Thromboembolism (from platelet aggregation due to disruption of the intima and sludging of blood in low-flow regions, such as in a false lumen).
 - i. *Most common mechanism of stroke following spontaneous carotid dissection.*^{201,208}
 - (b) Dissection and impairment of blood flow.
 - i. *Less common.*
 5. Clinical features:
 - (a) Sudden onset of unilateral neck pain (in 82% of patients²⁰⁶), facial pain, and headache.
 - (b) Most common physical finding: Horner's syndrome.
 - i. Constricted pupil
 - ii. Ptosis
 - iii. Unilateral anhidrosis
 - (c) Ischemic symptoms may follow pain symptoms by hours or days.
 - i. Range: a few minutes to 31 days.²⁰⁹
 - ii. May include retinal ischemic symptoms, hemispheric TIA, or completed stroke.
 6. Radiographic evaluation:
 - (a) MRI/MRA accompanied by T1-weighted images with fat saturation is the imaging method of choice.²¹⁰
 - i. Fat-suppressed T1W images improve detection of the mural hematoma – the so-called *crescent sign*.
 - (b) CTA is also a valid option.^{211,212}
 - (c) Catheter angiography – still the "gold standard."
 - i. Can complement MRI by identifying a false lumen, hemodynamic effects, and collateral circulation.
 - ii. Noninvasive imaging is usually adequate.
 7. Management:
 - (a) *Controversial.*
 - i. No randomized trials comparing either anticoagulants or antiplatelet drugs with control have been published.²¹³
 - (b) Antithrombotic therapy with either antiplatelet agents or anticoagulation is generally accepted.
 - (c) The authors' protocol:
 - i. Screening is done for patients with evidence of dissection (MRA or CTA). A catheter angiogram is done only if needed to confirm the diagnosis.
 - ii. Antiplatelet therapy:
 - Aspirin 325 mg daily
 - iii. *If there is evidence of a false lumen or pseudoaneurysm containing thrombus:*
 - Anticoagulation is used instead of antiplatelet agents.
 - IV heparin administration to maintain the partial thromboplastin time 50–70 seconds.

- Warfarin is begun; heparin is discontinued when the INR is 2.0–3.0.
- iv. The patient is followed with MRA or CTA at 3 months and 6 months.
 - Once the lesion has recanalized or stabilized:
 - Anticoagulation (if it is being used) and/or clopidogrel is discontinued.
 - Aspirin is continued indefinitely.
- (d) Stenting is an option for patients who remain symptomatic despite anti-thrombotic therapy.²¹⁴
- 8. Prognosis – *favorable*.
 - (a) Recanalization is common.
 - i. Occurs in 68–100% of stenotic lesions and 25–43% of occlusions.²¹⁵
 - Resolution of angiographic changes occurs by 3 months in 65% of cases.²¹⁶
 - ii. Usually occurs in the first two months after the injury but can take up to 6–12 months.²¹⁷
 - (b) Recurrence is uncommon.
 - i. 4% recurrence rate (mean follow-up 34 months) in one prospective study of spontaneous carotid artery dissections.²¹⁸

18.2.1.2. Blunt trauma to the carotid artery

1. Uncommon. Incidence among patients with head and neck trauma ranges from 0.67%²¹⁹ to 1.03%.²²⁰
2. Cerebral ischemia can result from:
 - (a) Thromboembolism (see above).
 - i. *Most common mechanism of stroke following traumatic carotid dissection.*^{221,222}
 - (b) Dissection and impairment of blood flow.
 - i. *Rare.*
3. Clinical features
 - (a) Symptoms may develop hours or weeks after the injury.²²³
 - (b) Head and/or neck pain is the most common symptom...
 - i. Followed by cerebral or retinal ischemia.
4. Compared to penetrating injury, blunt carotid injury carries a lower mortality rate but higher stroke rate.²²⁴
 - (a) Mortality: 7%
 - (b) Stroke rate: 56%
5. Radiographic evaluation:
 - (a) Suggested triggers for evaluation for traumatic carotid dissection:²²⁰
 - i. Cervical spine fracture
 - ii. Horner's syndrome
 - iii. Le Fort II or III facial fracture
 - iv. Skull base fracture involving the carotid canal
 - v. Penetrating neck injuries
 - vi. Focal neurological deficit not explainable by other causes
 - (b) CTA in the evaluation of blunt trauma to the carotid artery.
 - i. Can demonstrate other soft tissue and bony injuries.
 - ii. Permits examination of the vertebral arteries as well.
 - iii. Easy to do.
 - iv. However, sensitivity is limited.
 - Comparison of CTA to catheter angiography in patients with blunt carotid artery injury demonstrated a sensitivity of only 47%.²²⁰
 - v. MRI/MRA also has limited sensitivity (50%²²⁰) and is often problematic in the setting of trauma.
 - (c) Angiography is the “gold standard” for diagnosis of arterial injury.
 - i. Can also identify intraluminal thrombus, a false lumen, and assess collateral supply to the affected arterial territory.
 - (d) Authors' preference:
 - i. CTA is done as the initial imaging technique.
 - Proceed to catheter angiography if:
 - The CTA indicates a dissection.
 - If the CTA is *negative* and the index of suspicion for an arterial injury is *high* (e.g., there is evidence of neurologic injury attributable to an arterial injury or if there is additional evidence of an arterial injury not seen on CTA).

6. Management.
- (a) *Medical management – Controversial.*
- i. Most agree that some kind of antithrombotic therapy is necessary.
 - ii. Anticoagulation
 - Retrospective series have supported the use of systemic anticoagulation with heparin in blunt carotid injury.²²⁵
 - A logistic regression analysis found heparin therapy to be associated independently with survival ($p < 0.02$) and improvement in neurologic outcome ($p < 0.01$).²¹⁹
 - Biffi et al. recommendations for anticoagulation according to grade of injury (Table 18.7):²²⁶
 - Grade I – may heal without anticoagulation, consider antiplatelet agent.
 - Grade II, III, and IV should be treated with systemic anticoagulation.
 - iii. *However*
 - Hemorrhagic complication rates as high as 57% with heparin therapy have been reported.²²⁷
 - A significant percentage of trauma patients are unsuitable for anticoagulation because of bleeding from other sites.
 - iv. Antiplatelet therapy
 - Rationale: disruption of the intima leads to platelet activation and aggregation.
 - Bleeding complications were found to be significantly lower for patients treated with aspirin compared to systemic heparinization.²²⁷
 - v. The authors' preference in most cases is aspirin 325 mg daily (can be given via NG or as a suppository).
 - Systemic anticoagulation (i.e., IV heparin) is reserved for cases in which there is a significant false lumen with stasis and a tangible risk of thromboembolism.
- (b) Endovascular intervention
- i. Stenting has been advocated for the treatment of dissections and pseudoaneurysms that continue to enlarge or are symptomatic despite antithrombotic therapy.
 - Stent placement lead to resolution of 89% of pseudoaneurysms.²²⁶
 - Risk of thromboembolic complications from endovascular manipulation of an acutely injured vessel is believed to be high.
 - Some authors recommend waiting 7 days before stenting in blunt carotid injury.²²⁸
 - Requires a course of combination antiplatelet therapy
 - Combination antiplatelet therapy may complicate management of other traumatic injuries.

18.2.2. Vertebral dissection

18.2.2.1. Spontaneous vertebral artery dissection

1. 67% of cerebellar infarctions in young adults are attributable to vertebral artery dissection.²²⁹
2. Most patients are in their 30s or 40s.

Table 18.7 Blunt carotid artery injury scale²²⁶

Injury grade	Description
I	Luminal irregularity or dissection with <25% luminal narrowing
II	Dissection or intramural hematoma with ≥25% narrowing
III	Pseudoaneurysm
IV	Occlusion
V	Transection with free extravasation

- (a) 48% of patients have hypertension.²³⁰
- (b) Associated with FMD (see below), migraine, and oral contraceptives.²³¹
- (c) History of sustained hyperextension and rotation in some patients:
 - i. *Beauty Parlor Stroke Syndrome*.²³²
 - ii. *Bottoms Up Dissection*.²³³
- 3. The cardinal symptom in patients with vertebral artery dissection is pain, involving the neck, occiput, and shoulder.²³⁰
 - (a) Median interval between neck pain and onset of other symptoms is 2 weeks.²³⁴
 - (b) Frequency of VBI symptoms with vertebral artery dissection: 56%.²³⁵
- 4. Spontaneous vertebral artery dissections can occur anywhere along the course of the vessel.²³⁵
 - (a) Tend to occur in the dominant vertebral artery.
 - (b) 36% of patients have dissections at other sites.
 - (c) 21% have bilateral vertebral artery dissections.²³⁶
- 5. Radiographic evaluation
 - (a) Catheter angiography is the preferred imaging technique.
 - (b) MRI/MRA are not as sensitive for detecting vertebral dissections as for detecting carotid dissections.²³⁷
 - i. Low sensitivity is due to:²³⁸
 - Inherent asymmetry of the vertebral arteries.
 - Poor delineation of the intramural hematoma against the surrounding soft tissues, and slow flow proximal and distal to the dissection.
 - Enhancement in the vertebral veins may mimic a dissection.
 - ii. However, dynamic MRA (i.e., imaging of the vessels in neutral position, then with extension and rotation) can identify areas of impingement by the vertebral arteries by bony or ligamentous structures.²³²
 - (c) CTA also has limited sensitivity.
 - i. Vertebral artery size and position in the transverse foramina vary markedly in normal young subjects.²³⁹
 - This variation may make recognition of a dissection difficult.
- 6. Management
 - (a) Same as for spontaneous internal carotid artery dissections (see above).
- 7. Prognosis – *favorable*
 - (a) Angiographic abnormalities either subside or improve in 76%.²³⁰
 - (b) Recurrence rate is low.²¹⁸

18.2.2.2. Blunt trauma to the vertebral artery

- 1. In blunt trauma, vertebral artery injuries are more common than carotid injuries.
 - (a) Due to the proximity of the vessel to the bony and ligamentous structures of the spine.
- 2. Blunt vertebral artery injury incidence: 0.53% of all blunt trauma admissions.²⁴⁰
- 3. Vertebral artery injuries were found in 46% of patients with mid-cervical spine fracture or subluxation.²⁴¹
 - (a) Conversely, cervical spine injuries were present in 71% of patients with blunt vertebral artery injury.²⁴⁰
 - (b) Dissections tend to occur where the artery is adjacent to a bony prominence (e.g., C2-2 or at C6 where the vessel enters the foramen transversarium).
- 4. Incidence of posterior circulation stroke in blunt vertebral artery injury: 24%.²⁴⁰
 - (a) Symptoms can result from:
 - i. Thromboembolism
 - ii. Arterial stenosis
 - iii. Occlusion
 - iv. Aneurysm formation
- 5. Radiographic evaluation
 - (a) Most recommend catheter angiography if the index of suspicion for an arterial injury is high.
 - i. Noninvasive imaging accuracy is limited.
 - Comparison of CTA and MRA with cerebral angiography demonstrated sensitivities of 53% (CTA) and 47% (MRA) for vertebral artery injury.²²⁰
 - ii. CTA has limited sensitivity in the evaluation of blunt vertebral artery trauma.
 - iii. CTA may not be sensitive for detecting small intimal injuries.²⁴²

- iv. Vertebral artery size and position in the transverse foramina vary markedly in normal young subjects²³⁹
 - This variation may make recognition of a dissection difficult
 - (b) Authors' preference:
 - i. CTA is done as the initial imaging technique
 - Proceed to catheter angiography if
 - The CTA indicates a dissection
 - If the CTA is *negative* and the index of suspicion for an arterial injury is *high* (e.g., there is evidence of neurologic injury attributable to an arterial injury or if there is additional evidence of an arterial injury not seen on CTA)
6. Management
- (a) Similar to management of blunt carotid artery injury (see above)
 - i. Systemic anticoagulation has been advocated for blunt vertebral artery injury²⁴⁰
 - ii. The authors' preference:
 - Antiplatelet treatment (aspirin 325 mg daily).
 - iii. Endovascular intervention
 - Reserved for patients with active bleeding, symptomatic injuries despite antithrombotic therapy, or an arteriovenous fistula.
 - Usually consists of embolization and occlusion of the vessel²⁴³
 - Stenting with distal embolic protection has been reported.²⁴⁴
 - (b) Follow-up imaging is necessary because of the potential for aneurysm or arteriovenous fistula formation²⁴⁵
 - i. Authors' preference is to image the affected vessel noninvasively (e.g., CTA) 6 months after the injury.

18.2.2.3. Penetrating neck injury

- 1. Another kettle of fish.
 - (a) Some 36% of patients with penetrating neck injuries have a vascular injury.²⁴⁶
- 2. Mortality is higher but stroke rates are lower with penetrating neck injuries compared to blunt injury²²⁴
 - (a) Overall mortality with penetrating cervical vascular injury: 22%
 - (b) Overall stroke rate: 15%
 - i. Zone 1
 - Between cricoid cartilage and clavicles
 - 13% of penetrating neck injuries.²⁴⁷
 - ii. Zone 2
 - Cricoid cartilage to angle of mandible
 - 67% of injuries.
 - iii. Zone 3
 - Angle of mandible to skull base
 - 0% of injuries.
- 3. Radiographic evaluation
 - (a) CT/CTA is first-line.^{211,248}
 - i. Sensitivity of CTA in detecting arterial injury in this setting is high (90–100%).^{242,249,250}
 - ii. Metal and bone artifact can obscure identification of vascular injuries.
 - (b) Angiography
 - i. In cases where CTA interpretation is limited or a need for endovascular intervention is anticipated.
 - ii. Diagnostic yield is very limited in patients with Zone 2 injuries without physical findings or symptoms of vascular injury.
 - Positive finding in this setting is <1%.²⁵¹
 - iii. Some centers use selective angiography according to zone.
 - Zone 1 and Zone 3 injuries (symptomatic and asymptomatic) are evaluated with angiography.
 - These zones are difficult to assess clinically, and surgical access is difficult.
 - Zone 2 injuries are explored surgically if they are symptomatic.
- 4. Penetrating carotid artery injuries
 - (a) Carotid system is involved in 80% of cases.
 - (b) ICA occlusion occurs in 36% of cases.²⁵²
 - (c) ICA pseudoaneurysms are found in 33% of cases.²⁵²

5. Penetrating vertebral artery injuries
 - (a) Vertebral arteries are involved in 43% of cases.
 - (b) Only some 2.6% of patients have symptoms of transient VBI²⁴⁶
 6. Management
 - (a) Vascular management of penetrating neck injury is in evolution.
 - (b) Endovascular management is gaining favor over surgical exploration and repair.²⁵³
 - (c) A number of series have reported favorable results with endovascular management²⁵⁴⁻²⁵⁶ (Fig. 18.3).
1. Zone I. Clavicle to cricoid process.
 2. Zone II. Cricoid process to angle of mandible.
 3. Zone III. Angle of mandible to skull base.

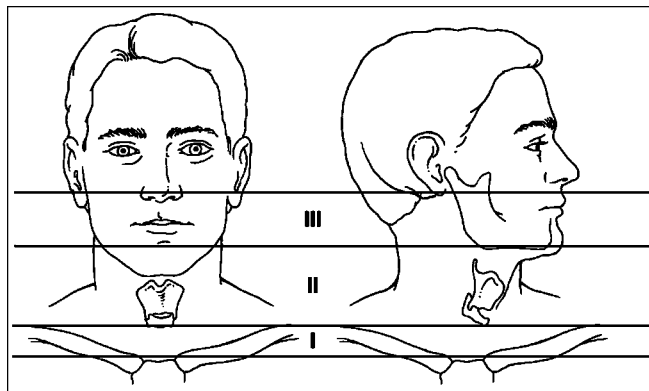


Fig. 18.3 Penetrating neck trauma. Zones of the neck.

18.3. Fibromuscular dysplasia

Fibromuscular dysplasia (FMD) is a nonatherosclerotic, noninflammatory condition that characteristically affects medium-sized arteries (e.g., the internal carotid, vertebral, coronary, and renal arteries). Classification is based on the arterial layer affected.

1. Media
 - (a) Medial *fibroplasia*. Most common form; ~65% of FMD cases.
 - i. Classic “stack of coins” appearance on angiography (Fig. 18.4).
 - ii. Histologically, the media is involved and the intima, internal elastic lamina, and adventitia are spared.
 - iii. Associated with Ehlers-Danlos syndrome (type IV).²⁵⁷
 - (b) Medial *hyperplasia*. ~10% of FMD cases.
 - i. Smooth tubular stenosis on angiography (Fig. 18.5).
 - ii. May be indistinguishable on angiography from intimal fibroplasia.²⁵⁸

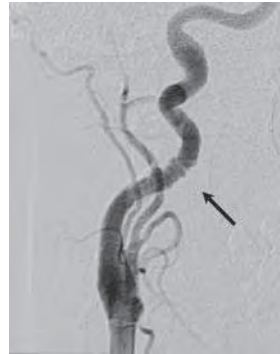

Fig. 18.4 Fibromuscular dysplasia: Medial fibroplasia variant. Carotid angiogram showing the classic “stack of coins” appearance of the affected part of the ICA (arrow).

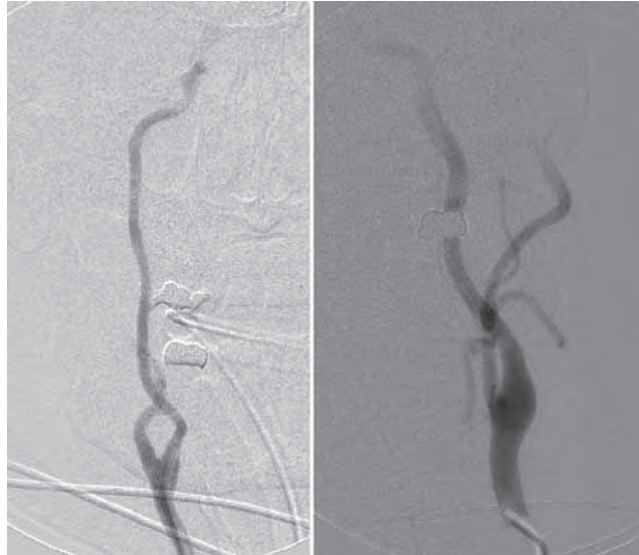


Fig. 18.5 Fibromuscular dysplasia: Medial hyperplasia variant. Carotid angiogram showing medial hyperplasia causing a long tubular stenosis of the ICA (*left*). The same patient's normal contralateral carotid is shown (*right*) for comparison.

- (c) Perimedial fibroplasia. ~20% of FMD cases.
 - i. Appears on angiography as a focal stenosis, or, occasionally, multiple stenoses.
 - ii. Characterized by a homogeneous collar of elastic tissue at the junction of the media and adventitia.²⁵⁹
- 2. Intima.
 - (a) Intimal fibroplasia. ~1% of FMD cases.
 - i. May appear on angiography as a focal concentric stenosis, or a long, smooth narrowing.
- 3. Adventitia
 - (a) Adventitial hyperplasia. <1% of rarest form of FMD.
 - i. Localized, tubular stenosis on angiography.²⁶⁰

18.3.1. Pathogenesis of FMD

1. Cause is not yet understood.
2. Risk factors²⁵⁹:
 - (a) Hypertension
 - (b) Cigarette smoking
3. Possible causes:
 - (a) Alteration of the vaso vasorum
 - (b) Repeated microtrauma
 - (c) Hormonal deficiency
 - (d) α -antitrypsin deficiency²⁶¹
 - (e) Genetic component²⁶²

18.3.2. Cerebrovascular FMD

1. The extracranial internal carotid and vertebral arteries are affected in 25–30% of cases, and there are associated intracranial aneurysms in 7–50% of cases.²⁵⁹

2. Usually discovered as an incidental finding during imaging.
3. Bilateral in 85% of cases.²⁶³
4. Female preponderance (85% of cases).²⁶³
5. Mean age approximately 50.²⁵⁹
6. Typically affects the middle and distal portions of the internal and vertebral arteries, at the level of C1 and C2.
7. Natural history is usually benign.²⁶⁴⁻²⁶⁶
8. Theoretical elevated risk of complications during neurointerventional procedures (e.g., dissection, perforation).
9. Cerebrovascular symptoms are uncommon. Symptoms can result from:
 - (a) Stenosis or occlusion of the vessel
 - (b) Spontaneous dissection
 - (c) Subarachnoid hemorrhage
 - (d) Spontaneous vertebro-vertebral arteriovenous fistula²⁶⁷
10. Treatment
 - (a) Antiplatelet therapy may reduce the risk of thromboembolic events.
 - (b) Endovascular treatment has emerged as the primary approach in patients with symptomatic cerebrovascular FMD.²⁵⁹
 - i. Angioplasty alone^{268,269}
 - ii. Angioplasty and stent placement²⁷⁰
 - iii. Endovascular treatment combined with surgery²⁷¹

18.4. References

1. Grau AJ, Weimar C, Bugge F, et al. Risk factors, outcome, and treatment in subtypes of ischemic stroke: the German Stroke Data Bank. *Stroke* 2001;32(11):2559-66.
2. Woo D, Gebel J, Miller R, et al. Incidence rates of first-ever ischemic stroke subtypes among blacks: a population-based study. *Stroke* 1999;30(12):2517-22.
3. Ross R. Atherosclerosis—an inflammatory disease. *N Engl J Med* 1999;340(2):115-26.
4. Schwartz CJ, Valente AJ, Sprague EA, Kelley JL, Nerem RM. The pathogenesis of atherosclerosis: an overview. *Clin Cardiol* 1991;14(2 Suppl 1):11-16.
5. Napoli C, D'Armiato FP, Mancini FP, et al. Fatty streak formation occurs in human fetal aortas and is greatly enhanced by maternal hypercholesterolemia. Intimal accumulation of low density lipoprotein and its oxidation precede monocyte recruitment into early atherosclerotic lesions. *J Clin Invest* 1997;100(11):2680-90.
6. Morel DW, Hessler JR, Chisolm GM. Low density lipoprotein cytotoxicity induced by free radical peroxidation of lipid. *J Lipid Res* 1983;24(8):1070-6.
7. Nehler MR, Taylor LM, Jr., Porter JM. Homocysteinemia as a risk factor for atherosclerosis: a review. *Cardiovasc Surg* 1997;5(6):559-67.
8. Espinola-Klein C, Rupprecht H-J, Blankenberg S, et al. Are morphological or functional changes in the carotid artery wall associated with chlamydia pneumoniae, helicobacter pylori, cytomegalovirus, or herpes simplex virus infection? *Stroke* 2000;31(9):2127-33.
9. Libby P, Egan D, Skarlatos S. Roles of infectious agents in atherosclerosis and restenosis: an assessment of the evidence and need for future research. *Circulation* 1997;96(11):4095-103.
10. Ross R, Glomset JA. Atherosclerosis and the arterial smooth muscle cell: proliferation of smooth muscle is a key event in the genesis of the lesions of atherosclerosis. *Science* 1973;180(93):1332-9.
11. Zarins CK, Giddens DP, Bharadvaj BK, Sottiurai VS, Mabon RF, Glagov S. Carotid bifurcation atherosclerosis. Quantitative correlation of plaque localization with flow velocity profiles and wall shear stress. *Circ Res* 1983;53(4):502-14.
12. Huo Y, Ley K. Adhesion molecules and atherogenesis. *Acta Physiol Scand* 2001;173(1):35-43.
13. Ku DN, Giddens DP, Zarins CK, Glagov S. Pulsatile flow and atherosclerosis in the human carotid bifurcation. Positive correlation between plaque location and low oscillating shear stress. *Arteriosclerosis* 1985;5(3):293-302.
14. Julian OC, Dye WS, Javid H, Hunter JA. Ulcerative lesions of the carotid artery bifurcation. *Arch Surg* 1963;86:803-9.
15. Moore WS, Malone JM. Effect of flow rate and vessel calibre on critical arterial stenosis. *J Surg Res* 1979;26(1):1-9.
16. Prati P, Vanuzzo D, Casaroli M, et al. Prevalence and determinants of carotid atherosclerosis in a general population. *Stroke* 1992;23(12):1705-11.
17. Colgan MP, Strode GR, Sommer JD, Gibbs JL, Sumner DS. Prevalence of asymptomatic carotid disease: results of duplex scanning in 348 unselected volunteers. *J Vasc Surg* 1988;8(6):674-8.
18. Fabris F, Zancocci M, Bo M, et al. Carotid plaque, aging, and risk factors. A study of 457 subjects. *Stroke* 1994;25(6):1133-40.
19. Fine-Edelstein JS, Wolf PA, O'Leary DH, et al. Precursors of extracranial carotid atherosclerosis in the Framingham Study. *Neurology* 1994;44(6):1046-50.
20. Pujia A, Rubba P, Spencer MP. Prevalence of extracranial carotid artery disease detectable by echo-Doppler in an elderly population. *Stroke* 1992;23(6):818-22.
21. Ramsey DE, Miles RD, Lambeth A, Sumner DS. Prevalence of extracranial carotid artery disease: a survey of an asymptomatic population with noninvasive techniques. *J Vasc Surg* 1987;5(4):584-8.
22. Fabris F, Zancocci M, Bo M, Fonte G, Fiandra U, Poli L. Risk factors for atherosclerosis and aging. *Int Angiol* 1994;13(1):52-8.
23. Mathiesen EB, Joakimsen O, Bonna KH. Prevalence of and risk factors associated with carotid artery stenosis: the Tromsø Study. *Cerebrovasc Dis* 2001;12(1):44-51.
24. Mast H, Thompson JLP, Lin IF, et al. Cigarette smoking as a determinant of high-grade carotid artery stenosis in hispanic, black, and white patients with stroke or transient ischemic attack. *Stroke* 1998;29(5):908-12.
25. Iemolo F, Martiniuk A, Steinman DA, Spence JD. Sex differences in carotid plaque and stenosis. *Stroke* 2004;35(2):477-81.
26. Su T-C, Jeng J-S, Chien K-L, Sung F-C, Hsu H-C, Lee Y-T. Hypertension status is the major determinant of carotid atherosclerosis: a community-based study in Taiwan. *Stroke* 2001;32(10):2265-71.
27. Wilson PWF, Hoeg JM, D'Agostino RB, et al. Cumulative effects of high cholesterol levels, high blood pressure, and cigarette smoking on carotid stenosis. *N Engl J Med* 1997;337(8):516-22.
28. Ishizaka N, Ishizaka Y, Toda E, Hashimoto H, Nagai R, Yamakado M. Hypertension is the most common compo-

- ment of metabolic syndrome and the greatest contributor to carotid arteriosclerosis in apparently healthy Japanese individuals. *Hypertens Res* 2005;28(1):27-34.
29. De Angelis M, Scrucca L, Leandri M, et al. Prevalence of carotid stenosis in type 2 diabetic patients asymptomatic for cerebrovascular disease. *Diabetes Nutr Metab* 2003;16(1):48-55.
 30. Kallikazaros IE, Tsioufis CP, Stefanadis CI, Pitsavos CE, Toutouzas PK. Closed relation between carotid and ascending aortic atherosclerosis in cardiac patients. *Circulation* 2000;102(9):263-8.
 31. Adler Y, Koren A, Fink N, et al. Association between mitral annulus calcification and carotid atherosclerotic disease. *Stroke* 1998;29(9):1833-7.
 32. Simons PC, Algra A, Eikelboom BC, Grobbee DE, van der Graaf Y. Carotid artery stenosis in patients with peripheral arterial disease: the SMART study. SMART study group. *J Vasc Surg* 1999;30(3):519-25.
 33. Oh J, Wunsch R, Turzer M, et al. Advanced coronary and carotid arteriopathy in young adults with childhood-onset chronic renal failure. *Circulation* 2002;106(1):100-5.
 34. Blackburn R, Giral P, Bruckert E, et al. Elevated C-reactive protein constitutes an independent predictor of advanced carotid plaques in dyslipidemic subjects. *Arterioscler Thromb Vasc Biol* 2001;21(12):1962-8.
 35. Wolff B, Grabe HJ, Volzke H, et al. Relation between psychological strain and carotid atherosclerosis in a general population. *Heart* 2005;91(4):460-4.
 36. Association AH. Heart and Stroke Statistical Update - 2005 Update. Dallas, TX: 2005.
 37. Anonymous. Beneficial effect of carotid endarterectomy in symptomatic patients with high-grade carotid stenosis. North American Symptomatic Carotid Endarterectomy Trial Collaborators. *N Engl J Med* 1991;325(7):445-53.
 38. Beneficial effect of carotid endarterectomy in symptomatic patients with high-grade carotid stenosis. North American Symptomatic Carotid Endarterectomy Trial Collaborators. *N Engl J Med* 1991;325(7):445-53.
 39. Barnett HJ, Taylor DW, Eliasziw M, et al. Benefit of carotid endarterectomy in patients with symptomatic moderate or severe stenosis. North American Symptomatic Carotid Endarterectomy Trial Collaborators. *N Engl J Med* 1998;339(20):1415-25.
 40. Anonymous. MRC European Carotid Surgery Trial: interim results for symptomatic patients with severe (70-99%) or with mild (0-29%) carotid stenosis. European Carotid Surgery Trialists' Collaborative Group. *Lancet* 1991;337(8752):1235-43.
 41. Donnan GA, Davis SM, Chambers BR, Gates PC. Surgery for prevention of stroke. *Lancet* 1998;351(9113):1372-3.
 42. Anonymous. Randomised trial of endarterectomy for recently symptomatic carotid stenosis: final results of the MRC European Carotid Surgery Trial (ECST). *Lancet* 1998;351(9113):1379-87.
 43. Cunningham EJ, Bond R, Mehta Z, Mayberg MR, Warlow CP, Rothwell PM. Long-term durability of carotid endarterectomy for symptomatic stenosis and risk factors for late postoperative stroke. European Carotid Surgery Trialists' Collaborative Group. *Stroke* 2002;33(11):2658-63.
 44. Mayberg MR, Wilson SE, Yatsu F, et al. Carotid endarterectomy and prevention of cerebral ischemia in symptomatic carotid stenosis. Veterans Affairs Cooperative Studies Program 309 Trialist Group. *JAMA* 1991;266(23):3289-94.
 45. Rothwell PM, Eliasziw M, Gutnikov SA, et al. Analysis of pooled data from the randomised controlled trials of endarterectomy for symptomatic carotid stenosis. *Lancet* 2003;361(9352):107-16.
 46. Biller J, Feinberg WM, Castaldo JE, et al. Guidelines for carotid endarterectomy: a statement for healthcare professionals from a special writing group of the Stroke Council, American Heart Association. *Stroke* 1998;29(2):554-62.
 47. Barnett HJ, Gunton RW, Eliasziw M, et al. Causes and severity of ischemic stroke in patients with internal carotid artery stenosis. *JAMA* 2000;283(11):1429-36.
 48. Eliasziw M, Streifler JY, Fox AJ, Hachinski VC, Ferguson GG, Barnett HJ. Significance of plaque ulceration in symptomatic patients with high-grade carotid stenosis. North American Symptomatic Carotid Endarterectomy Trial. *Stroke* 1994;25(2):304-8.
 49. Ferguson GG, Eliasziw M, Barr HW, et al. The North American Symptomatic Carotid Endarterectomy Trial: surgical results in 1415 patients. *Stroke* 1999;30(9):1751-8.
 50. Streifler JY, Eliasziw M, Benavente OR, et al. The risk of stroke in patients with first-ever retinal vs hemispheric transient ischemic attacks and high-grade carotid stenosis. North American Symptomatic Carotid Endarterectomy Trial. *Arch Neurol* 1995;52(3):246-9.
 51. Lanzino G, Couture D, Andreoli A, Guterman LR, Hopkins LN. Carotid endarterectomy: can we select surgical candidates at high risk for stroke and low risk for perioperative complications? *Neurosurgery* 2001;49(4):913-23; discussion 23-4.
 52. Morgenstern LB, Fox AJ, Sharpe BL, Eliasziw M, Barnett HJ, Grotta JC. The risks and benefits of carotid endarterectomy in patients with near occlusion of the carotid artery. North American Symptomatic Carotid Endarterectomy Trial (NASCET) Group. *Neurology* 1997;48(4):911-15.
 53. Gassecki AP, Eliasziw M, Ferguson GG, Hachinski V, Barnett HJ. Long-term prognosis and effect of endarterectomy in patients with symptomatic severe carotid stenosis and contralateral carotid stenosis or occlusion: results from NASCET. North American Symptomatic Carotid Endarterectomy Trial (NASCET) Group. *J Neurosurg* 1995;83(5):778-82.
 54. Villarreal J, Silva J, Eliasziw M, et al. Prognosis of patients with intraluminal thrombus in the internal carotid artery (for the North American Symptomatic Carotid Endarterectomy Trial) (Abstract 18). *Stroke* 1998;29(1):276.
 55. Ferguson GG, Eliasziw M, Barr HW, et al. The North American Symptomatic Carotid Endarterectomy Trial: surgical results in 1415 patients. *Stroke* 1999;30(9):1751-8.
 56. Atamowitch S, Eliasziw M, Algra A, Meldrum H, Barnett HJ. Risk, causes, and prevention of ischaemic stroke in elderly patients with symptomatic internal-carotid-artery stenosis. North American Symptomatic Carotid Endarterectomy Trial Group. *Lancet* 2001;357(9263):1154-60.
 57. Rothwell PM, Slattery J, Warlow CP. Clinical and angiographic predictors of stroke and death from carotid endarterectomy: systematic review. *BMJ* 1997;315(7122):1571-7.
 58. Kappelle LJ, Eliasziw M, Fox AJ, Barnett HJ. Small, unruptured intracranial aneurysms and management of symptomatic carotid artery stenosis. North American Symptomatic Carotid Endarterectomy Trial Group. *Neurology* 2000;55(2):307-9.
 59. Moore WS, Barnett HJ, Beebe HG, et al. Guidelines for carotid endarterectomy. A multidisciplinary consensus statement from the ad hoc committee, American Heart Association. *Stroke* 1995;26(1):188-201.
 60. Anonymous. Endarterectomy for asymptomatic carotid artery stenosis. Executive Committee for the Asymptomatic Carotid Atherosclerosis Study. *JAMA* 1995;273(18):1421-8.
 61. Baker WH, Howard VJ, Howard G, Toole JF. Effect of contralateral occlusion on long-term efficacy of endarterectomy in the asymptomatic carotid atherosclerosis study (ACAS). ACAS Investigators. *Stroke* 2000;31(10):2330-4.
 62. Hobson RW, II, Weiss DG, Fields WS, et al. Efficacy of carotid endarterectomy for asymptomatic carotid stenosis. The Veterans Affairs Cooperative Study Group. *N Engl J Med* 1993;328(4):221-7.
 63. Tuhim S, Bederson JB. Patient selection for carotid endarterectomy. In: Tuhim S, Bederson J, eds. *Treatment of Carotid Disease: A Practitioner's Manual*. Park Ridge: The American Association of Neurological Surgeons; 1998:129-42.
 64. Anonymous. Carotid surgery versus medical therapy in asymptomatic carotid stenosis. The CASANOVA Study Group. *Stroke* 1991;22(10):1229-35.
 65. Anonymous. Mayo Asymptomatic Carotid Endarterectomy Study Group: results of a randomized controlled trial of carotid endarterectomy for asymptomatic carotid stenosis. *Mayo Clin Proc* 1992;67:513-18.
 66. Halliday A, Mansfield A, Marro J, et al. Prevention of disabling and fatal strokes by successful carotid endarterectomy in patients without recent neurological symptoms: randomised controlled trial. *Lancet* 2004;363(9420):1491-502.
 67. Turnipseed WD, Kennell TW, Turski PA, Acher CW, Hoch JR. Combined use of duplex imaging and magnetic

- resonance angiography for evaluation of patients with symptomatic ipsilateral high-grade carotid stenosis. *J Vasc Surg* 1993;17(5):832-40.
68. Goldstein LB, Bonito AJ, Matchar DB, et al. US national survey of physician practices for the secondary and tertiary prevention of ischemic stroke. Design, service availability, and common practices. *Stroke* 1995;26(9):1607-15.
 69. Chassin MR, Brook RH, Park RE, et al. Variations in the use of medical and surgical services by the Medicare population. *N Engl J Med* 1986;314(5):285-90.
 70. Qureshi AI, Suri MF, Ali Z, et al. Role of conventional angiography in evaluation of patients with carotid artery stenosis demonstrated by Doppler ultrasound in general practice. *Stroke* 2001;32(10):2287-91.
 71. Polak JF, Kalina P, Donaldson MC, O'Leary DH, Whittemore AD, Mannick JA. Carotid endarterectomy: preoperative evaluation of candidates with combined Doppler sonography and MR angiography. Work in progress. *Radiology* 1993;186(2):333-8.
 72. Dawson DL, Zierler RE, Strandness DE, Jr., Clowes AW, Kohler TR. The role of duplex scanning and arteriography before carotid endarterectomy: a prospective study. *J Vasc Surg* 1993;18(4):673-83.
 73. Dillon EH, van Leeuwen MS, Fernandez MA, Eikelboom BC, Mali WP. CT angiography: application to the evaluation of carotid artery stenosis. *Radiology* 1993;189(1):211-19.
 74. Lustgarten JH, Solomon RA, Quest DO, Khanji AG, Mohr JP. Carotid endarterectomy after noninvasive evaluation by duplex ultrasonography and magnetic resonance angiography. *Neurosurgery* 1994;34(4):612-19.
 75. Back MR, Wilson JS, Rushing G, et al. Magnetic resonance angiography is an accurate imaging adjunct to duplex ultrasound scan in patient selection for carotid endarterectomy. *J Vasc Surg* 2000;32(3):429-40.
 76. deBray J, Glatt B. Quantitation of atheromatous stenosis in the extracranial internal carotid artery. *Cerebrovasc Dis* 1995;5:414-26.
 77. Grant EG, Benson CB, Moneta GL, et al. Carotid artery stenosis: Gray-scale and Doppler US diagnosis—Society of Radiologists in Ultrasound Consensus Conference. *Radiology* 2003;229(2):340-6.
 78. Grant EG, Duerinckx AJ, El Saden SM, et al. Ability to use duplex US to quantify internal carotid arterial stenoses: Fact or Fiction? *Radiology* 2000;214(1):247-52.
 79. Frericks H, Kievit J, van Baalen JM, van Bockel JH. Carotid recurrent stenosis and risk of ipsilateral stroke: a systematic review of the literature. *Stroke* 1998;29(1):244-50.
 80. Reina-Gutierrez T, Serrano-Hernando FI, Sanchez-Hervas L, Ponce A, Vega de Ceniga M, Martin A. Recurrent carotid artery stenosis following endarterectomy: natural history and risk factors. *Eur J Vasc Endovasc Surg* 2005;29(4):334-41.
 81. AbuRahma AF, Jennings TG, Wulu JT, Tarakji L, Robinson PA. Redo carotid endarterectomy versus primary carotid endarterectomy. *Stroke* 2001;32(12):2787-92.
 82. MacMahon S, Sharpe N, Gamble G, et al. Effects of lowering average of below-average cholesterol levels on the progression of carotid atherosclerosis: results of the LIPID Atherosclerosis Substudy. LIPID Trial Research Group. *Circulation* 1998;97(18):1784-90.
 83. Baldassarre D, Veglia F, Gobbi C, et al. Intima-media thickness after pravastatin stabilizes also in patients with moderate to no reduction in LDL-cholesterol levels: the carotid atherosclerosis Italian ultrasound study. *Atherosclerosis* 2000;151(2):575-83.
 84. Blauw GJ, Lagaay AM, Smelt AH, Westendorp RG. Stroke, statins, and cholesterol. A meta-analysis of randomized, placebo-controlled, double-blind trials with HMG-CoA reductase inhibitors. *Stroke* 1997;28(5):946-50.
 85. Panel NCEPE. Detection, evaluation, and treatment of high blood cholesterol in adults (Adult Treatment Panel III). In: *Health NIO*, ed.; 2001.
 86. Pasternak RC, Smith SC, Jr., Bairey-Merz CN, et al. ACC/AHA/NHLBI Clinical Advisory on the Use and Safety of Statins. *Stroke* 2002;33(9):2337-41.
 87. Merck & Co. I. Package insert: Mevacor® (Lovastatin). In: Whitehouse Station, NJ; 2002.
 88. Sacco RL, Wolf PA, Gorelick PB. Risk factors and their management for stroke prevention: outlook for 1999 and beyond. *Neurology* 1999;53(7 Suppl 4):S15-24.
 89. Collins R, Peto R, MacMahon S, et al. Blood pressure, stroke, and coronary heart disease. Part 2. Short-term reductions in blood pressure: overview of randomised drug trials in their epidemiological context. *Lancet* 1990;335(8693):827-38.
 90. Shinton R, Beevers G. Meta-analysis of relation between cigarette smoking and stroke. *BMJ* 1989;298(6676):789-94.
 91. Dale LC, Hurt RD, Hays JT. Drug therapy to aid in smoking cessation. Tips on maximizing patients' chances for success. *Postgrad Med* 1998;104(6):75-8, 83-4.
 92. Anczak JD, Nogler RA, II. Tobacco cessation in primary care: maximizing intervention strategies. *Clin Med Res* 2003;1(3):201-16.
 93. Steffen CM, Gray-Weale AC, Byrne KE, Lusby RJ. Carotid artery atheroma: ultrasound appearance in symptomatic and asymptomatic vessels. *Aust N Z J Surg* 1989;59(7):529-34.
 94. Ruggeri ZM. Mechanisms of shear-induced platelet adhesion and aggregation. *Thromb Haemost* 1993;70(1):119-23.
 95. Siess W, Zangl KJ, Essler M, et al. Lysophosphatidic acid mediates the rapid activation of platelets and endothelial cells by mildly oxidized low density lipoprotein and accumulates in human atherosclerotic lesions. *Proc Natl Acad Sci USA* 1999;96(12):6931-6.
 96. Anonymous. Randomised trial of intravenous streptokinase, oral aspirin, both, or neither among 17,187 cases of suspected acute myocardial infarction: ISIS-2. ISIS-2 (Second International Study of Infarct Survival) Collaborative Group. *Lancet* 1988;2(8607):349-60.
 97. Anonymous. A comparison of two doses of aspirin (30mg vs. 283 mg a day) in patients after a transient ischemic attack or minor ischemic stroke. The Dutch TIA Trial Study Group. *N Engl J Med* 1991;325(18):1261-6.
 98. Anonymous. Swedish Aspirin Low-Dose Trial (SALT) of 75mg aspirin as secondary prophylaxis after cerebrovascular ischaemic events. The SALT Collaborative Group. *Lancet* 1991;338(8779):1345-9.
 99. Taylor DW, Barnett HJ, Haynes RB, et al. Low-dose and high-dose acetylsalicylic acid for patients undergoing carotid endarterectomy: a randomised controlled trial. ASA and Carotid Endarterectomy (ACE) Trial Collaborators. *Lancet* 1999;353(9171):2179-84.
 100. Dyken ML, Barnett HJ, Easton JD, et al. Low-dose aspirin and stroke. "It ain't necessarily so." *Stroke* 1992;23(10):1395-9.
 101. A randomised, blinded, trial of clopidogrel versus aspirin in patients at risk of ischaemic events (CAPRIE). CAPRIE Steering Committee. *Lancet* 1996;348(9038):1329-39.
 102. Diener HC, Bogousslavsky J, Brass LM, et al. Aspirin and clopidogrel compared with clopidogrel alone after recent ischaemic stroke or transient ischaemic attack in high-risk patients (MATCH): randomised, double-blind, placebo-controlled trial. *Lancet* 2004;364(9431):331-7.
 103. Diener HC, Cunha L, Forbes C, Sivenius J, Smets P, Lowenthal A. European Stroke Prevention Study. 2. Dipyridamole and acetylsalicylic acid in the secondary prevention of stroke. *J Neurol Sci* 1996;143(1-2):1-13.
 104. Sacco RL, Sivenius J, Diener HC. Efficacy of aspirin plus extended-release dipyridamole in preventing recurrent stroke in high-risk populations. *Arch Neurol* 2005;62(3):403-8.
 105. Lipton RB, Bigal ME, Kolodner KB, et al. Acetaminophen in the treatment of headaches associated with dipyridamole-aspirin combination. *Neurology* 2004;63(6):1099-101.
 106. Hass WK, Easton JD, Adams HP, Jr., et al. A randomized trial comparing ticlopidine hydrochloride with aspirin for the prevention of stroke in high-risk patients. Ticlopidine Aspirin Stroke Study Group. *N Engl J Med* 1989;321(8):501-7.
 107. Bennett CL, Weinberg PD, Rozenberg-Ben-Dror K, Yarnold PR, Kwaan HC, Green D. Thrombotic thrombocytopenic purpura associated with ticlopidine. A review of 60 cases. *Ann Intern Med* 1998;128(7):541-4.

108. Albers GW, Amarencu P, Easton JD, Sacco RL, Teal P. Antithrombotic and thrombolytic therapy for ischemic stroke: the Seventh ACCP Conference on Antithrombotic and Thrombolytic Therapy. *Chest* 2004;126(3 Suppl):483S-512S.
109. Kerber CW, Cromwell LD, Loehden OL. Catheter dilatation of proximal carotid stenosis during distal bifurcation endarterectomy. *AJNR Am J Neuroradiol* 1980;1(4):348-9.
110. Bockenheimer SA, Mathias K. Percutaneous transluminal angioplasty in arteriosclerotic internal carotid artery stenosis. *AJNR Am J Neuroradiol* 1983;4(3):791-2.
111. Castaneda-Zuniga WR, Formanek A, Tadavarthy M, et al. The mechanism of balloon angioplasty. *Radiology* 1980;135(3):565-71.
112. Block PC, Fallon JT, Elmer D. Experimental angioplasty: lessons from the laboratory. *AJR Am J Roentgenol* 1980;135(5):907-12.
113. Zollikofer CL, Salomonowitz E, Sibley R, et al. Transluminal angioplasty evaluated by electron microscopy. *Radiology* 1984;153(2):369-74.
114. Bergeron P, Chambran P, Hartung O, Bianca S. Cervical carotid artery stenosis: which technique, balloon angioplasty or surgery? *J Cardiovasc Surg (Torino)* 1996;37(3 Suppl 1):73-5.
115. Bergeron P, Chambran P, Benichou H, Alessandri C. Recurrent carotid disease: will stents be an alternative to surgery? *J Endovasc Surg* 1996;3(1):76-9.
116. Shawl FA. Emergency percutaneous carotid stenting during stroke. *Lancet* 1995;346(8984):1223.
117. Yadav JS, Roubin GS, Iyer S, et al. Elective stenting of the extracranial carotid arteries. *Circulation* 1997;95(2):376-81.
118. Naylor AR, Bolia A, Abbott RJ, et al. Randomized study of carotid angioplasty and stenting versus carotid endarterectomy: a stopped trial. *J Vasc Surg* 1998;28(2):326-34.
119. Theron J, Courtheoux P, Alachkar F, Bouvard G, Maiza D. New triple coaxial catheter system for carotid angioplasty with cerebral protection. *AJNR Am J Neuroradiol* 1990;11(5):869-77.
120. Tong FC, Cloft HJ, Joseph GJ, Samuels OB, Dion JE. Abciximab rescue in acute carotid stent thrombosis. *AJNR Am J Neuroradiol* 2000;21(9):1750-2.
121. Yadav JS. Management practices in carotid stenting. *Cerebrovasc Dis* 2001;11(Suppl 2):18-22.
122. Wholey MH, Wholey M, Mathias K, et al. Global experience in cervical carotid artery stent placement. *Catheter Cardiovasc Interv* 2000;50(2):160-7.
123. Wholey MH, Al-Mubarek N, Wholey MH. Updated review of the global carotid artery stent registry. *Catheter Cardiovasc Interv* 2003;60(2):259-66.
124. Bettmann MA, Katzen BT, Whinsant J, et al. Carotid stenting and angioplasty: a statement for healthcare professionals from the Councils on Cardiovascular Radiology, Stroke, Cardio-Thoracic and Vascular Surgery, Epidemiology and Prevention, and Clinical Cardiology, American Heart Association. *Stroke* 1998;29(1):336-8.
125. Goldberg MPe. ARCHeR. In: *Internet Stroke Center*; 2005.
126. White CJ. BEACH 1-year trial results. In: *14th Annual Peripheral Angioplasty and All That Jazz Meeting* New Orleans; 2005.
127. Hopkins LN. First presentation of CABERNET 30-day trial results with a new carotid specific stent. In: *Veith Symposium*. New York City; 2004.
128. Carotid revascularization using endarterectomy or stenting systems (CaRESS) phase I clinical trial: 1-year results. *J Vasc Surg* 2005;42(2):213-19.
129. Reimers B, Sievert H, Schuler GC, et al. Proximal endovascular flow blockage for cerebral protection during carotid artery stenting: results from a prospective multicenter registry. *J Endovasc Ther* 2005;12(2):156-65.
130. Yadav JS, Wholey MH, Kuntz RE, et al. Protected carotid-artery stenting versus endarterectomy in high-risk patients. *N Engl J Med* 2004;351(15):1493-501.
131. Whitlow PL. SECURITY: multicenter evaluation of carotid stenting with a distal protection filter. In: *Transcatheter Cardiovascular Therapeutics, 15th Annual Symposium*. Washington, D.C.; 2003.
132. Ringleb PA, Allenberg J, Bruckmann H, et al. 30-day results from the SPACE trial of stent-protected angioplasty versus carotid endarterectomy in symptomatic patients: a randomised non-inferiority trial. *Lancet* 2006;368(9543):1239-47.
133. Mas J-L, Chatellier G, Beysens B, et al. Endarterectomy versus stenting in patients with symptomatic severe carotid stenosis. *N Engl J Med* 2006;355(16):1660-71.
134. Wennberg DE, Lucas FL, Birkmeyer JD, Bredenberg CE, Fisher ES. Variation in carotid endarterectomy mortality in the Medicare population: trial hospitals, volume, and patient characteristics. *JAMA* 1998;279(16):1278-81.
135. Paciaroni M, Eliasziw M, Kappelle LJ, Finan JW, Ferguson GG, Barnett HJ. Medical complications associated with carotid endarterectomy. North American Symptomatic Carotid Endarterectomy Trial (NASCET). *Stroke* 1999;30(9):1759-63.
136. Wong JH, Findlay JM, Suarez-Almazor ME. Regional performance of carotid endarterectomy. Appropriateness, outcomes, and risk factors for complications. *Stroke* 1997;28(5):891-8.
137. McCrory DC, Goldstein LB, Samsa GP, et al. Predicting complications of carotid endarterectomy. *Stroke* 1993;24(9):1285-91.
138. Goldstein LB, Samsa GP, Matchar DB, Oddone EZ. Multicenter review of preoperative risk factors for endarterectomy for asymptomatic carotid artery stenosis. *Stroke* 1998;29(4):750-3.
139. Kappelle LJ, Eliasziw M, Fox AJ, Sharpe BL, Barnett HJ. Importance of intracranial atherosclerotic disease in patients with symptomatic stenosis of the internal carotid artery. The North American Symptomatic Carotid Endarterectomy Trial. *Stroke* 1999;30(2):282-6.
140. Goldstein LB, McCrory DC, Landsman PB, et al. Multicenter review of preoperative risk factors for carotid endarterectomy in patients with ipsilateral symptoms. *Stroke* 1994;25(6):1116-21.
141. Rockman CB, Su W, Lamparello PJ, et al. A reassessment of carotid endarterectomy in the face of contralateral carotid occlusion: surgical results in symptomatic and asymptomatic patients. *J Vasc Surg* 2002;36(4):668-73.
142. Loftus CM, Biller J, Hart MN, Cornell SH, Hiratzka LF. Management of radiation-induced accelerated carotid atherosclerosis. *Arch Neurol* 1987;44(7):711-14.
143. Mellièrè D, Bequemin JP, Berrahal D, Desgranges P, Cavillon A. Management of radiation-induced occlusive arterial disease: a reassessment. *J Cardiovasc Surg* 1997;38(3):261-9.
144. Kashyap VS, Moore WS, Quinones-Baldrich WJ. Carotid artery repair for radiation-associated atherosclerosis is a safe and durable procedure. *J Vasc Surg* 1999;29(1):90-9.
145. Meyer FB, Piegras DG, Fode NC. Surgical treatment of recurrent carotid artery stenosis. *J Neurosurg* 1994;80(5):781-7.
146. Hertzler NR, O'Hara PJ, Mascha EJ, Krajewski LP, Sullivan TM, Beven EG. Early outcome assessment for 2228 consecutive carotid endarterectomy procedures: the Cleveland Clinic experience from 1989 to 1995. *J Vasc Surg* 1997;26(1):1-10.
147. Featherstone RL, Brown MM, Coward LJ. International carotid stenting study: protocol for a randomised clinical trial comparing carotid stenting with endarterectomy in symptomatic carotid artery stenosis. *Cerebrovasc Dis* 2004;18(1):69-74.
148. Ringleb PA, Kunze A, Allenberg JR, et al. The Stent-Supported Percutaneous Angioplasty of the Carotid Artery vs. Endarterectomy Trial. *Cerebrovasc Dis* 2004;18(1):66-8.
149. Shrivastava V, Sookhoo S, Macdonald S, Dunning J. Is carotid artery stenting equivalent or superior to carotid endarterectomy for treatment of carotid artery stenosis? *Interact Cardiovasc Thorac Surg* 2005;4:550-4.
150. Endovascular versus surgical treatment in patients with carotid stenosis in the Carotid and Vertebral Artery Transluminal Angioplasty Study (CAVATAS): a randomised trial. *Lancet* 2001;357(9270):1729-37.
151. McCabe DJH, Pereira AC, Clifton A, Bland JM, Brown MM, on behalf of the CI. Restenosis after carotid angi-

- oplasty, stenting, or endarterectomy in the Carotid and Vertebral Artery Transluminal Angioplasty Study (CAVATAS). *Stroke* 2005;36(2):281-6.
152. Hobson RW, II, Howard VI, Roubin GS, et al. Carotid artery stenting is associated with increased complications in octogenarians: 30-day stroke and death rates in the CREST lead-in phase. *J Vasc Surg* 2004;40(6):1106-11.
 153. Theiss W, Langhoff R, Schulte KL. SPACE and EVA-3S: two failed studies? *VASA* 2007;36(2):77-9.
 154. Naylor AR. SPACE: not the final frontier. *Lancet* 2006;368(9543):1215-16.
 155. Willfort-Ehringer A, Ahmadi R, Gschwandtner ME, Haumer M, Lang W, Minar E. Single-center experience with carotid stent restenosis. *J Endovasc Ther* 2002;9(3):299-307.
 156. dLevy EI, Hanel RA, Lau T, et al. Frequency and management of recurrent stenosis after carotid artery stent implantation. *J Neurosurg* 2005;102(1):29-37.
 157. Bossiers M, Peeters P, Deloose K, et al. Does carotid artery stenting work on the long run: 5-year results in high-volume centers (ELOCAS Registry). *J Cardiovasc Surg (Torino)* 2005;46(3):241-7.
 158. Jordan WD, Jr., Voellinger DC, Dohlar DD, Plyushcheva NP, Fisher WS, McDowell HA. Microemboli detected by transcranial Doppler monitoring in patients during carotid angioplasty versus carotid endarterectomy. *Cardiovasc Surg* 1999;7(1):33-8.
 159. van Heesewijk HPM, Vos JA, Louwerse ES, et al. New brain lesions at MR imaging after carotid angioplasty and stent placement. *Radiology* 2002;224(2):361-5.
 160. Kastrop A, Groschel K, Krapp H, Brehm BR, Dichgans J, Schulz JB. Early outcome of carotid angioplasty and stenting with and without cerebral protection devices: a systematic review of the literature. *Stroke* 2003;34(3):813-19.
 161. Carotid angioplasty and stenting with and without cerebral protection: clinical alert from the Endarterectomy Versus Angioplasty in Patients with Symptomatic Severe Carotid Stenosis (EVA-3S) Trial. *Stroke* 2004;35(1):18e-20.
 162. Sundt T. Occlusive cerebrovascular disease. In: Philadelphia: W.D. Saunders; 1987:226-30.
 163. Pierce GE, Keushkerian SM, Hermreck AS, Iliopoulos JI, Thomas JH. The risk of stroke with occlusion of the internal carotid artery. *J Vasc Surg* 1989;9(1):74-80.
 164. Vernieri F, Pasqualetti P, Passarelli F, Rossini PM, Silvestrini M. Outcome of carotid artery occlusion is predicted by cerebrovascular reactivity. *Stroke* 1999;30(3):593-8.
 165. Bornstein NM, Norris JW. Benign outcome of carotid occlusion. *Neurology* 1989;39(1):6-8.
 166. Powers WJ, Derdeyn CP, Fritsch SM, et al. Benign prognosis of never-symptomatic carotid occlusion. *Neurology* 2000;54(4):878-82.
 167. Flaherty ML, Flemming KD, McClelland R, Jorgensen NW, Brown RD, Jr. Population-based study of symptomatic internal carotid artery occlusion: incidence and long-term follow-up. *Stroke* 2004;35(8):e349-52.
 168. Klijn CJ, Kappelle LJ, Tulleken CA, van Gijn J. Symptomatic carotid artery occlusion. A reappraisal of hemodynamic factors. *Stroke* 1997;28(10):2084-93.
 169. Grubb RL, Jr., Derdeyn CP, Fritsch SM, et al. Importance of hemodynamic factors in the prognosis of symptomatic carotid occlusion. *JAMA* 1998;280(12):1055-60.
 170. Yonas H, Smith HA, Durham SR, Pentheny SL, Johnson DW. Increased stroke risk predicted by compromised cerebral blood flow reactivity. *J Neurosurg* 1993;79(4):483-9.
 171. Yasargil M. Anastomosis between the superficial temporal artery and a branch of the middle cerebral artery. In: Yasargil M, ed. *Microsurgery Applied to Neurosurgery*. Stuttgart: Georg Thieme; 1969:105-15.
 172. van der Zwan A, Tulleken CA, Hillen B. Flow quantification of the non-occlusive excimer laser-assisted EC-IC bypass. *Acta Neurochir (Wien)* 2001;143(7):647-54.
 173. Klijn CJM, Kappelle LJ, van der Zwan A, van Gijn J, Tulleken CAF. Excimer laser-assisted high-flow extracranial/intracranial bypass in patients with symptomatic carotid artery occlusion at high risk of recurrent cerebral ischemia: safety and long-term outcome. *Stroke* 2002;33(10):2451-8.
 174. Failure of extracranial-intracranial arterial bypass to reduce the risk of ischemic stroke. Results of an international randomized trial. The EC/IC Bypass Study Group. *N Engl J Med* 1985;313(19):1191-200.
 175. Ausman JI, Diaz FG. Critique of the extracranial-intracranial bypass study. *Surg Neurol* 1986;26(3):218-21.
 176. Awad IA, Spetzler RF. Extracranial-intracranial bypass surgery: a critical analysis in light of the International Cooperative Study. *Neurosurgery* 1986;19(4):655-64.
 177. Day AL, Rhoton AL, Jr., Little JR. The extracranial-intracranial bypass study. *Surg Neurol* 1986;26(3):222-6.
 178. Goldring S, Zervas N, Langfitt T. The extracranial-intracranial bypass study. A report of the committee appointed by the American Association of Neurological Surgeons to examine the study. *N Engl J Med* 1987;316(13):817-20.
 179. Furlan AJ, Little JR, Dohn DF. Arterial occlusion following anastomosis of the superficial temporal artery to middle cerebral artery. *Stroke* 1980;11(1):91-5.
 180. Gumerlock MK, Ono H, Neuwelt EA. Can a patent extracranial-intracranial bypass provoke the conversion of an intracranial arterial stenosis to a symptomatic occlusion? *Neurosurgery* 1983;12(4):391-400.
 181. Awad I, Furlan AJ, Little JR. Changes in intracranial stenotic lesions after extracranial-intracranial bypass surgery. *J Neurosurg* 1984;60(4):771-6.
 182. Caplan L. Posterior circulation ischemia: then, now, and tomorrow: the Thomas Willis Lecture-2000. *Stroke* 2000;31(8):2011-23.
 183. Hass WK, Fields WS, North RR, Kircheff II, Chase NE, Bauer RB. Joint study of extracranial arterial occlusion. II. Arteriography, techniques, sites, and complications. *JAMA* 1968;203(11):961-8.
 184. Cloud GC, Markus HS. Diagnosis and management of vertebral artery stenosis. *QJM* 2003;96(1):27-54.
 185. Caplan L. *Stroke: A Clinical Approach*. 3rd ed. Stoneham, MA: Butterworth-Heinemann; 2000.
 186. Caplan LR, Gorelick PB, Hier DB. Race, sex and occlusive cerebrovascular disease: a review. *Stroke* 1986;17(4):648-55.
 187. Wityk RJ, Chang HM, Rosengart A, et al. Proximal extracranial vertebral artery disease in the New England Medical Center Posterior Circulation Registry. *Arch Neurol* 1998;55(4):470-8.
 188. Charbel F, Pappy K, Carney A, Ausman J. Extracranial vertebral artery disease. In: Winn H, ed. *Youmans Neurological Surgery*. Fifth ed. Philadelphia, PA: Saunders; 2004:1691-714.
 189. Caplan LR, Wityk RJ, Glass TA, et al. New England Medical Center Posterior Circulation Registry. *Ann Neurol* 2004;56(3):389-98.
 190. Farres MT, Grabenwoger F, Magometschnig H, Trattng S, Heimberger K, Lammer J. Spiral CT angiography: study of stenoses and calcification at the origin of the vertebral artery. *Neuroradiology* 1996;38(8):738-43.
 191. Flossmann E, Rothwell PM. Prognosis of vertebral-basilar transient ischaemic attack and minor stroke. *Brain* 2003;126(9):1940-54.
 192. Sivenius I, Riekkinen PJ, Smets P, Laakso M, Lowenthal A. The European Stroke Prevention Study (ESPS): results by arterial distribution. *Ann Neurol* 1991;29(6):596-600.
 193. Grundy SM, Cleeman JI, Merz CN, et al. Implications of recent clinical trials for the National Cholesterol Education Program Adult Treatment Panel III Guidelines. *J Am Coll Cardiol* 2004;44(3):720-32.
 194. Berguer R, Flynn LM, Kline RA, Caplan L. Surgical reconstruction of the extracranial vertebral artery: management and outcome. *J Vasc Surg* 2000;31(1 Pt 1):9-18.
 195. Albuquerque FC, Fiorella D, Han P, Spetzler RF, McDougall CG. A reappraisal of angioplasty and stenting for the treatment of vertebral origin stenosis. *Neurosurgery* 2003;53(3):607-14; discussion 14-16.
 196. Ko YG, Park S, Kim JY, et al. Percutaneous interventional treatment of extracranial vertebral artery stenosis with coronary stents. *Yonsei Med J* 2004;45(4):629-34.
 197. Jenkins JS, White CJ, Ramee SR, et al. Vertebral artery stenting. *Catheter Cardiovasc Interv* 2001;54(1):1-5.
 198. Cloud GC, Crawley F, Clifton A, McCabe DJH, Brown MM, Markus HS. Vertebral artery origin angioplasty and primary stenting: safety and restenosis rates in a prospective series. *J Neurol Neurosurg Psychiatry* 2003;74(5):586-90.

199. The SSI. Stenting of symptomatic atherosclerotic lesions in the vertebral or intracranial arteries (SSYL VIA): study results. *Stroke* 2004;35(6):1388-92.
200. Bogousslavsky J, Regli F. Ischemic stroke in adults younger than 30 years of age. Cause and prognosis. *Arch Neurol* 1987;44(5):479-82.
201. Milhaud D, de Freitas GR, van Melle G, Bogousslavsky J. Occlusion due to carotid artery dissection: a more severe disease than previously suggested. *Arch Neurol* 2002;59(4):557-61.
202. Schievink WI, Mokri B, Whisnart JP. Internal carotid artery dissection in a community, Rochester, Minnesota, 1987-1992. *Stroke* 1993;24(11):1678-80.
203. Harbaugh RE. Carotid artery dissection, fibromuscular dysplasia, and other disorders of the carotid artery. In: Bederson J, Tuhim S, eds. *Treatment of Carotid Disease: A Practitioner's Manual*. Park Ridge, IL: The American Association of Neurological Surgeons; 1998:211-28.
204. Guillon B, Berthet K, Benslamia L, Bertrand M, Bousser M-G, Tzourio C. Infection and the risk of spontaneous cervical artery dissection: a case-control study. *Stroke* 2003;34(7):796-81.
205. Sturzenegger M. Spontaneous internal carotid artery dissection: early diagnosis and management in 44 patients. *J Neurol* 1995;242(4):231-8.
206. Norris JW, Beletsky V, Nadareishvili Z, Brandt T, Grond-Ginsbach C. "Spontaneous" cervical arterial dissection - response. *Stroke* 2002;33(8):1945-6.
207. Schievink WI. Spontaneous dissection of the carotid and vertebral arteries. *N Engl J Med* 2001;344(12):898-906.
208. Benninger DH, Georgiadis D, Kremer C, Studer A, Nedelchev K, Baumgartner RW. Mechanism of ischemic infarct in spontaneous carotid dissection. *Stroke* 2004;35(2):482-5.
209. Bioussé V, D'Anglejan-Chatillon J, Touboul PJ, Amarencu P, Bousser MG. Time course of symptoms in extracranial carotid artery dissections. A series of 80 patients. *Stroke* 1995;26(2):235-9.
210. Galal FM, Kitis O, Calli C, Yuntan N, Vidinli BD, Uygur M. Craniocervical artery dissection: diagnosis and follow-up with MR imaging and MR angiography. *Med Sci Monit* 2004;10(10):MT109-16.
211. Nunez DB, Jr., Torres-Leon M, Munera F. Vascular injuries of the neck and thoracic inlet: helical CT-angiographic correlation. *Radiographics* 2004;24(4):1087-98.
212. Stuhlfaut JW, Barest G, Sakai O, Lucey B, Soto JA. Impact of MDCT angiography on the use of catheter angiography for the assessment of cervical arterial injury after blunt or penetrating trauma. *Am J Roentgenol* 2005;185(4):1063-8.
213. Section E, Hankey GJ, Lyrrer P, Engelter S. Antithrombotic drugs for carotid artery dissection. *Stroke* 2004;35(2):613-14.
214. Cohen JE, Leker RR, Gotkine M, Gomori M, Ben-Hur T. Emergent stenting to treat patients with carotid artery dissection: clinically and radiologically directed therapeutic decision making. *Stroke* 2003;34(12):2546-7.
215. Zetterling M, Carlstrom C, Konrad P. Internal carotid artery dissection. *Acta Neurol Scand* 2000;101(1):1-7.
216. Ast G, Woimant F, Georges B, Laurian C, Haguenuau M. Spontaneous dissection of the internal carotid artery in 68 patients. *Eur J Med* 1993;2(8):466-72.
217. Steinke W, Rautenberg W, Schwartz A, Hennerici M. Noninvasive monitoring of internal carotid artery dissection. *Stroke* 1994;25(5):998-1005.
218. Bassetti C, Carruzzo A, Sturzenegger M, Tuncdogan E. Recurrence of cervical artery dissection: a prospective study of 81 patients. *Stroke* 1996;27(10):1804-7.
219. Fabian TC, Patton JH, Jr., Croce MA, Minard G, Kudsk KA, Pritchard FE. Blunt carotid injury. Importance of early diagnosis and anticoagulant therapy. *Ann Surg* 1996;223(5):513-22; discussion 22-5.
220. Miller PR, Fabian TC, Croce MA, et al. Prospective screening for blunt cerebrovascular injuries: analysis of diagnostic modalities and outcomes. *Ann Surg* 2002;236(3):386-93; discussion 93-5.
221. Mokri B, Piepgras DG, Houser OW. Traumatic dissections of the extracranial internal carotid artery. *J Neurosurg* 1988;68(2):189-97.
222. Lucas C, Moulin T, Deplanque D, Tatu L, Chavot D. Stroke patterns of internal carotid artery dissection in 40 patients. *Stroke* 1998;29(12):2646-8.
223. Li MS, Smith BM, Espinosa J, Brown RA, Richardson P, Ford R. Nonpenetrating trauma to the carotid artery: seven cases and a literature review. *J Trauma* 1994;36(2):265-72.
224. Ramadan F, Rutledge R, Oller D, Howell P, Baker C, Keagy B. Carotid artery trauma: a review of contemporary trauma center experiences. *J Vasc Surg* 1995;21(1):46-55; discussion 55-6.
225. Parikh AA, Luchette FA, Valente JF, et al. Blunt carotid artery injuries. *J Am Coll Surg* 1997;185(1):80-6.
226. Biffl WL, Moore EE, Offner PJ, Brega KE, Franciose RJ, Burch JM. Blunt carotid arterial injuries: implications of a new grading scale. *J Trauma* 1999;47(5):845-53.
227. Wahl WL, Brandt MM, Thompson BG, Taheri PA, Greenfield LJ. Antiplatelet therapy: an alternative to heparin for blunt carotid injury. *J Trauma* 2002;52(5):896-901.
228. Biffl WL, Moore EE, Ray C, Elliott JP. Emergent stenting of acute blunt carotid artery injuries: a cautionary note. *J Trauma* 2001;50(5):969-71.
229. Barinagarrementeria F, Amaya LE, Cantu C. Causes and mechanisms of cerebellar infarction in young patients. *Stroke* 1997;28(12):2400-4.
230. Mokri B, Houser OW, Sandok BA, Piepgras DG. Spontaneous dissections of the vertebral arteries. *Neurology* 1988;38(6):880-5.
231. Leys D, Lesoin F, Pruvo JP, Gozet G, Jomin M, Petit H. Bilateral spontaneous dissection of extracranial vertebral arteries. *J Neurol* 1987;234(4):237-40.
232. Weintraub MI. Beauty parlor stroke syndrome: report of five cases. *JAMA* 1993;269(16):2085-6.
233. Troesch RM, Hashani M, Brass LM. "Bottoms up" dissection. *N Engl J Med* 1989;320(23):1564-5.
234. Silbert PL, Mokri B, Schievink WI. Headache and neck pain in spontaneous internal carotid and vertebral artery dissections. *Neurology* 1995;45(8):1517-22.
235. Provenzale JM, Morgenlander JC, Gress D. Spontaneous vertebral dissection: clinical, conventional angiographic, CT, and MR findings. *J Comput Assist Tomogr* 1996;20(2):185-93.
236. Lalwani AK, Dowd CF, Halbach VV. Grading venous restrictive disease in patients with dural arteriovenous fistulas of the transverse/sigmoid sinus. *J Neurosurg* 1993;79(1):11-15.
237. Levy C, Laissy JP, Raveau V, et al. Carotid and vertebral artery dissections: three-dimensional time-of-flight MR angiography and MR imaging versus conventional angiography. *Radiology* 1994;190(1):97-103.
238. Mascalchi M, Bianchi MC, Mangiafico S, et al. MRI and MR angiography of vertebral artery dissection. *Neuroradiology* 1997;39(5):329-40.
239. Sanelli PC, Tong S, Gonzalez RG, Eskey CJ. Normal variation of vertebral artery on CT angiography and its implications for diagnosis of acquired pathology. *J Comput Assist Tomogr* 2002;26(3):462-70.
240. Biffl WL, Moore EE, Elliott JP, et al. The devastating potential of blunt vertebral arterial injuries. *Ann Surg* 2000;231(5):672-81.
241. Willis BK, Greiner F, Orrison WW, Benzel EC. The incidence of vertebral artery injury after midcervical spine fracture or subluxation. *Neurosurgery* 1994;34(3):435-41; discussion 41-2.
242. Hollingworth W, Nathens AB, Kanne JP, et al. The diagnostic accuracy of computed tomography angiography for traumatic or atherosclerotic lesions of the carotid and vertebral arteries: a systematic review. *Eur J Radiol* 2003;48(1):88-102.
243. Demetriades D, Theodorou D, Asensio J, et al. Management options in vertebral artery injuries. *Br J Surg* 1996;83(1):83-6.
244. Cohen JE, Gomori JM, Umansky F. Endovascular management of symptomatic vertebral artery dissection achieved using stent angioplasty and emboli protection device. *Neurol Res* 2003;25(4):418-22.
245. Nakagawa K, Touho H, Morisako T, et al. Long-term follow-up study of unruptured vertebral artery dissection: clinical outcomes and serial angiographic findings. *J Neurosurg* 2000;93(1):19-25.

246. LeBlang SD, Nunez DB, Jr. Noninvasive imaging of cervical vascular injuries. *AJR Am J Roentgenol* 2000;174(5):1269-78.
247. Biffl WL, Moore EE, Rehse DH, Offner PJ, Franciose RJ, Burch JM. Selective management of penetrating neck trauma based on cervical level of injury. *Am J Surg* 1997;174(6):678-82.
248. Munera F, Soto JA, Palacio DM, et al. Penetrating neck injuries: helical CT angiography for initial evaluation. *Radiology* 2002;224(2):366-72.
249. LeBlang S, Nunez D, Jr., Rivas L, Falcone S, Pogson S. Helical computed tomographic angiography in penetrating neck trauma. *Emerg Radiol* 1997;4:200-6.
250. Munera F, Soto JA, Palacio D, Velez SM, Medina E. Diagnosis of arterial injuries caused by penetrating trauma to the neck: comparison of helical CT angiography and conventional angiography. *Radiology* 2000;216(2):356-62.
251. Menawat SS, Dennis JW, Laneve LM, Frykberg ER. Are arteriograms necessary in penetrating zone II neck injuries? *J Vasc Surg* 1992;16(3):397-400; discussion 400-1.
252. Kuehne JP, Weaver FA, Papanicolaou G, Yellin AE. Penetrating trauma of the internal carotid artery. *Arch Surg* 1996;131(9):942-7.
253. Thompson EC, Porter JM, Fernandez LG. Penetrating neck trauma: an overview of management. *J Oral Maxillofac Surg* 2002;60(8):918-23.
254. Higashida RT, Halbach VV, Tsai FY, et al. Interventional neurovascular treatment of traumatic carotid and vertebral artery lesions: results in 234 cases. *AJR Am J Roentgenol* 1989;153(3):577-82.
255. Scifani AP, Scifani SJ. Angiography and transcatheter arterial embolization of vascular injuries of the face and neck. *Laryngoscope* 1996;106(2 Pt 1):168-73.
256. Albuquerque FC, Javedan SP, McDougall CG. Endovascular management of penetrating vertebral artery injuries. *J Trauma* 2002;53(3):574-80.
257. Schievink WI, Limburg M. Angiographic abnormalities mimicking fibromuscular dysplasia in a patient with Ehlers-Danlos syndrome, type IV. *Neurosurgery* 1989;25(3):482-3.
258. Kincaid OW, Davis GD, Hallermann FJ, Hunt JC. Fibromuscular dysplasia of the renal arteries. Arteriographic features, classification, and observations on natural history of the disease. *Am J Roentgenol Radium Ther Nucl Med* 1968;104(2):271-82.
259. Slovut DP, Olin JW. Fibromuscular dysplasia. *N Engl J Med* 2004;350(18):1862-71.
260. McCormack LJ, Poutasse EF, Meaney TF, Noto TJ, Jr., Dustan HP. A pathologic-arteriographic correlation of renal arterial disease. *Am Heart J* 1966;72(2):188-98.
261. Schievink WI, Meyer FB, Parisi JE, Wijdicks EF. Fibromuscular dysplasia of the internal carotid artery associated with alpha-1-antitrypsin deficiency. *Neurosurgery* 1998;43(2):229-33; discussion 33-4.
262. Pannier-Moreau I, Grimbret P, Fiquet-Kempf B, et al. Possible familial origin of multifocal renal artery fibromuscular dysplasia. *J Hypertens* 1997;15(12 Pt 2):1797-801.
263. Tan AK, Venkatasubramanian N, Tan CB, Lee SH, Tjia TL. Ischaemic stroke from cerebral embolism in cephalic fibromuscular dysplasia. *Ann Acad Med Singapore* 1995;24(6):891-4.
264. Stewart MT, Moritz MW, Smith RB, III, Fulenwider JT, Perdue GD. The natural history of carotid fibromuscular dysplasia. *J Vasc Surg* 1986;3(2):305-10.
265. Wells RP, Smith RR. Fibromuscular dysplasia of the internal carotid artery: a long term follow-up. *Neurosurgery* 1982;10(1):39-43.
266. Wesen CA, Elliott BM. Fibromuscular dysplasia of the carotid arteries. *Am J Surg* 1986;151(4):448-51.
267. Bahar S, Chiras J, Carpena JP, Meder JF, Bories J. Spontaneous vertebro-vertebral arterio-venous fistula associated with fibro-muscular dysplasia. Report of two cases. *Neuroradiology* 1984;26(1):45-9.
268. Welch EL, Lemkin JA, Geary JE. Gruntzig balloon dilation for fibromuscular dysplasia of the internal carotid arteries. *N Y State J Med* 1985;85(3):115-17.
269. Tsai FY, Matovich V, Hieshima G, et al. Percutaneous transluminal angioplasty of the carotid artery. *AJNR Am J Neuroradiol* 1986;7(2):349-58.
270. Finsterer J, Strassegger J, Haymerle A, Hagnmuller G. Bilateral stenting of symptomatic and asymptomatic internal carotid artery stenosis due to fibromuscular dysplasia. *J Neurol Neurosurg Psychiatry* 2000;69(5):683-6.
271. Manninen HI, Koivisto T, Saari T, et al. Dissecting aneurysms of all four cervicocranial arteries in fibromuscular dysplasia: treatment with self-expanding endovascular stents, coil embolization, and surgical ligation. *AJNR Am J Neuroradiol* 1997;18(7):1216-20.

19. Intracranial Cerebrovascular Occlusive Disease

This chapter will discuss intracranial arterial stenosis and occlusion due to atherosclerosis and moyamoya syndrome.

19.1. Atherosclerotic intracranial arterial disease

19.1.1. Prevalence and risk factors

Approximately 8–10% of ischemic strokes are attributable to intracranial atherosclerosis.^{1,2} In the USA, it is estimated that 40,000–60,000 new strokes per year are due to intracranial atherosclerosis.³

Distribution of symptomatic intracranial stenosis by location:

1. Internal carotid – 20.3%
 2. MCA – 33.9%
 3. Vertebral artery – 19.6%
 4. Basilar artery – 20.3%
 5. Multiple arteries – 5.9%
- (a) Percentages are taken from the patients randomized to aspirin in WASID.⁴

Risk factors:

1. Black, Asian, or Hispanic ethnicity⁵
 - (a) Black patients with TIA or stroke are more likely than white patients to have intracranial stenosis, whereas whites are more likely to have extracranial carotid atherosclerotic stenosis.¹
 - In a comparison of white and black patients with symptomatic posterior circulation disease, black patients had more lesions of the distal basilar artery, more high-grade lesions of intracranial branch vessels, and more symptomatic intracranial branch disease. Race was found to be the only factor increasing the risk of intracranial posterior circulation occlusive disease.⁶
 - (b) Asian patients have a higher proportion of MCA stenosis compared with Caucasian and black patients.⁷
 - Intracranial stenosis is responsible for stroke in up to 33% of Chinese patients.⁸
2. Hypertension is present in up to 75% of patients.⁹ Diabetes, coronary artery disease, cigarette smoking, and hypercholesterolemia, and peripheral arterial occlusive disease are also strongly associated.
3. Patients *without* carotid bifurcation disease are more likely to demonstrate progression of intracranial stenosis compared with patients with it.¹⁰
4. *Metabolic syndrome* is present in about 50% of patients with symptomatic intracranial atherosclerotic disease and is associated with a substantially higher risk of major vascular events.
 - Metabolic syndrome is a cluster of interrelated risk factors that together increase an individual's risk of cardiovascular disease.¹¹ The syndrome consists of four main categories of metabolic abnormalities: atherogenic dyslipidemia (elevated triglycerides and decreased high-density lipoproteins), increased blood pressure, elevated plasma glucose, and a prothrombotic state. Some 24% of US adults have metabolic syndrome.¹²

19.1.2. Etiology of symptoms

Ischemic symptoms due to intracranial stenosis are believed to arise from the following:

1. Hypoperfusion^{13, 14}
2. Thrombosis at the site of stenosis due to plaque rupture, hemorrhage within the plaque, or occlusive growth of the plaque^{15, 16}
3. Thromboembolism distal to the stenosis
4. Occlusion of small perforating arteries at the site of the plaque^{7, 17}

19.1.3. Natural history

Intracranial stenoses are dynamic lesions that may demonstrate both progression and regression on serial imaging.^{10, 18}

1. In a study of patients with intracranial stenosis undergoing repeat angiography at an average interval of 26.7 months, 40% of lesions were stable, 20% regressed, and 40% progressed.¹⁰
2. Stenosis progression, as detected by TCD, is an independent predictor of stroke recurrence.¹⁹
3. *Extracranial-intracranial (EC-IC) bypass surgery appears to promote progression of the lesion and occlusion of MCA in patients with nonoccluded MCA stenosis.*¹⁵

Asymptomatic intracranial stenosis is generally believed to be benign. In a series of 50 patients with asymptomatic MCA stenosis followed for a mean of 351 days, no patient had an ischemic stroke in the corresponding territory.⁹

The best studies of the natural history of *symptomatic* stenosis have been from several prospective studies of medical therapy. Estimates of the overall annual ipsilateral stroke risk in patients with intracranial stenosis from prospective studies range from 2.3 to nearly 13%.^{4, 7, 19-22} The most definitive study so far is the prospective WASID trial, which found a first-year risk of ischemic stroke in the pertinent vascular territory of 11–12%.⁴

The natural history of intracranial stenosis is somewhat dependent on the location of the lesion. Although a systematic review found no differences in recurrent ipsilateral stroke risk, overall mortality was found to be the lowest for patients with MCA stenosis.²³

1. Mean overall annual mortality²³:
 - a. MCA stenosis: 6.8%
 - b. Vertebrobasilar stenosis: 11.6%
 - c. Intracranial ICA stenosis: 12.4%

19.1.3.1. EC/IC Bypass Study

The subset of patients in the EC/IC Bypass Study with MCA stenosis randomized to medical therapy had an annual ipsilateral ischemic stroke rate of 7.8% per year.⁷ The EC/IC Bypass Study is discussed in detail in Chap. 18.

19.1.3.2. Warfarin vs. Aspirin for Symptomatic Intracranial Disease (WASID) studies

The WASID studies evaluated two medical management strategies in the treatment of patients with symptomatic intracranial stenosis. Two separate studies were done. The first study was retrospective and suggested that warfarin is superior to aspirin.²⁴ The second study was a prospective, multicenter, double-blinded randomized trial. Warfarin was associated with significantly higher rates of adverse events and did not provide a benefit over aspirin.⁴

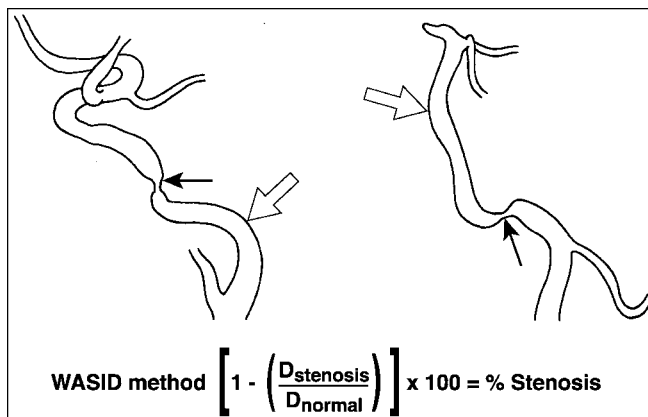


Fig. 19.1 WASID technique for measuring intracranial stenosis.

The equation used for determining percent stenosis of a major intracranial artery in WASID.²⁵ D_{stenosis} = the diameter of the artery at the site of the most severe degree of stenosis and D_{normal} = the diameter of the proximal normal artery. D_{normal} is selected according to the following criteria:

1. First choice (*left*): The diameter of the proximal part of the artery at its widest, nontortuous, normal segment is selected. Stenotic region (*arrow*); reference area (D_{normal}) (*open arrow*).
2. Second choice (*right*): If the lesion is at the origin of the vessel, or if the proximal artery is diseased (e.g., proximal basilar artery stenosis or M1 segment origin stenosis), the diameter of the distal portion of the artery at its widest, parallel, nontortuous normal segment is used. Stenotic region (*arrow*); reference area (D_{normal}) (*open arrow*).
3. Third choice: If the entire intracranial artery was diseased, the most distal, parallel, nontortuous normal segment of the feeding artery is measured.

WASID RETROSPECTIVE STUDY

The retrospective study examined 151 patients with symptomatic intracranial atherosclerotic stenosis evaluated by angiography at seven centers between 1985 and 1991.²⁴ Treatment consisted of either warfarin or aspirin and was determined at the treating physician's discretion. The mean follow-up period was 14.7 months in the warfarin group and 19.3 months in the aspirin group. The annualized rate of stroke was 3.6% in the warfarin group and 10.4% in the aspirin group ($p = 0.01$), suggesting that warfarin is superior to aspirin in the treatment of patients with symptomatic intracranial stenosis. These findings lead to the organization of the prospective WASID trial.

WASID PROSPECTIVE TRIAL

A total of 569 patients with TIA or stroke attributable to angiographically verified 50–99% stenosis of a major intracranial artery were randomized to receive warfarin (target INR, 2.0–3.0) or aspirin (1,300 mg per day).⁴ Enrollment was stopped prematurely (enrollment of 806 patients was originally planned) because of a significantly higher rate of hemorrhage in the warfarin group. The median time from qualifying event to randomization was 17 days, and the mean follow-up period was 1.8 years.

1. The primary endpoint of ischemic stroke, brain hemorrhage, or death from vascular causes other than stroke:
 - (a) 21.8% in the warfarin group
 - (b) 22.1% in the aspirin group ($p = 0.83$)
2. Rate of death:
 - (a) 9.7% in the warfarin group
 - (b) 4.3% in the aspirin group ($p = 0.02$)
3. Major hemorrhage
 - (a) 8.3% in the warfarin group
 - (b) 3.2% in the aspirin group ($p = 0.01$)

4. Myocardial infarction or sudden death:
 - (a) 7.3% in the warfarin group
 - (b) 2.9% in the aspirin group ($p = 0.02$)
5. Rate of death from vascular causes:
 - (a) 5.9% in the warfarin group
 - (b) 3.2% in the aspirin group ($p = 0.16$)
6. Rate of death from nonvascular causes
 - (a) 3.8% in the warfarin group
 - (b) 1.1% in the aspirin group ($p = 0.05$)

The risk of ischemic stroke in the territory of the stenotic artery at 1 year in patients treated with aspirin was 12%, and in patients treated with warfarin the risk was 11% ($p = 0.31$). Because of the high adverse event rates for patients treated with warfarin, and lack of therapeutic benefit of warfarin over aspirin for prevention of ischemic stroke caused by intracranial stenosis, the WASID investigators concluded that aspirin should be used in preference to warfarin for patients with intracranial arterial stenosis.

WASID PROSPECTIVE TRIAL SUBGROUP ANALYSES

An analysis of selected subgroups of patients in the WASID trial found no advantage of warfarin over aspirin for preventing the primary endpoint of ischemic stroke, brain hemorrhage, or vascular death.²⁶ A statistically significant benefit was associated with warfarin in patients with symptomatic basilar artery stenosis in terms of the primary endpoint (ischemic stroke, brain hemorrhage, or death from vascular causes other than stroke). However, the sample size and wide confidence intervals of this finding diminished the credibility of this finding. Furthermore, there was no difference in the rates of ischemic stroke in the territory of the symptomatic basilar artery between treatment group, and no benefit was found in patients with symptomatic intracranial vertebral artery stenosis. The WASID investigators concluded that warfarin demonstrated no convincing benefit in patients with basilar artery stenosis.

WASID PREDICTORS OF ISCHEMIC STROKE IN THE TERRITORY

OF A SYMPTOMATIC INTRACRANIAL STENOSIS

The majority of strokes (73%) in WASID patients were in the territory of the stenotic artery.²⁷ The risk of stroke in the territory of the stenotic artery was greatest in patients with the following characteristics:

1. Severe ($\geq 70\%$) stenosis ($p = 0.0025$).
2. Patients enrolled early (≤ 17 days) ($p = 0.028$).
3. There was a statistical trend toward an increased risk for women ($p = 0.051$).
4. Location of stenosis, type of qualifying event, and prior use of antithrombotic medications *were not* associated with increased risk.

19.1.3.3. GESICA study

The GESICA Study (Groupe d'Etude des Sténoses Intra-Crâniennes Athéromateuses symptomatiques) was a prospective, multicenter nonrandomized study in France.²² A total of 102 patients with symptoms attributable to intracranial stenosis $\geq 50\%$ indicated by either angiography or ultrasonography were enrolled. *Optimal medical therapy* was left to the discretion of the local investigators. The mean follow-up period was 23.4 months.

1. The annualized risk of a cerebrovascular event (TIA or stroke) in the territory of the affected artery was 19.2%.
 - (a) Annualized risk of TIA: 12.6%.
 - (b) Annualized risk of stroke: 7.0%

19.1.4. Medical treatment of symptomatic intracranial stenosis

Medical management of symptomatic intracranial stenosis consists of antiplatelet therapy, strategies to treat hyperlipemia, and aggressive control of medical risk factors, such as diabetes, hypertension, and cigarette smoking. Medical therapy of

patients with cerebral ischemia is discussed in detail in Chap. 17: *Acute Ischemic Stroke*. The authors of this handbook favor the following regimen for patients with symptomatic intracranial stenosis:

1. Aggrenox™ (Boehinger Ingelheim Pharmaceuticals, Inc.)
 - (a) Aspirin (25 mg) plus extended-release dipyridamole (200 mg) PO BID has been found in a randomized trial to reduce risk of recurrent stroke.²⁸
2. Atorvastatin (Lipitor®, Pfizer, Inc.)
 - (a) High-dose atorvastatin (80-mg PO QD) was found in a randomized trial to reduce the risk of recurrent stroke.²⁹
 - (b) Note: Myalgia is a common side effect; myopathy and rhabdomyolysis occur in <0.01% of patients. Blood work including serum creatinine, creatine kinase (CK), and liver function tests should be done prior to starting the drug and at 3 months on the drug.
3. Antihypertensive agents, as needed.
4. Tight control of serum glucose, for diabetic patients.
5. Smoking cessation.

19.1.5. Intracranial angioplasty and stenting

Intracranial angioplasty with or without stenting is beginning to emerge as an acceptable treatment in selected patients. However, the efficacy of the technique is difficult to assess from the existing literature due to (1) rapidly evolving technology; (2) a wide variety of techniques reported in the literature; and (3) a paucity of prospective data, and the complete absence of randomized trial data. Most single-center series have reported on angioplasty alone,^{30–34} or angioplasty and stenting with balloon-mounted coronary stents.^{33, 35} Angioplasty without stenting is associated with a significant risk of restenosis,³⁰ which has led to interest in angioplasty with stenting. Balloon-mounted coronary stents, however, are limited by the low flexibility of coronary stent system, the high inflation pressures needed to deploy balloon-mounted stents in fragile intracranial vessels, and the risk of shearing the stent from the balloon while navigating to the target lesion.³⁶ The best studies of intracranial angioplasty and stenting are the *SSYLVA*³⁷ and *Wingspan*³⁶ studies, both of which were prospective, nonrandomized studies using devices specifically designed for the treatment of intracranial stenosis.

A Cochrane systematic review of 79 publications of intracranial angioplasty with or without stenting found the following³⁸:

1. Overall perioperative stroke rate of 7.9%
2. Perioperative death rate of 3.4%
3. Perioperative rate of stroke or death of 9.5%

19.1.5.1. Stenting of Symptomatic Atherosclerotic Lesions in the Vertebral or Intracranial Arteries (SSYLVA)

The SSYLVA trial was a multicenter, nonrandomized, prospective feasibility study of the Neurolink® intracranial stent system (a product of the Guidant Corporation, which is now part of Boston Scientific) for treatment of vertebral or intracranial artery stenosis.³⁷ The Neurolink stent is a balloon-mounted device. A total of 43 patients with symptomatic intracranial stenosis and 18 patients with extracranial vertebral artery stenosis were enrolled.

1. Successful stent placement was achieved in 95% of cases.
2. Thirty-day periprocedural stroke rate: 6.6%. No deaths occurred. Two strokes occurred during the procedure.
3. At 6-month angiographic follow-up, restenosis of >50% occurred in 32.4% of intracranial vessels and 42.9% of extracranial vertebral arteries.
 - (a) 39% of the recurrent stenoses were symptomatic.
4. Strokes in the distribution of the target lesion occurring after 30 days but by 12 months were seen in 7.3% of patients.

Based upon this study, the FDA granted a humanitarian device exemption to treat patients with significant intracranial and extracranial atherosclerotic disease by balloon angioplasty and stent placement. Boston Scientific is not currently marketing the Neurolink device, in favor of the Wingspan® system.

19.1.5.2. Wingspan study

The Wingspan™ Stent System with Gateway™ PTA Balloon Catheter (Boston Scientific SMART, Fremont, CA) was designed for the treatment of intracranial atherosclerotic stenosis. Pre-stent dilation of the lesion is done with the angioplasty balloon, and the stent, a self-expanding nitinol device, is then deployed. The device received FDA approval as a new humanitarian device in August 2005 (<http://www.fda.gov/cdrh/mda/docs/h050001.html>). The Wingspan Study was a prospective, multicenter nonrandomized study of the devices in medically refractory patients with recurrent symptoms attributable to intracranial stenosis $\geq 50\%$ in a vessel 2.5–4.5 mm in diameter.³⁶ A total of 45 patients were enrolled. The mean initial degree of stenosis was 77.9%, and the mean lesion length was 7.2 mm.

1. The stent was successfully deployed in 97.8% of cases.
 - (a) Procedural adverse events were reported in 27% of patients but none resulted in permanent sequelae.
2. The degree of stenosis was reduced from a baseline of 74.9% to 31.9% after stenting.
3. The 30-day composite stroke/death rate was 4.5%.
4. Clinical follow-up at 6 months:
 - (a) Ipsilateral stroke/death rate: 7.0%
 - (b) Incidence of all strokes: 9.7%
 - (c) All-cause mortality: 2.3%
5. Angiographic follow-up at 6 months:
 - (a) Mean degree of stenosis: 28%.
 - (b) Three patients (6.8%) showed restenosis $>50\%$; all were asymptomatic.

In contrast to SSYLVA, which reported a rate of restenosis $>50\%$ of 32.4% at 6 months, the mean degree of stenosis at 6 months in the Wingspan Study was not significantly different from the degree of stenosis immediately after the procedure.

19.1.5.3. Other notable studies

1. MORI 1998

Mori et al. reported on angioplasty without stenting in 42 patients with intracranial stenosis $>70\%$ stenosis.^{30,31} The risk of recurrent stenosis was strongly associated with lesion length and complexity:

	Lesion length and geometry	Rate of restenosis at 3 months
Type A	≤ 5 mm, concentric or moderately eccentric	0
Type B	5–10 mm, extremely eccentric or totally occluded	30.8%
Type C	>10 mm, $>90\%$ angulation, or totally occluded	66.7%

2. MARKS 2006

Report of 120 patients with intracranial stenosis $\geq 50\%$ who were treated with angioplasty without stenting.³⁴ A total of 116 patients were available for a mean follow-up time of 42.3 months.

- (a) Degree of stenosis was reduced by angioplasty from a mean of 82.2% to 36.0%.
- (b) Combined 30-day periprocedural stroke and death rate was 5.8%.
- (c) Annual postprocedure stroke rate was 3.2% in the territory of treatment and annual overall stroke rate was 4.4%.

19.1.5.4. Position statement on intracranial angioplasty and stenting for cerebral atherosclerosis by the ASITN, SIR, and ASNR³:

1. For symptomatic patients with $>50\%$ intracranial stenosis, who have failed medical therapy, balloon angioplasty with or without stenting should be considered.
2. Patients who have an asymptomatic intracranial arterial stenosis should first be counseled regarding optimizing medical therapy. There is insufficient evi-

dence to make definitive recommendations regarding endovascular therapy in asymptomatic patients with severe intracranial atherosclerosis. They should be counseled regarding the nature and extent of their disease, monitored for new neurological symptoms, and have periodic noninvasive imaging at regular intervals of 6–12 months (MRA or CTA) initially, and then by cerebral angiography if warranted. At a minimum, optimal prophylactic medical therapy should be instituted, which might include antiplatelet and/or statin therapy.

- Continued evaluation and improvements in both pharmacological and catheter-based therapies are needed to reduce the stroke burden from intracranial atherosclerosis.

Note: *ASITN*, American Society of Interventional and Therapeutic Neuroradiology, *SIR* Society of Interventional Radiology, *ASNR* American Society of Neuroradiology

19.2. Moyamoya disease and moyamoya syndrome

Moyamoya disease (aka spontaneous occlusion of the circle of Willis) is a nonatherosclerotic progressive steno-occlusive arteriopathy that most frequently affects the intracranial ICAs and proximal segments of the MCAs and ACAs. It may also involve the posterior circulation. Spontaneous occlusion of the major intracranial arteries is typically accompanied by the appearance of a tuft of fine collateral vessels at the base of the brain. *Moyamoya* is a Japanese word meaning *puff of smoke*, or *ambiguous*, which are descriptions not only of the tuft of collaterals but also the obscure etiology of the syndrome, which remains unelucidated.³⁹ The term *moyamoya disease* is reserved for those cases in which the intracranial vascular changes are primary and truly idiopathic, whereas *moyamoya syndrome* (aka secondary moyamoya, moyamoya phenomenon, syndromic moyamoya, quasi-moyamoya, or moyamoya-like vascular changes) is used with the intracranial vascular changes that occur in association with another condition, such as cranial radiation or neurofibromatosis type 1.⁴⁰

19.2.1. Epidemiology

Ethnicity plays a major role. Japan and South Korea appear to have the highest concentrations of patients with moyamoya disease.

- Japan:
 - Approximately 3,900 patients in Japan were treated for moyamoya in 1994.⁴¹
 - Prevalence rate of 3.16 and annual incidence of 0.35 per 100,000.
 - Approximately 100 new cases are identified each year.⁴²
 - Male to female ratio: 1:1.8.
 - Peak ages are 10–14 years and 40s.
 - Age at onset is <10 years in 47.8% of the patients; some develop the disease at the age of 25–49 years.
- South Korea:
 - Female predominance and bimodal age distribution pattern are similar to those seen in Japanese patients. The incidence of adult moyamoya disease in South Korea is 20% higher than that in Japanese patients, and the incidence of familial moyamoya syndrome is only 1.8%.⁴³
- China:
 - Data on moyamoya in China is very limited. Two reports indicate the following:
 - More common in males and the average age of onset is higher, compared with Japanese patients.^{44, 45}
 - One report has attributed the majority of cases (53%) in China to leptospiral arteritis, and found that 81.4% of patients with moyamoya syndrome have positive leptospiral test results.⁴⁴
- North America:
 - The overall incidence of moyamoya syndrome in California and Washington is 0.086 per 100,000.⁴⁶
 - Male to female ratio: 1:2.15

- Incidence per 100,000 is highest among Asian Americans and lowest among Hispanics:
 - Asian Americans: 0.28
 - African Americans: 0.13
 - Whites: 0.06
 - Hispanics: 0.03
 - Median age of onset is as follows:
 - Asian Americans: 36
 - African Americans: 18
 - Whites: 32
 - Hispanics: 21
 - Sickle cell disease likely accounts for the relatively high incidence and low age of onset among African Americans; when patients with sickle cell disease were excluded, the incidence among African Americans was similar to that in whites.
- (b) The prevalence of moyamoya disease in Hawaii appears to be higher than in the rest of the USA.⁴⁷
5. Europe:
- (a) A survey of European centers lead to an estimate of the incidence of moyamoya to be about 1/10 the incidence in Japan.⁴⁸
- (b) A slightly higher incidence in Eastern Europe has been hypothesized to be due to the Mongolian invasion of Europe, which may have spread the genetic predisposition for moyamoya disease.⁴⁹

19.2.2. Pathophysiology

The primary lesion in moyamoya disease is progressive fibrocellular thickening of the intima.⁵⁰⁻⁵² The intima acquires an onion-like appearance, consisting of fibrocellular materials, but without lipids or calcification as is seen in atherosclerosis.⁵³ The internal elastic lamina is also abnormal, becoming infolded, tortuous, redundant, and fragmented.⁵⁴ The media is thinned, with a diminished number of smooth muscle cells.⁵² No inflammatory changes are seen. Intimal thickening has also been found in the superficial temporal arteries of patients with moyamoya.⁵⁵ Histological analysis has shown thrombotic lesions in the affected intracranial vessels in 54% of cases.⁵⁶

The secondary lesions in moyamoya syndrome are dilated, tortuous thalamostriate and lenticulostriate arteries at the base of the brain. These vessels do not appear to be normal collateral vessels that would be expected to develop in response to chronic occlusion of major arteries. They exhibit thinned and fragmented internal elastic laminae, medial fibrosis, microaneurysms, and areas of rupture.⁵⁰ Stenosis of these vessels, due to fibrous intimal thickening and thrombosis, is seen in 50% of cases.⁵⁰

The etiology of moyamoya disease is unknown. Several mechanisms have been implicated:

1. Primary defect in smooth muscle cells.
 - (a) Deoxyribonucleic acid synthesis experiments involving cultured smooth muscle cells from moyamoya patients indicate that the cells are less responsive to their normal mitogens. This suggests that there be a derangement in the vessel wall repair mechanism that leads to long-term proliferation of cells and progressive occlusion of the vessel lumen.⁵⁷
2. Role of angiogenic factors.
 - (a) Basic fibroblast growth factor (bFGF). Elevated levels of bFGF have been found in the CSF^{58, 59}, superficial temporal artery,⁶⁰ and in the affected ICA⁶¹ of patients with moyamoya disease. Basic FGF is a potent angiogenic factor. It is not clear whether elevation of bFGF is a primary event in the pathogenesis of moyamoya, or an epiphenomenon in response to chronic ischemia. Interestingly, elevated CSF bFGF correlates with the degree of angiogenesis seen with indirect revascularization procedures in patients with moyamoya disease.^{59, 62}
 - (b) Elevated expression of transforming growth factor beta 1 has been found in cultured smooth muscle cells and in serum from patients with moyamoya disease.⁶³
 - (c) Hepatocyte growth factor, an angiogenic factor, is elevated in CSF and intracranial arteries in patients with moyamoya disease.⁶⁴
3. Alteration in metalloproteinase gene expression.

- (a) The association analysis of tissue inhibitor of metalloproteinase 2 in 17q25 showed that a polymorphism in the promoter region was markedly associated with familial moyamoya disease.⁶⁵
- 4. Excessive prostaglandin synthesis.
 - (a) Cultured smooth muscle cells from moyamoya patients produce excess amounts of prostaglandin E(2) in response to stimulation with interleukin-1 beta.⁶⁶ This may increase vascular permeability and exposure of the vessels to blood constituents, leading to intimal thickening.
- 5. Role of Epstein-Barr virus (EBV) infection.
 - (a) Antibody titers of EBV are significantly elevated in patients with moyamoya disease,⁶⁷ raising the possibility that EBV infection may be involved.

19.2.3. Diagnosis of moyamoya disease

The Ministry of Health and Welfare in Japan has established guidelines for the diagnosis of moyamoya disease.⁶⁸ The diagnosis may be made by catheter angiography or MRI and MRA. Cases are defined as either definite or probable, depending on which criteria are satisfied.

19.2.3.1. Diagnostic criteria

1. Cerebral angiography should demonstrate the following findings:
 - (a) Stenosis or occlusion at the terminal portion of the ICA and/or the proximal portion of the ACA and/or MCA.
 - (b) Abnormal vascular networks in the vicinity of the occlusive or stenotic lesions.
 - (c) These findings should be present bilaterally.
2. When MRI and MRA clearly demonstrate all of the findings listed later, catheter angiography is not mandatory.
 - (a) Stenosis or occlusion at the terminal portion of the ICA and at the proximal portion of the ACA and MCA.
 - (b) An abnormal vascular network in the basal ganglia on MRA. An abnormal vascular network can be diagnosed on MRI when >2 apparent flow voids are seen in one side of the basal ganglia.
 - (c) (1) and (2) are seen bilaterally.
3. Other causes are excluded. Because the etiology of the disease is unknown, associated cerebrovascular diseases or conditions should be excluded. These include, but are not limited to the following:
 - (a) Arteriosclerosis
 - (b) Autoimmune disease
 - (c) Meningitis
 - (d) Brain neoplasm
 - (e) Down syndrome
 - (f) Neurofibromatosis type 1
 - (g) Head trauma
 - (h) Cranial irradiation
4. Pathological findings that can be helpful in the diagnosis are as follows:
 - (a) Intimal thickening that causes stenosis or occlusion of the lumen is observed in and around the terminal portion of the internal carotid artery. Lipids deposition is occasionally seen in the proliferating intima.
 - (b) Arteries of the circle of Willis often show stenosis or occlusion associated with fibrocellular thickening of the intima, waving of the internal elastic lamina, and attenuation of the media.
 - (c) Numerous small arteries (perforating and anastomotic branches) are observed around the circle of Willis.
 - (d) Reticular conglomerates of small vessels are often seen in the pia mater.

19.2.3.2. Diagnosis

1. *Definite case:* Either all criteria in (1) or all criteria in (2) and (3) are fulfilled. In children, however, a case that fulfills [1, (a) and (b)] or [2, (a) and (b)] on one

- side and demonstrates narrowing at the terminal portion of the internal carotid artery on the opposite side is also considered to be a definite case.
2. *Probable case*: Either [1, (a) and (b)] or [2, (a) and (b)] and (3)] are fulfilled (i.e., unilateral involvement).

19.2.4. Evaluation

19.2.4.1. CT

Significant abnormal findings on CT are present in 92% of cases.⁶⁹ These include cortical atrophy, ventricular dilatation, and irregular, multiple or bilateral lucent areas in the cortex, white matter, and central gray matter.

19.2.4.2. Angiography

Although a diagnosis of moyamoya disease may be made with MRI and MRA alone,⁶⁸ the authors of this handbook recommend catheter angiography in most patients and all adults suspected of having moyamoya disease or moyamoya syndrome. Angiography in children with moyamoya disease is not associated with a higher rate of complications compared with angiography in children without moyamoya.⁷⁰ Angiography is the best imaging technique to distinguish high-grade stenosis from occlusion, identify intracranial aneurysms, and assess collateral circulation. Importantly, angiography is critical for planning surgical procedures; for instance, angiography can best demonstrate transdural collateral vessels that should be preserved during revascularization procedures.

1. Angiographic staging of moyamoya disease is summarized in [Table 19.1](#). Stage 4 is the most common stage at presentation. Angiographic stage is usually more advanced in more elderly patients.⁷²
2. Stenosis or occlusion of the intracranial ICA and/or the A1 and M1 segments are seen in all cases.
3. Stenosis or occlusion of the PCA is seen in 43% of cases.⁷³
4. Involvement of the ECA is usually not seen,⁷⁴ although stenosis of branches of the ECA was reported in 20% of cases in one series.⁷⁵
5. Abnormal moyamoya vessels may be seen in several locations.
 - (a) Basal ganglia – branches of the circle of Willis
 - (b) Ethmoidal region – branches of the ICA and ophthalmic artery⁷⁶
 - (c) Cerebral hemispheres (i.e., *vault moyamoya*) – branches of the anterior falx, middle meningeal, occipital, tentorial, and superficial temporal arteries⁷⁷
 - (d) Posterior choroidal, thalamogeniculate, and other thalamoperforating arteries⁷⁸
6. The extensive development of basal moyamoya vessels is a sign of severe hemodynamic impairment in adult patients with ischemic moyamoya disease.⁷⁹
7. Moyamoya vessels may recede after surgical revascularization.⁸⁰
8. Intracranial aneurysms are present in about 10% of cases.^{81–84} They are attributable to abnormal hemodynamic patterns, or for those that arise from

Table 19.1 Angiographic stages of moyamoya disease

Stage	Angiographic findings
1	Stenosis of the supraclinoid ICA. Usually bilateral. No other abnormalities.
2	Initiation of moyamoya vessels at the base of brain.
3	Intensification of moyamoya vessels. Increased stenosis or occlusion of the ICA, MCA, or ACA.
4	Complete occlusion of the ICA with some reduction in moyamoya vessels. First appearance of collaterals from ECA branches. Most common stage at presentation.
5	Further reduction of moyamoya vessels with increased collateralization from ECA.
6	Complete absence of major intracranial arteries and moyamoya vessels. Uncommon.

From Suzuki and Takaku⁷¹

moyamoya vessels, abnormal vessel architecture. Aneurysms are found in three locations:⁸⁵

- (a) Circle of Willis, mostly in the posterior circulation: 60% of cases.
 - (b) Peripheral cerebral arteries, such as the anterior or posterior choroidal arteries: 20%.
 - (c) Abnormal moyamoya vessels: 20%.
9. Persistent primitive arteries have been observed in both moyamoya disease and moyamoya syndrome at higher frequencies than in the general population.⁸⁶

19.2.4.3. MRI

1. MRI findings in moyamoya disease:⁸⁷⁻⁹⁰
 - (a) Stenosis or occlusion of the distal ICA or proximal ACA and MCA
 - (b) Signal voids in the basal ganglia
 - (c) Marked leptomeningeal enhancement on postcontrast images
 - (d) Evidence of infarction, atrophy, and ventriculomegaly
 - (e) Hemorrhage
2. Compared with conventional angiography, the sensitivity and specificity of MRI plus MRA in the diagnosis of moyamoya disease is 92 and 100%, respectively.⁸⁷
 - (a) Basal cerebral moyamoya vessels were depicted on MRI in 92% of cases and on MRA in 81% of cases.⁸⁷
3. In a series of 30 patients with moyamoya disease, all showed clear evidence on MRI of bilateral stenosis or occlusion of the supraclinoid ICA and proximal ACAs and MCAs.⁸⁸ Parenchymal lesions were apparent on MRI in 80% of cases. White matter infarctions are the most frequent parenchymal lesions and are seen in 73% of cases.
4. *Ivy sign*: Marked diffuse leptomeningeal enhancement on postcontrast T1-weighted and FLAIR images.⁹⁰⁻⁹² Considered to represent the fine vascular network over the pial surface.

19.2.4.4. Cerebral blood flow studies

CBF imaging techniques for moyamoya patients include PET,⁹³ xenon CT,^{94, 133} Xe,⁹⁵⁻⁹⁷ and SPECT.^{98, 99} Regional CBF in patients with moyamoya is characteristically diminished in the frontal and temporal lobes, and elevated in the posterior circulation territory (cerebellum and occipital lobes), and in central brain structures that are involved with basal moyamoya vessels. The degree of hemodynamic stress in patients with moyamoya disease varies greatly between patients.¹⁰⁰ CBF studies can help predict the risk of stroke⁹⁴ and the success of revascularization surgery.¹⁰¹

19.2.4.5. EEG

EEG findings are nonspecific in adults with moyamoya. Although EEG used to be a screening tool for children suspected of having moyamoya disease, it is currently considered to be somewhat obsolete for this purpose.⁸⁵ Characteristic EEG findings may be observed in children with moyamoya disease. These include the following¹⁰²:

1. Low-amplitude slow waves, aka hemispheric posterior slowing or centrotemporal slowing.
2. Sleep spindle depression.
3. *Rebuildup phenomenon*: Hyperventilation characteristically causes a buildup of slow waves that resolves within 20–60 s after hyperventilation. In 70% of cases, buildup of slow waves appears after the original buildup had returned to baseline. Rebuildup of slow waves has been localized to the deep cortical sulci in regions of hemodynamic failure.¹⁰³ This phenomenon disappears after surgery for moyamoya,¹⁰⁴ and is not observed in adults with moyamoya.¹⁰²

19.2.5. Clinical features of moyamoya disease

The classic description of moyamoya disease separates the *juvenile form* from the *adult form*. This corresponds to the bimodal age distribution – with a higher peak around 5 years of age and a lower peak during the fourth and fifth decades – and the

observation that younger patients tend to present with ischemic symptoms and adult patients often present with hemorrhage. This distinction is appropriate for patients with moyamoya disease. Growing evidence suggests that the clinical expression of moyamoya syndrome, particularly in North American and European patients, is fundamentally different, in that ischemia seems to be the most common presenting symptom, regardless of age.⁸³⁻⁸⁵ The clinical features of moyamoya syndrome are discussed separately later.

1. Juvenile form:

- (a) Initial signs and symptoms on admission¹⁰⁵:
 - Motor deficit: 81.5%
 - Headache: 27.2%
 - Mental retardation: 19.8%
 - Speech disturbance: 17.3%
 - Sensory disturbance: 16.0%
 - Seizure: 6.2%
 - Involuntary movement: 6.2%
- (b) Neurological symptoms are often precipitated by hyperventilating during activities such as crying or blowing.³⁹
- (c) Intracranial hemorrhage and aneurysms are rare.³⁹
- (d) Mental retardation has been described in >50% of cases, and the onset of ischemic symptoms in patients <5-years old is associated with progressive mental retardation.¹⁰⁶
- (e) Symptoms in children often stabilize over time, as collateral circulation develops and an age-dependent decrease in CBF demand by the brain occurs.³⁹

2. Adult form:

- (a) Intracranial hemorrhage is the presenting event in >60% of cases.⁸³
 - Bleeding may arise from the following¹⁰⁷:
 - Abnormal vascular networks
 - Intracranial aneurysms
 - About 1/3 of patients presenting with hemorrhage will have another hemorrhage within days to years of the initial event.⁸³
- (b) Intraventricular hemorrhage is the most common form of hemorrhage, present in 69% of patients presenting with hemorrhage.¹⁰⁸
- (c) Mortality in the acute phase is 2.4% with infarction and 16.4% with hemorrhage.⁸⁵
- (d) Risk of rehemorrhage: In a series of 42 patients with hemorrhagic moyamoya disease followed for a mean of 80.6 months, the average annual rebleeding rate was 7.09% per person.¹⁰⁸ After rebleeding, the rate of good recovery fell from 45.5 to 21.4% and the mortality rate rose from 6.8 to 28.6%.
- (e) Long-term clinical outcome:
 - Overall, some 75% of the patients in Japan with moyamoya disease have normal activities of daily life or working ability, even prior to treatment.⁴¹

3. Unilateral disease (aka probable moyamoya disease): There is some evidence that unilateral moyamoya disease is distinct from typical bilateral moyamoya disease.

- (a) Progression to bilateral disease:
 - In an analysis of 180 cases of unilateral disease in Japan, only 7% developed into the definite type in an average follow-up period of 6.6 years.¹⁰⁹
 - In a South Korean series, 2 of 7 unilateral cases (28.5%) progressed to bilateral involvement in a mean follow-up period of 5.4 years.¹¹⁰
 - In a North American series of 18 patients with unilateral disease (defined as no, equivocal, or mild involvement of the contralateral side), progression to bilateral disease was seen in 7 patients (38.9%) at a mean follow-up of 12.7 months.¹¹¹
 - The presence of mild or equivocal contralateral disease was an important predictor of progression; although 75% of patients with mild or equivocal contralateral findings progressed, only 10% of patients with no initial contralateral findings progressed.
- (b) Unilateral disease appears to be more common among adults than among children.¹⁰⁹
- (c) Familial occurrence is less common in patients with unilateral disease.^{112, 113}

- (d) CSF levels of bFGF are lower in patients with unilateral disease compared with patients with definite moyamoya disease.¹¹²
- 4. *Asymptomatic moyamoya disease*: A prospective study followed 40 patients with asymptomatic moyamoya disease at 12 centers in Japan for a mean period of 43.7 months.⁷² Six of these patients underwent surgical revascularization.
 - (a) On initial evaluation, 20% of patients had radiographic evidence of infarction and 40% exhibited disturbed cerebral hemodynamics.
 - (b) The annual risk for any stroke was 3.2%. Of 34 patients treated without surgery, 7 had a neurologic event during the follow-up period, 3 had a TIA, 1 had an ischemic stroke, and 3 had hemorrhage.
 - (c) No cerebrovascular event occurred in the six patients who underwent surgical revascularization.

19.2.6. Familial moyamoya disease

1. Definition of familial moyamoya disease: when at least one first-degree relative is affected.¹¹⁴
 - (a) Compared with the general population, first- or second-degree relatives of patients with moyamoya disease have a 30- to 40-fold risk of having the disease.¹¹⁵
2. Approximately 10% of moyamoya disease cases are familial.^{41, 116-118}
 - (a) A family history of moyamoya is present in about 1.8% of Korean patients.⁴³
3. Mean age of onset (11.8 years) is significantly lower compared with that in sporadic moyamoya disease (30 years).¹¹⁴
4. Greater female preponderance compared with sporadic moyamoya disease
 - (a) Male:female ratio is (1:5)¹¹⁴ or 1:3.3.¹¹⁵
5. Mode of inheritance is autosomal dominant with incomplete penetrance.¹¹⁹
6. Familial moyamoya has been linked to chromosomes 3p24.2-p26, 6q25, 8q23, 12p12, and 17a25.¹²⁰⁻¹²³
7. Familial moyamoya disease is associated with
 - (a) Systemic lupus erythematosus.¹²⁴
 - (b) Basilar apex aneurysms.¹²⁵
8. Screening with MRA has been recommended for family members of patients with moyamoya disease.¹²⁶

19.2.7. Conditions associated with moyamoya syndrome

A large number of systemic conditions and other factors have been associated with moyamoya. The presence of one of these factors in a patient with moyamoya-type radiographic findings may indicate that the patient has moyamoya *syndrome*, rather than the *disease*, particularly if the patient is not Asian. Caution must be used in interpreting these associations, because many of them are based only on case reports. Among non-Asian patients with moyamoya syndrome, Down syndrome, sickle cell disease, and a history of cranial irradiation are the most established associated factors.

1. Autoimmune disorders
 - (a) Graves disease^{127, 128}
 - (b) Sjögren syndrome^{129, 130}
 - (c) Primary antiphospholipid syndrome^{131, 132}
 - (d) Systemic lupus erythematosus^{124, 130, 133}
2. Infections
 - (a) Pneumococcal meningitis¹³⁴
 - (b) Tuberculosis^{135, 136}
 - (c) Leptospirosis⁴⁴
 - (d) Congenital human immunodeficiency virus infection¹³⁷
3. Hematological disorders
 - (a) Sickle cell disease^{46, 138}
 - (b) Aplastic anemia¹³⁹
 - (c) Fanconi anemia^{140, 141}
 - (d) Hereditary spherocytosis¹⁴²
 - (e) Thalassemia¹⁴³
 - (f) Hemophilia A¹⁴⁴

- (g) Thrombocytopenic purpura¹⁴⁵
- (h) Hemolytic anemia¹⁴⁶
- (i) Essential thrombocytopenia¹⁴⁷
- (j) Acute lymphoblastic anemia¹⁴⁸
- (k) Protein C or S deficiency^{149–152}
- (l) Hageman factor (Factor XII) deficiency¹⁵³
- 4. Metabolic disorders
 - (a) Hyperlipoproteinemia type 2A¹⁵⁴
 - (b) Glycogen storage disease type 1¹⁵⁵
 - (c) Pseudoxanthoma elasticum¹⁵⁶
 - (d) Hyperthyroidism¹⁵⁷
 - (e) Impaired NADH-CoQ reductase activity
 - (f) Hyperhomocysteinemia¹⁵⁸
- 5. Genetic syndromes
 - (a) Down syndrome^{146, 159}
 - (b) Neurofibromatosis type I^{146, 160}
 - (c) Apert syndrome¹⁶¹
 - (d) Turner syndrome¹⁶²
 - (e) Williams syndrome¹⁶³
 - (f) Tuberous sclerosis¹⁶⁴
 - (g) Osteogenesis imperfecta¹⁶⁵
 - (h) Noonan syndrome^{166, 167}
 - (i) Costello syndrome¹⁶⁸
 - (j) Alagille syndrome^{169, 170}
 - (k) Smith-Magenis syndrome¹⁷¹
 - (l) Trisomy 12p syndrome¹⁷²
- 6. Connective tissue or collagen vascular syndromes
 - (a) Fibromuscular dysplasia¹⁷³
 - (b) Polycystic kidney disease¹⁷⁴
 - (c) Marfan syndrome¹⁷⁵
 - (d) CREST syndrome¹⁷⁶
- 7. Neoplasms
 - (a) Craniopharyngioma¹⁷⁷
 - (b) Pituitary adenoma¹⁷⁸
 - (c) Brainstem glioma¹⁷⁹
 - (d) Wilm's tumor¹⁸⁰
- 8. Medications and recreational drugs
 - (a) Oral contraceptives¹⁸¹
 - (b) Cocaine^{182, 183}
- 9. Radiation
 - (a) Cranial irradiation^{184–186}
- 10. Other disorders or factors
 - (a) Atherosclerosis¹⁸⁷
 - (b) Behcet's disease¹⁸⁸
 - (c) Morning glory syndrome¹⁸⁹
 - (d) Brain AVM^{190, 191}
 - (e) Cerebral arterial dolichoectasia¹⁹²
 - (f) Persistent primitive arteries^{86, 193}
 - (g) Renovascular hypertension^{194, 195}
 - (h) Phakomatosis pigmentovascularis type IIIb¹⁹⁶
 - (i) Pulmonary sarcoidosis¹⁹⁷
 - (j) Heterotopic ossification¹⁹⁸
 - (k) Congenital heart disease¹⁹⁹
 - (l) Head injury²⁰⁰
 - (m) Hirschsprung disease²⁰¹
 - (n) Peripheral vascular occlusive disease²⁰²

19.2.7.1. Clinical features of moyamoya disease and syndrome in North American patients

The manifestations of moyamoya disease appear to be fundamentally different in North American (and European) patients compared with Japanese and Korean patients.^{84, 85} Cerebral ischemia and not hemorrhage appears to be the most common presentation in adults in North America and Europe.^{83, 84} In addition, moyamoya syndrome seems to be more common than the disease in North America,²⁰³ whereas

the reverse is true in Japan.⁸⁵ Conditions associated with moyamoya syndrome, therefore, play a greater role in the clinical features of affected American and European patients. Two publications from centers in the USA have shed light on these issues:

1. *Chiu 1998*⁸⁴: Series of 35 patients from Houston, TX with moyamoya disease. Mean age was 32 years (range: 6–59). Thirty-two patients had definite moyamoya disease and three had probable disease. Only two patients were of Asian descent. The male to female ratio was 1:2.5. The mean follow-up period was 40 months after diagnosis.
 - (a) Ischemic stroke or TIA was the initial symptom in both adults and children, occurring on presentation in 75% of patients overall. Of the adult patients, 88% presented with ischemic symptoms and 11.5% presented with hemorrhage. The crude stroke recurrence rate was 10.3% per year.
 - The stroke recurrence risk was highest in the first year after diagnosis (18%) and decreased to 5% per year thereafter.
 - (b) IVH was the most common form of hemorrhage, occurring in 83% of patients presenting with intracranial hemorrhage.
 - (c) Twenty patients underwent surgical revascularization, including indirect and direct procedures.
 - (d) The 5-year risk of ipsilateral stroke after indirect revascularization was 15%, compared with 20% for medical treatment and 22% overall for surgery.
2. *Hallemeier 2006*²⁰⁴: Series of 34 adults with definite or probable moyamoya disease. Patients included both those with bilateral ($n = 22$) and unilateral ($n = 12$) disease. Only two patients were of Asian descent. Patients were excluded from this study if they had another disease that may have been responsible for the vasculopathy. Median age was 42 (range 20–79). The median follow-up period was 5.1 years.
 - (a) Ischemia was the initial symptom in 24 (70.6%) of patients. Seven (20.6%) presented with hemorrhage and three were asymptomatic.
 - In the medically treated patients, the 5-year risk of recurrent ipsilateral stroke was 65% after the initial symptom.
 - Patients with bilateral involvement presenting with ischemic symptoms were at the highest risk of subsequent stroke: 5-year risk of stroke with medical management was 82%.
 - Of the seven patients presenting with hemorrhage, none had a subsequent hemorrhage and only one experienced an ischemic stroke.
 - None of the asymptomatic patients had a stroke.
 - (b) Fourteen patients underwent surgical revascularization procedures.
 - i. In patients treated with surgery, the 5-year risk of perioperative or subsequent ipsilateral stroke or death was 17%.

19.2.8. Management

19.2.8.1. Medical management

No medical regimen has been proven to be effective in moyamoya patients. Long-term anticoagulation is not recommended because of the risk of hemorrhagic stroke.⁸⁴ Antiplatelet therapy may be useful, given the relatively high frequency of thrombosis noted in pathology reports.^{50, 56} The authors of this handbook favor aspirin, 325-mg PO QD for most patients with moyamoya syndrome or disease and ischemic symptoms.

19.2.8.2. Surgical management

An array of surgical revascularization techniques has been introduced for patients with moyamoya disease. The first procedure, cervical sympathectomy, which was done to decrease vasomotor tone, was found to be ineffective in the long term.²⁰⁵ Direct bypass procedures consist of direct anastomoses between the extracranial and intracranial circulations (EC-IC bypass) and can be subdivided into high-flow (e.g., saphenous vein graft anastomosis) or low-flow (e.g., STA-MCA bypass) techniques. Indirect procedures were developed because of the difficulty in doing direct bypass procedures in children, and involve the placement of the STA or vascular tissue, such as the temporalis muscle, dura, or omentum directly on the surface of the brain to promote collateral formation.

INDICATIONS FOR SURGICAL REVASCLARIZATION

No randomized trial of bypass surgery for moyamoya has been completed yet. The Ministry of Health and Welfare in Japan has published guidelines for the use of bypass surgery for patients with moyamoya disease.⁶⁸

1. Ischemic disease: Bypass surgery is indicated for patients with the following symptoms:
 - (a) Repeated clinical symptoms due to apparent cerebral ischemia
 - (b) Decreased regional cerebral blood flow, vascular response and perfusion reserve, based on the findings of a cerebral circulation and metabolism study
2. Hemorrhagic disease: The benefits of bypass surgery for the prevention of rebleeding are unclear.

SURGICAL TECHNIQUES

1. Direct revascularization
 - (a) Low-flow bypass
 - STA-MCA bypass
 - The first STA-MCA bypass for moyamoya disease was done by Yaşargil in 1972.²⁰⁶
 - Occipital artery bypass
 - For patients with a small STA, occipital artery (OA)-MCA bypass²⁰⁷ or OA-PCA anastomoses²⁰⁸ are alternatives.
 - (b) High-flow bypass
 - Vein graft bypass²⁰⁹
2. Indirect revascularization: An exhaustive listing of published indirect procedures are available in Matsushima (1999)⁸⁹ The most commonly used procedures include the following²¹⁰.
 - (a) Encephalo-myo-synangiosis (EMS): A temporalis muscle flap is applied directly to the surface of the brain.
 - (b) Encephalo-duro-arterio-synangiosis (EDAS): The STA is sutured to the open dura.
 - (c) Encephalo-duro-arterio-myo-synangiosis (EDAMS): Temporalis muscle and the STA are applied to the surface of the brain.
3. Combined direct and indirect revascularization:
 - (a) STA-MCA with EMS
 - (b) STA-MCA with EDAMS
4. Selection of surgical technique:
 - (a) The younger the patient, the more likely indirect revascularization will be successful.²¹¹ With advancing age, the ability to develop collaterals declines, presumably because of declining angiogenic or arteriogenic factor availability or responsiveness.^{59, 62}
 - In a report of indirect procedures done in adults with moyamoya disease, patients aged 20–29 had good results – similar to pediatric patients – but patients aged >30 had moderate or poor indirect revascularization results.²¹¹ Patients of age >40 had the worst angiographic results from indirect procedures, leading the authors to conclude that direct procedures (or combined procedures) should be the main treatment option for patients of age >40.
 - (b) Synangiosis procedures work best when there is some degree of hemodynamic stress, as demonstrated by CBF imaging (e.g., PET, or xenon CT or SPECT with acetazolamide challenge).¹⁰¹
 - (c) Elevated CSF bFGF levels may predict the extent of angiogenesis to be expected with indirect revascularization.⁵⁹
 - (d) Patients with spontaneous transdural collateral vessels (*vault collaterals*) should not be considered for synangiosis.⁸⁴
5. Surgical results
 - (a) Pediatric moyamoya disease: A review of 57 studies of revascularization surgery for pediatric moyamoya found the following²¹⁰:
 - Indirect procedures are the most commonly reported (73% of cases) and combined direct and indirect was next (23%).
 - In 87% of cases the patients were reported to derive symptomatic benefit.
 - Overall rates of perioperative stroke and reversible deficit were 4.4 and 6.1%, respectively.

- (b) Adult ischemic moyamoya: Several series have reported clinical improvement in most adults undergoing revascularization procedures.^{84, 98, 204, 211, 212}
- Two North American retrospective series have reported a benefit with revascularization:
 - Chiu⁸⁴: The 5-year risk of ipsilateral stroke after indirect revascularization was 15%, compared with 20% for medical treatment.
 - Hallemeier²⁰⁴: The 5-year risk of perioperative or subsequent ipsilateral stroke or death for surgical patients was 17%, compared with 65% for patients not having surgery.
- (c) Hemorrhagic moyamoya disease. The value of revascularization in preventing rehemorrhage in patients with hemorrhagic moyamoya disease is not clear. Several reports have not found a benefit.^{108, 212, 213}
- Revascularization has been reported to decrease hemodynamic stress and lead to the obliteration of peripheral intracranial aneurysms.²¹⁴

19.2.8.3. Intracranial angioplasty

A single case of intracranial angioplasty for ischemic moyamoya disease has been reported.⁴⁰ Angioplasty was done of the distal ICA and M1 segment; the patient's symptoms resolved and follow-up angiograph 2 years later showed no progression of the stenosis and a reduction in the moyamoya vessel pattern.

19.2.8.4. Pregnancy and moyamoya

A review of 30 reported cases of patients with moyamoya disease and pregnancy found that good outcomes were achieved for both mother and child in all but one case.²¹⁵ The one poor outcome occurred in a woman with hemorrhagic moyamoya disease. The authors concluded that pregnancy can be managed successfully in patients with moyamoya disease. Furthermore, they surmised that the presence of moyamoya disease should not determine the method of delivery, as successful deliveries have been obtained with both vaginal delivery and cesarean section.

19.3. References

1. Wityk RJ, Lehman D, Klag M, Coresh J, Ahn H, Litt B. Race and sex differences in the distribution of cerebral atherosclerosis. *Stroke* 1996;27(11):1974–80.
2. Sacco RL, Roberts JK, Boden-Albala B, et al. Race-ethnicity and determinants of carotid atherosclerosis in a multiethnic population. The Northern Manhattan Stroke Study. *Stroke* 1997;28(5):929–35.
3. Intracranial angioplasty and stenting for cerebral atherosclerosis: a position statement of the American Society of Interventional and Therapeutic Neuroradiology, Society of Interventional Radiology, and the American Society of Neuroradiology. *AJNR Am J Neuroradiol* 2005;26(9):2323–7.
4. Chimowitz MI, Lynn MJ, Howlett-Smith H, et al. Comparison of warfarin and aspirin for symptomatic intracranial arterial stenosis. *N Engl J Med* 2005;352(13):1305–16.
5. Caplan LR, Gorelick PB, Hier DB. Race, sex and occlusive cerebrovascular disease: a review. *Stroke* 1986;17(4):648–55.
6. Gorelick PB, Caplan LR, Hier DB, et al. Racial differences in the distribution of posterior circulation occlusive disease. *Stroke* 1985;16(5):785–90.
7. Bogousslavsky J, Barnett HJ, Fox AJ, Hachinski VC, Taylor W. Atherosclerotic disease of the middle cerebral artery. *Stroke* 1986;17(6):1112–20.
8. Wong KS, Huang YN, Gao S, Lam WW, Chan YL, Kay R. Intracranial stenosis in Chinese patients with acute stroke. *Neurology* 1998;50(3):812–13.
9. Kremer C, Schaettin T, Georgiadis D, Baumgartner RW. Prognosis of asymptomatic stenosis of the middle cerebral artery. *J Neurol Neurosurg Psychiatry* 2004;75(9):1300–3.
10. Akins PT, Pilgram TK, Cross DT, III, Moran CJ. Natural history of stenosis from intracranial atherosclerosis by serial angiography. *Stroke* 1998;29(2):433–8.
11. Wilson PW. Estimating cardiovascular disease risk and the metabolic syndrome: a Framingham view. *Endocrinol Metab Clin North Am* 2004;33(3):467–81, v.
12. Ford ES, Giles WH, Dietz WH. Prevalence of the metabolic syndrome among US adults: findings from the third National Health and Nutrition Examination Survey. *JAMA* 2002;287(3):356–9.
13. Naritomi H, Sawada T, Kuriyama Y, Kinugawa H, Kaneko T, Takamiya M. Effect of chronic middle cerebral artery stenosis on the local cerebral hemodynamics. *Stroke* 1985;16(2):214–19.
14. Derdeyn CP, Grubb RL, Jr., Powers WJ. Cerebral hemodynamic impairment: methods of measurement and association with stroke risk. *Neurology* 1999;53(2):251–259.
15. Constantinides P. Pathogenesis of cerebral artery thrombosis in man. *Arch Pathol* 1967;83(5):422–8.
16. Craig DR, Meguro K, Watridge C, Robertson JT, Barnett HJ, Fox AJ. Intracranial internal carotid artery stenosis. *Stroke* 1982;13(6):825–8.
17. Caplan LR. Intracranial branch atheromatous disease: a neglected, understudied, and underused concept. *Neurology* 1989;39(9):1246–50.

18. Awad I, Furlan AJ, Little JR. Changes in intracranial stenotic lesions after extracranial-intracranial bypass surgery. *J Neurosurg* 1984;60(4):771-6.
19. Arenillas JF, Molina CA, Montaner J, Abilleira S, Gonzalez-Sanchez MA, Alvarez-Sabin J. Progression and clinical recurrence of symptomatic middle cerebral artery stenosis: a long-term follow-up transcranial Doppler ultrasound study. *Stroke* 2001;32(12):2898-904.
20. Failure of extracranial-intracranial arterial bypass to reduce the risk of ischemic stroke. Results of an international randomized trial. The EC/IC Bypass Study Group. *N Engl J Med* 1985;313(19):1191-200.
21. Gao S, Wong KS, Hansberg T, Lam WW, Droste DW, Ringelstein EB. Microembolic signal predicts recurrent cerebral ischemic events in acute stroke patients with middle cerebral artery stenosis. *Stroke* 2004;35(12):2832-6.
22. Mazighi M, Tanasescu R, Ducrocq X, et al. Prospective study of symptomatic atherothrombotic intracranial stenoses: the GESICA Study. *Neurology* 2006;66(8):1187-91.
23. Komotar RJ, Wilson DA, Mocco J, et al. Natural history of intracranial atherosclerosis: a critical review. *Neurosurgery* 2006;58(4):595-601; discussion 595-601.
24. Chimowitz MI, Kokkinos J, Strong J, et al. The warfarin-aspirin symptomatic intracranial disease study. *Neurology* 1995;45(8):1488-93.
25. Samuels OB, Joseph GJ, Lynn MJ, Smith HA, Chimowitz MI. A standardized method for measuring intracranial arterial stenosis. *AJNR Am J Neuroradiol* 2000;21(4):643-6.
26. Kasner SE, Lynn MJ, Chimowitz MI, et al. Warfarin vs aspirin for symptomatic intracranial stenosis: subgroup analyses from WASID. *Neurology* 2006;67(7):1275-8.
27. Kasner SE, Chimowitz MI, Lynn MJ, et al. Predictors of ischemic stroke in the territory of a symptomatic intracranial arterial stenosis. *Circulation* 2006;113(4):555-63.
28. Diener HC, Cunha L, Forbes C, Sivenius J, Smets P, Lowenthal A. European Stroke Prevention Study. II. Dipyridamole and acetylsalicylic acid in the secondary prevention of stroke. *J Neurol Sci* 1996;143(1-2):1-13.
29. Amarencu P, Bogousslavsky J, Callahan A, III, et al. High-dose atorvastatin after stroke or transient ischemic attack. *N Engl J Med* 2006;355(6):549-59.
30. Mori T, Mori K, Fukuoka M, Arisawa M, Honda S. Percutaneous transluminal cerebral angioplasty: serial angiographic follow-up after successful dilatation. *Neuroradiology* 1997;39(2):111-16.
31. Mori T, Fukuoka M, Kazita K, Mori K. Follow-up study after intracranial percutaneous transluminal cerebral balloon angioplasty. *AJNR Am J Neuroradiol* 1998;19(8):1525-33.
32. Gress DR, Smith WS, Dowd CF, Van Halbach V, Finley RJ, Higashida RT. Angioplasty for intracranial symptomatic vertebrobasilar ischemia. *Neurosurgery* 2002;51(1):23-7; discussion 7-9.
33. Wojak JC, Dunlap DC, Hargrave KR, DeAlvarez LA, Culbertson HS, Connors JJ, III. Intracranial angioplasty and stenting: long-term results from a single center. *AJNR Am J Neuroradiol* 2006;27(9):1882-92.
34. Marks MP, Wojak JC, Al-Ali F, et al. Angioplasty for symptomatic intracranial stenosis: clinical outcome. *Stroke* 2006;37(4):1016-20.
35. Yu W, Smith WS, Singh V, et al. Long-term outcome of endovascular stenting for symptomatic basilar artery stenosis. *Neurology* 2005;64(6):1055-7.
36. Bose A, Hartmann M, Henkes H, et al. A novel, self-expanding, nitinol stent in medically refractory intracranial atherosclerotic stenoses: the Wingspan study. *Stroke* 2007;38(5):1531-7.
37. The SSL. Stenting of symptomatic atherosclerotic lesions in the vertebral or intracranial arteries (SSYLVA): study results. *Stroke* 2004;35(6):1388-92.
38. Cruz-Flores S, Diamond A. Angioplasty for intracranial artery stenosis. *Cochrane Database Syst Rev* 2006;3:CD004133.
39. Matsushima Y. Moyamoya disease. In: Albright L, Pollack I, Adelson D, eds. Principles and practice of pediatric neurosurgery. New York: Thieme Medical Publishers; 1999:1053-69.
40. Rodriguez GI, Kirmani JF, Erzeddine MA, Qureshi AI. Primary percutaneous transluminal angioplasty for early moyamoya disease. *J Neuroimaging* 2007;17(1):48-53.
41. Wakai K, Tamakoshi A, Ikezaki K, et al. Epidemiological features of moyamoya disease in Japan: findings from a nationwide survey. *Clin Neurol Neurosurg* 1997;99 Suppl 2:S1-S5.
42. Fukui M. Current state of study on moyamoya disease in Japan. *Surg Neurol* 1997;47(2):138-43.
43. Ikezaki K, Han DH, Dmsci DH, Kawano T, Kimukawa N, Fukui M. A clinical comparison of definite moyamoya disease between South Korea and Japan. *Stroke* 1997;28(12):2513-17.
44. Cheng MK. A review of cerebrovascular surgery in the People's Republic of China. *Stroke* 1982;13(2):249-55.
45. Matsushima Y, Qian L, Aoyagi M. Comparison of moyamoya disease in Japan and moyamoya disease (or syndrome) in the People's Republic of China. *Clin Neurol Neurosurg* 1997;99 Suppl 2:S19-S22.
46. Uchino K, Johnston SC, Becker KJ, Tirschwell DL. Moyamoya disease in Washington State and California. *Neurology* 2005;65(6):956-8.
47. Graham JF, Matoba A. A survey of moyamoya disease in Hawaii. *Clin Neurol Neurosurg* 1997;99 (Suppl 2):S31-S35.
48. Yonekawa Y, Ogata N, Kaku Y, Taub E, Imhof H-G. Moyamoya disease in Europe, past and present status. *Clin Neurol Neurosurg* 1997;99 (Suppl 2):S58-S60.
49. Nyary I. Moyamoya disease: the Hungarian experience. In: International Symposium on Moyamoya Disease, Fukuoka; 1996.
50. Yamashita M, Oka K, Tanaka K. Histopathology of the brain vascular network in moyamoya disease. *Stroke* 1983;14(1):50-8.
51. Hosoda Y, Ikeda E, Hirose S. Histopathological studies on spontaneous occlusion of the circle of Willis (cerebrovascular moyamoya disease). *Clin Neurol Neurosurg* 1997;99 Suppl 2:S203-S208.
52. Takagi Y, Kikuta K, Nozaki K, Hashimoto N. Histological features of middle cerebral arteries from patients treated for Moyamoya disease. *Neurol Med Chir* 2007;47(1):1-4.
53. Takakawa Y, Umezawa T, Ueno Y, Sawada T, Kobayashi M. Pathological and immunohistochemical findings of an autopsy case of adult moyamoya disease. *Neuropathology* 2004;24(3):236-42.
54. Li B, Wang ZC, Sun YL, Hu Y. Ultrastructural study of cerebral arteries in Moyamoya disease. *Chin Med J* 1992;105(11):923-8.
55. Aoyagi M, Fukui N, Yamamoto M, Nakagawa K, Matsushima Y, Yamamoto K. Early development of intimal thickening in superficial temporal arteries in patients with moyamoya disease. *Stroke* 1996;27(10):1750-4.
56. Ikeda E, Hosoda Y. Distribution of thrombotic lesions in the cerebral arteries in spontaneous occlusion of the circle of Willis: cerebrovascular moyamoya disease. *Clin Neuropathol* 1993;12(1):44-8.
57. Aoyagi M, Fukui N, Sakamoto H, et al. Altered cellular responses to serum mitogens, including platelet-derived growth factor, in cultured smooth muscle cells derived from arteries of patients with moyamoya disease. *J Cell Physiol* 1991;147(2):191-8.
58. Takahashi A, Sawamura Y, Houkin K, Kamiyama H, Abe H. The cerebrospinal fluid in patients with moyamoya disease (spontaneous occlusion of the circle of Willis) contains high level of basic fibroblast growth factor. *Neurosci Lett* 1993;160(2):214-16.
59. Malek AM, Connors S, Robertson RL, Folkman J, Scott RM. Elevation of cerebrospinal fluid levels of basic fibroblast growth factor in moyamoya and central nervous system disorders. *Pediatr Neurol* 1997;27(4):182-9.
60. Hoshimaru M, Takahashi JA, Kikuchi H, Nagata I, Hatanaka M. Possible roles of basic fibroblast growth factor in the pathogenesis of moyamoya disease: an immunohistochemical study. *J Neurosurg* 1991;75(2):267-70.
61. Hosoda Y, Hirose S, Kameyama K. Histopathological and immunohistochemical study of growth factor in spontaneous occlusion of the circle of Willis. In: Fukui M, ed. Annual report of the research committee on spontaneous

- occlusion of the circle of Willis (Moyamoya disease) 1993. Japan: Ministry of Health and Welfare; 1994:25-8.
62. Yoshimoto T, Houkin K, Takahashi A, Abe H. Angiogenic factors in moyamoya disease. *Stroke* 1996;27(12):2160-5.
 63. Hojo M, Hoshimaru M, Miyamoto S, et al. Role of transforming growth factor-beta1 in the pathogenesis of moyamoya disease. *J Neurosurg* 1998;89(4):623-9.
 64. Nanba R, Kuroda S, Ishikawa T, Houkin K, Iwasaki Y. Increased expression of hepatocyte growth factor in cerebrospinal fluid and intracranial artery in moyamoya disease. *Stroke* 2004;35(12):2837-42.
 65. Kang HS, Kim SK, Cho BK, Kim YY, Hwang YS, Wang KC. Single nucleotide polymorphisms of tissue inhibitor of metalloproteinase genes in familial moyamoya disease. *Neurosurgery* 2006;58(6):1074-80; discussion 80.
 66. Yamamoto M, Aoyagi M, Fukui N, Matsushima Y, Yamamoto K. Increase in prostaglandin E(2) production by interleukin-1beta in arterial smooth muscle cells derived from patients with moyamoya disease. *Circ Res* 1999;85(10):912-18.
 67. Tanigawara T, Yamada H, Sakai N, Andoh T, Deguchi K, Iwamura M. Studies on cytomegalovirus and Epstein-Barr virus infection in moyamoya disease. *Clin Neurol Neurosurg* 1997;99 Suppl 2:S225-S228.
 68. Fukui M. Guidelines for the diagnosis and treatment of spontaneous occlusion of the circle of Willis ('moyamoya' disease). Research Committee on Spontaneous Occlusion of the Circle of Willis (Moyamoya Disease) of the Ministry of Health and Welfare, Japan. *Clin Neurol Neurosurg* 1997;99 Suppl 2:S238-S240.
 69. Handa J, Nakano Y, Okuno T, Komuro H, Hojyo H, Handa H. Computerized tomography in Moyamoya syndrome. *Surg Neurol* 1977;7(5):315-19.
 70. Robertson RL, Chavali RV, Robson CD, et al. Neurologic complications of cerebral angiography in childhood moyamoya syndrome. *Pediatr Radiol* 1998;28(11):824-9.
 71. Suzuki J, Takaku A. Cerebrovascular "moyamoya" disease. Disease showing abnormal net-like vessels in base of brain. *Arch Neurol* 1969;20(3):288-99.
 72. Kuroda S, Hashimoto N, Yoshimoto T, Iwasaki Y. Radiological findings, clinical course, and outcome in asymptomatic moyamoya disease: results of multicenter survey in Japan. *Stroke* 2007;38(5):1430-5.
 73. Yamada I, Himeno Y, Suzuki S, Matsushima Y. Posterior circulation in moyamoya disease: angiographic study. *Radiology* 1995;197(1):239-46.
 74. Komiya M, Nishikawa M, Yasui T, Kitano S, Sakamoto H, Fu Y. Steno-occlusive changes in the external carotid system in moyamoya disease. *Acta Neurochir (Wien)* 2000;142(4):421-4.
 75. Hoshimaru M, Kikuchi H. Involvement of the external carotid arteries in moyamoya disease: neuroradiological evaluation of 66 patients. *Neurosurgery* 1992;31(3):398-400.
 76. Suzuki J, Kodama N. Cerebrovascular "Moyamoya" disease. II. Collateral routes to forebrain via ethmoid sinus and superior nasal meatus. *Angiology* 1971;22(4):223-36.
 77. Kodama N, Fujiwara S, Horie Y, Kayama T, Suzuki J. [Transdural anastomosis in moyamoya disease - vault moyamoya (author's trans)]. *No Shinkei Geka* 1980;8(8):729-37.
 78. Miyamoto S, Kikuchi H, Karasawa J, Nagata I, Ikota T, Takeuchi S. Study of the posterior circulation in moyamoya disease. Clinical and neuroradiological evaluation. *J Neurosurg* 1984;61(6):1032-7.
 79. Piao R, Oku N, Kitagawa K, et al. Cerebral hemodynamics and metabolism in adult moyamoya disease: comparison of angiographic collateral circulation. *Ann Nucl Med* 2004;18(2):115-21.
 80. Wang MY, Steinberg GK. Rapid and near-complete resolution of moyamoya vessels in a patient with moyamoya disease treated with superficial temporal artery-middle cerebral artery bypass. *Pediatr Neurosurg* 1996;24(3):145-50.
 81. Yabumoto M, Funahashi K, Fujii T, Hayashi S, Komai N. Moyamoya disease associated with intracranial aneurysms. *Surg Neurol* 1983;20(1):20-4.
 82. Borota L, Marinkovic S, Bajic R, Kovacevic M. Intracranial aneurysms associated with moyamoya disease. *Neurol Med Chir* 1996;36(12):860-4.
 83. Yonekawa Y, Kahn N. Moyamoya disease. *Adv Neurol* 2003;92:113-18.
 84. Chiu D, Shedden P, Bratina P, Grotta JC. Clinical features of moyamoya disease in the United States. *Stroke* 1998;29(7):1347-51.
 85. Yonekawa Y, Taub E. Moyamoya disease: status 1998. *Neurologist* 1999;5:13-23.
 86. Komiya M, Nakajima H, Nishikawa M, et al. High incidence of persistent primitive arteries in moyamoya and quasi-moyamoya diseases. *Neurol Med Chir* 1999;39(6):416-20; discussion 20-2.
 87. Yamada I, Suzuki S, Matsushima Y. Moyamoya disease: comparison of assessment with MR angiography and MR imaging versus conventional angiography. *Radiology* 1995;196(1):211-18.
 88. Yamada I, Suzuki S, Matsushima Y. Moyamoya disease: diagnostic accuracy of MRI. *Neuroradiology* 1995;37(5):356-61.
 89. Hasuo K, Mihara F, Matsushima T. MRI and MR angiography in moyamoya disease. *J Magn Reson Imaging* 1998;8(4):762-6.
 90. Yoon H-K, Shin H-J, Chang YW. "Ivy Sign" in childhood moyamoya disease: depiction on FLAIR and contrast-enhanced T1-weighted MR images. *Radiology* 2002;223(2):384-9.
 91. Ohta T, Tanaka H, Kuroiwa T. Diffuse leptomeningeal enhancement, "ivy sign," in magnetic resonance images of moyamoya disease in childhood: case report. *Neurosurgery* 1995;37(5):1009-12.
 92. Maeda M, Tsuchida C. "Ivy sign" on fluid-attenuated inversion-recovery images in childhood moyamoya disease. *AJNR Am J Neuroradiol* 1999;20(10):1836-8.
 93. Iwama T, Akiyama Y, Morimoto M, Kojima A, Hayashida K. Comparison of positron emission tomography study results of cerebral hemodynamics in patients with bleeding- and ischemic-type moyamoya disease. *Neurosurg Focus* 1998;5(5):e3.
 94. McAuley DJ, Poskitt K, Steinbok P. Predicting stroke risk in pediatric moyamoya disease with xenon-enhanced computed tomography. *Neurosurgery* 2004;55(2):327-32; discussion 32-3.
 95. Ogawa A, Nakamura N, Yoshimoto T, Suzuki J. Cerebral blood flow in moyamoya disease. Part 2: autoregulation and CO2 response. *Acta Neurochir* 1990;105(3-4):107-11.
 96. Ogawa A, Yoshimoto T, Suzuki J, Sakurai Y. Cerebral blood flow in moyamoya disease. Part 1: correlation with age and regional distribution. *Acta Neurochir* 1990;105(1-2):30-4.
 97. Kohno K, Oka Y, Kohno S, Ohta S, Kumon Y, Sakaki S. Cerebral blood flow measurement as an indicator for an indirect revascularization procedure for adult patients with moyamoya disease. *Neurosurgery* 1998;42(4):752-7; discussion 7-8.
 98. Han DH, Nam DH, Oh CW. Moyamoya disease in adults: characteristics of clinical presentation and outcome after encephalo-duro-arterio-synangiosis. *Clin Neurol Neurosurg* 1997;99 Suppl 2:S151-S155.
 99. Honda M, Ezaki Y, Kitagawa N, Tsutsumi K, Ogawa Y, Nagata I. Quantification of the regional cerebral blood flow and vascular reserve in moyamoya disease using split-dose iodoamphetamine I 123 single-photon emission computed tomography. *Surg Neurol* 2006;66(2):155-9; discussion 9.
 100. Nariai T, Matsushima Y, Imae S, et al. Severe haemodynamic stress in selected subtypes of patients with moyamoya disease: a positron emission tomography study. *J Neurol Neurosurg Psychiatry* 2005;76(5):663-9.
 101. Nariai T, Suzuki R, Matsushima Y, et al. Surgically induced angiogenesis to compensate for hemodynamic cerebral ischemia. *Stroke* 1994;25(5):1014-21.
 102. Kodama N, Aoki Y, Hiraga H, Wada T, Suzuki J. Electroencephalographic findings in children with moyamoya disease. *Arch Neurol* 1979;36(1):16-19.
 103. Qiao F, Kuroda S, Kamada K, Houkin K, Iwasaki Y. Source localization of the re-build up phenomenon in pediatric moyamoya disease - a dipole distribution analysis using MEG and SPECT. *Childs Nerv Syst* 2005;19(10-11):760-4.

104. Kuroda S, Kamiyama H, Isobe M, Houkin K, Abe H, Mitsumori K. Cerebral hemodynamics and "re-build-up" phenomenon on electroencephalogram in children with moyamoya disease. *Childs Nerv Syst* 1995;11(4):214-19.
105. Matsushima Y, Aoyagi M, Niimi Y, Masaoka H, Ohno K. Symptoms and their pattern of progression in childhood moyamoya disease. *Brain Dev* 1990;12(6):784-9.
106. Moritake K, Handa H, Yonekawa Y, Taki W, Okuno T. [Follow-up study on the relationship between age at onset of illness and outcome in patients with moyamoya disease]. *No Shinkei Geka* 1986;14(8):957-63.
107. Iwama T, Morimoto M, Hashimoto N, Goto Y, Todaka T, Sawada M. Mechanism of intracranial rebleeding in moyamoya disease. *Clin Neurol Neurosurg* 1997;99 Suppl 2:S187-S190.
108. Kobayashi E, Saeki N, Oishi H, Hirai S, Yamaura A. Long-term natural history of hemorrhagic moyamoya disease in 42 patients. *J Neurosurg* 2000;93(6):976-80.
109. Ikezaki K, Inamura T, Kawano T, Fukui M. Clinical features of probable moyamoya disease in Japan. *Clin Neurol Neurosurg* 1997;99 Suppl 2:S173-S177.
110. Seol HJ, Wang KC, Kim SK, et al. Unilateral (probable) moyamoya disease: long-term follow-up of seven cases. *Childs Nerv Syst* 2006;22(2):145-50.
111. Kelly ME, Bell-Stephens TE, Marks MP, Do HM, Steinberg GK. Progression of unilateral moyamoya disease: a clinical series. *Cerebrovasc Dis* 2006;22(2-3):109-15.
112. Houkin K, Abe H, Yoshimoto T, Takahashi A. Is "unilateral" moyamoya disease different from moyamoya disease? *J Neurosurg* 1996;85(5):772-6.
113. Kusaka N, Tamiya T, Adachi Y, et al. Adult unilateral moyamoya disease with familial occurrence in two definite cases: a case report and review of the literature. *Neurosurg Rev* 2006;29(1):82-7.
114. Nanba R, Kuroda S, Tada M, Ishikawa T, Houkin K, Iwasaki Y. Clinical features of familial moyamoya disease. *Childs Nerv Syst* 2006;22(3):258-62.
115. Kanai N. A genetic study of spontaneous occlusion of the circle of Willis (moyamoya disease). *J Tokyo Women Med Univ* 1992;62:1227-58.
116. Kitahara T, Ariga N, Yamaura A, Makino H, Maki Y. Familial occurrence of moyamoya disease: report of three Japanese families. *J Neurol Neurosurg Psychiatry* 1979;42(3):208-14.
117. Yamada H, Nakamura S, Kageyama N. Moyamoya disease in monozygotic twins: case report. *J Neurosurg* 1980;53(1):109-12.
118. Yamauchi T, Houkin K, Tada M, Abe H. Familial occurrence of moyamoya disease. *Clin Neurol Neurosurg* 1997;99 Suppl 2:S162-S167.
119. Mineharu Y, Takenaka K, Yamakawa H, et al. Inheritance pattern of familial moyamoya disease: autosomal dominant mode and genomic imprinting. *J Neurol Neurosurg Psychiatry* 2006;77(9):1025-9.
120. Ikeda H, Sasaki T, Yoshimoto T, Fukui M, Arinami T. Mapping of a familial moyamoya disease gene to chromosome 3p24.2-p26. *Am J Hum Genet* 1999;64(2):533-7.
121. Yamauchi T, Tada M, Houkin K, et al. Linkage of familial moyamoya disease (spontaneous occlusion of the circle of Willis) to chromosome 17q25. *Stroke* 2000;31(4):930-5.
122. Inoue TK, Ikezaki K, Sasazuki T, Matsushima T, Fukui M. Linkage analysis of moyamoya disease on chromosome 6. *J Child Neurol* 2000;15(3):179-82.
123. Sakurai K, Horiuchi Y, Ikeda H, et al. A novel susceptibility locus for moyamoya disease on chromosome 8q23. *J Hum Genet* 2004;49(5):278-81.
124. Lee CM, Lee SY, Ryu SH, Lee SW, Park KW, Chung WT. Systemic lupus erythematosus associated with familial moyamoya disease. *Korean J Intern Med* 2003;18(4):244-7.
125. Akutsu H, Sonobe M, Sugita K, Nakai Y, Matsumura A. Familial association of basilar bifurcation aneurysm and moyamoya disease - four case reports. *Neurol Med Chir (Tokyo)* 2003;43(9):435-8.
126. Houkin K, Tanaka N, Takahashi A, Kamiyama H, Abe H, Kajii N. Familial occurrence of moyamoya disease. Magnetic resonance angiography as a screening test for high-risk subjects. *Childs Nerv Syst* 1994;10(7):421-5.
127. Im SH, Oh CW, Kwon OK, Kim JE, Han DH. Moyamoya disease associated with Graves disease: special considerations regarding clinical significance and management. *J Neurosurg* 2005;102(6):1013-17.
128. Sasaki T, Nogawa S, Amano T. Co-morbidity of moyamoya disease with Graves' disease. Report of three cases and a review of the literature. *Intern Med* 2006;45(9):649-53.
129. Nagahiro S, Mantani A, Yamada K, Ushio Y. Multiple cerebral arterial occlusions in a young patient with Sjogren's syndrome: case report. *Neurosurgery* 1996;38(3):592-5; discussion 5.
130. Matsuki Y, Kawakami M, Ishizuka T, et al. SLE and Sjogren's syndrome associated with unilateral moyamoya vessels in cerebral arteries. *Scand J Rheumatol* 1997;26(5):392-4.
131. Booth F, Yanofsky R, Ross IB, Lawrence P, Oen K. Primary antiphospholipid syndrome with moyamoya-like vascular changes. *Pediatr Neurosurg* 1999;31(1):45-8.
132. Shuja-Ud-Din MA, Ahamed SA, Baidas G, Naem M. Moyamoya syndrome with primary antiphospholipid syndrome. *Med Princ Pract* 2006;15(3):238-41.
133. El Ramahi KM, Al Rayes HM. Systemic lupus erythematosus associated with moyamoya syndrome. *Lupus* 2000;9(8):632-6.
134. Czartoski T, Hallam D, Lacy JM, Chun MR, Becker K. Postinfectious vasculopathy with evolution to moyamoya syndrome. *J Neurol Neurosurg Psychiatry* 2005;76(2):256-9.
135. Mathew NT, Abraham J, Chandy J. Cerebral angiographic features in tuberculous meningitis. *Neurology* 1970;20(10):1015-23.
136. Nakayama Y, Tanaka A, Nagasaka S, Ikui H. [Intracerebral hemorrhage in a patient with moyamoya phenomenon caused by tuberculous arteritis: a case report]. *No Shinkei Geka* 1999;27(8):751-5.
137. Hsiung GY, Sotero de Menezes M. Moyamoya syndrome in a patient with congenital human immunodeficiency virus infection. *J Child Neurol* 1999;14(4):268-70.
138. Dobson SR, Holden KR, Nietert PJ, et al. Moyamoya syndrome in childhood sickle cell disease: a predictive factor for recurrent cerebrovascular events. *Blood* 2002;99(9):3144-50.
139. Tomura N, Inugami A, Higano S, et al. [Cases similar to cerebrovascular moyamoya disease - investigation by angiography and computed tomography]. *No To Shinkei* 1988;40(10):905-12.
140. Cohen N, Berant M, Simon J. Moyamoya and Fanconi's anemia. *Pediatrics* 1980;65(4):804-5.
141. Pavlakis SG, Verlander PC, Gould RJ, Strimling BC, Auerbach AD. Fanconi anemia and moyamoya: evidence for an association. *Neurology* 1995;45(5):998-1000.
142. Tokunaga Y, Ohga S, Suita S, Matsushima T, Hara T. Moyamoya syndrome with spherocytosis: effect of splenectomy on strokes. *Pediatr Neurol* 2001;25(1):75-7.
143. Sanefuji M, Ohga S, Kira R, Yoshiura T, Torisu H, Hara T. Moyamoya syndrome in a splenectomized patient with beta-thalassemia intermedia. *J Child Neurol* 2006;21(1):75-7.
144. Matsuda M, Enomoto T, Yanaka K, Nose T. Moyamoya disease associated with hemophilia A. Case report. *Pediatr Neurosurg* 2002;36(3):157-60.
145. Hiyama H, Kusano R, Muragaki Y, Miura N. [Moyamoya disease associated with thrombotic thrombocytopenic purpura (TTP)]. *No Shinkei Geka* 1994;22(6):567-72.
146. Brockmann K, Stolpe S, Fels C, Khan N, Kulozik AE, Pekrun A. Moyamoya syndrome associated with hemolytic anemia due to Hb Alesha. *J Pediatr Hematol Oncol* 2005;27(8):436-40.
147. Korbliht LI, Cocorullo S, Miranda C, Lylyk P, Heller PG, Molinas FC. Moyamoya syndrome in an adolescent with essential thrombocythemia: successful intracranial carotid stent placement. *Stroke* 2005;36(8):E71-3.
148. Kikuchi A, Maeda M, Hanada R, et al. Moyamoya syndrome following childhood acute lymphoblastic leukemia. *Pediatr Blood Cancer* 2007;48(3):268-72.
149. Andeejani AM, Salih MA, Kolawole T, et al. Moyamoya syndrome with unusual angiographic findings and protein C deficiency: review of the literature. *J Neurol Sci* 1998;159(1):11-16.

150. Akgun D, Yilmaz S, Senbil N, Aslan B, Gurer YY. Moyamoya syndrome with protein S deficiency. *Eur J Paediatr Neurol* 2000;4(4):185-8.
151. Kikuta K, Miyamoto S, Kataoka H, et al. An adult case of moyamoya syndrome that developed dural sinus thrombosis associated with protein C deficiency: case report and literature review. *Surg Neurol* 2005;63(5):480-4; discussion 4.
152. Cheong PL, Lee WT, Liu HM, Lin KH. Moyamoya syndrome with inherited proteins C and S deficiency: report of one case. *Acta Paediatr Taiwan* 2005;46(1):31-4.
153. Dhopes VP, Dunn DP, Schick P. Moyamoya and Hageman factor (factor XII) deficiency in a black adult. *Arch Neurol* 1978;35(6):396.
154. Likavcan M, Benko J, Papiernikova E, Lindnerova L. [Moyamoya syndrome with hyperlipoproteinemia type IIa]. *Cesk Neurol Neurochir* 1979;42(1):49-53.
155. Goutieres F, Bourgeois M, Trioche P, Demelier JF, Odievre M, Labrune P. Moyamoya disease in a child with glycogen storage disease type Ia. *Neuropediatrics* 1997;28(2):133-4.
156. Meyer S, Zanardo L, Kaminski WE, et al. Elastosis perforans serpiginosa-like pseudoxanthoma elasticum in a child with severe moyamoya disease. *Br J Dermatol* 2005;153(2):431-4.
157. Squizzato A, Gerdes VE, Brandjes DP, Buller HR, Stam J. Thyroid diseases and cerebrovascular disease. *Stroke* 2005;36(10):2302-10.
158. Cerrato P, Grasso M, Lentini A, et al. Atherosclerotic adult Moyamoya disease in a patient with hyperhomocysteinemia. *Neurol Sci* 2007;28(1):45-7.
159. Cramer SC, Robertson RL, Dooling EC, Scott RM. Moyamoya and Down syndrome. Clinical and radiological features. *Stroke* 1996;27(11):2131-5.
160. Kwong KL, Wong YC. Moyamoya disease in a child with neurofibromatosis type-1. *J Paediatr Child Health* 1999;35(1):108-9.
161. Inoue T, Matsushima T, Fujii K, Fukui M, Hasuo K, Matsuo H. [Akin moyamoya disease in children]. *No Shinkei Geka* 1993;21(1):59-65.
162. Spengos K, Kosmidou-Aravidou Z, Tsigoulis G, Vassilopoulou S, Grigori-Kostaraki P, Zis V. Moyamoya syndrome in a Caucasian woman with Turner's syndrome. *Eur J Neurol* 2006;13(10):e7-e8.
163. Kawai M, Nishikawa T, Tanaka M, et al. An autopsied case of Williams syndrome complicated by moyamoya disease. *Acta Paediatr Jpn* 1993;35(1):63-7.
164. Imaizumi M, Nakada T, Yoneda S, Takano T, Hasegawa K, Abe H. Tuberos scleriosis with moyamoya disease. Case report. *Med J Osaka Univ* 1978;28(3-4):345-53.
165. Albayram S, Kirzilkilic O, Yilmaz H, Tuysuz B, Kocer N, Islak C. Abnormalities in the cerebral arterial system in osteogenesis imperfecta. *AJNR Am J Neuroradiol* 2003;24(4):748-50.
166. Ganesan V, Kirkham FJ. Noonan syndrome and moyamoya. *Pediatr Neurol* 1997;16(3):256-8.
167. Yamashita Y, Kusaga A, Koga Y, Nagamitsu S, Matsuishi T. Noonan syndrome, moyamoya-like vascular changes, and antiphospholipid syndrome. *Pediatr Neurol* 2004;31(5):364-6.
168. Shihara T, Kato M, Mitsuhashi Y, Hayasaka K. Costello syndrome showing moyamoya-like vasculopathy. *Pediatr Neurol* 2005;32(5):361-3.
169. Rachmel A, Zeharia A, Neuman-Levin M, Weitz R, Shamir R, Dinari G. Alagille syndrome associated with moyamoya disease. *Am J Med Genet* 1989;33(1):89-91.
170. Emerick KM, Krantz ID, Kamath BM, et al. Intracranial vascular abnormalities in patients with Alagille syndrome. *J Pediatr Gastroenterol Nutr* 2005;41(1):99-107.
171. Girirajan S, Mendoza-Londono R, Vlangos CN, et al. Smith-Magenis syndrome and moyamoya disease in a patient with del(17)(p11.2p13.1). *Am J Med Genet A* 2007;143(9):999-1008.
172. Kim YO, Baek HJ, Woo YI, Choi YY, Chung TW. Moyamoya syndrome in a child with trisomy 12p syndrome. *Pediatr Neurol* 2006;35(6):442-5.
173. Pitz P, Hartjes HJ. Fibromuscular dysplasia and multiple dissecting aneurysms of intracranial arteries. A further cause of Moyamoya syndrome. *Stroke* 1976;7(4):393-8.
174. Pracyk JB, Massey JM. Moyamoya disease associated with polycystic kidney disease and eosinophilic granuloma. *Stroke* 1989;20(8):1092-4.
175. Terada T, Yokote H, Tsutsumi M, Nakai K, Ohshima A, Itakura T. Marfan syndrome associated with moyamoya phenomenon and aortic dissection. *Acta Neurochir* 1999;141(6):663-5.
176. Terajima K, Shimohata T, Watanabe M, et al. Cerebral vasculopathy showing moyamoya-like changes in a patient with CREST syndrome. *Eur Neurol* 2001;46(3):163-5.
177. Lau YL, Milligan DW. Atypical presentation of craniopharyngioma associated with Moyamoya disease. *J R Soc Med* 1986;79(4):236-7.
178. Arita K, Uozumi T, Oki S, et al. Moyamoya disease associated with pituitary adenoma - report of two cases. *Neurol Med Chir* 1992;32(10):753-7.
179. Kitano S, Sakamoto H, Fujitani K, Kobayashi Y. Moyamoya disease associated with a brain stem glioma. *Childs Nerv Syst* 2000;16(4):251-5.
180. Watanabe Y, Todani T, Fujii T, Toki A, Uemura S, Koike Y. Wilms' tumor associated with Moyamoya disease: a case report. *Z Kinderchir* 1985;40(2):114-16.
181. Sequeira W, Naseem M, Bouffard DA. An association with birth control pills. Moyamoya. *IMJ Ill Med J* 1984;166(6):434-6.
182. Schwartz MS, Scott RM. Moyamoya syndrome associated with cocaine abuse. Case report. *Neurosurg Focus* 1998;5(5):e7.
183. Storen EC, Wijdicks EF, Crum BA, Schultz G. Moyamoya-like vasculopathy from cocaine dependency. *AJNR Am J Neuroradiol* 2000;21(6):1008-10.
184. Bitzer M, Topka H. Progressive cerebral occlusive disease after radiation therapy. *Stroke* 1995;26(1):131-6.
185. Desai SS, Paulino AC, Mai WY, Teh BS. Radiation-induced moyamoya syndrome. *Int J Radiat Oncol Biol Phys* 2006;65(4):1222-7.
186. Ullrich NJ, Robertson R, Kinnamon DD, et al. Moyamoya following cranial irradiation for primary brain tumors in children. *Neurology* 2007;68(12):932-8.
187. Steinke W, Tatemichi TK, Mohr JP, Massaro A, Prohownik I, Solomon RA. Caudate hemorrhage with moyamoya-like vasculopathy from atherosclerotic disease. *Stroke* 1992;23(9):1360-3.
188. Joo SP, Kim TS, Lee JH, et al. Moyamoya disease associated with Behcet's disease. *J Clin Neurosci* 2006;13(3):364-7.
189. Taskintuna I, Oz O, Teke MY, Kocak H, Firat E. Morning glory syndrome: association with moyamoya disease, midline cranial defects, central nervous system anomalies, and persistent hyaloid artery remnant. *Retina* 2003;23(3):400-2.
190. Mawad ME, Hilal SK, Michelsen WJ, Stein B, Ganti SR. Occlusive vascular disease associated with cerebral arteriovenous malformations. *Radiology* 1984;153(2):401-8.
191. Nakashima T, Nakayama N, Furuchi M, Kokuzawa J, Murakawa T, Sakai N. Arteriovenous malformation in association with moyamoya disease. Report of two cases. *Neurosurg Focus* 1998;5(5):e6.
192. Yamada K, Hayakawa T, Ushio Y, Mitomo M. Cerebral arterial dolichoectasia associated with moyamoya vessels. *Surg Neurol* 1985;23(1):19-24.
193. Katayama W, Enomoto T, Yanaka K, Nose T. Moyamoya disease associated with persistent primitive hypoglossal artery: report of a case. *Pediatr Neurosurg* 2001;35(5):262-5.
194. Shoskes DA, Novick AC. Surgical treatment of renovascular hypertension in moyamoya disease: case report and review of the literature. *J Urol* 1995;153(2):450-2.
195. Bayraktar B, Topaloglu R, Cila A, Saatci I. Renovascular hypertension and prolonged encephalopathy associated with moyamoya disease. *Eur J Pediatr* 1999;158(4):342.
196. Tsuruta D, Fukai K, Seto M, et al. Phakomatosis pigmentovascularis type IIIb associated with moyamoya disease. *Pediatr Dermatol* 1999;16(1):35-8.
197. Takenaka K, Ito M, Kumagai M, et al. Moyamoya disease associated with pulmonary sarcoidosis - case report. *Neurol Med Chir* 1998;38(9):566-8.
198. Sharma J, Sehgal KV, Harmon RL. Heterotopic ossification in moyamoya disease: a case report. *Am J Phys Med Rehabil* 1998;77(5):455-7.

199. Lutterman J, Scott M, Nass R, Geva T. Moyamoya syndrome associated with congenital heart disease. *Pediatrics* 1998;101(1, Part 1):57-60.
200. Fernandez-Alvarez E, Pineda M, Royo C, Manzanares R. "Moya-moya" disease caused by cranial trauma. *Brain Dev* 1979;1(2):133-8.
201. Fukui M, Natori Y, Matsushima T, Ikezaki K. Surgical treatment of akin Moyamoya disease in children. In: Fukui M, ed. Annual report of the 1995 research committee on spontaneous occlusion of the circle of Willis. Tokyo, Japan; 1996.
202. Goldenberg HJ. 'Moyamoya' associated with peripheral vascular occlusive disease. *Arch Dis Child* 1974;49(12):964-6.
203. Peerless SJ. Risk factors of moyamoya disease in Canada and the USA. *Clin Neurol Neurosurg* 1997;99 Suppl 2:S45-S48.
204. Hallemeier CL, Rich KM, Grubb RL, Jr., et al. Clinical features and outcome in north American adults with moyamoya phenomenon. *Stroke* 2006;37(6):1490-6.
205. Suzuki J, Takaku A, Kodama N, Sato S. An attempt to treat cerebrovascular 'Moyamoya' disease in children. *Childs Brain* 1975;1(4):193-206.
206. Donaghy RM. Neurologic surgery. *Surg Gynecol Obstet* 1972;134(2):269-70.
207. Spetzler R, Chater N. Occipital artery - middle cerebral artery anastomosis for cerebral artery occlusive disease. *Surg Neurol* 1974;2(4):235-8.
208. Ikeda A, Yamamoto I, Sato O, Morota N, Tsuji T, Seguchi T. Revascularization of the calcarine artery in moyamoya disease: OA-cortical PCA anastomosis - case report. *Neurol Med Chir* 1991;31(10):658-61.
209. Ishii R, Koike T, Takeuchi S, Ohstugi S, Tanaka R, Konno K. Anastomosis of the superficial temporal artery to the distal anterior cerebral artery with interposed cephalic vein graft. Case report. *J Neurosurg* 1983;58(3):425-9.
210. Fung LW, Thompson D, Ganesan V. Revascularisation surgery for paediatric moyamoya: a review of the literature. *Childs Nerv Syst* 2005;21(5):358-64.
211. Mizoi K, Kayama T, Yoshimoto T, Nagamine Y. Indirect revascularization for moyamoya disease: is there a beneficial effect for adult patients? *Surg Neurol* 1996;45(6):541-8; discussion 8-9.
212. Choi JU, Seok Kim D, Kim EY, Lee KC. Natural history of Moyamoya disease: comparison of activity of daily living in surgery and non surgery groups. *Clin Neurol Neurosurg* 1997;99 (Suppl 2):S11-S18.
213. Yoshida Y, Yoshimoto T, Shirane R, Sakurai Y. Clinical course, surgical management, and long-term outcome of moyamoya patients with rebleeding after an episode of intracerebral hemorrhage: an extensive follow-up study. *Stroke* 1999;30(11):2272-6.
214. Kuroda S, Houkin K, Kamiyama H, Abe H. Effects of surgical revascularization on peripheral artery aneurysms in moyamoya disease: report of three cases. *Neurosurgery* 2001;49(2):463-7; discussion 7-8.
215. Komiya M, Yasui T, Kitano S, Sakamoto H, Fujitani K, Matsuo S. Moyamoya disease and pregnancy: case report and review of the literature. *Neurosurgery* 1998;43(2):360-8; discussion 8-9.

20. Spinal Vascular Lesions

Several classification schemes for spinal vascular lesions have been described.¹⁻⁴ The following four-type system is the most commonly used, with cavernous malformations and vascular tumors added for completeness:

1. Type I: Dural arteriovenous fistula (dAVF)
2. Type II: Intramedullary arteriovenous malformation (AVM)
3. Type III: Juvenile AVM
4. Type IV: Intradural perimedullary AVF
5. Intramedullary cavernous malformations
6. Spinal vascular tumors
 - (a) Includes hemangioma, hemangioblastoma, metastatic tumors, aneurysmal bone cyst, osteoblastoma, angiosarcoma, hemangiopericytoma, angiofibroma, angioliipoma, hemangioendothelioma

Technical aspects of endovascular treatment of spinal vascular lesions are discussed in Chap.8, Extracranial Embolization.

20.1. Type I: Dural arteriovenous fistula

Type I lesions (aka angioma racemosum, angioma racemosum venosum, intradural dorsal AVF, long dorsal AVF, dorsal extramedullary AVF) consist of an abnormal communication between the radicular artery in the nerve root sleeve and the intradural venous system, causing venous hypertension (Fig. 20.1). They can be subclassified into type I-A and type I-B lesions, depending on whether there is one or more radicular feeding arteries.^{5,6}

20.1.1. Epidemiology and clinical features

1. Type I dAVFs are the most common spinal vascular lesion, representing approximately 70% of spinal vascular malformations.⁷
2. More common in males (male/female ratio is 5:1).^{8,9}
3. Mean age at presentation is 60; range is 28–83 years.⁸⁻¹⁰
4. Mean duration of symptoms prior to diagnosis: 23 months.^{8,9,11}
5. The majority of type I lesions are located in the thoracolumbar spine, with T7, 8, and 9 being the most common levels.¹²
 - (a) 85% of lesions are below T6, and 100% of lesions are below T3.¹²
6. *Extradural* dAVFs are uncommon.^{13,14} They cause arterialization of the epidural venous system, and produce symptoms by spinal cord compression, venous congestion,¹⁵ or, rarely, by steal of blood flow from the spinal cord.²
7. Presentation:
 - (a) Symptoms are typically progressive and may be exacerbated by physical activity.¹¹
 - (b) Motor symptoms are present in 78–100% of cases.^{8,9,11,16}
 - (c) Upper or motor neurons may be involved; flaccid paresis is about as common as spastic paresis.¹⁶
 - (d) Sensory symptoms are present in 69–90% of cases.^{9,11,16}
 - (e) Paresthesias, and sensory and gait abnormalities are common.
 - (f) Pain is a complaint in more than half of cases.^{9,11,16}
 - (g) Patients may report worsening of symptoms with exertion (neurogenic claudication) or with certain postural changes.¹²
8. Imaging:
 - (a) MRI is the screening procedure of choice for spinal dAVFs.¹⁷
 - Spinal cord hyperintensity on T2-weighted images and postgadolinium enhancement on T1-weighted images are the most common findings.^{7,18} Cord signal changes usually extend for six or seven vertebral levels.^{7,16}

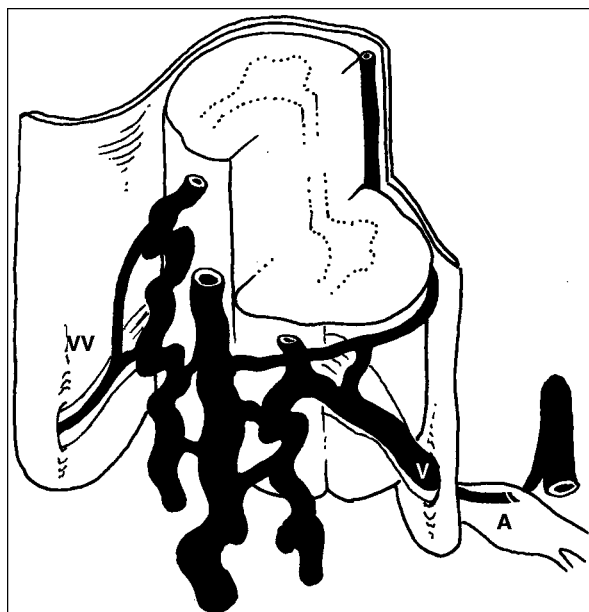


Fig. 20.1 Type I dural arteriovenous fistula (dAVF) Type I dAVF: There is a direct connection between a radicular artery (A) and a radicular vein (V) in the dura of the nerve root sleeve. Arterialization of the coronal venous plexus causes engorgement and congestion of the veins. Note that the contralateral radicular vein (VV) in this depiction is small; impairment of alternative routes of venous drainage is thought to contribute to the development of venous hypertensive myelopathy.

- Cord edema is seen in up to 74% of cases.¹⁶
 - The coronal venous plexus has a characteristically nodular, shaggy, and tortuous appearance on MRI and MRA.⁷
 - Dilated veins on the dorsal surface of the cord can be distinguished from CSF pulsation artifact by a typical salt and pepper appearance on postcontrast T1-weighted images.¹⁶
- (b) Catheter angiography is the gold standard for the workup of spinal dAVFs.¹⁷
- Selective injection of the thoracic and lumbar spinal arteries should be done first, since the majority of dAVFs are located in those regions.
 - In some 10% of cases, the sacral arteries are involved.^{19, 20}
 - Rarely, intracranial dural AVFs may drain inferiorly and mimic spinal dural AVFs clinically and on MRI.^{20–22} Thus, if a fistula is not found during spinal angiography, angiography of the cerebral vessels should be done.
 - Dilated, tortuous veins are characteristic, which are predominantly along the posterior surface of the spinal cord.
 - When a fistula is found, the adjacent levels should be imaged as well, because of the possibility of multiple radicular feeding arteries.
 - When possible, placement of a metal coil in the major feeding artery can facilitate intraoperative fluoroscopic localization of the fistula.²³
- (c) Myelography is very accurate in identifying spinal dAVFs, showing tortuous filling defects in up to 100% of cases.^{7, 11, 24} These abnormal vessels

are always located on the dorsal surface of the cord, and may also be present on the ventral surface in some 10% of cases.¹¹

20.1.2. Pathophysiology

1. Normal radicular veins have a constriction at the point where the vein passes through the dura, which prevents the transmission of arterial pressure into the valveless coronal venous plexus.²⁵ Fistulas are usually located at this point or within the nerve root sleeve.²⁶ The fistulas is usually supplied by a menin-goradicular branch of a segmental artery, although any artery supplying the dura may be involved.¹⁷ The intrathecal spinal venous system is valveless, and therefore arterial pressure is transmitted via the corresponding radicular vein into the perimedullary and spinal veins, causing venous hypertension, congestion and impairment of the spinal cord and nerve root microcirculation.²⁷ Direct measurement of the coronal venous pressure during surgery found that the spinal cord venous pressure averages 74% of the simultaneous mean systemic venous pressure.²⁷
2. The etiology of spinal dAVFs is not understood. Interestingly, in contrast to cranial dAVFs, in which venous sinus thrombosis is believed to contribute to the development of those lesions, prothrombotic conditions are not associated with spinal dAVFs.²⁸
3. Spinal dAVFs are associated with infection,²⁹ syringomyelia,³⁰ spine trauma,³¹ and surgery.^{32, 33}

20.1.3. Management

The natural history of untreated spinal dAVFs is generally thought to be poor. An early series found that 50% of untreated patients became severely disabled (wheel-chair-bound) within 3 years of the onset of lower extremity weakness.³⁴

Both surgery and endovascular treatment can be effective for treatment of type I lesions. Although surgery appears to be more curative, embolization is less invasive and some authors recommend an attempt at embolization prior to surgery. In a systematic review of 20 published clinical series, 98% of patients treated with surgery were reported to have successful obliteration of their fistulae, compared to only 46% with embolization.³⁵ Complications were reported in 1.9% of surgical patients and 3.7% of embolization patients.

Extradural dAVFs are treated almost exclusively with embolization of the arterial feeder and rarely require surgery.^{2, 36}

20.1.3.1. Surgical considerations

1. Neurophysiological monitoring with evoked potentials is not necessary, as manipulation of the spinal cord is not required.¹⁹
2. A two-level hemilaminectomy is done to adequately expose the affected nerve root.
3. The dura is opened in the midline and retracted laterally.
4. The radicular draining vein is exposed where it penetrates the dura and is coagulated and divided.
 - (a) Interruption of the radicular vein usually leads to a visible change in venous turgor, and the color of the arterialized venous plexus may change from red to blue.
5. If the fistula involves a thoracic nerve root, the root may be sacrificed to facilitate dural closure. Obviously, cervical and lumbar nerve roots should be preserved.
6. In cases in which extradural drainage of the fistula is present, the entire fistula should be excised and the intradural and extradural components should be divided to prevent recurrence.³⁷
7. Outcomes with surgery:
 - a. A systematic review of surgical outcomes found that 55% of patients improved after surgery, 34% were stabilized, and 11% worsened.³⁵ Only 33% of patients showed an improvement in micturition, and 11% worsened.

20.1.3.2. Endovascular considerations

1. Case selection: Embolization should be done only when the anatomy of the lesion will permit obliteration of the nidus.
 - (a) Embolization is feasible in some 75% of cases.³⁸
 - Barriers to embolization include advanced atherosclerosis, arterial feeders too small to catheterize, and collateralization of the feeding vessel with normal spinal cord vessels.
 - (b) Moreover, embolization is most effective when the glue penetrates the proximal portion of the draining vein; if the glue does not reach the draining vein, the fistula may persist or recanalize. In an endovascular series, the fistula recurred in 68% of cases in which the glue did not reach the draining vein, compared with 50% of cases in which the glue did reach the draining vein.³⁹
2. Embolization is particularly useful in patients who are poor candidates for surgery, or in some cases as a temporizing measure, to reduce venous congestion until a definitive surgical procedure can be performed.⁴⁰
3. The embolization agent of choice is N-butyl cyanoacrylate. Onyx embolization has been reported.⁴¹
4. Partial embolization of the fistula and embolization with particulate agents (e.g., polyvinyl alcohol) should be avoided.^{42–45} Failure to permanently obliterate the lesion may lead to recurrence, and further difficulty in later treatment.
5. Reports on long-term outcomes after embolization are lacking. Clinical outcome data on embolization were insufficient for analysis in the systematic review discussed earlier.³⁵

THE OFTEN MISUNDERSTOOD FOIX–ALAJOUANINE SYNDROME

In 1926, Foix and Alajouanine published a 42-page report of two cases of progressive myelopathy.²⁹ An extensive pathological analysis was carried out, and the authors implicated vascular congestion, as reflected by spinal cord vessel thickening, in the pathological process afflicting both patients. In the decades since this report, numerous authors have included spinal cord venous thrombosis as a central feature of the Foix–Alajouanine Syndrome.^{6, 40, 46–49} Indeed, both authors of this handbook were taught, during their training, that Foix–Alajouanine Syndrome is equivalent to progressive, malignant spinal cord venous thrombosis. In the actual report, however, Foix and Alajouanine emphasized that in their two cases no thrombosis was present.⁵⁰ They described vessel wall thickening, without luminal narrowing or obliteration of cord vessels, and excluded the presence of vascular malformations within the cord. The inclusion of thrombosis as a feature of Foix–Alajouanine Syndrome is a myth that has been perpetuated most likely because the original report was written in French. In retrospect, it seems likely that both patients in the original report had progressive myelopathy due to type I dural AVFs,⁴⁰ an entity that had not yet been recognized at the time of the publication.⁵⁰

20.2. Type II: Intramedullary arteriovenous malformation

Type II lesions (aka glomus or classic AVM) consist of an AVM within the substance of the spinal cord. The nidus can be classified as compact or diffuse, and they often have multiple feeding vessels arising from the anterior and posterolateral spinal arteries (Fig. 20.2).

20.2.1. Epidemiology and clinical features

1. Type II lesions are the second most common kind of spinal vascular lesion, accounting for up to 36–45% of spinal vascular lesions.^{3, 51}
2. Most commonly present in the third or fourth decade.
 - (a) Average age at diagnosis is 27.¹²
3. Slight male predominance.³⁶

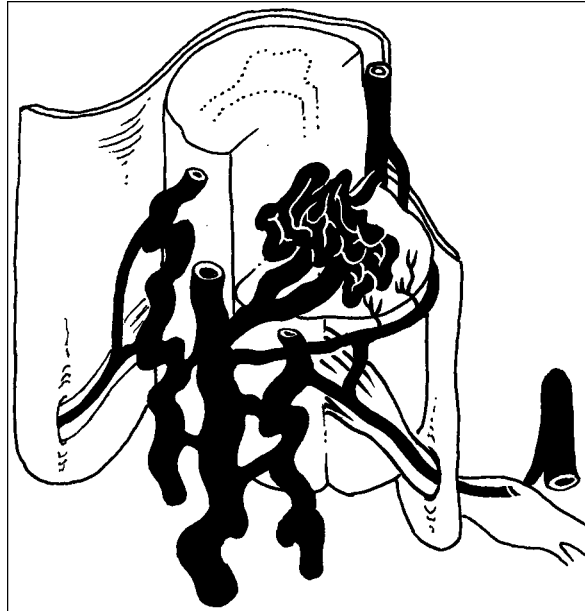


Fig. 20.2 Type II intramedullary AVM. Intramedullary arteriovenous malformation with a compact nidus is illustrated.

4. Associated with neurofibromatosis and the Rendu-Osler-Weber, Klippel-Trenaunay-Weber,⁵² and Parkes-Weber syndromes.⁵³
5. Aneurysms are present in 20–44% of cases and are associated with hemorrhage.^{12, 54, 55}
6. Spinal cord AVMs are located in the cervical cord in 30% of cases and in the thoracolumbar cord in 70%, which is proportional to the volume of the spinal cord at each segment.³⁶
7. Conus AVMs comprise a special category of spinal cord AVMs.^{2, 56} They are attributed to an abnormality during neurulation and are associated with a tethered cord.⁵⁷ Conus AVMs are typically extensive and possess multiple arterial feeders.
8. Presentation:
 - (a) Symptoms may be acute or progressive, although in most cases the symptoms develop relatively rapidly.⁵⁸
 - (b) Hemorrhage (intraparenchymal or subarachnoid hemorrhage) is the most common presenting symptom.^{12, 58, 59}
 - Mortality associated with hemorrhage is 10–20%.⁶⁰
 - Hemorrhage at presentation may be more common among children with cord AVMs compared with adults.⁶¹
 - Rehemorrhage appears to happen at higher rates for spinal cord AVMs compared with brain AVMs, occurring in 10% of patients at 1 month and in 40% within the first year after the initial hemorrhage.⁶⁰
 - (c) Venous congestion may also produce symptoms in the absence of hemorrhage.⁶²
 - (d) Conus AVMs may present with myelopathy or radiculopathy.
9. Imaging:
 - (a) MRI is highly sensitive and is able to detect all, or nearly all spinal cord AVMs.^{47, 63, 64}

- MRI findings include a focal dilatation of the cord around the lesion, an area of low signal around the nidus on T1- and T2-weighted imaging that corresponds to hemosiderin deposition, and multiple flow voids (on axial images) and serpentine structures (on sagittal and coronal images) due to feeding and draining vessels.
 - T2 signal change may represent cord edema due to venous congestion.⁶²
 - Subacute hemorrhage appears as increased signal on T1-weighted images.
- (b) Catheter angiography remains the *gold standard* for the evaluation of spinal cord AVMs.³⁶ A complete angiogram to characterize all feeding and draining vessels, look for aneurysms, and distinguish the lesion from associated normal vessels is necessary to plan treatment.
- Selective injection of numerous arteries is necessary to fully characterize a cord AVM, as feeding vessels may arise from sources as far afield as the occipital, ascending pharyngeal, vertebral, ascending and deep cervical, supreme intercostal, intercostal, lumbar, and the lateral and median sacral arteries.⁶⁰

20.2.2. Management

The natural history of untreated intramedullary AVMs is not clear. Progressive evolution of symptoms, by either worsening myelopathy or subsequent hemorrhages, is reported in 31–71% of patients observed over several years.^{12, 61, 65, 66} Because spinal cord AVM anatomy is variable and the risk of potential complications on any procedure involving the cord is relatively high, decision making about the management of these patients is highly individualized. Patients with a cord AVM consisting of a compact, surgically accessible nidus may be good candidates for surgery. Embolization may be a useful adjunct to surgery, or, in some cases, may provide symptomatic relief without necessarily obliterating the lesion. There is a school of thought that holds that partial embolization of spinal cord AVMs, even with impermanent materials (such as PVA) may provide an (impermanent) improvement in symptoms such as pain and myelopathy.⁶⁵ The notion that partial treatment of cord AVMs lowers the risk of hemorrhage, which is generally believed not to be the case with intracranial AVMs, is more controversial.

20.2.2.1. Surgical considerations

1. Embolization of major feeders prior to surgery can be helpful,^{54, 67, 68} particularly for lesions with multiple feeding vessels, such as conus AVMs.⁵⁶
 - a. Alternatively, intraoperative angiography may be helpful in localizing the lesion during surgery.⁶⁹
2. With *appropriate case selection* (i.e., by operating on patients with a relatively compact, surgically accessible nidus), angiographic obliteration of the lesion can be achieved in up to 94% of cases.⁵⁸
 - a. Surgery for diffuse spinal cord AVMs has been reported. In a series of three cases, the lesion was obliterated in all; neurological outcome improved in one patient and deteriorated slightly to mildly in the other two patients.⁷⁰
3. Surgical approach is via a standard laminotomy. Exposure should extend at least one level above and one level below the lesion. A small myelotomy is done in the posterior median sulcus, and the spinal cord is split between the two posterior columns. Alternatively, a posterolateral myelotomy, done in the dorsal root entry zone between two or more nerve roots, can provide access to lateral lesions.
4. In one series, delayed imaging (mean follow-up, 8.5 years) in patients with no evidence of residual AVM on early postoperative imaging detected new draining veins in 23% of cases.⁵⁸
5. Outcomes with surgery:
 - (a) As expected, surgical results are better with compact AVMs compared with AVMs with a diffuse nidus.⁴
 - (b) Surgical series overall clinical results:

- Neurologic improvement in 40%,⁵⁸ 87%⁴
 - Neurologically unchanged 53%,⁵⁸ 10%⁴
 - Neurologically worsened in 7%,⁵⁸ 3%⁴
- (c) *Good functional outcome* in 86%,⁵⁸
- (d) Chronic dysesthetic pain syndromes are common, affecting two-thirds of patients.⁵⁸

20.2.2.2. Endovascular considerations

1. Complete obliteration rates with embolization range from 24 to 53%.^{60, 71}
2. Transient complication rates are 10.6–14%^{60, 71} and permanent complication rates are also 10.6–14%.^{60, 71}
3. Biondi et al. advocate routine yearly spinal angiography and embolization with PVA, regardless of symptoms.⁶⁵ Despite frequent lesion revascularization, 63% of patients demonstrated long-term clinical improvement with this strategy. Worsening of symptoms after embolization was observed in 20% of patients.
4. Some authors assert that partial embolization of spinal cord AVMs is protective against hemorrhage, unlike brain AVMs.^{36, 65}
5. Choice of embolic agent:
 - (a) The first-line agent for embolization of any cord AVM should be NBCA or Onyx, provided that the microcatheter tip can be placed within the nidus.
 - (b) If the microcatheter tip can be placed close to the nidus, but beyond angiographically visible normal spinal cord vessels, NBCA is still a good choice.
 - (c) Particulate embolization should be reserved for cases in which the microcatheter tip is relatively proximal to the lesion. *Flow-directed* embolization with a particulate agent will theoretically carry most of the particles past normal branches and into the nidus. Injection should be done slowly and carefully, without attempting to completely occlude the nidus.
 - Sizing of the particulate agent is based on the following reasoning: Because the normal anterior spinal artery diameter is 340–1,100 μm and the normal sulcal artery diameter is 60–72 μm , particles with a diameter of 150–250 μm should pass through the anterior spinal artery and into the AVM nidus without entering the normal sulcal arteries.^{72, 73}
 - Although PVA is the particulate agent of choice by some operators, PVA size is highly variable. The authors of this handbook prefer to use 100–300 μm Bead Block™ Microspheres (Terumo Medical Corporation, Somerset, NJ) or 100–300 μm Embosphere® Microspheres (BioSphere Medical, Inc., Rockland, MA).

20.2.2.3. Radiosurgery

In a preliminary report of stereotactic radiosurgery for intramedullary AVMs, six of seven patients at least 3 years from treatment had a significant reduction in AVM volume, and one patient with a conus lesion was found to have complete angiographic obliteration.⁷⁴

SPINAL CORD ANEURYSMS

Spinal cord aneurysms are rare. Most are discovered as flow-related lesions associated with an intramedullary AVM, although isolated spinal cord aneurysms do occur^{75–77} and can cause subarachnoid hemorrhage.⁷⁷ There appears to be a strong association with developmental vascular anomalies, as metameric angiomatosis was found in 43% of patients in a series of cord aneurysms.⁵⁵ Spinal aneurysms are typically fusiform in shape and thus very difficult to treat directly with endovascular techniques. Surgery of spinal cord AVMs with trapping⁷⁵ and wrapping⁷⁶ has been reported. Disappearance or a decrease in size of the aneurysm was observed in several patients who underwent treatment of an associated intramedullary AVM.⁵⁴ Importantly, even solitary spinal cord aneurysms may spontaneously regress without treatment.⁷⁷

20.3. Type III: Juvenile arteriovenous malformation

Type III lesions (aka juvenile, metameric, or extradural-intradural AVM) are complex AVMs that have both intradural and extradural components, and typically involve the spinal cord, vertebra, and paraspinal muscles (Fig. 20.3). The portion of the nidus involving the spinal cord typically has neural tissue within its interstices. They are high-flow lesions, and may have a bruit over the lesion. They are extremely rare and may appear as part of Cobb syndrome (see below). Patients are typically children or young adults (thus the term *juvenile*), and present with pain and/or myelopathy. These AVMs typically have multiple feeding vessels arising from diverse locations, such as the vertebral arteries, radicular arteries, and other cervical vessels. Catheter angiography of a juvenile AVM can be somewhat like shining a small flashlight on an elephant in a dark room – only a part of the lesion can be seen with injection of contrast into any particular artery. These lesions are extremely difficult to treat. Although complete lesion resection by staged embolization followed by surgery has been reported,^{78, 79} fatal complications with this approach have also been reported.⁶

20.3.1. Cobb Syndrome

Cobb syndrome is a rare congenital disorder with a slight male predominance characterized by a combination of vascular skin nevi and a spinal vascular lesion occurring within the same metameres (i.e., the skin lesions are found in the dermatomes corresponding to the spinal levels where the spine lesion is). It was first described by Stanley Cobb, a resident of Harvey Cushing, in a report of a 8-year-old boy who presented with paraplegia.⁸⁰ The child had nevi over the 9th to 12th ribs, and at surgery he was found to have an angioma of the thoracic spinal cord. The spinal vascular lesion that occurs as part of Cobb syndrome may be a type III AVM, or a less complex lesion such as a perimedullary AV fistula.⁸¹ Therefore, type III spinal vascular lesions and Cobb syndrome are not exactly synonymous.

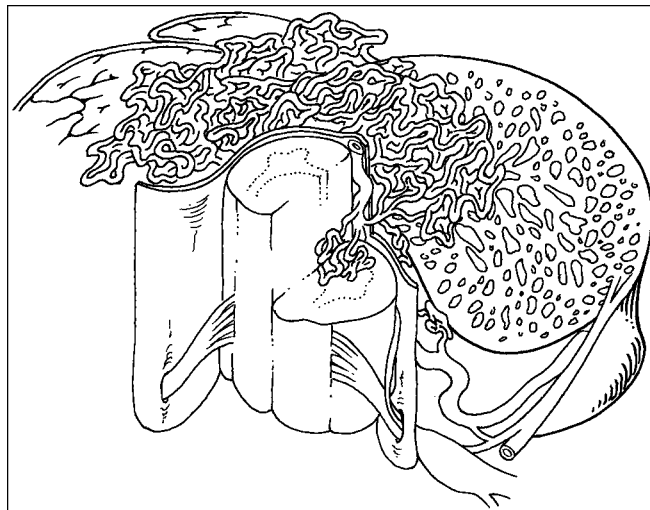


Fig. 20.3 Type III Juvenile AVM Type III lesions characteristically extend across tissue planes from the spinal cord into the adjacent bone and muscle.

20.4. Type IV: Intradural perimedullary arteriovenous fistula

Type IV lesions (aka perimedullary, or ventral intradural AV fistulas) are located on the pial surface of the spinal cord, usually on the anterior or lateral surface. They consist of a fistula between a spinal cord artery or arteries and the coronal venous plexus, and there is often a varix at the artery-to-vein transition site. Type IV lesions account for 13–17% of all spinal vascular lesions.^{12, 51} They were originally subdivided into type I, II, or III lesions depending on size and complexity⁸²; subsequent authors have adopted a type A–C system² (Table 20.1). An association with split cord malformation has been reported,⁸³ and type B and C lesions are associated with Rendu-Osler-Weber and Cobb syndrome.⁸⁴

1. Type A: The least common type IV lesion. Small, single-vessel fistulae supplied by the anterior spinal artery, usually located on the anterior surface of the conus or on the upper part of the filum terminale. Venous drainage is slow and is in a rostral direction.
2. Type B: Larger, multiple-vessel fistulae supplied by the anterior and posterolateral spinal arteries, usually located on the posterolateral or anterolateral surface of the conus. Venous drainage is slow and is in a rostral direction.
3. Type C: The most common type IV lesion. These lesions consist of a single giant fistula supplied by multiple, enlarged feeders from the anterior and posterolateral spinal arteries. They are located on the thoracic cord, or, less commonly the cervical cord.^{51, 85} Venous drainage is rapid and into segmental veins.

20.4.1. Clinical features

1. Patients are relatively young. The average age at presentation is 20–25 years (range 2–42).^{51, 84}
2. No sex predominance.
3. The location of these lesions along the spinal axis is bimodal, with most occurring at the thoracolumbar junction, particularly at the conus, and, to a lesser extent, in the upper cervical region.⁸⁶
4. Rarely, perimedullary AVFs may develop after spinal cord surgery.^{82, 87}
5. Presentation:
 - (a) The majority of patients (91%) present with an asymmetric, slowly progressive myeloradiculopathy of the conus and cauda equina.⁵¹
 - (b) An acute onset of symptoms is less common and is usually seen only in patients with type B and C lesions.⁵¹
 - (c) Subarachnoid hemorrhage is a presenting feature in 20–40% of cases.^{51, 84}
6. Imaging:
 - (a) Type B and C lesions characteristically demonstrate large flow voids on MRI scanning.⁸⁴ However, it is important to note that type I lesions may not be apparent on MRI,⁸⁸ and myelography or angiography should be done if a type IV-A lesion is suspected but not seen on MRI.
 - (b) Apparent diffusion coefficient (ADC) values may be reduced, indicating vasogenic edema, and may normalize after treatment.⁸⁹
 - (c) CTA diagnosis of type IV-A lesions has been reported.⁹⁰
 - (d) Catheter angiography is necessary to make a clear diagnosis of a perimedullary fistula and plan therapy.

Table 20.1 Subtypes of perimedullary AV fistulae

Type	Arterial supply	Venous drainage	Primary mode of treatment
A	Anterior spinal artery only	Ascending	Surgery
B	Anterior and posterolateral spinal arteries	Ascending	Embolization ± surgery
C	Anterior and posterolateral spinal arteries	Dilated segmental veins	Embolization

20.4.2. Management

Because type IV lesions are rare, published series are limited, and firm conclusions about treatment cannot be made. Estimations of the natural history of untreated lesions suggest progression from myelopathy to paraplegia within 5–7 years, and a high incidence of repeated hemorrhage in patients presenting with hemorrhage.^{12, 51, 82, 85, 86} Most authors recommend prompt diagnosis and treatment of perimedullary fistulae to minimize neurological injury.^{12, 51, 82, 85} The objective of treatment should be occlusion of the fistula. The absence of a nidus facilitates surgery⁵¹; most lesions can be effectively obliterated with either surgery or embolization, or a combination of both.^{3, 51, 84, 91, 92}

1. Type A: Most authors recommend that subtype A lesions should be treated with surgery, as catheterization of the anterior spinal artery is problematic.^{51, 82, 85, 93, 94}
2. Type B: Embolization or embolization followed by surgery can occlude the fistula in nearly all cases.^{51, 85}
3. Type C: Embolization is usually the first-line treatment of type C lesions.⁹⁵ Complete occlusion was achieved by embolization alone in 68% of patients with type C lesions.⁵¹
4. Clinical outcome appears to be somewhat variable, with partial neurological improvement or no change occurring in the majority of patients, and worsening in a small minority of patients.^{51, 85}

20.5. Intramedullary cavernous malformation

Cavernous malformations (aka cavernomas) are distributed along the entire neuroaxis and represent 5–12% of all spinal vascular lesions.^{96, 97} Rarely, they may be found in an epidural location.⁹⁸ Spinal cavernomas are histologically identical to those in the brain (see Chap. 16). They are angiographically occult and have a characteristic appearance on MRI.⁹⁷ As many as 40% of patients with a spinal cavernoma may be found to have a similar intracranial lesion.⁹⁹ As in the brain, spinal cord cavernomas are frequently associated with a venous angioma.¹⁰⁰ A systematic review of published series found a female predominance with a peak age at presentation in the fourth decade.¹⁰¹ The course of symptoms is highly variable. The natural history of symptomatic spinal cavernomas is far from clear. Assessments of the annual rate of symptomatic rehemorrhage rates range from 0%¹⁰² to 66%.¹⁰³ Although surgical series report relatively good results,^{97, 101, 104} expectant management of selected patients may also be reasonable.¹⁰²

20.6. References

1. Borden JA, Wu JK, Shucart WA. A proposed classification for spinal and cranial dural arteriovenous fistulous malformations and implications for treatment. *J Neurosurg* 1995;82(2):166–79.
2. Spetzler RF, Detwiler PW, Riina HA, Porter RW. Modified classification of spinal cord vascular lesions. *J Neurosurg* 2002;96(2 Suppl):145–56.
3. Bao YH, Ling F. Classification and therapeutic modalities of spinal vascular malformations in 80 patients. *Neurosurgery* 1997;40(1):75–81.
4. Zozulya YP, Slin'ko EI, Al Q, II. Spinal arteriovenous malformations: new classification and surgical treatment. *Neurosurg Focus* 2006;20(5):E7.
5. Anson JA, Spetzler RF. Interventional neuroradiology for spinal pathology. *Clin Neurosurg* 1992;39:388–417.
6. Ferch RD, Morgan MK, Sears WR. Spinal arteriovenous malformations: a review with case illustrations. *J Clin Neurosci* 2001;8(4):299–304.
7. Gilbertson JR, Miller GM, Goldman MS, Marsh WR. Spinal dural arteriovenous fistulas: MR and myelographic findings. *AJNR Am J Neuroradiol* 1995;16(10):2049–57.
8. Jellema K, Canta LR, Tijssen CC, van Rooij WJ, Koudstaal PJ, van Gijn J. Spinal dural arteriovenous fistulas: clinical features in 80 patients. *J Neurol Neurosurg Psychiatry* 2003;74(10):1438–40.
9. Van Dijk JM, TerBrugge KG, Willinsky RA, Farb RI, Wallace MC. Multidisciplinary management of spinal dural arteriovenous fistulas: clinical presentation and long-term follow-up in 49 patients. *Stroke* 2002;33(6):1578–83.
10. Thron A. [Spinal dural arteriovenous fistulas]. *Radiologe* 2001;41(11):955–60.
11. Atkinson JLD, Miller GM, Krauss WE, et al. Clinical and radiographic features of dural arteriovenous fistula, a treatable cause of myelopathy. *Mayo Clin Proc* 2001;76(11):1120–30.
12. Rosenblum B, Oldfield EH, Doppman JL, Di Chiro G. Spinal arteriovenous malformations: a comparison of dural arteriovenous fistulas and intradural AVM's in 81 patients. *J Neurosurg* 1987;67(6):795–802.
13. Heier LA, Lee BC. A dural spinal arteriovenous malformation with epidural venous drainage: a case report. *AJNR Am J Neuroradiol* 1987;8(3):561–3.

14. Arnaud O, Bille F, Pouget J, Serratrice G, Salamon G. Epidural arteriovenous fistula with perimedullary venous drainage: case report. *Neuroradiology* 1994;36(6):490-1.
15. Pirouzmand F, Wallace MC, Willinsky R. Spinal epidural arteriovenous fistula with intramedullary reflux. Case report. *J Neurosurg* 1997;87(4):633-5.
16. Koch C, Kucinski T, Eckert B, Rother J, Zeumer H. [Spinal dural arteriovenous fistula: clinical and radiological findings in 54 patients]. *Rofo* 2003;175(8):1071-8.
17. Koch C. Spinal dural arteriovenous fistula. *Curr Opin Neurol* 2006;19(1):69-75.
18. Bowen BC, Fraser K, Kochan JP, Pattany PM, Green BA, Quencer RM. Spinal dural arteriovenous fistulas: evaluation with MR angiography. *AJNR Am J Neuroradiol* 1995;16(10):2029-43.
19. Watson JC, Oldfield EH. The surgical management of spinal dural vascular malformations. *Neurosurg Clin N Am* 1999;10(1):73-87.
20. Partington MD, Rufenacht DA, Marsh WR, Piepgras DG. Cranial and sacral dural arteriovenous fistulas as a cause of myelopathy. *J Neurosurg* 1992;76(4):615-22.
21. Woimant F, Merland JJ, Riche MC, et al. [Bulbospinal syndrome related to a meningeal arteriovenous fistula of the lateral sinus draining into spinal cord veins]. *Rev Neurol* 1982;138(6-7):559-66.
22. Wrobel CJ, Oldfield EH, Di Chiro G, Tarlov EC, Baker RA, Doppman JL. Myelopathy due to intracranial dural arteriovenous fistulas draining intrathecally into spinal medullary veins. Report of three cases. *J Neurosurg* 1988;69(6):934-9.
23. Britz GW, Lazar D, Eskridge J, Winn HR. Accurate intraoperative localization of spinal dural arteriovenous fistulae with embolization coil: technical note. *Neurosurgery* 2004;55(1):252-4; discussion 4-5.
24. N'Diaye M, Chiras J, Meder JF, Barth MO, Koussa A, Borjes J. Water-soluble myelography for the study of dural arteriovenous fistulae of the spine draining in the spinal venous system. *J Neuroradiol* 1984;11(4):327-39.
25. Tadie M, Hemet J, Freger P, Clavier E, Creissard P. Morphological and functional anatomy of spinal cord veins. *J Neuroradiol* 1985;12(1):3-20.
26. Benhaïem N, Poirier J, Hurth M. Arteriovenous fistulae of the meninges draining into the spinal veins. A histological study of 28 cases. *Acta Neuropathol* 1983;62(1-2):103-11.
27. Hassler W, Thron A, Grote EH. Hemodynamics of spinal dural arteriovenous fistulas. An intraoperative study. *J Neurosurg* 1989;70(3):360-70.
28. Jellema K, Tjissen CC, Fijnheer R, de Groot PG, Koudstaal PJ, van Gijn J. Spinal dural arteriovenous fistulas are not associated with prothrombotic factors. *Stroke* 2004;35(9):2069-71.
29. Foix C, Alajouanine T. Subacute necrotic myelitis, slowly progressive central myelitis with vascular hyperplasia, and slowly ascending, increasingly flaccid amyotrophic paraplegia accompanied by albuminocytologic dissociation (in French). *Rev Neurol* 1926;33:1-42.
30. Finsterer J, Bavinzski G, Ungersböck K. Spinal dural arteriovenous fistula associated with syringomyelia. *J Neuroradiol* 2000;27(3):211-14.
31. Vankan Y, Demaerel P, Heye S, et al. Dural arteriovenous fistula as a late complication of upper cervical spine fracture. Case report. *J Neurosurg* 2004;100(4 Suppl Spine):382-4.
32. Asakuno K, Kim P, Kawamoto T, Ogino M. Dural arteriovenous fistula and progressive conus medullaris syndrome as complications of lumbar discectomy. Case report. *J Neurosurg* 2002;97(3 Suppl):375-9.
33. Flannery T, Tan MH, Flynn P, Choudhari KA. Delayed post-surgical development of dural arteriovenous fistula after cervical meningocele repair. *Neurol India* 2003;51(3):390-1.
34. Aminoff MJ, Logue V. The prognosis of patients with spinal vascular malformations. *Brain* 1974;97(1):211-18.
35. Steinmetz MP, Chow MM, Krishnaney AA, et al. Outcome after the treatment of spinal dural arteriovenous fistulae: a contemporary single-institution series and meta-analysis. *Neurosurgery* 2004;55(1):77-87; discussion 8.
36. Niimi Y, Berenstein A. Endovascular treatment of spinal vascular malformations. *Neurosurg Clin N Am* 1999;10(1):47-71.
37. Afshar JK, Doppman JL, Oldfield EH. Surgical interruption of intradural draining vein as curative treatment of spinal dural arteriovenous fistulas. *J Neurosurg* 1995;82(2):196-200.
38. Song JK, Gobin YP, Duckwiler GR, et al. *N*-butyl 2-cyanoacrylate embolization of spinal dural arteriovenous fistulae. *AJNR Am J Neuroradiol* 2001;22(1):40-7.
39. Jellema K, Sluzewski M, van Rooij WJ, Tjissen CC, Beute GN. Embolization of spinal dural arteriovenous fistulas: importance of occlusion of the draining vein. *J Neurosurg Spine* 2005;2(5):580-3.
40. Criscuolo GR, Oldfield EH, Doppman JL. Reversible acute and subacute myelopathy in patients with dural arteriovenous fistulas. Foix-Alajouanine syndrome reconsidered. *J Neurosurg* 1989;70(3):354-9.
41. Warakaulle DR, Aviv RI, Niemann D, Molyneux AJ, Byrne JV, Teddy P. Embolisation of spinal dural arteriovenous fistulae with Onyx. *Neuroradiology* 2003;45(2):110-12.
42. Niimi Y, Berenstein A, Setton A, Neophytides A. Embolization of spinal dural arteriovenous fistulae: results and follow-up. *Neurosurgery* 1997;40(4):675-82; discussion 82-3.
43. Morgan MK, Marsh WR. Management of spinal dural arteriovenous malformations. *J Neurosurg* 1989;70(6):832-6.
44. Nichols DA, Rufenacht DA, Jack CR, Jr., Forbes GS. Embolization of spinal dural arteriovenous fistula with polyvinyl alcohol particles: experience in 14 patients. *AJNR Am J Neuroradiol* 1992;13(3):933-40.
45. McDougall CG, Deshmukh VR, Fiorella DJ, Albuquerque FC, Spetzler RF. Endovascular techniques for vascular malformations of the spinal axis. *Neurosurg Clin N Am* 2005;16(2):395-410, x-xi.
46. Di Chiro G, Wener L. Angiography of the spinal cord. A review of contemporary techniques and applications. *J Neurosurg* 1973;39(1):1-29.
47. Minami S, Sagoh T, Nishimura K, et al. Spinal arteriovenous malformation: MR imaging. *Radiology* 1988;169(1):109-15.
48. Gaensler EH, Jackson DE, Jr., Halbach VV. Arteriovenous fistulas of the cervicomedullary junction as a cause of myelopathy: radiographic findings in two cases. *AJNR Am J Neuroradiol* 1990;11(3):518-21.
49. Renowden SA, Molyneux AJ. Case report: spontaneous thrombosis of a spinal dural AVM (Foix-Alajouanine syndrome) - magnetic resonance appearance. *Clin Radiol* 1993;47(2):134-6.
50. Di Chiro G. Foix-Alajouanine syndrome. *AJNR Am J Neuroradiol* 1990;11(6):1286.
51. Mourier KL, Gobin YP, George B, Lot G, Merland JJ. Intradural perimedullary arteriovenous fistulae: results of surgical and endovascular treatment in a series of 35 cases. *Neurosurgery* 1993;32(6):885-91; discussion 91.
52. Djindjian M, Djindjian R, Hurth M, Rey A, Houdart R. Spinal cord arteriovenous malformations and the Klippel-Trenaunay-Weber syndrome. *Surg Neurol* 1977;8(4):229-37.
53. Lasjaunias PL. Spinal arteriovenous shunts. Berlin: Springer-Verlag; 1997.
54. Biondi A, Merland JJ, Hodes JE, Aymard A, Reizine D. Aneurysms of spinal arteries associated with intramedullary arteriovenous malformations. II. Results of AVM endovascular treatment and hemodynamic considerations. *AJNR Am J Neuroradiol* 1992;13(3):923-31.
55. Biondi A, Merland JJ, Hodes JE, Pruvo JP, Reizine D. Aneurysms of spinal arteries associated with intramedullary arteriovenous malformations. I. Angiographic and clinical aspects. *AJNR Am J Neuroradiol* 1992;13(3):913-22.
56. Gonzalez LF, Spetzler RF. Treatment of spinal vascular malformations: an integrated approach. *Clin Neurosurg* 2005;52:192-201.
57. Hurst RW, Bagley LJ, Marcotte P, Schut L, Flamm ES. Spinal cord arteriovenous fistulas involving the conus medullaris: presentation, management, and embryologic considerations. *Surg Neurol* 1999;52(1):95-9.

58. Connolly ES, Jr, Zubay GP, McCormick PC, Stein BM. The posterior approach to a series of glomus (Type II) intramedullary spinal cord arteriovenous malformations. *Neurosurgery* 1998;42(4):774-85; discussion 85-6.
59. Tobin WD, Layton DD. The diagnosis and natural history of spinal cord arteriovenous malformations. *Mayo Clin Proc* 1976;51(10):637-46.
60. Berenstein A, Lasjaunias PL. Spine and spinal cord vascular lesions. In: Berenstein A, Lasjaunias PL, eds. *Endovascular treatment of spine and spinal cord lesions (Surgical Neuroangiography, Vol. 5)*. Berlin: Springer-Verlag; 1992:1.
61. Riche MC, Modenesi-Freitas J, Djindjian M, Merland JJ. Arteriovenous malformations (AVM) of the spinal cord in children. A review of 38 cases. *Neuroradiology* 1982;22(4):171-80.
62. Kataoka H, Miyamoto S, Nagata I, Ueba T, Hashimoto N. Venous congestion is a major cause of neurological deterioration in spinal arteriovenous malformations. *Neurosurgery* 2001;48(6):1224-9; discussion 9-30.
63. Doppman JL, Di Chiro G, Dwyer AJ, Frank JL, Oldfield EH. Magnetic resonance imaging of spinal arteriovenous malformations. *J Neurosurg* 1987;66(6):830-4.
64. Dormont D, Gelbert F, Assouline E, et al. MR imaging of spinal cord arteriovenous malformations at 0.5 T: study of 34 cases. *AJNR Am J Neuroradiol* 1988;9(5):833-8.
65. Biondi A, Merland JJ, Reizine D, et al. Embolization with particles in thoracic intramedullary arteriovenous malformations: long-term angiographic and clinical results. *Radiology* 1990;177(3):651-8.
66. Yasargil MG, Symon L, Teddy PJ. Arteriovenous malformations of the spinal cord. *Adv Tech Stand Neurosurg* 1984;11:61-102.
67. Ausman JI, Gold LH, Tadavarthi SM, Amplatz K, Chou SN. Intraparenchymal embolization for obliteration of an intramedullary AVM of the spinal cord. Technical note. *J Neurosurg* 1977;47(1):119-25.
68. Latchaw RE, Harris RD, Chou SN, Gold LH. Combined embolization and operation in the treatment of cervical arteriovenous malformations. *Neurosurgery* 1980;6(2):131-7.
69. Schievink WI, Vishteh AG, McDougall CG, Spetzler RF. Intraoperative spinal angiography. *J Neurosurg* 1999;90(1 Suppl):48-51.
70. Ohata K, Takami T, El-Naggar A, et al. Posterior approach for cervical intramedullary arteriovenous malformation with diffuse-type nidus. Report of three cases. *J Neurosurg* 1999;91(1 Suppl):105-11.
71. Rodesch G, Lasjaunias PL, Berenstein A. Embolization of arteriovenous malformations of the spinal cord. In: Valavanis A, ed. *Interventional neuroradiology*. Berlin: Springer-Verlag; 1993:135.
72. Horton JA, Latchaw RE, Gold LH, Pang D. Embolization of intramedullary arteriovenous malformations of the spinal cord. *AJNR Am J Neuroradiol* 1986;7(1):113-18.
73. Theron J, Cosgrove R, Melanson D, Ethier R. Spinal arteriovenous malformations: advances in therapeutic embolization. *Radiology* 1986;158(1):163-9.
74. Sinclair J, Chang SD, Gibbs IC, Adler JR, Jr. Multisession CyberKnife radiosurgery for intramedullary spinal cord arteriovenous malformations. *Neurosurgery* 2006;58(6):1081-9; discussion 9.
75. el Mahdi MA, Rudwan MA, Khaffaji SM, Jadallah FA. A giant spinal aneurysm with cord and root compression. *J Neurol Neurosurg Psychiatry* 1989;52(4):532-5.
76. Vishteh AG, Brown AP, Spetzler RF. Aneurysm of the intradural artery of Adamkiewicz treated with muslin wrapping: technical case report. *Neurosurgery* 1997;40(1):207-9.
77. Berlis A, Scheufler KM, Schmahl C, Rauer S, Gotz F, Schumacher M. Solitary spinal artery aneurysms as a rare source of spinal subarachnoid hemorrhage: potential etiology and treatment strategy. *AJNR Am J Neuroradiol* 2005;26(2):405-10.
78. Spetzler RF, Zabramski JM, Flom RA. Management of juvenile spinal AVM's by embolization and operative excision. Case report. *J Neurosurg* 1989;70(4):628-32.
79. Menku A, Akdemir H, Durak AC, Oktem IS. Successful surgical excision of juvenile-type spinal arteriovenous malformation in two stages following partial embolization. *Minim Invasive Neurosurg* 2005;48(1):57-62.
80. Cobb S. Hemangioma of the spinal cord associated with skin naevi of the same metamere. *Ann Surg* 1915;65:641-9.
81. Maranattom BV, Cohen-Gadol AA, Wijedicks EF, Kallmes D. Segmental cutaneous hemangioma and spinal arteriovenous malformation (Cobb syndrome). Case report and historical perspective. *J Neurosurg Spine* 2005;3(3):249-52.
82. Gueguen B, Merland JJ, Riche MC, Rey A. Vascular malformations of the spinal cord: intrathecal perimedullary arteriovenous fistulas fed by medullary arteries. *Neurology* 1987;37(6):969-79.
83. Vitarbo EA, Sultan A, Wang D, Morcos JJ, Levi AD. Split cord malformation with associated type IV spinal cord perimedullary arteriovenous fistula. Case report. *J Neurosurg Spine* 2005;3(5):400-4.
84. Halbach VV, Higashida RT, Dowd CF, Fraser KW, Edwards MS, Barnwell SL. Treatment of giant intradural (perimedullary) arteriovenous fistulas. *Neurosurgery* 1993;33(6):972-9; discussion 9-80.
85. Hida K, Iwasaki Y, Goto K, Miyasaka K, Abe H. Results of the surgical treatment of perimedullary arteriovenous fistulas with special reference to embolization. *J Neurosurg* 1999;90(2 Suppl):198-205.
86. Djindjian M, Djindjian R, Rey A, Hurth M, Houdart R. Intradural extramedullary spinal arteriovenous malformations fed by the anterior spinal artery. *Surg Neurol* 1977;8(2):85-93.
87. Barrow DL, Colohan AR, Dawson R. Intradural perimedullary arteriovenous fistulas (type IV spinal cord arteriovenous malformations). *J Neurosurg* 1994;81(2):221-9.
88. Dillon WP, Norman D, Newton TH, Bolla K, Mark A. Intradural spinal cord lesions: Gd-DTPA-enhanced MR imaging. *Radiology* 1989;170(1, Part 1):229-37.
89. Inoue T, Takahashi T, Shimizu H, Matsumoto Y, Takahashi A, Tominaga T. Congestive myelopathy due to cervical perimedullary arteriovenous fistula evaluated by apparent diffusion coefficient values - case report. *Neurol Med Chir* 2006;46(11):559-62.
90. Lai PH, Weng MJ, Lee KW, Pan HB. Multidetector CT angiography in diagnosing type I and type IVA spinal vascular malformations. *AJNR Am J Neuroradiol* 2006;27(4):813-17.
91. Sure U, Wakat JP, Gatscher S, Becker R, Bien S, Bertalanffy H. Spinal type IV arteriovenous malformations (perimedullary fistulas) in children. *Childs Nerv Syst* 2000;16(8):508-15.
92. Cho KT, Lee DY, Chung CK, Han MH, Kim HJ. Treatment of spinal cord perimedullary arteriovenous fistula: embolization versus surgery. *Neurosurgery* 2005;56(2):232-41; discussion 41.
93. Heros RC, Debrun GM, Ojemann RG, Lasjaunias PL, Naessens PJ. Direct spinal arteriovenous fistula: a new type of spinal AVM. Case report. *J Neurosurg* 1986;64(1):134-9.
94. Aminoff MJ, Gutin PH, Norman D. Unusual type of spinal arteriovenous malformation. *Neurosurgery* 1988;22(3):589-91.
95. Ricolfi F, Gobin PY, Aymard A, Brunelle F, Gaston A, Merland JJ. Giant perimedullary arteriovenous fistulas of the spine: clinical and radiologic features and endovascular treatment. *AJNR Am J Neuroradiol* 1997;18(4):677-87.
96. Cosgrove GR, Bertrand G, Fontaine S, Robitaille Y, Melanson D. Cavernous angiomas of the spinal cord. *J Neurosurg* 1988;68(1):31-6.
97. Deutsch H, Jallo GI, Faktorovich A, Epstein F. Spinal intramedullary cavernoma: clinical presentation and surgical outcome. *J Neurosurg* 2000;93(1 Suppl):65-70.
98. Aoyagi N, Kojima K, Kasai H. Review of spinal epidural cavernous hemangioma. *Neurol Med Chir* 2003;43(10):471-5; discussion 6.
99. Cohen-Gadol AA, Jacob JT, Edwards DA, Krauss WE. Coexistence of intracranial and spinal cavernous malformations: a study of prevalence and natural history. *J Neurosurg* 2006;104(3):376-81.
100. Vishteh AG, Sankhla S, Anson JA, Zabramski JM, Spetzler RF. Surgical resection of intramedullary spinal cord cavernous malformations: delayed complications, long-term outcomes, and association with cryptic venous malformations. *Neurosurgery* 1997;41(5):1094-100; discussion 100-1.

- 237–45.
101. Zeygaridis D, Medele RJ, Hamburger C, Steiger HJ, Reulen HJ. Cavernous haemangiomas of the spinal cord. A review of 117 cases. *Acta Neurochir* 1999;141(3):237–45.
 102. Kharkar S, Shuck J, Conway J, Rigamonti D. The natural history of conservatively managed symptomatic intramedullary spinal cord cavernomas. *Neurosurgery* 2007;60(5):865–72; discussion 72.
 103. Sandalcioglu IE, Wiedemayer H, Gasser T, Asgari S, Engelhorn T, Stolke D. Intramedullary spinal cord cavernous malformations: clinical features and risk of hemorrhage. *Neurosurg Rev* 2003;26(4):253–6.
 104. Jallo GI, Freed D, Zareck M, Epstein F, Kothbauer KF. Clinical presentation and optimal management for intramedullary cavernous malformations. *Neurosurg Focus* 2006;21(1):e10.

21. Index

Page numbers followed by f refer to illustrations; page numbers followed by t refer to tables. The abbreviation “aka” means “also known as.”

- 1/3rd rule, superior sagittal sinus occlusion 67
¹⁵O Positron Emission Tomography (PET)
and carotid occlusion 661, 663
2-hexyl cyanoacrylate (Neuracryl) 224
2-hydroxyethyl methacrylate (HEMA) 227
5-Lipoxygenase-activating protein gene 586
- ### A
- Abciximab 251, 416
for treatment of acute ischemic stroke,
320–321
Abciximab (Reopro) (*see also* Glycoprotein
IIb-IIIa Inhibitor), 140t
Abducens nerve 32, 60
blood supply 7t, 9, 24
Aberant internal carotid artery
and pulsatile tinnitus 542
Aberrant internal carotid artery 30
Aberrant subclavian artery (*see* Artery,
subclavian)
Abscess brain
after embolization 248, 405
Absolute ethanol (*see* Ethanol)
Abulia 610, 613
ACAS (Asymptomatic Carotid Atherosclerosis
Study) 646
Acculink for Revascularization of Carotids
in High-Risk Patients
(ARChER) 654t
Acculink stent 347, 358
Accunet embolic protection device 347, 356
Acetazolamide 182
for central retinal artery occlusion 328
Acetyl cholinesterase (ACE) inhibitors 589
Acetylcysteine (Mucomyst) 105, 106, 141
“A-comm syndrome” 455
Acromegaly 403
ACST (Asymptomatic Carotid Surgery Trial)
647
Activated protein C resistance (*see also* Factor
V Leyden mutation) 581t
Activin-receptor-like kinase (ALK1) gene 514
Acute ischemic stroke (*see* Stroke)
Acute lymphoblastic anemia
and moyamoya syndrome 691
Adamkiewicz
artery of. *see* Artery of Adamkiewicz
Adamkiewicz, Albert Wojciek (*see also* Artery,
of Adamkiewicz) 77
Adrenocorticotrophic hormone (ACTH)
393–403
Agalsidase alpha 585
Agalsidase beta 585
Age
risk for stroke 576
Aggrenox (*see* Dipyridamole/Aspirin)
and intracranial stenosis 682
Agnosia
color 613
finger 612t
visual 613
Agraphia 612t, 613
AHA (*see* American Heart Association)
Air emboli 93, 94
Alagille syndrome
and moyamoya syndrome 691
Albumin
and subarchnoid hemorrhage 478t
Albuterol (aka Proventil, Ventolin) 108t
Alcohol use
and intracranial aneurysms 439
and ischemic stroke risk 576
Alexia 613
Alien hand 613
Allcock maneuver 112
Allen test 104
Alligator Retrieval device 251, 313
Alpha-1-antitrypsin deficiency 437
and fibromuscular dysplasia (FMD) 671
Alpha-galactosidase A, 585
Alteplase (Activase) 302–303
Alupent (*see* Metaproterenol)
Amaurosis fugax 608
American Academy of Neurology (AAN)
website 636
American Heart Association (AHA)
recommendations
alcohol consumption 577
asymptomatic carotid stenosis 647
exercise 597
smoking cessation 598
symptomatic carotid stenosis 646

- American Heart Association (AHA) (*cont'd*)
 weight reduction 595
 website 636
- American Society Of Interventional And
 Therapeutic Neuroradiology
 (ASITN) 87
 quality improvement guidelines 89t
- American Society of Interventional and
 Therapeutic Neuroradiology
 (ASITN)
 and intracranial angioplasty and stenting
 684–685
- American Society Of Neuroradiology (ASNR)
 87
 quality improvement guidelines 89t
- American Society of Neuroradiology (ASNR)
 and intracranial angioplasty and stenting
 684–685
- American Stroke Association (ASA)
 website 636
- Amicar (*see* Epsilon-aminocaproic acid)
- Aminophylline 108t
- Amnesia 574, 613
- Amobarbital 192, 195–198, 272
 in pre-embolization testing 199–202,
 223–224
- Amplatz Goose Neck microsnare
 in acute stroke 312, 312–312
- Amygdalohippocampectomy 192
- Amytal (*see* Sodium Amobarbital)
- Anamnestic symptoms 573, 574
- Anaphylactic reaction 107
- Ancrod 303
- Aneurysmal bone cyst 701
- Aneurysmal subarachnoid hemorrhage (*see*
also Subarachnoid hemorrhage)
 462–480
- Aneurysms 433–461
 anatomy 434f
 anterior cerebral 455–456
 anterior choroidal 454
 anterior communicating 455
 anterior inferior cerebellar 458–459
 associated with brain AVMs 523–524
 basilar apex 456–457
 and moyamoya disease 694
 basilar trunk 458
 carotid bifurcation 454
 carotid cave 453
 cavernous segment 450–452
 conditions associated with 435–439
 dissecting 489–490, 491
 dolichoectatic, fusiform, and serpentine 491
 in elderly patients 484–485
 endovascular treatment
 a brief history 460–461
 classification 444–445
 results 446–447
- Aneurysms (*cont'd*)
 familial 435
 giant 486–489
 infectious 485–487
 treatment algorithm 487t
 intracranial 111
 intranidal 132
 middle cerebral 456
 mycotic 584
 paraclinoid 452–453
 pathology 433–434
 pediatric 480–481
 posterior cerebral 457–458
 posterior circulation 456–460
 posterior communicating 449–450,
 453–454
 posterior inferior cerebellar 459–460
 superior cerebellar 457–458
 superior hypophyseal 453
 surgical results 444–445
 traumatic 492–493
 treatment 143–176
 awake versus asleep 144–145
 clip versus coil 448–449
 endovascular
 aneurysm access technique 156–157
 balloon-assisted aneurysm coiling
 161–162
 coiling 148–168
 coiling technique 157–158
 complications 168–174
 “double catheter” coiling technique
 167–168
 microcatheter selection 149–152
 parent vessel sacrifice 174–176
 partial coiling 168
 recurrence after coiling 173–174
 small aneurysms 160–161
 stent-assisted aneurysm coiling
 162–167
 vascular access phase 145–148
 indications and contraindications 143
 unruptured 434–444
 with mass effect 449–450
 natural history 439–443
 prevalence 434–434
 vertebrobasilar junction 459
- Angiitis 575
 definition 572
 primary CNS
 vs. Call-Fleming syndrome
 604–605t
- Angioedema (hemi-oro-lingual) 321
 with IV t-PA for acute stroke 308
- Angiofibroma
 spine 701
- Angiogenic factors
 and moyamoya disease 686–687

- Angiographic control
 - in balloon test occlusion 181–182
- Angiographic equipment
 - flat panel technology 137, 141
 - specifications 136
- Angiography
 - 3-D imaging 122, 132, 136, 137, 138
 - in acute stroke 309–310
 - biplane imaging 95, 136, 137
 - of brain AVMs 517
 - and brain AVMs 519
 - and cavernous malformations 564
 - and dAVFs 542
 - and direct CCFs 554
 - and Ehlers-Danlos Type IV 555
 - and giant aneurysms 488
 - history 87–88
 - Huber maneuver 554
 - intraoperative 107, 109
 - magnetically guided 141
 - Mehringer-Hieshima maneuver 554
 - and moyamoya disease 688
 - pediatric angiography 109
 - and penetrating neck injury 669
 - in pregnant patients 482
 - spinal 122
 - intraoperative 132
 - Type I, Dural arteriovenous fistula 702
 - Type II, Intramedullary arteriovenous malformation 706
 - Type IV, Intradural perimedullary arteriovenous fistula 709
 - and subarchnoid hemorrhage 463
 - and vasculitis 573, 600, 601, 602
 - and vasospasm 470
- Angioguard 356
- Angiojet 319, 416, 419, 422
- Angiolipoma
 - spine 701
- Angioma Alliance 561
- Angiomax (*see* Bivalirudin)
- Angiopathy
 - benign cerebral 604. *see also* Call-Fleming syndrome
 - definition 572
 - postpartum cerebral 604. *see also* Call-Fleming syndrome
- Angioplasty
 - for acute ischemic stroke 313–314
 - for treatment of vasospasm 476
- Angioplasty and stenting (*see also* Carotid angioplasty and stenting)
 - and fibromuscular dysplasia (FMD) 672
- Angiosarcoma
 - spine 701
- Angio-Seal 103
- Anomia
 - color 613
 - object 613
- Anosognosia 612
- Anterior choroidal syndrome 454
- Anterior clinoid process 33, 34f
- Anterior disconnection syndrome 610t
- Anticardiolipin antibody 581, 581t
- Anticoagulants
 - in secondary stroke prevention 627
- Anticoagulation
 - and carotid stenosis 652
- Antifibrinolytic therapy, 464–465 478t
- Antiphospholipid antibody 575, 581, 581t, 584
- Antiplatelet agents
 - post-embolization 242
 - in secondary stroke prevention 627
- Antiplatelet therapy
 - and arterial dissection 665, 667, 669
 - and carotid stenosis 650–652
 - and fibromuscular dysplasia (FMD) 672
- Antithrombin III deficiency 581, 581t
- Anton syndrome 613t
- Aortic aneurysms 438
- Aortic arch
 - anatomy 1
 - angiography of 99, 112
 - atheroma 577
 - bovine arch 1, 2f
 - classification 3
 - coarctation, and pediatric aneurysms 480
 - effects of aging on 2
 - variants 1–2
 - and the vertebral artery 55
- Apathy 613
- Apert syndrome
 - and moyamoya syndrome 691
- Aphasia 573, 610, 613, 614t
 - Broca 611t, 612t
 - classification 611t
 - conduction 611t
 - expressive 611t
 - global 611t
 - receptive 611t
 - transcortical motor 610, 611t
 - transcortical sensory 611t
 - Wernicke 611t
- Aphonia 616t
- Aplastic anemia
 - and moyamoya syndrome 691
- Apraxia 610
 - drressing 612
 - gaze 613t
- Arachnoid granulation 66f
- A Randomized Trial of Unruptured Brain Arteriovenous Malformations (ARUBA) 518

- ARCHEr (Acculink for Revascularization of Carotids in High-Risk Patients) 654t
- Argatroban 209, 588
- Arterial dissection
during aneurysm treatment 172–173
and subarachnoid hemorrhage 462
- Arteriopathy
definition 572
- Arteriovenous fistula (AVF) (*see also* dural Arteriovenous Fistula (dAVF))
Carotid-Cavernous 112
epidural/paraspinal AVF 296
extracranial 259
 embolization 290–291
 mandibular 415
 pial. *see* Pial arteriovenous fistula
 spinal 124, 132, 133, 701–704
- Arteriovenous malformation (AVM)
brain 511–527
 anatomic features 512–513
 angiography of 111
 and associated aneurysms 523–524
 AVM volume estimation 523t
 in children 525–526
 Embolization 199
 embolization 522–523
 curative 242
 hemorrhage post-op 251
 history 246–247
 incomplete 242
 pre-operative 242
 pre-radiosurgery 242
 epidemiology 512
 etiology 511
 familial intracranial AVMs 513
 hemorrhage
 management 252
 and intracranial aneurysms 438
 large and giant 524–525
 lifetime risk of hemorrhage 515
 management 517–523
 natural history 514–515
 normal perfusion pressure
 breakthrough 519
 pathology 511
 physiology 512
 and pregnancy 526–527
 presentation 516–517
 risk factors for hemorrhage 516
 Spetzler-Martin grading system 518t
 steal phenomenon 512
 and subarachnoid hemorrhage 462
 surgery 518–520
 post-operative brain edema 519–520
 extracranial 259
 embolization 290–291
 spinal 123, 132, 704–708
- Arteritis
definition 572
Giant cell 599t, 600
Heubner's 602. *see also* Syphilis, meningovascular
Takayasu 599t, 600
temporal, 600. *see also* Arteritis, Giant cell
- Artery
accessory meningeal 6t, 19f, 20t, 21–22, 25f
anastomoses 10
branches
 anterior descending ramus (aka inferopalatine branch) 21
 descending companion ramus 21
 intracranial ascending ramus (aka intracranial branch) 21
 lateral territory ascending ramus (aka posterior branch) 21
 medial territory ascending ramus (aka inferomedial branch) 21
 cranial nerve blood supply 7t
accessory middle cerebral artery 46
of Adamkiewicz 77, 123, 124, 127f, 132
angular 5f, 13, 47f, 48
anterior auricular 16
anterior cerebral 36, 40–45, 41f, 44f
 A1 segment 40–42, 40t, 61t
 A2 segment 42–43
 A3 branches 43–45
 A4 segments 43
 A5 segments 43
 accessory 42
 cranial nerve blood supply 7t
 occlusion 610t
 syndrome 610
 territory 609f
anterior choroidal 38–39, 38f, 454
 occlusion 609
 syndrome 609
 territory 609f
 and Wada test 197
anterior communicating 39, 40t, 41–42, 41f, 42
 branches
 perforating 41
 recurrent artery of Heubner 41
anterior deep temporal 6t, 23, 25f
anterior falx 6t, 20t, 35f, 36
 anastomoses 19f
anterior inferior cerebellar 7t
anterior inferior cerebellar (AICA) 59–60
 anastomoses, 58f
 syndrome 617, 617t
 territory 617f
anterior internal frontal 44f
anterior jugal 5, 13
anterior meningeal 20t
anterior parietal 47, 47f

Artery (*cont'd*)

anterior spinal 59, 74, 75, 77, 77t, 78
communicating artery 59
Type IV, Intradural perimedullary
arteriovenous fistula 709
anterior temporal artery 46
anterior temporal (branch of MCA)
47f, 49
anterior temporal (branch of PCA) 50f, 53
anterior tympanic 18, 25f
anastomoses 16
aorta 75t, 76
aortic arch. *see* Aortic arch
ascending cervical 7t, 11, 75, 75t, 77t, 120t
ascending palatine 11–12, 19f
branches
glossal 12
hamular 12
tonsillar 12
ascending pharyngeal 4f, 6t, 7, 7t, 9–11,
20t, 27, 75t, 77t, 120t
branches 4, 9
cranial nerve blood supply 7t
inferior tympanic branch 6t, 8
middle pharyngeal branch 10
superior pharyngeal branch 10
variants 15
auricular 15
axillary
puncture 127
basal tentorial 31
basilar 36, 52, 59–61, 61t
cranial nerve blood supply 7t
occlusion 322–323
perforators 60
territory 615f
brachial
puncture 104, 127, 187
buccal 22, 25f
calcarine 50f, 52, 53, 54
callosomarginal 44, 44f
capsular arteries of McConnell 33
caroticotympanic 6t, 30
carotid. *see also* Artery, common carotid;
Artery, external carotid; Artery,
internal carotid
catheterization 99, 100, 131
central (branch of MCA) 47, 47f
central retinal 34, 35f
occlusion 327–329
of cervical enlargement 77t
ciliary 35, 35f
circumflex 51, 52
common carotid 3, 7, 55
costocervical trunk 75, 75t, 76, 77t
catheterization 121, 129, 130
cryothyroid
anastomoses 8

Artery (*cont'd*)

Davidoff and Schechter, artery of, 54. *see*
also Artery, posterior cerebral,
meningeal branch
deep auricular 17, 25f
deep cervical 7t, 75, 75t, 77t, 120t
dorsal (aka medial) clival 32
dorsal meningeal 31f, 32
dorsal nasal 36
ethmoidal 6t, 20t, 36
posterior 35f
external carotid 4, 4f, 25f, 75t
branches 3, 4, 4f, 5
facial 4f, 5f, 11–14
anastomoses 13
branches 11–13
territories 13
variants 13
falx cerebelli 59
femoral 99f, 103f
puncture 98
foramen rotundum 6t, 23, 25f
anastomoses 33
cranial nerve blood supply 7t
frontopolar 42, 44f
Gasserian ganglion 33
greater palatine 19f, 23, 25f
branches
lesser palatine 23
palatine 23
septal 24
Heubner. *see* Artery, recurrent artery of
Heubner
hippocampal 50f, 53
hypoglossal 4f, 9, 20t, 59
ileolumbar 75t, 76, 120t
catheterization 130
inferior alveolar (aka dental) 22, 25f
branches
incisive 22
mental 22
mylohyoid 22
inferior hypophyseal 31f, 32
inferior labial 5f, 13
inferior masseteric 5f, 12
inferior palpebral
anastomoses 13
inferior parietal 36f
inferior pharyngeal 4f, 9
inferior temporal 53
inferior tympanic 4f
inferolateral trunk 6t, 20t
cranial nerve blood supply 7t
infrahyoid 8
infraorbital 6t, 23, 25f
branches
anterior superior alveolar 23
middle superior alveolar 23

- Artery (*cont'd*)
- naso-orbital 23
 - orbital 23
 - palpebral 23
 - zygomatic 23
 - cranial nerve blood supply 7t
 - innominate 1
 - intercostal 75t, 76, 77t, 120t, 122, 123, 125f, 132
 - catheterization 121, 128, 129
 - superior 120t, 124f, 129
 - supreme 120t, 129
 - internal auditory (aka labyrinthine) 60, 61
 - internal carotid 4f, 7, 36, 40t, 41f, 61t
 - aberrant course 8
 - anastomoses 11
 - cavernous segment 6t, 20t, 30–33, 31f, 32f
 - lateral trunk 31f
 - posterior trunk 31f
 - cervical segment 26–27
 - classification 26f
 - clinoidal segment 33, 34f
 - communicating segment 37–39
 - hypoplasia 27
 - hypoplasia or agenesis 33
 - ischemic syndromes 608
 - ophthalmic segment 33–36
 - petrous segment 6t, 29–30, 29f
 - caroticotympanic 30
 - periosteal branch 29
 - Vidian (aka artery of pterygoid canal) 30
 - siphon 112
 - supraclinoidal segment
 - cranial nerve blood supply 7t
 - variants 15
 - internal frontal 45
 - internal iliac 75t
 - internal maxillary 4f, 17–24
 - anastomoses 10, 35, 36
 - branches
 - accessory meningeal 21–22
 - anterior deep temporal 23
 - anterior tympanic 18
 - buccal 22
 - deep auricular artery 17
 - foramen rotundum 23
 - greater palatine 23–24
 - inferior alveolar (aka dental) 22
 - infraorbital 23
 - masseteric 22
 - middle deep temporal 22
 - middle meningeal 18–20
 - posterior superior alveolar 23
 - pterygoid 22
 - pterygo-vaginal 23
 - sphenopalatine 24
 - Vidian 23
- Artery (*cont'd*)
- deep-type 25f
 - superficial-type 25f
 - intrinsic cord arteries 78
 - jugal trunk 5f, 12–13
 - branches
 - bucco-masseteric (aka buccal) 12
 - posterior jugal 13
 - jugular 9, 20t
 - lacerum segment 30
 - lacrimal 35, 35f
 - lateral clival 32
 - lateral nasal 5f
 - lateral nasal (aka alar) 13
 - lateral sacral 75t, 76
 - lateral spinal 75
 - lateral trunk (aka inferolateral trunk, artery of the inferior cavernous sinus, or lateral main stem) 32
 - left subclavian 1
 - lenticulostriate 46
 - lenticulostriates 42
 - lingual 4f, 11
 - branches
 - deep lingual 11
 - dorsal lingual 11
 - sublingual 11
 - suprahyoid 11
 - lingulofacial trunk 7
 - lumbar 75t, 76, 77t, 120t, 122, 123, 126f, 132
 - catheterization 121, 128, 129
 - mandibular 6t
 - marginal tentorial (aka Bernasconi and Cassinari) 20t, 31
 - masseteric 22
 - mastoid 14, 20t
 - branches
 - ascending 14
 - descending 14
 - posteromedial, 14
 - medial branch group (aka capsular arteries of McConnell) 33
 - median sacral 75t, 76
 - meningohypophyseal trunk 6t, 32
 - cranial nerve blood supply 7t
 - middle cerebral 36, 39, 45–49
 - candelabra 112
 - M1 segment 46, 61t
 - M2 segment 46
 - M3 segments 46
 - M4 branches 47
 - syndrome 610
 - territory 610f
 - middle deep temporal 22, 25f
 - middle internal frontal 44f
 - middle jugal 13
 - middle meningeal 6t, 18–20, 18–21, 19f, 20t, 25f, 36

Artery (*cont'd*)

anastomoses 10, 35
branches
 accessory meningeal 18
 frontal 19f, 20
 masseteric 25f
 meningolacrimal 18
 parietal 19, 19f
 petrosquamosal 18, 19f
 petrous 18, 19f
 sphenoidal 18, 19f
 temporo-occipital (aka temporal)
 18, 19f
cranial nerve blood supply 7t
frontal branch 6t
sphenoidal branch 6t
middle mental 5f, 13
middle pharyngeal 4f
middle temporal (aka posterior deep
temporal; branch of PCA) 17,
50f, 53
middle temporal (branch of MCA)
47f, 48
musculospinal 4f, 9
nasal arcade 13
neuromeningeal trunk 4f, 6t, 7t
 branches 9
 territories 9
occipital 4f, 5f, 7, 7t, 14–15, 20t, 27, 75t,
77t, 120t
 anastomoses 8, 10, 16
 descending branch 14
 territories 15
 variants 15
occipital (branch of posterior auricular) 15
occipitoauricular trunk 8
ophthalmic 6t, 20t, 33, 33–36, 34f, 39
 anastomoses 13, 19f, 33
 branches
 nasal 13
 cranial nerve blood supply 7t
 occlusion 328
 recurrent meningeal 6t
orbitofrontal (branch of ACA) 42, 44f
orbitofrontal (branch of MCA) 47, 47f
P1 segment 61t
palpebral 36
paracentral, 44f, 45
parietal 45
parietal (branch of posterior auricular) 15
parieto-occipital 50f, 52, 53, 54
parotid 15
of Percheron 612
pericallosal 44, 44f
persistent hypoglossal 11, 28, 28f
persistent olfactory 41
persistent otic 27–28, 30
persistent stapedial 8, 27, 30

Artery (*cont'd*)

persistent trigeminal 27–28, 33
 and Wada test 197
petrosquamosal 20t
posterior auricular 4f, 15–16
 anastomoses 8
 branches
 auricular 15
 occipital 15
 parietal 15
 parotid 15
 sternocleidomastoid (aka muscular
 branch) 15
 stylomastoid 15
 variants 15, 16
posterior cerebral 36, 39, 44, 49–54, 50f, 61
 cranial nerve blood supply 7t
 meningeal branch (aka Davidoff and
 Schechter) 20t, 51
 P1 segment 40t, 50–51, 52
 P2 segment 51–54, 54
 P3 segment 52, 54
 P4 segment 54
 perforators 50, 51
 syndrome 612
 mimicking MCA occlusion 613, 614t
 territory 612f
 and Wada test 197
posterior communicating 36, 37, 37f, 38f,
40t, 50f, 61t
posterior deep temporal 25f
posterior inferior cerebellar (PICA) 56,
57–59, 57f, 74, 75, 78, 130
 syndrome 618t
 territory 617f
posterior internal frontal 44f
posterior meningeal 20t, 27, 56, 59
posterior parietal 47f, 48
posterior spinal 75
posterior superior alveolar 23, 25f
posterior temporal (branch of MCA) 47f, 48
posterior temporal (branch of PCA) 53, 54
posterolateral choroidal 50f, 52
posterolateral spinal 74–75, 77t, 78, 78f
 Type IV, intradural perimedullary
 arteriovenous fistula 709
posteromedial choroidal 50f, 51, 52, 52f,
53, 54
precentral 47, 47f
prefrontal 47, 47f
prevertebral 9
proatlantal intersegmental 28–29, 28f, 59
pterygoid 22
pterygo-vaginal 23, 25f
radial
 puncture 104, 127
radicular 76–77, 78f
radiculomedullary 122

- Artery (*cont'd*)
- radiculomedullary 77, 77t, 78f
 - radiculopial 77, 77t, 78f, 122
 - recurrent artery of Heubner 41, 42, 46, 610
 - recurrent artery of the foramen lacerum 33
 - recurrent meningeal 20t, 35, 35f
 - anastomoses 33
 - sacral
 - anterior 120t, 130
 - lateral 120t, 130
 - sphenoidal 20t
 - sphenopalatine 23, 25f, 292
 - anastomoses 36
 - branches
 - lateral nasal (aka posterior lateral nasal) 24
 - septal 24
 - spinal
 - anterior 122, 123, 123f, 127f, 130
 - posterolateral 122, 123, 130
 - spinal arterial anatomy 78f
 - splenic (aka posterior pericallosal) 44, 50f, 54
 - sternocleidomastoid 8
 - sternocleidomastoid (aka muscular branch) 15
 - sternocleidomastoid (aka muscular branches of occipital artery) 14
 - stylomastoid 5f, 14, 15–16
 - cranial nerve blood supply 7t
 - subarcuate 60
 - subclavian 55, 56f, 75, 75t
 - aberrant left subclavian artery 2f
 - aberrant right subclavian artery 2, 2f
 - branches 3, 3f
 - submandibular 12
 - submental 5f, 12, 13
 - superficial temporal 4f, 6t, 16–17, 25f
 - anastomoses 16, 19f, 35, 36
 - branches
 - anterior auricular 17
 - frontal 17
 - middle temporal (aka posterior deep temporal) 17
 - parietal 17
 - transverse facial 17
 - zygomatico-orbital 17
 - superior anterior communicating 43
 - superior cerebellar
 - syndrome 616, 617t
 - territory 616f
 - superior cerebellar (SCA) 58f, 60, 60–61
 - cranial nerve blood supply 7t
 - superior hypophyseal 32, 36
 - superior intercostal 75t
 - superior labial 5f, 13
 - superior laryngeal 8
 - anastomoses 8
 - superior parietal 44f
- Artery (*cont'd*)
- superior pharygeal 4f, 6t
 - superior thyroid 4f, 7, 27
 - anastomoses 8
 - branches 8
 - territories 8
 - variants 9
 - suprascapular
 - anastomoses 8
 - supratrochlear 36
 - supreme intercostal 75t, 76
 - tempero-occipital (aka temporal) 47f, 48
 - temperopolar 47f, 49
 - temporo-occipital 20t
 - tentorial 31f
 - thyrocervical trunk 75t
 - anastomoses 8
 - catheterization 121, 130
 - thyrolingual trunk 7
 - thyrolingulofacial trunk 8
 - tonsillar 5f
 - tonsillar 12
 - transverse facial 6t, 16
 - branches
 - jugal 16
 - parotid 16
 - superior masseteric 16
 - zygomatic 16
 - vertebral 11, 20t, 55–59, 56f, 61t, 74, 75, 75t, 77t, 120t, 123f
 - anastomoses 11
 - branches
 - anterior meningeal 55
 - artery of cervical enlargement 55
 - muscular 55
 - spinal 55
 - catheterization 100, 121, 130
 - V1 segment 55
 - V2 segment 55–56, 65
 - V3 segment 56
 - V4 segment 56–59
 - vertebral segmental 7t
 - Vidian (aka artery of pterygoid canal) 23, 27, 30
 - zygomatico-orbital 16–17
- ARUBA (A Randomized Trial of Unruptured Brain Arteriovenous Malformations) 518
- ASITN (*see* American Society Of Interventional And Therapeutic Neuro-radiology; American Society of Interventional and Therapeutic Neuroradiology)
- ASNR (*see* American Society Of Neuroradiology; American Society of Neuroradiology)
- Aspigoillus*
- and infectious aneurysms 486

- Aspirin 141, 207, 290, 425, 428, 578t, 579, 599, 634t, 635t
 and carotid stenosis 650–651
 and intracranial stenosis 680–682
 post-embolization 242
- Asymptomatic Carotid Atherosclerosis Study (ACAS) 646
- Asymptomatic Carotid Surgery Trial (ACST) 647
- Ataxia 614t, 616, 617t
 optic 613t
- Atherosclerosis 575, 582, 641–642
 aortic 128
 aortic arch 2
 Atherosclerotic plaque 574
 carotid
 angiography 111
 and the carotid bifurcation 642
 in the intracranial circulation 679–685
 medical management 649–652
 and moyamoya syndrome 691
 pathophysiology 641
 and vertebral artery stenosis 663
 vertebral
 angiography 111
- Atorvastatin 591
 and intracranial stenosis 682
- Atrial fibrillation 575, 577, 578t, 599, 635t
- Atrial flutter 577
- Atrial myxoma 575
- Atrial natriuretic factor 467
- Atropine 108t, 140, 184, 390
- Auditory nerve 60
 blood supply 7t, 24
- Australian Urokinase Stroke Trial 322
- Avandamet (*see* Metformin)
- Azathioprine 600–603
- Azygos anterior cerebral artery 41f, 42, 43f, 61t
- B**
- Back pressure
 in balloon test occlusion 181
- Balint syndrome 613t, 615t
- Balloon 243
 calibrated leak 247
 detachable 227, 244, 274, 297
 technique 237–239, 284–285
- Goldvalve 227
- Guardwire 186–187
 technique 190–191
- Hyperform 186–187, 229, 238, 250, 275, 287, 392, 412
 technique 189
- Hyperglide 221, 419, 421
 technique 189
- Maverick 314, 378
- Balloon (*cont'd*)
 NC Ranger 419, 421
 NC Raptor 419, 421
 Savvy 392
- Balloon-assisted aneurysm coiling 161–162
- Balloon test occlusion 179
 complications 184
 and direct CCFs 243
 history 179
 indications 183
 predictive power 180
 rationale 179–180
 technique 184–186
 venous 388–389
 complications 389
 technique 392–393
- Barbiturate coma 94
- Barrow classification of carotid-cavernous fistulas 547
- Barthel index 636
- Basic fibroblast growth factor
 and moyamoya disease 686
 and moyamoya syndrome 694
- BASICS (Basilar Artery International Cooperation Study) 322
- Basilar Artery International Cooperation Study (BASICS) 322
- BEACH (Boston Scientific EPI-A Carotid Stenting Trial for High Risk Surgical Patients) 654t
- Bead Block 226–227, 246, 274
 and spinal vascular lesions 707
- Beauty parlor stroke syndrome 668
- Behcet's disease 604
- Behcet's disease
 and moyamoya syndrome 691
- Benadryl (*see* Diphenhydramine)
- Benedikt syndrome 614t
- Bernoulli principle 419
- Bicêtre neonatal evaluation score 529t
- Bivalirudin 210, 588
- Bleeding intracranial
 embolization 245
- Blood flow velocity 182
- Borden classification, dAVFs 539, 543–544
- Boston Scientific EPI-A Carotid Stenting Trial for High Risk Surgical Patients (BEACH) 654t
- Bottoms up dissection 668
- Bovine arch 1, 2f
- Bradycardia 390
- Brain arteriovenous malformation (AVM)
 and moyamoya syndrome 691
- Brain natriuretic factor 467
- Brainstem evoked responses (BAER) 272
 in pre-embolization testing 223
- Brainstem glioma
 and moyamoya syndrome 691

- Brethaire (*see* Terbutaline)
 Brevital (*see* Sodium Methohexital)
 Bridging Trial (*see* Emergency Management of Stroke Bridging Trial)
 British Aneurysm Nimodipine Trial (BRANT) 471
 Bronchospasm 108t
 Bruit
 carotid 608
Bubbles 93
 Buddy wire technique 267, 351
 Bupivacaine 196
 Bupropion (Zyban) 598
 and intracranial aneurysms 439
 Buscopan (*see* Hyocine-N-butylbromide)
- C**
- CABERNET (Carotid Artery Revascularization Using the Boston Scientific FilterWire EX/EZ and the EndoTex NexStent), 654t
 CADASIL (*see* Cerebral Autosomal Dominant Arteriopathy with Subcortical Infarcts And Leukoencephalopathy)
 Cadence syringe 377, 377f
 Calcium channel blockers
 and traumatic subarachnoid hemorrhage 493
 Caldwell view 96f, 97t
 Call-Fleming syndrome 604
 CAPTURE (Carotid Acculink/Accunet Post Approval Trial to Uncover Rare Events) 654t
 Carbonic anhydrase inhibiting drugs
 and Wada test 193
 Cardiac abnormalities
 and subarchnoid hemorrhage 468–469
 Cardiac arrhythmia 575
 Cardiac failure
 high output
 in Vein of Galen malformations 244
 Cardiac myxoma
 and pediatric aneurysms 481t
 Cardiomyopathy 580
 Cardioversion 579
 CaRESS (Clopidogrel and Aspirin for Reduction of Emboli in Symptomatic Carotid Stenosis) 654t
 Carotid Acculink/Accunet Post Approval Trial to Uncover Rare Events (CAPTURE) 654t
 Carotid and Vertebral Transluminal Angioplasty Study (CAVATAS) 656t, 657
- Carotid angioplasty and stenting 652–660
 in acute stroke 323–325
 brief history 652–653
 carotid artery origin lesions 361–363
 versus carotid endarterectomy 659–660
 embolic protection devices 356–357
 indications and contraindications 347–348
 list of trials 654–655t
 management of complications 354–356
 patient preparation 348–349
 rationale 653–656
 recurrent stenosis after 659
 risk factors for complications 354
 technique 349–354
 Carotid Artery Revascularization Using the Boston Scientific FilterWire EX/EZ and the EndoTex NexStent (CABERNET), 654t
 Carotid Artery Stenosis with Asymptomatic Narrowing: Operation versus Aspirin (CASANOVA) 646–647
 Carotid Artery Stenting With Emboli Protection Surveillance-Post-Marketing Study (CASES-PMS) 655t
 Carotid blow-out syndrome 259
 endovascular treatment 293
 complications 293
 Carotid bulb 26
 Carotid cave 34f
 Carotid-cavernous fistula (CCF) 229
 direct 553–555
 embolization 243, 411–412
 indirect 547–549
 Carotid dissection 664–667
 and pulsatile tinnitus 541
 Carotid Duplex ultrasonography 648–649
 Carotid endarterectomy 642–649
 versus carotid angioplasty and stenting 659–660
 Carotid occlusion
 atherosclerotic
 asymptomatic 660
 symptomatic 660–663
 Carotid Occlusion Surgery Study (COSS) 663
 Carotid Revascularization Endarterectomy versus Stent Trial (CREST) 655t, 656t, 657–658
 Carotid Revascularization With ev3 Arterial Technology Evolution (CREATE) 655t
 Carotid siphon 31, 32, 32f
 Carotid stenosis
 asymptomatic 646–647
 high risk patients 645–646, 653
 intraluminal thrombus 659–660
 medical management 649–652

- Carotid stenosis (*cont'd*)
 radiographic evaluation 647–648
 risk factors 642
 symptomatic 642–646
 tandem lesions, 653 659–660
 timing of treatment 659
 ulcerated plaque 659–660
- Carotid stenting
 for dissection or pseudoaneurysm 358
- Carotid-vertebrobasilar anastomoses
 27–29, 28f
- CASANOVA (Carotid Artery Stenosis with Asymptomatic Narrowing: Operation versus Aspirin) 646–647
- CASES-PMS (Carotid Artery Stenting With Emboli Protection Surveillance-Post-Marketing Study) 655t
- Catheter
 Angioptic 104, 110
 Angled Taper 91f, 91t, 119, 120f, 130
 Berenstein 110, 130, 264–265, 387, 396
 Berenstein Large Lumen Balloon Guide 210, 211t
 CK-1 91f, 91t
 Cobra 119, 120f, 128, 129
 Envoy 197, 210, 211t, 264, 387, 391, 396, 419
 Glidecath 195, 265, 387, 396
 Guider Softip 210, 211t, 253, 264
 H1 (aka Headhunter) 91f, 91t
 Harwood-Nash 110
 Magic 198
 Mikaelson 265
 Mikaelsson 119, 120f, 128–131
 Neuron 210, 211t, 213–214, 222
 Newton 91f, 91t
 Northstar Lumax 210, 211t, 212, 253, 265, 382, 391, 407, 419
 Penumbra Reperfusion 419
 Prowler Plus 287
 RDC 119, 120f
 Runway 265
 Simmons 265
 Simmons 1, 91f, 91t, 119, 120f, 128–131, 397
 Simmons 2, 91f, 91t, 102f
 Simmons 3, 91f, 91t
 Spinaker 198
 Straight 119, 120f, 128
 Ultraflow 198
 Vertebral 91f, 91t, 130
- CAVATAS (Carotid and Vertebral Transluminal Angioplasty Study) 656t, 657
- Cavernous malformation
 spinal cord 701, 710
 and subarchnoid hemorrhage 462
- Cavernous malformations 561–567
 brainstem 566–567
 CCM genes 563
 epidemiology and risk factors 561
 familial form 562–563
 imaging 563–564
 management 564–567
 natural history 564
 pathophysiology 562
 presentation and clinical features 564
 spinal 561
 sporadic versus familial 561
- Cavernous sinus sampling 403
 technique 398
- Centers for Medicare and Medicaid Services (CMS)
 and carotid stenting 347
- Central retinal artery occlusion 327–329
- Central volume principle 332
- Cerebral Amyloid Angiopathy (CAA) 575, 579
- Cerebral arterial dolichoectasia
 and moyamoya syndrome 691
- Cerebral Autosomal Dominant Arteriopathy With Subcortical Infarcts And Leukoencephalopathy (CADASIL) 575, 579, 586
- Cerebral Autosomal Recessive Arteriopathy With Subcortical Infarcts And Leukoencephalopathy (CARASIL) 586
- Cerebral blood flow
 CT perfusion imaging of 330–336
 normal values 331
- Cerebral blood flow (CBF) imaging
 and moyamoya disease 689
- Cerebral blood volume
 definition 330
- Cerebral edema
 management 630–631
- Cerebral oximetry
 in balloon test occlusion 181
- Cerebral salt wasting 467
- Cerebral vasospasm (*see* Vasospasm)
- Cerebral venous thrombosis (CVT) 415
 clinical presentation 415
 endovascular treatment 416
 indications 416–417
 technique 417–422
 imaging findings 416
 treatment 416
- Cerebritis
 paraneoplastic 604
- CHADS score 578t, 579
- Chantix (*see* Varenicline (Chantix))
- Chiari II malformation 73, 74f
- Chito-seal 101
- Chlamydia pneumoniae* 641

- Cholesterol
 - and carotid stenosis 642
 - reduction 650
- Choroidal blush 35, 329
- Choroidal point 57f, 58f
- Churg-Strauss syndrome 600t, 601–602
- Cigarette smoking 575, 580, 598, 635t
 - and carotid stenosis 642, 650
 - and fibromuscular dysplasia (FMD) 671
 - and intracranial aneurysms 439
- Circle of Willis 40
- Circle Of Willis 112
- Circle of Willis
 - and moyamoya disease 687, 689
- Claude syndrome 614
- Clopidogrel and Aspirin for Reduction of Emboli in Symptomatic Carotid Stenosis (CaRESS) 654t
- Clopidogrel (Plavix) 141, 207, 290, 428, 634t
 - and carotid stenosis 651
 - post-embolization 242
- Closure device 102, 103
- CNS angitis 602
- CNS granulomatous angitis 602
- Coagulopathy 575, 580, 584
- Cobb syndrome 708
- Cocaine 583
 - and moyamoya syndrome 691
 - in pregnant patients with SAH 483
 - and stroke risk 603–604
 - and subarachnoid hemorrhage 462, 470
- Coffee
 - and intracranial aneurysms 439
- Cognard classification, dAVFs 539, 543–544
- Coil pusher
 - Pusher 10, 239
 - Trupush 239
- Coils
 - 10-system versus 18-system 153
 - ACT spherical 228
 - Axiom 228
 - basic shapes 153f
 - Berenstein Liquid coils 228, 275
 - bioactive 154
 - detachable 228, 275, 407, 409
 - technique 239–240, 286
 - detachable coated 228
 - detachable fibered 228, 275, 407
 - electrolytic coil detachment and the heart 154
 - fibered GDC 228, 275
 - fibered platinum 227
 - GDC, 228 275
 - GDC (Guglielmi Detachable Coil) 153, 155
 - Helipaq, 228
 - Hilal 274
 - Hydrocoil 229, 243, 275
 - HydroCoils 154–155
 - Matrix 228, 275
- Coils (*cont'd*)
 - Microplex 228
 - Micrus 155
 - pushable 227, 274
 - technique 239, 285–286
 - Sapphire NXT, 228, 275
 - Tornado 227, 274
 - Trufill 227, 274
 - Trufill DCS, 228
 - Vortex 227
 - Vortex 274
- Coil stretching 171–172
 - microsnare technique for retrieval of a stretched coil 173f
- Collagen vascular disease
 - and pediatric aneurysms 481t
- Coma 415, 612
- Compliant versus noncompliant balloons 376t
- Complications
 - balloon test occlusion 184
 - venous 390
 - cerebral angiography 88, 89, 89t
 - embolization
 - transvenous 405
 - extracranial embolization 296–297
 - Inferior petrosal sinus sampling (IPSS) 394
 - intracranial embolization 247–254
 - pediatric angiography 109
 - spinal angiography 117, 118
 - venography 385
 - warfarin therapy 578t
- Compressor 102
- Computed tomography
 - and cavernous malformations 564
- Computed tomography (CT)
 - acquisition with angiographic imaging system 137, 138, 141. *see also* Dynavision
 - in acute stroke 329–330
 - and moyamoya disease 688
 - perfusion 573
 - and vasospasm 374
- Computed tomography (CT) perfusion
 - in balloon test occlusion 182
- Confusional state 573t
- Confusional State 613
- Congenital heart disease
 - and moyamoya syndrome 691
- Congenital human immunodeficiency virus infection
 - and moyamoya syndrome 691
- Constipation
 - prevention 634
- Contour emboli (*see* Polyvinyl alcohol)
- Contraceptives 575
- Contrast-induced nephropathy 105–106
 - prevention 106
 - risk factors 106

- Contrastoma (after thrombolysis) 321
 Contrast reactions 106–108
 risk factors 107
 Cooper, Irving S., 39
 Coronary artery disease
 and carotid stenosis 642
 Corynebacteria
 and infectious aneurysms 485
 COSS (Carotid Occlusion Surgery Study (COSS) 663
 Costello syndrome
 and moyamoya syndrome 691
 Covered stents
 and direct CCFs 555
Coxiella burnetii 583t
 Cranial irradiation
 and moyamoya syndrome 691
 Cranial nerves
 blood supply 7t
 Craniectomy, decompressive (*see* Hemicraniectomy)
 Craniopharyngioma
 and moyamoya syndrome 691
 C-reactive protein 582
 CREATE (Carotid Revascularization With ev3 Arterial Technology Evolution) 655t
 Creatinine, serum 302
 CREST (Carotid Revascularization Endarterectomy versus Stent Trial) 655t, 656t, 657–658
 CREST syndrome (Calcinosis, Raynaud phenomenon, esophageal dysmotility, sclerodactyly, and telangiectasia)
 and moyamoya syndrome 691
 Crossed cerebellar diaschisis 182
 CT angiography (CTA) 336
 and arterial dissection 665, 666, 668, 669
 and AVMs 517
 in basilar artery occlusion 322
 and carotid stenosis 648
 and dAVFs 543
 and giant aneurysms 488
 and penetrating neck injury 669
 and subarchnoid hemorrhage 463
 and vasospasm 470
 and vertebral artery stenosis 664
 CT perfusion 330–336
 in acute stroke 302
 at-a-glance interpretation 334–335f
 interpretation 333
 in ischemic stroke 334–335
 technique 330–333
 theory 331–333
 and vasospasm 470
 Cushing's disease (*see also* Cushing's syndrome) 393–394, 400–401, 403
 Cushing's syndrome 393–394, 399
 CVT (*see* Cerebral venous thrombosis)
 Cyanoacrylates 224, 273
 Cyclophosphamide 600–603
 Cyst
 bone, aneurysmal 132, 260
- ## D
- Dandy's vein (*see* Vein, petrosal)
 Dandy-Walker complex 73, 74f
 Dangerous anastomoses 292–293
 Dangerous anastomosis 200, 201
 Danger zones:Common anastomoses
 anterior circulation 6t
 ophthalmic artery 6t
 posterior circulation 7t
 spinal cord 77t
 dAVF (dural arteriovenous fistula) (*see* Dural arteriovenous fistula)
 Davidoff and Schecter, artery of 20t, 51
 Deafness 617t
 Deconvolution method (of CT perfusion) 331–332, 335, 335f
 Decubitus ulcers
 prevention of 633
 Deep venous thrombosis (DVT) 248, 581
 prevention of 633
 Dehydration
 prevention 633
 Dejerine-Roussy thalamic syndrome 613, 613t
 Dejerine's anterior bulbar syndrome 618
 Delayed ischemic neurological deficit (*see* Vasospasm)
 Deterium 613
 prevention 634
 Dementia 573t
 Depression
 prevention 634
 Desmetoprase 302–303
Desmodus rotundus 303
 Detachable balloons 175–176
 Developmental venous anomaly (DVA) 567–568
 Dexamethasone 246
 Dextrose solution 230, 232–234
 Diabetes 575, 582
 and carotid stenosis 642
 Diabetes insipidus 467–468
 Diazepam (Valium) 109t
 Diffusion-weighted imaging (MRI) 336t
 Dilantin (*see* Phenytoin)
 Dimethyl sulfoxide (DMSO) 225, 232, 234–235, 279–280, 410–411
 Diphenhydramine (Benadryl) 107, 108t, 141
 Diplopia
 in carotid-cavernous fistula (CCF) 243

- Dipyridamole
 - and carotid stenosis 651
 - Dipyridamole/Aspirin (Aggrenox) 634t
 - Direct carotid cavernous fistula (CCF) 553–555
 - Dissecting aneurysms 489–490
 - Dissection 574
 - complicating brain AVM embolization 252–253
 - Disseminated intravascular coagulopathy (DIC)
 - in pregnant patients with SAH 483
 - DMSO (*see* Dimethyl sulfoxide)
 - Dobutamine 141
 - Dolichoectasia 574
 - Dolichoectatic aneurysms 490–492
 - Dorsal midbrain syndrome (*see* Paranaud syndrome)
 - “Double catheter” coiling technique 167–168
 - Double flushing 92, 265, 384
 - Down syndrome
 - and moyamoya syndrome 691
 - Dribble technique 233f
 - Duke criteria 583
 - Dural arteriovenous fistula (dAVF)
 - intracranial 539–553
 - anterior fossa 550–551
 - cavernous sinus 547–549
 - Barrow classification 547
 - classification 539
 - clinical features 541
 - common locations 545f
 - embolization 243–244
 - transvenous 412–415
 - etiology 539–541
 - inferior petrosal sinus 547
 - management 544–545
 - natural history 543–544
 - pathophysiology 539–541
 - superior sagittal sinus 550–551
 - tentorial 549–550
 - transverse-sigmoid 545–547
 - and venous sinus stenosis 423
 - and subarchnoid hemorrhage 462
 - Dural ring
 - internal carotid 33, 34f
 - Dural vascular supply 20t, 36
 - Dynavision 138
 - Dysarthria 610
 - Dysarthria-clumsy hand syndrome 616
 - Dysesthesia 613t
- E**
- Echelon 10 microcatheter 150
 - EC-IC Bypass 661–663
 - direct versus indirect bypass 693–695
 - for moyamoya syndrome 693–695
 - EC-IC Bypass Trial 662, 680
 - ECST (European Carotid Surgery Trial) 643–644
 - Edema
 - laryngeal 108t
 - EEG (*see* Electroencephalography)
 - Ehlers-Danlos syndrome 248, 405, 437, 555, 586
 - and pediatric aneurysms 480–481
 - EKOS MicroLysUS infusion catheter 319
 - Elderly patients
 - with aneurysms 484–485
 - Electrocardiography (EKG) 382
 - Electroencephalography (EEG) 193, 196, 208, 272
 - in balloon test occlusion 180
 - and moyamoya disease 689
 - in pre-embolization testing 199–201, 223
 - Embolectomy 251
 - Embolization
 - of brain AVMs 242, 522–523
 - brief history 522–523
 - brief history 246–247
 - complications 247
 - curative 242
 - effect on hemorrhage rate 248
 - hemorrhage post-op 251
 - incomplete 242
 - mortality 248, 249
 - pre-operative 242
 - pre-radiosurgery 242
 - complications 247–254
 - management 247–254
 - prevention 247–254
 - of dAVFs 243–244
 - anterior condylar 415
 - anterior fossa 552–553
 - cavernous sinus 412–413, 548–549
 - inferior petrosal 415
 - superior petrosal sinus 415
 - superior sagittal sinus 414, 551
 - tentorial 414, 550
 - transverse-sigmoid 413–414, 546
 - of direct CCFs 243, 554–555
 - transvenous 411–412
 - epidural/paraspinal AVF 296
 - of epistaxis 292–293
 - extracranial 259–297
 - complications 296–297
 - indications 259
 - extracranial AVF
 - transvenous 415
 - of extracranial AVFs 290–291
 - of extracranial AVMs 290–291
 - of extracranial bleeding 292
 - intracranial 205–254
 - complications 247–254
 - indications 205
 - and intracranial tumors 246

- Embolization (*cont'd*)
 - of juvenile nasopharyngeal angiofibroma 293
 - meningiomas
 - complications 249
 - of paragangliomas 294
 - and pial AVFs 244
 - spinal
 - indications 260
 - spinal AVM 295
 - spinal dural fistula 294
 - spinal perimedullary AVF 295–296
 - transvenous 415
 - transvenous 243, 244, 404–415
 - complications 405
 - indications 404–405
 - technique 405–411
 - of Vein of Galen malformations 244–245, 530–531
 - transvenous 414–415
 - Emboshield 356
 - Embosphere
 - and spinal vascular lesions 707
 - Embospheres 226, 246, 274
 - Emergency Management of Stroke Bridging Trial 320
 - EMLA cream 194
 - Encephalo-duro-arterio-myo-synangiosis (EDAMS) 694
 - Encephalo-duro-arterio-synangiosis (EDAS) 694
 - Encephalo-myo-synangiosis (EMS) 694
 - Enderterectomy versus Angioplasty in Patients with Symptomatic Severe Carotid Stenosis (EVA-3S) 656t, 658–659
 - Endocarditis 575, 581, 583
 - Libman-Sacks 583, 603
 - non-bacterial (NBTE) 584
 - and pediatric aneurysms 481t
 - Endoglin gene 514
 - Endovascular Photo Acoustic Recanalization (EPAR) system 319
 - EnSnare device 318
 - Enterococcus*
 - and infectious aneurysms 485
 - Enterprise stent 166–167, 229–230, 275, 286–287
 - versus Neuroform 162–163
 - technique 240–241
 - Envoy 185
 - Epinephrine 108t, 140
 - Epistaxis 259
 - embolization 291–293
 - complications 292
 - endoscopic ligation of sphenopalatine artery for 292
 - Epsilon-aminocaproic acid (Amicar) 464–465
 - and subarachnoid hemorrhage 478t
 - Epstein-Barr virus
 - and moyamoya disease 687
 - Eptifibatid (Integrilin) (*see also* Glycoprotein IIb-IIIa Inhibitor) 140t
 - Essential thrombocytopenia
 - and moyamoya syndrome 691
 - Estrogens 588, 595
 - Ethanol 225, 226, 274
 - technique 235–236, 280
 - Ethiodol 224, 225, 230, 273, 276–279
 - Ethnicity
 - stroke risk 585
 - and subarachnoid hemorrhage 462
 - Ethylene vinyl copolymer (*see also* Onyx) 225
 - Etiomidate 191, 197
 - European Assessment Group for Lysis in the Eye (EAGLE) 327
 - European Carotid Surgery Trial (ECST) 643–644
 - EVA-3S (Enderterectomy versus Angioplasty in Patients with Symptomatic Severe Carotid Stenosis) 656t, 658–659
 - EVOH (*see* Ethylene vinyl copolymer)
 - Excelsior 1018 150
 - Excelsior SL-10 150
 - Exorcist, The* 88
 - Exponent RX stent 358
 - Extracranial-Intracranial Bypass Trial (*see also* EC-IC Bypass Trial) 660, 662
- ## F
- Fabry disease 585, 586
 - Facial nerve 60
 - blood supply 7t, 24
 - Factor V Leyden mutation 415, 580, 581t
 - Falls
 - prevention of 633
 - Familial cerebrovascular syndromes
 - AVMs 513
 - cavernous malformations 562–563
 - intracranial aneurysms 562–563
 - moyamoya disease 685, 687, 691
 - Familial Intracranial Aneurysm Study 435
 - Fanconi anemia
 - and moyamoya syndrome 691
 - Femoral artery hemorrhage 321
 - FemoStop 102
 - Fenestration, arterial 61t
 - Fentanyl (Sublimaze) 90, 386
 - Fetal posterior communicating artery 37, 37f
 - Fever
 - in acute ischemic stroke 628
 - Fibromuscular dysplasia 574
 - and direct CCFs 553
 - and intracranial aneurysms 438
 - and pediatric aneurysms 481t
 - and pulsatile tinnitus 541

Fibromuscular dysplasia (FMD) 670–672
 and moyamoya syndrome 691
 FilterWire EX 356
 Fisher grading system for SAH 464t
 Flo-switch 189
 Flumazenil (Romazicon) 90, 141
 Foix-Alajouanine syndrome 701–703
 Foramen
 cecum 36
 lacerum 31, 69
 of Monro 53, 71
 ovale 63, 69
 spinosum 18, 19f, 63
 transverse 55
 Vesalius 69
 Foville syndrome 616
 Full column technique 233f
 Functional disorder 573t, 574
 Furosemide
 and Wada test 193
 Furosemide (Lasix) 109t, 141
 Fusiform aneurysms 490–492

G

G-6-PD deficiency
 and pediatric aneurysms 481t
 Gadodiamide (Omniscan) 338
 Gadolinium 338
 Gadolinium contrast 105
 Gamma knife
 of brain AVMs 520
 Gardner, W. James 191
 Gastric ulceration
 prevention 634
 Gateway Balloon Catheter
 device specifications 371
 procedure 371
 Gaze deviation 610
 Gemfibrozil 591
 Gerstmann syndrome 612t
 GESICA Study 682
 Giant cell arteritis
 and vertebral artery stenosis 663
 Glacial acetic acid 224, 225, 232, 273
 Glidecath 185, 188, 190
 Glossopharyngeal nerve 26
 blood supply 7t, 9, 10, 24
 Glucagon 129, 141
 Glucophage (*see* Metformin)
 Glucose
 and subarachnoid hemorrhage 466
 Glucose management
 in acute ischemic stroke 627–628
 Glucovance (*see* Metformin)
 Glue (*see* N-butyl cyanoacrylate)
 Glued microcatheter 253
 management 253

Glycogen storage disease
 and moyamoya syndrome 691
 Glycoprotein IIb-IIIa Inhibitor 140
 eptifibatid 140
 Goldvalve balloon 175–176
 Graves disease
 and moyamoya syndrome 691
 Guardwire 357 (*see* Balloon, Guardwire)
 GuardWire balloon 174
 Guglielmi detachable coil (GDC) 153, 155
 Guide catheter
 Neuron guide catheter technique
 147–148
 placement
 technique 212–214
 head and neck 265–266
 spinal 266–267
 tips to minimize guide catheter-induced
 spasm 148
 Guidelines
 Early Management of Patients with
 Ischemic Stroke 301
 Guidewire
 Glidewire 187, 195, 210, 212, 263, 267,
 418, 425
 J-tip 263
 Mirage 198
 Storq 210, 263
 Transend 187
 X-pedion 189

H

Hageman factor (Factor XII) deficiency
 and moyamoya syndrome 691
 Hagen-Poiseuille equation 474
 Hairpin Turn (*see also* Artery,
 of Adamkiewicz) 127
 Haughton view 97t, 112, 113f
 HbA_{1c} levels 582
 Headache
 post-embolization 241–242
 Head injury
 and moyamoya syndrome 691
 Headliner microwire 152
 Heart and Estrogen/Progestin Study (HERS)
 589t
 Heart valves
 prosthetic 599
 Hemangioblastoma
 spinal 132
 spine 701
 Hemangioblastomas 260
 embolization, preoperative 246
 spinal
 embolization 296
 Hemangioendothelioma
 spine 701

- Hemangioma
spine 701
 endovascular treatment 296
- Hemangiopericytoma
spine 701
- Hematoma
subdural 572f
- Hemianesthesia 610
- Hemianopia 198, 610, 613, 614t
 homonymous 613
- Hemicraniectomy 631–632
- Hemineglect 614t
- Hemiparesis 196, 614t, 616
- Hemiplegia 197–198, 610, 614t, 616
 hypoglycemic 573
- Hemisensory syndrome 613
- Hemolytic anemia
 and moyamoya syndrome 691
- Hemophililia A
 and moyamoya syndrome 691
- Heparin 104, 110, 140, 185, 188, 195, 209, 250,
 260, 263, 384, 386, 388, 391,
 395, 396, 406, 416, 585, 588
 during IA thrombolysis for acute
 stroke 310
- Heparin-induced thrombocytopenia 575,
 587–588
- Hepatocyte growth factor
 and moyamoya disease 686
- Hereditary hemorrhagic telangiectasia
 (Rendu-Osler-Weber syndrome)
 513–514
- Hereditary spherocytosis
 and moyamoya syndrome 691
- Herniation 631
- Heroin
 and stroke risk 604
- Herpes virus 641
- Heterotopic ossification
 and moyamoya syndrome 691
- Heubner, artery of (*see* Artery, recurrent artery
 of Heubner)
- Hirschsprung disease
 and moyamoya syndrome 691
- Histocryl (*see* N-butyl cyanoacrylate (NBCA))
- Homocystinuria 586
- Homunculus 607t
- Hormone replacement therapy (HRT) 588, 588t
- Horner syndrome 608t, 609, 617t
- Horton's disease (*see also* Arteritis,
 Giant cell) 600
- HRT (*see* Hormone replacement therapy)
- Huber maneuver 112, 554
- Hughes syndrome (*see also* Antiphospholipid
 antibody) 581t
- Human immunodeficiency virus (HIV)
 and pediatric aneurysms 481t
- Hunterian ligation 174–176
- Hunt-Hess Scale 463t
- Hutchinson-Horton's disease (*see also*
 Arteritis, Giant cell) 600
- Hydrocephalus
 and subarchnoid hemorrhage 465
 in Vein of Galen malformations 245
- Hydrochlorothiazide
 and Wada test 193
- Hydrocortisone 107
- Hydroxyurea 597
- Hyocine-N-butylbromide 129
- Hyperbaric oxygen 94
- Hypercoagulable state 415
- Hyperdynamic therapy
 for prevention of vasospasm 473
 for treatment of vasospasm 474–476
- Hyperfibrinogenemia 575
- Hyperform (*see* Balloon, Hyperform)
- HyperForm balloon 174
 technique 376–378
- HyperGlide balloon
 technique 376–378
- Hyperglycemia 573
 and subarchnoid hemorrhage 466, 470
- Hyperhomocysteinemia 589
 and moyamoya syndrome 691
- Hyperlipidemia 575
- Hyperlipoproteinemia
 and moyamoya syndrome 691
- Hypernatremia
 and subarchnoid hemorrhage 467–468
- Hyperparathyroidism 404
- Hyperperfusion syndrome 355
- Hypertension 575, 635t
 and AVMs 516
 and carotid stenosis 642, 650
 and dolichoectatic aneurysms 491
 and fibromuscular dysplasia (FMD) 671
 and intracranial aneurysms 439
 and moyamoya syndrome 691
 and stroke risk 589–590
 venous
 spinal 123, 124
- Hyperthyroidism
 and moyamoya syndrome 691
- Hypoglossal nerve 26
 blood supply 7t, 9, 10, 24
- Hypoglycemia 573
- Hypokalemia
 and subarchnoid hemorrhage 468
- Hypomagnesemia
 and subarchnoid hemorrhage 468
- Hyponatremia
 and subarchnoid hemorrhage 467
- Hypotension 107, 108t, 390, 575
 post-embolization 242, 244
- Hypotensive challenge
 in balloon test occlusion 180

Hypothermia, induced
in acute ischemic stroke 629
after cardiac arrest 629

I

Impaired NADH-CoQ reductase activity
and moyamoya syndrome 691

Infarct
cerebral 584, 602
definition 571

Infectious aneurysms
and subarachnoid hemorrhage 462, 485–486

Infectious endocarditis
and subarachnoid hemorrhage 462

Inferior petrosal sinus sampling (IPSS)
393–403
complications 394
indications 394
personnel requirements 395
technique 396–398

Infundibulum 39, 39f, 434

Innominate artery 1

In-stent restenosis 354
after transvenous stenting 424

Insular ribbon sign 330f

Insulin 582
and acute ischemic stroke 627–628
and subarachnoid hemorrhage 466

Intensive care unit (ICU)
for stroke patients 629

Interceptor 357

International Study of Unruptured Intracranial
Aneurysms (ISUIA) 441–443
anomalies and study limitations 443
and elderly patients 484
and giant aneurysms 488

International Subarachnoid Aneurysm Trial
(ISAT) 479–480

Internet Stroke Center at Washington
University
website 636

Interventional Management of Stroke trial 320

Interventional suite, specifications 135

Intima media thickness (IMT) 591

Intra-arterial drug infusion for vasospasm 379

Intracranial angioplasty
for moyamoya disease 695

Intracranial angioplasty and/or stenting
for atherosclerotic stenosis 365–374
indications 365
technique 366
Wingpan 370–373

Intracranial angioplasty and stenting
position statement on, by ASITN, SIR, and
ASNR 684–685
published clinical data 683–685
Wingspan clinical trial 683

Intracranial angioplasty for vasospasm
374–379
balloon selection 376t
indications 374–375
technique 375–379

Intracranial arterial stenosis
and hypertension 679
medical management 682–683
Mori system for classification 684t
natural history 680–682
and race 679

Intracranial pressure (ICP), monitoring 139

Intracranial venous hypertension
and pulsatile tinnitus 542

Intracranial venous sinus stenosis
and pulsatile tinnitus 542

Intracranial venous sinus thrombosis
and subarachnoid hemorrhage 462

Iodixanol (Visipaque) 105, 106, 117, 118,
238, 253

Iohehol 117

Iohexol (Omnipaque) 90, 105, 106, 110, 185,
194, 253, 391, 406

IPSS (*see* Inferior petrosal sinus sampling)

Ischemia
acute
cerebral 572, 584

Isobutyl cyanoacrylate (i-BCA) 247

ISUIA (*see* International Study of Unruptured
Intracranial Aneurysms)

Ivy sign, in Moyamoya disease 689

J

Janeway lesions 583t, 584

Japanese ethnicity
and intracranial aneurysms 440–441

Jostent 229–230, 245, 286–287, 288–289
technique 240–241

Jugal trunk (*see* Artery, jugal trunk)

Jugular venous sampling 399

Juvenile nasopharyngeal angiofibroma 260
pre-operative embolization 293

K

Kearns-Sayre syndrome (KSS) 594

Keppra (*see* Levetiracetam)

Kippel-Trenaunay-Weber syndrome
and spinal vascular lesions 705

Koeber-Salus-Elsching syndrome (*see*
Paranaud syndrome)

L

Labetalol
in acute stroke 308

Labetalol hydrochloride 140

- Labyrinthine artery (*see* Artery, internal auditory)
- Lateral medullary syndrome (*see also* Artery, posterior inferior cerebellar (PICA) syndrome) 618t
- Leicester trial 656
- Lepirudin 588
- Leptospirosis
and moyamoya syndrome 691
- Leukemia 590
- Levetiracetam (Keppra) 466
- Lidocaine 104, 141, 272, 387
in pre-embolization testing 199–202, 223–224
- Life expectancy table
and AVMs 515
and intracranial aneurysms 443–444
- Lima, Almeida 87
- Lindegaard ratio 470–471
- Linear accelerator (LINAC)
of brain AVMs 520
- Livedo reticularis 581
- Locked-in syndrome 615, 616t
- Luessenhop, Alfred 246, 460
- Lumbar drainage
and subarachnoid hemorrhage 472–473
- Lumbar puncture
and subarachnoid hemorrhage 463
- Lupus anticoagulant 581t
- ## M
- Magnesium infusion
and subarachnoid hemorrhage 473
- Magnetic resonance angiography (MRA) 338, 573
and arterial dissection 665, 666, 668
in basilar artery occlusion 322
and direct CCFs 554
elliptical centric time-resolved imaging of contrast kinetics (EC-TRICKS) 554
for imaging of coiled aneurysms 160
- Magnetic resonance imaging (MRI) 336–339, 594, 602
and cavernous malformations 563
in cerebral infarction 336t
and dAVFs 542–543
diffusion weighted imaging (DWI) 606
functional MRI (fMRI) 198–199
guidance for angiographic procedures 141
and hemorrhage 339
and moyamoya disease 687, 689
perfusion 573
and pulsatile tinnitus 542
and subarachnoid hemorrhage 463
and Vein of Galen malformations 528
- Magnetic resonance (MR) perfusion
in balloon test occlusion 183
- Magnetic resonance venogram (MRV) 428
- Magnetoencephalography (MEG) 198
- Malignancy
stroke risk 592
- Mannitol 141
- Marfan syndrome 437, 586
and moyamoya syndrome 691
and subarachnoid hemorrhage 481t
- Marie-Foix syndrome 616
- Mass lesion 572t, 573
- Mastoiditis
and CVT 416
- Matas test 179
- Maverick angioplasty balloon
technique 378
- Maverick balloon 314
- MAVERiC (Medtronic AVE Self-Expanding Carotid Stent System With Distal Protection In the Treatment of Carotid Stenosis) 655t
- Maximum slope method (of CT perfusion) 332, 334f, 335
- Mayo Asymptomatic Carotid Endarterectomy Trial 647
- MCA (*see* Artery, middle cerebral)
- MCA sign 330f
- MCA syndrome
deep MCA syndrome 612
superficial MCA syndrome 612
- Mean transit time
definition 330
- Medial fibroplasia 670
- Medial hyperplasia 670
- Medial medullary syndrome (*see also* Dejerines Anterior Bulbar syndrome) 618t
- Medicorp balloon 357
- Medtronic AVE Self-Expanding Carotid Stent System With Distal Protection In the Treatment of Carotid Stenosis (MAVERiC) 655t
- Megadolichovertebrobasilar anomaly, 491
- Mehring-Hieshima maneuver 554
- Melting brain syndrome, Vein of Galen malformations 528
- Meningiomas
embolization, preoperative 246
- Meningitis
basilar 602
- Merci retrieval system 251, 314–316
- Metabolic syndrome 592
and intracranial stenosis 679
- Metaglip (*see* Metformin)
- Metaloproteinase gene expression
and moyamoya disease 686–687
- Metaplastic transformation 2
- Metaproterenol (Alupent) 108t
- Metastases
bone 132, 260
spine 701

- Metformin 105, 106
Methotrexate 600–603
Microangiopathy 575
 diabetic 582
Microcatheter
 access
 technique 215
 Courier Enzo 217t, 222–223
 Echelon 150, 216t, 217, 219, 269, 271, 407, 419
 Excelsior 1018, 150, 216t, 269, 407
 Excelsior SL-10 150, 216t, 407, 419
 flow-directed 215–217
 technique 220–221
 Magic 215, 217, 217t, 221, 225, 269
 Marathon 217t, 220, 221, 410
 over-the-wire 215–217
 technique 219–220
 Pivot 150–151, 217t, 222–223, 269, 272
 Prowler 216t, 217, 269, 419
 Prowler Plus 214, 216t, 229
 RapidTransit 387, 396, 398, 407, 408, 419, 420, 425
 Rebar 153t, 216t, 219, 271
 Renegade 214, 216t, 229
 retained. *see* Glued microcatheter
 shape 150–151
 steerable 215–217
 technique 222–223
 Tracker 217
 Ultraflow 217t, 220, 221, 269
Micro Elite snare 318
Microwire
 Agility 218
 Gold-tip Glidewire 382, 387, 391, 396, 406, 418, 425
 Headliner 152, 218, 269, 270, 387, 391, 406, 408, 418, 425
 Mirage 218, 220, 269
 PressureWire, 388, 392
 Silverspeed 218
 Synchro 152, 218, 219, 222, 269, 270, 407, 418, 425–426
 Transend 218, 222, 269, 387, 391, 398, 407, 408, 425–426
 Transend EX 152
Midazolam (Versed) 90, 109t, 140, 386
Midbrain syndrome
 of Foville 614
Migraine 573, 573t, 604
 familial hemiplegic 586
 stroke risk 593
Migrainous infarct 593
Minocycline 590
Mitochondrial Encephalomyelopathy, Lactic Acidosis, Stroke-like episodes (MELAS) 594
Mitral annular calcification 599
 and carotid stenosis 642
Mitral valve prolapse 575, 583t, 599
Mnemonics
 3rd cranial nerve palsy 450
 carotid-vertebrobasilar anastomoses 27
 cortical ACA branches 45
 cortical MCA branches 48f
 external carotid 4
 IV t-PA dose 308
Modified Rankin scale (mRS) 632t
MO.MA device 354, 357, 655t
Moniz, Antonio de Egas 87–88
Mononeuropathy 573t
Montreal test (*see* Wada test, memory testing)
Morning glory syndrome
 and moyamoya syndrome 691
Morphine 109t
Motor evoked potentials (MEP) 272, 296
 in pre-embolization testing 199, 223
Movements
 ballistic 613t
 chorioathetoid 613t, 614t
Moyamoya 685–695
 disease 574, 586
 clinical features 689–691
 diagnosis 687–688
 epidemiology 685–686
 familial form 691
 pathophysiology 686–687
 disease versus syndrome 685
 and pediatric aneurysms 481t
 and pregnancy 695
 in pregnant patients with SAH 483
 syndrome
 clinical features 692–693
 management 693
MRA (*see* Magnetic resonance angiography (MRA))
MRI (*see* Magnetic Resonance Imaging)
Mucomyst (*see* Acetylcysteine)
Mycobacterium tuberculosis 602
Myelography
 Type I, Dural arteriovenous fistula 702
Myeloma 590
Myocardial Infarction (MI) 575
 with intraventricular thrombus 576
Myocardial rupture
 with IV t-PA for acute stroke 308
Myoclonic Epilepsy and Ragged Red Fibers (MERRF) 594
- ## N
- Naloxone (Narcan) 141
NASCET (North American Symptomatic Endarterectomy Trial) 643–646
 method of measurement. *see* NASCET

- National Stroke Association (NSA)
website 636
- NBCA (*see* N-butyl cyanoacrylate)
- N-butyl cyanoacrylate (NBCA) 224–226, 235, 242, 247, 273, 409–410, 413, 415
direct percutaneous injection 277–279
technique 230–232, 276–277
- Needle
21 gauge 99
butterfly 110
Potts 90, 98, 99, 387, 407
Smart-Needle 98, 110
SmartNeedle 381
- Nephrogenic systemic fibrosis 338
- Neuracryl (*see* 2-hexyl cyanoacrylate)
- Neurofibromatosis 438, 586, 705
and moyamoya syndrome 691
- Neuroflo system 319
- Neuroform stent 164–166, 229–230, 275, 286–287, 412
versus Enterprise 162–163
technique 240–241
- Neurogenic pulmonary edema 469
- Neurointerventional team, personnel
requirements 139, 140
- Neurojet 319
- NEUROLINK stent system 664
- Neuronet Retriever thrombectomy device 318
- Neuron guide catheter 147–148, 317–318
- Neuroprotection
in acute ischemic stroke 627
- Neuropsychological testing
in balloon test occlusion 180
in pre-embolization testing 199–201
in Wada test 196
- Neutral Protamine Hagedorn (NPH) 105, 398
- New England Medical Center Posterior Circulation Registry (NEMC-PC) 663
- NexStent 358
- Niacin 591
- Nicardipine
for vasospasm 379
- Nicardipine (Cardene)
for treatment of vasospasm 476–477
- NIH Interventional Management of Stroke trial 320
- NIH stroke scale 339–341t, 636
- Nimodipine (*see also* Calcium channel blockers) 471–473
intra-arterial pharmacologic treatment 477
prevention of ischemic injury due to 478t
- Nitric oxide 585
for pulmonary hypertension 245
- Nitroglycerin
intra-arterial 148
paste
for treatment of guide catheter-induced spasm 148
- Nitroglycerine 104, 108t, 140
- Noonan syndrome
and moyamoya syndrome 691
- Normal perfusion breakthrough
and brain AVMs 252, 519
management 252
and pial AVFs 244
- North American Symptomatic Endarterectomy Trial (*see* NASCET)
- Northstar 185
- Notch 3 gene (*see also* Cerebral Autosomal Dominant Arteriopathy with Subcortical Infarcts and Leukoencephalopathy) 579
- Nothnagel syndrome 614t
- Novastan (*see* Argatroban)
- NPH (*see* Neutral Protamine Hagedorn)
- Nystagmus 617t
- ## O
- Obstructive Sleep Apnea (OSA) 595
- Ocular massage
for central retinal artery occlusion 328
- Oculomotor nerve 69
blood supply 7t, 24
- Olfactory nerve
blood supply 7t
- Omnipaque (*see* Iohexol)
- Omniscan (*see* Gadodiamide)
- Ondansetron (Zofran) 141
- Onyx (*see also* Ethylene vinyl copolymer) 219, 220, 223, 229, 242, 247, 270, 271, 273, 274, 410–411, 413
for aneurysm treatment 158–159
technique 232–235, 279–280
- Ophthalmoplegia
internuclear 615
wall-eyed 615
- Optic nerve 33
blood supply 7t
- Optic strut 33, 34f
- Oral contraceptives (OCP) 415, 595
and intracranial aneurysms 439
and moyamoya syndrome 691
progesterin-only 595
stroke risk 596t
- Osler nodes 583, 583t
- Osler-Weber-Rendu syndrome (*see* Rendu-Osler-Weber syndrome)
- Osteoblastoma
spine 701
- Osteogenesis imperfecta
and direct CCFs 553
and moyamoya syndrome 691
- Otitis media
and CVT 416
- Ovine corticotropin releasing hormone (oCRH) 398

P

- PA (*see* Postero-anterior View)
- Papavarine
 - and traumatic subarachnoid hemorrhage 493
 - for treatment of vasospasm 476–477
- Paragangliomas 260
 - embolization, preoperative 246
 - pre-operative embolization 293
- Paramedian pontine syndrome 616
- Paranaud syndrome 614, 615t
- Parkes-Weber syndrome
 - and spinal vascular lesions 705
- Parodi Anti-Emboloc System 354, 357
- Paroxysmal atrial fibrillation 577
- Particle beam radiosurgery
 - of brain AVMs 521
- Particulate embolization 226
 - technique 236–237, 282–283
- PASCAL (Performance And Safety of the Medtronic AVE Self-Expandable Stent in Treatment of Carotid Artery Lesions) 655t
- Patent Foramen Ovale (PFO) 575, 580
 - stroke risk 596t
- Pediatric aneurysms 480–481
- Peduncular hallucinosis 615
- Penetrating neck injury 669–670
- Penumbra system 317–318
- Perclose 103, 241, 289
- PercuSurge balloon 356
- Perforation vessel
 - complicating brain AVM embolization 249
- Performance And Safety of the Medtronic AVE Self-Expandable Stent in Treatment of Carotid Artery Lesions (PASCAL) 655t
- Perfusion imaging (MRI) 337–338
- Perimesencephalic nonaneurysmal subarachnoid hemorrhage 461–462
- Peripheral vascular occlusive disease
 - and moyamoya syndrome 691
- Persistent primitive arteries
 - and moyamoya syndrome 691
- Persistent stapedia artery (aka persistent hyoido-stapedial artery) (*see* Artery, persistent stapedia)
 - and pulsatile tinnitus 541
- PET (*see* Positron emission tomography)
- Petrolingual ligament 30
- Phakomatosis
 - and moyamoya syndrome 691
- Phenox Clot Retriever 319
- Phentolamine 108t
- Phenylephrine 141
- Phenytoin (Dilantin) 109t, 466
- Pheochromocytoma 108t
- Phosphodiesterase 4D gene 586
- Pial arteriovenous fistula
 - embolization 244
 - and Osler-Weber-Rendu syndrome 244
- Pitchfork 53f
- Pituitary adenoma
 - and moyamoya syndrome 691
- Pituitary apoplexy
 - and subarchnoid hemorrhage 462
- Pituitary gland
 - arterial supply 32, 36
- Pivot microcatheter 150–151
- Plasminogen deficiency 581t
- Plavix (*see* Clopidogrel)
- Pneumococcal meningitis
 - and moyamoya syndrome 691
- Polyarteritis nodosa 601
- Polycystic kidney disease 435–437
 - and moyamoya syndrome 691
 - and pediatric aneurysms 480
- Polycythemia vera 575, 590
- Polymethyl methacrylate (PMMA) 296
- Polyvinyl alcohol (PVA) 201, 226, 246, 274
 - and spinal vascular lesions 707
- Positron emission tomography (PET)
 - in balloon test occlusion 182–183
 - memory localization 198
- Posterior circulation
 - anastomoses 7t
- Postero-anterior (PA) view 96f
- Post-operative bleeding 292
- Post-traumatic bleeding 292
- Power injector 94, 121
 - settings 95t, 122t
- Power Injector
 - specifications 136
- Power Injector, specifications 135
- Pravastatin
 - and subarchnoid hemorrhage 472, 478t
- Precise stent 358
- Prednisone 107
- Pregnancy
 - and Call-Fleming syndrome 604
 - complications 581t
 - contrast agents 105
 - and CVT 416
 - and intracranial aneurysms 482–484
 - miscarriage 581
 - radiation exposure 105, 139
 - stroke risk 575
 - thrombosis 581t
- Pressure measurements
 - and test occlusion 181
 - venous 388–389
- Presyncope 572t, 573
- Primary antiphospholipid syndrome
 - and moyamoya syndrome 691
- Primer on imaging in stroke 329–339

- PROACT (*see* Prolyse in Acute Cerebral Thromboembolism)
- Prolyse in Acute Cerebral Thromboembolism (PROACT) 302, 320
- exclusion criteria 306–307t
- Propofol 141, 191, 197
- Proptosis
- in Carotid-cavernous fistula (CCF) 243
- Prosody 612
- Prostaglandin synthesis
- and moyamoya disease 687
- Prosthetic heart valves 575
- Protamine 140, 209, 263, 398
- Protege stent 358
- Protein C or S deficiency 581, 581t
- and moyamoya syndrome 691
- Prothrombin gene mutation 580, 581t
- Prourokinase 302–303
- Proventil (*see* Albuterol)
- Provocative testing 179–201, 234, 272, 297
- technique 223–224
- Pseudobulbar palsy 616
- Pseudomonas*
- and infectious aneurysms 485
- Pseudophlebitic pattern, with intracranial venous congestion
- and dAVFs 542
- Pseudotumor cerebri
- clinical presentation 423
- and venous sinus stenosis 423
- Pseudoxanthoma elasticum 438
- and direct CCFs 553
- and moyamoya syndrome 691
- and pediatric aneurysms 481t
- Pulmonary embolism (PE) (*see* Pulmonary thromboembolism (PTE))
- Pulmonary sarcoidosis
- and moyamoya syndrome 691
- Pulmonary thromboembolism (PTE)
- 248, 633
- Pulsatile tinnitus 390, 423, 541–542
- in Carotid-cavernous fistula (CCF) 243
- Pulseless disease (*see also* Arteritis, Takayasu) 600
- Pulsatility index 182
- Push technique 233f
- PVA (*see* Polyvinyl alcohol)
- Q**
- Quadruparesis 616t
- Qureshi grading system for acute ischemic stroke 307t
- R**
- Radial arterial line 139
- Radial artery cocktail 104
- Radiation exposure 110, 138, 139
- and pediatric aneurysms 481t
- in pregnant patients 482
- Radiosurgery
- of brain AVMs 520–522
- cavernous malformations 567
- and dAVFs 545, 547, 549, 550, 551, 553
- Raymond-Cestan syndrome 616
- Raymond syndrome 616
- Rebar 153f
- Recurrent stenosis
- after carotid endarterectomy 649
- Red-eyed shunt syndrome, indirect
- CC fistula 547
- Rehabilitation 635
- Rendu-Osler-Weber syndrome (aka hereditary hemorrhagic telangiectasia)
- 513–514
- and spinal vascular lesions 705
- Reopro (*see* Abciximab)
- Rescue angioplasty
- for acute ischemic stroke 313–314
- Retepase (Retavase) 302–303
- Retinal artery embolization
- complicating meningioma embolization 249
- Retrograde aortic flush 128
- Reversible ischemic neurological deficit (RIND) 606
- Rheumatic heart disease 575
- Rheumatoid arthritis 603
- Right-left confusion 612t
- Ringer's lactate 108t
- Romazicon (*see* Flumazenil)
- Rubber duck 349f
- Rubicon 357
- S**
- Safety point
- ophthalmic artery 35f
- Safety zones
- for AVM embolization 230
- Saltzman variants, persistent trigeminal artery 27
- SAPPHIRE (Stenting and Angioplasty with Protection in Patients at High Risk for Endarterectomy)
- 655t, 657
- Sapporo criteria 581
- Sclerosing agents 225
- Sclerotherapy
- technique 281–282
- Seattle test (*see* Wada test, memory testing)
- SECURITY (Study to Evaluate the Neuroshield Bare Wire Cerebral Protection System and X-Act Stent in Patients at High Risk for Carotid Endarterectomy) 655t

- Seizure 572t, 573, 600, 606
- Seizures 248, 415
 and brain AVMs 516, 519
 and cavernous malformations 565
 postischemic stroke 632
 and subarchnoid hemorrhage 463, 465–466
- Seldinger technique 247
- Sensorimotor syndrome 613
- Sentinel headache
 and subarchnoid hemorrhage 463
- Sepsis 572t, 573
- Serbinenko, Fedor 460
- Serpentine aneurysms 490–492
- Sheath 90, 101
 arterial 119, 126, 139
 femoral 185, 187, 194, 208, 262
 femoral vein 381, 395, 424
 jugular 381
 Pinnacle Destination 211, 211t
 radial 104
 Shuttle 211, 211t, 263, 264, 265, 287, 391, 406, 419, 425
- Shuttle 185
- Sickle cell disease 575, 586, 590, 597
 and intracranial aneurysms 438
 and moyamoya syndrome 691
 and pediatric aneurysms 481t
 stroke risk 597–598
 and subarchnoid hemorrhage 462
- Sick sinus syndrome 577
- Silicone spheres
 for AVM embolization 247
- Silk suture embolization 274
 technique 237, 283–284
- Single photon emission computed tomography (SPECT) 192
 in balloon test occlusion 183
- SIR (*see* Society of Interventional Radiology; Society Of Interventional Radiology)
- Sjögren syndrome 603
 and moyamoya syndrome 691
- Smile and mustache 44f
- Smith-Magenis syndrome
 and moyamoya syndrome 691
- Snare (*see* Amplatz Goose Neck microsnare)
 Micro Elite 318
 microsnare technique for retrieval of a stretched coil 173f
- Snare-assisted catheterization 383f
- Society of Interventional Radiology (SIR)
 and intracranial angioplasty and stenting 684–685
- Society of Interventional Radiology (SIR)
 quality improvement guidelines 89t
- Sodium amobarbital (Amytal) 141
- Sodium methohexital (Brevital) 141, 191, 197
 in superselective Wada test 199
- Sodium nitroprusside 141
- Somatosensory evoked potentials (SSEP)
 272, 296
 in balloon test occlusion 181
 in pre-embolization testing 199, 223
- Somnolence 613
- SPACE (Stent-Protected Percutaneous Angioplasty of the Carotid vs. Endarterectomy) 656t, 658
- Spetzler-Martin grade (*see also* Arteriovenous malformation (AVM), brain)
 247, 518t
- SpideRX 356–357
- Spike of death 264
- Spinal accessory nerve 26
 blood supply 7t, 9, 10, 24
- Spinal cord pathology 573t, 574
- Spinal neurovascular anatomy 74–79
- Spinal vascular abnormalities
 in pregnant patients with SAH 483
- Spinal vascular lesions
 classification 701
 spinal cord aneurysms 705, 707
 Type I, Dural arteriovenous fistula 260, 701–704, 702f
 embolization 294–295
 epidemiology and clinical features 701–703
 management 701–703
 endovascular considerations 704
 surgical considerations 703
 pathophysiology 703
 Type III, Juvenile arteriovenous malformation 260, 708
 embolization 295
 Type II, Intramedullary arteriovenous malformation 260, 704–707, 705f
 embolization 295
 epidemiology and clinical features 704–706
 management
 endovascular considerations 707
 radiosurgery 707
 surgical considerations 706–707
 Type II, Intramedullary arteriovenous malformations
 provocative testing 199
 Type IV, Intradural perimedullary arteriovenous fistula 260, 709–710
 embolization 295–296
- SSEP (*see* Somatosensory evoked potentials)
- SSYLVA (Stenting of Symptomatic Atherosclerotic Lesions in the Vertebral or Intracranial Arteries) 664, 683, 684
- STA-MCA bypass
 and moyamoya syndrome 693–694

- Staphylococcus*
and infectious aneurysms 485
- Statins 591, 626, 635t, 650
mechanism of action 592t
and subarachnoid hemorrhage 471–472
- Stellate ganglion 55
- Stem-cell transplantation 635
- Stent
Wingspan 370–373
- Stent-assisted aneurysm coiling 162–167, 229
- Stent-graft placement
technique 288–289
- Stenting and Angioplasty with Protection
in Patients at High Risk for
Endarterectomy (SAPHIRE)
655t, 657
- Stenting of Symptomatic Atherosclerotic
Lesions in the Vertebral or
Intracranial Arteries (SSYLVIA)
664, 683, 684
- Stent placement
transvenous 423–428
complications 424
indications 423
technique 424–428
- Stent-Protected Percutaneous Angioplasty of
the Carotid vs. Endarterectomy
(SPACE) 656t, 658
- Stents
Acculink 275, 287, 428
Enterprise. *see* Enterprise stent
Jostent 275. *see* Jostent
Neuroform. *see* Neuroform stent
NexStent 275, 287
open cell versus closed cell 357
placement for AVF 286–288
Precise 425
stent-graft 297
Viabahn 275, 289
Wallgraft 289
- Strange, but true* 192, 194
- Streptococcus*
and infectious aneurysms 485
- Stroke 223
acute
clinical presentation 605
definition 571
deteriorating neurological
examination 630t
ischemic 571, 582
basilar artery occlusion 322–323
cardioembolic 574, 575
cryptogenic 576, 635
definition 571
incidence 571
ischemic 586, 587, 599, 600
mechanisms 574
mortality 571
- Stroke (*cont'd*)
outcomes 636
prevention
secondary 634t
risk factors 576
thrombolysis for 301–329
associated carotid stenosis + stroke
323–325
associated intracranial stenosis + stroke
326–327
carotid or vertebral dissection + stroke
325–326
combined IV + IA strategies 320–321
intra-arterial thrombolysis/thrombec-
tomy 309–321
general technique 309–312
IV thrombolysis 307
complications 308
IV versus IA thrombolysis 304–306
management of complications 321
patient preparation 303–304
patient selection 304–306
- Stroke mimics 572–574, 572t–573t
- Stroke-o-gram 309f
- Stroke Prevention by Aggressive Reduction in
Cholesterol Levels (SPARCL) 591
results 591t
- Study to Evaluate the Neuroshield Bare Wire
Cerebral Protection System and
X-Act Stent in Patients at High
Risk for Carotid Endarterectomy
(SECURITY) 655t
- Stump pressure (*see* Back pressure)
- Stunned myocardium
and subarachnoid hemorrhage 468–469
- Sturge-Weber syndrome 514
- Stylomastoid artery (*see* Artery, stylomastoid)
- Subarachnoid hemorrhage 461–480
and antifibrinolytic therapy 464–465
and cardiac abnormalities 468–469
in CVT 415
diagnosis 462–464
and hydrocephalus 465
International Subarachnoid Aneurysm Trial
(ISAT) 479–480
management protocol 477–479t
mortality and morbidity 464
Perimesencephalic nonaneurysmal
subarachnoid hemorrhage
461–462
in pregnant patients 482–484
rebleeding 464–465
timing of treatment 465
traumatic 493
and vasospasm 469–477
- Sublimaze (*see* Fentanyl)
- Submental artery (*see* Artery, submental)
- Submentovertex 96f, 97t

Suction thrombectomy 313
 Superior labial artery 5f
 Superior sympathetic ganglion
 blood supply 9
 Susceptibility-weighted imaging (MRI) 339
 Swallowing evaluation
 prevention 634
 Swan-Ganz balloon catheter 186–189
 technique 188–189
 Swiss Alps 57f
 Sylvian aqueduct syndrome (*see* Paranaud syndrome)
 Sylvian dot sign 330
 Synchro microwire (*see also* Microwire, Synchro) 152
 Syncope 572t, 573
 Syndrome of inappropriate ADH secretion (SIADH) 467
 Syphilis
 meningovascular 602
 and pediatric aneurysms 481t
 Systemic lupus erythematosus (SLE) 581, 603
 and moyamoya syndrome 691
 Syvek hemostatic patch 101, 289, 385, 398, 422

T

Tachycardiabradycardia syndrome 577
 Tandem stenoses 351
 TCD (*see* Transcranial doppler (TCD))
 Temporal lobectomy 192
 Tenecteplase 302–303
 Terbutaline (Brethaire) 108t
 Terson syndrome 463
 Thalassemia
 and pediatric aneurysms 481t
 Theory
 hemodynamic balance of facial arteries 13
 normal perfusion pressure breakthrough and brain AVMs 519
 three-stage hypothesis for the formation of intracranial dural fistulas 539–541
 Therapeutic arterial occlusion 174–176
 Thiazide diuretics 589–590
 Thiopental
 in superselective Wada test 199
 Thrombectomy 314–318
 for CVT
 indications 416–417
 technique 421–422
 Thrombocythemia
 essential 590
 Thrombocytopenia
 idiopathic 581
 Thrombocytopenic purpura
 and moyamoya syndrome 691
 Thromboembolism
 complicating brain AVM embolization 250
 Thrombolysis 302–322
 for CVT
 indications 416–417
 technique 420–421
 Thrombolysis in Myocardial Infarction (TIMI) scale 306t
 Thrombolytic agents 140, 302–303
 Thrombotic thrombocytopenic purpura 575, 590
 Thunderclap headache 604
 Ticlopidine (Ticlid) 634t
 and carotid stenosis 651–652
 Time to peak
 definition 330
 TIMI scale (*see* Thrombolysis in Myocardial Infarction scale)
 Tissue Plasminogen Activator (tPA) 140, 416, 420, 420–421
 Todd's Paralysis 572t
 Tonsillar artery (*see* Artery, tonsillar)
 Topiramate
 and Wada test 193
 Top of the basilar syndrome 615, 615t, 616
 Torcular Herophili (aka confluence of the sinuses) 67, 67f, 73, 74f
 Tower of power access technique 351
 Towne view 96f, 97t, 111
 tPA (*see* Tissue plasminogen activator)
 Tranexamic acid 464–465, 478t
 Transcranial doppler (TCD) 573
 in acute stroke
 therapeutic TCD 308
 in balloon test occlusion 182
 and vasospasm 470–471
 Transend EX microwire 152
 Transesophageal echo 584
 Transforming factor beta 1
 and moyamoya disease 686
 Transfusion 597
 Transient contrast encephalopathy 355
 Transient global amnesia (TGA) 606
 Transient ischemic attack (TIA) 599, 605, 612, 615, 616, 617, 620–621, 634t, 635t
 crescendo 606
 limb-shaking 608
 Transitional aneurysms 450–452
 Transverse facial artery (*see* Artery, transverse facial)
 Trauma
 and subarachnoid hemorrhage 462
 Traumatic aneurysms 492–493
 Trendelenberg Position 108t
 Trigeminal nerve 60, 69
 blood supply 7t, 24
 Trigeminal neuralgia 60
 "Trigeminal segment," internal carotid artery 30

- Triple H therapy (*see* Hyperdynamic therapy)
- Trisomy 12p
and moyamoya syndrome 691
- Troclear nerve 69
blood supply 7t, 24
- Trufull glue (*see* N-butyl cyanoacrylate (NBCA))
- Tuberculosis
and moyamoya syndrome 691
- Tuberous sclerosis
and moyamoya syndrome 691
and pediatric aneurysms 481t
- Tumor, intracranial
embolization 245–246
hemorrhage 249
- Turner syndrome
and moyamoya syndrome 691
- ## U
- Ultravist (*see* Iopromide)
- Urokinase (Abbokinse) 302–303
- Urticaria 108t
- ## V
- Vagal reaction 107, 108t
- Vagus nerve 26
blood supply 7t, 9, 10, 24
- Valium (*see* Diazepam)
- Vampire bat (*see* *Desmodus rotundus*)
- Varenicline (Chantix) 598
and intracranial aneurysms 439
- Vasculitis 574, 599–604
amphetamine-related 603–604
definition 571
Lupus 600t
lymphoma-related 604
primary CNS 602
rheumatoid 600t
secondary CNS 602
and subarachnoid hemorrhage 462
varicella zoster 602
- Vasculopathy
definition 571
- Vasoconstriction
reversible cerebral 604.
see also Call-Fleming syndrome
- Vasomotor disturbance 613t
- Vasopressin 141
- Vasospasm 469–477, 574, 604
clinical features and diagnosis 470–471
frequency and time course 469
guide catheter-induced 253
prevention of ischemic injury due to 471–473
risk factors 470
treatment 474–477
angioplasty 374–379, 476
- Vasospasm (*cont'd*)
hyperdynamic therapy 474–476
IA drug infusion 379
intra-arterial pharmacologic treatment 476–477
- Vein
angular 62, 63, 63f, 64f
anterior caudate 71, 71f
anterior cerebral 72
anterior condylar 65, 396
anterior medullary 72f
anterior pontomesencephalic 72f, 73
atrial 71
basal vein of Rosenthal 51, 71, 71f, 72, 72f
basilar venous plexus 68f, 69
brachial 72f
central retinal
occlusion 328
cerebellar 69
cerebellar hemispheric 67
cervical veins 64–65
clinoid venous plexus 33
common facial 64, 64f
coronal venous plexus 123
cortical 67
Cortical veins 69–70
cranial venous system 61–73
deep extracranial 64f
deep facial 63, 64f
deep middle cerebral 72
deep venous system 70–72, 71f, 73
diploic veins 65
emissary veins 65, 68
external jugular 63f
external jugular (EJ) 64
facial 63, 63f, 64f, 67
facial veins 62–64
femoral
catheterization 396, 420
puncture 381
frontal 62, 63f
of Galen 71, 71f, 72, 72f, 73
malformation 110
inferior ophthalmic 62, 69
inferior orbital 64f
inferior retrotonsilar 72f
inferior vermian 72f
infratentorial venous system 72–73
“intermediate” 67
internal auditory 69
internal cerebral 71, 71f, 72, 73
internal jugular 388
sampling 399
internal jugular (IJ) 63, 63f, 64
puncture 381
of Labbé 68, 70, 70f
labial 63f, 64
lateral mesencephalic 72f, 73

- Vein (*cont'd*)
- maxillary 63, 64, 64f
 - medial ophthalmic 62
 - medial temporal 62, 63f
 - medullary veins 70–71, 71f
 - meningeal 65
 - nasal 67
 - occipital 62, 63f
 - orbital 62
 - petrosal 72f, 73
 - pharyngeal 64f, 65
 - posterior auricular 62, 63f
 - posterior condylar 65
 - posterior mesencephalic 72f, 73
 - posterior pericallosal 72
 - precentral cerebellar 72, 72f, 73
 - pterygoid plexus 63, 64f, 69, 70
 - radicular 123
 - retromandibular 63f, 64
 - scalp 62, 67
 - septal 71, 71f
 - spinal venous plexus 55, 79
 - spinal venous system 78–79
 - subependymal 71, 71f
 - submental 63f, 64
 - suboccipital 64f, 65
 - superficial extracranial veins 63f
 - superficial Sylvian 65
 - superficial temporal 62, 63f
 - superior cerebellar 72
 - superior convexity 70, 70f
 - superior ophthalmic 411
 - superior ophthalmic (SOV) 62, 69
 - superior orbital 64f
 - superior retrotonsillar 72f
 - superior vermian 72f, 73
 - supraorbital 62, 63f
 - supratrochlear 62, 63f
 - Sylvian 69, 69–70, 70f
 - thalamostriate 71, 71f
 - thyroid 63f, 65
 - of Trolard 70, 70f
 - vermian 67
 - vertebral 55, 65
 - vertebral venous plexus 65, 68f
- Vein of Galen malformation 73, 244, 527–531, 529
- anatomy 528
 - Bicêtre neonatal evaluation score 529t
 - classification 527
 - clinical features 528
 - embolization 244–245, 530–531
 - transvenous 414–415
 - embryology 527–528
 - heart failure in 244–245
 - hydrocephalus in 245
 - melting brain syndrome 528
 - natural history and prognosis 529
- Vein of Galen malformation (*cont'd*)
- outcomes 529–531
 - spontaneous cure 244
- Velasquez A.C., 460
- Venography 408
- complications 385
 - interpretation 388
- Venous angioma (aka developmental venous anomaly, DVA) 73, 567–568
- Venous malformation
- superficial 259
- Venous sinus 65–69
- cavernous 63, 68f, 69, 70
 - sampling 398
 - circular 69
 - inferior group 68–69, 68f
 - inferior petrosal 68f, 69
 - sampling 393–403
 - inferior sagittal 66f, 67
 - marginal 69
 - occipital 66f, 67, 69
 - sigmoid 66f, 68
 - sphenoparietal 65, 68f, 69
 - straight 66f, 67, 72f, 73, 74f
 - superior petrosal 68, 68f, 69
 - superior sagittal 66f, 67, 68, 73
 - tentorial 67
 - tentorial dural sinus 70
 - thrombosis 574, 581t
 - transverse 66f, 67–68, 67f, 73, 74f
- Venous sinus stenosis 423
- and dAVFs 423
- Venous sinus thrombosis 415
- and dAVFs 539–541
- Ventolin (*see* Albuterol)
- Verapamil 104
- intra-arterial pharmacologic treatment 477
 - for vasospasm 379
- Versed (*see* Midazolam)
- Vertebral artery angioplasty and stenting 359–361, 664
- technique 360–361
- Vertebral artery injury 668–670
- Vertebrobasilar insufficiency (VBI)
- diagnosis 663
 - medical management 663
 - prognosis 664
- Very busy little artery 11
- Vestibular dysfunction 573t
- Veterans Administration Cooperative Asymptomatic Trial 646
- Vidian nerve 30
- Virchow-Robin spaces
- and infectious aneurysms 485
- Visipaque (*see* Iodixanol (Visipaque))
- Visual simultanagnosia 613t
- ViVEXX Carotid Revascularization Trial 655t
- Vivexx stent 358

W

- Wada, Juhn 191
 - Wada Test 191–199
 - alternatives 198
 - complications 193
 - history 191
 - indications 193
 - memory testing 192
 - Montreal test 192
 - Seattle test 192
 - monitoring devices required 135
 - superselective
 - complications 197
 - indications 197
 - technique 197–198
 - technique 194–196
 - Waldenstrom’s macroglobulinemia 590
 - Wallenberg syndrome (*see also* Artery, posterior inferior cerebellar (PICA) syndrome) 618t
 - and dissecting aneurysms 489
 - Wallstent (*see also* Stent), Wallstent 358
 - Warfarin 105, 576, 578t, 579, 580, 581, 585, 588, 599
 - hemorrhagic complications 578t
 - and intracranial stenosis 680–682
 - stroke risk reduction 578t
 - Warfarin-induced skin necrosis 581t
 - Warfarin vs. Aspirin for Symptomatic Intracranial Disease (WASID) 680–682
 - WASID (*see* Warfarin vs. Aspirin for Symptomatic Intracranial Disease)
 - Watermelon seeding 361
 - Watershed syndrome 613, 618
 - ACA-MCA 608
 - Waters view 96f, 97t
 - Weber syndrome 614t
 - Wedged technique 233f
 - Wegener’s granulomatosis 600t, 601
 - Whole brain method (of CT perfusion) 332–333, 336
 - Williams syndrome
 - and moyamoya syndrome 691
 - Willis, Thomas (*see also* Circle of Willis) 40
 - Wilm’s tumor
 - and moyamoya syndrome 691
 - Wingspan stent
 - in acute stroke 327
 - device specifications 371
 - procedure 370–373
 - Wingspan clinical trial 683
 - Wire
 - ATW Marker wire 98
 - Glidewire 91, 382, 387, 391, 396, 406, 408
 - J-tip 381, 387
 - J-wire 90, 98
 - Women Estrogen Stroke Trial (WEST) 589t
 - Women’s Health Initiative (WHI) 589t
 - Wren, Christopher 40
 - Wyburn-Mason syndrome 514
- ## X
- Xact stent 358
 - Xenon 133 imaging
 - in balloon test occlusion 182
 - Xenon-CT
 - in balloon test occlusion 182
 - and carotid occlusion 661
- ## Y
- Yasargil classification
 - of Vein of Galen malformations 414, 527
 - Yasargil, Gazi 88, 661
- ## Z
- Zonisamide
 - and Wada test, 193
 - Zyban (*see* Bupropion)